

# We are IntechOpen, the world's leading publisher of Open Access books Built by scientists, for scientists

4,800

Open access books available

122,000

International authors and editors

135M

Downloads

Our authors are among the

154

Countries delivered to

TOP 1%

most cited scientists

12.2%

Contributors from top 500 universities



WEB OF SCIENCE™

Selection of our books indexed in the Book Citation Index  
in Web of Science™ Core Collection (BKCI)

Interested in publishing with us?  
Contact [book.department@intechopen.com](mailto:book.department@intechopen.com)

Numbers displayed above are based on latest data collected.  
For more information visit [www.intechopen.com](http://www.intechopen.com)



---

# Image-Guided Adaptive Brachytherapy for Cervical Cancer Using Magnetic Resonance Imaging: Overview and Experience

---

Kenji Yoshida, Ryo Nishikawa, Daisuke Miyawaki,  
Yasuhiko Ebina and Ryohei Sasaki

Additional information is available at the end of the chapter

<http://dx.doi.org/10.5772/67382>

---

## Abstract

Image-guided adaptive brachytherapy (IGABT) using magnetic resonance imaging (MRI) has been accepted as a novel treatment technique for cervical cancer. During the development of MRI-based IGABT, a very important concept called “High-risk clinical target volume (HR-CTV)” was introduced. However, computed tomography (CT)-based IGABT is the most common modality in Japan.

MRI-based IGABT was initiated in September 2014 at Kobe University Hospital and 50 patients were treated through March 2016. Although a total HR-CTV D90 ranging from 80 to 85 Gy equivalent dose in 2 Gy fractions in combination with 45 Gy of external beam radiotherapy (EBRT) and 7 Gy×4 fractions of IGABT is the most standard treatment aim in European institutions, our aim for a total HR-CTV D90 was a 70–80 Gy because of the use of the central shielding technique for the protection of organs at risk in the late phase of EBRT.

The mean total HR-CTV D90 for our 50 patients was 77 Gy. Although our aim was achieved, it was relatively low because Japanese radiotherapy protocols for cervical cancer still differ from those in European institutions. Therefore, a new treatment protocol, which is closer to the global standard, should be established.

**Keywords:** image-guided adaptive brachytherapy, high-risk clinical target volume, D90, D2cc, magnetic resonance imaging

## 1. Introduction

Image-guided adaptive brachytherapy (IGABT) using magnetic resonance imaging (MRI) has been widely accepted as a novel treatment technique for gynecologic malignancies, especially for cervical cancer. In 2005, the primary concept of IGABT, which is high-risk clinical target volume (HR-CTV), was described by the Gynaecologic (GYN) GEO-ESTRO working group [1]. Around the same time, the first clinical report on the effectiveness of MRI-based IGABT was published by Pötter et al. [2]. In that study, 44 of 48 patients had stage IIB to IVA disease. Overall survival at 3 years was 61%, progression-free survival was 51%, and continuous complete remission for true pelvis was 85% with a median follow up of 33 months.

By using MRI or computed tomography (CT), three-dimensional (3D) description of the HR-CTV and the organs at risk (OAR), such as the bladder, rectum, sigmoid colon, and small bowel, can be achieved. Therefore, dosimetric evaluation for both the HR-CTV and OAR using dose volume histograms (DVH) can be performed with greater accuracy than that with traditional point A treatment planning using the definition of the ICRU report 38 for the OAR doses [3]. The GYN GEO-EATRO working group also published recommendations regarding the 3D dosimetric parameters [4]. Although various dosimetric parameters were described by GYN GEO-EATRO, HR-CTV D90 and OAR D2cc have been emphasized in clinical brachytherapy (BT). The working group also published recommendations for the acquisition protocols of MRI sequences [5].

Implementation of IGABT made it possible to use interstitial needles more safely. This is one of the most important points in performing IGABT, because the use of interstitial needles can change the dose distribution dramatically, especially in large tumors. In European institutions, MRI-based IGABT is a common technique and interstitial needles are frequently used. However, CT-based IGABT is most common in Japanese institutions and interstitial needles are less frequently used than in European institutions. In addition, 3D-conformal radiotherapy (3D-CRT) with a central shielding (CS) technique for the protection of OAR from higher doses has been applied as the standard external beam radiotherapy (EBRT) for many years at most Japanese institutions, even after the introduction of intensity-modulated radiotherapy (IMRT), which is performed without a CS technique at many European institutions. Therefore, radiotherapy (RT) for cervical cancer in Japan is somewhat different from that in institutions in other countries.

MRI-based IGABT for cervical cancer was initiated at Kobe University Hospital in September 2014 and 50 patients were treated with definitive IGABT through March 2016. Similar to other institutions in Japan, for EBRT, a 3D-CRT with a CS technique is still performed. Interstitial needles are applied for some patients with large tumors. The purpose of this chapter is to provide an overview of MRI-based IGABT and the introduction of the experience at Kobe University Hospital along with a comparison with European representative institutions.

## 2. Applicators for IGABT

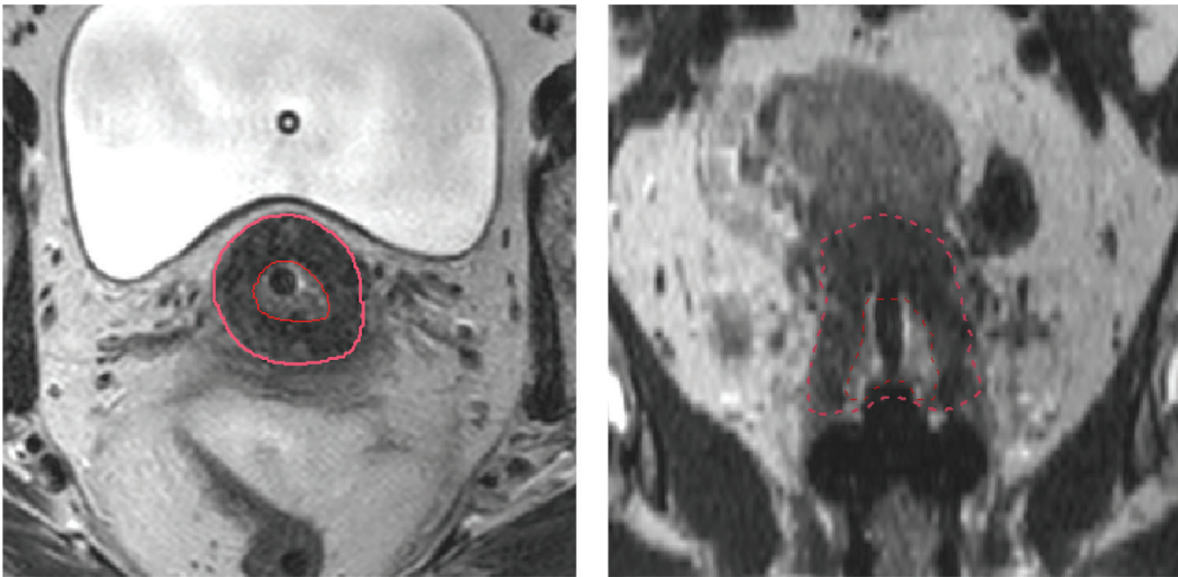
Applicators compatible with MRI must be used for MRI-based IGABT. Even if CT-based IGABT is performed, traditional stainless steel applicators should not be used because severe metal artifacts may occur when CT images are acquired. Tandem and ovoid applicators are used most frequently in Japanese institutions.

The Medical University of Vienna, the most representative institution in Europe, and a lot of other institutions in other countries have used Vienna applicators compatible with MRI that were developed for combined intracavitary (IC) and interstitial (IS) BT [6]. This applicator has a tandem and a ring part. The ring part includes the source pathway and it also has a templated function for titanium interstitial needle implantation. By setting the dwell point in the ring, a dose distribution the same as when using a tandem and ovoid applicator can be developed. Therefore, both MRI-based IC-BT alone and combined with IC- and IS-BT can be performed by using the Vienna applicator. Unfortunately, this applicator is not allowed to be used in Japan. In addition, only plastic or stainless steel needles are available for IGABT. When using stainless steel needles, MRI cannot be performed after needle implantation. CT-based IGABT, or acquisition of MR images before needle implantation and fusion of the MRI images to the CT images acquired after needle implantation, is one of the ways to deal with this problem. Plastic needles are also compatible with MRI; however, these are not suitable for hard tumors because of the dull edge. Metal stainless needles may help to create a pathway for plastic needles. After pathway preparation with metal stainless needles, implantation may be easier and acquisition of MR images can be achieved.

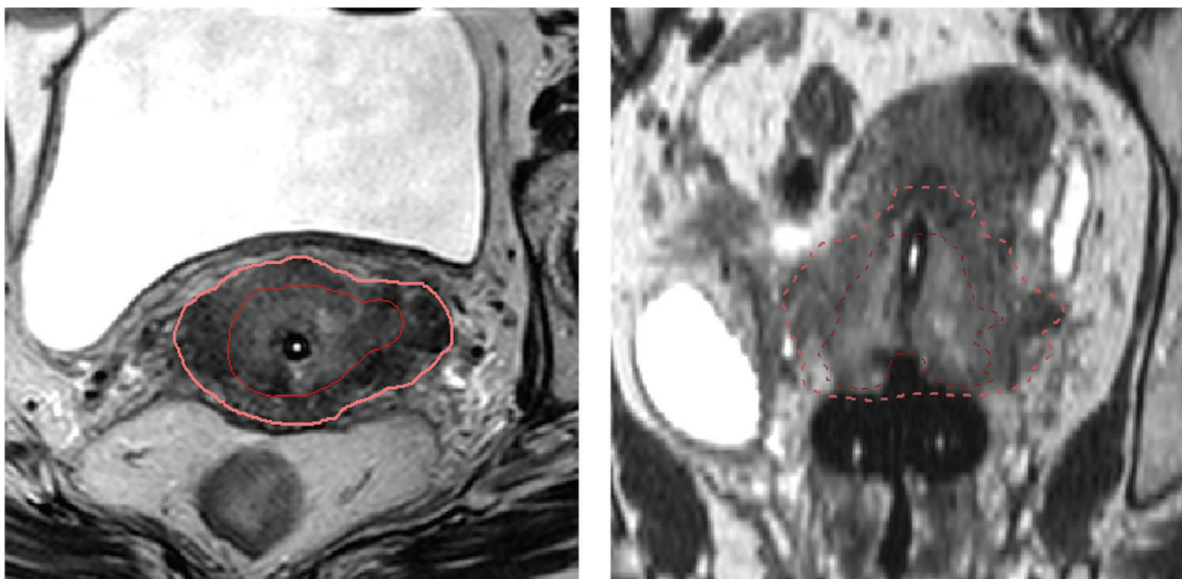
Jürgenliemk-Schulz et al. investigated the potential benefit of newly designed tandem and ovoid applicators compatible with IC- and IS-BT using plastic needles [7]. They performed MRI-based IGABT using the applicators in six patients and reported that additional improvement was achieved with a combined IC/IS approach. The results are encouraging because the newly developed applicators for both IC/IS approaches may be used in many countries including Japan, resulting in significant progress in IGABT.

## 3. Definition of high risk clinical target volume (HR-CTV)

The most important target volume in IGABT, the HR-CTV, can be defined at the time of first BT. In the recommendations from the GYN GEO-ESTRO working group, a brief definition of HR-CTV in 3D image-based 3D treatment is described as follows (1) carrying a high tumor load, includes the gross tumor volume (GTV) and always includes the whole cervix and presumed extracervical tumor extension at the time of BT. Limited disease is defined as a tumor less than 4 cm and/or limited to the cervix at the time of diagnosis. Therefore, in such cases, the whole cervix including the GTV at BT corresponds to the HR-CTV. For extensive disease, presumed tumor extension is defined by clinical examination (visualization and palpation) and imaging (MRI). Interstitial needles are usually required in such extensive cases. Examples of HR-CTVs of both limited and extensive cases treated at Kobe University are shown in **Figures 1** and **2**.



**Figure 1.** HR-CTV (pink and outer line) and GTV (red and inner line) of limited disease delineated on axial image (original) and coronal image (reconstructed).



**Figure 2.** HR-CTV (pink and outer line) and GTV (red and inner line) of extensive disease delineated on axial image (original) and coronal image (reconstructed).

## 4. IGABT procedure (Kobe University Hospital)

### 4.1. Anesthesia

To perform more appropriate IGABT, appropriate anesthesia is very important. There are four types of anesthesia and combinations as follows: general anesthesia, lumbar subarachnoid spinal nerve block, sacral epidural block, and intravenous sedation. Intravenous sedation

is inadequate to perform appropriate IGABT and therefore should only be performed in patients who cannot safely receive other anesthesia modalities. Lumbar subarachnoid spinal nerve block seems to be better than sacral epidural block. However, sacral epidural block may be better for patients receiving anticoagulation therapy. In addition, anesthesia should be performed by an anesthetist for patient safety. Lumbar subarachnoid spinal nerve block or sacral epidural block is performed most frequently. In our institution, the first choice for IGABT is a lumbar subarachnoid spinal nerve block. A sacral epidural block is the second choice for patients receiving anticoagulation therapy or those with severe medical complications.

#### 4.2. Flow of IGABT

Applicator implantation should be performed using transrectal ultrasound. This is important for guidance during dilatation of the cervical canal and tandem implantation. X-ray is also useful. If available in the BT room, CT is very useful to verify the final position of the applicators, and also to perform needle implantation. Moreover, when CT-based planning is performed, the entire BT procedure (implant, imaging, planning, and irradiation) can be done in the same room. Therefore, if an institution is going to initiate IGABT, the most important thing is to place CT in the BT room.

When MRI-based IGABT is performed, patients must be transported to the MRI room. Transfer must be performed as quickly as possible for safety and the MRI protocol must be limited to that necessary for treatment. After acquisition of MR images, treatment planning, and irradiation is performed.

#### 4.3. Imaging protocols

For the acquisition of MR images, a 1.5 or 3.0 T machine is recommended. T2-weighted images (WI) with transverse sections are necessary for treatment planning. Sagittal sections are also important. Diffusion-weighted images (DWI) are optional but are useful to define GTV. As an example, details of MRI performed at Kobe University Hospital are shown in **Table 1**.

Sequence	Slice thickness (mm)	No. of slices	Imaging time (seconds)
T2WI (transverse)	2	70	308
T2WI (sagittal)	2.5	40	85
DWI	5	25	263

Notes: T2WI: T2 weighted image, DWI: diffusion weighted image.

**Table 1.** MR imaging protocol at Kobe University.

## 5. Treatment

### 5.1. Treatment schedule and details of EBRT

The Japanese protocol for EBRT and BT for cervical cancer is shown in **Table 2a**. Most institutions, including Kobe University Hospital, still use this protocol. Most patients are treated

with 3D conformal pelvic irradiation (PI), with a total dose of 50.4 Gy in 28 fractions. At first, whole pelvic irradiation (WPI) is performed, and then WPI with a CS technique is performed. Generally, BT is initiated at the end of the WPI period and before the start of PI with a CS technique. Most patients are treated with three or four sessions of BT given once or twice a week. Regarding combined WPI and CS technique, 30.6 Gy in 17 fractions of WPI and 19.8 Gy in 11 fractions with CS technique are used for International Federation of Gynecologists and Obstetricians (FIGO) stage IB to IIB disease. For more advanced disease, 41.4 Gy in 23 fractions of WPI and 9.0 Gy in 5 fractions with CS technique are used. Paraaortic regional irradiation is added for patients with gross metastases. For lymph node metastases, an additional 10 Gy in 5 fractions is usually applied to each metastatic region.

In contrast with the Japanese protocol, many foreign institutions such as Medical University of Vienna deliver EBRT consisting of 45 Gy in 25 fractions without using a CS technique; at the end of EBRT, 4 fractions of BT are administered. IMRT is usually performed. The treatment schedules at representative institutions are also shown in **Table 2b** for direct comparison with the Japanese protocol. CS technique is not used by all institutions [8–12].

## 5.2. Treatment planning for BT

### 5.2.1. Applicator reconstruction

Fusion of CT and MR images is necessary for BT treatment planning, even for MRI-based IGABT, if the positions of the sources cannot be identified correctly due to the lack of simulated sources compatible with MRI (**Figure 3a**). To achieve true MRI-based treatment planning, home-made catheters using flexible tubes filled with normal saline solution for interstitial BT that were compatible with MRI were used as simulated sources (**Figure 3b**). Using these catheters, positions of the sources could be described very clearly. By using the system included in the Oncentra Brachy applicator placement technique and these catheters, it is possible to achieve true MRI-based treatment planning for patients treated with IC-BT (**Figure 4**).

### 5.2.2. Delineation of target and OAR

The GTV and HR-CTV are delineated based on the recommendations from GYN GEO-ESTRO [1]. The intermediate risk clinical target volume (IR-CTV) is automatically delineated with a 5–15 mm margin from the HR-CTV, excluding the OAR.

FIGO stage, tumor size	WPI (Gy)	CS technique (Gy)	HDR-BT (to point A)
Ib1, II (small)	20	30	6 Gy × 4 fractions
Ib2, II (large), III	30	20	6 Gy × 4 fractions
	40	10	6 Gy × 3 fractions
IVA	40	10	6 Gy × 3 fractions
	50	0	6 Gy × 2 fractions

Notes: WPI: whole pelvic irradiation, CS: central shielding, HDR-BT: high dose rate brachytherapy.

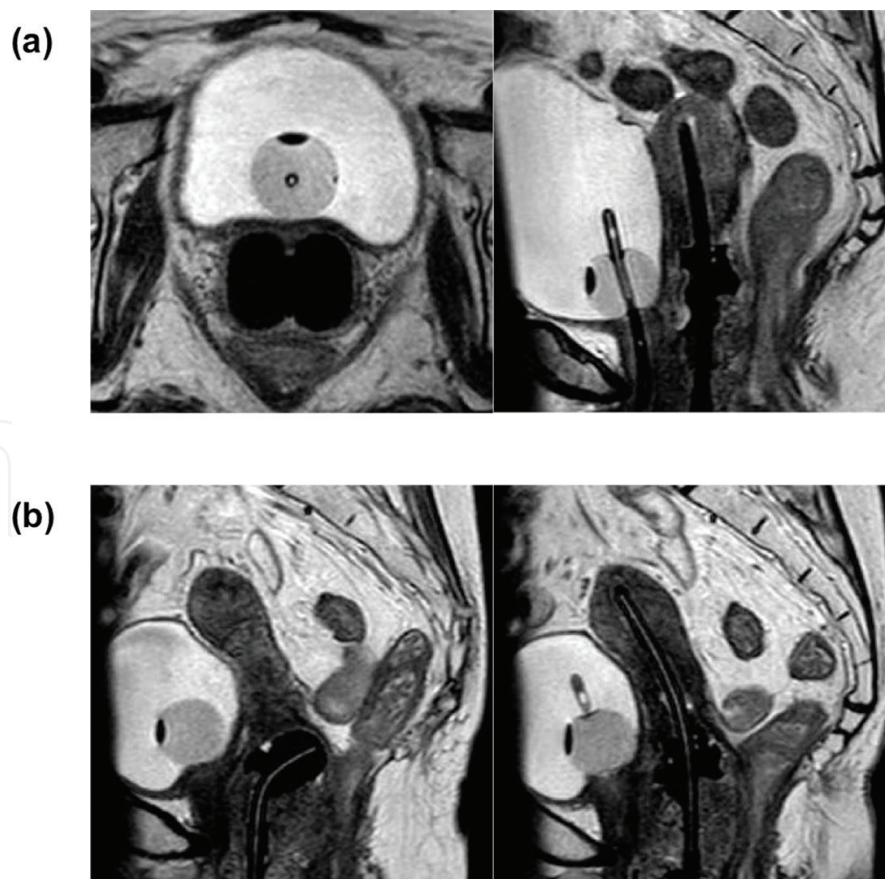
**Table 2a.** Details of Japanese treatment protocol for cervical cancer.

Institutions	WPI (Gy)	CS technique (Gy)	HDR-BT (to HRCTV)
Medical University of Vienna [8]	45	0	7 Gy × 4 fractions
University Medical Center Utrecht [9]	45	0	7 Gy × 4 fractions
University of Pittsburgh Medical Center [10]	45	0	25–30 Gy in 5 fractions
Leiden University Medical Center [11]	46 or 45–50.4	0	7 Gy × 3 or, 8.5 Gy × 2 fractions
University of California San Diego [12]	45	0	25–30 Gy in 3–5 fractions

Notes: WPI: whole pelvic irradiation, CS: central shielding, HDR-BT: high dose rate brachytherapy, HRCTV: high risk clinical target volume.

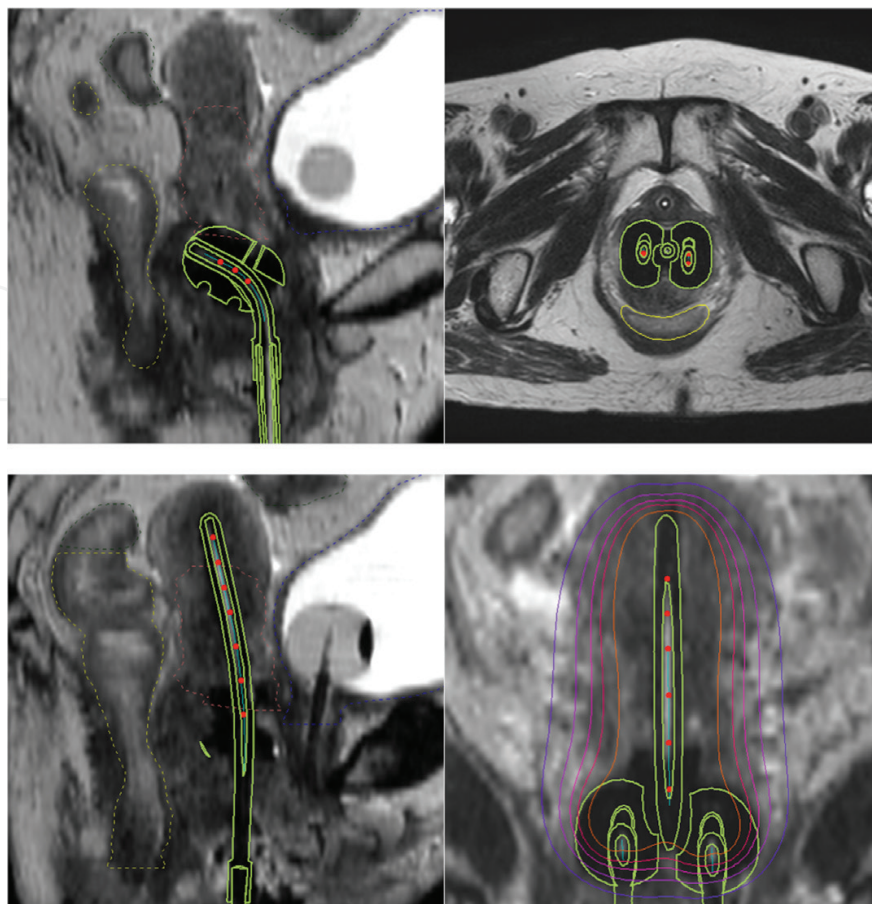
**Table 2b.** Details of treatment protocols for cervical cancer at the representative institutions.

The rectum, bladder, sigmoid colon, and small bowel are delineated using MR images. The bladder is usually filled with 100 mL of normal saline solution to avoid high doses to the small bowels before the acquisition of images. If necessary, the urethra is also delineated.



**Figure 3.** (a) MR images for treatment planning without simulated sources. (b) MR images for treatment planning with simulated sources consisting of flexible tube for interstitial BT.





**Figure 4.** MRI-based treatment planning of intracavitary BT using simulated sources and applicator placement technique.

### 5.2.3. Treatment aim for dosimetric parameters

#### 5.2.3.1. HR-CTV

The most important dosimetric parameter of the target is the HR-CTV D90. Our primary treatment aim is that the HR-CTV D90 should be more than 7.0 Gy per implant with a total of 70–80 Gy equivalent dose in 2 Gy fractions (EQD2) calculated by using the following formula:

$$\text{EQD2} = n * d * ((d + \alpha/\beta)/(2 + \alpha/\beta)) \quad (1)$$

where  $n$  is the number of fractions,  $d$  is the single fraction dose, tumor  $\alpha/\beta = 10$ , normal tissue  $\alpha/\beta = 3$ .

Total HR-CTV D90s calculated from the single fraction dose and the number of fractions of IGABT and WPI are shown in **Table 3a**. Doses for pelvic irradiation with the CS technique are not included. At other representative institutions, the total HR-CTV D90 is usually aimed at more than 85 Gy in EQD2. In previous reports, Nomden et al. reported that the mean HR-CTV D90 in EQD2 was 84 Gy [9]. Simpson et al. reported that the mean HR-CTV D90 was 86.3 Gy [12]. Although our HR-CTV D90 per implant was equivalent to that in other institutions [8, 9],

HR-CTV D90 in IGABT single dose × fractions (Gy)	WPI: single dose × fractions (total) (Gy)			
	1.8 × 17 (30.6)	1.8 × 23 (41.4)	1.8 × 25 (45)	1.8 × 28 (50.4)
Total HR-CTV D90 in 3/4 fractions (Gy, EQD2)				
6.5 × 3/4	56.9/65.8	67.5/76.5	71.1/80.0	76.4/85.3
7 × 3/4	59.8/69.8	70.5/80.4	74/83.9	79.3/89.2
7.5 × 3/4	62.9/73.8	73.5/84.5	77.1/88.0	82.4/93.3
8 × 3/4	66.1/78.1	76.7/88.7	80.3/92.3	85.6/97.6
8.5 × 3/4	69.4/82.5	80.0/93.1	83.4/96.7	88.9/102.0
9 × 3/4	72.8/87.1	83.5/97.7	87.0/101.3	92.3/106.6

Notes: HR-CTV: high risk clinical target volume, EQD2: equivalent dose in 2 Gy fractions, IGABT: image-guided adaptive brachytherapy, WPI: whole pelvic irradiation.

**Table 3a.** Total HR-CTV D90 (EQD2) calculated from the single dose and number of fractions of IGABT and WPI.

the goal of total D90 was set lower because the use of the CS technique might hinder delivery of higher D90.

#### 5.2.3.2. OAR

For the OAR, D2cc is recognized as the most important dosimetric parameter. In clinical IGABT, bladder, rectum, sigmoid colon, and small bowel D2cc must be calculated and recorded for every implant. The proposed upper limit of the total bladder dose is 85 Gy with a maximum of 90 Gy in EQD2. Those of the total rectum, sigmoid colon, and small bowel are 70 Gy with a maximum of 75 Gy in the EQD2. The upper limit of single OAR doses (non-EQD2) in IGABT calculated from the total OAR D2cc and WPI dose are shown in **Table 3b**. Doses from PI with the CS technique are not included. As for these OARs, many previous studies used similar criteria [8–10, 12].

Total D2cc in EQD2 (Gy)	WPI: single dose × fractions (total) (Gy)			
	1.8 × 17 (30.6)	1.8 × 23 (41.4)	1.8 × 25 (45)	1.8 × 28 (50.4)
Upper limit of single OAR dose in 3/4 fractions (Gy, non-EQD2)				
Bladder				
85	8.2/6.9	7.3/6.1	6.9/5.8	6.4/5.4
90	8.6/7.3	7.7/6.5	7.4/6.2	6.9/5.8
Rectum and other bowels				
70	6.8/5.7	5.7/4.8	5.3/4.4	4.6/3.9
75	7.3/6.1	6.3/5.3	5.9/4.9	5.3/4.4

Notes: EQD2: equivalent dose in 2 Gy fractions, OAR: organ at risk, WPI: whole pelvic irradiation.

**Table 3b.** Upper limit of single OAR doses (non-EQD2) in IGABT calculated from the total OAR D2cc and WPI dose.

#### 5.2.4. Dose prescription and optimization

##### 5.2.4.1. Intracavitary BT

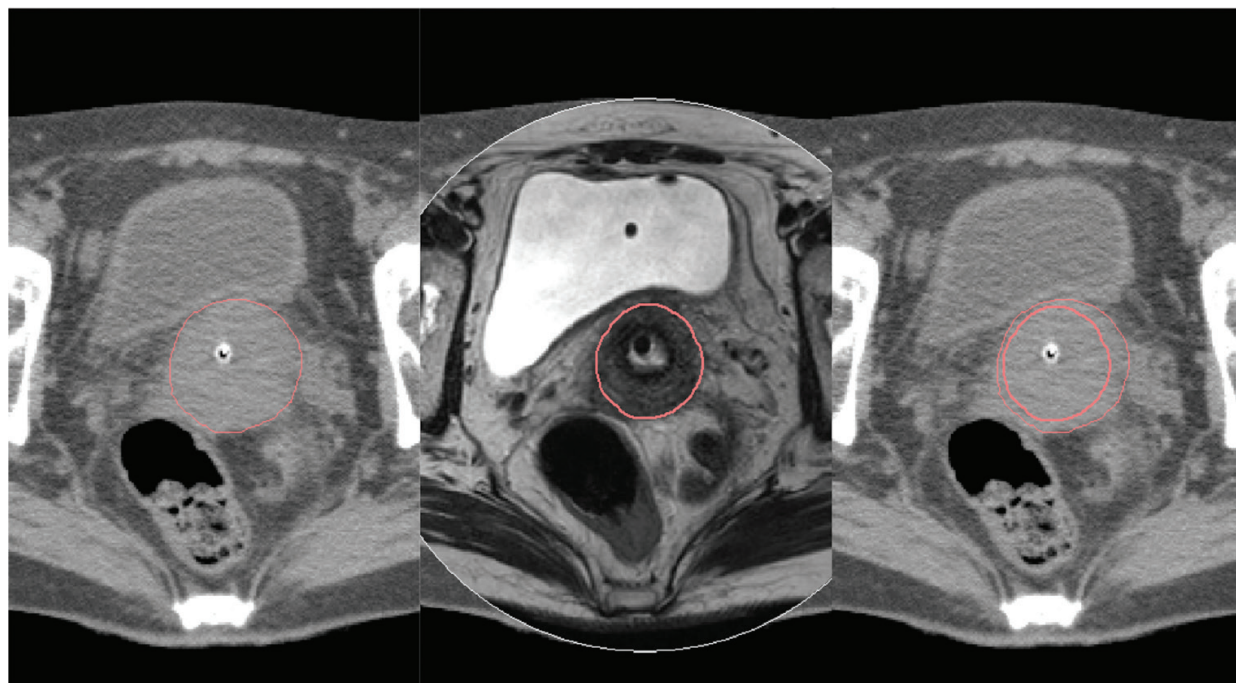
The basic treatment plan prescribed to point A according to Japanese guidelines is first created for every implant. The point A dose is 6.0 Gy. Then, graphical optimization is performed to achieve the treatment aim for both the HR-CTV and the OAR.

##### 5.2.4.2. Combined intracavitary/interstitial BT

Similar to intracavitary BT, a basic plan prescribed to point A (6.0 Gy) is first created. Next, optimization of the intracavitary applicator is performed to reduce the doses to the OAR. Then, the interstitial needles are activated to increase the target coverage. Additional optimization is usually performed to achieve the treatment aim.

### 5.3. Limitations of CT-based planning

In performing CT-based planning, the most important limitation is inaccurate delineation of the HR-CTV. CT-based delineation is often very different from MRI-based delineation (**Figure 5**). The HR-CTV D90 may be significantly affected by the difference in imaging modality at BT (MRI or CT). Hegazy et al. reported that CT-based HR-CTV contouring based on FIGO stage led to a large overestimation of the width and volume. They concluded that if only CT was available, a minimum two-third of the uterine height might be a good surrogate for the height of the HR-CTV [13]. Clinical gynecologic examination and acquisition of MR images just before the start of BT can help to improve the accuracy of delineation.



**Figure 5.** Comparison of CT-based and MRI-based delineation of HRCTV. CT-based delineation is quite large compared to MRI-based delineation.

## 6. Reported treatment results

There are an increasing number of published reports regarding treatment results of IGABT for cervical cancer as shown in **Table 4** [8–12, 14–17]. In 2011, Pötter et al. retrospectively analyzed 156 patients with FIGO stage IB to IVA cervical cancer treated by IGABT at Medical University of Vienna [8]. A combined IC/IS approach was used in 44% of the patients with residual disease at the time of BT. They reported the three-year overall survival (OS) rates for stage IB, IIB, and IIIB disease were 74, 79, and 45%, respectively. They also reported that three-year local control (LC) rates for stage IB, IIB, and IIIB disease were 100, 96, and 86%, respectively. These results indicate that IGABT can achieve excellent LC rates even in cases of unfavorable advanced disease, such as stage IIIB disease, by using interstitial needles.

In a recent large multicenter study called RetroEMBRACE, Sturdza et al. analyzed 731 patients [17]. They reported that three-year overall survival rates for stage IB, IIB, and IIIB patients

Author (year)	No. of patients	median follow up (months)	Imaging	mean HRCTV D90 (SD) in EQD2 (Gy)	LC rate (%)	CSS rate (%)	OS rate (%)
Pötter et al. (2011) [8]	156	42	MRI	93 (13)	95 (3-year)	74 (3-year)	68 (3-year)
Lindegaard et al. (2013) [14]	140	36	MRI	91	91 (3-year)	87 (3-year)	79 (3-year)
Nomden et al. (2013) [9]	46	41	MRI	84 (9)	93 (3-year)	74 (3-year)	65 (3-year)
Gill et al. (2014) [10]	128	24.4	MRI	83.2 (2.7)	91.6 (3-year)	85.4 (3-year)	76.6 (3-year)
Rijkmans et al. (2014) [11]	83	42.3	MRI	80.8	NA	NA	86 (3-year)
Castelnaud-Marchand et al. (2015) [15]	225	38.8	MRI	80.4 (10.3)	86.4 (3-year)	NA	76.1 (3-year)
Simpson et al. (2015) [12]	76	17	CT	86.3 (8.1)	NA	NA	75 (2-year)
Ribeiro et al. (2016) [16]	170	37	MRI	85 (8.4)	96 (3-year)	NA	73 (3-year)
Sturdza et al. (2016) [17]	731	43	MRI/CT	87 (15)	91 (3-year)	79 (3-year)	74 (3-year)

Notes: IGABT: image-guided adaptive brachytherapy, HR-CTV: high risk clinical target volume, LC: local control, CSS: cancer specific survival, OS: overall survival.

**Table 4.** Reported treatment results of IGABT for cervical cancer.

were 88, 78, and 56%, respectively. They also reported that three-year LC rates were 98, 93, and 79%, respectively. These results indicate that IGABT is an indispensable treatment tool to achieve excellent LC rates. Lindegaard et al. compared the treatment results of MRI-guided IGABT to X-ray-based BT [14]. Both OS and cancer-specific survival (CSS) rates were significantly better in the patient group treated with MRI-guided IGABT.

The mean total HR-CTVs in these reports ranged from 80.3 to 93 Gy in EQD2. All of the total HR-CTV D90s were more than 80 Gy. In our experience with IGABT for 50 cervical cancer patients, the mean total HR-CTV D90 was 77.0 Gy, lower than that at the representative centers. This difference was caused by the CS technique. According to other reports from Japan, although treatment outcomes were excellent, HR-CTV D90s were less than 70 Gy [18, 19]. These results are also lower than our findings. The studies used CT-based planning, which also accounted for the large difference when combined with CS technique. It is likely that a larger HR-CTV delineated using CT and a lower WPI dose combined with CS technique resulted in a significantly lower D90. MRI-based planning without CS technique might achieve HR-CTV D90 comparable to that in foreign institutions. More institutions in Japan should perform MRI-based planning because it may become the global standard. Use of CS technique should also be discussed.

In summary, the use of IGABT can help achieve excellent LC even in advanced stage cervical cancer with the help of interstitial needles. Survival results with IGABT showed superiority to those achieved with traditional X-ray-based BT. HR-CTV D90 can be easily affected by imaging modality and variability of EBRT dosing. However, 45 Gy of WPI and MRI-based treatment planning aiming for a total HR-CTV D90 from 80 to 85 Gy should be considered the most appropriate treatment regimen.

## 7. Treatment-related adverse events

Late bladder, gastrointestinal, and vaginal toxicities have been reported by previous studies. In the Retro-EMBRACE study [17], five-year Grade 3–5 toxicity in the bladder, gastrointestinal tract, and vagina among 610 patients affected 5, 7, and 5%, respectively. Ribeiro et al. also reported Grade 3–4 late rectal, urinary, sigmoid, and vaginal morbidity rates were 5, 6, 2, and 5%, respectively, in their long-term treatment outcome study [16]. They also identified a correlation between rectal D2cm<sup>3</sup> > 65 Gy and Grade > 3 late morbidity. Among patients treated at Kobe University Hospital, Grade 3 rectal toxicity occurred in two (4%) patients. No Grade 3 or greater late bladder and vaginal toxicities have occurred to date.

Acute toxicities are rarely reported in published studies. According to our experience, hematological toxicity is the most frequent, especially in patients treated with concurrent chemoradiotherapy (CCRT). Among the 50 patients treated at Kobe University Hospital, Grade 3 or greater acute hematologic toxicity occurred in 36 (72%) patients. Procedure-related complications should also be reported. In the early period, mild pressure ulcers around the buttocks occurred in five patients. Respiratory suppression occurred in one patient who received intravenous sedation. In addition, interstitial needles may cause severe complications. The most common is bleeding. It is sometimes difficult to manage extravaginal bleeding caused by laceration of the vaginal wall. It is also important to be aware of possible intraabdominal bleeding.

This may be caused by injury to the uterine arteries. Performing CT immediately after removal of the applicators may be useful for the early detection of intraabdominal bleeding.

In summary, according to the results from previous studies and our experience, Grade  $\geq 3$  late treatment-related toxicity occurs in approximately 5% of patients. Acute severe hematologic toxicity frequently occurs in patients treated with CCRT. The role of the CS technique performed for the protection of OAR from higher doses should be discussed from the aspect of toxicity. Monitoring is essential for procedure-related complications. Interstitial needles can cause severe complications. It is necessary to improve procedures, including needle implantation, to prevent complications.

## 8. Conclusions

In this chapter, an overview of our experience of MRI based-IGABT for cervical cancer was described. IGABT using MRI has been widely accepted, especially in European countries, and the combination of 45 Gy in 25 fractions of EBRT without using a CS technique and more than 7 Gy  $\times$  4 fractions for HR-CTV is the most standard protocol. Pelvic IMRT has been increasingly performed. The total EQD2 delivered in this protocol is usually more than 85 Gy. Interstitial needles are often implanted for large tumors using a Vienna ring applicator, which is very suitable for combined IC/IS BT because the ring part has the source pathway and can be used as the template of the needles. Tandem and ovoid applicator which had function for the template of the interstitial needles were also reported [7]. Increasing numbers of treatment results have been reported, and the impressive role of IGABT, especially in LC, has been demonstrated when delivering more than 80 Gy as a mean total HR-CTV D90s. Therefore, many representative institutions aimed at least more than 80 Gy [9–13]. Although MRI-based IGABT has been performed since September 2014 at Kobe University, CT-based IGABT still has been performed at most Japanese institutions because of various circumstances, and interstitial needles are less frequently used. CT-based IGABT is well established; however, considerable differences in the delineation of HR-CTV can occur as compared to MRI-based BT. In addition, we continue to use a CS technique with EBRT and pelvic IMRT has not been accepted in the definitive RT for cervical cancer. Therefore, although successful outcomes were reported [18, 19], RT for cervical cancer in Japan is still different from that in European countries in both BT and EBRT. In the immediate future, a new treatment protocol (MRI-or CT-based? with or without the CS technique? 3D-CRT or IMRT?), which is closer to the global standard, should be established for the further development of RT treatment of cervical cancer in Japan.

## Author details

Kenji Yoshida<sup>1\*</sup>, Ryo Nishikawa<sup>1</sup>, Daisuke Miyawaki<sup>1</sup>, Yasuhiko Ebina<sup>2</sup> and Ryohei Sasaki<sup>1</sup>

\*Address all correspondence to: [kyoshi@med.kobe-u.ac.jp](mailto:kyoshi@med.kobe-u.ac.jp)

<sup>1</sup> Division of Radiation Oncology, Kobe University Graduate School of Medicine, Kobe, Japan

<sup>2</sup> Department of Gynecology, Kobe University Graduate School of Medicine, Kobe, Japan

## References

- [1] Haie-Meder C, Pötter R, Van Limbergen E, Briot E, De Brabandere M, Dimopoulos J, Dumas I, Hellebust TP, Kirisits C, Lang S, Muschitz S, Nevinson J, Nulens A, Petrow P, Wachter-Gerstner N. Gynaecological (GYN) GEC-ESTRO Working Group. Recommendations from Gynaecological (GYN) GEC-ESTRO Working Group (I): concepts and terms in 3D image based 3D treatment planning in cervix cancer brachytherapy with emphasis on MRI assessment of GTV and CTV. *Radiother Oncol.* 2005 Mar;74(3):235–245. Review.
- [2] Pötter R, Dimopoulos J, Bachtiry B, Sissolak G, Klos B, Rheinthaller A, Kirisits C, Knocke-Abulesz TH. 3D conformal HDR-brachy- and external beam therapy plus simultaneous cisplatin for high-risk cervical cancer: clinical experience with 3-year follow-up. *Radiother Oncol.* 2006 Apr;79(1):80–86. Epub 2006 Mar 3.
- [3] International Commission on Radiation Units and Measurements. Dose and volume specification for intracavity therapy in gynecology. 1985, ICRU report 38. ICRU, Washington
- [4] Pötter R, Haie-Meder C, Van Limbergen E, Barillot I, De Brabandere M, Dimopoulos J, Dumas I, Erickson B, Lang S, Nulens A, Petrow P, Rownd J, Kirisits C; GEC ESTRO Working Group. Recommendations from Gynaecological (GYN) GEC ESTRO working group (II): concepts and terms in 3D image-based treatment planning in cervix cancer brachytherapy-3D dose volume parameters and aspects of 3D image-based anatomy, radiation physics, radiobiology. *Radiother Oncol.* 2006 Jan;78(1):67–77. Epub 2006 Jan 5.
- [5] Dimopoulos JC, Petrow P, Tanderup K, Petric P, Berger D, Kirisits C, Pedersen EM, van Limbergen E, Haie-Meder C, Pötter R. Recommendations from Gynaecological (GYN) GEC-ESTRO Working Group (IV): basic principles and parameters for MR imaging within the frame of image based adaptive cervix cancer brachytherapy. *Radiother Oncol.* 2012 Apr;103(1):113–22. doi: 10.1016/j.radonc.2011.12.024. Epub 2012 Jan 30.
- [6] Kirisits C, Lang S, Dimopoulos J, Berger D, Georg D, Pötter R. The Vienna applicator for combined intracavitary and interstitial brachytherapy of cervical cancer: design, application, treatment planning, and dosimetric results. *Int J Radiat Oncol Biol Phys.* 2006 Jun 1;65(2):624–30.
- [7] Jürgenliemk-Schulz IM, Tersteeg RJ, Roesink JM, Bijmolt S, Nomden CN, Moerland MA, de Leeuw AA. MRI-guided treatment-planning optimisation in intracavitary or combined intracavitary/interstitial PDR brachytherapy using tandem ovoid applicators in locally advanced cervical cancer. *Radiother Oncol.* 2009 Nov;93(2):322–30. doi: 10.1016/j.radonc.2009.08.014.
- [8] Pötter R, Georg P, Dimopoulos JC, Grimm M, Berger D, Nesvacil N, Georg D, Schmid MP, Reinthaller A, Sturdza A, Kirisits C. Clinical outcome of protocol based image (MRI) guided adaptive brachytherapy combined with 3D conformal radiotherapy with or without chemotherapy in patients with locally advanced cervical cancer. *Radiother Oncol.* 2011 Jul;100(1):116–23. doi: 10.1016/j.radonc.2011.07.012. Epub 2011 Aug 5.

- [9] Nomden CN, de Leeuw AA, Roesink JM, Tersteeg RJ, Moerland MA, Witteveen PO, Schreuder HW, van Dorst EB, Jürgenliemk-Schulz IM. Clinical outcome and dosimetric parameters of chemo-radiation including MRI guided adaptive brachytherapy with tandem-ovoid applicators for cervical cancer patients: a single institution experience. *Radiother Oncol*. 2013 Apr;107(1):69–74. doi: 10.1016/j.radonc.2013.04.006. Epub 2013 Apr 29.
- [10] Gill BS, Kim H1, Houser CJ, Kelley JL, Sukumvanich P, Edwards RP, Comerici JT, Olawaiye AB, Huang M, Courtney-Brooks M, Beriwal S. MRI-guided high-dose-rate intracavitary brachytherapy for treatment of cervical cancer: the University of Pittsburgh experience. *Int J Radiat Oncol Biol Phys*. 2015 Mar 1;91(3):540–7. doi: 10.1016/j.ijrobp.2014.10.053. Epub 2015 Jan 30.
- [11] Rijkmans EC, Nout RA, Rutten IH, Ketelaars M, Neelis KJ, Laman MS, Coen VL, Gaarenstroom KN, Kroep JR, Creutzberg CL. Improved survival of patients with cervical cancer treated with image-guided brachytherapy compared with conventional brachytherapy. *Gynecol Oncol*. 2014 Nov;135(2):231–8. doi: 10.1016/j.ygyno.2014.08.027. Epub 2014 Aug 27.
- [12] Simpson DR, Scanderbeg DJ, Carmona R, McMurtrie RM, Einck J, Mell LK, McHale MT, Saenz CC, Plaxe SC, Harrison T, Mundt AJ, Yashar CM. Clinical outcomes of computed tomography-based volumetric brachytherapy planning for cervical cancer. *Int J Radiat Oncol Biol Phys*. 2015 Sep 1;93(1):150–7. doi: 10.1016/j.ijrobp.2015.04.043. Epub 2015 May 4.
- [13] Hegazy N, Pötter R, Kirisits C, Berger D, Federico M, Sturdza A, Nesvacil N. High-risk clinical target volume delineation in CT-guided cervical cancer brachytherapy: impact of information from FIGO stage with or without systematic inclusion of 3D documentation of clinical gynecological examination. *Acta Oncol*. 2013 Oct;52(7):1345–52. doi: 10.3109/0284186X.2013.813068. Epub 2013 Aug 2.
- [14] Lindegaard JC, Fokdal LU, Nielsen SK, Juul-Christensen J, Tanderup K. MRI-guided adaptive radiotherapy in locally advanced cervical cancer from a Nordic perspective. *Acta Oncol*. 2013 Oct;52(7):1510–9. doi: 10.3109/0284186X.2013.818253. Epub 2013 Aug 21.
- [15] Castelnau-Marchand P, Chargari C, Maroun P, Dumas I, Del Campo ER, Cao K, Petit C, Martinetti F, Tafo-Guemnie A, Lefkopoulos D, Morice P, Haie-Meder C, Mazon R. Clinical outcomes of definitive chemoradiation followed by intracavitary pulsed-dose rate image-guided adaptive brachytherapy in locally advanced cervical cancer. *Gynecol Oncol*. 2015 Nov;139(2):288–94. doi: 10.1016/j.ygyno.2015.09.008. Epub 2015 Sep 11.
- [16] Ribeiro I, Janssen H, De Brabandere M, Nulens A, De Bal D, Vergote I, Van Limbergen E. Long term experience with 3D image guided brachytherapy and clinical outcome in cervical cancer patients. *Radiother Oncol*. 2016 May 2. pii: S0167-8140(16):31050-57. doi: 10.1016/j.radonc.2016.04.016. [Epub ahead of print]



- [17] Sturdza A, Pötter R, Fokdal LU, Haie-Meder C, Tan LT, Mazeron R, Petric P, Šegedin B, Jurgenliemk-Schulz IM, Nomden C, Gillham C, McArdle O, Van Limbergen E, Janssen H, Hoskin P, Lowe G, Tharavichitkul E, Villafranca E, Mahantshetty U, Georg P, Kirchheiner K, Kirisits C, Tanderup K, Lindegaard JC. Image guided brachytherapy in locally advanced cervical cancer: Improved pelvic control and survival in RetroEMBRACE, a multicenter cohort study. *Radiother Oncol.* 2016 Apr 29. pii: S0167-8140(16):31018-0. doi: 10.1016/j.radonc.2016.03.011. [Epub ahead of print]
- [18] Murakami N, Kasamatsu T, Wakita A, Nakamura S, Okamoto H, Inaba K, Morota M, Ito Y, Sumi M, Itami J. CT based three dimensional dose-volume evaluations for high-dose rate intracavitary brachytherapy for cervical cancer. *BMC Cancer.* 2014 Jun 17;14:447. doi: 10.1186/1471-2407-14-447.
- [19] Ohno T, Noda SE, Okonogi N2, Murata K, Shibuya K, Kiyohara H, Tamaki T, Ando K, Oike T, Ohkubo Y, Wakatsuki M, Saitoh JI, Nakano T. In-room computed tomography-based brachytherapy for uterine cervical cancer: results of a 5-year retrospective study. *J Radiat Res.* 2016 Dec 15. [Epub ahead of print]