

# We are IntechOpen, the world's leading publisher of Open Access books Built by scientists, for scientists

4,800

Open access books available

122,000

International authors and editors

135M

Downloads

Our authors are among the

154

Countries delivered to

TOP 1%

most cited scientists

12.2%

Contributors from top 500 universities



WEB OF SCIENCE™

Selection of our books indexed in the Book Citation Index  
in Web of Science™ Core Collection (BKCI)

Interested in publishing with us?  
Contact [book.department@intechopen.com](mailto:book.department@intechopen.com)

Numbers displayed above are based on latest data collected.  
For more information visit [www.intechopen.com](http://www.intechopen.com)



---

# Biological Reconstruction Using Liquid Nitrogen-Treated Tumor Bearing Bone

---

Norio Yamamoto and Hiroyuki Tsuchiya

Additional information is available at the end of the chapter

<http://dx.doi.org/10.5772/67487>

---

## Abstract

In general, a tumor prosthesis is used for reconstruction after removal of osteosarcoma. However, the durability of artificial materials becomes a problem in the long term, and many patients inevitably undergo revision due to loose or damaged prostheses. Moreover, preservation of articular surface is the key to maintain better limb function for long duration. Reconstruction of affected limbs using biological materials has been sought to overcome the aforementioned problems. In some countries, it is significantly difficult to obtain allograft as a biological reconstruction material because of socio-religious or cost problem. Thus, a biological reconstruction method has been developed in which the patient's affected bone is treated and used for reconstruction. Especially in recycling treatment for affected autologous bone, liquid nitrogen treatment has several favorable characteristics. There is optimal morphological fit because the treated bone itself is one's own, and bone strength is maintained after treatment. Satisfactory bone union and bone regeneration are expected to be achieved due to good osteoconduction and osteoinduction because proteins and enzymes are preserved in the bone.

**Keywords:** osteosarcoma, biological reconstruction, liquid nitrogen, frozen autograft, joint preservation

---

## 1. Background

Osteosarcoma is the most common primary malignant bone tumor, but the reported incidence is very rare about 1 in 200,000 compared to other malignant neoplasms such as breast and lung cancer [1]. Because it has a predilection for children in the second decade of life, in order to ensure a prognosis that preserves life and limb function as well, treatment must be carried out with the utmost care. Limb-sparing surgery has become the standard surgical treatment for malignant bone tumors including osteosarcoma in recent years, and mega-prosthesis replacement is generally

---

used in reconstruction for limb salvage. Using mega-prosthesis for bone tumors usually results in good limb function in short term but various complications due to deterioration of non-biological materials in longer term. Total joint replacement for osteoarthritis of knee joint showed good functional results for instance, and several designs for total joint replacement have been applied for more rigorous position and alignment in recent years to obtain better functions in contrast to hinge or rotating hinge-type prosthesis. Limitation of the mega-prosthesis for reconstruction of bone tumor resection is much larger than such surface replacement regarding alignment and torsion force. Thus, activities of daily life would be much more restricted, and various problems may occur especially in younger patients with osteosarcoma after mega-prosthetic replacement.


To overcome these problems, so-called biological reconstructions using allogenic bone graft, vascularized or non-vascularized autologous bone graft, autologous bone extension, and sterilized processing autologous bone grafts have been utilized, and those reconstruction methods were more desired than mega-prosthesis in some regions in the world due to sociological and economic reasons. Sterilized autologous bone grafts have been developed by killing cancer cells using irradiation, autoclaving, or pasteurization onto patient's own diseased bone. Each processing methods for sterilization of diseased bone has the problem such as special equipment for irradiation and autoclaving, temperature control for pasteurization and those are sometimes complicated. One of the biggest problems is the quality of processed bone after autoclaving, irradiation, and pasteurization. Therefore, we developed the processing method by freezing using liquid nitrogen (LN2) and confirmed the feasibility of LN2-frozen bone in terms of safety and quality issues [2, 3]. We applied this freezing method to reconstructive surgery for bone tumor including osteosarcoma and obtained the satisfied results up to date [4, 5]. In addition, histological examination revealed good regenerative activity of LN2-processed bone [6–8].

## 2. Characteristics of liquid nitrogen-treated bone

The characteristics of LN2-treated bone show several advantages compared to other processed methods. That includes simple procedure without any specific equipment and complicated temperature control; strength of treated bone and superior osteo-conductive and osteo-inductive capacity with spared matrix proteins and enzymes; best compatibility of size and form and attachment of soft tissues such as ligaments and tendons [2, 3, 11]. These advantages could lead to more preferable bone regeneration and limb functions.

## 3. Indication of reconstruction using LN2-treated bone

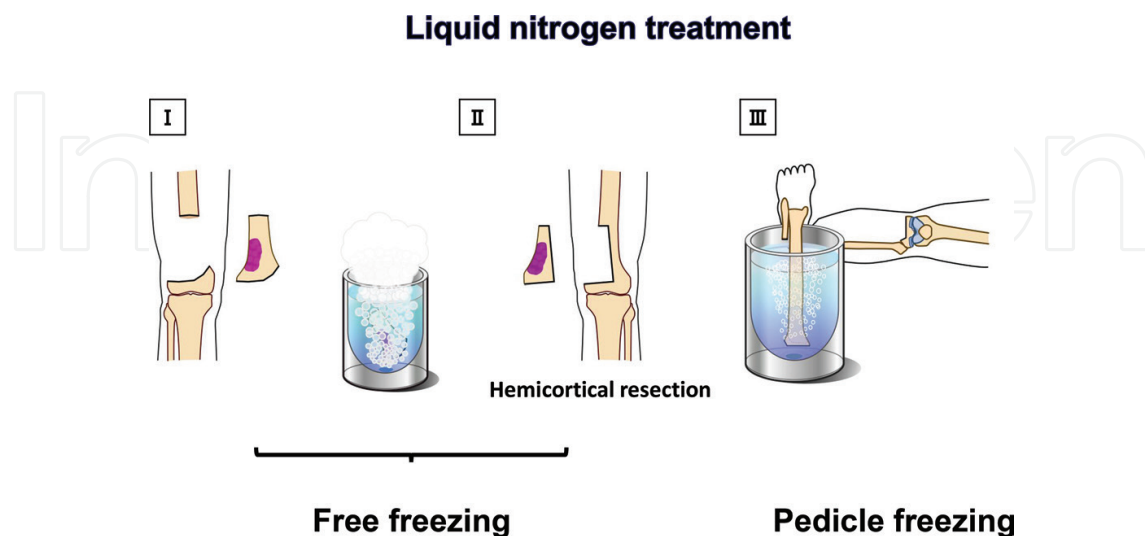
Bone-forming tumor such as osteosarcoma is the good indication for reconstruction using LN2-treated bone. Thus, we applied this method mainly to the patients with osteosarcoma. However, this method can be applied to the cases of osteolytic-type bone tumors such as bone metastasis with the reinforcement by polymethyl methacrylate. The tumor location, tumor origin (primary or metastatic), will not be a limiting factor for this method. Minimum equipment is a sterile thermos (Dewar) and sufficient amount of LN2 (usually 10–20 L) to immerse the disease-affected bone for freezing (**Figure 1A** and **B**).



**Figure 1.** Intraoperative photograph of free-freezing method: (A) pour enough liquid nitrogen into a sterilized thermos (Dewar) such that the affected bone can be completely immersed and (B) allow the diseased bone to be processed in the liquid nitrogen for 20 min.

#### 4. Processing method for LN2 treatment of disease-affected bone

Freezing methods of disease-affected bone can be classified as so-called ‘free-freezing’ and ‘pedicle-freezing’ method. The free-freezing method is performed in a way of complete disconnection of disease-affected bone from patient’s body, immersion into LN2 and returning into patient’s body (**Figure 2I and II**) [4]. Pedicle-freezing method is performed in a way of making the distal portion of the limb from the tumor as a pedicle with continuity with the



**Figure 2.** Types of liquid nitrogen treatment methods: for the free-freezing method, a conventional wide resection should be performed. A hemicortical resection can be applied to preserve the healthy bone cortex of contralateral side. For the pedicle-freezing method, the process is carried out without any breakage of continuity between the body and the affected bone.

patient's body, inversion of the limb into LN2 to immerse the affected site, then putting back into the patient's body (**Figure 2 III**) [9].

Hemi-cortical resection preserving a side of cortical bone can be performed in free-freezing method if the tumor margin is safe. That results in an increase of contact area between graft and host bone, which secures a high mechanical force and good treated-bone regeneration (**Figure 2 II**). Pedicle-freezing method is more advantageous for processed-bone regeneration because osteotomy site is only proximal side from the tumor [10].

Since the procedure of this method is quite simple, it can be performed everywhere in the world. However, several concerns have been raised, and fracture during LN2 treatment is one of main concerns. Because the expansion coefficients during freezing in LN2 are different among bone matrix, tumor bed, and blood, fracture is sometimes inevitable, such that careful curettage and reinforcement using Kirschner wire would be important to prevent fracture. Therefore, alternative operation plans such as mega-prosthesis replacement should be prepared in case.

## 5. Reconstruction by free-freezing method

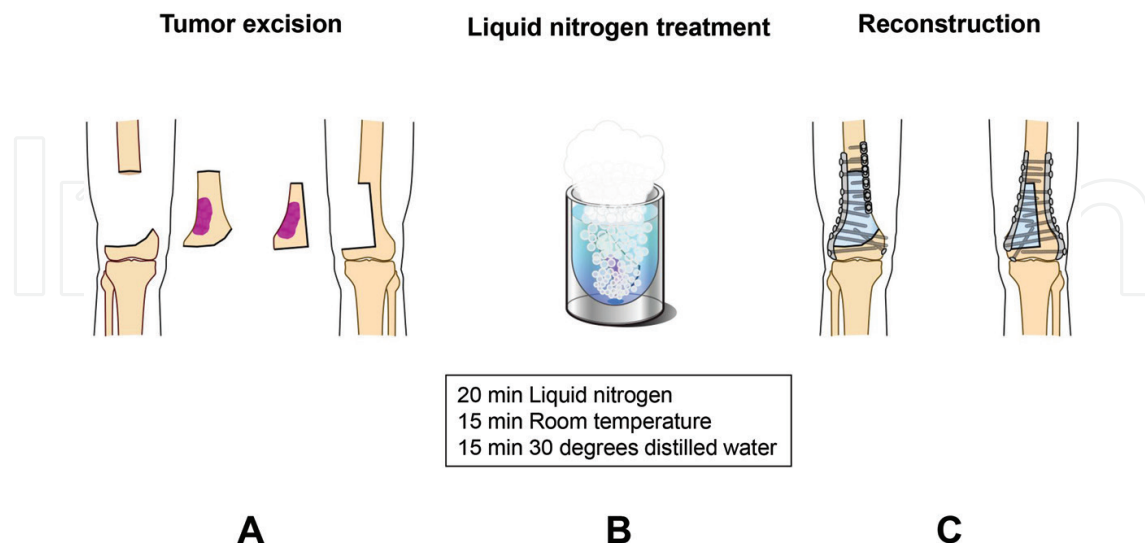
Site and route for biopsy should be placed under the careful consideration of the mode of definitive surgery. Resection of the tumor must secure the wide surgical margin including biopsy route and chevron (V-shaped) osteotomy using micro sagittal saw is recommended to increase the contact area, which reduces torsion force for the reconstruction of osteotomy site. When attempting hemi-cortical resection, fluoroscopy and navigation system in case will help accurate osteotomy to preserve the contralateral cortical bone.

Tumor tissues and other soft tissues excised with the disease-affected bone must be removed before freezing on a workbench separated from the surgical field, then a tunnel through the medullary canal in the affected bone should be created to prevent the fracture during the freezing process (**Figure 3A**).

After LN2 is stabilized in the Dewar, the excised bone tissue will be immersed in LN2 for 20 min, then placed in room temperature for 15 min and thawed in warm distilled water at about 30°C for another 15 min. We sometimes use 1% iodine solution in the distilled water to prevent an infection (**Figure 3B**).

Double-plate fixation or intramedullary nail with plate fixation is strongly recommended to secure the stability at the osteotomy sites (**Figure 3C**). In case of large defect in processed bone, polymethyl methacrylate fulfillment will give strength to the processed bone. Composite graft with allogenic bone can be applied for certain cases too. Soft tissue reconstruction such as insertion of ligaments and tendons can be performed by direct attachment to the processed bone or remaining soft tissues on the processed bone using screws and staples.

## Free Freezing Method



**Figure 3.** Free-freezing method: (A) perform wide resection of the tumor with or without sparing the contralateral bone cortex; (B) freeze the resected bone in the liquid nitrogen for 20 min; and (C) strong fixation should be done by double plate fixation.

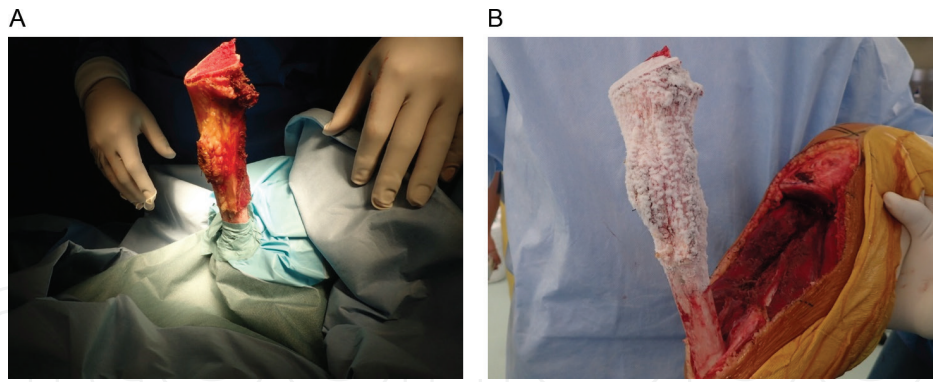
## 6. Reconstruction by pedicle-freezing method

Basics for the wide resection are as same as the free-freezing method, and chevron (V-shaped) osteotomy should be performed at the proximal side from the tumor with the appropriate surgical margin using a micro-sagittal saw.

Bone with surrounding tissues, which should be excised with a wide margin, can be elevated at the osteotomy site. Unnecessary soft tissues should be detached from the bone at approximately 5-cm distal portion from the planned level for freezing to prevent the unwanted soft tissue damages by LN2 treatment. Marking the position for soaking into LN2 by electrode would be preferable before freezing.

After the detachment of unnecessary soft tissues with wide margin, the bone is elevated, and a tourniquet is applied to the affected limb to prevent bleeding and tumor cell dissemination during the curettage of tumor tissues. Covering the normal soft tissues with cotton and Esmarch lubber bandages and large clean sheets should be applied to prevent the damages by LN2 treatment (**Figure 4A** and **B**).

Tumor tissues must be curetted very carefully as possible without any contamination in the operation field as well as distal portion from the planned freezing site to secure the surgical margins then create a hole in the bone cavity to prevent the fracture during the LN2 treatment. Changing the gloves and scrubs of the operators is required to prevent the contamination with tumor cells (**Figure 5A**).

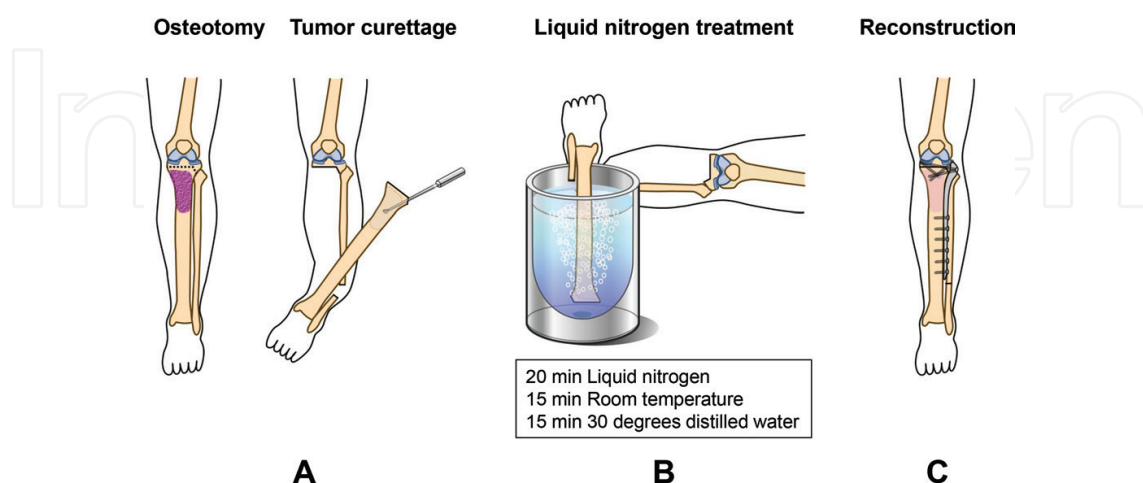


**Figure 4.** Intraoperative photograph of pedicle-freezing method: (A) secure that no normal soft tissue is frozen during the processing of the affected bone in liquid nitrogen for 20 min and (B) thaw for 15 min at room temperature after freezing.

After curettage, the covering sheets are carefully removed without a contact with the bone. Then, operators firmly hold the elevated affected limb to soak the pedicle bone into LN2. Careful placement of affected bone into LN2 can be secured by controlling the levels of operating table. It is very important to confirm that the bone is properly immersed in LN2 at the level of marking for planned site. The processing will continue in LN2 for 20 min as describe earlier. It is also important to verify that the remaining normal soft tissue is not affected by freezing. At the end of freezing, the operating table is slowly raised to remove the bone from the LN2 (**Figure 5B**).

Thawing in room temperature for 15 min and in the warm distilled water for 15 min will be carried out as same as the free-freezing method. Firm fixation with double plates or intramedullary nailing with plate fixation and supplemental bone grafts if necessary should be performed as described earlier (**Figure 5C**).

### Pedicle Freezing Method



**Figure 5.** Pedicle-freezing method: (A) make the osteotomy on the proximal side of the tumor location. Careful curettage should be performed and bone tunnels are created to prevent fractures; (B) the distal portion maintains continuity with the body in a pedicle form, and inversion of affected limb and soaking into liquid nitrogen is performed; and (C) strong fixation should be done as same as free-freezing method.

## 7. Conclusion

The procedure in reconstruction using liquid nitrogen-treated bone is simple. If surgeons learn small skills of this techniques, this procedure can be used in many institutions. When surgeons become familiar with the procedure, bone fractures rarely occur under processing. However, it is important to prepare cable system or tumor prosthesis in case.

Surgical resection of joint surface and prosthetic reconstruction has several disadvantages and is not only option for reconstruction after osteosarcoma resection. Surgeons should keep in mind that joint preservation technique has the advantages for better limb function especially with longer durability. Thus, reconstruction methods including recycled bone technology as describe above might be considered as an alternative rather than prosthetic reconstruction for more precise surgery in osteosarcoma.

## Author details

Norio Yamamoto\* and Hiroyuki Tsuchiya

\*Address all correspondence to: [norinori@med.kanazawa-u.ac.jp](mailto:norinori@med.kanazawa-u.ac.jp)

Department of Orthopedic Surgery, Graduate School of Medical Sciences, Kanazawa University, Kanazawa, Ishikawa, Japan

## References

- [1] Souhami RL, Craft AW, Van der Eijken JW, et al: Randomized trial of regimens of chemotherapy in operable osteosarcoma: a study of the European Osteosarcoma Intergroup. *Lancet* **350**: 911–917, 1997
- [2] Yamamoto N. Experimental study for reconstruction using liquid nitrogen treated tumor bearing bone. *Juzen Gakkaishi* **109**: 193–202, 2000.
- [3] Yamamoto N, Tsuchiya H, Tomita K. Effects of liquid nitrogen treatment on the proliferation of osteosarcoma and the biomechanical properties of normal bone. *J Orthop Sci* **8**: 374–380, 2003.
- [4] Tsuchiya H, Wan SL, Sakayama K, et al. Reconstruction using an autograft containing tumour treated by liquid nitrogen. *J Bone Joint Surg Br* **87**: 218–225, 2005.
- [5] Igarashi K, Yamamoto N, Shirai T, et al. The long-term outcome following the use of frozen autograft treated with liquid nitrogen in the management of bone and soft-tissue sarcomas. *Bone Joint J* **96-B**: 555–561, 2014
- [6] Sakayama K, Tsuchiya H, Fujibuchi T, et al. Pathological findings of an autograft containing osteosarcoma treated by liquid nitrogen retrieved 2 years after implantation. *J Orthop Sci* **11**: 655–656, 2006.



- [7] Tanzawa Y, Tsuchiya H, Shirai T, et al. Histological examination of frozen autograft treated by liquid nitrogen removed after implantation. *J Orthop Sci* **14**: 761–768, 2009.
- [8] Yamamoto N, Inatani H, Shirai T, et al. Histological study on liquid nitrogen-treated tumor-bearing bone of the proximal femur excised eight years after transplantation. *Low Temp Med* **38**: 5–8, 2012.
- [9] Tsuchiya H, Nishida H, Srisawat P, Shirai T, Hayashi K, Takeuchi A, Yamamoto N, Tomita K. Pedicle frozen autograft reconstruction in malignant bone tumors. *J Orthop Sci* **15**: 340–349, 2010.
- [10] Shimozaki S, Yamamoto N, Shirai T, et al. Pedicle versus free frozen autograft for reconstruction in malignant bone and soft tissue tumors of the lower extremities. *J Orthop Sci* **19**: 156–163, 2014.
- [11] Takata M, Sugimoto N, Yamamoto N, et al. Activity of bone morphogenetic protein-7 after treatment at various temperatures: freezing vs. pasteurization vs. allograft. *Cryobiology* **63**: 235–239, 2011.