

# We are IntechOpen, the world's leading publisher of Open Access books Built by scientists, for scientists

4,800

Open access books available

122,000

International authors and editors

135M

Downloads

Our authors are among the

154

Countries delivered to

TOP 1%

most cited scientists

12.2%

Contributors from top 500 universities



WEB OF SCIENCE™

Selection of our books indexed in the Book Citation Index  
in Web of Science™ Core Collection (BKCI)

Interested in publishing with us?  
Contact [book.department@intechopen.com](mailto:book.department@intechopen.com)

Numbers displayed above are based on latest data collected.  
For more information visit [www.intechopen.com](http://www.intechopen.com)



---

## New Surgical Procedure for Pancreas Head

---

Yoshinobu Sato, Yoshiaki Hara, Naruhiko Sawada,  
Shoji Shimada, Kenta Nakahara,  
Daisuke Takayanagi, Fumio Ishida, Shin-Ei Kudo and  
Junichi Tanaka

Additional information is available at the end of the chapter

<http://dx.doi.org/10.5772/66493>

---

### Abstract

In this study, we demonstrate two new methods for pancreaticoduodenectomy (PD). One method is the mini-laparotomic PD by Shuriken-shaped umbilicoplasty with the real-time moving window's method. The other method is the new pancreaticojejunostomy (PJ) by punctured stent slide guiding method (PSSGM). This procedure could be performed by complete mini-laparotomy under direct vision, and the final major wound is only 2 cm of round navel. PSSGM prevents the difference of caliber between pancreatic anastomosis and the inside out of jejunal mucosa in theory. Ten cases of mini-lap PD were successfully performed under new PJ anastomosis. The pancreatic leakage (PL) was only one case of ISGPF grade A, and its frequency was 9% (1/11). Our mini-lap PD by Shuriken-shaped umbilicoplasty might be a useful way for overcoming the obstacles about safety, complication risk, cosmetic demand, and medical cost compared to laparoscopic PD. Also, our new device of PJ reconstruction by PSSGM might be an easy and useful device for the prevention of PL.

**Keywords:** laparoscopic pancreaticoduodenectomy, pancreaticojejunostomy, navel surgery, Shuriken-shaped umbilicoplasty, minimal invasive surgery

---

## 1. Introduction

Recently, laparoscopic surgery has been used for pancreas surgery. Laparoscopic pancreatic surgery has gradually expanded to include pancreaticoduodenectomy (PD) [1–3]. However, as the outcomes of feasibility and safety have become better yearly in the laparoscopic pancreaticoduodenectomy (LPD), a superior operative skill must be required. Therefore, LPD

remains technically a difficult surgery with high rates of mortality and morbidity for usual HPB surgeons. LPD is a challenging operation for multiple reasons, including but not limited to the following: difficult access and exposure of the pancreas, which is situated in the retroperitoneum; hemorrhage control from major vasculature, a technically demanding reconstruction of the biliary and pancreatic remnants; maintaining oncologic surgical principles; and surgeon fatigue from a long operation requiring intense concentration. Limitations of the laparoscopic approach include the inability to palpate the lesion or surrounding vascular structures. Owing to the limitations of LPD, we reported a new surgical device of hybrid laparoscopic complete uncinectomy of the pancreas by Shuriken-shaped umbilicoplasty with the sliding window's method [4] in pursuit of both safety and cosmetic advantages. In this chapter, we would like to demonstrate our modified novel technique of Shuriken-shaped umbilicoplasty with the real-time moving sliding window's method in pancreas for PD by mini-laparotomy. Our technique might be used for PD from complete mini-laparotomy to hybrid laparoscopic operation and be a useful procedure with the advantages of cosmetic, safety, and learning tools to the complete LPD.

The pancreatic fistula is a major obstacle as a complication after pancreatojejunostomy (PJ) in PD would result in intra-abdominal abscess or bleeding from arterial aneurism. A reconstruction of PJ has been reported; however, the pancreatic leakage (PL) has not disappeared. The cause for PL might be divided into two factors. First is the host's factors and second is the surgeon's factors (**Table 1**). The host's factors are their nutrition status, diabetes mellitus, pancreatitis, aging, liver cirrhosis, and so on. Those conditions might influence wound healing, immunocompetence, and susceptibility to infection. The surgeon's factors are technical problems including their surgical skill, surgical instruments, and reconstruction's method. In this study, we will also demonstrate the new PJ technique by pancreatic stent slide guiding method (PSSGM).

Case	Sex	Age	Disease	Real time sliding window's method	Operative time	Blood loss	Hospital stay	PL	BL	Other postoperative complications	Preoperative complications
1	M	66	PvC	HALS	980	2256	23	-	-	-	-
2	F	69	BDC	+ Mini-Lap	492	257	37	-	-	-	-
3	F	77	PK	+ Mini-Lap	445	389	17	-	-	-	-
4	M	78	PK	+ Mini-Lap	659	1026	18	-	-	-	DM
5	F	75	PK	+ Mini-Lap	517	673	31	-	-	-	-
6	M	77	BDC	+ Mini-Lap	485	914	17	-	-	-	-
7	M	68	PvC	+ Mini-Lap	482	344	36	Grade A	-	Bleeding of gastric anastomosis	-
8	F	70	BDC	+ Mini-Lap	577	1375	42	-	-	Liver abscess	Cholangitis

Case	Sex	Age	Disease	Real time sliding window's method	Operative time	Blood loss	Hospital stay	PL	BL	Other postoperative complications	Preoperative complications
9	F	75	BDC	+ Mini-lap	552	1284	90	-	-	Liver abscess	DM
10	F	74	PK	+ Mini-Lap	545	795	28	-	-	-	DM

PL: leakage of pancreatic juice; PvC: papilla vater carcinoma; BL: leakage of bile juice; BDC: bile duct cancer; DM: diabetes mellitus; PK: pancreatic cancer; Mini-Lap: mini-laparotomy.

Pancreatic leakage was the only one case of grade A by ISGPF classification. Two patients suffered from liver abscess and their hospital stay prolonged by 42 and 90 postoperative days, respectively. There were no cases that had bile leakage.

**Table 1.** Profiles and perioperative data of 10 patients who underwent PD with the Shuriken-shaped umbilicoplasty.

## 2. Surgical procedures

### 2.1. Shuriken-shaped umbilicoplasty with the sliding window's method

The patient was placed in the supine position with legs closed. Hybrid laparoscopic surgery was performed by the hand-assisted or the direct manipulation with a small open wound by the sliding window's method. Under general anesthesia, a Shuriken-shaped umbilical skin incision was made 6 cm horizontally, 4 cm longitudinally and 1.8 cm wide. The intermediate skin between outside and inside skin incision was removed. Subcutaneous tissue around the umbilicus and the upper abdominal subcutaneous region was dissected, and the upper abdominal minilaparotomy, from 8 to 12 cm, was performed (**Figures 1** and **2**). GelPort was used for the hand-assisted laparoscopic surgery.

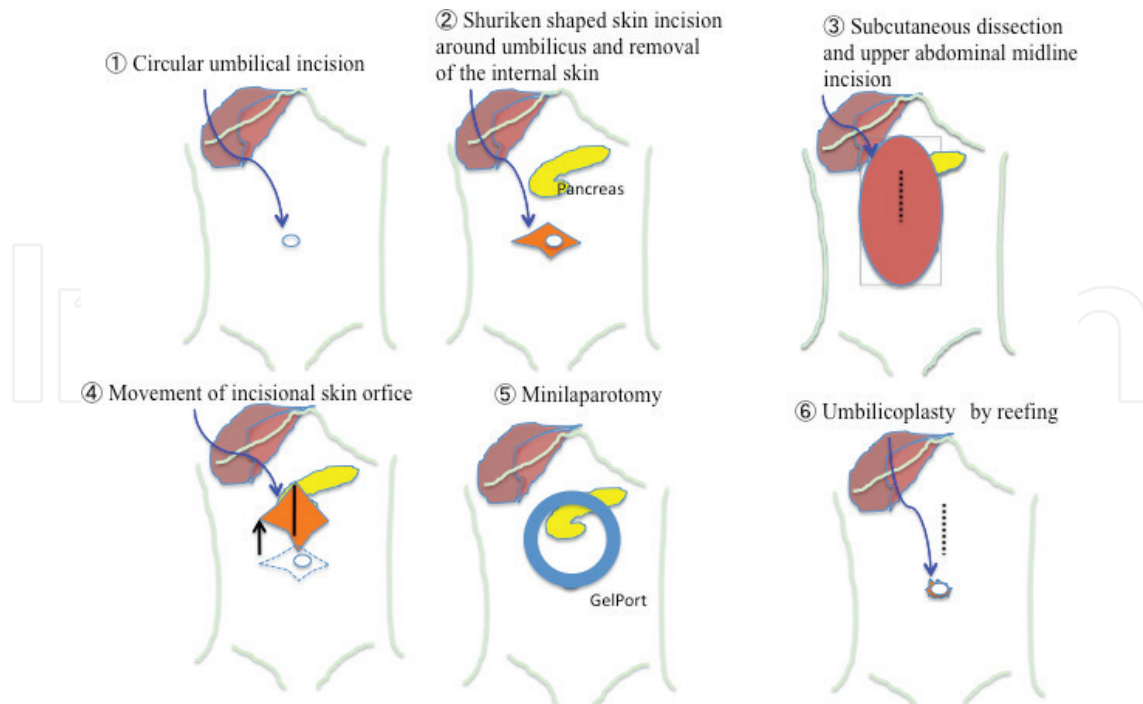
After that, two of Kent retractors for the upper region and two of surgical arms for the lower region are placed at each bilateral side.

### 2.2. Real-time moving window's method for PD

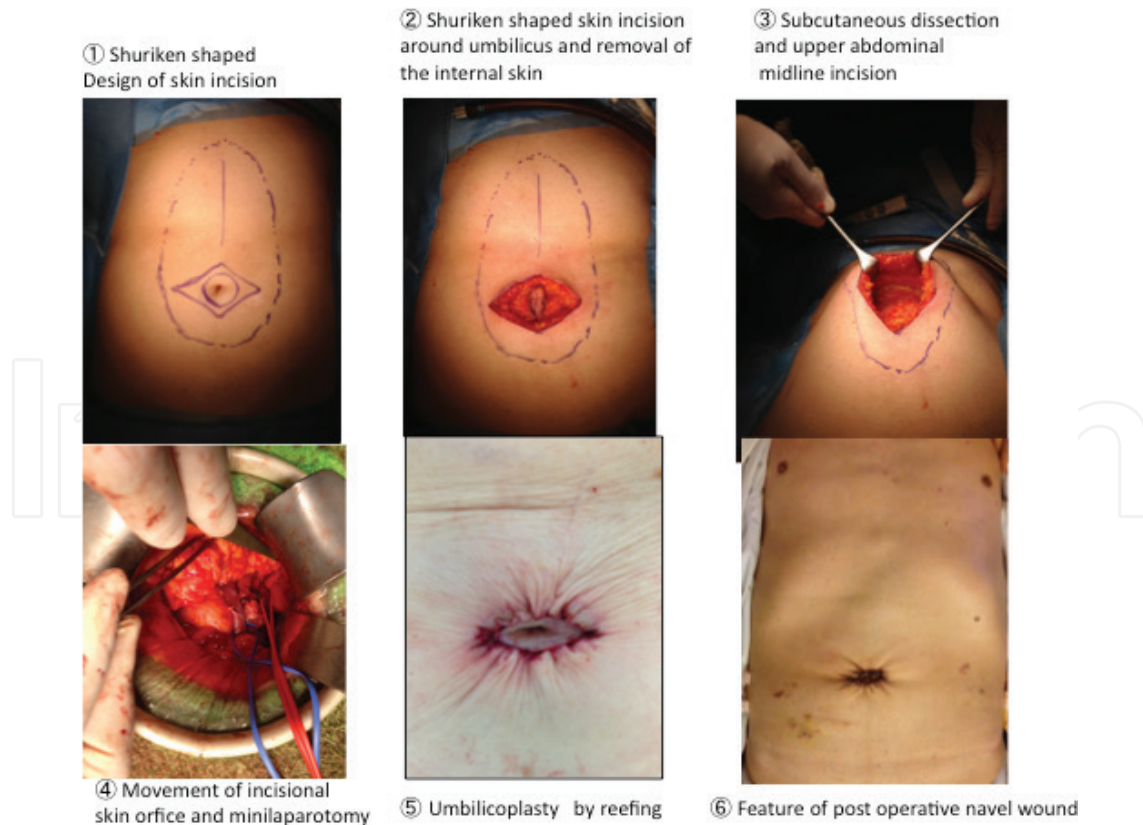
The three operative fields were divided into the hepatic hilus region, pancreas head region, and SMA region (**Figure 3**). The four retractors were moved according to each operative region. For each operation of the hepatoduodenal and common hepatic arterial regions, Kent retractor was pulled forward to the right or left upper by placing surgical gazes at the right sub-diaphragmatic space. And then, for the paraduodenal approach of SMA or Treize'ligament, the right or left surgical arm was pulled to the right lower direction or the left lower direction after loosening the Kent retractor. For the pancreas head region, Kent retractor was pulled toward the middle upper after loosening the surgical arms.

The operative manipulations were done and were the same as those of the usual open PD.

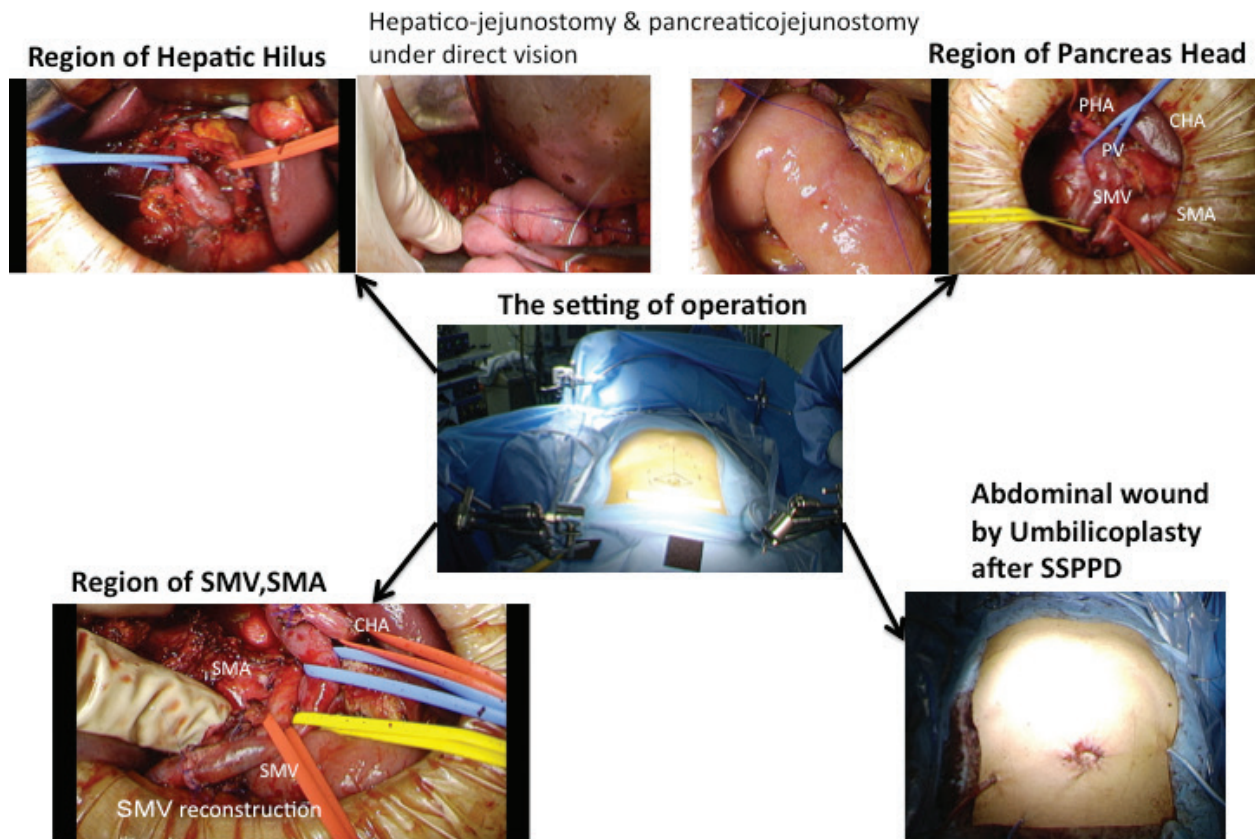
Especially, the processing of IPDA was firstly made by paraduodenal approach under the concept of "artery first" before dealing with SMV.



**Figure 1.** Schema of Shuriken-shaped umbilicoplasty with sliding window's method. The figure shows each step of our procedure by the laparotomy from ① to ⑤ and umbilicoplasty by reefing in ⑥.



**Figure 2.** Operative photographs of Shuriken-shaped umbilicoplasty with sliding window's method. The figure also shows each step from ① to ⑥.



**Figure 3.** Schema of pancreatoduodenectomy by Shuriken-shaped umbilicoplasty with real-time sliding window's method using operative photographs. The center photograph shows the setting of operation using two Kent retractors and two surgical arms. The three operative fields, region of hepatic hilus, region of pancreas head, and region of SMA and SMV were exposed by real-time moving window's method by their retractors. The last photograph shows the 2-cm operative navel wound by umbilicoplasty and each of the three drains—Winslow's drain, drain of post pancreaticojejunostomy, and subcutaneous drain.

The hepaticojejunostomy, the pancreaticojejunostomy, and the gastrojejunostomy were done under direct vision without laparoscopic manner. After the reconstruction, three closed drainage tubes were detained in the Winslow foramen, the posterior space of pancreaticojejunostomy, and subcutaneous space, respectively.

### 2.3. Pancreatojejunostomy by punctured stent slide guiding method (PSSGM)

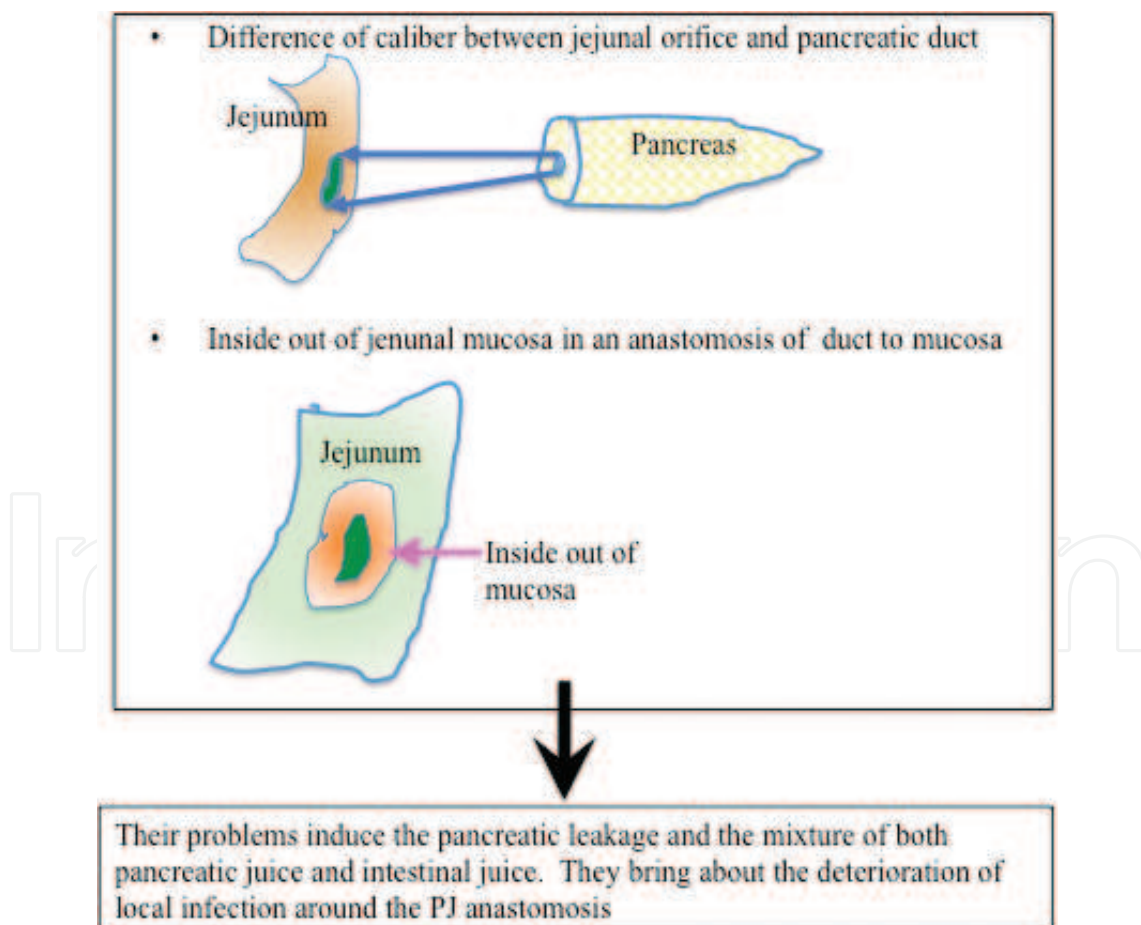
#### 2.3.1. The cutting and sealing of pancreas stump

A cause for PL is due to insufficient sealing of the pancreas stump. We cut the pancreas by using the SonoSurg or the bipolar forceps near the pancreatic duct. The pancreatic duct is cut by the surgical knife.

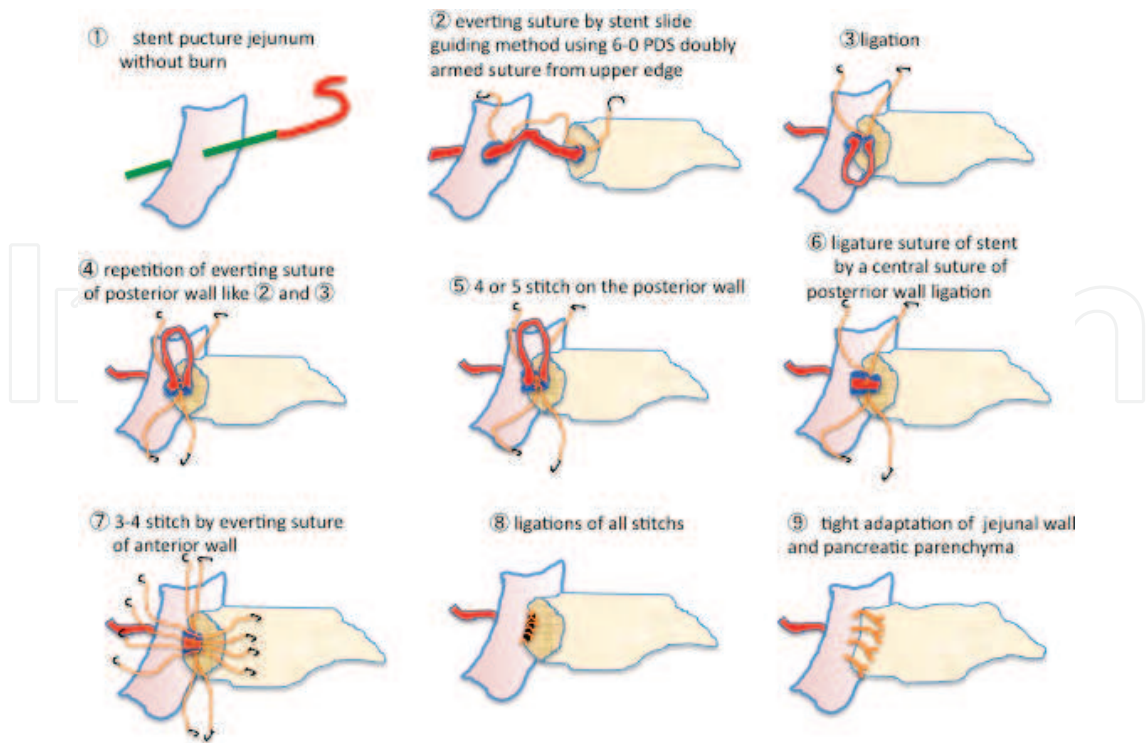
#### 2.3.2. Anastomosis of duct to "seromuscular layer"

We consider that the major cause for PL is technical problems at the anastomosis in the PJ. The possible problems of PJ anastomosis are thought to be two reasons. One is a difference of caliber between the jejunal orifice and the pancreatic duct. The other is an inside out of jejunal

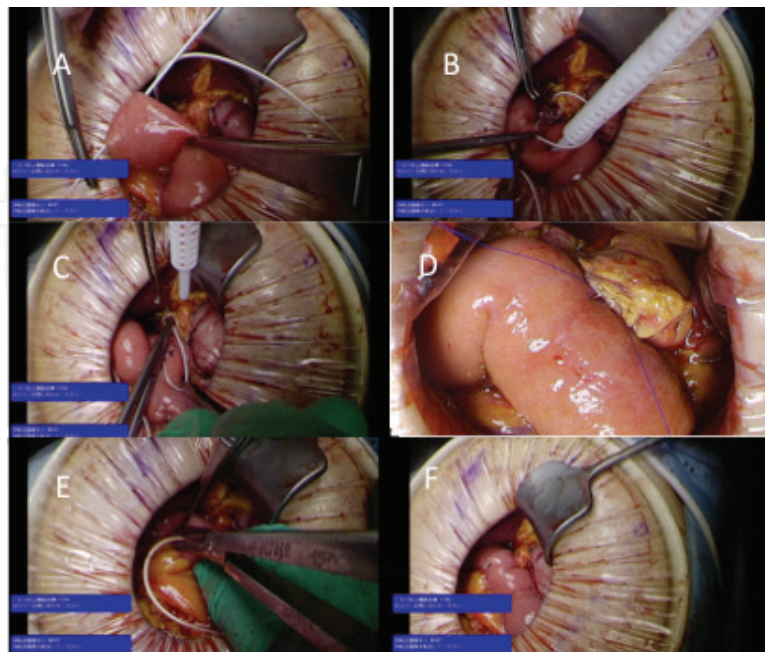
mucosa in anastomosis of the duct to mucosa (**Figure 4**). These problems lead to PL and local infection around PJ anastomosis. Sometimes, those infections induce the arterial aneurism and its rupture and bleeding. As a solution, we devised the punctured stent slide guiding method. The first step in this method is a puncture of jejunum by a pancreatic stent adapted to the orifice of the pancreatic duct without any incineration of serosa of jejunum as shown in **Figures 5** and **6A**. This surgical idea might prevent the difference of anastomotic orifice and not resist the healing of anastomosis because of the none of any destroy of fire by the surgical device. The second step is an anastomosis of the duct to jejunal seromuscular layer without the mucosa. This duct to seromuscular anastomosis might prevent the necrosis of mucosa by the ligating strings. These evertting suturing by all around 8–10 needles are made by 6-0PDS doubly armed suture. Both the small orifice of the pancreatic duct and the jejunum are easily and simply anastomosed by each needle sliding on the pancreatic stent tube. After that, the third step is an anastomosis of the pancreatic parenchymal stump by the jejunal seromuscular layers with the Kakita method, utilizing a full, thick penetrating suture for tight stump adhesion. The last step is a resection of the pancreatic stent with the opposite side for the lost stent. The orifice after resection of stent is closed by suturing.



**Figure 4.** Ideas of technical causes of PL from anastomosis of duct to mucosa in pancreaticojejunostomy. The major technical cause is considered to be pancreaticojejunostomy of duct to mucosa. This origin will be induced by the two cause of the difference of caliber between jejunal orifice and pancreatic duct and the inside out of jejunal mucosa in an anastomosis of duct to mucosa.



**Figure 5.** Schema of duct to seromuscular layer anastomosis by punctured stent slide guiding method (PSSGM). The first step of this device is a puncture of jejunum by a pancreatic stent adapted to the orifice of pancreatic duct without any incineration of serosa of jejunum like **Figure 5**①. After that, the everting suture of seromuscular layer to pancreatic duct by 6-0 PDS double armed absorbed suture is started from upper edge using punctured stent slide guide. The posterior wall is anastomosed by the four or five stitches one by one according to the schema from ② to ⑥. The anterior wall is anastomosed by the consecutive three or four stitches by PSSGM. Finally, all stitches are ligated. The tight adaptation is the modified Kakita method.



**Figure 6.** Operative photographs of pancreaticojejunostomy by punctured stent slide guiding method. Operative photographs showing the procedures of PSSGM according to the schema of **Figure 5**.



### 3. Patients and perioperative data

#### 3.1. PD with Shuriken-shaped umbilicoplasty

We experienced 10 cases of PD by real-time moving window's method. Mean age was  $72.6 \pm 4.2$  years old. Operative procedures were mentioned as described above. The pancreaticojejunostomy was done by our original stent slide guiding method. The patient's profile is demonstrated in **Figure 5**. Average of operative times was  $528 \pm 63$  min. Average of operative blood was  $795 \pm 405$  ml. Average of hospital stay was  $33 \pm 21$  (17-90). Two patients suffered from liver abscess, and their hospital stay was prolonged by 42 and 90 postoperative days, respectively. There were no cases that had bile leakage. Pancreatic leakage was only one case of grade A by ISGPF classification (**Table 1**).

#### 3.2. Pancreaticojejunostomy by punctured stent slide guiding method

Ten cases were operated using the Shuriken-shaped umbilicoplasty and one case by the usual open surgery. We divided the PD with PJ reconstruction into three groups from 2004 to 2015 in our center. There were 114 cases of PD with PJ reconstruction operated by the previous HPB surgeons in Group A from 2004 to 2013. There were 24 cases operated by present HPB surgeons from 2014 to 2015. Eleven cases in Group C were operated by the first author using PSSGM from 2014 to 2015. The 13 cases of Group B were operated by other surgeons without PSSGM. The PLs were compared among three groups according to the ISGPF criteria.

### 4. Changes in amylase level in the sump solution

The amylase level in the two sump solutions was measured (**Table 2**). The two drains of eight cases were removed within 5 days after operation without PL. The drains of the other two cases were removed 7 days after the operation. The one in two cases had a PL of grade A.

Levels of amylase in the sump solution of pancreatic anastomotic drain						Levels of amylase in the sump solution of Winslow's drain					
Case	1POD	3POD	5POD	7POD	PF	Case	1POD	3POD	5POD	7POD	PF
1	142	47			0	1	137	45			
2	637	90	34		0	2	507	126	15		–
3	108	23	14		0	3	126	19	14		–
4	99	115	13	14	0	4	153	37	21	16	–
5	43	52	28		0	5	210	141	16		–
6	7192	2453	1777	254	Grade A	6	1735	368	344	129	Grade A
7	1034	83	18		0	7	539	281	14		–

Levels of amylase in the sump solution of pancreatic anastomotic drain						Levels of amylase in the sump solution of Winslow's drain					
Case	1POD	3POD	5POD	7POD	PF	Case	1POD	3POD	5POD	7POD	PF
8	1228	180	99		0	8	2494	102	16		-
9	18	12	4		0	9	15	10	4		-
10	148	299			0	10	169	219			
11	78	38				11	125	134.8	55	72	
Av	975	308	248	134		Av	564	134	55	72	
SD	2105	716	618	169		SD	801	114	109	56	

The amylase level in the two drainage solutions of Winslow's foramen and posterior of PJ anastomosis was measured. All of the two drains in 8 cases were removed within 5 days after operation without PL. The drains of the other two cases were removed 7 days after operation. The one in two cases had grade A PL of ISGPF criteria.

**Table 2.** Changes of amylase in the sump solution after SSPPD with PSSGM.

#### 4.1. Changes in the frequency of pancreatic leakage compared among the three distinguished periods from 2004 to 2015 in our hospital

Total frequency of PL was 39% in the 114 cases of PJ reconstruction of Group A from 2004 to 2015 (Table 3). Total frequency of PL of Group B and Group C was 31 and 9%, respectively, at the same period from 2014 to 2015. The frequency of grade C PL was 7.9% in Group A. Groups B and C had no grade C PL. Moreover, Group C had no grade B and grade C PL that underwent PSSGM.

Group	Number	ISGPF grade				Total (%)
		Grade 0	A(%)	B(%)	C(%)	Grade A-C
A (2004-2013)	114	60.5 (69)	5.2 (6)	26.3 (30)	7.9 (9)	39
B 2014.1.1-2015.10.31	13	69.2	15.3(2)	15.3(2)	0	31
C 2014.11.1-2015.10.31	11	91	9(1)	0	0	9

Total frequency of PL was 39% in the 114 cases of PJ reconstruction of Group A from 2004 to 2015. Total frequency of PL of Group B and Group C was 31 and 9%, respectively, at the same period from 2014 to 2015. The frequency of grade C PL was 7.9% in Group A. Group B and Group C had no grade C PL. Moreover, Group C had no grade B and grade C PL that underwent PSSGM.

**Table 3.** Changes in frequency of pancreatic leakage in our hospital for three distinguished periods from 2004 to 2015.

## 5. Discussion

In 1994, Gagner and Pomp [5, 6] first introduced LPPPD in an advanced laparoscopic surgical trial in an effort to reduce postoperative morbidity. Since then, however, there have been few reports from centers with experience performing this procedure, and the reported clinical

outcomes of LPD have remained unsatisfactory over the last decade [7, 8]. Technical progress in LPD was achieved by several pioneering laparoscopic surgeons, including hand-assisted LPD [9, 10] as well as laparoscopically assisted [11, 12] and robot-assisted PD [13]. However, some surgeons have recently reported favorable outcomes [14–17]. LPD has not been accepted as a generalized surgical method for the resection of pancreatic head lesions. LPD includes technically difficult surgeries with high rates for mortality and morbidity.

Most of risky complications are leakages of pancreatic duct anastomosis and hepaticojejunostomy in the PD in spite of open or laparoscopic. Their reconstruction might be very stressful and fatigue for surgeons because of the limitations of laparoscopic approach and long operation.

In our operative procedure, the final main operative abdominal wound by Shuriken-shaped umbilicoplasty is almost 2 cm round around the navel except the three wounds for drainage tubes in our new device of operation. The length of subcutaneous upper abdominal incision is longer than that of the complete untinatectomy which was reported elsewhere. Although the opening window of abdomen using GelPort is small, the favorable operative window could be exposed by the real-time sliding window's method with two Kent retractors and two of surgical arms.

Otherwise, our techniques could bring their anastomosis under direct vision. Although our clinical research was very small number, the results of the only one case of pancreatic leakage of Grade A in ISGPF might be enough to verify the availability of our device. Moreover, all of surgical manipulations could be completely done under direct vision including ability to palpate the lesion and the vascular reconstructions as well as those of the open PD (OPD).

Therefore, our new device might be same as the OPD at the viewpoint of minimum invasive surgery and same as LPD at the viewpoint of cosmetic merit. However, that might be as same as the OPD at the viewpoint of safety.

In this chapter, we demonstrated the new device of PL by PSSGM. The causes for PL are shown in **Table 4**. We would consider that the origins of PL are divided into two parts, host's factor and surgeon's factor. The major cause for PL of PJ might be surgeon's technical problems. The PL from the anastomosis of the PJ and a cut stump of pancreas are the main origins, and we would consider that the difference of caliber of PJ anastomosis and the inside out of the jejunal mucosa are major obstacles. The only puncture by pancreatic stent to jejunum without burns must prevent from both the inside out of the jejunal mucosa and the difference of caliber of PJ anastomosis. The mixture of pancreatic juice and intestinal juice would deteriorate the PL and the local infection after the PL. Because the mixture of jejunal juice and pancreatic juice activate the inactivate pancreatic juice and activate pancreatic juice promote the PL. The above risk might be low in our new device. The other merit of our device is an easy anastomosis by the stent slide guiding method. If the pancreatic duct is small at the soft pancreas, the suture would be easy by handling of the needle using the guide of stent sliding. However, the comparison among three periods was retrospective and the surgeons also were various with the exception of Group C, the PL of Group C was low level in the frequency and the severity. Two major PJ reconstructions of Kakita method and Blumgart's technique have been reported [18–21]. Oda et al. reported that the rate of ISGPF grade B+C PF was 29/78 (37.2%) in the Kakita group and 16/78 (20.5%) in the Blumgart group ( $P = 0.033$ ) [22]. The principal technique of these two methods is a tight adaptation of pancreatic parenchyma and duodenal seromuscularis. Their device is not for the anastomosis of the pancreatic duct to mucosa. Our technique would be

countermeasures against the difference of caliber of PJ anastomosis and the inside out of jejunal mucosa. Moreover, our device might prevent the mixture of pancreatic juice and jejunal juice, which deteriorate the local infection following PL. I performed this PJ anastomosis by PSSGM at the living related partial pancreas transplantation as a first case of enteric drainage in Japan and the heterotopic pancreas autotransplantation [23, 24]. This technique is thought to be useful for soft pancreas. Although the number of our studies about PL was very small, they included the retrospective data in the same period. Therefore, we confirm that our new device is theoretically useful and effective.

---

**Host factor**

---

1. DM, age, nutrition, obesity, general condition
  2. Condition of pancreas
    - Soft pancreas, fibrosis, pancreatitis
- 

**Sugeon's factor**

---

1. Technical problems
    - a. Type of surgical suture, skill of surgeon, management of stent
    - b. Surgical device of pancreatic resection
      - Dealing of pancreatic stump
      - Bleeding from pancreatic stump,
      - Lack of sealing of pancreatic stump
  2. Differences of reconstruction method
- 

**Table 4.** Causes for pancreatic leakage.

Many authors mentioned the necessity of learning periods for LPD. This complex procedure requires a relatively long training period to ensure technical proficiency.

Wang et al. [25] reported that based on the cumulative sum (CUSUM) and the risk-adjusted CUSUM analyses, the learning curve for LPD was grouped into three phases: phase I was the initial learning period, phase II represented the technical competence period, and phase III was regarded as the challenging period. There were no significant differences in terms of postoperative complications or the 30-day mortality among the three phases. More challenging cases were encountered in phase III. To attain technical competence for performing LPD, a minimum of 40 cases are required for laparoscopic surgeons with a degree of laparoscopic experience. Therefore, the acquisition of LPD might be not so easy, especially, in the center with a small amount of PD operations. Our device could be done by complete minilaparotomy so the usual HPB surgery might perform without the long learning period. Because the PJ and the HJ anastomosis could be done under direct vision as well as open surgery.

Of course, according to the learning curve, our operation could change from the complete minilaparotomy to the hybrid laparoscopic procedure or to complete LPD. Our procedure might be useful as a way of learning for LPD.

As other subjects, there is medical cost. Tan et al. reported that the mean total cost was higher in the total LPD (TLPD) group compared to the OPD group. When the total cost was broken down, TLPD was noted to result in significant increases in the cost of both surgery and anesthesia, but a decrease in the cost of admission evaluation. The higher cost of surgery and anesthesia in the TLPD group was due to the required surgical equipment and supplies and longer surgical time. The lower cost of admission evaluation in the TLPD group was due to a shorter hospital stay and reduced requirement for parenteral alimentation. From the thinking of learning cost, the cost of admission evaluation also must not decrease compared with OPD. Our operation could be done without any laparoscopic supplies.

## 6. Conclusions

In conclusion, the goal of minimal invasive surgery might be TLPD; however, there are several problems, for example, safety, complications, medical cost, and learning cost. Our PD by Shuriken-shaped umbilicoplasty with the real-time moving window's method might be a useful way for overcoming the above obstacles. Also, our new device of PJ reconstruction by PSSGM might be an easy and a useful device for preventing PL.

## Abbreviations

PD	pancreaticoduodenectomy
LPD	laparoscopic pancreaticoduodenectomy
ISGPF	international study group on pancreatic fistula
PJ	pancreaticojejunostomy
PSSGM	punctured stent slide guiding method
PL	pancreatic leakage

## Author details

Yoshinobu Sato<sup>1,2\*</sup>, Yoshiaki Hara<sup>1</sup>, Naruhiko Sawada<sup>1</sup>, Shoji Shimada<sup>1</sup>, Kenta Nakahara<sup>1</sup>, Daisuke Takayanagi<sup>1</sup>, Fumio Ishida<sup>1</sup>, Shin-EI Kudo<sup>1</sup> and Junichi Tanaka<sup>2</sup>

\*Address all correspondence to: kanishok@med.showa-u.ac.jp

1 Digestive Disease Center, Showa University, Yokohama Northern Hospital, Yokohama, Japan

2 Department of General and Digestive Surgery, Showa University, Fujigaoka Hospital, Fujigaoka, Japan

## References

- [1] Machado MA, Surjan RC, Basseres T, Silva IB, Makdissi FF. Laparoscopic pancreatoduodenectomy in 50 consecutive patients with no mortality: a single-center experience. *J Laparoendosc Adv Surg Tech A*. 2016 Apr 26 [Epub ahead of print].
- [2] Nagakawa Y, Hosokawa Y, Sahara Y, Takishita C, Nakajima T, Hijikata Y, Tago T, Kasuya K, Tsuchida A. A novel “artery first” approach allowing safe resection in laparoscopic pancreaticoduodenectomy: the uncinata process first approach. *Hepatogastroenterology*. 2015 Jun;62(140):1037–1040.
- [3] Doula C, Kostakis ID, Damaskos C, Machairas N, Vardakostas DV, Feretis T, Felekouras E. Comparison between minimally invasive and open pancreaticoduodenectomy: a systematic review. *Surg Laparosc Endosc Percutan Tech*. 2016 Feb;26(1):6–16.
- [4] Sato Y, Sawada N, Shimada M, Takayanagi D, Mukai S, Shimada S, Kida H, Ishida F, Kudo S-E. Hybrid laparoscopic complete uncinatactomy of pancreas by shuriken shaped umbilicoplasty with sliding window’s method. *Hepatogastroenterology*. 2014;61:1486–1488.
- [5] Gagner M, Pomp A. Laparoscopic pylorus-preserving pancreatoduodenectomy. *Surg Endosc*. 1994;8:408–410.
- [6] Gagner M, Pomp A. Laparoscopic pancreatic resection: is it worthwhile? *J Gastrointest Surg* 1997;1:20–26.
- [7] Cuschieri A. Laparoscopic surgery of the pancreas. *J R Coll Surg Edinb*. 1994;39:178–184.
- [8] Kimura Y, Hirata K, Mukaiya M, Mizuguchi T, Koito K, Katsuramaki T. Hand-assisted laparoscopic pylorus-preserving pancreaticoduodenectomy for pancreas head disease. *Am J Surg*. 2005;189:734–737.
- [9] Ammori BJ. Laparoscopic hand-assisted pancreaticoduodenectomy: initial UK experience. *Surg Endosc*. 2004;18:717–718.
- [10] Masson B, Sa-cunha A, Laurent C. Laparoscopic pancreatectomy: report of 22 cases. *Ann Chir*. 2003;128:452–456.
- [11] Staudacher C, Orsenigo E, Baccari P, Palo SD, Crippa S. Laparoscopic assisted duodeno-pancreatectomy. *Surg Endosc*. 2005;19:352–356.
- [12] Giulianotti PC, Coratti A, Angelini M, Sbrana F, Cecconi S, Balestracci T, Caravaglios G. Robotics in general surgery: personal experience in a large community hospital. *Arch Surg*. 2003;138:777–784.
- [13] Palanivelu C, Jani K, Senthilnathan P, Parthasarathi R, Rajapandian S, Madhankumar MV. Laparoscopic pancreaticoduodenectomy: technique and outcomes. *J Am Coll Surg*. 2007;205:222–223.

- [14] Dulucq JL, Wintringer P, Mahajna A. Laparoscopic pancreaticoduodenectomy for benign and malignant diseases. *Surg Endosc.* 2006;20:1045–1050.
- [15] Zureikat AH, Breaux JA, Steel JL, Hughes SJ. Can laparoscopic pancreaticoduodenectomy be safely implemented? *J Gastrointest Surg.* 2011;15:1151–1157.
- [16] Kendrick ML, Cusati D. Total laparoscopic pancreaticoduodenectomy; feasibility and outcome in an early experience. *Arch Surg.* 2010;145:19–23.
- [17] Giulianotti PC, Sbrana F, Bianco FM, Elli EF, Shah G, Addeo P, Caravaglios G, Coratti A. Robot-assisted laparoscopic pancreatic surgery: single-surgeon experience. *Surg Endosc.* 2010;24:1646–1657.
- [18] Kakita A, Yoshida M, Takahashi T. History of pancreaticojejunostomy in pancreaticoduodenectomy: development of a more reliable anastomosis technique. *J Hepatobiliary Pancreat Surg.* 2001;8:230–237.
- [19] Grobmyer SR, Kooby D, Blumgart LH, Hochwald SN. Novel pancreaticojejunostomy with a low rate of anastomotic failure-related complications. *J Am Coll Surg.* 2010;210:54–59.
- [20] Satoi S, Toyokawa H, Yanagimoto H, Yamamoto T, Hirooka S, Yui R, Yamaki S, Takahashi K, Matsui Y, Mergental H, Kwon AH. Is a nonstented duct-to-mucosa anastomosis using the modified Kakita method a safe procedure? *Pancreas.* 2010;39:165–170.
- [21] Mishra PK, Saluja SS, Gupta M, Rajalingam R, Pattnaik P. Blumgart's technique of pancreaticojejunostomy: an appraisal. *Dig Surg.* 2011;28:281–287.
- [22] Oda T, Hashimoto S, Miyamoto R, Shimomura O, Fukunaga K, Kohno K, Ohshiro Y, Akashi Y, Enomoto T, Ohkohchi N. The tight adaptation at pancreatic anastomosis without parenchymal laceration: an institutional experience in introducing and modifying the new procedure. *World J Surg.* 2015;39:2014–2022.
- [23] Sato Y, Nakatsuka H, Yamamoto S, et al. Living related pancreas transplantation alone with enteric drainage in Japan: case report. *Transplant Proc.* 2008;40:2559–2561.
- [24] Sato Y, Oya H, Yamamoto S, Kokai H, Miura K, Hatakeyama K. Heterotopic pancreas autotransplantation with spleen for uncontrollable hemorrhagic pseudocyst and disabling pain in chronic pancreatitis. *Hepato-Gastroenterology.* 2013;60:425–427.
- [25] Wang M, Meng L, Cai Y, Li Y, Wang X, Zhang Z, Peng B. Learning curve for laparoscopic pancreaticoduodenectomy: a CUSUM analysis. *J Gastrointest Surg.* 2016;20:924–935.