

# We are IntechOpen, the world's leading publisher of Open Access books Built by scientists, for scientists

**4,800**

Open access books available

**122,000**

International authors and editors

**135M**

Downloads

Our authors are among the

**154**

Countries delivered to

**TOP 1%**

most cited scientists

**12.2%**

Contributors from top 500 universities



**WEB OF SCIENCE™**

Selection of our books indexed in the Book Citation Index  
in Web of Science™ Core Collection (BKCI)

Interested in publishing with us?  
Contact [book.department@intechopen.com](mailto:book.department@intechopen.com)

Numbers displayed above are based on latest data collected.

For more information visit [www.intechopen.com](http://www.intechopen.com)



---

# Diagnostic Laparoscopy for Abdominal Tuberculosis: A Promising Tool for Diagnosis

Arshad M. Malik

Additional information is available at the end of the chapter

<http://dx.doi.org/10.5772/64611>

---

## Abstract

**Introduction:** Abdominal tuberculosis has plagued the mankind over several decades and is a major reason of morbidity and mortality even today in the developing world. It's a difficult problem to diagnose as most patients present with vague and nonspecific symptomatology. This study was performed with a view to find out an efficient and practical tool for diagnosing this problem.

**Methods:** This analytical descriptive study including 283 patients of abdominal tuberculosis is a continuation of an earlier study by the author in the same context. The study was conducted to highlight the usefulness of diagnostic laparoscopy in patients with vague abdominal symptoms, posing difficulty in establishing a conclusive diagnosis. The study extended over a nine-year period in a teaching hospital as well as some private hospitals. The data was collected and statistically analyzed on SPSS version 22.

**Results:** We had a total of 266 patients with unsettled diagnosis having vague abdominal symptoms. Out of the total study subjects, 214 (80.45%) were finally conclusively diagnosed to have abdominal tuberculosis on diagnostic laparoscopy. Abdominal pain is the most frequent symptom which makes the patients seek medical advice coupled with changing bowel habits, loss of weight and generalized weakness. Laparoscopy revealed various tuberculous lesions which were biopsied and diagnosed.

**Conclusion:** Diagnostic laparoscopy is a potential answer for the diagnostic dilemma posed by abdominal tuberculosis. Its efficacy and reliability need further studies in future.

**Keywords:** abdominal tuberculosis, diagnostic dilemma, morbidity, cost-effectiveness

## 1. Background

Abdominal tuberculosis remains one of the commonest and most difficult diseases globally as far as the diagnosis is concerned [1–5]. It is also one of the common extra-pulmonary sites for tuberculous lesions. The disease may affect any part of the gut and may produce a chronic illness with vague abdominal symptoms or else may present in an acute obstructive form. The gravity of this problem is further increased by the vague and totally non-specific symptomatology [6–7]. The presentation of abdominal tuberculosis always mimics many other conditions like inflammatory bowel diseases and other similar conditions [8–10]. This state of confusion usually leads to an undue delay in diagnosis and treatment plan and thus further increases the overall morbidity. A large number of these patients present with acute abdomen and are diagnosed on exploratory laparotomy only. This actually has been a practice in our setup where a large number of patients undergo unnecessary laparotomies. These laparotomies could be easily avoided had there been an efficient and reliable method to diagnose abdominal tuberculosis. This actually led to the consideration of diagnostic laparoscopy in all patients with suspected abdominal tuberculosis to find out tuberculous lesions and to take biopsy of any such foci. This proved to be a breakthrough with a very encouraging result [11–13]. The study focused on the possible role of laparoscopy to establish the histopathological diagnosis of tuberculosis in patients having a high degree of suspicion but we found it difficult to establish a concrete diagnosis. Early diagnosis and starting anti-tuberculous treatment and an early resort to the anti-tuberculous treatment can come after morbidity can facilitate an early recovery and an early return to work. This has a lot of benefits to the patient, the community and a major cut short on the health facility.

### 1.2. Pathology and pathogenesis

Tuberculosis is a common problem in developing countries like Pakistan, India, Bangladesh, etc. In the early 1990s, it was considered a lethal disease as there were no medications effective against the tubercle bacillus. With the advent of anti-tuberculous drugs, the disease is no more a problem as it used to be in the past. The disease represents one of the most dreaded forms of extra-pulmonary disease and can affect virtually all parts of the GIT including intestines and various abdominal viscera.

The portal of entry of mycobacterium into the GIT is through ingestion of the infected sputum, via blood, or there may be a direct spread from infected contiguous organs like fallopian tubes, etc. [14]. The abdominal tuberculosis is divided into the following categories based on the gross appearance and involvement of the target tissue.

- A. Intestinal tuberculosis
- B. Glandular tuberculosis
- C. Peritoneal tuberculosis
- D. Solid organs

Rathi et al. [15] claim that abdominal tuberculosis constitutes 11% of the extra-pulmonary sites and the commonest area affected is the ileocecal region. The intestinal tuberculosis usually has three gross pathological forms as under

- a. Hypertrophied
- b. Ulcerative
- c. Strictureous

The ileocecal tuberculosis is always a hypertrophied lesion which may present with acute intestinal obstruction. The ulcerative lesion is in the form of mucosal ulcers which usually present with diarrhoea and other abdominal symptoms. There is a recent claim that the extra-pulmonary manifestations of tuberculosis are observed with increasing frequency in Immuno-suppressed patients and more so with HIV patients as an accompaniment of the chronic illness [16]. An early diagnosis is the key to a curable non-operative treatment as a vast majority of these patients can be treated by anti-tuberculous drugs and thus can be saved from an undue laparotomy. In order to achieve this goal, the first and the foremost thing is to have a high index of suspicion about this entity [17] coupled with expertise in the laparoscopic technique.

## 2. Methods

This analytical descriptive study was conducted in a teaching hospital as well as some private hospitals. The study subjects attended the outpatient department with acute or chronic presentations. Patients having a totally confusing symptomatology and vague symptoms where a firm conclusive diagnosis could not be established were included in the study and were informed about the purpose of the study and the possible outcome. Having learnt the objectives of the study, only those who gave their consent were enrolled and admitted in the hospital. Patients who were already diagnosed as ileocecal tuberculosis or were on anti-tuberculous treatment were excluded. Upon arrival, the initial management was totally determined by the mode of presentation. Patients with acute presentation were resuscitated with I/V fluids and decompressed by nasogastric suction to stabilize for intervention. The patients who presented with vague abdominal symptoms were thoroughly examined and were given conservative treatment to correct body fluids and electrolytes and to relieve pain.

After having done the initial resuscitation and management, investigations were sent including blood complete picture, chest x-ray, abdominal x-rays, ultrasound examination and CT scan in some patients. Failing to achieve a conclusive clue on abdominal examination and investigations, a diagnostic laparoscopy was planned, keeping in view a very high incidence of the tuberculosis in our part of the world. The various variables studied included demographics, clinical presentations, common laboratory results and outcomes of diagnostic laparoscopy.

### 3. Results

Of the total study subjects, 266 patients were chosen for diagnostic laparoscopy based on the fact that their findings and symptomatology were so vague that a conclusion could not be drawn from the clinical examination and the usual laboratory workup. The demographics included 186 (70%) males and 80 (30%) females with a mean age of 36.59, range of 48 (17–65) and a standard deviation of 10.875. The main symptoms and the mode of presentation of the patients are shown in **Table 1**. The minimum duration of the symptoms was found to be eight days (3%), while the maximum duration of symptoms was found to be > 1 month (43%). A vast majority (81%) of the patients were found to have haemoglobin < 10 G%. Ultrasound examination was not a very helpful tool as depicted in **Table 2**. The Mantoux test was positive only in eight (3%) patients while 97% had a negative Mantoux. Erythrocyte sedimentation rate (ESR) was raised in a high number of patients (97%). Generalised tenderness of abdomen and weakness was present in 88% of the study population, while the remaining patients had insignificant examination findings. Chest x-ray was absolutely normal in 250 (94%) of the total study subjects. The various laparoscopic findings are shown in **Table 3**. One hundred and seventy-eight (67%) patients had a positive history of taking off and on anti-tuberculous medication prescribed by the local general practitioners. Most of the patients, referred from far flung areas, referred from remote far flung areas had positive laparoscopic findings compared to the urban population ( $p < 0.001$ ). Of the total population, we were able to confirm histopathological diagnosis in 259 patients having different forms of abdominal tuberculosis. The various tuberculous findings on laparoscopy are found in **Figures 1–3**. Stricture pathology and obstructive ileocecal tuberculosis needed operative intervention in 23 (9%) patients while remaining patients received a full course of anti-tuberculous drugs and showed full recovery. A follow-up of these patients was carried for a period of three years.

	Main symptoms			Total
	Sub-acute intestinal obstruction	Vague abdominal pain and loss of weight	Chronic off-and on-obstruction	
Mode of presentation				
Acute	0	0	12	12
Chronic	2	180	0	182
Acute-on-chronic	66	0	6	72
Total	68	180	18	266

**Table 1.** Mode of presentations and main symptoms.

	Frequency	Percentage	Total
Inconclusive	150	56	
Diagnosed tuberculosis	34	12.78	266
Gave suspicion of tuberculosis	82	30	

**Table 2.** Ultrasound abdomen results.

Finding	Frequency	Percentage
No abnormality detected	52	19
Miliary tuberculosis found	104	39
Mesenteric lymphadenopathy detected	90	34
Intestinal strictures found	20	7.5

Table 3. Various laparoscopic findings.

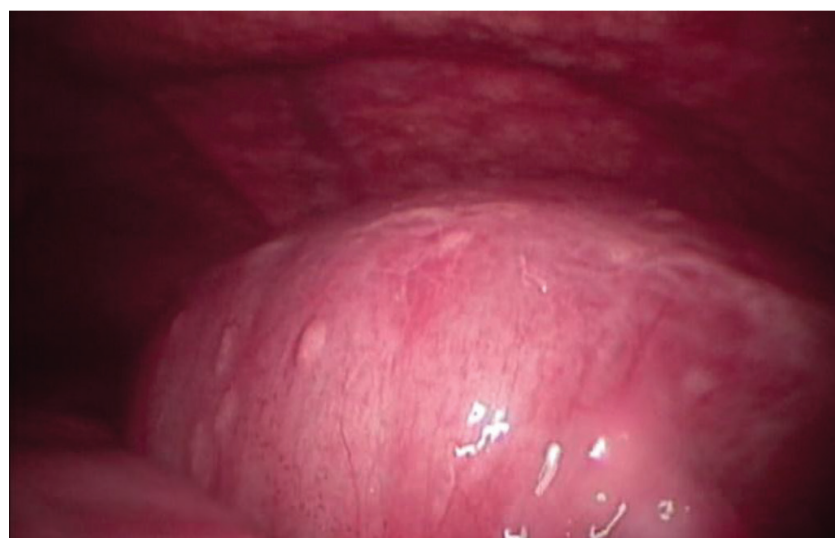

Figure 1. Miliary tubercles on the intestinal wall and abdominal wall.

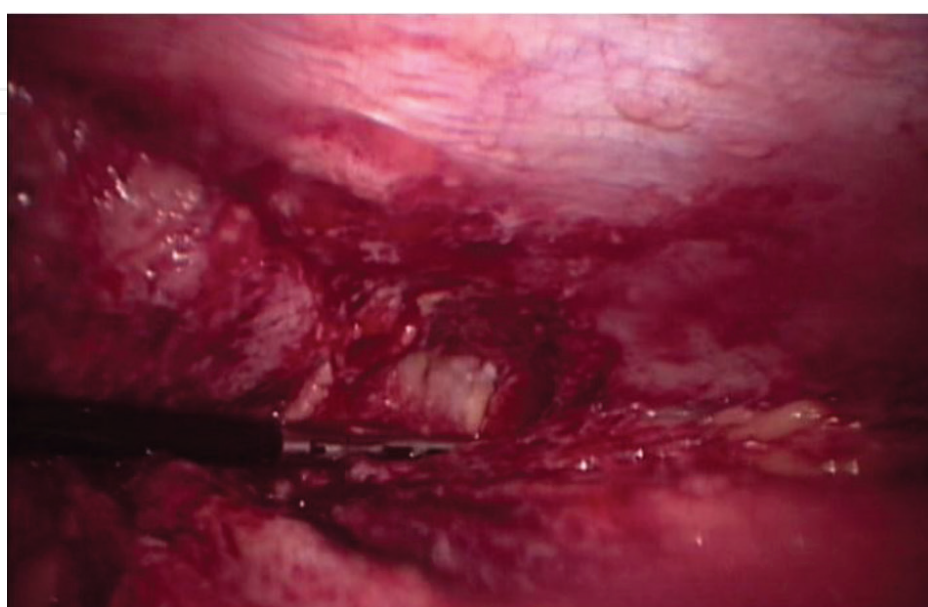
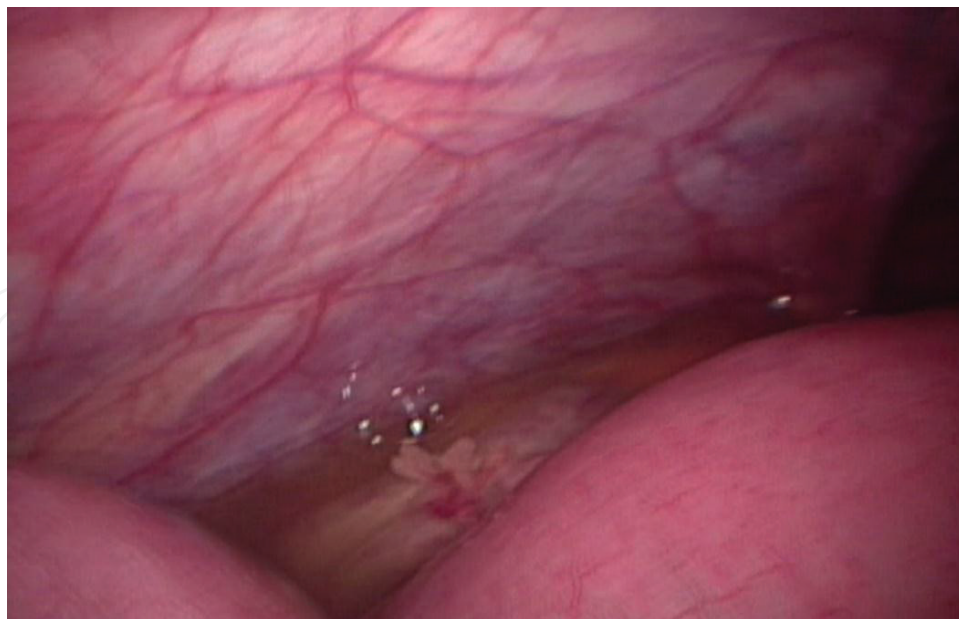

Figure 2. Plastic adhesions.



**Figure 3.** Ascitic fluid.

### **3.1. Difficulties and limitations**

Although apparently an excellent diagnostic tool for the diagnosis of abdominal tuberculosis, at times we faced a lot of problems especially when there are severe plastic adhesions and more so when you find an abdominal cocoon. It is usually very difficult to introduce the first trocar in such situations.

## **4. Discussion**

Abdominal tuberculosis remains a difficult major health issue all over the world. It is highly challenging and a dreaded problem for surgeons working in far-flung remote areas with limited resources and facilities. It is a diagnostic challenge for surgeons globally but more so in the third-world countries where the disease is rife and remains unnoticed till it turns into a serious emergency. The abdominal tuberculosis is known for its varied and confusing symptomatology whereby it mimics closely with various other similar diseases like inflammatory bowel diseases [18–19]. The unusual presentation and confusion in diagnosis usually lead to unnecessary and avoidable laparotomies, which is most of the time performed as a last resort to reach to a conclusive diagnosis. Contrary to the earlier reports, the developing countries are showing a fearful increase in the incidence of abdominal tuberculosis, as reported in recent studies [20–22]. The increase in the prevalence of abdominal tuberculosis in the developing countries is attributed to a rising incidence of HIV-positive population linking it to immunosuppression [12, 19]. The age incidence of our study population coincides with other similar reports [20]. The male dominance is very clear in our studies as reported by other similar studies [18]. The varied presentation is the hallmark of abdominal tuberculosis, and as

shown in our results, it is also consistent with and reported by other similar reports [23–24]. Our study highlights the fact that there is a very alarmingly high incidence of this disease in the poor, underprivileged rural population of Sind province of Pakistan. It is highly recommended to have a high level of suspicion to reach a conclusive diagnosis whenever a patient presents with vague abdominal symptoms [25]. There is hardly any absolutely reliable diagnostic test that can give a 100% confirmed diagnosis of abdominal tuberculosis. This simply is the reason for an unnecessary and life-threatening delay in the diagnosis of this disease [8, 26]. The diagnostic laparoscopy and biopsy of the tuberculous lesions are not a recent advancement but are rather known for over 30 years now [27]. It however has not been practiced widely and as commonly as it should have been. Even today, this diagnostic tool has not attracted the desired level of attention and usually is considered a last resort rather than the first in difficult diagnostic situations. In the current study, we gave it a place of primary investigation tool along with other diagnostic tests and we found it extremely encouraging as the yield of diagnosis is over 80%, in line with other similar studies [28–29]. Diagnostic laparoscopy prompts the diagnosis and can reduce the delay which can increase the morbidity and can lead to unnecessary laparotomies while improving the outcome [30–31]. Despite all the benefits, some limitations like a deceiving view leading to mis-diagnosis regardless of the experience of surgeon are mentioned by few studies [32–35].

## 5. Conclusion

The diagnostic laparoscopy in suspected cases of abdominal tuberculosis is an efficient and rewarding method of diagnosis. A regular use of this diagnostic modality can improve the overall outlook of this common disease in the developing world.

## Author details

Arshad M. Malik

Address all correspondence to: [arshadhamzapk@yahoo.com](mailto:arshadhamzapk@yahoo.com)

College of Medicine, Qassim University, Saudi Arabia

## References

- [1] Aston NO. Abdominal tuberculosis. *World J Surg* 1997; 21(5):492–9.
- [2] Rai S, Thomas WM. Diagnosis of abdominal tuberculosis: The importance of laparoscopy. *J R Soc Med* 2003; 96:586–8.
- [3] Bouma BJ, Tytgat KMAJ, Shipper HG, Kager PA. Be aware of abdominal tuberculosis. *Neth J Med* 1997; 51:119–22.



- [4] Shakil AO, Korula J, Kanel GC, Murray NGB, Reynolds TB. Diagnostic features of tuberculous peritonitis in the absence and presence of chronic liver disease: A case control study. *Am J Med* 1996; 100:179–85.
- [5] Sinkala E, Gray S, Zulu I, Mudenda V, Zimba L, Vermund SH, Droniewski F, Kelly P. Clinical and ultrasonological features of abdominal tuberculosis in HIV positive adults in Zambia. *BMC Infect Dis* 2009; 9:44.
- [6] Uygur-Bayramicli O, Dabak G, Babak R. A clinical dilemma: Abdominal tuberculosis. *World J Gastroenterol* 2003; 9(5):1098–101.
- [7] Krishnan P, Vayoth SO, Dhar P et al. Laparoscopy in suspected abdominal tuberculosis is useful as an early diagnostic method. *ANZ J Surg* 2008; 78(11):987–9.
- [8] Akcam M, Artan R, Yilmaz A, Cig H, Aksoy NH. Abdominal tuberculosis in adolescents. Difficulties in diagnosis. *Saudi Med J* 2005; 26(1):122–6.
- [9] Ramesh J, Banait GS, Ormerod LP. Abdominal tuberculosis in a district general hospital: A retrospective review of 86 cases. *Q J Med* 2008; 101:189–95.
- [10] Jaydyar H, Mindelzun RE, Olcott EW, Levitt DB. Still a great mimicker: Abdominal tuberculosis. *Am J Radiol* 1997; 168:1455–60.
- [11] Salky BA, Edey MB. The role of laparoscopy in the diagnosis and treatment of abdominal of abdominal pain syndromes. *Surg Endosc* 1998; 7(12):911–4.
- [12] McLaughlin S, Jones T, Pitcher M, Evans P. Laparoscopic diagnosis of abdominal tuberculosis. *ANZ J Surg* 2008; 68(8):599–601.
- [13] Sharma MP, Bhatia V. Abdominal tuberculosis. *Indian J Med Res.* 2004; 120(4):305–15.
- [14] Rathi P, Gambhire P. Abdominal tuberculosis. *J Assoc Physicians India.* 2016; 64(2):38–47.
- [15] Kienzl-Palma D, Prosch H. Extrathoracic manifestations of tuberculosis. *Radiologe.* 2016; 56(10):885–9.
- [16] Debi U, Ravisankar V, Prasad KK, Sinha SK, Sharma AK. Abdominal tuberculosis of the gastrointestinal tract: Revisited. *World J Gastroenterol.* 2014; 20(40):14831–40. doi:10.3748/wjg.v20.i40.14831.
- [17] Sinan T, Sheikh M, Ramadan S, Sahwney S, Behbehani A. CT features in abdominal tuberculosis: 20 years experience. *BMC Med Imag* 2002; 2(1):3.
- [18] Jadvar H, Mindelzun RE, Olcott EW, Levitt DB. Still the great mimicker: Abdominal tuberculosis. *Am J Roentgenol* 1997; 168:1455–60.
- [19] Navaneethan U, Cherian JV, Prabhu R, Venkataraman J. Distinguishing tuberculosis and Crohn's disease in developing countries: How certain can you be of the diagnosis? *Saudi J Gastroenterol* 2009; 15(2):142–4.
- [20] Kapoor V. Abdominal tuberculosis. *Medicine* 2009; 35(5):257–60.
- [21] Kishore PV, Palaian S, chandersekhar TS. Diagnosing tuberculosis. A retrospective study from Nepal. *Internet J Gastroenterol* 2008; 6(2):1–6

- [22] Al Karawi MA, Mohammed AE, Yasawy MI, Graham DY, Shariq S, Ahmed AM et al. Protean manifestations of gastrointestinal tuberculosis; report on 130 patients. *J Clin Gastroenterol* 1995; 20(3):225–32.
- [23] Tan KK, Chen K, Sim R. The spectrum of abdominal tuberculosis in a developed country: A single institutions experience over 7 years. *J Gastrointest Surg* 2009; 13(1):142–7.
- [24] Vyravanathan S, Jeyarajah R. Tuberculous peritonitis: A review of thirty-five cases. *Post Grad Med J* 1980; 56(659):649–51.
- [25] Uzunkoy A, Harma M, Harma M. Diagnosis of abdominal tuberculosis: Experience from 11 cases and review of the literature. *World J Gastroenterol* 2004; 10(24):3647–9.
- [26] Al Muneef M, Memish Z, Al Mahmoud S, Al Sadoon S, Bannatyne R, Khan Y. Tuberculosis in the belly: A review of forty six cases involving the gastrointestinal tract and peritoneum. *Scand J Gastroenterol* 2001; 36(5):528–32.
- [27] Tarcoveanu E, Flip V, Moldovanu R, Dimofte G, Lupascu C, Vlad N et al. Abdominal tuberculosis- a surgical reality. *Chirurgia (Bucur)* 2007; 102(3):303–8.
- [28] Machado N, Grant CS, Scrimgeour E. Abdominal tuberculosis—experience of a university hospital in Oman. *Acta Trop* 2001; 80(2):187–90.
- [29] Trujillo NP. Peritoneoscopy and guided biopsy in the diagnosis of intra abdominal diseases. *Gastroenterology* 1976; 71:1083–5.
- [30] Singh-Ranger D. Diagnosis of abdominal tuberculosis. *J R Soc Med* 2004; 97:154–7.
- [31] Udwardia TE. Diagnostic laparoscopy. *Surg Endosc* 2004; 18(1):6–10.
- [32] Al-Akeely MH. Impact of elective diagnostic laparoscopy in chronic abdominal disorders. *Saudi J Gastroentrol* 2006; 12(1):27–30.
- [33] Cached J, Mekki M, Mansour A, Ben Brahim M, Maazoun K, Hidouri S et al. Contribution of laparoscopy in abdominal tuberculosis diagnosis: Retrospective study of about 11 cases. *Pediatr Surg Int* 2010; 26(4):413–8.
- [34] Tarcoveanu E, Dimofte G, Bradea C, Lupascu C, Moldovanu R, Vasilescu A. Peritoneal tuberculosis in laparoscopic era. *Acta Chir Belg* 2009; 109(1):65–70.
- [35] Meshikhes AW. Pitfalls of diagnostic laparoscopy in abdominal tuberculosis. *Surg Endosc* 2010; 24(4):908–10.

