

# We are IntechOpen, the world's leading publisher of Open Access books Built by scientists, for scientists

**4,800**

Open access books available

**122,000**

International authors and editors

**135M**

Downloads

Our authors are among the

**154**

Countries delivered to

**TOP 1%**

most cited scientists

**12.2%**

Contributors from top 500 universities



**WEB OF SCIENCE™**

Selection of our books indexed in the Book Citation Index  
in Web of Science™ Core Collection (BKCI)

Interested in publishing with us?  
Contact [book.department@intechopen.com](mailto:book.department@intechopen.com)

Numbers displayed above are based on latest data collected.

For more information visit [www.intechopen.com](http://www.intechopen.com)



---

# Intense Pulsed Light Therapy

---

Gu Weijie, Liu Hongmei and Liu Wei

Additional information is available at the end of the chapter

<http://dx.doi.org/10.5772/65345>

---

## Abstract

Intense pulsed light (IPL) is one of the most effective nonablative approaches to treat skin photoaging. The broad range of wavelengths (500–1200 nm) emitted from IPL devices effectively target both melanin and hemoglobin in the skin. Numerous trials show the effectiveness and compatibility of IPL devices in a variety of skin conditions, especially in cosmetic indications such as hypertrichosis and telangiectasias. Compared with the wide clinical use of IPL, the biochemical and molecular mechanism is not clear. Both *in vivo* and *in vitro* studies demonstrate that IPL could increase the production of extracellular matrix, promote the proliferation of fibroblasts, and increase the secretion of TGF- $\beta$  and matrix metalloproteinases, which play important roles in the photorejuvenation effects of IPL. However, investigations regarding the detailed underlying mechanism are necessary.

**Keywords:** intense pulsed light, photorejuvenation, fibroblast, collagen, matrix metalloprotease

---

## 1. Introduction

Intense pulse light (IPL) treatment currently represents one of the most popular nonablative photodamage skin treatments [1]. Initially, it was promoted as an approach for leg telangiectasias treatment. In continued use, this device was found to be of far greater utility for indications other than leg telangiectasias. IPL technology had its birthplace in San Diego in 1992, with the first commercial IPL system introduced in 1994, and cleared by the U.S. FDA in late 1995. In the last 22 years (1994–2016), more than 20 different laser companies have developed a wide variety of IPL devices, which testified the acceptance of IPL as a valid, efficacious technological breakthrough. First-generation IPL devices (Photoderm, ESC) emit light of the infrared part of the spectrum, which prevalently leads to epithelial damage and a high incidence of side effects. In

---

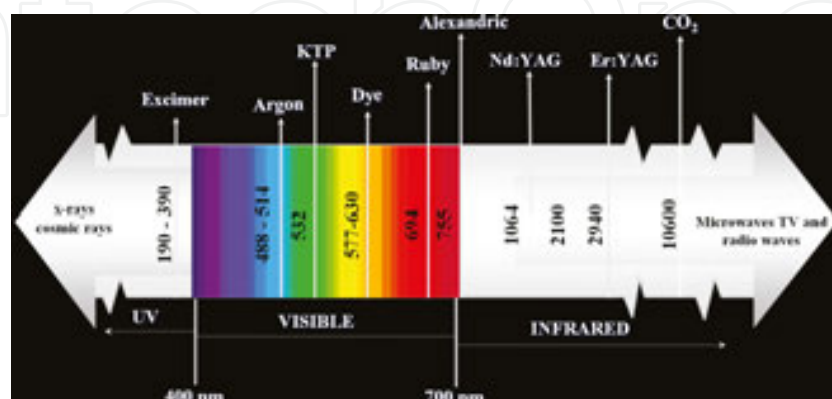
second- (Vasculight VL, ESC) and third-generation IPL devices (Quantum SR, Lumenis), water filters out the infrared portion, significantly reducing the risk of side effects. The fourth-generation IPL devices (Lumenis one, Lumenis) have improved the defects of the existing IPL. They maximize the effectiveness and minimize the side effects by fairly transferring energy to the entire face. Their proportionate distribution of energy allows to treat not only the skin surface but also inside the dermis where discoloration originates.

IPL is now considered the gold standard for treatment of many signs of photoaging, including facial telangiectasias, hyperpigmentation, and fine wrinkling. The main advantages of IPL are the lower risk of postinflammatory hyperpigmentation, minimal recovery downtime, long-term improvement, etc. [1].

## 2. Main body

### 2.1. Biophysical interactions

IPL is situated in the visible light and infrared radiation of the electromagnetic spectrum (**Figure 1**). The broad range of wavelengths (500–1200 nm) emitted from IPL devices effectively target all the three main chromophores (hemoglobin, water, and melanin) in human skin [2]. The wavelength determines not only the absorption behavior but also the penetration depth of the light, which increases with the wavelength (**Figure 2**). Cut-off filters are used to eliminate the shorter than desired wavelengths from a particular treatment to focus the residual emissions on the feature to be treated. The patient's skin type and the skin condition determine the choice of suitable cut-off filters and therefore the spectrum of wavelengths to be emitted. In addition, to avoid the burning of the epidermis, the skin can be cooled by applying a thick layer of cold gel or, with newer models, by integrated cooling on the IPL crystal [3, 4]. Compared with lasers devices, an important advantage of the IPL system is its relatively large spot size, which can increase the speed of treatment given that large areas can be treated quickly with fewer pulses. However, the hand pieces are larger and have a flat surface, hindering treatment of irregular surfaces.



**Figure 1.** IPL is situated in the visible light and infrared radiation of the electromagnetic spectrum (reprinted with permission of Lumenis company, Yokneam, Israel).

Pulses can be delivered singly, doubly, or triply, with variable delay between the pulses. Pulse duration can range widely from 0.5 to over 20 ms. Selective photothermolysis is the basic principle of IPL treatment. This often leads to cell necrosis, blood coagulation, and structure alterations, which contribute to the clinical and side effects of IPL. To prevent unselective damage to the surrounding tissue, pulse duration should be lower than the thermal relaxation time of the target structure. The particular wavelengths combined with pulse durations, pulse intervals, and fluences facilitates the treatment of a wide spectrum of skin conditions, such as vascular lesions, pigmented lesions, fine wrinkling, and unwanted hair growth.

The incidence of acute side effects has been markedly reduced with the newest progressive set of parameters. Most side effects associated to IPL photodepilation are transient and minimal, including stinging pain, swelling, and erythema. Blistering and scattered crusting are permanent side effects of overflued treatment. Before IPL treatment, a signed informed consent is mandatory. Therapy sequelae and potential side effects have to be mentioned.

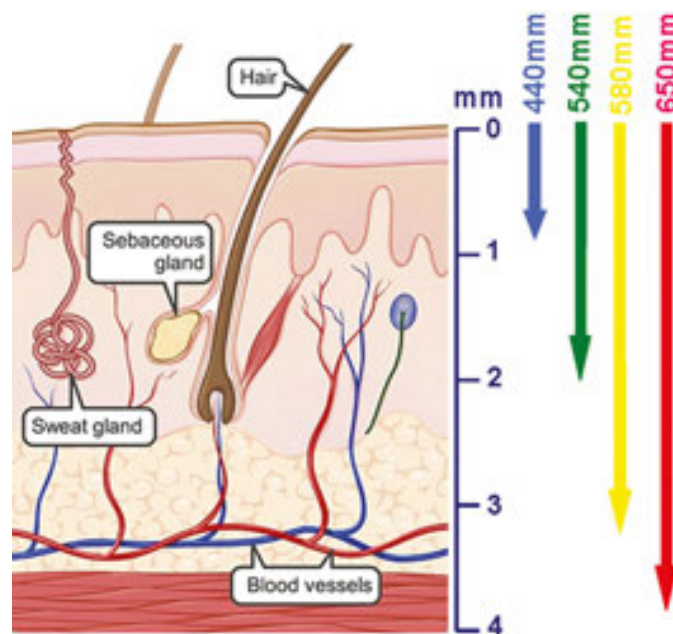


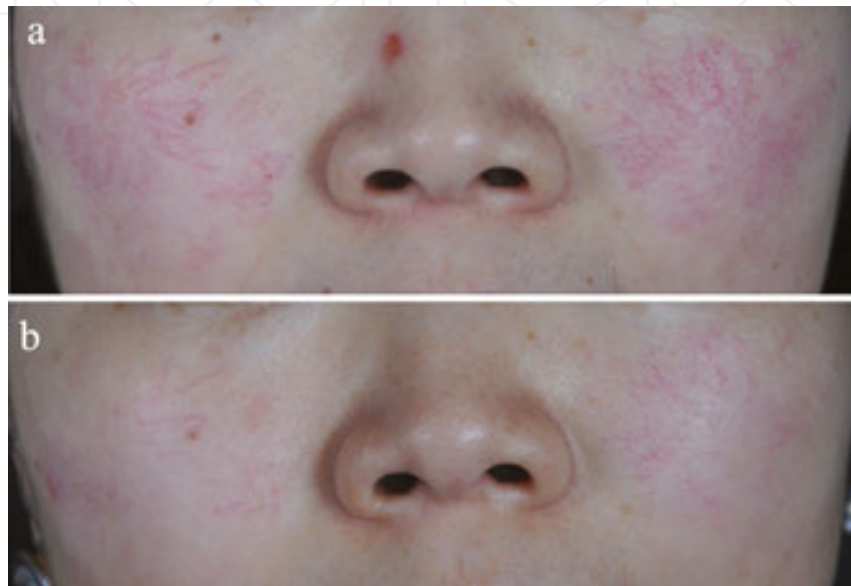Figure 2. Depth of light penetration into the skin, at various wavelengths.

## 2.2. Indications of IPL therapy

### 2.2.1. Facial telangiectasias

Pulsed dye laser (PDL) is considered the gold standard for vascular lesions. However, this technique is limited by the need to achieve postoperative purpura that lasts 10–14 days. In contrast, the absence of postoperative purpura and minimized postprocedure downtime are main advantages of IPL technology. IPL is able to raise the blood vessel temperature high enough to cause its coagulation, leading to its destruction and replacement by fibrous granulation tissue. The successful treatment of vascular lesions with IPL depends on the type and

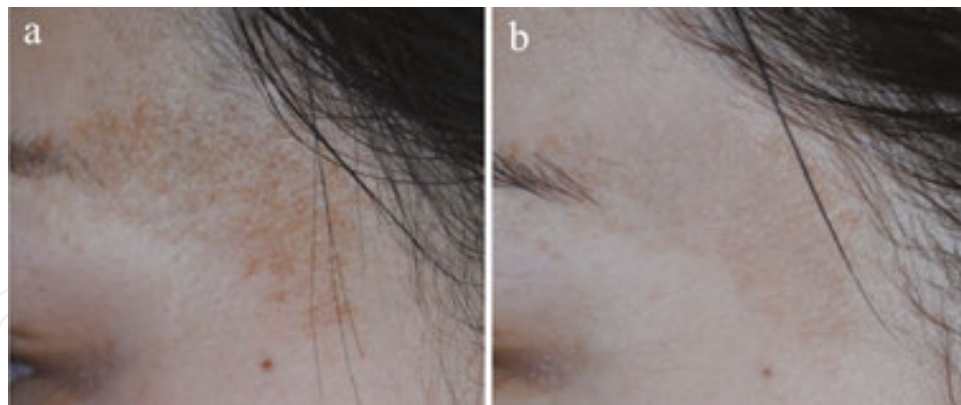
size of vessels targeted, with cherry angiomas and superficial telangiectatic veins typically demonstrating the best response. A study analyzed the effect of IPL on facial telangiectasias and found that 79.2% of patients achieved greater than 50% reduction of vessels after one to four treatments [5]. In the largest study to date, Clementoni analyzed 1000 patients with telangiectasias treated using IPL and found that 89.7% experienced 75–100% improvement. These telangiectasias included leg veins that had no associated feeding reticular veins [6]. In our clinical experience, facial telangiectasias achieved marked improvement after IPL treatment (**Figure 3a and b**).



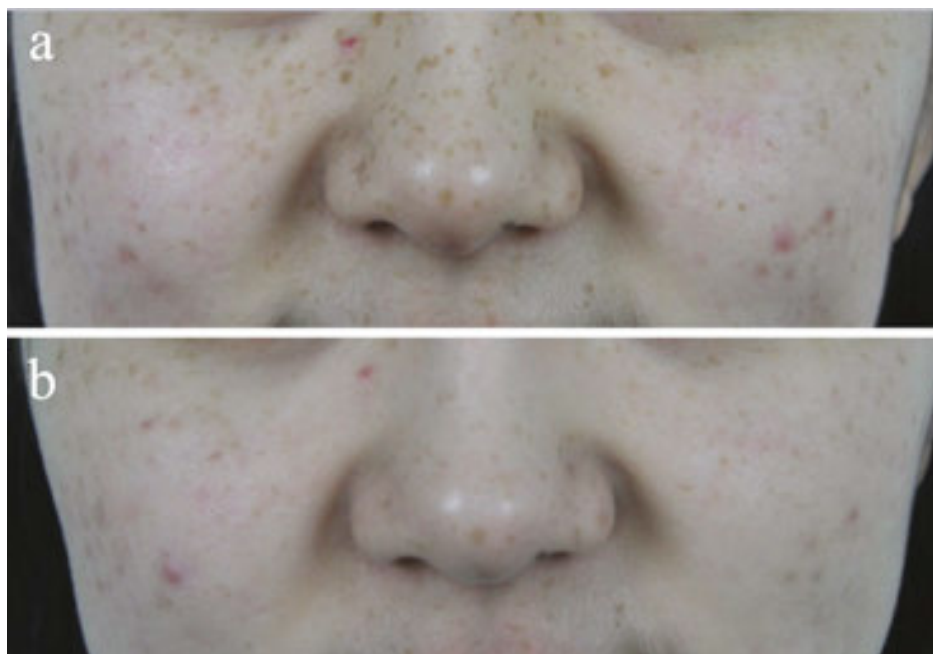**Figure 3.** (a) Facial telangiectasias before treatment and (b) after a single IPL treatment. (reprinted with the permission of Liu Hongmei Laser Center, Huangsi Aesthetic Surgery Hospital, Beijing, China).

### 2.2.2. Pigmented lesions

Pigmented lesions are frequent targets of laser and IPL treatment. Deep (dermal) pigmented lesions such as melanocytic nevi, nevi of Ota and Ito, drug-induced hyperpigmentation, Becker's nevi, nevus spilus, and tattoos may be preferred to Q-switched lasers [7, 8]. Superficial pigments include solar lentigines, ephelides, café-au-lait macules, and epidermal melasma, which respond well to IPL. Moreno Arias published a study in which 20 patients with pigmented lesions were treated with IPL. They concluded that greater efficacy (76–100%) was attained with superficial lesions (ephelides, epidermal melasma, café-au-lait spots) compared with efficacy of less than 25% for deep lesions (Becker's nevus, epidermal nevus, and mixed melasma) [9–11]. It is important to carefully assess each patient's skin type preoperatively and adjust the IPL settings appropriately to avoid complications. In darker skin types, there is a risk of inducing hyperpigmentation. The immediate endpoint from IPL treatment of dyschromia should be visible darkening of the treated brown spots. These typically crust over 24–48 h and peel off within 7 days. Satisfied results were achieved in café-au-lait macules (**Figure 4a and b**) and ephelides (**Figure 5a and b**) treatment by IPL.



**Figure 4.** Café-au-lait macules (a) before treatment and (b) after a single IPL treatment (reprinted with the permission of Liu Hongmei).



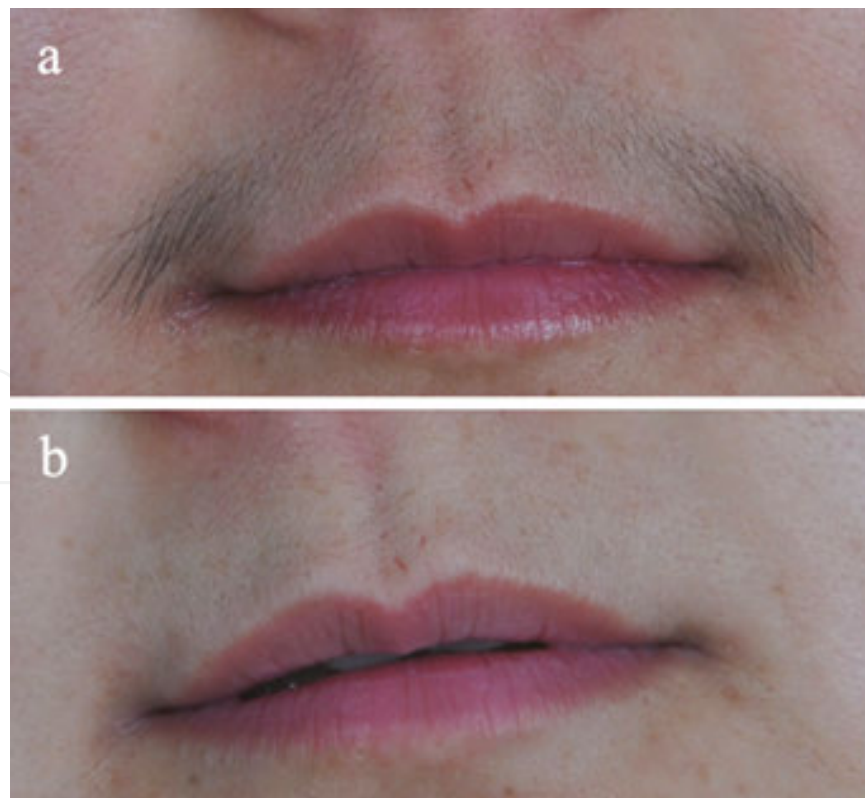**Figure 5.** Ephelides (a) before treatment and (b) after a single IPL treatment.

Melasma is commonly seen in the Asian population. Traditional therapies including depigmenting agents, chemical peels, and Chinese medicine have some therapeutic effects but are often unsuccessful for refractory melasma. IPL technology provided an effective approach for melasma treatment. Over the last decade, the demand for IPL therapy in treating melasma has risen steadily, although IPL was traditionally considered as a second-line treatment. Li reported that 69 of 89 Chinese patients (77.5%) being treated for melasma improved by more than 50% following a total of four IPL treatments at 3-week intervals [12]. Recently, low-fluence IPL and fractionated IPL were used in treating melasma. The latter IPL system delivers more than 40 subpulses of 40  $\mu$ s duration within milliseconds. In contrast to conventional IPL, fractionated IPL attenuates peak fluence and reduces nonselective heat diffusion, and is

assumed to be safer than its conventional IPL. Bae demonstrated that low-fluence and short-pulse duration IPL at dose of 10 and 13 J significantly decreased the modified MASI score in 20 Korean melasma patients. Yun's study showed that fractionated IPL had modest effectiveness in female Asian melasma patients. With regard to safety, fractionated IPL is a good alternative to conventional IPL with no indication that it exacerbates melasma [13, 14]. They suggested that low-fluence IPL protocol could provide more effective treatment for melasma with minimal side effects in Asian skin.

### 2.2.3. Hair removal

Hair removal has become a key indication for IPL devices. Safe and long-lasting hair reduction in cosmetically undesirable locations can be achieved with IPL devices. These IPL systems emit red and infrared light with wavelengths ranging 600–1200 nm, which are capable of targeting melanin in the hair shaft, follicular epithelium, and hair matrix. During treatment, concomitant epidermal cooling sources help to minimize unwanted thermal injury induced by epidermal melanin (particularly in patients with darker skin) [15]. To protect the epidermal melanin from thermal injury, IPL pulses can be divided in synchronized millisecond pulses separated by short thermal relaxation times. The hair follicle is most susceptible to IPL treatment during the anagen phase. In addition, the darker the skin and the brighter the hair, the less effective the treatment will be (**Figure 6**).



**Figure 6.** A woman with hypertrichosis (a) prior to treatment and (b) after five IPL treatments.

#### 2.2.4. Photorejuvenation

Photorejuvenation has been described as a dynamic nonablative process involving the use of the IPL to reduce mottled pigmentation and telangiectasias and smooth the textural surface of the skin. There are two types of photorejuvenation: type I photorejuvenation refers to vascular anomalies, pigmentary changes, or pilosebaceous changes, while type II is related to dermal and subcutaneous senescence. Histologically, analysis showed that both type I and type III collagens increased after IPL treatment, whereas the elastin content decreased but elastin fibers were more neatly arranged. According to transmission electron microscope investigations, the amount of fibroblast activity increased, the fibroblasts were more active, and more collagen fibers were neatly rearranged within the stroma. Thus, morphological evidence exists for clinical improvement of the skin texture [16].

#### 2.2.5. Poikiloderma of Civatte

Poikiloderma of Civatte consists of a reddish-brown reticulate pattern of pigmentation with associated telangiectasias and atrophic changes of the skin. There is no single effective treatment for poikiloderma of Civatte. Because of their ability to target vascular and pigment abnormalities simultaneously, IPL sources have been utilized in the treatment of poikiloderma of Civatte. Treatment of poikiloderma is one of the most effective uses of IPL technology [17]. In a previous study, 135 randomly selected patients with typical changes of poikiloderma of Civatte on the neck and/or upper chest underwent one to five IPL treatments [17]. Parameters included the 515- and 550-nm filters with pulse durations of 2–4 ms, either single or double with a 10-ms delay. Fluences were between 20 and 40 J/cm<sup>2</sup>. Clearance over 75% of hyperpigmentation was reported.

#### 2.2.6. Rosacea

Rosacea affects the appearance and can have important psychosocial effects.

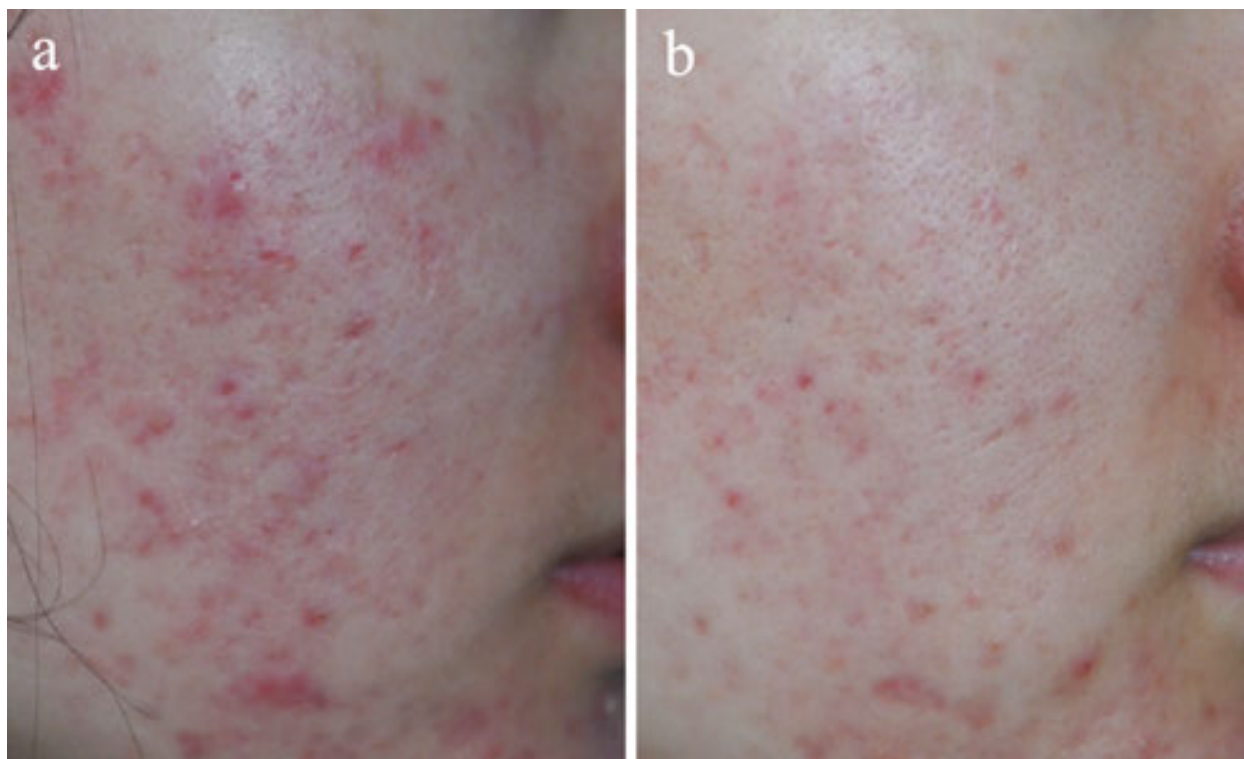
Erythematotelangiectatic rosacea is the most common and may have the strongest vascular component among the four subtypes. Studies showed that IPL significantly reduces erythema and telangiectasia of rosacea and this is sustained for at least 6 months.

#### 2.2.7. Acne

Acne vulgaris is a common disease in adolescents and young adults. Effective conventional therapies include oral and topical antibiotics and occasionally with oral and topical vitamin A. But these therapies were limited for adverse effects such as antibiotic resistance, teratogenicity, and skin dryness and irritation. IPL has been demonstrated to be an effective treatment for acne in Caucasians and Asian [18, 19]. Proposed mechanisms for the effects of our IPL therapy include photoinactivation of *P. acnes* and photothermolysis of the sebaceous glands, as well as anti-inflammatory action.

In our experience, significant improvement was observed in patients after two IPL treatments (**Figure 7a** and **b**).





**Figure 7.** Acne vulgaris (a) before treatment and (b) after two IPL treatment.

#### 2.2.8. Unconventional use of IPL

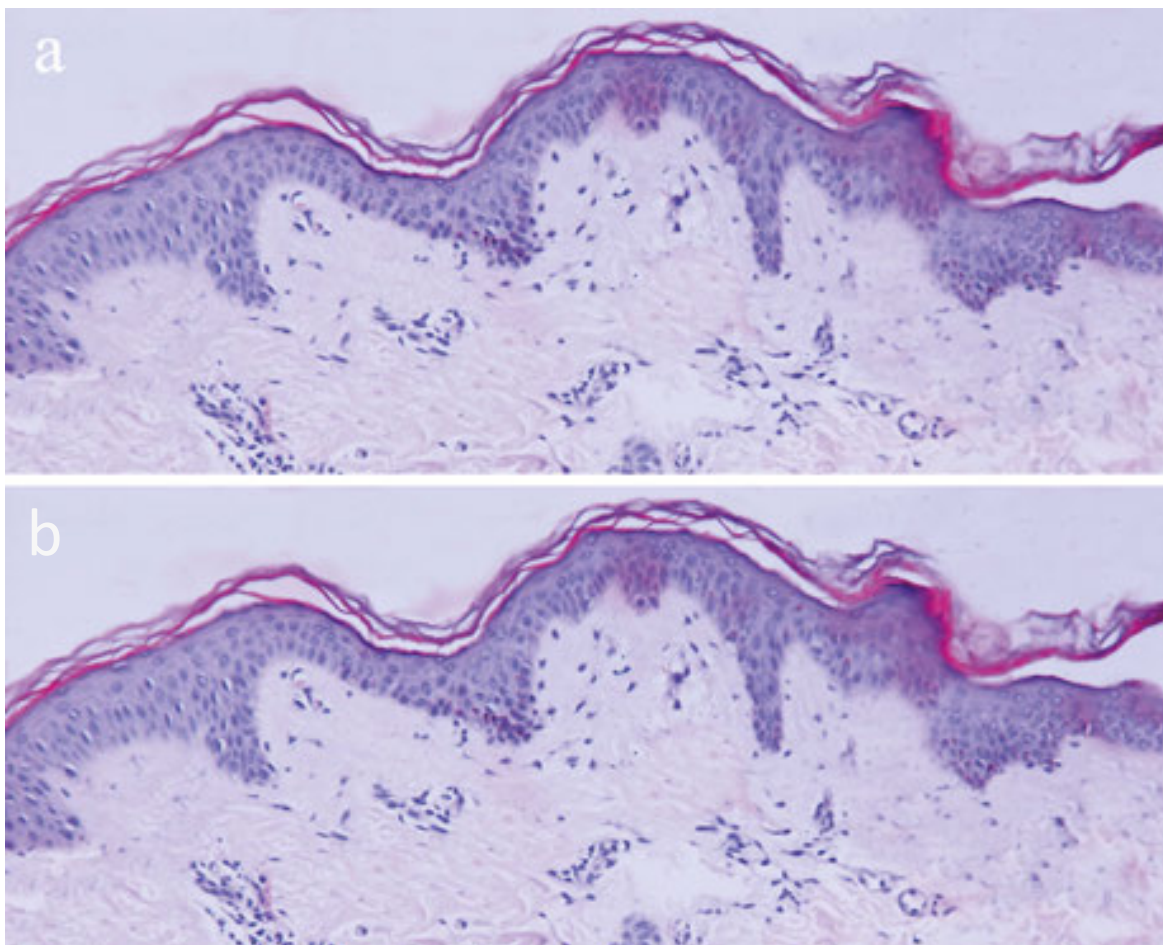
It is well known that UV irradiation resulted in DNA damage in microorganism. A study by Takeshita revealed that DNA damage, such as formation of single-strand breaks and pyrimidine dimers, was induced in IPL irradiated yeast cells. A new sterilization technique/technology based on the use of pulsed light, which has been developed by PurePulse Technologies (San Diego, CA, USA), is suggested to have great potential in the development of a new method of sterilization [20].

### 2.3. Mechanisms involved in IPL therapy

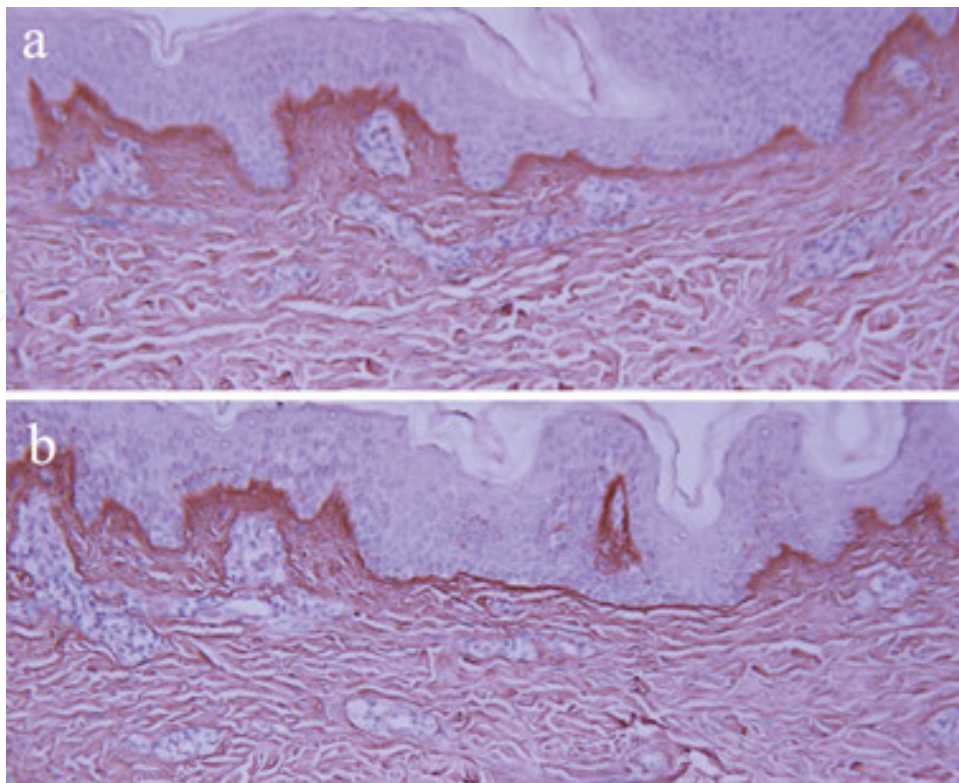
The efficacy of IPL in photorejuvenation of aged skin had been proven by numerous clinical trials. However, information regarding the precise mechanisms of IPL's actions is currently still far from complete, despite some achievements in recent years. The basic principle of IPL treatment is heating and selective photothermolysis, which can lead to cell necrosis (melanin damage), blood coagulation, and structure alterations. It has been proved that pigmented and vascular lesions treatment is based on the cell necrosis (melanin damage) and blood coagulation effects. The elimination of superficial wrinkles results from the structure alterations and collagen remodeling. However, the detailed mechanism involved in collagen remodeling, which many studies focus on, is not clear. Two aspects were included in the mechanism of IPL treatment, *in vivo* effects of IPL on the skin and *in vitro* effects of IPL on fibroblasts, cytokines, etc.

### 2.3.1. *In vivo* effects of IPL on the skin

Accumulation of procollagen I and procollagen III in porcine and human skin after IPL treatment has been documented by several studies [21, 22]. Enrique investigated the gross and microscopic changes after nonablative IPL facial resurfacing. All the patients showed clinical and microscopic improvement after IPL treatment. Microscopic improvement includes increased epidermal thickness, elimination of horny plugs, appearance of new rete ridges, and increase in the number of melanocytes and melanophages. Thickness of the epidermis showed a statistically significant increase after treatment ( $p < 0.01$ ; 0.24 vs. 0.36) [23]. Elastosis and collagen damage showed improvement after treatment, the elastotic masses disappeared and showed a more orderly and fibrillar pattern, parallel to the basal cell layer. In Gu's study, similar increase in epidermal thickness was found in IPL irradiated human buttock skin (17 J/cm<sup>2</sup>, four irradiations at 2-week intervals). Compared with the untreated control skin, IPL irradiated skin showed thicker stratum corneum and epidermis. Collagen fibers showed a more orderly pattern, parallel to the basal cell layer (**Figure 8a** and **b**). Immunohistochemistry showed more compactly arranged collagen I fibers and smaller interspaces in IPL-treated skin (**Figure 9a** and **b**).



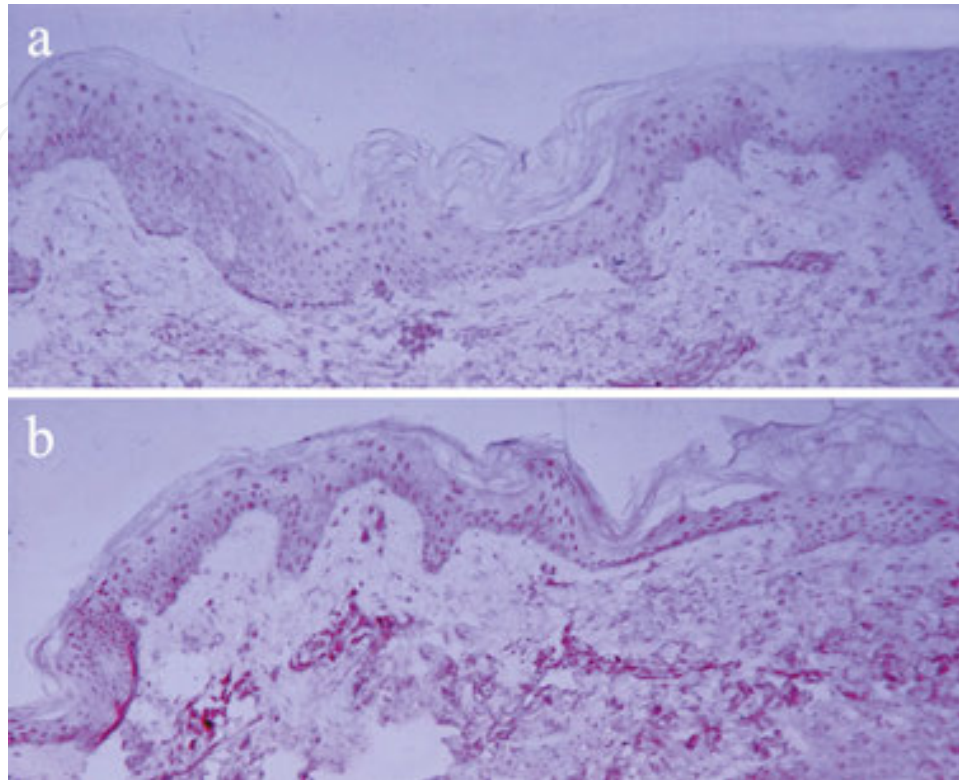
**Figure 8.** Histological manifestation in (a) untreated human buttock skin and (b) human buttock skin after four IPL irradiations (hematoxylin and eosin staining, magnification 10 $\times$ ).



**Figure 9.** Collagen I fibers in (a) untreated human buttock skin and (b) human buttock skin after four IPL irradiations (immunohistochemistry, magnification 10 $\times$ ).

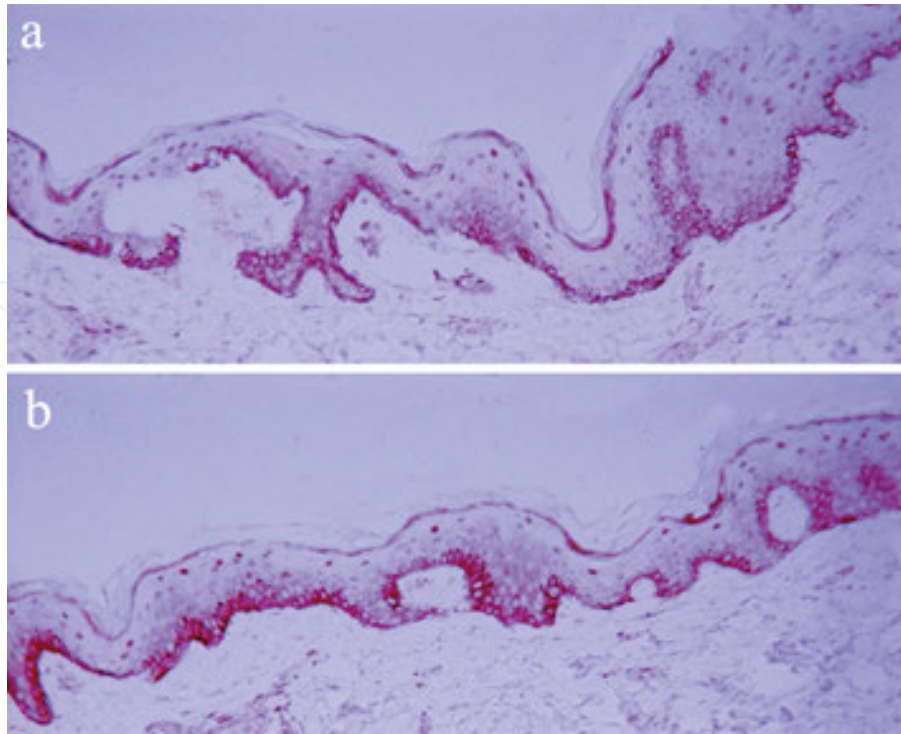
Matrix metalloproteinases (MMPs) play important roles in many physiological and pathological processes, such as skin ageing, wound healing, and even in tumor invasion. In the process of IPL photorejuvenation, MMPs are thought to be responsible for the turnover and degradation of extracellular matrix (ECM) [24, 25]. MMPs are composed of 23 family members, the main target molecules being connective tissue and basement membrane proteins (e.g., all types of collagens [both native and denatured ones, i.e., gelatins], laminins, integrins, elastin, proteoglycans, fibronectin, vitronectin, tenascins, etc.) Orringer has revealed marked increases in messenger RNA levels of MMP-1, MMP-3, MMP-9, and MMP-13 in carbon dioxide laser resurfaced photodamaged human skin. Wang detected increased MMP-1 and TIMP-1 protein levels in IPL-irradiated rat skin, which concord with Orringer's study. They proposed that the increased matrix metalloproteinase may play a constructive role in collagen synthesis in the IPL-activated wound healing process [26, 27]. On the contrary, Luo found increased procollagens but decreased matrix metalloproteinase mRNA levels in BALB/C mouse skin, suggesting IPL irradiation can not only enhance new collagen production, but also decrease collagen degradation through downregulation of MMP [28]. So far, few studies documented decreased matrix metalloproteinase mRNA levels in IPL-irradiated skin *in vivo*. Gu confirmed the elevation of MMP protein levels in IPL-treated human buttock skin. In addition, by comparing with the UVA-induced MMP expression patterns, they found that IPL induced a different MMP expression pattern (remarkable increase of MMP-1, MMP-3, and MMP-12 in UVA-exposed skin, while lower MMP-1, MMP-3, and MMP-12 but higher MMP-9 levels in IPL-irradiated

skin). They proposed MMP-1, MMP-3, and MMP-12 could play a destructive role, whereas MMP-9 may play a constructive one in ECM metabolism (**Figures 10a and b, 11a and b, and 12a and b**).

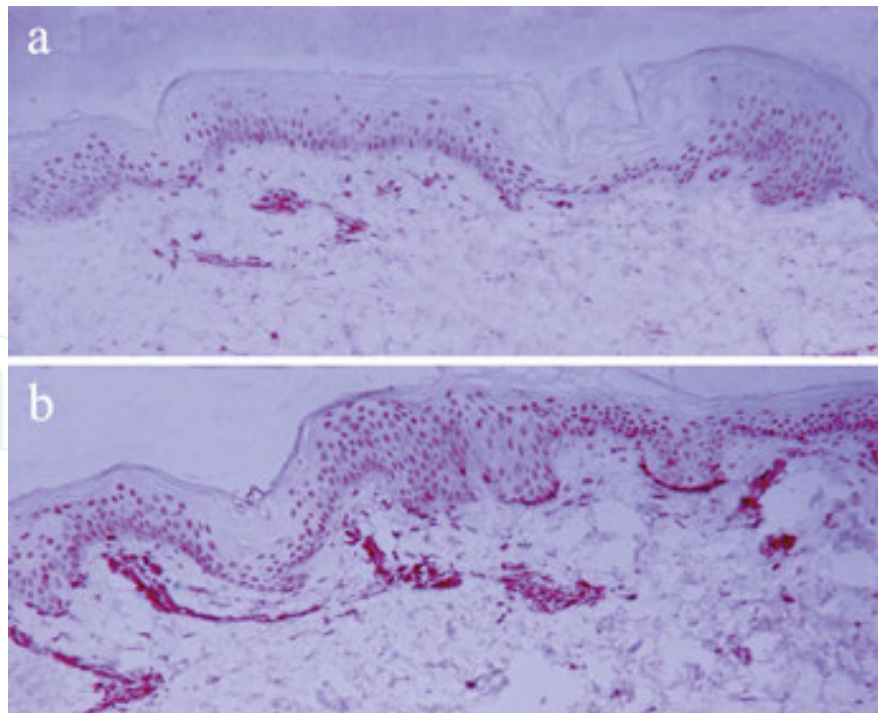


**Figure 10.** Protein expression of MMP-1 before (a) and after (b) IPL irradiation (immunohistochemistry, magnification 10 $\times$ ).

Transforming growth factor- $\beta$  (TGF- $\beta$ ) is a major regulator of the synthesis of ECM proteins in human skin as it stimulates fibroblast proliferation and collagen production. A study by Wang showed that TGF- $\beta$  may be involved in the IPL photorejuvenation process. *In situ* hybridization showed strong positive TGF- $\beta$ 1 mRNA expression levels in rat skin 7 days after IPL exposure, as compared with the negative TGF- $\beta$ 1 mRNA expression in the nonexposed skin. Thus, they suggest TGF- $\beta$ 1 plays an important role in photorejuvenation [29]. Ali's study confirmed that IPL elicits a statistically significant increase in epidermal TGF- $\beta$ 1 expression 48 h following the first treatment session, and this increase was maintained 1 week following the last treatment session. The induction of TGF- $\beta$ 1 was epidermal and limited to the upper differentiated layers of the epidermis [30]. However, another study by El-Domyati showed no significant differences ( $p < 0.05$ ) in TGF- $\beta$ 1 protein expression levels among the IPL-treated and the control groups (baseline [before treatment]; end of treatment [after 3 months]; posttreatment [6 months after the start of treatment]) [31], which did not concord with Ali's study. This may be due to the different time points to obtain skin biopsies (the former detected the TGF- $\beta$ 1 7 days after IPL irradiation, whereas the latter obtained the biopsies 3 and 6 months after IPL irradiation) and different IPL devices and parameters.



**Figure 11.** Protein expression of MMP-3 before (a) and after (b) IPL irradiation (immunohistochemistry, magnification 10 $\times$ ).

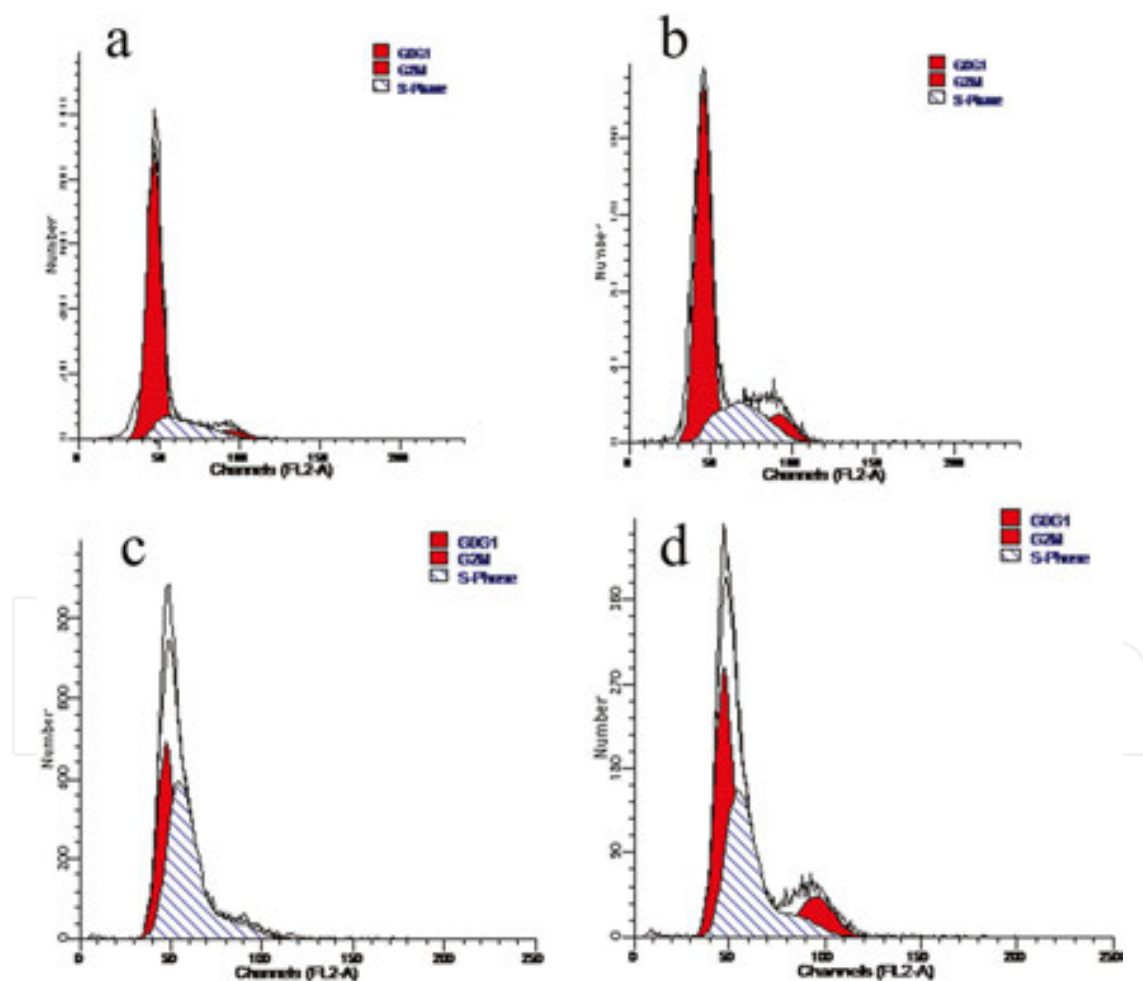


**Figure 12.** Protein expression of MMP-9 before (a) and after (b) IPL irradiation (immunohistochemistry, magnification 10 $\times$ ).

Some results indicated that IPL activates a wound healing process and leads to vascular formation, which may play roles in IPL photorejuvenation. Recently, a study with mouse island skin flap model revealed that IPL at lower dose could improve wound healing through the dilation of tissue vasculature and heat-shock protein production [32]. An investigation by Wu demonstrated that IPL irradiation significantly enhanced aquaporin 3 protein levels in rat skin, which is responsible for substratum corneum hydration, biosynthesis of the substratum corneum, and wound healing process [33].

### 2.3.2. *In vitro* effects of IPL on fibroblasts, cytokines, etc

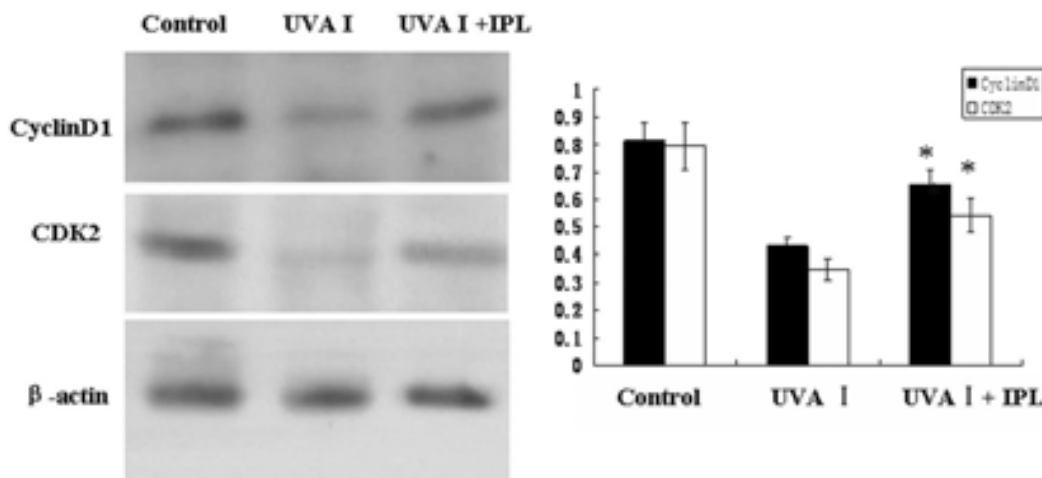
IPL treatment has been shown to be highly effective for skin rejuvenation but the biochemical and molecular mechanism are not well known. Fibroblasts secrete procollagen and then convert it to collagen, which is an important component of ECM. Effects of IPL on fibroblasts were focused by many *in vitro* studies.



**Figure 13.** Cell cycle in fibroblasts was assessed by flow cytometry after cells were stained with PI. (a) Control group, (b) UVA I irradiated group, (c) IPL irradiated group, and (d) IPL irradiation after PUVA exposure. Cells were stained by PI before flow cytometry. IPL irradiation, wavelength 570–960 nm, pulse duration 12 ms, energy intensity 15 J/cm<sup>2</sup>, irradiated once a day, for 2 days.

Liu investigated the effects of IPL and UVA on fibroblasts proliferation. In untreated control group, most cells were in cell cycle phase G1, while minor cells were in cell cycle phase S. UVA I irradiated group was designed to construct a cell injury model and compare the effects of IPL and UVA on human skin fibroblasts. Compared with the control, UVA induced no significant changes in proportion of cells in cycle phase S, as well as cell cycle phase G2. As compared with the UVA I irradiated group and the control group, the UVA+IPL group (fibroblasts irradiated with IPL after PUVA exposure) proliferate at a faster rate ( $p < 0.05$ ) [34] (**Figure 13a–d**).

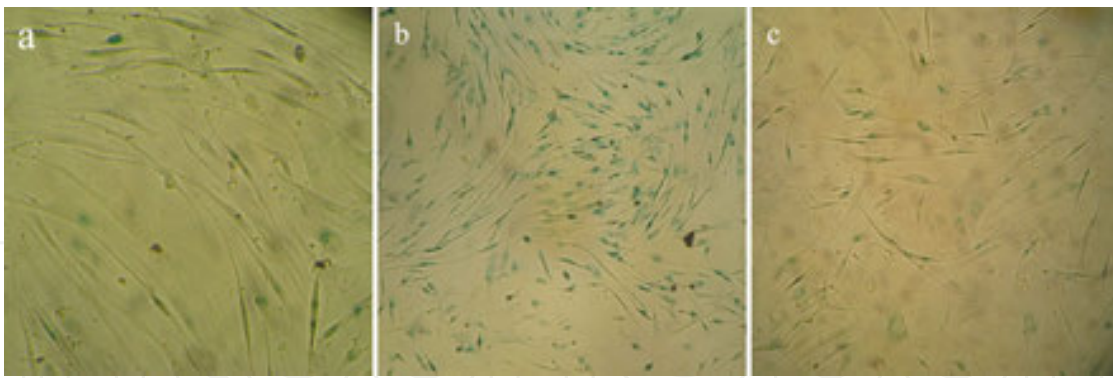
Cells were also stained by CCK-8 and assessed by flow cytometry to detect the proliferation ability. Note that 72 h after therapeutic dose of IPL irradiation, results showed an increase of cell proliferating index than the control ( $p < 0.01$ ). As compared with the UVA I irradiated group, the UVA+IPL group increased in cell proliferating index ( $p < 0.05$ ). Cell cycle protein cyclin D1 and CDK2 expression levels were also upregulated after IPL irradiation (**Figure 14**).



**Figure 14.** Cyclin D1 and CDK2 protein expression levels were detected by Western blot.

Cuerda-Galindo did a series of studies regarding the effects of IPL on fibroblasts. Their study showed that SA Filter 800–1200 nm using a  $60.1 \text{ J/cm}^2$  energy density double-pulse induces a significant skin fibroblast proliferation. Note that 48 h after IPL irradiation, 1BR3G human skin fibroblasts were observed to proliferate at a faster rate, showing a significant increase of cells in S and G2/M cell cycle phases (S cell cycle phase, 8.23 vs. 10; G2/M cell cycle phase, 8.63 vs. 17.5), which is consistent with the results of Liu [34].

Further studies show IPL could reverse or rejuvenate the cell senescence in fibroblasts. Wang evaluated the influence of IPL irradiation on 8-methoxypsoralen plus ultraviolet-A irradiation (PUVA)-induced senescence of fibroblasts. In their study, PUVA treatment increased the number of SA- $\beta$ -gal-positive fibroblasts, increased the level of ROS, and shortened the telomere length. However, irradiation with IPL after PUVA exposure decreased the number of SA- $\beta$ -gal-positive cells, decreased the ROS level, and prevented telomere shortening, in comparison with PUVA treatment only ( $p < 0.05$ ) (**Figure 15a–c**). They proposed that irradiation with IPL after PUVA exposure partially rejuvenated the cells, demonstrating a protective effect against PUVA-induced fibroblast senescence [36].



**Figure 15.** The staining of SA- $\beta$ -gal in (a) control (untreated) human fibroblasts, (b) PUVA-induced senescence of fibroblasts, and (c) fibroblasts irradiated with IPL after PUVA exposure (reprinted with the permission of Wang Ruiyan).

It is well known that collagen in the dermis is mainly composed of type I (80%) and III (10%) collagens, which are responsible for the elasticity and integrity of the skin. Fibroblasts secrete procollagens and then convert them into collagens, which decreased in photoaged skin. More and more studies have proved that IPL irradiation could promote the production of collagens in fibroblasts [21, 22]. Besides collagen, other molecular components are present and contribute to the overall mechanical properties of skin. Among the noncollagenous components of the dermis, there are proteoglycans (PG), glycosaminoglycan conjugated proteins (GAG), hyaluronic acid, and versican, which are important constituents of human skin connective tissue and essential for maintaining mechanical strength of the skin. A study by Cuerda-Galindo detected an increase in the amount of collagens, accompanied by an elevation in protein production of hyaluronic acid and versican, which can be a possible mechanism of action for IPL devices in aging skin treatment [35, 37].

When referred to the biochemical and molecular mechanism of IPL treatment, three aspects should be mentioned: fibroblasts proliferation, ECM production, and ECM degrading enzymes. MMPs are endopeptidases that perform a degradative function, generally targeting the extracellular matrix. MMP1 is called collagenase and its main substrate are collagen type III, I, II, VII, and X. Although it is well established that MMP expression was increased in damaged or photoaged skin [38, 39], Cuerda-Galindo observed MMP-1 increased following IPL irradiation, consistent with the previous findings induced by laser treatment [40, 41]. Based on the above theories, these authors speculate that increased MMP could be an overlooked mechanism of skin rejuvenation, in which it will be implicated, contributing to the degradation of senescent collagens and then the turnover of the ECM [35]. So, it is reasonable that upregulation of MMPs levels following IPL irradiation did not contradict with the photorejuvenation effects and upregulation of collagen levels.

According to the effects of IPL on MMPs levels, there was another tendency, the downregulation of MMPs levels following IPL irradiation. Wong demonstrated reduced protein levels of MMP-2, MMP-14, and TIMP-2 in primary human skin fibroblasts following IPL irradiation [28]. Other authors reported that the IPL management had no impact on MMP secretion levels in fibroblasts [42]. More than the stimulation of ECM proteins production observed by many studies, they postulate that photorejuvenation effect of IPL also involves the inhibition of



MMPs and therefore the decrease of ECM protein destruction [43]. Recent studies demonstrated that significant differences in the expression of MMP (down- and upregulation) may be related to the laser parameters such as wavelength and fluence [44, 45].

TGF- $\beta$  acts as a multifunctional cytokine in regulating cell growth and differentiation and the biosynthesis of ECM proteins. Previous studies confirmed that TGF- $\beta$  substantially increases elastin and type I collagen expression, via a Smads signaling pathway [46, 47]. Wong's study verified upregulated expression of collagen III and TGF- $\beta$  in dermal fibroblasts cultured within contracted collagen lattices, provided a potential mechanistic explanation for the mechanism of clinical photorejuvenation effects of IPL. This was verified by Byun, who observed slight increases in TGF- $\beta$ 1 mRNA and protein levels after IPL treatment.

Other cytokines involved in IPL treatment include interleukin 10 (IL-10), one of the regulatory cytokines that inhibit cytokine production in activated T lymphocytes and antigen-presenting cells. In Byun's study, IL-10 protein increased up to 5.95-fold in IPL-irradiated cultured keratinocytes (HaCaT cells), which may contribute to the anti-inflammatory effect and the therapeutic benefit of IPL for inflammatory dermatoses such as acne vulgaris [48].

To determine the principal mechanism that is involved in IPL hair removal treatment, the hair structures targeted by IPL were observed. Human scalp specimens were exposed *ex vivo* to IPL pulses and were then processed for histological analysis, immunofluorescence labeling of keratin 19, and endogenous alkaline phosphatase activity. Histological analysis confirmed that the melanin-rich matrix cells of the bulb in anagen follicles and the hair shaft are principally targeted by IPL treatment, while white hairs and epidermis remained unaffected. Damage caused by heat sometimes extended over the dermal papilla cells, while stem cells were mostly spared [49]. Collateral damage does not deplete stem cells. Damage at the dermal papilla was observed only with high-energy treatment modalities. These observations histologically verified the mechanism of IPL hair removal technology, explained why some hairs grow back after a single IPL treatment.

### 3. Summary

IPL systems are a successful and a noninvasive means of treatment, providing a viable alternative to laser systems and conventional therapeutic options when it comes to treating a series of indications, such as telangiectasias, skin photoaging, dyspigmentation, and unwanted hair. Compared with the wide clinical use, molecular mechanism involved in IPL therapy has not been thoroughly investigated. However, there are enough data to show that various biological effects have been shown to be exerted via IPL including fibroblasts proliferation, collagen production, and MMP secretion. It has also been shown that IPL protect PUVA induced senescence of fibroblasts. Advances have been made with respect to mechanism of IPL therapy, but a great deal is still unknown.

## Author details

Gu Weijie<sup>1</sup>, Liu Hongmei<sup>2</sup> and Liu Wei<sup>1\*</sup>

\*Address all correspondence to: [lwei5811@126.com](mailto:lwei5811@126.com)

<sup>1</sup> Department of Dermatology, The General Hospital of Air Force, Beijing, China

<sup>2</sup> Laser Center, Huangsi Aesthetic Surgery Hospital, Beijing, China

## References

- [1] Goldman MP, Weiss RA, Weiss MA. Intense pulsed light as a nonablative approach to photoaging. *Dermatol Surg.* 2005 Sep;31(9 Pt 2):1179–87; discussion 87.
- [2] Steiner R. Laser-Tissue Interactions [A]. In: Raulin C GB(ed). *Laser and IPL Technology in Dermatologic and Aesthetic Medicine*[M]. 1st ed. Springer, Heidelberg, Germany; 2011.1:23.
- [3] Goldman MP. Treatment of benign vascular lesions with the photoderm VL high-intensity pulsed light source. *Adv Dermatol.* 1997;13:503–21.
- [4] Sadick NS, Weiss R. Intense pulsed-light photorejuvenation. *Semin Cutan Med Surg.* 2002 Dec;21(4):280–7.
- [5] Bjerring P, Christiansen K, Troilius A. Intense pulsed light source for treatment of facial telangiectasias. *J Cosmet Laser Ther.* 2001 Dec;3(4):169–73.
- [6] Clementoni MT, Gilardino P, Muti GF, Signorini M, Pistorale A, Morselli PG, et al. Intense pulsed light treatment of 1,000 consecutive patients with facial vascular marks. *Aesthetic Plast Surg.* 2006 Mar–Apr;30(2):226–32.
- [7] Tanzi EL, Lupton JR, Alster TS. Lasers in dermatology: four decades of progress. *J Am Acad Dermatol.* 2003 Jul;49(1):1–31; quiz-4.
- [8] Kilmer SL, Garden JM. Laser treatment of pigmented lesions and tattoos. *Semin Cutan Med Surg.* 2000 Dec;19(4):232–44.
- [9] Kawada A, Shiraishi H, Asai M, Kameyama H, Sangen Y, Aragane Y, et al. Clinical improvement of solar lentigines and ephelides with an intense pulsed light source. *Dermatol Surg.* 2002 Jun;28(6):504–8.
- [10] Sasaya H, Kawada A, Wada T, Hirao A, Oiso N. Clinical effectiveness of intense pulsed light therapy for solar lentigines of the hands. *Dermatol Ther.* 2012 Nov–Dec;24(6):584–6.

- [11] Moreno Arias GA, Ferrando J. Intense pulsed light for melanocytic lesions. *Dermatol Surg.* 2001 Apr;27(4):397–400.
- [12] Li YH, Chen JZ, Wei HC, Wu Y, Liu M, Xu YY, et al. Efficacy and safety of intense pulsed light in treatment of melasma in Chinese patients. *Dermatol Surg.* 2008 May;34(5):693–700; discussion 1.
- [13] Bae MI, Park JM, Jeong KH, Lee MH, Shin MK. Effectiveness of low-fluence and short-pulse intense pulsed light in the treatment of melasma: a randomized study. *J Cosmet Laser Ther.* 2015;17(6):292–5.
- [14] Yun WJ, Lee SM, Han JS, Lee SH, Chang SY, Haw S, et al. A prospective, split-face, randomized study of the efficacy and safety of a novel fractionated intense pulsed light treatment for melasma in Asians. *J Cosmet Laser Ther.* 2015;17(5):259–66.
- [15] Dierickx CC. Hair removal by lasers and intense pulsed light sources. *Dermatol Clin.* 2002 Jan;20(1):135–46.
- [16] Feng Y, Zhao J, Gold MH. Skin rejuvenation in Asian skin: the analysis of clinical effects and basic mechanisms of intense pulsed light. *J Drugs Dermatol.* 2008 Mar;7(3):273–9.
- [17] Weiss RA, Goldman MP, Weiss MA. Treatment of poikiloderma of Civatte with an intense pulsed light source. *Dermatol Surg.* 2000 Sep;26(9):823–7; discussion 8.
- [18] Kawana S, Tachihara R, Kato T, Omi T. Effect of smooth pulsed light at 400 to 700 and 870 to 1,200 nm for acne vulgaris in Asian skin. *Dermatol Surg.* 2009;36(1):52–7.
- [19] Choi YS, Suh HS, Yoon MY, Min SU, Lee DH, Suh DH. Intense pulsed light vs. pulsed-dye laser in the treatment of facial acne: a randomized split-face trial. *J Eur Acad Dermatol Venereol.* 2009 Jul;24(7):773–80.
- [20] Takeshita K, Shibato J, Sameshima T, Fukunaga S, Isobe S, Arihara K, et al. Damage of yeast cells induced by pulsed light irradiation. *Int J Food Microbiol.* 2003 Aug;85(1–2):151–8.
- [21] Goldberg DJ. New collagen formation after dermal remodeling with an intense pulsed light source. *J Cutan Laser Ther.* 2000 Jun;2(2):59–61.
- [22] Iyer S, Carranza D, Kolodney M, Macgregor D, Chipps L, Soriano T. Evaluation of procollagen I deposition after intense pulsed light treatments at varying parameters in a porcine model. *J Cosmet Laser Ther.* 2007 Jun;9(2):75–8.
- [23] Hernandez-Perez E, Ibiatt EV. Gross and microscopic findings in patients submitted to nonablative full-face resurfacing using intense pulsed light: a preliminary study. *Dermatol Surg.* 2002 Aug;28(8):651–5.
- [24] Bruckner-Tuderman L. Biology of the extracellular matrix. In: Bologna JL, Jorizzo JL, Rapini, RP, editors. *Dermatology*. 2nd ed. London: Elsevier; 2007. pp. 1447–54.

- [25] Sardy M. Role of matrix metalloproteinases in skin ageing. *Connect Tissue Res.* 2009;50(2):132–8.
- [26] Wang ML, Liu DL, Yuan Q, Du, B.J. Study of effect of intense pulsed light on TIMP-1 expression in rat skin. *Chin J Aesth Med.* 2006;15:122–5.
- [27] Wang ML, Liu DL, Yuan Q. Effect of intense pulsed light on MMP-1 expression in rat skin. *Chin J Aesth Plast Surg.* 2006;17:392–4.
- [28] Luo D, Cao Y, Wu D, Xu Y, Chen B, Xue Z. Impact of intense pulse light irradiation on BALB/c mouse skin-in vivo study on collagens, matrix metalloproteinases and vascular endothelial growth factor. *Lasers Med Sci.* 2009 Jan;24(1):101–8.
- [29] Wang ML, Liu DL, Yuan Q, Du BJ. Effect of intense pulsed light on transforming growth factor- $\beta$ 1 mRNA expression in rat skin. *J South Med Univ.* 2009;29(1):92–6.
- [30] Ali MM, Porter RM, Gonzalez ML. Intense pulsed light enhances transforming growth factor beta1/Smad3 signaling in acne-prone skin. *J Cosmet Dermatol.* 2013 Sep;12(3):195–203.
- [31] El-Domyati M, El-Ammawi TS, Medhat W, Moawad O, Mahoney MG, Uitto J. Expression of transforming growth factor-beta after different non-invasive facial rejuvenation modalities. *Int J Dermatol.* 2015 Apr;54(4):396–404.
- [32] Cao MT, Xuan HD, Thi NP. Effects of intense pulsed light on tissue vascularity and wound healing: a study with mouse island skin flap model. *Plast Surg Int.* 2015;2015:429367.
- [33] Wu CJ, Chen CC, Shih HS, Chang LR, Liu CH, Liu YT, et al. Effect of intense pulsed light on the expression of aquaporin 3 in rat skin. *Lasers Med Sci.* 2015 Sep;30(7):1959–65.
- [34] Liu HM, Liu W, Zhao XZ, Tian Y, Yuan XY, Wang RY. Protective effect of intense pulsed light on fibroblast injury induced by UVA I. *Chinese J Med Aest Cosmetol.* 2011;17(2):117–20.
- [35] Cuerda-Galindo E, Diaz-Gil G, Palomar-Gallego MA, Linares-GarciaValdecasas R. Increased fibroblast proliferation and activity after applying intense pulsed light 800–1200 nm. *Ann Anat.* 2015 Mar;198:66–72.
- [36] Wang R, Liu W, Gu W, Zhang P. Intense pulsed light protects fibroblasts against the senescence induced by 8-methoxypsoralen plus ultraviolet-A irradiation. *Photomed Laser Surg.* 2011 Oct;29(10):685–90.
- [37] Cuerda-Galindo E, Diaz-Gil G, Palomar-Gallego MA, Linares-GarciaValdecasas R. Intense pulsed light induces synthesis of dermal extracellular proteins in vitro. *Lasers Med Sci.* 2015 Sep;30(7):1931–9.

- [38] Jansen PL, Rosch R, Jansen M, Binnebosel M, Junge K, Alfonso-Jaume A, et al. Regulation of MMP-2 gene transcription in dermal wounds. *J Invest Dermatol.* 2007 Jul; 127(7):1762–7.
- [39] Ohnishi Y, Tajima S, Akiyama M, Ishibashi A, Kobayashi R, Horii I. Expression of elastin-related proteins and matrix metalloproteinases in actinic elastosis of sun-damaged skin. *Arch Dermatol Res.* 2000 Jan;292(1):27–31.
- [40] Kuo YR, Wu WS, Jeng SF, Wang FS, Huang HC, Lin CZ, et al. Suppressed TGF-beta1 expression is correlated with up-regulation of matrix metalloproteinase-13 in keloid regression after flashlamp pulsed-dye laser treatment. *Lasers Surg Med.* 2005 Jan;36(1): 38–42.
- [41] Orringer JS, Kang S, Johnson TM, Karimipour DJ, Hamilton T, Hammerberg C, et al. Connective tissue remodeling induced by carbon dioxide laser resurfacing of photo-damaged human skin. *Arch Dermatol.* 2004 Nov;140(11):1326–32.
- [42] Wu D, Zhou B, Xu Y, Yin Z, Luo D. Impact of intense pulsed light irradiation on cultured primary fibroblasts and a vascular endothelial cell line. *Exp Ther Med.* 2009 Oct;4(4): 669–74.
- [43] Wong WR, Shyu WL, Tsai JW, Hsu KH, Lee HY, Pang JH. Intense pulsed light modulates the expressions of MMP-2, MMP-14 and TIMP-2 in skin dermal fibroblasts cultured within contracted collagen lattices. *J Dermatol Sci.* 2008 Jul;51(1):70–3.
- [44] Dang Y, Ye X, Weng Y, Tong Z, Ren Q. Effects of the 532-nm and 1,064-nm Q-switched Nd:YAG lasers on collagen turnover of cultured human skin fibroblasts: a comparative study. *Lasers Med Sci.* 2010 Sep;25(5):719–26.
- [45] Huang J, Luo X, Lu J, Chen J, Zuo C, Xiang Y, et al. IPL irradiation rejuvenates skin collagen via the bidirectional regulation of MMP-1 and TGF-beta1 mediated by MAPKs in fibroblasts. *Lasers Med Sci.* 2011 May;26(3):381–7.
- [46] Kucich U, Rosenbloom JC, Abrams WR, Rosenbloom J. Transforming growth factor-beta stabilizes elastin mRNA by a pathway requiring active Smads, protein kinase C-delta, and p38. *Am J Respir Cell Mol Biol.* 2002 Feb;26(2):183–8.
- [47] Ghosh AK, Yuan W, Mori Y, Varga J. Smad-dependent stimulation of type I collagen gene expression in human skin fibroblasts by TGF-beta involves functional cooperation with p300/CBP transcriptional coactivators. *Oncogene.* 2000 Jul;19(31):3546–55.
- [48] Byun JY, Choi HY, Myung KB, Choi YW. Expression of IL-10, TGF-beta(1) and TNF-alpha in cultured keratinocytes (HaCaT Cells) after IPL treatment or ALA-IPL photodynamic treatment. *Ann Dermatol.* 2009 Feb;21(1):12–7.
- [49] Larouche D, Kim DH, Ratte G, Beaumont C, Germain L. Effect of intense pulsed light treatment on human skin in vitro: analysis of immediate effects on dermal papillae and hair follicle stem cells. *Br J Dermatol.* 2013 Oct;169(4):859–68.