

# We are IntechOpen, the world's leading publisher of Open Access books Built by scientists, for scientists

4,800

Open access books available

122,000

International authors and editors

135M

Downloads

Our authors are among the

154

Countries delivered to

TOP 1%

most cited scientists

12.2%

Contributors from top 500 universities



WEB OF SCIENCE™

Selection of our books indexed in the Book Citation Index  
in Web of Science™ Core Collection (BKCI)

Interested in publishing with us?  
Contact [book.department@intechopen.com](mailto:book.department@intechopen.com)

Numbers displayed above are based on latest data collected.  
For more information visit [www.intechopen.com](http://www.intechopen.com)



---

# Surgical Strategy of Cleft Palate Repair and Nasometric Results

---

Norifumi Nakamura and Masahiro Tezuka

Additional information is available at the end of the chapter

<http://dx.doi.org/10.5772/67093>

---

## Abstract

The goal of cleft palate (CP) repair is to achieve normal speech. Despite the recent development of surgical repair of cleft palate, there is no standard procedure that ensures patients' speech to the same level as that in noncleft children. In this chapter, we describe our surgical strategy of cleft palate repair that approaches each anatomical and pathological abnormality of cleft palate and the postoperative speech outcomes using the subjective and objective manners. After palate repair based on our surgical strategy, patients' speech was significantly improved, and the nasalance scores were recovered to almost the same levels as those of Japanese children without cleft palate.

**Keywords:** cleft palate, palatal repair, nasometry, speech

---

## 1. Introduction

The surgical goals of primary repair for cleft palate (CP) include closure of the defect of the hard and soft palate and achievement of normal speech based on favorable velopharyngeal (VP) closure. Patients and family members always desire their speech in the same level as that of healthy children. However, it is said that approximately 40% of patients have a persistent, often lifelong, speech impairment in connected to CP [1]. Despite the recent development of surgical repair of cleft palate, there has been no standard procedure that can ensure complete VP closure (VPC) in patients with CP to date.

The Department of Oral and Maxillofacial Surgery, Kagoshima University Hospital, worked on cleft lip and palate repair for 30 years. We assessed their speech from 2000 to 2005 and revealed that more than 30% of patients had a moderate or poor VPC, and only 40% had achieved normal articulation. Therefore, to improve our speech results, the following countermeasures were carried out: First, we tried to standardize the surgical procedures for pala-

---

tal repair. Second, postoperative speech results were assessed objectively by speech language therapists (SLT). Third, these objective data were shared with all surgeons to provide feedback for the next operation.

In this chapter, we described our surgical strategy of cleft palate repair that approaches each anatomical and pathological abnormality of cleft palate and evaluated postoperative speech outcomes including presence/severity of hypernasality, nasal emission, and nasalance scores after standardized palatal repair. We then compared speech outcomes to ones using our previous palatal repair protocol without following surgical strategy. Furthermore, we also compared them to the nasalance scores of Japanese noncleft children.

## 2. Surgical strategy of palate repair approaching each anatomical and pathological abnormality

The concept of our strategy for CP repair was to approach each anatomical and pathological abnormality that may cause postoperative velopharyngeal incompetence (VPI): short palate, asymmetric palate, insufficient velar elevation, and a midline defect of the velum, to establish CP repair that can ensure VP closure (**Table 1**) [2]. The above factors were identified based on our experiences during the treatment of persistent VPI after CP repair. Therefore, our CP repair consisted of (1) presurgical orthopedics using Hotz's plate as much as possible to minimize the cleft space, (2) modified V-Y palatoplasty, allowing conservation of the periosteum in the anterior part of the maxilla, minimizing maxillary growth disturbance, (3) lengthening of the nasal mucosa using a large Z-plasty and a free mucosal graft, (4) muscular reconstruction producing a symmetrical levator sling and pharyngeal arch, and (5) two-layered suture of the palatal muscles.

Possible causes of VPI	Anatomical pathological abnormalities	Surgical procedures in palatal repair
Short palate	<ul style="list-style-type: none"> <li>• Wide cleft palate.</li> <li>• Growth deficiency of the soft palate.</li> <li>• Insufficient retropositioning of the palatal muscles.</li> </ul>	<ul style="list-style-type: none"> <li>• Presurgical orthopedics for narrowing the cleft space using Hotz's plate, as much as possible.</li> <li>• Sufficient retropositioning of the palatal muscle.</li> </ul>
Asymmetric velopharynx	<ul style="list-style-type: none"> <li>• Antero-posterior discrepancy between the maxillary segments.</li> <li>• Discrepancy of the velar length between the segments.</li> <li>• Malpositioning of the palatal muscles.</li> </ul>	<ul style="list-style-type: none"> <li>• Presurgical orthopedics improving the positional gap using Hotz's plate, as much as possible.</li> <li>• Extension of the nasal mucosa by large Z-plasty with a free mucosal graft.</li> <li>• Symmetrical reconstruction of the palatal muscle referencing the anatomical landmarks.</li> </ul>

Possible causes of VPI	Anatomical pathological abnormalities	Surgical procedures in palatal repair
Insufficient velar elevation	<ul style="list-style-type: none"> <li>• Insufficient releasing of the palatal muscles from the palatal bone.</li> <li>• Muscular pooling in the soft palate.</li> <li>• Wide scar in the soft palate.</li> </ul>	<ul style="list-style-type: none"> <li>• Freeing the palatal muscle in a single layer on the tensor aponeurosis.</li> <li>• Sufficient repositioning of the palatal muscle.</li> <li>• Sufficient extension of the oral and nasal mucosa.</li> </ul>
Midline defect of the velum	<ul style="list-style-type: none"> <li>• Unsatisfactory repair or defect of musculus uvulae.</li> </ul>	<ul style="list-style-type: none"> <li>• Two-layer suture of the palatal muscles in the midline of the velum.</li> </ul>

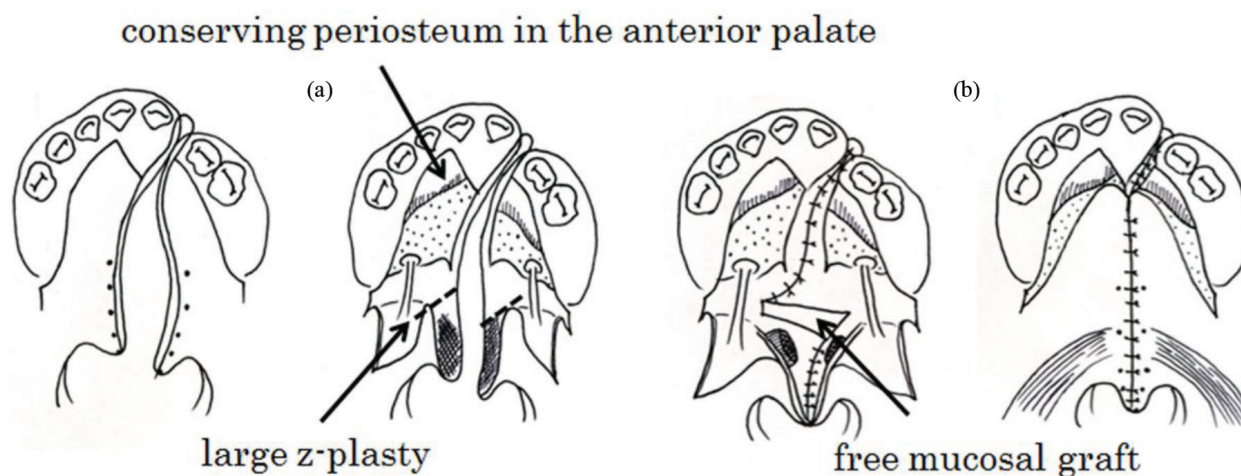
**Table 1.** Our surgical strategy for palatal repair approaching each anatomical and pathological abnormality and possible causes of VPI [2].

### 3. Surgical procedures for cleft palate repair

We adopt a modified V-Y palatoplasty for cleft palatal repair, although a large number of surgeons have developed surgical procedures for palatal repair [3–10]. The reason why we adopt a modified V-Y palatoplasty for cleft palatal repair is due to the following previous reports. Brothers et al. observed that the success rates for VP closure after Furlow palatoplasty and the modified Wardill-Kilner procedure were 64.0 and 70.0%, respectively, using pressure-flow testing, and they concluded that there was no difference between the two procedures [11]. Van Lierde et al. also compared Furlow palatoplasty and the Wardill-Kilner procedure using the nasometry and observed significantly better results in those treated with the Wardill-Kilner procedure [12].

The surgical procedures of a modified V-Y palatoplasty are shown in **Figure 1**. On designing the incision line, anatomical landmarks at the velopharynx were marked carefully (**Figure 1a**). The palatal flaps were elevated while preserving the periosteum in the anterior and lateral parts of the hard palate, and the palatal muscles were bluntly dissected along the surface of the tensor aponeurosis and nasal mucosa in a single layer. For extension of the nasal mucosa of the soft palate, large Z-plasty was performed in the nasal surface of the soft palate (**Figure 1b**). Mucosal incision for the large Z-plasty was extended until the surgeon could confirm contact between the soft palate and posterior pharyngeal wall without any tension. When the velar length became shorter on complete closure of the Z-plasty, the mucosal defect that remained on the nasal side was filled using a free mucosal graft donated from the buccal area (**Figure 1c**). Palatal muscles were then sutured in the midline of the soft palate by the two-layered suture (**Figure 1d**).

Palatal muscle was sutured carefully on producing a symmetrical levator sling and also the symmetrical palatopharyngeal and palatoglossal arches and uvula, while referencing five anatomical landmarks, as described above.



**Figure 1.** Surgical steps in palate repair for UCLP.

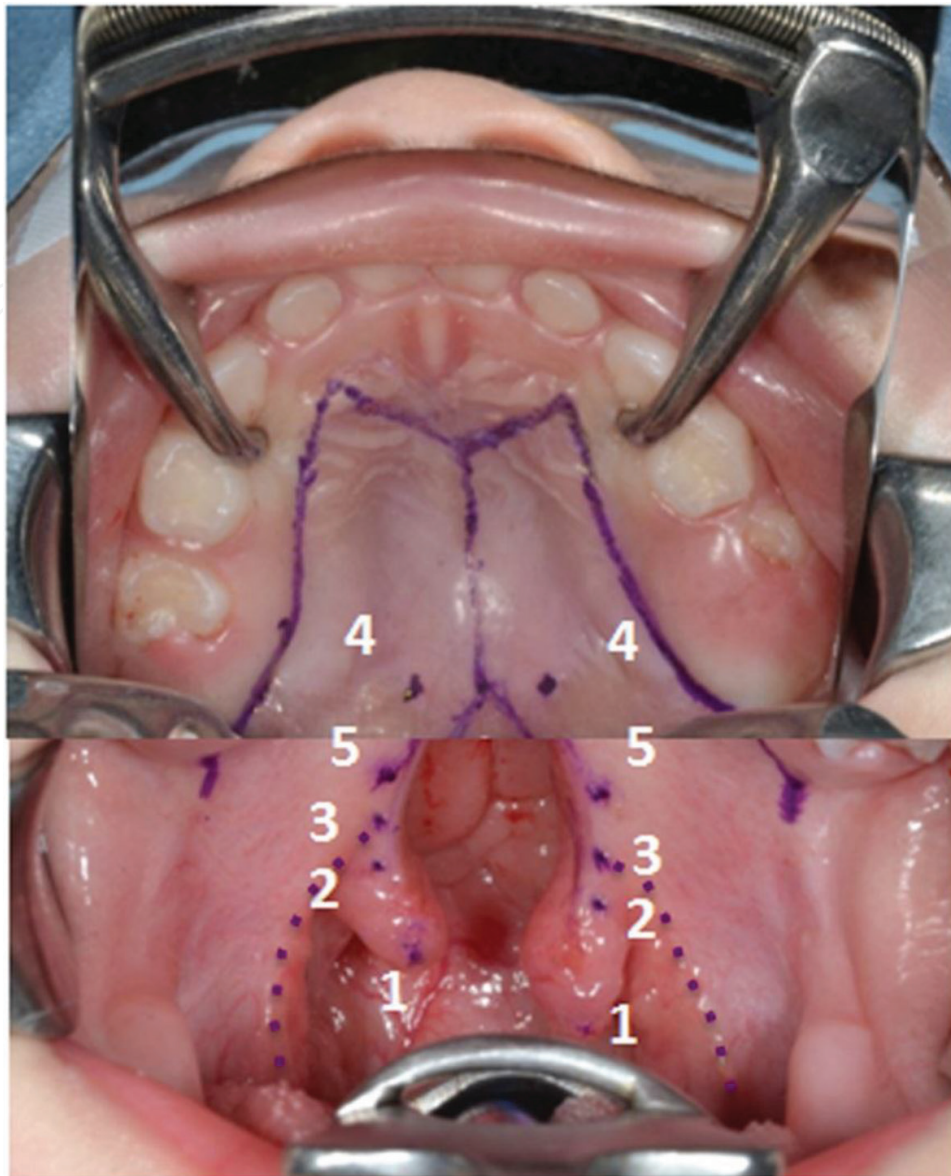
On designing the incision line, anatomical landmarks at the velopharynx were marked using 0.05% Toluidine blue solution (**Figure 2**). The marked points included the tip and base of the uvula (nos. 1 and 2), point in which the extension line of the palatoglossal arch crossed the cleft edge (no. 3), posterior edge of the hard palate (no. 4), and midpoint between nos. 3 and 4 (no. 5).

The palatal flaps were elevated while preserving the periosteum in the anterior and lateral parts of the hard palate, and the palatal muscles including the levator veli palatini muscle, palatopharyngeal muscle, and musculus uvulae, although these muscles were not clearly identified, were bluntly dissected along the surface of the tensor aponeurosis and nasal mucosa in a single layer. Muscles were sufficiently repositioned as the direction was turned sideways. The hamular process was not fractured.

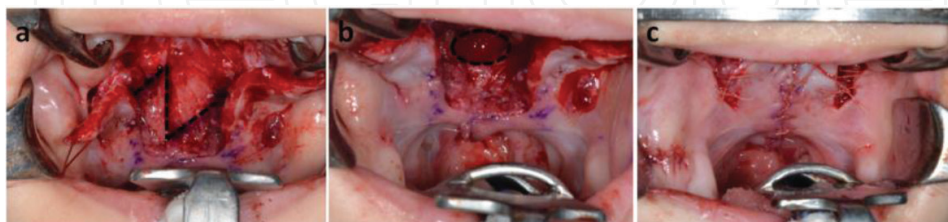
For extension of the nasal mucosa of the soft palate, a large Z-plasty was made in the nasal mucosa of the soft palate (**Figure 3a**). Mucosal incision for the large Z-plasty was extended until the soft palate contact to the posterior pharyngeal wall without any tension. The mucosal defect produced by a large Z-plasty was closed. However, when the velar length became shorter on complete closure of the Z-plasty, the mucosal defect that remained on the nasal side was filled using a free mucosal graft donated from the buccal area (**Figure 3b**). Because the shortened velar length due to complete closure of a Z-plasty might cause an asymmetric VP form and asymmetric closure motion.

Palatal muscles were then sutured in the midline of the soft palate by the two-layered suture (nasal and oral sides) using a nonabsorbable thread (5-0 Nylon; **Figure 3c**). Palatal muscle was sutured carefully on producing a symmetrical levator sling and also the symmetrical palatopharyngeal and palatoglossal arches and uvula, while referencing five anatomical landmarks, as described above. The raw area of the hard palate was dressed using a collagen-based artificial dermis and covered using an acrylic plate for 1 week.





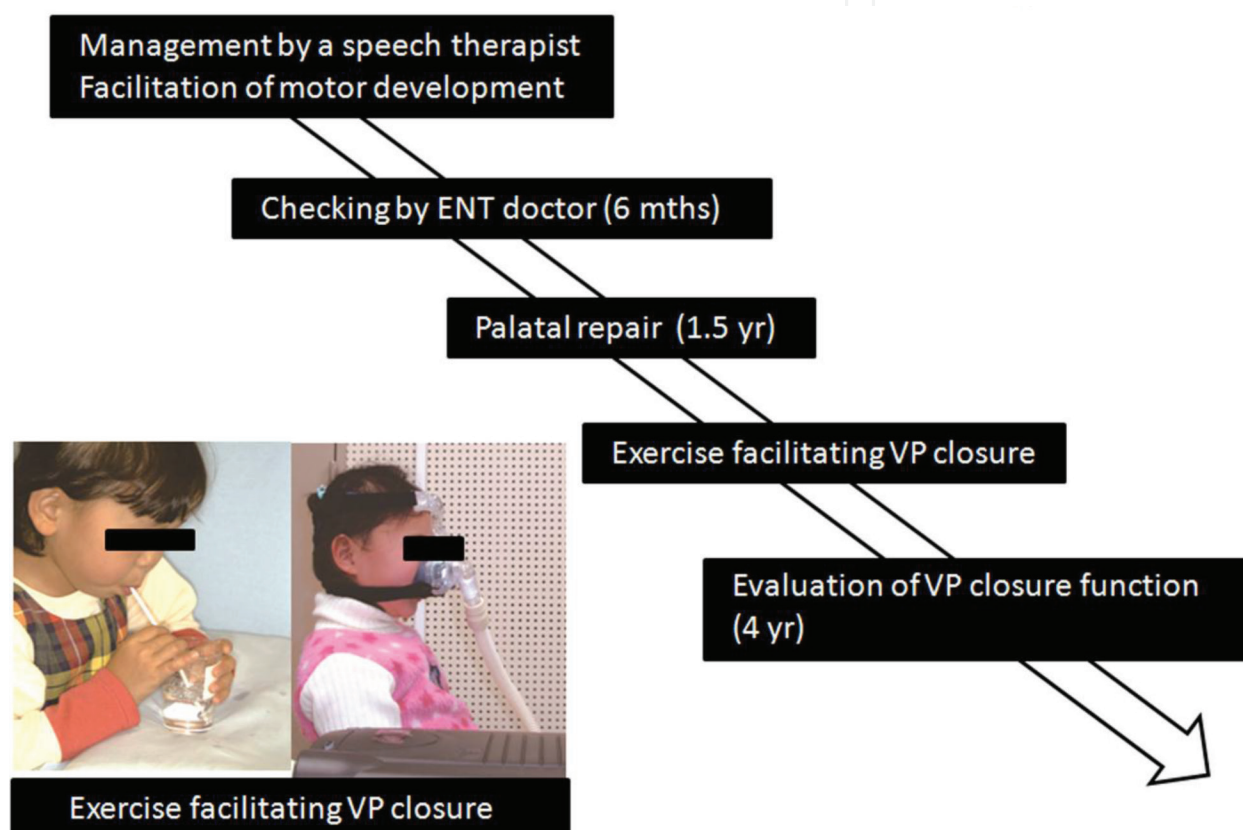
**Figure 2.** Surgical steps in palatal repair. The figure demonstrates anatomical landmarks and the incision line.



**Figure 3.** Surgical steps in palatal repair. The figure demonstrates elevation of the palatal flaps conserving the periosteum in the anterior and lateral parts of the hard palate and a large Z-plasty on the nasal side (dotted line) (a), a free mucosal graft on the nasal side (b), and symmetrical muscular reconstruction producing a levator sling while referring to the anatomical landmarks (c).

#### 4. Speech assessment

**Figure 4** shows our treatment schedule for speech in cleft palate patients. Speech management by a speech therapist starts just after birth, and the patient's motor development is facilitated. A check by an ENT doctor for the presence of otitis media is performed every 6 months. Palatal repair is then performed at 1.5 years. And after palatal repair, exercise facilitating VP closure is performed by a speech therapist. When the patient reaches the age of 4 years, VP closure (VPC) function is evaluated more precisely. If VPI remains, speech therapist starts training facilitating VPC. Our goal is to achieve a normal speech before entering elementary school.



**Figure 4.** Treatment schedule for speech in cleft palate patients in Kagoshima University Hospital.

Postoperatively, patients were followed by 2 SLTs every 3 months until around 4 years. In this study, perceptual rating of hypernasality and nasal emission was carried out for all participants using the preserved sound sources by SLTs. In perceptual rating, hypernasality and nasal emission were classified into four categories: none, slight/mild, moderate, and severe. Articulation was also evaluated using the articulation test of the Japan Society of Logopedics and Phoniatics and then converted to IPA 2005 phonetic symbols so that all abnormalities could be diagnosed and transcribed in IPA.

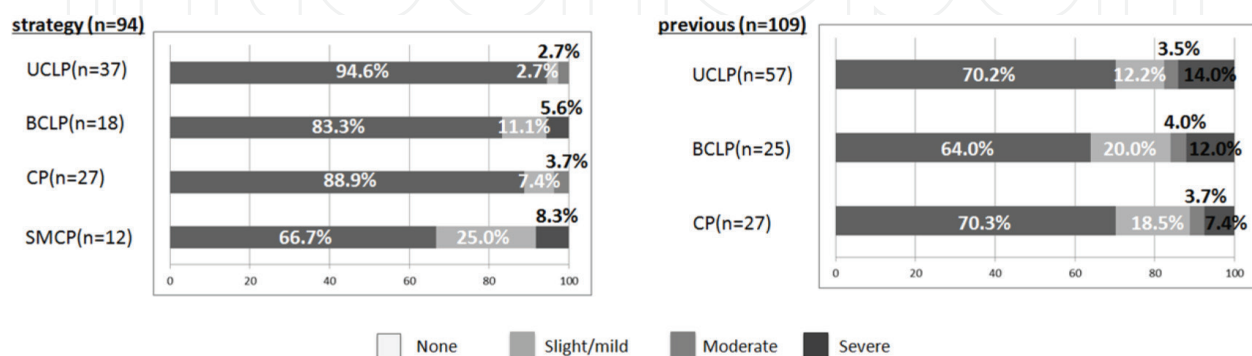
Nasometry scores were obtained for all patients using the Kay 6200 Nasometer II (Kay Elemetics, Lincoln Park, NJ, USA). For speech stimuli, the low-pressure vowel /i:/ and

low-pressure sentence /yooi wa ooi/ and the high-pressure consonant-vowel syllable /tsu/ and high-pressure sentence /kitsutsuki ga kiwotsutsuku/ were used [13]. The reason, why we selected /i:/ extending the verbalization of /i/ among the all low-pressured vowels, was based on our previous study on the relationship between nasalance score and the perceptual rating of resonance in Japanese cleft and noncleft subjects [14]. In the previous study, we found that nasalance score during phonation of /i:/ was correlated with perceptual rating of resonance and cleft and noncleft subjects with normal resonance demonstrated the mean nasalance score less than 20% during phonation of /i:/.

## 5. Postoperative speech results comparing to the previously operated patients and noncleft controls

Postoperative speech results of 94 patients who underwent palate repair based on our surgical strategy during 2006–2012 (strategy group) and those of 109 patients who previously underwent palate repair without following strategy during 2000–2005 (previous group) were compared. As control group, speech data on 37 Japanese noncleft controls were used. For speech assessment, perceptual rating of hypernasality and nasal emission was classified into four categories: none, slight/mild, moderate, and severe, by one experienced speech language therapist for all participants. Articulation was also evaluated using the articulation test. For objective assessment, Nasometer test was performed for all patients. This study was approved by the Clinical Research Ethical Review Boards of Kagoshima University Hospital.

Comparison of the rate of achieving normal resonance in each cleft type is shown in **Figure 5**. Normal resonance was achieved in 35/37 (94.6%) in Unilateral cleft lip and palate (UCLP), 15/18 (83.3%) in Bilateral cleft lip and palate (BCLP), 24/27 (88.9%) in CP, and 8/12 (66.7%) in Submucous cleft palate (SMCP) in the strategy group. Severe hypernasality was observed in each one patient with BCLP and SMCP. On the other hand, normal resonance was achieved in 40/57 (70.2%) in UCLP, 16/25 (64.0%) in BCLP, and 19/27 (70.3%) in CP in the previous group. Successful achievement of normal resonance was obtained more reliably in all types of CP following palate repair based on our surgical strategy.



**Figure 5.** Postoperative hypernasality of each cleft type in the strategy and previous group.

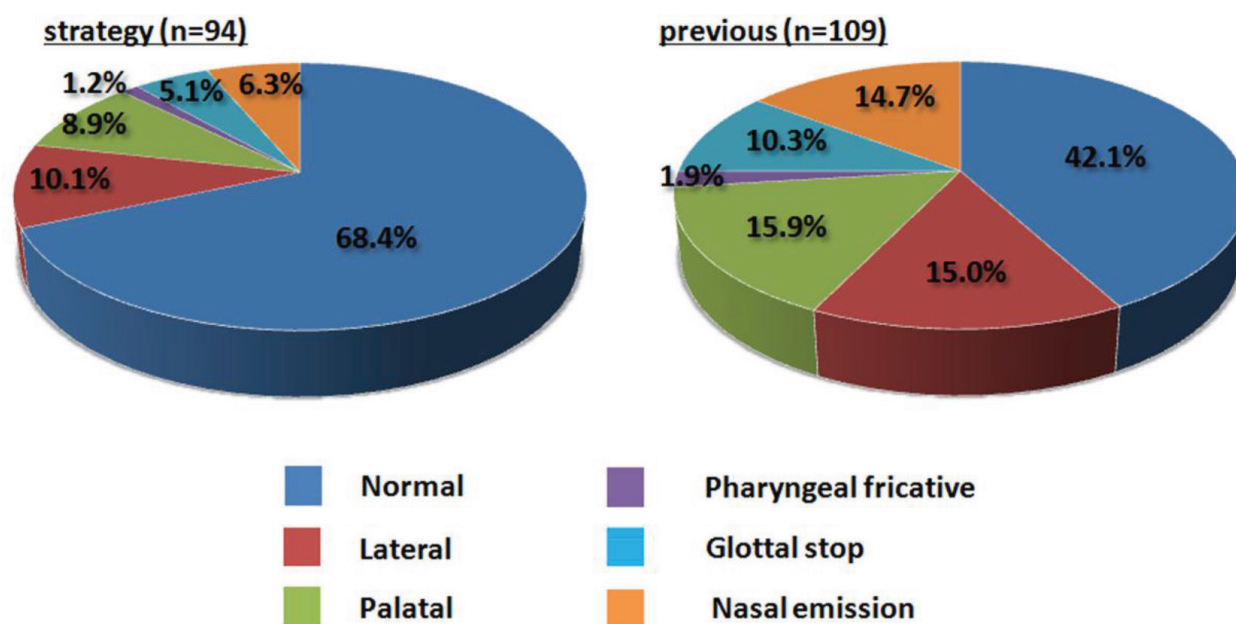


The mean and SD of the nasalance scores of the strategy and previous groups and controls are shown in **Table 2**. The mean nasalance scores in the strategy group were less than 20% and were significantly lower than those of the previous group. When comparing the nasalance scores of control groups, those in the previous group were significantly higher on phonating /i:/ and the low-pressure sentence than in controls. On the other hand, there was no significant difference between the strategy and control groups. In other words, the nasalance scores representing hypernasality in the subjects of the strategy group recovered to almost the same levels as those of Japanese children without cleft palate.

Regarding articulation at 4 years of age, normal articulation was obtained in 68.4% in the strategy group, and this was better than that of the previous group (**Figure 6**).

	Nasalance score (%)				
	Strategy ( <i>n</i> = 94)		Previous ( <i>n</i> = 109)		Controls ( <i>n</i> = 37)
/i/	20.3 ± 13.5	<0.01	33.6 ± 23.9	<0.01	22.7 ± 14.4
/tsu/	16.8 ± 13.5	<0.05	22.6 ± 19.3	<0.05	15.2 ± 8.5
/youihaooi/	19.7 ± 13.6	NS	24.2 ± 17.0	<0.01	13.0 ± 9.7
/kitsutsuki ga kiwo tsutsuku/	19.2 ± 12.7	NS	23.6 ± 18.3	NS	17.5 ± 9.8

**Table 2.** Mean ± SD of the nasalance score in the strategy, previous, and control groups.

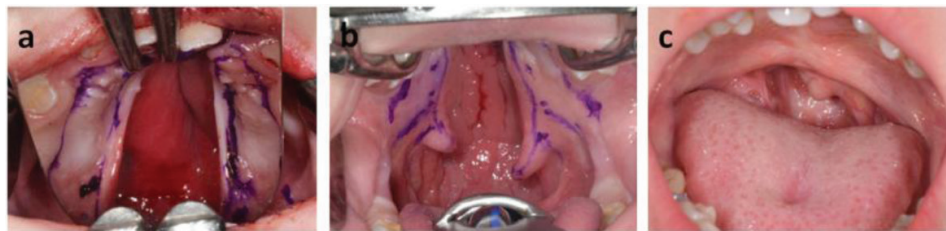

**Figure 6.** Postoperative articulation in the strategy and previous groups.

## 6. Discussion

When considering the postoperative VPI following CP repair, there are several main causes, including a wide cleft, short palate, deep pharynx, and unsatisfactory muscle reconstruction,

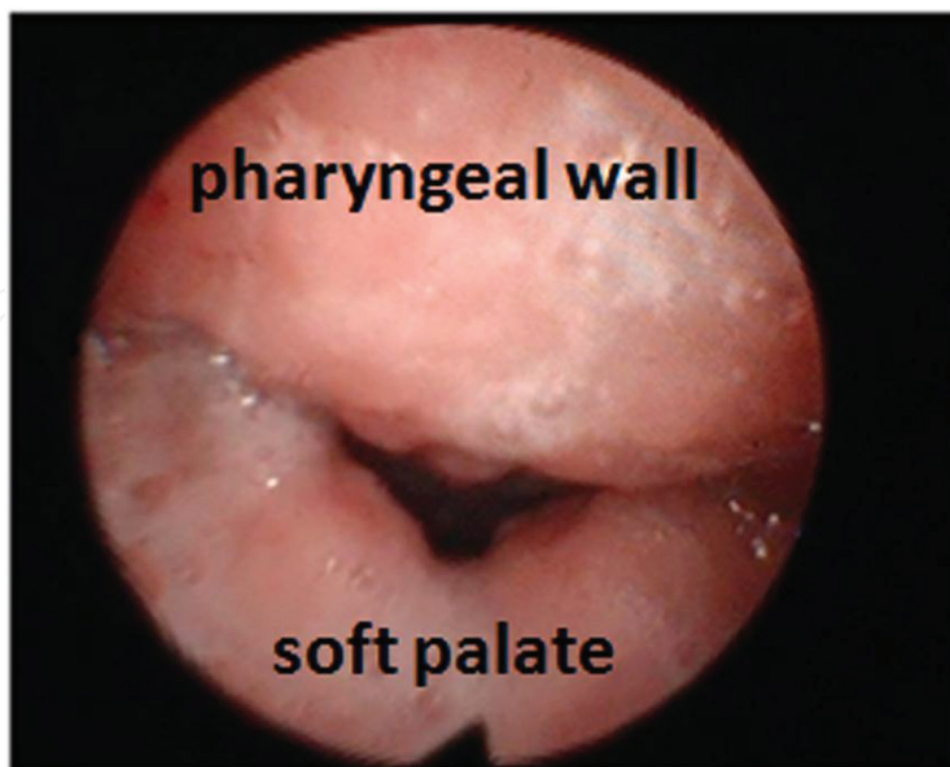
when syndromic conditions, hearing loss, and mental retardation are excluded (**Figure 7a, b**). The preoperative portion between the velar length and pharyngeal depth bilaterally often differed, especially in subject with UCLP whose major and minor segments dislocated antero-posteriorly. During palatal repair, Z-plasty was usually used for adjusting the velar length; however, complete closure of the mucosal defect by large Z-plasty sometimes moved the uvula forward remaining asymmetry of the uvula position and pharyngeal arches (**Figure 7c**). The authors thought that these asymmetries in the velopharyngeal form may disturb the symmetrical muscular approximation and cause different sizes of the velopharyngeal orifice, resulting in persistent VPI following palatal repair [15, 16]. Therefore, it is thought to be useful to add a mucosal graft on the nasal side to fill the mucosal defect and to avoid an asymmetric VP form that may facilitate symmetrical velar motion in the VP closure mechanism.



**Figure 7.** The reasons for postoperative VPI following CP repair: (a) the wide cleft, (b) short palate, (c) asymmetry of the uvula position and pharyngeal arch.

Furthermore, in the authors' experience during endoscopic examination of patients with persistent VPI, an asymmetric pharyngeal form or movement of the velopharynx and the midline defect of the velum were often observed, and they might be critical causes of VP closure dysfunction. Regarding the midline defect of the velum, Kuehn and Perry also reported that a midline defect suggested the presence of a deficiency or lack of musculus uvulae tissue or unsatisfactory surgical repair of this muscle (**Figure 8**) [17]. The anatomy and functional significance of the uvular muscle for VP closure was described by Kuehn et al. [18]. The uvular muscle courses posteriorly from its origin along the midline of the velum near the nasal surface of the velum. It is in its most cohesive form in the area overlying, and cradled by, the levator sling. The uvular muscle adds bulk to the dorsal aspect of the velum, thereby helping to fill the area between the velum and posterior pharyngeal wall. Without such bulk, the dorsal region would be concave, rather than convex, demonstrating a midline defect in the velum. In these cases, complete VP closure would not be achieved [17].

Considering the above, to ensure complete VP closure on CP repair, it is important to construct a symmetrical and functional velopharynx. Therefore, the authors have established a surgical strategy for palatal repair focusing on sufficient lengthening of the nasal mucosa, retropositioning the palatal muscles to produce a symmetrical levator sling, and unionizing the palatal muscles with a certain width in the midline of the velum. In the result, the surgical strategy for palatal repair facilitates successful speech outcomes in almost the same levels as those of Japanese children without cleft palate. There was no description about speech results of the CP patients based on the successful achievement of postoperative Velopharyngeal closure function equal to normal children.



**Figure 8.** The midline defect of the velum of endoscopic examination might be a critical cause of VP closure dysfunction.

## 7. Conclusions

Cleft palate repair using a modified V-Y palatoplasty combining with a large Z-plasty and a mucosal graft on the nasal side of the velum for symmetrical muscular reconstruction based on the surgical strategy that approaches each anatomical and pathological abnormalities of cleft palate. Following palate repair based on our surgical strategy, patients' speech was significantly improved, and the nasalance scores were recovered to almost the same levels as those of Japanese children without cleft palate.

### Author details

Norifumi Nakamura\* and Masahiro Tezuka

\*Address all correspondence to: nakamura@dent.kagoshima-u.ac.jp

Department of Oral and Maxillofacial Surgery, Field of Maxillofacial Rehabilitation, Kagoshima University Graduate School of Medical and Dental Sciences, Kagoshima, Japan

## References

- [1] Stengelhofen J: The nature and causes of communication problems in cleft palate. In: Stengelhofen J, editors. *Cleft Palate: The Nature and Remediation of Communication Problems*. Edinburg: Churchill Livingstone; 1989:1-30.

- [2] Oyama K, Nishihara K, Matsunaga K, Miura N, Kibe T, Nakamura N: Perceptual-speech, nasometric, and cephalometric results after modified V-Y palatoplasties with or without mucosal graft. *Cleft Palate Craniofac J*. 2016;53:469-480.
- [3] Dorrance GM, Bransfield JW: Cleft palate. *Ann Surg*. 1943;117:1-27.
- [4] Ruding R: Cleft palate. *Plast Reconstr Surg*. 1964;33:132-147.
- [5] Kreins OB: Fundamental anatomic findings for and intravelar veloplasty. *Cleft Palate J*. 1970;7:27-36.
- [6] Edgerton MT, Dellon L: Surgical retrodisplacement of the levator veli palatine muscle. Preliminary report. *Plast Reconstr Surg*. 1971;47:154-167.
- [7] Kaplan EN: Soft palate repair by levator muscle reconstruction and a buccal mucosal flap. *Plast Reconstr Surg*. 1975;56:129-136.
- [8] Millard DR Jr: Refining the V-Y palate repositioning. In: Millard DR Jr, editors. *Cleft Craft. The Evolution of Its Surgery III. Alveolar and Palatal Deformities*. Boston: Little Brown and Co.; 1980:419-448.
- [9] Jackson IT, Moreira-Gonzales AA, Rogers A, Beal BJ: The buccal flap – a useful technique in cleft palate repair? *Cleft Palate-Craniofac J*. 2004;41:144-151.
- [10] Nishio J, Yamanishi T, Kohara H, Hirano Y, Sako M, Adachi T, Mukai T, Miya S: Early two-stage palatoplasty using modified Furlow's veloplasty. *Cleft Palate-Craniofac J*. 2010;47:73-81.
- [11] Brothers DB, Dalston RW, Peterson HD: Comparison of the Furlow double-opposing z-plasty with the Wardill-Kilner procedure for isolated cleft of the soft palate. *Plast Reconstr Surg*. 1995;95:969-977.
- [12] van Lierde KM, Monstrey S, Bonte K, Van Cauwenberg P, Vinck B: The long-term speech outcome in Flemish young adults after two different types of palatoplasty. *Int J Pediatr Otorhinolaryngol*. 2004;68:865-875.
- [13] Ogata Y, Tezuka M, Matsunaga K, Nakamura N: A trial for characterizing the behaviors of velopharyngeal closure insufficiency under various oral pressure conditions in cleft palate. In: Jaso N, Maria D'Cruz A, editors. *Cleft Lip and Palate: Etiology, Surgery & Repair and Sociopsychological Consequences*. New York: Nova Science Publishers Inc.; 2013:145-158.
- [14] Ogata Y, Nakamura N, Kubota Y, Sasaguri M, Kikuta R, Shirasuna K, Ohishi M: Nasometer test for analysis on velopharyngeal function of patients with cleft palate (in Japanese with English Abstract). *Jpn J Cleft Palate Assoc*. 2003;28;9-19.
- [15] Nakamura N, Ogata Y, Sasaguri M, Suzuki A, Kikuta R, Ohishi M: Aerodynamic and cephalometric analyses of velopharyngeal structure and function following re-pushback surgery for secondary correction in cleft palate. *Cleft Palate-Craniofac J*. 2003;40(1):46-53.
- [16] Nakamura N, Ogata Y, Kunimitsu K, Suzuki A, Sasaguri M, Ohishi M: Velopharyngeal morphology of patients with persistent velopharyngeal incompetence following re-pushback surgery for cleft palate. *Cleft Palate-Craniofac J*. 2003;40(6):612-617.



- [17] Kuehn DP, Perry JL: Anatomy and physiology of the velopharynx. Part V Cleft palate speech and management of velopharyngeal dysfunction. In: Losee JE, Kirshner RE, editors. *Comprehensive Cleft Care*. New York: The McGraw-Hill Companies Inc.; 2009:557-567.
- [18] Kuehn DP, Folkins JW, Cutting CB: Relationships between muscle activity and velar position. *Cleft Palate J*. 1982;19:25-35.

IntechOpen

IntechOpen