

# We are IntechOpen, the world's leading publisher of Open Access books Built by scientists, for scientists

4,800

Open access books available

122,000

International authors and editors

135M

Downloads

Our authors are among the

154

Countries delivered to

TOP 1%

most cited scientists

12.2%

Contributors from top 500 universities



WEB OF SCIENCE™

Selection of our books indexed in the Book Citation Index  
in Web of Science™ Core Collection (BKCI)

Interested in publishing with us?  
Contact [book.department@intechopen.com](mailto:book.department@intechopen.com)

Numbers displayed above are based on latest data collected.  
For more information visit [www.intechopen.com](http://www.intechopen.com)



---

# Adjustable Midurethral Slings in the Treatment of Female Stress Urinary Incontinence

Funda Gungor Ugurlucan and Cenk Yasa

Additional information is available at the end of the chapter

<http://dx.doi.org/10.1163/174552512X632115>

---

## Abstract

Midurethral slings have become the gold standard in the surgical treatment of stress urinary incontinence (SUI). However, despite the high cure rates with these procedures, nearly 20% of the patients are incontinent after surgery. On the other hand, in a small percentage of women, voiding dysfunction may develop after surgery. Adjustable slings have been advocated in patients who fail an anti-incontinence surgery or have intrinsic sphincter deficiency (ISD) or in order to prevent postoperative voiding dysfunction. There are various options of adjustable slings according to the surgical route or the type of mesh used.

**Keywords:** stress urinary incontinence, adjustable slings, midurethral slings, minisling, mesh

---

## 1. Introduction

Stress urinary incontinence (SUI) is the involuntary loss of urine occurring with increases in intra-abdominal pressure such as coughing and sneezing and is encountered in 4–35% of women [1, 2]. First-line treatments for symptomatic SUI are behavioral treatment, pelvic floor muscle exercises and continence pessaries [3]. For women who do not benefit from or are not willing to undergo conservative treatment, surgery is recommended.

In the last 20 years, there has been an increasing search and demand for minimally invasive approaches in SUI surgery. After the wide acceptance of the integral theory proposed by Petros and Ulmsten [4] suggesting that the urethral closure occurred in the midurethra, instead of suburethral slings supporting the bladder neck, midurethral slings have been developed. In 1996, Ulmsten described the tension-free vaginal tape (TVT) operation [5]. Afterward, in

---

order to prevent potential complications of TVT, Delorme described the transobturator tape (TOT) operation in 2001 [6]. Due to their long-term efficacy, the most commonly used anti-incontinence surgeries are midurethral sling surgeries (MUS). They are similar in efficacy to conventional suburethral slings, Burch retropubic colposuspension and laparoscopic colposuspension; are minimally invasive; have shorter operating time and have less postoperative complications [3].

Midurethral slings have been classified into three generations [7]. First-generation MUS is retropubic TVT and is accepted as the gold standard surgery for SUI. Second-generation MUS is the TOT, both outside in and inside out approaches. The advantage of this technique is the avoidance of the retropubic space. Third-generation MUS are the single-incision slings, which have a shorter mesh and only a single incision that is vaginal. The long-term success rates of MUS vary between 77 and 90% [8]. Both objective and subjective success rates for single-incision slings are lower when compared to standard MUS [9].

Despite high success rates of standard MUS operations, nearly 20% of patients undergoing MUS suffer from persistent or recurrent symptoms after surgery [10, 11]. Therefore, there is a need for other options in patients who fail standard minisling, transobturator, or retropubic sling operations. In addition, voiding dysfunction may develop in 2.8–38% after retropubic sling and 0–15.6% after TOT operation and additional interventions such as intermittent catheterization, sling excision and urethrolisis may be required [11].


Adjustable slings are reasonable alternatives in order to avoid or treat these two potential complications [12]. The aims of adjustable sling operations are adjusting the tension of the sling according to the severity of the patients' condition or symptoms, either during surgery or after surgery in order to prevent persistence of symptoms or development of postoperative voiding dysfunction. In some cases, there is the possibility of adjusting sling tension anytime during follow-up, even years after the primary operation. Various adjustable sling materials are discussed below according to the route of application and their adjustment techniques.

## 2. Adjustable slings with retropubic approach

### 2.1. Remeex system

Regulation Mechanical External® (Remeex; Neomedic International, Terrassa, Spain) is a readjustable sling and allows the regulation of sling tension not only in the postoperative period but also at anytime during follow-up. Theoretically, it is based on the TVT operation. The Remeex system contains 30 × 15 mm<sup>2</sup> type-1 macroporous polypropylene mesh, 2 polypropylene sutures attached to this mesh, a *varitensor* and a manipulator attached to the *varitensor* for the adjustment of the tension of the mesh (**Figure 1**). The *varitensor* and the manipulator are made of biocompatible materials such as titanium and ultrahigh-molecular-weight polyethylene (Chirulen®).

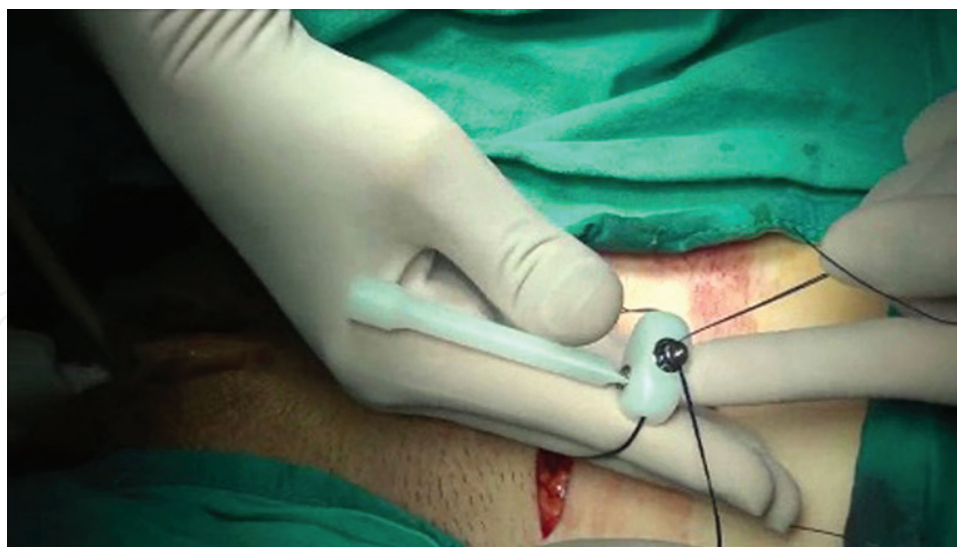
First, a 4 cm transverse skin incision is made 2 cm above the symphysis pubis dissecting the subcutaneous fat and exposing the rectus fascia. A vertical vaginal incision is made at



**Figure 1.** The Remeex system.

the level of the midurethra and dissection is continued until the pubic rami are reached. Traction needles are passed from the vaginal incision retropubically through the rectus fascia. After ensuring that the bladder is intact with cystoscopy, sutures are passed through the *varitensor* and tied (**Figure 2**). Mesh is placed at the level of the midurethra. The *varitensor* is placed over the rectus fascia and the skin and vaginal incisions are sutured. The day after surgery, the bladder is filled with 300 ml saline through the Foley catheter. The Foley catheter is removed and the patient is asked to stand up and cough. If there is any leakage, the manipulator attached to the *varitensor* can be rotated and the tension on the mesh can be adjusted. Afterward, the patient is asked to void; if the postvoid residual urine volume is less than 100 ml, the manipulator is withdrawn. If the residual urine volume is over 100 ml, the tension is decreased by rotating the manipulator on the opposite direction. If the patient develops recurrent urinary incontinence or voiding dysfunction anytime during follow-up, it is possible to incise the previous suprapubic incision under local anesthesia, find the *varitensor*, which is located inside the subcutaneous tissue and adjust the tension of the mesh by using the same technique.

Iglesias and Espuna first reported the usage of Remeex<sup>®</sup> system in 21 patients with recurrent urinary incontinence in 2003. They reported 90.5% success rate with mean follow-up of 12 months [13]. Mantovani et al. applied Remeex system in 32 patients with fixed urethra, urethral hypermobility, intrinsic sphincter deficiency (ISD) and previous anti-incontinence surgery with a follow-up of 3 years [14]. Thirty-one of the patients were cured and readjustment



**Figure 2.** The Remeex system. Polypropylene sutures are passed through the *varitensor* and tied above the rectus fascia. The manipulator is attached to the *varitensor*.

was performed in three. The device was removed due to infection in one case. Yoo et al. evaluated the outcome of Remeex procedure in 17 patients in whom the success rate of tension-free slings was low, such as patients with ISD [15]. Five (29.4%) had previous anti-incontinence surgery and four (23.5%) had mixed urinary incontinence. Mean follow-up period was 13 months. Fourteen patients (82.3%) were cured and three patients (17.6%) were improved. Araco et al. applied Remeex system in 38 patients with ISD [16]. Immediate postoperative adjustment of sling tension was necessary in three patients (7.9%), two for obstructive voiding and one for incontinence. Late adjustment was necessary in three patients (7.9%), two for obstructive voiding and one for incontinence. The possibility of immediate and late adjustment of sling tension resolved postoperative failures and maintained the success rate of the Remeex system in the long term.

Moreno Sierra et al. retrospectively evaluated the outcome of Remeex system in 683 patients with mixed urinary incontinence, ISD and recurrent SUI [17]. Mean follow-up period was 23 months. 73.1% of the patients had ISD and 35.7% of the patients had a previous history of failed surgery for SUI. In this group, 92.2% cure, 6.9% improvement and 0.9% failure were observed. Errando et al., in their prospective study, evaluated the outcomes, complications and quality of life of 125 patients with recurrent SUI and ISD who underwent Remeex system [18]. After a mean follow-up of 38 months, objective and subjective cure was observed in 109 patients (87%). Sixteen patients (13%) remained incontinent, but nine (7%) were satisfied to the point that they declined readjustment of the sling. The *varitensor* was removed in one case because of infection.

Park et al. evaluated the efficacy of Remeex system in 102 patients with recurrent SUI after failed anti-incontinence surgery or ISD [19]. After a mean follow-up of 27 months, 91 patients (89.2%) were cured and six patients (5.9%) were improved. Forty percent of the patients had complications: 15 (14.7%) presented with de novo urgency, which was managed with

anticholinergics; 14 (13.7%) underwent delayed sling readjustment during follow-up; and six (5.9%) developed wound infection with two of these undergoing removal of the Remeex system. Although the complication rate was 40% in this study, 70% of these complications were minor and 88% of grade 3 complications were postoperative sling tension readjustments.

Yasa et al. evaluated the efficacy and safety of Remeex system in the treatment of recurrent SUI after MUS failure prospectively in 19 women [20]. Mean follow-up was  $20 \pm 14$  months. The overall cure and improvement rates were 84.2 and 10.5%, respectively. Fifteen (79%) patients were very satisfied and three (15.7%) were moderately satisfied. Sling tension readjustment was needed during follow-up in one patient (5.3%), 13 months after the initial surgery. The authors suggested that Remeex system was effective in the treatment of recurrent SUI after MUS failure with acceptable rate of adverse effects.

Studies with long-term follow-up after Remeex procedure have been published as well. Barrington et al. evaluated the effect of Remeex system in 20 women with previous anti-incontinence surgery with a follow-up of 5 years [21]. Two systems had to be removed due to chronic infection around the *varitensor* that failed to respond to antibiotics and aspiration/drainage. However, the sling was left in situ and continence was maintained. No suture breakage or urethral erosions were observed in any patients. Two women performed intermittent self-catheterization. All the domains of the King's Health Questionnaire were improved significantly except for the general health domain at both 1 year and 5 years. There was also a significant reduction in the number of pads used daily. At 1 year, nine women considered that their incontinence had been cured by the Remeex procedure; 11 women felt their symptoms had improved. By 5 years, nine women were still cured and only two women felt the system had failed but declined any further tightening.

Giberti et al. evaluated the objective and subjective outcomes of the Remeex system for SUI caused by ISD in 30 patients, retrospectively [22]. Mean follow-up was 60.6 months. 86.0% of the patients were cured, 7.0% were improved and 7.0% had failed. There was a significant decrease in the mean pad weight and significant improvement in quality of life. Sling tension readjustment was needed in two patients (7%). Persistent urinary retention developed in 10%, seroma formation occurred in 3% and de novo urgency developed in 7% and they were treated with anticholinergics.

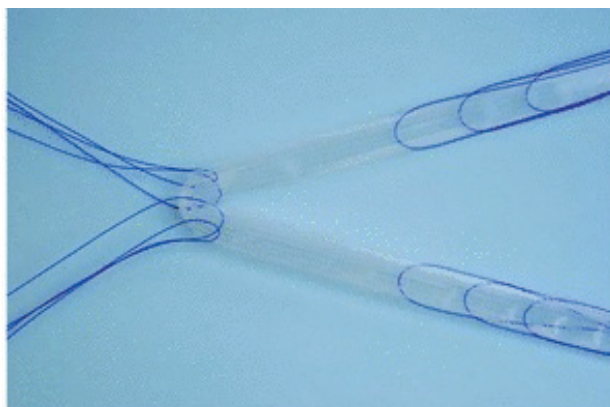
Main complications encountered with the Remeex system include wound infection and seroma formation, voiding dysfunction including urinary retention and de novo urge incontinence. Lorenzo-Gómez et al. evaluated the severe complications and failures of Remeex system retrospectively in 60 women [23]. The procedure was successful in 68.3% of the cases. Thirty-five percent of the patients required sling adjustment. There were three cases with severe complications: refractory urinary incontinence in one patient, massive pelvic hemorrhage in a patient who was on anticoagulant treatment and infected vaginal calculi measuring 7 cm on an eroded Remeex suture 4 years after the implantation.

All of the studies support that the Remeex system is a useful adjuvant in the treatment of recurrent or persistent SUI that has not been cured by conventional surgery. The cure rates may decline slightly over time, but this deterioration is mild and readjustment can be easily

performed rather than repeating the entire sling procedure or another invasive procedure. Although this system can be used in primary surgery due to the advantage of long-term adjustability, in our opinion, it should not be used as a primary option except in cases with low urethral closing pressure, where the reported cure rates of other methods are generally lower. In addition, the procedure is more expensive than a standard TVT, but when compared to repeat surgery, it becomes cost-effective. In our opinion, it is best to perform this operation in patients with previous failed anti-incontinence procedure or ISD.

## 2.2. Transvaginal adjustable tape (TVA)

Transvaginal adjustable tape (TVA) (Agency for Medical Innovations, Im Letten 1, 6800 Feldkirch, Austria) insertion technique is similar to that of the TVT and suprapubic arc (SPARC) sling procedures. The tape used is a macroporous, monofilament polypropylene non-elastic mesh. Two groups of polypropylene sutures are attached to this mesh (**Figure 3**). The first group of sutures consists of two strings of polypropylene on either side situated 1.5 cm from the midline of the tape which are externalized through the vaginal wall. These sutures serve to reduce the tension on the mesh when pulled downward. The second group of sutures is formed of three strings of polypropylene in each arm of the tape situated at different distances from the midline. These are externalized from the suprapubic incisions through which the mesh is taken out. These sutures serve to increase the tension on the mesh when pulled up.



**Figure 3.** TVA sling [24].

Adjustment is performed the day after surgery by filling the bladder with 250 ml saline through the Foley catheter. The patient is asked to cough while standing or in the supine position. After adjustment of the tape, uroflowmetry is performed. If the maximum flow rate is below 10 ml/s or the postvoid residual urine volume is above 50 ml, the sutures on the vaginal side are pulled down in order to reduce the tension.

Romero Maroto et al. evaluated 64 women who suffered from SUI and underwent TVA prospectively [24]. Mean follow-up was  $40 \pm 13$  months. Objective and subjective cure rates were 94 and 56%, respectively. The tension was adjusted in 26 (40.6%) patients postoperatively; in 16 (25%), the tension was increased and in 10 (15.6%), the tension was decreased. After

adjustment, all patients were continent and none had postvoid residual urine. Urgency disappeared or was ameliorated in 77% of cases suffering from overactive bladder symptoms preoperatively and appeared de novo in four of the 27 cases (15%). No infection and vaginal or urethral erosions were reported. There was significant improvement in quality of life. TVA mesh was found as a good option for the postoperative adjustment of tension of the mesh in patients who are incontinent after the procedure and better objective and subjective results could be obtained than those achieved with the traditional nonadjustable mesh without increasing complications. However, there are no other studies comparing TVA with other adjustable or nonadjustable slings or tapes as far as we know.

### 3. Adjustable slings with retropubic and transobturator approach

#### 3.1. Safyre

Safyre (Promedon, Córdoba, Argentina) is also a type of adjustable sling used for treatment of SUI. Safyre consists of a central monofilament polypropylene mesh held between two self-anchoring columns, which are made up of polydimethylsiloxane polymer (silicone) (Figure 4). These columns are the basis of the adjustment system; these columns attach to the surrounding tissue and are held by fibrotic encapsulation [25]. Safyre can be inserted via retropubic approach similar to TVT or transobturator approach similar to TOT. Safyre VS, Safyre T and Safyre T Plus types can be inserted via vaginal-suprapubic, suprapubic-vaginal and transobturator routes, respectively. Intraoperative and postoperative adjustments are possible with Safyre system, but adjustments should be done under local or general anesthesia and an incision should be made in order to locate the silicone columns. The columns can be easily palpated under local anesthesia. Unilateral adjustment is usually sufficient. During this maneuver, scissors or a clamp should be inserted between the urethra and the mesh in order to avoid excessive tensioning. During adjustment, cough stress test may be used. In order to reduce the tension on the mesh, one of the arms should be held with a clamp and pulled downward. Generally, it is advised to make the adjustment within 30 days after surgery, before fibrosis occurs. However, theoretically fibrotic encapsulation of the polydimethylsiloxane columns allows easy adjustment even after this period.




Figure 4. Safyre sling set [26].

Palma et al. reported good results with Safyre both with suprapubic and transvaginal approaches [26]. Forty-five women underwent Safyre sling operation with transvaginal



approach in their preliminary prospective study [26]. Mean follow-up period was 10 months. Ninety percent of the women were continent, 3% improved and 7% were the same. Postoperative urinary retention developed in three women (6.7%) who could not void spontaneously within 4 weeks after surgery and needed sling readjustment. There were four cases (9%) of vaginal wall infection, but no vaginal or urethral wall erosion. Palma et al., in their prospective, multicenter, single-arm, unrandomized study evaluated 126 women with clinical and urodynamic SUI who underwent Safyre sling [27]. Sixty percent of the patients had a history of failed sling procedure. Mean follow-up period was 18 months. Bladder perforation developed in 2% and de novo urgency symptoms developed in 21% of the patients. Urinary retention developed in four of the 126 patients (3%) who could not void spontaneously 4 weeks after surgery and underwent sling tension loosening. During follow-up, 116 women (92%) were continent, three (2%) improved and seven (6%) were dissatisfied. Six patients (5%) presented with recurrent urinary incontinence and underwent sling adjustment. Four patients were continent afterward and symptoms improved in two. Six patients (5%) presented with vaginal pain, discharge, bleeding, dyspareunia and dysuria and were diagnosed with vaginal erosion and one had recurrent urinary tract infection. Topical treatment and oral antibiotics failed and all patients underwent transvaginal tissue debridement. The protruding part of the tape was removed in four women and reconstruction with a vaginal flap was needed in two. None of the erosions recurred. Using transobturator approach, the results were similar with a cure rate of 90% with 6 months of follow-up [28]. The same group conducted a comparative study of transobturator ( $n = 100$ ) and retropubic ( $n = 126$ ) approaches using Safyre in 2005 in a total of 226 patients [29]. The mean follow-up period was 18 months in the retropubic and 14 months in the transobturator group. The mean operative time was significantly longer and bladder injury was significantly greater in the retropubic group (2.3% vs 0%). There was no significant difference in the cure rate between the two groups (retropubic 92.1% and transobturator 94%). The overall complication rate was 33.3 and 20% in the retropubic and transobturator group, respectively. Postoperatively, 20.6% of the patients presented with de novo urgency in the retropubic group as opposed to 10% in the transobturator group. The authors concluded that Safyre performed by transobturator approach was as effective as the retropubic approach with the additional advantages of fewer complications and shorter operative time.

Silva-Filho et al. compared autologous pubovaginal sling with transobturator Safyre; 20 women suffering from SUI were randomly assigned to pubovaginal sling or Safyre [30]. Mean operative time and duration of hospitalization were significantly longer in the pubovaginal sling group. There were no intraoperative complications in either group. One (10%) patient in the Safyre group developed urinary retention. The mean postoperative pad test was significantly higher in the Safyre group and improvement in the quality of life parameters was better in the pubovaginal sling group. The rate of persistent SUI was significantly higher in the Safyre group (70% vs 10%). The authors ended their study prematurely due to significant discrepancy in the success rates between the two groups.

The main concerns over Safyre are the potential higher risk of erosion and dislocations due to the silicone columns. In various studies regarding urogynecologic surgery, the use of silicone

has been found to carry a higher risk of erosions ranging from 19 to 71% [25, 31–33]. Kuschel et al. evaluated the efficacy and safety of Safyre-t in 79 women, retrospectively [25]. The mean follow-up period was  $20 \pm 4$  months. 59.5% of the women stated that they were subjectively continent. Vaginal sling erosion and a pre-erosive state were found in 8.8 and 13.9% of the patients, respectively. The lateral silicone column could be palpated in 47% of the patients indicating dislocation. Six women complained of dyspareunia and one woman stated that her partner had felt discomfort during sexual intercourse since her vaginal sling surgery. The authors concluded that despite acceptable subjective continence rates, Safyre-t was associated with a comparatively high rate of vaginal sling erosions and dislocations. The fibrous encapsulation of the silicone columns offers the potential advantage of adjustability but also increases the risk of dislocation. Dislocation may be related to sinus formation around the columns [32]. Padilla-Fernández et al., in their study comparing the efficacy of different types of TOT, stated that in 4 of the 44 patients who underwent Safyre implantation, the silicone column was detached from the mesh and patients had recurrent incontinence and required readjustment [34]. However, this study is limited with low numbers of patients in each mesh group.

In conclusion, Safyre, despite its advantage of intraoperative and postoperative adjustment and high subjective satisfaction rates, has shown high erosion, infection and dyspareunia rate in some studies. Comparative studies with higher number of patients and long-term follow-up are needed.

## **4. Adjustable slings with transobturator approach**

### **4.1. Transobturator adjustable tape (TOA)**

Transobturator adjustable tape (TOA) (Agency for Medical Innovations, Im Letten 1, 6800 Feldkirch, Austria) is a nonelastic tape made of macroporous polypropylene mesh. It contains two groups of polypropylene sutures; one group has two sutures located at 1.5 cm from the midline of the mesh laterally and is exteriorized through the anterior vaginal mucosa and used to reduce sling tension. The other group consists of three sutures in each arm of the mesh and these sutures are exteriorized through the groin incisions in order to increase the tension. Technically, the procedure is the same as the outside-in TOT.

Adjustment is performed the day after surgery by filling the bladder with 250 ml saline through the Foley catheter. The patient is asked to cough while standing or in the supine position. After adjustment of the tape by pulling the groin sutures by 0.5 cm, uroflowmetry is performed. If the maximum flow rate is below 10 ml/s or the postvoid residual urine volume is above 50 ml, the sutures on the vaginal side are pulled down in order to reduce the tension. When the adjustment is completed, the sutures are cut.

Lee et al., in their prospective multicenter study, evaluated the efficacy and safety of TOA in 65 women with SUI or combined SUI and voiding dysfunction [35]. Forty-six of the patients suffered from severe SUI and 30 patients had both SUI and voiding dysfunction. Twenty-seven of the 65 patients (41%) required tape readjustment. Fourteen patients (21%) underwent loosening and 13 patients (20%) underwent sling tensioning. Six months after surgery, the

cure rate for patients with combined SUI and voiding dysfunction was 76.7% and the cure rate for patients with severe SUI was 89.1%. There was a significant improvement in quality of life. There were no intraoperative complications. One patient underwent sling excision due to persistent voiding dysfunction and another patient underwent sling removal due to infection.

Oh et al. evaluated 80 women who suffered from ISD and underwent either TOA (n = 80) or TOT (n = 47) [36]. There was no difference between the two groups regarding the cure rates (TOA group, 75.6%, vs TOT group, 72.3%). Four patients (12.1%) in the TOA group underwent release of sling tension due to urinary obstruction, whereas sling tensioning was performed in five patients (15.2%). TOA procedure allows postoperative readjustment of the sling tension for a couple of days after surgery leading to good short-term results after surgery.

Patrelli et al. performed TOA procedure in 77 women with SUI and the cure rate and satisfaction rate were 90.9 and 75.3%, respectively [37]. 46.8% of the patients were immediately adjusted, whereas 14.3% of the patients had sling adjustment during hospitalization. The authors stated that the TOA was a safe and effective procedure with high rate of patient satisfaction.

## 5. Adjustable minislings

### 5.1. Altis

The Altis® (Coloplast) is an adjustable single-incision sling made of type-1 macroporous polypropylene mesh measuring 7.75 cm [38]. It has low elasticity (7.5%), which allows the maintenance of integrity under tension and two anchors, one static and one bidirectional, that allow intraoperative tension adjustment. The procedure can be performed under general, spinal, or local anesthesia. A 1.5 cm incision is made on the vaginal mucosa at the level of the midurethra. Sharp and blunt dissection is carried through the periurethral tissue and the pubic rami are reached bilaterally. The sling and the needle are advanced behind the ischiopubic rami toward the obturator space bilaterally. The needle is then removed. After the fixation of the anchors at the 2 and 10 o'clock positions, the bladder is filled with 250 ml of saline, intraoperative cough stress test is performed and the tension adjustment suture is pulled, when necessary. The adjustment thread is then cut short and the vaginal incision is closed.

Dias et al. evaluated the efficacy and complication rate of Altis® in 52 women suffering from SUI [38]. Fifty women completed the 12-month follow-up period. The subjective and objective cure rates were 84 and 90%, respectively. One case of vaginal extrusion developed requiring surgical removal of the eroded mesh. Vaginal exposure of the adjustment thread developed in three patients and was managed conservatively. De novo urgency developed in three patients and mild dyspareunia developed in two patients. The Altis® sling was found as a safe and an effective procedure for the treatment of SUI with a short-term follow-up.

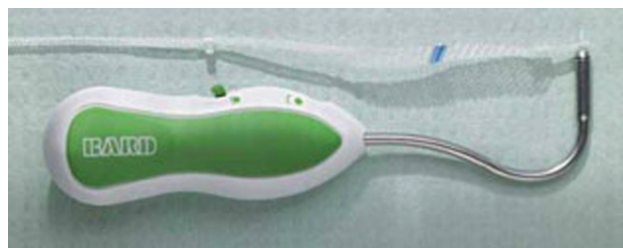Kocjancic et al. evaluated the efficacy and safety of Altis® in 113 women suffering from SUI [39]. One hundred and one women completed the 12 months of follow-up. Ninety-one women

(90.1%) achieved a 50% or greater reduction in pad weight and the stress test was negative in 91 (90.1%) women at 12 months. There was a significant improvement in quality of life and patient-reported outcomes. There were no reports of mesh erosion or migration through 12 months of follow-up.

Although these two studies have shown that Altis® is an efficient procedure with minimal adverse effects, it should be noted that these two studies are limited with the short follow-up period of 12 months and no randomized comparison of the procedure to other sling operations.

## 5.2. Ajust

Ajust™ (adjustable single-incision transobturator sling, C.R. Bard Inc., New Providence, NJ, USA) is an adjustable single-incision sling with a 1.2 cm wide macroporous polypropylene mesh. The Ajust differs from the other single-incision slings in that it has a pulley-like system that allows adjustment following insertion. The Ajust™ system consists of a curved introducer with an anchor release lever, the sling implant, one fixed anchor, one adjustable anchor, adjustment mesh, sling lock, adjusting tab and a flexible stylet (**Figure 5**).



**Figure 5.** Ajust™ system. The sling and the curved introducer [41].

A vertical vaginal incision is performed at the level of the midurethra. Bilateral paraurethral tunnels are formed until the posterior margin of the inferior pubic rami without perforating the obturator membrane. Curved introducers loaded with self-fixating anchors are used to turn around the ischiopubic rami and fixate the anchors to obturator internus muscle and obturator membrane. Following the insertion of both anchors, the sling is adjusted in its final position by the sling lock and flexible stylet. The tension of the sling is adjusted so that the mesh is positioned in direct contact with the urethra as opposed to other retropubic or transobturator slings. Then, the adjustment mesh is cut and the vaginal incision is sutured.

In a cadaveric study, the fixation site of the anchor of the Ajust™ was studied [40]. Correct placement in the obturator membrane was achieved in 65.6% of cases. In 87.5% of cases, the anchor was placed within the complex of the obturator membrane and obturator muscles. There was more than 2 cm distance to the obturator bundle in all cases.

Meschia et al. evaluated the short-term outcomes of Ajust™ in 102 women with SUI [41]. No intraoperative complications occurred, except for technical difficulty with the fixation of the adjusting anchor on the left side of the patient. Insertion of a new Ajust tape or a TOT tape was necessary in four and two subjects, respectively. One woman suffered from urinary retention

and required sling excision 9 days after surgery. The subjective and objective cure rates were 85 and 91%, respectively. There was a significant improvement in quality of life.

Similarly, Liapis et al. reported a 90% objective success rate at 6 months in 42 cases under epidural anesthesia [42]. Lucente et al., in their study, showed 91% subjective and objective success rates at 8 months in 43 women who underwent Ajust under local anesthesia [43].

Abdel-Fattah et al. evaluated the results of the Ajust™ operation with a 1-year follow-up [44]. Ninety women were operated and all completed the follow-up. Last 45 women were operated under local anesthesia. No complications occurred. Significantly, lower rates of blood loss and voiding difficulties were observed in the local anesthesia group. Subjective cure rate was 80% at the end of 1-year follow-up, with an additional 6% reporting improvement. In 13 women (14%), the procedure failed; eight reported being the same/worse and five underwent repeat surgery.

Naumann et al. compared the sexual function and quality of life following TVT and Ajust™ with a 6-month follow-up [45]. Seventy-five women underwent TVT and 75 women underwent Ajust™. Eighty-four percent of women in the Ajust™ group were cured and 9.3% were improved at the 6-month follow-up, whereas 88% of the women were cured and 6.7% were improved in the TVT group. There was a significant improvement in sexual functions and quality of life in both groups with no significant difference.

Grigoriadis et al. compared the efficacy and complication rate of Ajust™ and tension-free vaginal tape-obturator (TVT-O) [46]. The mean follow-up period was 22 months. No major intraoperative complications developed. For the TVT-O group, the objective cure rate was 86%, the improvement rate was 5.9% and the failure rate was 8.1%, while the subjective cure rate was 82.6%. For the Ajust™ group, the objective cure rate was 84.7%, the improvement rate was 4.7%, the failure rate was 10.6% and the subjective cure rate was 81.2%. Similarly, Boyers et al. compared Ajust™ with TVT-O in a total of 137 women [47]. Sixty-nine women underwent Ajust™ and 68 women underwent TVT-O. There were no significant differences between the two groups regarding subjective cure rates and improvement in quality of life. However, Ajust™ was found more cost-effective when compared to TVT-O.

Xin et al. randomized 368 women with SUI to Ajust™ or TVT-O [48]. There were no significant differences in the subjective and objective cure rates (94.4% vs 90.7% and 97.2% vs 90.7%, respectively) between Ajust™ and TVT-O. Compared with the TVT-O group, patients in the Ajust™ group had significantly less postoperative pain, shorter operative time, less intraoperative blood loss and shorter recovery time. There was no significant difference in the perioperative complications between the two groups.

Natale et al. evaluated the long-term results of Ajust™ operation [49]. Ninety-two patients completed the 2-year follow-up. The objective cure rate was 83.7% and the subjective cure rate was 81.5%. There was a significant improvement in quality of life. De novo urgency developed in nine women (9.8%). No intraoperative complications developed. Postoperative complications were leg pain in one woman, mesh extrusions in three women and recurrent urinary tract infections in one woman.

The main advantages of Ajust™ are its minimally invasive nature and adjustability. In a meta-analysis evaluating studies that compared single-incision slings with transobturator tape operations, similar subjective and objective cure rates were obtained and intraoperative complications were rare [50]. However, studies with long-term follow-up are needed.

## 6. Conclusion

Recurrent SUI and voiding dysfunction are the main problems encountered after midurethral sling operation. Adjustable midurethral slings may be used in order to avoid these problems. Some of the adjustable sling can only be adjusted during the procedure, whereas some could be adjusted at any desired time. This could prevent the requirement of additional sling surgery in patients with recurrent SUI.

There are various options of adjustable slings according to the surgical route such as retro-pubic or transobturator or single-incision slings or type of mesh used. Although there are studies suggesting high objective and subjective cure rates with these slings, still prospective randomized trials with long-term follow-up data are needed.

## Author details

Funda Gungor Ugurlucan\* and Cenk Yasa

\*Address all correspondence to: [fgungor@yahoo.com](mailto:fgungor@yahoo.com)

Department of Obstetrics and Gynecology, Istanbul Faculty of Medicine, Istanbul University, Istanbul, Turkey

## References

- [1] Luber KM. The definition, prevalence and risk factors for stress urinary incontinence. *Rev Urol* 2004; 6(Suppl 3): S3-S9.
- [2] Haylen BT, de Ridder D, Freeman RM, Swift SE, Berghmans B, Lee J, et al. An international Urogynecological Association (IUGA)/International Continence Society (ICS) joint report on the terminology for female pelvic floor dysfunction. *Neurourol Urodyn* 2009; 29: 4-20.
- [3] Abrams P, Cardozo L, Fall M, Griffiths D, Rosier P, Ulmsten U, et al. The standardisation of terminology in lower urinary tract function: report from the standardisation subcommittee of the International Continence Society. *Urology* 2003; 61: 37-49.
- [4] Petros PE and Ulmsten UI. An integral theory of female urinary incontinence: experimental and clinical considerations. *Acta Obstet Gynecol Scand* 1997; 166(Suppl): 3-8.

- [5] Ulmsten U, Henriksson L, Johnson P, Varhos G. An ambulatory surgical procedure under local anaesthesia for treatment of female urinary incontinence. *Int Urogynecol J* 1996; 7:81-86.
- [6] Delorme E. Transobturator urethral suspension: mini-invasive procedure in the treatment of stress urinary incontinence in women. *Prog Urol* 2001; 6:1306-1313.
- [7] Abdel-Fattah M, Ford JA, Lim CP, Madhuvrata P. Single-incision mini-slings versus standard midurethral slings in surgical management of female stress urinary incontinence: a meta-analysis of effectiveness and complications. *Eur Urol* 2011; 60: 468-480.
- [8] Ford AA, Rogerson L, Cody JD, Ogah J. Mid-urethral sling operations for stress urinary incontinence in women. *Cochrane Database Syst Rev* 2015; (7): CD006375.
- [9] Nilsson CG, Palva K, Pezapour M, Falconer C. Eleven years prospective follow-up of the tension-free vaginal tape procedure for treatment of stress urinary incontinence. *Int Urogynecol J Pelvic Floor Dysfunct* 2008; 19: 1043-1047.
- [10] Schimpf MO, Rahn DD, Wheeler TL, Patel M, White AB, Orejuela FJ, et al. Sling surgery for stress urinary incontinence in women: a systematic review and metaanalysis. *Am J Obstet Gynecol* 2014; 211: 71.e1-71.e27.
- [11] Liapis A, Bakas P, Creatsas G. Tension-free vaginal tape in the management of recurrent urodynamic stress incontinence after previous failed midurethral tape. *Eur Urol* 2009; 55: 1450-1455.
- [12] Jonsson Funk M, Siddiqui NY, Kawasaki A, Wu JM. Long-term outcomes after stress urinary incontinence surgery. *Obstet Gynecol* 2012; 120: 83-90.
- [13] Iglesias X, Espuna M. Surgical treatment of urinary stress incontinence using a method for postoperative adjustment of sling tension. *Int Urogynecol J Pelvic Floor Dysfunct* 2003; 14: 326-330.
- [14] Mantovani F, Castelnuovo C, Bernardini P. ReMeEx device (External Mechanic Regulator) for incontinence implantation and regulation procedure, complications and results at 3 years follow-up. *Arch Ital Urol Androl* 2004; 76: 49-50.
- [15] Yoo DH, Noh JH. Readjustable sling procedure for the treatment of female stress urinary incontinence with intrinsic sphincter deficiency: preliminary report. *Korean J Urol* 2010;51:420-425.
- [16] Araco F, Gravante G, Dati S, Bulzomi V, Sesti F, Piccione E. Results 1 year after the Reemex system was applied for the treatment of stress urinary incontinence caused by intrinsic sphincter deficiency. *Int Urogynecol J Pelvic Floor Dysfunct* 2008;19:783-786.
- [17] Moreno Sierra J, Marques Queimadelos A, Arano Beltran P, De La Fuente Perez P, Cerezela Requena JF, Cortes Otero E, et al. Spanish registry of TRT Reemex system in women with stress urinary incontinence (SUI). *Arch Esp Urol* 2006; 59: 169-174.

- [18] Errando C, Rodriguez-Escovar F, Gutierrez C, Baez C, Arano P, Villavicencio H. A re-adjustable sling for female recurrent stress incontinence and sphincteric deficiency: outcomes and complications in 125 patients using the Remeex Sling System. *Neurourol Urodyn* 2010; 29: 1429-1432.
- [19] Park BH, Kim JC, Kim HW, Kim YH, Choi JB, Lee DH. Midterm efficacy and complications of Readjustable Midurethral Sling (Remeex System) in female stress urinary incontinence with recurrence or intrinsic sphincter deficiency. *Urology* 2015; 85: 79-84.
- [20] Yasa C, Gungor Ugurlucan F, Dural O, Celik S, Yalcin O. A valuable option in the management of female recurrent stress urinary incontinence: re-adjustable sling (Remeex Sling System). *Urol Int.* 2016;97(2):224-9.
- [21] Barrington J, Archer R, Kulkarni M, Forrest A. The TRT Female Remeex System for recurrent female stress urinary incontinence: a 5-year follow-up study. *J Obstet Gynaecol* 2013; 33: 391-393.
- [22] Giberti C, Gallo F, Cortese P, Schenone M. The suburethral tension adjustable sling (Remeex system) in the treatment of female urinary incontinence due to 'true' intrinsic sphincter deficiency: results after 5 years of mean follow-up. *BJU Int* 2011; 108: 1140-1144.
- [23] Lorenzo-Gómez MF, Padilla-Fernández B, Virseda-Rodríguez AJ, Collazos-Robles RE, García-Cenador MB, Mirón-Canelo JA. Severe complications and failures of incontinence surgery using the Remeex<sup>®</sup> adjustable tension sling (external mechanical regulator) *Actas Urol Esp* 2015; 39(9): 558-563. doi: 10.1016/j.acuro.2015.05.001.
- [24] Romero Maroto J, Ortiz Gorraiz MO, Prieto Chaparro L, Pacheco Bru JJ, Mirales Bueno JJ, Lopez Lopez C. Transvaginal adjustable tape: an adjustable mesh for surgical treatment of female stress urinary incontinence. *Int Urogynecol J Pelvic Floor Dysfunct* 2008; 19: 1109-1116.
- [25] Kuschel S, Schuessler B. Results on function and safety of the Safyre-t a hybrid transob-turator vaginal sling for the treatment of stress urinary incontinence. *Neurourol Urodyn* 2008; 27: 403-406.
- [26] Palma PCR, Riccetto CLZ, Dambros M. SAFYRE: a readjustable minimally invasive sling for female urinary stress incontinence. *Int Braz J Urol* 2003; 29(4):353-359.
- [27] Palma PCR, Dambros M, Riccetto CZ, Thiel M, Netto NR. The Ibero-American experience with a re-adjustable minimally invasive sling. *BJU Int* 2004; 95: 341-345.
- [28] Palma PCR, Riccetto CLZ, Dambros M, Thiel M. Safyre sling: early results of a new tension-adjustable and self anchoring device for female stress incontinence. *J Endourol* 2002; 16(Suppl 1): Abst P25-2.
- [29] Palma P, Riccetto C, Herrmann V, Dambros M, Thiel M, Bandiera S, Netto NR Jr. Transob-turator SAFYRE sling is as effective as the transvaginal procedure. *Int Urogynecol J Pelvic Floor Dysfunct* 2005; 16(6): 487-491.



- [30] Silva-Filho AL, Candido EB, Noronha A, Triginelli SA. Comparative study of autologous pubovaginal sling and synthetic transobturator (TOT) Safyre sling in the treatment of stress urinary incontinence. *Arch Gynecol Obstet* 2006; 273: 288-292.
- [31] Govier FE, Kobashi KC, Kozlowski PM, et al. High complication rate identified in sacrocolpopexy patients attributed to silicone mesh. *Urology* 2005; 65: 1099-1103.
- [32] Duckett JR, Constantine G. Complications of silicone sling insertion for stress urinary incontinence. *J Urol* 2000; 163: 1835-1837.
- [33] Yamada BS, Govier FE, Stefanovic KB, et al. High rate of vaginal erosions associated with the mentor ObTape. *J Urol* 2006; 176: 651-654.
- [34] Padilla-Fernández B, Begoña García-Cenador M, Gómez-García A, Mirón-Canelo JA, Gil-Vicente A, Silva-Abuín JM, Lorenzo-Gómez MF. Results of the surgical correction of urinary stress incontinence according to the type of transobturator tape utilized. *Archives of Italian Urology and Andrology* 2013; 85(3): 149-153.
- [35] Lee SY, Lee YS, Lee HN, Choo MS, Lee JG, Kim HG, Woo JK, Lee KS. Transobturator adjustable tape for severe stress urinary incontinence and stress urinary incontinence with voiding dysfunction. *Int Urogynecol J* 2011; 22: 341-346.
- [36] Oh TH, Shin JH, Na YG. A comparison of the clinical efficacy of the transobturator adjustable tape (TOA) and transobturator tape (TOT) for treating female stress urinary incontinence with intrinsic sphincter deficiency: short-term results. *Korean J Urol* 2012; 53: 98-103.
- [37] Patrelli TS, Gizzo S, Noventa M, Dall'Asta A, Musaro A, Faioli R, et al. Female stress urinary incontinence: clinical efficacy and satisfaction after transobturator adjustable tape sling: an observational longitudinal cohort study. *Surg Innov* 2015; 22: 137-142.
- [38] Dias J, Xambre L, Costa L, Costa P, Ferraz L. Short-term outcomes of Altis single-incision procedure for stress urinary incontinence: a prospective single-center study. *Int Urogynecol J* 2014; 25: 1089-1095.
- [39] Kocjancic E, Tu L, Erickson T, Gheiler E, Drie DV. The safety and efficacy of a new adjustable single incision sling for female stress urinary incontinence. *J Urol* 2014; 192: 1477-1482.
- [40] Hubka P, Nanka O, Martan A, Svabik K, El-Haddad R, Masata J. Fixation of the Ajust minisling based upon cadaveric study. *Int Urogynecol J* 2013; 24: 2119- 2123.
- [41] Meschia M, Barbacini P, Baccichet R, Buanoguidi A, Maffiolini M, Ricci L, Braghin C, Brusati V, Dell'Utri C, Spreafico L. Short-term outcomes with the Ajust™ system: a new single incision sling for the treatment of stress urinary incontinence. *Int Urogynecol J* 2011; 22: 177-182.
- [42] Liapis A, Georgantopoulou C, Bakas P, et al. Short term results of the Ajust adjustable single incision sling procedure for the treatment of urodynamic stress urinary incontinence. *Int J Urogynaecol* 2010; 2(Suppl 1): 778.

- [43] Lucente V , Cornu J , Sèbe P , Peyrat L, Ciofu C, Haab F. Ajust single incision transobturator sling procedure for stress urinary incontinence in women: one year results. *Int J Urogynaecol* 2010; 2(Suppl 1): 775.
- [44] Abdel-Fattah M, Agur W, Abdel-All M, Guerrero K, Allam M, Mackintosh A, et al. Prospective multi-centre study of adjustable single-incision mini-sling (Ajust) in the management of stress urinary incontinence in women: 1-year follow-up study. *BJU Int* 2012; 109: 880-886.
- [45] Naumann G, Hagemeyer T, Zachmann S, Aktham A, Albrich S, Skala C, et al. Long-term outcomes of the Ajust adjustable single-incision sling for the treatment of stress urinary incontinence. *Int Urogynecol J* 2013; 24: 231-239.
- [46] Grigoriadis C, Bakas P, Derpapas A, Creatsa M, Liapis A. Tension-free vaginal tape-obturator versus Ajust adjustable single incision sling procedure in women with urodynamic stress urinary incontinence. *Eur J Obstet Gynecol Reprod Biol* 2013; 170: 563-566.
- [47] Boyers D, Kilonzo M, Mostafa A, Abdel-Fattah M. Comparison of an adjustable anchored single-incision minisling, Ajust<sup>®</sup>, with a standard midurethral sling, TVT-O<sup>™</sup>: a health economic evaluation. *BJU Int* 2013; 112: 1169-1177.
- [48] Xin X, Song Y, Xia Z. A comparison between adjustable single-incision sling and tension-free vaginal tape-obturator in treating stress urinary incontinence. *Arch Gynecol Obstet* 2016; 293: 457-463.
- [49] Natale F, Dati S, La Penna C, Rombola P, Capello S, Piccione E. Single incision sling (Ajust) for the treatment of female stress urinary incontinence: 2 year follow-up. *Eur J Obstet Gynecol Reprod Biol* 2014; 182: 48-52.
- [50] Zhang P, Fan B, Zhang P, Han H, Xu Y, Wang B, et al. Meta-analysis of female stress urinary incontinence treatments with adjustable single incision minislings and transobturator tension-free vaginal tape surgeries. *BMC Urol* 2015; 15: 64.

