

We are IntechOpen, the world's leading publisher of Open Access books Built by scientists, for scientists

4,800

Open access books available

122,000

International authors and editors

135M

Downloads

Our authors are among the

154

Countries delivered to

TOP 1%

most cited scientists

12.2%

Contributors from top 500 universities



WEB OF SCIENCE™

Selection of our books indexed in the Book Citation Index
in Web of Science™ Core Collection (BKCI)

Interested in publishing with us?
Contact book.department@intechopen.com

Numbers displayed above are based on latest data collected.
For more information visit www.intechopen.com



Regional Anesthesia: Advantages of Combined Use with General Anesthesia and Useful Tips for Improving Nerve Block Technique with Ultrasound Technology

Masahiko Tsuchiya

Additional information is available at the end of the chapter

<http://dx.doi.org/10.5772/66573>

Abstract

Regional anesthesia is not always performed independently, but rather is frequently employed as part of a general anesthesia technique. Thus, its procedures and usefulness should be considered in settings where general anesthesia is used. In this chapter, new perspectives regarding the interaction of regional and general anesthesia are presented, as well as novel tips for improving nerve block techniques during the course of general anesthesia. Regional anesthetics inhibit superoxide generation of neutrophils by inhibition of protein kinase C activity and also have potent antioxidant activities, while inhalation general anesthetics have contrasting effects. Therefore, it is considered that regional anesthetics are able to compensate for shortcomings of inhalation general anesthetics by reducing surgical oxidative stress. In clinical settings, combined use of regional with general anesthesia provides better intraoperative hemodynamics than general anesthesia alone, particularly in high-risk patients affected by severe cardiovascular disease. To further improve the analgesic potency and duration of regional anesthesia, especially in cases in which a peripheral nerve block is performed, addition of low molecular weight dextran as an adjuvant to the local anesthetic solution is quite effective. Furthermore, recent advancements in ultrasound technology have made previously difficult regional anesthesia techniques easier and safer to achieve. A typical example is use of a caudal block in adults, which is quite difficult with a conventional method. Expanding its indication to adults is beneficial, especially for high-risk patients undergoing surgery in the lower abdomen. Furthermore, proper in-line positioning of ultrasound images is key for successful and easy completion of ultrasound-guided procedures, such as needle insertion to the target. We have been able to establish such a positioning method by use of an iPad and the VT-100 image transfer system (Scalar Co., Tokyo, Japan). Following consideration of the present findings and related experience, it is evident that performance of regional anesthesia under general anesthesia provides great advantages, including better and safe anesthesia management.

Keywords: regional anesthesia, antioxidant activity, neutrophils, AAPH, Phycocerythrin, protein kinase C, ultrasound-guided nerve block, transversus abdominis plane block, intraoperative hemodynamics, caudal block, adjuvant, low molecular weight dextran, iPad, wireless image transmission, image position, radial artery catheterization

1. Introduction

With recent advancements in ultrasound technology, nerve block procedures have become easier and their accuracy improved [1, 2]. As a result, many regional anesthetic methods and techniques previously overlooked have been reevaluated, which has led to recent increased interest among anesthesiologists, with large numbers of papers and textbooks concerning regional anesthesia published during the past 10 years. However, the interrelationship between regional and general anesthesia has not been well-elucidated. Regional anesthesia is not always performed as an independent procedure in daily practice; rather it is frequently included as part of a general anesthesia technique, thus a full understanding of its effects is important to evaluate usefulness in settings where general anesthesia is employed. In the present chapter, new perspectives regarding the interaction of regional anesthesia with general anesthesia as well as the use of ultrasound technology are discussed based on findings obtained by our research team. Discussions regarding the antioxidant activities of local anesthetics and their effects for stabilizing the hemodynamics of patients under general anesthesia, the best adjuvants for local anesthetics used for regional nerve block, a simple but important tip for improving the accuracy and easiness of ultrasound-guided procedures, and other related topics are included.

2. Oxidative stress associated with surgery and inhalation anesthetics

Although the possibility that surgery increases oxidative stress has been suggested for several years [3, 4], how it develops remains unclear, especially during surgery. Analysis of intraoperative changes in the ferric-reducing ability of plasma may lead to a breakthrough for elucidation of surgical oxidative stress, as the reduction of ferric ions to ferrous ions in plasma is a simple but sensitive indicator of the antioxidant potential of blood in clinical settings [5]. These changes can be measured by use of a biological antioxidant power (BAP) test with an FRAS 4 analyzer (Wismerll Co. Ltd. Tokyo, Japan), which is based on color changes of a solution containing a source of ferric ions adequately bound to a special chromogenic substrate at 505 nm when the ferric ions are reduced to ferrous ions according to antioxidant activity induced by addition of plasma.

Using this unique method, adult patients with ASA I-II who underwent an open colectomy with sevoflurane anesthesia along with fentanyl and vecuronium were investigated. During surgery, the ferric reducing ability was significantly lowered, indicating that the colectomy procedure increased oxidative stress resulting in a reduction in the antioxidant ability of blood (**Figure 1**). To the best of our knowledge, these are the first reported findings to clearly demonstrate that surgery increases oxidative stress.

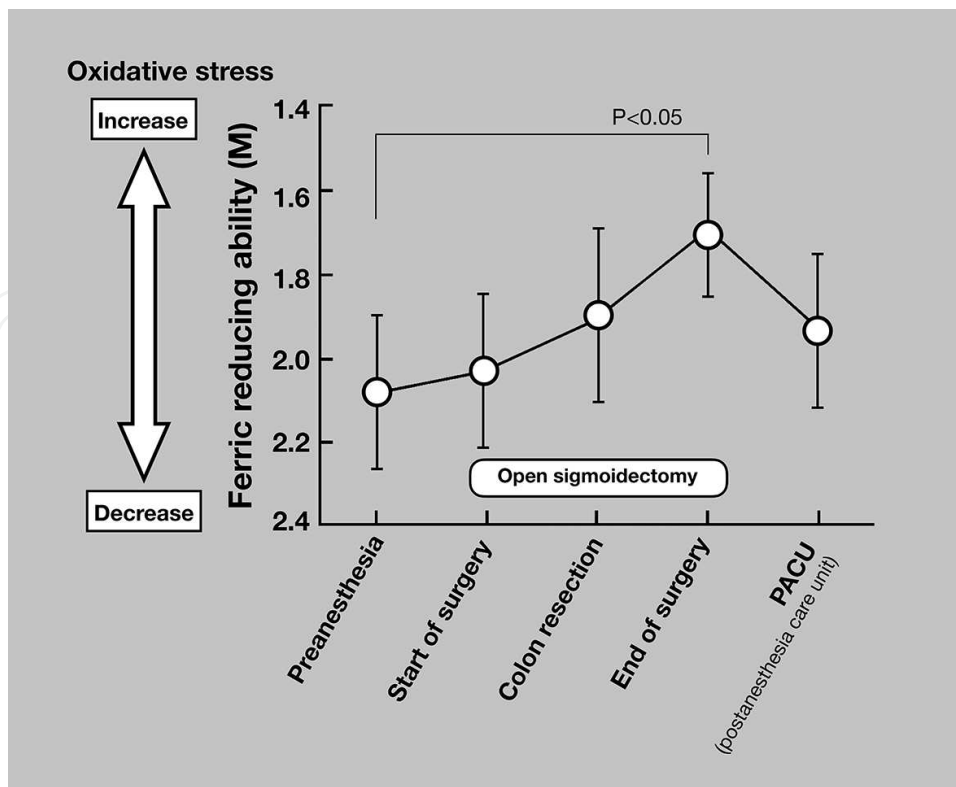


Figure 1. Plasma ferric-reducing ability in 18 patients who underwent an open sigmoidectomy with sevoflurane anesthesia. Lower values indicate increased oxidative stress; thus, our findings demonstrated that surgery increases oxidative stress.

Oxidative stress may also be a key factor to determine patient surgical stress [5], and we investigated this issue in cases of cardiac surgery [6]. Preoperative oxidative stress was determined by measuring plasma hydroperoxide values using a d-Rom test with an FRAS 4 analyzer, while the occurrence of major organ morbidity and mortality (MOMM) was also assessed. MOMM included death, deep sternal infection, reoperation, stroke, renal failure requiring hemodialysis, and prolonged ventilation (>48 h). Our results showed that an elevated preoperative hydroperoxide level in cardiac surgery patients is an independent risk factor for severe postoperative complications, and its reliability to predict postoperative complications appeared to be better as compared to preoperative BNP values and the European system for cardiac operative risk evaluation (EuroSCORE). The optimal threshold value of hydroperoxide concentration to differentiate between patients with and without MOMM was found to be 450 UCarr (sensitivity, 87.0%; specificity, 81.9%). These findings indicated that preoperative oxidative stress is an important risk factor for postoperative complications. In addition, they suggested the therapeutic potential of antioxidant therapy in surgical patients, as antioxidant control may reduce surgical stress, thereby improving postoperative recovery.

On the other hand, the drug used for inhalation anesthesia also has an oxidant effect. We studied the effects of inhalation anesthetics on protein kinase C (PKC) activity, which has been implicated

in regulation of cell secretion, modulation of membrane conductance, release of neurotransmitters, regulation of cytoplasmic Ca^{2+} , functional modification of receptors, and other components of the signal transduction machinery [7–9]. As for neutrophils, the ability of PKC activators such as TPA to trigger superoxide generation suggests a role for protein phosphorylation in the mechanism of transmembrane signaling. In addition, purified PKC stimulates superoxide generation by the particulate fraction of neutrophils. Thus, activation of PKC is involved in the process of superoxide generation of neutrophils [10, 11]. Using partially purified PKC from rat brains, we found that halothane, a typical inhalation anesthetic [12], activated this enzyme and increased superoxide generation from neutrophils (**Figure 2**). Furthermore, other inhalation anesthetics have been reported to activate PKC in a similar manner according to their anesthetic potency (**Figure 3**) [7–9]. H-7, a specific inhibitor of PKC, totally inhibited halothane-induced PKC activation (**Figure 4**) and superoxide generation of neutrophils (**Figure 2**), confirming that the reaction developed via activation of PKC [9]. In addition to the findings in blood cells, it has been reported that sevoflurane, another typical inhalation anesthetic, increases the generation of reactive oxygen species (ROS) in isolated hearts [13]. Together, these findings strongly suggest negative effects of inhalation general anesthetics including an increase in oxidative stress in surgical patients.

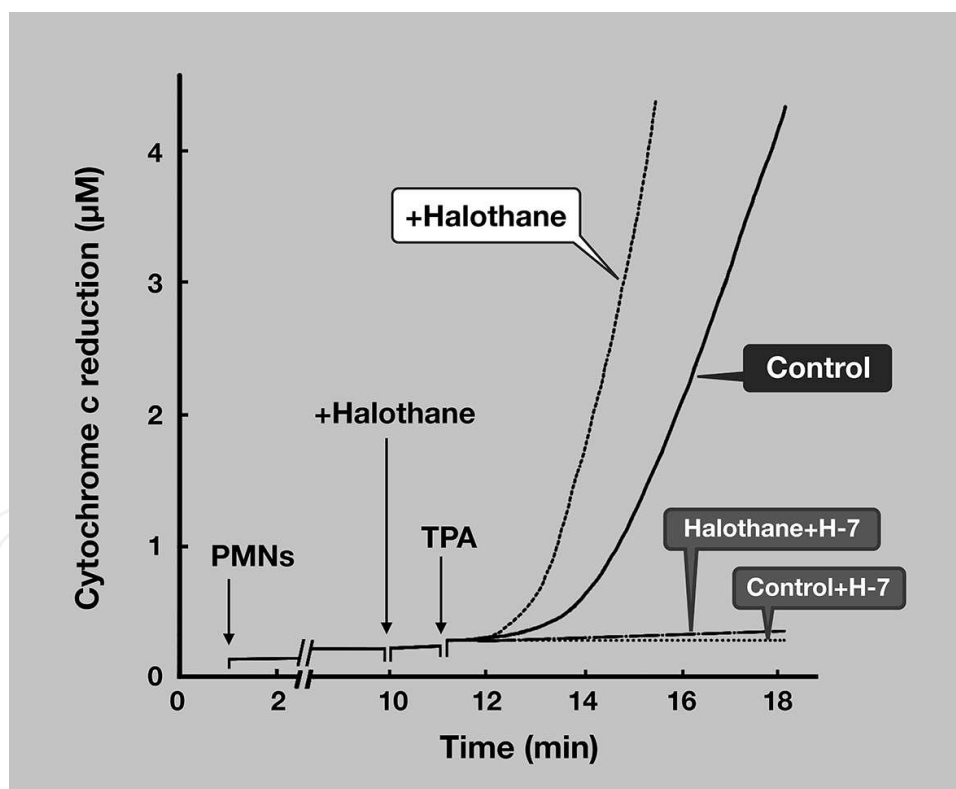


Figure 2. Effects of halothane and H-7 (1-(5-isoquinolinesulfonyl) methylpiperazine dihydrochloride) on superoxide generation by neutrophils. Superoxide generation was spectrophotometrically analyzed by measuring the reduction of cytochrome c at 550 nm with a reference wavelength of 540 nm. Neutrophils were obtained from a guinea pig using a method previously described [10], then 2×10^6 cells·ml⁻¹ were incubated in KRP (Krebs-Ringer phosphate solution) medium containing 1 mM Ca^{2+} , 10 mM glucose, 25 μM cytochrome c, and 0.1 mM NaN_3 at 37°C. The concentrations of halothane, TPA (12-O-tetradecanoylphorbol-13-acetate), and H-7 were 0.59 mM, 0.4 nM, and 100 μM , respectively. Halothane activated superoxide generation by neutrophils, whereas H-7, a specific inhibitor of protein kinase c, inhibited that activation.

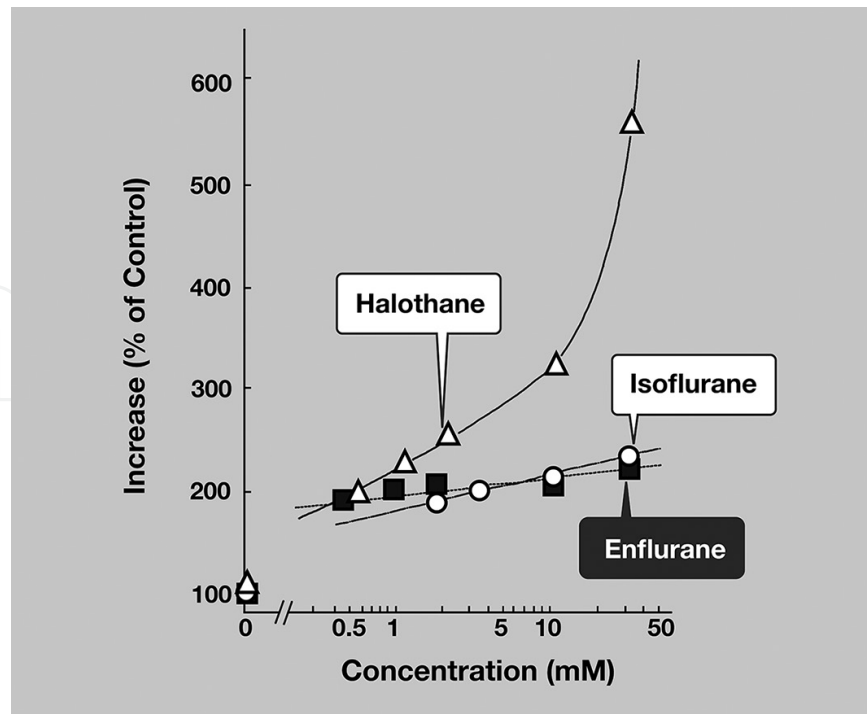


Figure 3. Effects of inhalation anesthetics on PKC (protein kinase C) activity. Enzyme activity was assayed by determining the incorporation of ^{32}P from $[\gamma\text{-}^{32}\text{P}]\text{ATP}$ into calf thymus H1 histone (type III-S) at 30°C over a period of 3 min in the presence of $1\ \mu\text{M}\ \text{Ca}^{2+}$, $1\ \text{mM}\ \text{EGTA}$, and $100\ \mu\text{M}$ phospholipid (phosphatidylcholine (PC)/phosphatidylserine (PS) (4:1 molar ratio) with various concentrations of inhalation anesthetics (halothane, enflurane, isoflurane). PKC was obtained from cerebral tissues of male Wistar/Slc rats and purified, using a previously described method [10]. Each of the examined inhalation anesthetics increased PKC activity in a dose-dependent manner.

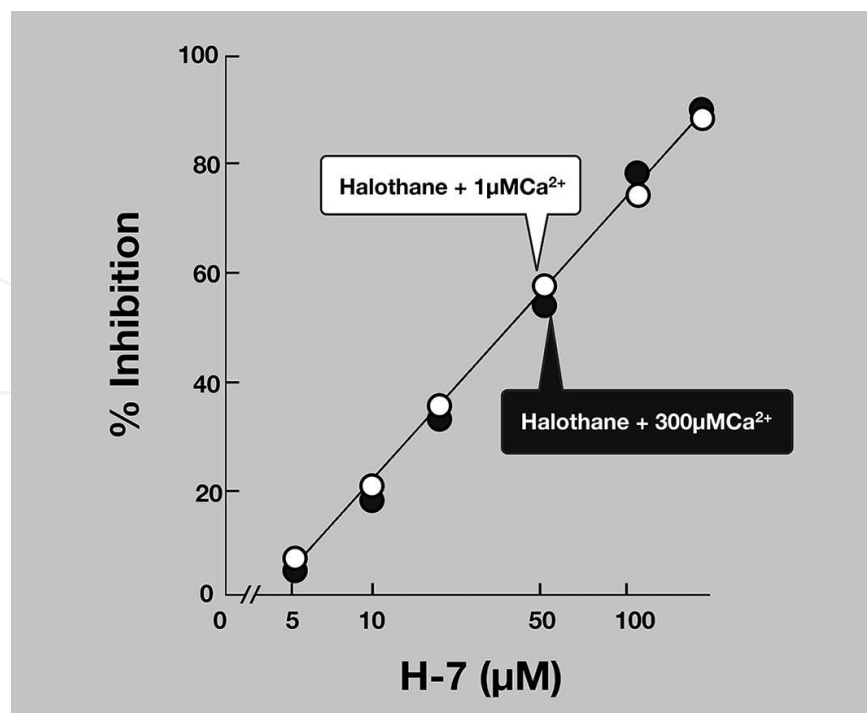


Figure 4. Effects of H-7, specific inhibitor of PKC, on halothane-activated PKC activity in the presence of low ($1\ \mu\text{M}$) and high ($0.3\ \text{mM}$) concentrations of Ca^{2+} . The concentration of halothane was $20\ \text{mM}$, whereas the other experimental conditions were the same as described in **Figure 3**. H-7 inhibited halothane-activated PKC activity in a dose-dependent manner.

3. Calming effect of local anesthetics on neutrophils

In contrast to general inhalation anesthetics, lidocaine has been found to inhibit protein kinase C in a manner competitive with phosphatidylserine as well as phosphorylation of the 47-kDa neutrophil cytoplasmic protein [11, 14, 15]. Thus, various stimulation-coupled responses of neutrophils, such as superoxide generation (**Figure 5**), depolarization of membrane potential (**Figure 6**), and transitional increase in intracellular Ca^{2+} (**Figure 7**), are suppressed by lidocaine. Other local anesthetics have also been shown to inhibit protein kinase C activity [15] and induce the same effects (**Figure 8**). These findings indicate that local anesthetics have unique calming effects on neutrophils as compared with inhalation anesthetics, which may reduce oxidative stress.

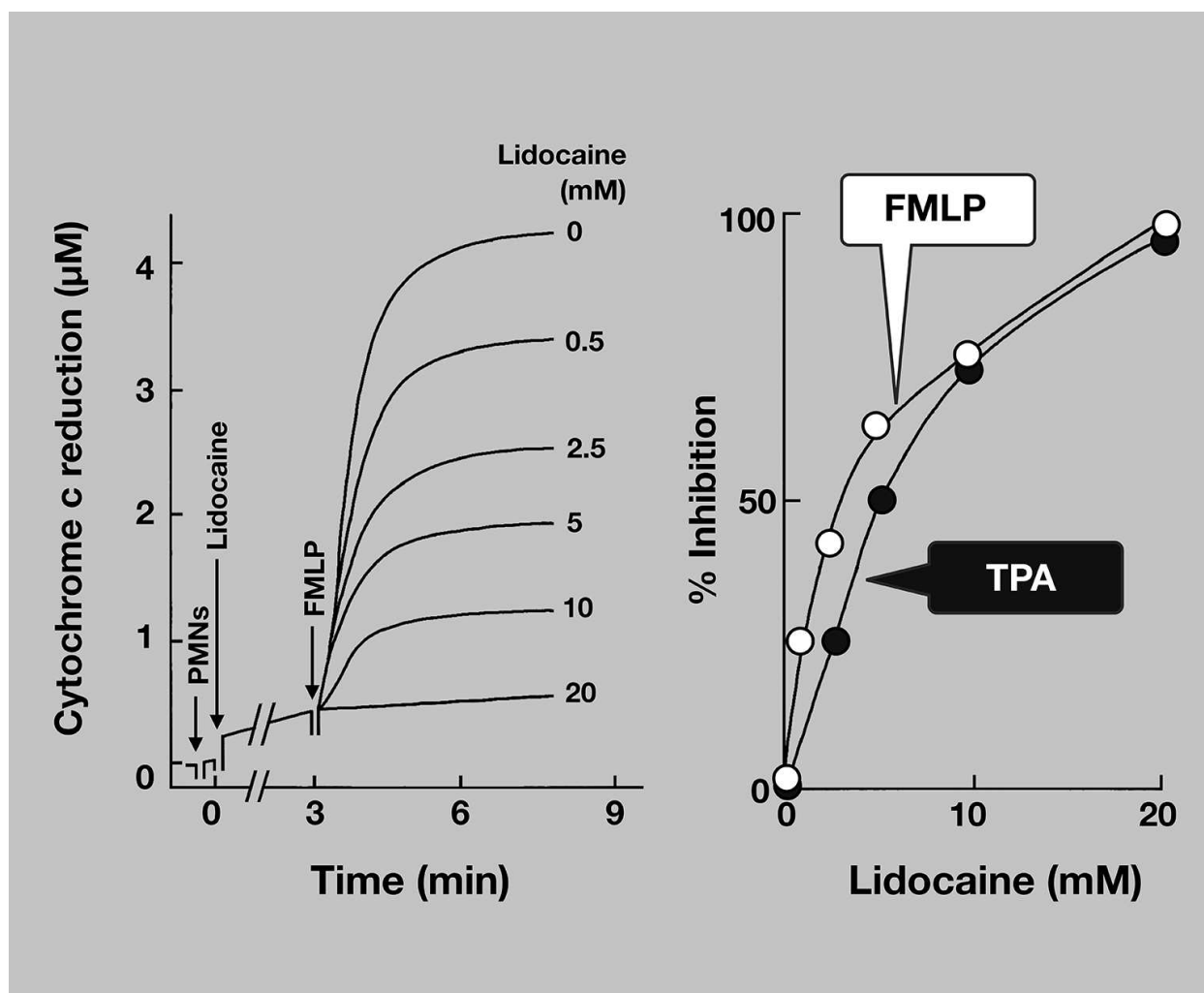


Figure 5. Effects of lidocaine on superoxide generation by neutrophils. Neutrophils were obtained from a guinea pig and suspended (1×10^6 cells·ml⁻¹) in KRP medium containing 10 mM glucose, 1.5 mM NaN_3 , 1 mM Ca^{2+} , and 25 μM cytochrome c. After pre-incubation for 3 min at 37°C with various concentrations of lidocaine (0–20 mM), 100 nM FMLP (formyl-methionyl-leucyl-phenylalanine) or 0.5 nM TPA (12-O-tetradecanoylphorbol-13-acetate) was added. Superoxide generation by neutrophils was analyzed by determining the reduction of cytochrome c, which was measured at 550 nm with a reference wavelength of 540 nm. *Left panel:* Time course of cytochrome c reduction induced by FMLP-stimulated neutrophils. *Right panel:* Percent inhibition of reduction of cytochrome c in FMLP or TPA-stimulated neutrophils by lidocaine. These results indicated that lidocaine strongly inhibited superoxide generation in neutrophils stimulated by treatment with TPA or FMLP in a dose-dependent manner.

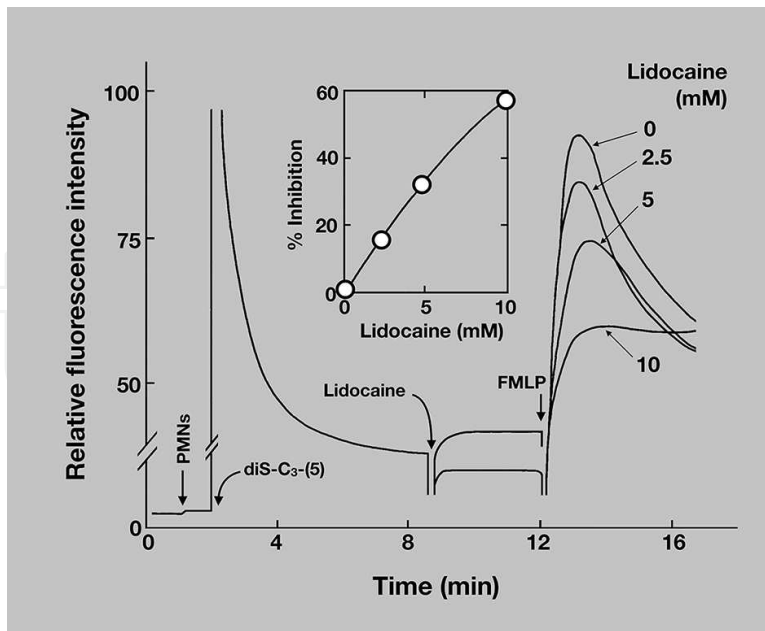


Figure 6. Effects of lidocaine on membrane potential in neutrophils. We used a cyanine dye method with diS-C3-(5). Neutrophils (1×10^6 cells·ml⁻¹) were obtained from a guinea pig and suspended in KRP medium containing 10 mM glucose, 1 mM Ca²⁺, and 5 μ M diS-C3-(5) at 37°C. After pre-incubation for 3 min with various concentrations of lidocaine, 100 nM FMLP was added. Changes in the fluorescence intensity of diS-C3-(5) were monitored at 670 nm after the dye had been excited at 622 nm. Downward deflections in the trace indicate uptake of diS-C3-(5) by the cells corresponding to hyperpolarization of the membrane potential. The inserted curved line graph indicates percent inhibition of fluorescence change by addition of lidocaine. Values were obtained by comparisons of peak values. These results indicated that lidocaine inhibited the membrane depolarization of neutrophils induced by FMLP, which was accompanied by superoxide generation.

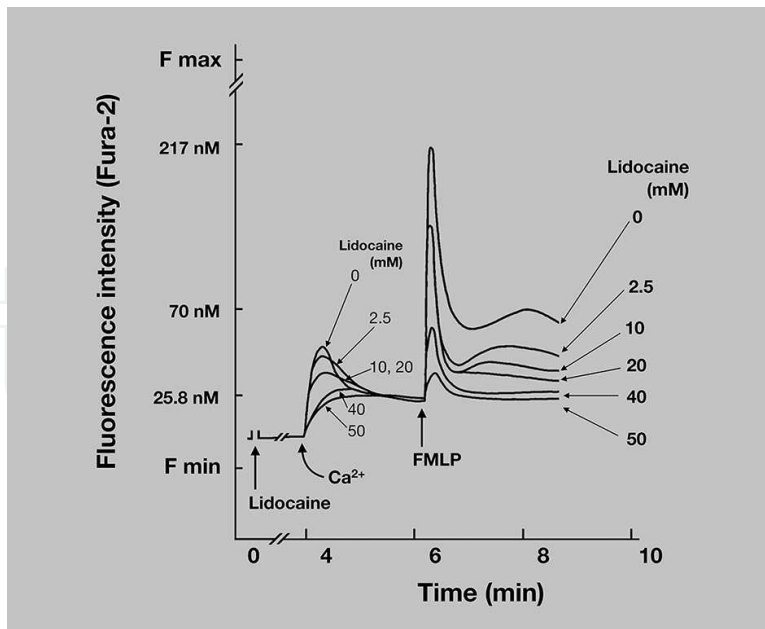


Figure 7. The effects of lidocaine on intracellular Ca²⁺ concentration. [Ca²⁺]_i in neutrophils was analyzed by determining the fluorescence intensity of Fura-2, a fluorescent indicator of intracellular calcium. Neutrophils were obtained from a guinea pig and suspended (1×10^6 cells·ml⁻¹) in Ca²⁺-free KRP medium, then Fura-2 was added. Neutrophils were pre-incubated for 3 min with various concentrations of lidocaine at 37°C, then incubated with 1 mM Ca²⁺ for 2 min before addition of 50 nM FMLP. [Ca²⁺]_i was calculated based on the change in fluorescence intensity of Fura-2. A change in intensity indicated that lidocaine inhibited the increase in intracellular Ca²⁺ during the course of neutrophil activation.

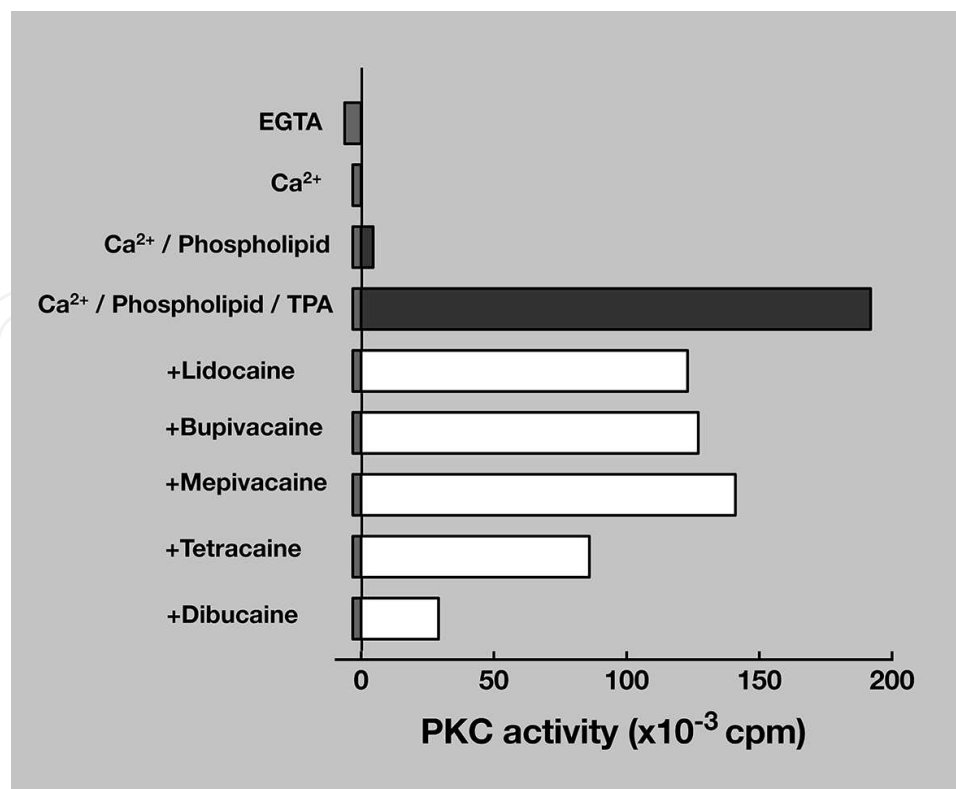
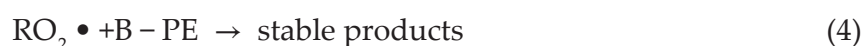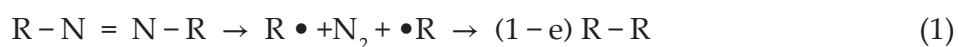

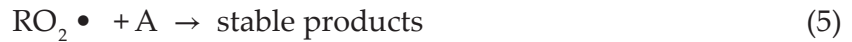
Figure 8. Effects of lidocaine and other local anesthetics on PKC activity in rat brain. PKC was obtained from a rat brain and purified using a method previously described [10]. Enzyme activity was assessed by measuring the incorporation of ³²P from [γ -³²P]ATP into H1 histone (type IIIs) at 30°C for 3 min. The medium contained 20 mM Tris-HCl (pH 7.5), 10 mM magnesium acetate, 0.2 mg·ml⁻¹ histone, and 1 μ M Ca²⁺. The amounts of phospholipid (phosphatidylserine (PS)/dipalmitoylphosphatidylcholine (DPPC), 1:4 molar ratio), TPA, and local anesthetics used were 100 μ M, 100 nM and 0.5 mM, respectively. These results indicated that lidocaine and other local anesthetics inhibited PKC activity, with dibucaine shown to be the most potent inhibitor.

4. Novel method for determining antioxidant activity of medical agents

We developed a phycoerythrin fluorescence-based assay to determine the antioxidant activity of various medical agents including local anesthetics [3, 16, 17]. This assay system consists of B-phycoerythrin (B-PE) as a fluorescence molecule to show oxidative stress and 2,2'-azobis (2-amidinopropane) dihydrochloride (AAPH) as a hydrophilic oxidative stress simulator, which continuously generates peroxy radicals at a constant rate, making it possible to easily evaluate the antioxidant activities of various medical agents [18]. Since the system is based on protein oxidation by peroxy radicals, it is considered to be a model of in vivo ROS reactions. The detailed reactions of B-PE with AAPH can be illustrated as follows.





The structure of AAPH [$\text{HCl} \cdot \text{NH}=\text{C}(\text{NH}_2)-\text{C}(\text{CH}_3)_2-\text{N}=\text{N}-\text{C}(\text{CH}_3)_2-\text{C}(\text{NH}_2)=\text{NH} \cdot \text{HCl}$] is represented by "R-N=N-R", where "e" represents the efficiency of free radical generation and "A" is an antioxidant. AAPH undergoes thermal decomposition to yield free radicals (reaction (2)), which rapidly react with oxygen molecules nearby to produce peroxy radicals (reaction (3)). With this assay, peroxy radicals may attack B-PE, resulting in fluorescence decay (reaction (4)), which, if successful, may be scavenged by an antioxidant (reaction (5)).

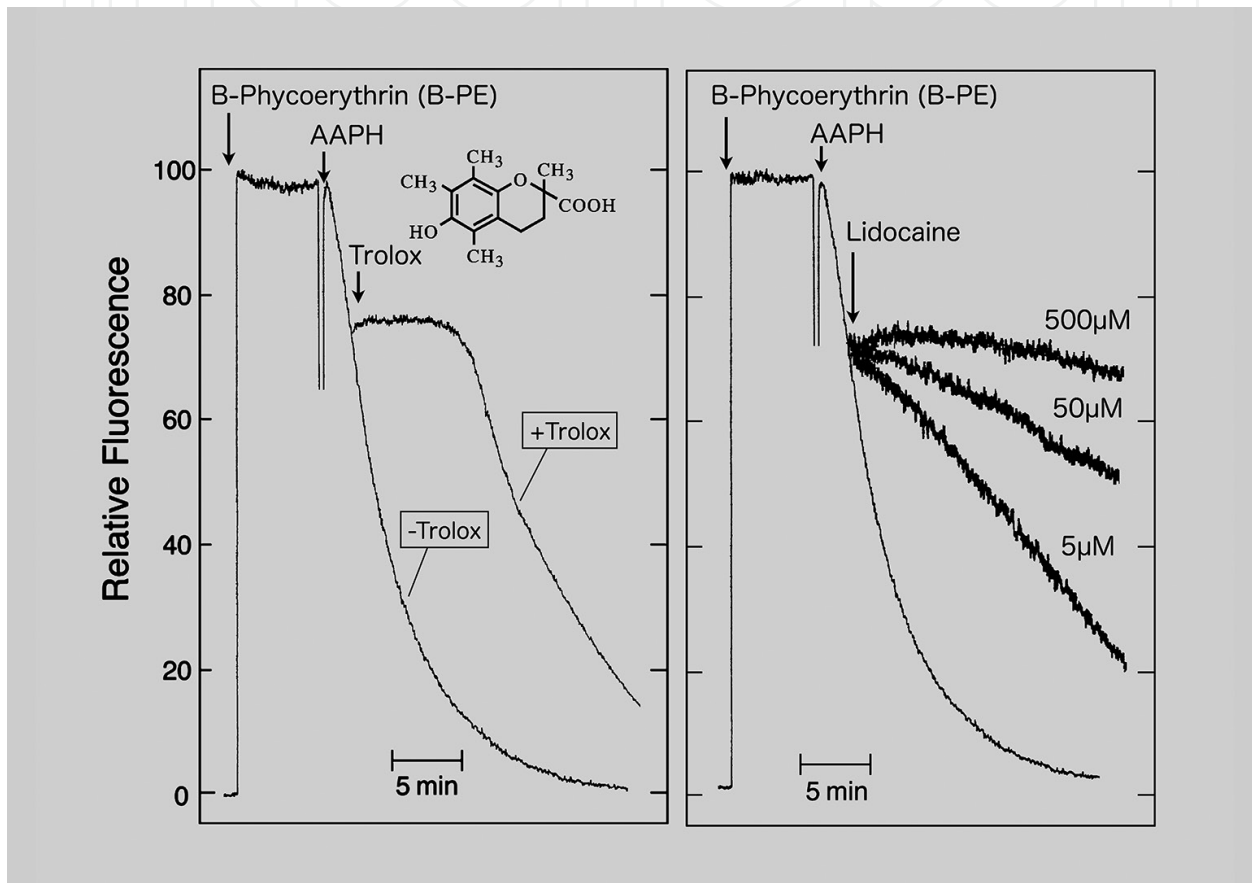


Figure 9. *Left panel:* Typical decay of fluorescence of B-PE (B-phycoerythrin) with AAPH (2,2'-azobis (2-amidinopropane) dihydrochloride) in Tris-HCl buffer (pH 7.4) at 38°C in the absence and presence of Trolox. The amounts of B-PE, AAPH, Trolox, and Tris-HCl buffer used were 1.78 nM, 6.25 mM, 4 μM, and 40 mM, respectively. The fluorescence excitation and emission wavelength were 545 nm (3-nm slit) and 575 nm (5-nm slit), respectively. Exposure of B-PE to peroxy radicals generated by AAPH led to a decrease in B-PE fluorescence. This peroxidation process was efficiently inhibited by addition of Trolox, which has potent antioxidant activity. The characteristic features of this assay offer great advantages for determining the possible antioxidant activity of various compounds when added to the reaction mixture. *Right panel:* Effects of lidocaine on B-PE fluorescence decay. Although lidocaine did not completely abrogate the fluorescence decay of B-PE, it reduced the rate of decay in a dose-dependent manner. This finding indicated that lidocaine has an antioxidant function, though its potency is not as strong as that of Trolox.

The rate of peroxy radical generation, R , from AAPH at a constant temperature is shown by Eq. (6) [19]:

$$R = K \times [AAPH] \quad (6)$$

where K is the rate constant for radical generation from AAPH and $[AAPH]$ is the concentration of AAPH in M. The rate of radical generation is virtually constant during the first few hours of this assay [20], since the half-life of AAPH is approximately 175 h in neutral pH water at 37°C [19]. The rate of peroxy radical generation at 38°C under the present assay conditions was $1.56 \times 10^{-6} \times [AAPH]$ ($M \cdot s^{-1}$) [3].

B-PE is a multisubunit protein extracted from the unicellular red alga, *Porphyridium cruentum* [16, 20]. Since it is easily oxidized, which decreases its fluorescence, B-PE functions as a reporting molecule of oxidative stress induced by peroxy radicals from AAPH. In addition, because of its very high extinction coefficient and fluorescence quantum yields, B-PE can be readily detected by fluorescence spectroscopy at concentrations as low as 10^{-12} M [20].

For this assay, the fluorescence decay of B-PE by the AAPH-generated peroxy radical was spectrophotometrically monitored at an excitation of 545 nm (3-nm slit) and emission of 575 nm (5-nm slit). The reaction mixture (2 ml) contained 1.78 nM B-PE and 6.25 mM AAPH in 40 mM Tris-HCl buffer (pH 7.4) at 38°C. Since the system is not closed, oxygen for the reactions is freely supplied from the atmosphere through the surface of the reaction mixture. As shown in **Figure 9**, B-PE fluorescence was linearly decreased by exposure to AAPH, which has a linear relationship with B-PE concentration. This peroxidative destruction of B-PE can be temporarily stopped by addition of a typical radical scavenger, such as Trolox.

5. Antioxidant activity of local anesthetics

We analyzed the antioxidant activity of lidocaine using this analysis system and the results showed that the rate of fluorescence decay was slowed in a concentration-dependent manner (**Figure 9**). The effect was evaluated by determining the percent inhibition against B-PE oxidation, an index used for the reactivity of peroxy radicals, in which 100% inhibition indicates the same level of fluorescence decay as that by Trolox and 0% inhibition indicates the same decay as that in the absence of the antioxidant. The dose-dependent effects of lidocaine are summarized in **Figure 10**, which indicates that lidocaine has potent antioxidant activity, while other local anesthetics such as mepivacaine showed similar but slightly weaker effects.

Combined with the findings of neutrophils, local anesthetics have effects to counter oxidative stress in a manner opposite of inhalation anesthetics, indicating that use of local anesthetics can reverse the deleterious effects of inhalation anesthetics. Thus, from the standpoint of oxidative stress management, anesthesia with a combination of local and general inhalation anesthetics provides better anesthesia management. The advantage of local anesthetics in oxidative stress management was also revealed in a study by Budic et al., who examined cases of pediatric extremity surgery using pneumatic tourniquets [21]. They measured generation of the oxidative products malondialdehyde and protein carbonyl groups in plasma and found that peripheral nerve block anesthesia did not increase the levels after tourniquet release as compared with general anesthesia with sevoflurane, which significantly increased those levels. These findings indicate that regional anesthesia provides an antioxidant defense that is superior to that of general inhalation anesthesia.

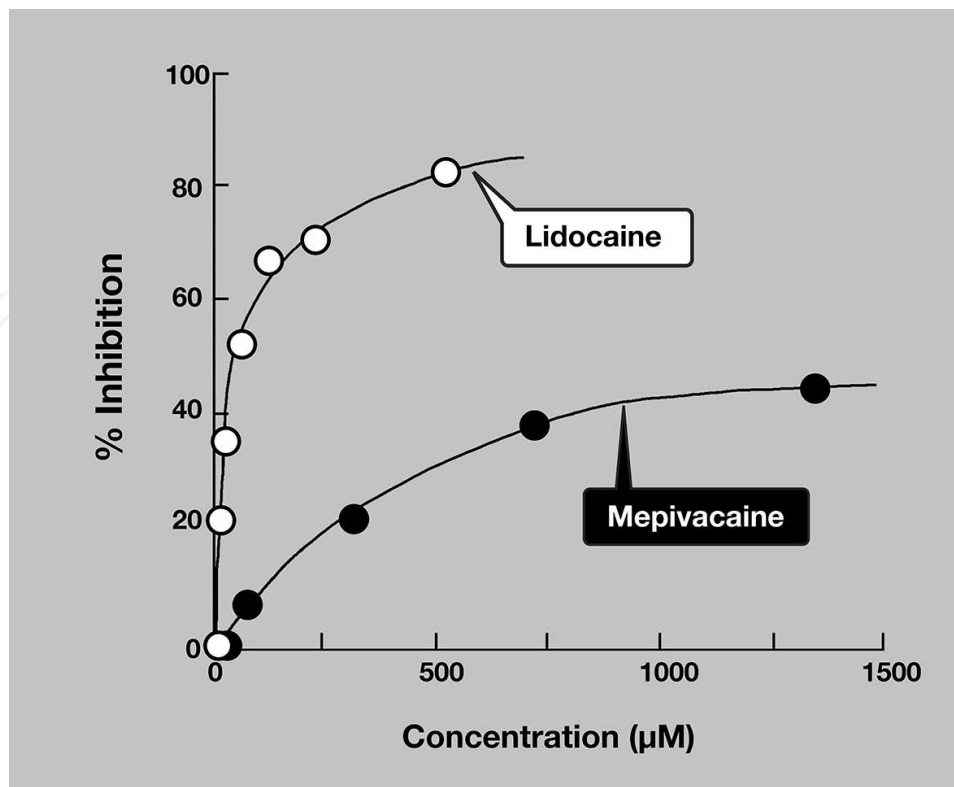


Figure 10. Dose-dependent effects of lidocaine and mepivacaine on B-PE fluorescence decay in the antioxidant assay system shown in **Figure 9**. These results indicated that both local anesthetics have a potent antioxidant activity.

6. Better intraoperative hemodynamic control by regional anesthesia

Regional anesthesia combined with general anesthesia provides not only better postoperative analgesia, but may also result in better intraoperative hemodynamic control than general anesthesia alone [22]. We demonstrated this advantage of regional anesthesia in an investigation of high-risk patients with severe cardiovascular disease classified as American Society of Anesthesiologists (ASA) physical status 3.

Patients undergoing elective open abdominal surgery were randomized into those receiving general anesthesia and a bilateral transversus abdominis plane block (TAPB) (Group T, $n = 33$), and those receiving general anesthesia alone (Group G, $n = 35$). The bilateral TAPB was performed after anesthesia induction using 40 ml of 0.3% ropivacaine, as shown in **Figure 11**. We compared the groups for intraoperative hemodynamic stability, anesthesia emergence time, amounts of anesthetics and opioids given, and frequency of emergency treatment with a cardiovascular agent. A hemodynamically stable period was defined as the time when systolic blood pressure and heart rate were 70–110% of their preanesthesia value. The ratio of hemodynamically stable time to total operative time was used as an index of hemodynamic stability.

Hemodynamically stable time was greater in Group T than Group G (**Figure 12**), while sevoflurane concentration, amount of fentanyl given, and frequency of vasopressor use were lower, and anesthesia emergence time was shorter in the Group T patients (**Figure 13**). These findings indicate that the combination of TAPB with general anesthesia promotes intraoperative

hemodynamic stability and early emergence from general anesthesia, while it also provides good postoperative analgesia. Furthermore, the advantageous effects obtained with TAPB may also be seen with use of other regional anesthetic protocols.

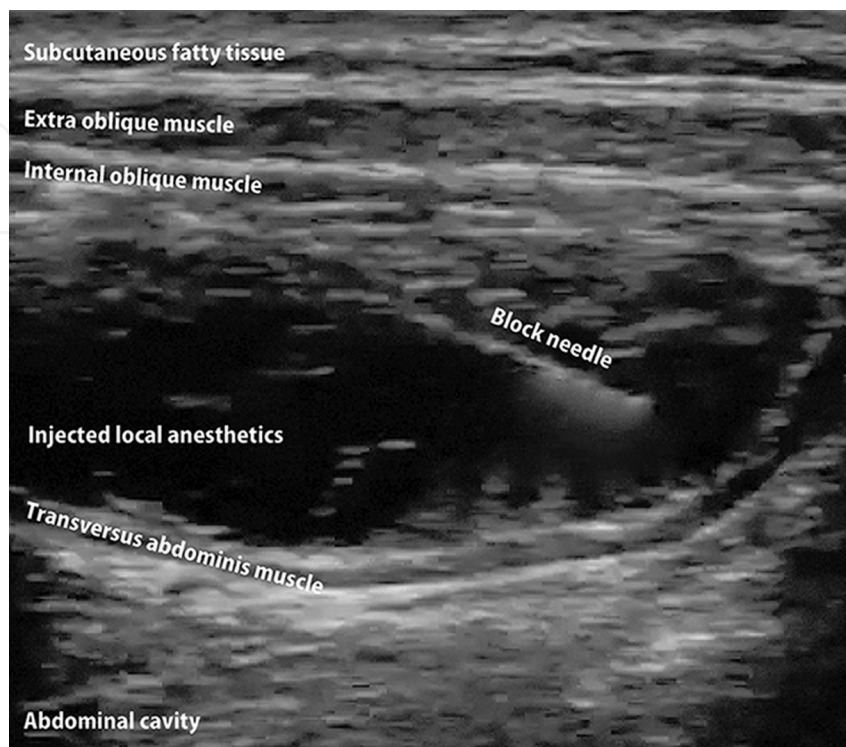


Figure 11. Ultrasound image of abdominal wall during transversus abdominis plane block (TAPB).

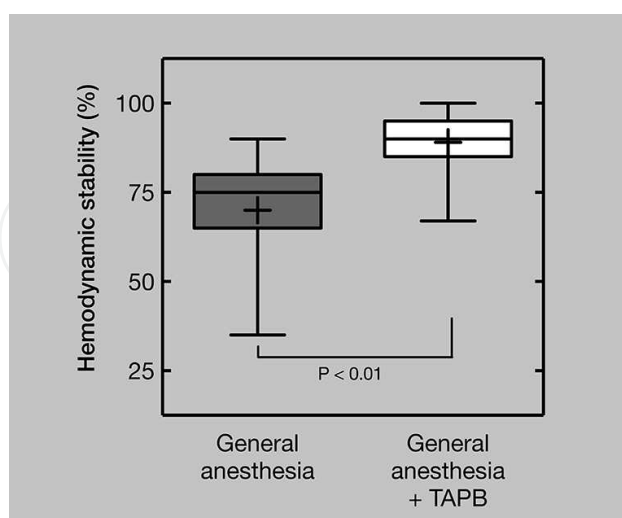


Figure 12. Box-plot for comparison of intraoperative hemodynamic stability between Group G (general anesthesia alone, $n = 35$) and Group T (general anesthesia plus TAPB, $n = 33$). The period during the operation when both systolic blood pressure and heart rate were within 70–110% of their pre-anesthesia value was defined as the hemodynamic stable time. The ratio of hemodynamic stable time to total operative time was used as an indicator of hemodynamic stability. The stability ratio was significantly higher in Group T (91%, range 50–100%) than in Group G (79, 40–91%), indicating greater hemodynamic stability in Group T. Values are presented as the median and minimum-maximum range.

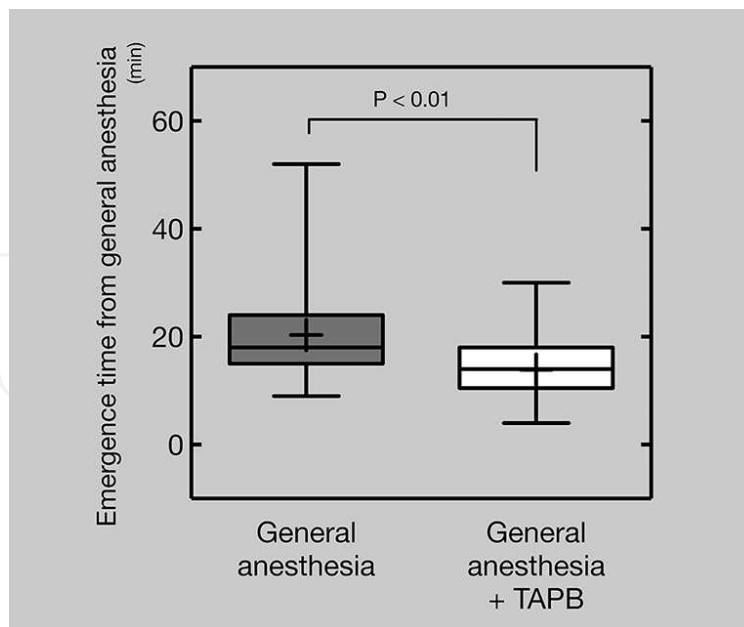


Figure 13. Box-plot for comparison of anesthesia emergence time between Group G (general anesthesia alone, $n = 35$) and Group T (general anesthesia plus TAPB, $n = 33$). Anesthesia emergence time was defined as the time from completion of surgery to extubation. That time was significantly shorter in Group T (14 min, range 4–30 min) than in Group G (18 min, 9–52 min). Values are presented as the median and minimum-maximum range.

It is important for anesthesiologists to offer effective anesthesia management for high-risk patients with severe cardiovascular disease [23], as they frequently require special treatment with a variety of expensive drugs and increased medical staffing. This combined regional and general anesthesia technique is simple and easy to perform, and its advantages include relief of the burden to the anesthesiologist and reduced medical costs for such high-risk cases, as well as improved patient safety.

7. Interim summary

Combined use of regional with general anesthesia is advantageous to decrease oxidative stress and also provides better intraoperative hemodynamics than general anesthesia alone. Namely, it compensates for the shortcomings of inhalation anesthetics and improves anesthesia management quality. Importantly, the hemodynamic stabilizing effects of regional anesthesia in high-risk patients provide a great advantage for the anesthesiologist to perform anesthesia management, even when additional efforts to perform regional anesthesia are required.

8. Addition of low-molecular weight dextran to local anesthetics: enhancement of analgesic effect and reduction of toxicity

Regional anesthesia, though useful, has some limitations. It is often performed as a single-shot procedure with a large dose of a local anesthetic drug, except for cases of epidural anesthesia, which is usually performed with insertion of a catheter for continuous administration. Therefore,

prolonging analgesia without toxicity is clinically important for most regional anesthesia procedures. Furthermore, when performed in combination with general anesthesia, a prolonged analgesia duration is required, because the period of postoperative analgesia is shortened depending on operation time. In light of these limitations and demands, studies aimed at improving the effects of local anesthetics have been performed, some of which have provided evidence showing that addition of low-molecular weight dextran (LMWD) to a local anesthetic and epinephrine mixture when given as infiltration anesthesia [24], or to a local anesthetic alone when performing a regional block [25] safely prolonged the effective action by reducing systemic absorption.

We demonstrated this favorable effect of LMWD as an adjuvant in patients being prepared for laparoscopic colon surgery, who received anesthesia with a combination of TAPB and rectus sheath block (RSB) using either 80 ml of 0.2% levobupivacaine in saline (control group, $n = 27$) or 80 ml of 0.2% levobupivacaine in 8% LMWD (LMWD group, $n = 27$). Following anesthesia induction, the combined block was performed under a double-blind condition. Levobupivacaine plasma concentration and postoperative analgesia were assessed using a numerical rating scale (NRS).

In the LMWD group, the time to reach the maximum plasma concentration of levobupivacaine (T_{max}) was longer (73 ± 25 vs. 51 ± 30 min, $P = 0.006$) and the maximum plasma concentration (C_{max}) was lower (1141 ± 287 vs. 1410 ± 322 ng·ml⁻¹, $P = 0.004$), as compared to the control group (Figure 14). The area under the plasma concentration-time curve (AUC) from 0 to

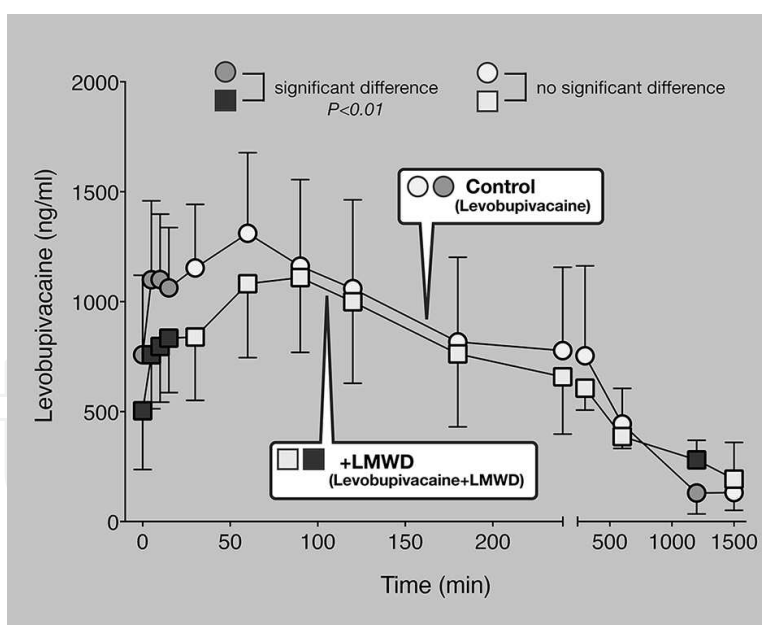


Figure 14. Changes in plasma concentration of levobupivacaine in patients receiving levobupivacaine at 160 mg (0.2%) in saline (control group, $n = 27$) or an 8% low-molecular weight dextran solution (LMWD group, $n = 27$) following a bilateral transversus abdominis block (TAPB) or rectus sheath block (RSB). Error bars show the SD and time 0 indicates completion of the nerve block procedure. In the control group, the plasma concentration of levobupivacaine quickly rose just after performing the nerve block. In the LMWD group, that rose in a more gradual manner with a lower maximum concentration. Subsequently, the plasma concentration of levobupivacaine gradually decreased in both groups, though a faster decline was seen in the control group. At 1200 min after performing the block, the plasma concentration of levobupivacaine was significantly higher in the LMWD group as compared to the control group.

240 min was also lower ($172,484 \pm 50,502$ vs. $229,124 \pm 87,254$ ng min·ml⁻¹, $P = 0.007$) in the LMWD group, while their NRS scores up to 24 h after surgery were reduced (**Figure 15**). Also, rescue treatment with IV flurbiprofen (50 mg) was utilized significantly less often in the LMWD group. No typical adverse effects, such as wound infection, delayed wound healing, tissue necrosis, or prolonged abnormal sensory disorder over the area of injection, were observed in either group. The lower C_{max} value was associated with reduced risk of levobupivacaine toxicity, while lower AUC indicated that the addition of LMWD reduced systemic absorption of levobupivacaine. Thus, those results indicated that addition of LMWD enhances analgesia for a longer duration along with decreased risk of local anesthetic toxicity.

However, the efficacy of dextrans including LMWD remains controversial, as several subsequent studies have reported an absence of any substantial difference in analgesic duration with their addition [26, 27]. These inconsistent findings related to the effects of dextrans may be due to differences in regional anesthesia techniques. Recent advances in ultrasound technology have greatly increased the accuracy of various types of nerve blocks, thus local anesthetics can be precisely injected into the target compartment or very near the target without complications in this modern era. Such improved accuracy may reveal the effects of dextrans not seen with classical techniques.

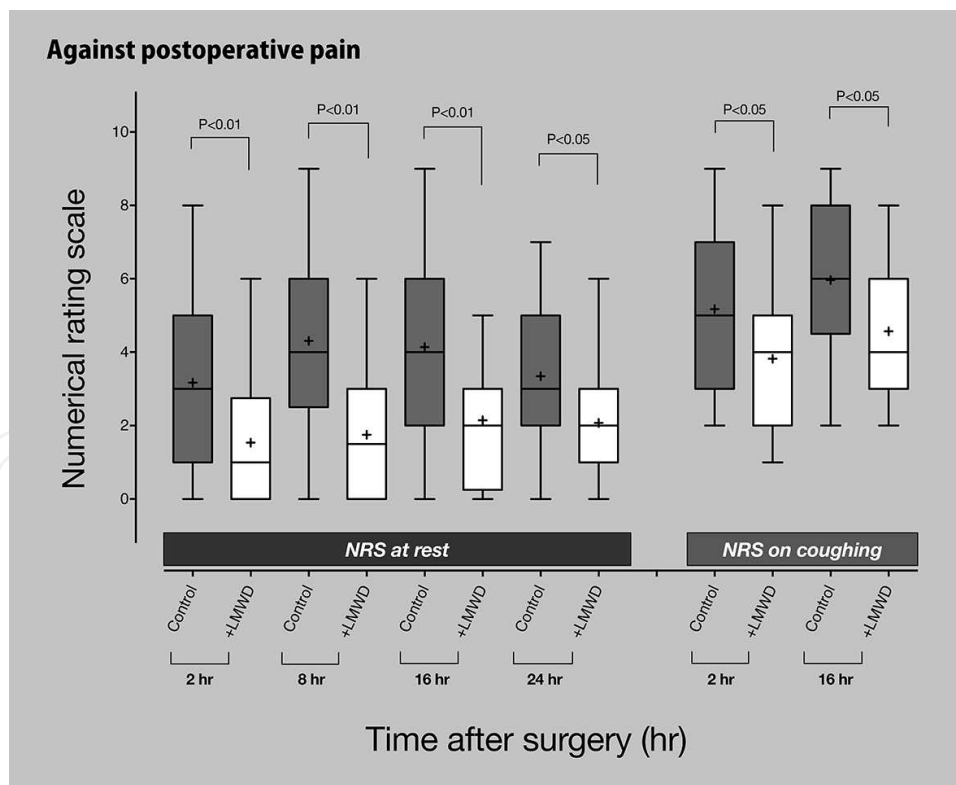


Figure 15. Box-plots for comparing postoperative pain between the control and LMWD groups at rest and during coughing using a numerical rating scale (NRS). Details of the nerve block procedures used in each group are described in the legend to **Figure 14**. NRS scores at both rest and during coughing at all time points up to 24 h after surgery were significantly lower in the LMWD group as compared to the control group.

Nevertheless, use of LMWD as a local anesthetic adjuvant has nearly been forgotten in recent years. We rediscovered its value with the aid of ultrasound technology and found that use of LMWD with a local anesthetic mixture is a good option to further improve the performance of TAPB or RSB, and likely other regional anesthesia procedures as well. Extension of the analgesia period to the next day after surgery by a simple single-shot approach is fully adequate for most surgery patients, making unnecessary the complicated procedure of inserting a catheter for continuous administration and subsequent management during the postoperative period. Thus, use of LMWD makes regional anesthesia more easily accessible to many anesthesiologists and may open a new horizon for them.

9. Novel clinical application of older mature nerve block technique by use of ultrasound technology: caudal block

Improvements in ultrasound technology have resulted in the return of some older mature nerve block techniques to clinical importance, as also seen with LMWD. One of those is caudal block. Since a high level of skill is required to safely perform an adequate caudal block in older adults, because of anatomical deformity of the sacrum associated with aging, it is rarely performed in elderly patients and generally believed to be a special nerve block technique for use in pediatric cases. However, ultrasound technology has made it much easier to safely perform a caudal block with high consistency in older patients [2].

We studied the clinical usefulness and availability of a caudal block for urinary catheter-induced bladder discomfort in adult patients, which is common in those who have undergone urinary catheterization during surgery. In some cases, the discomfort is severe, causing restlessness and agitation after emergence from anesthesia, with postoperative recovery sometimes disrupted due to the continual uneasiness. These adverse effects are more pronounced in middle-aged and elderly male patients due to anatomic considerations.

Muscarinic receptor antagonists, such as ketamine and gabapentin, have been shown to be effective for relieving postoperative bladder discomfort caused by a catheter. However, they may alter hemodynamics, leading to dry mouth or excessive sedation. In view of such unwanted side effects, these agents may not be best for treatment of bladder discomfort in all patients. Since caudal block anesthesia is used in the fields of urological and gynecological surgery, we speculated that ultrasound-guided single shot anesthesia by a caudal block would be a reliable and safe method for relief of urinary catheter-induced bladder discomfort.

We enrolled male patients (ASA I-II) older than 50 years who were scheduled for cervical spine surgery, and allocated them to either the caudal block (Group CB, $n = 22$) or non-block (Group NB, $n = 22$) group. Following induction of anesthesia, urinary catheterization was performed

using a 16-F Foley catheter. In Group CB, an ultrasound-guided single shot caudal block was additionally performed before the start of surgery using an 8-ml mixture of 0.3% ropivacaine and 100 µg of fentanyl. Group NB did not undergo a caudal block or receive any other drugs. Thereafter, spine surgery started. The severity of urinary catheter-related discomfort was assessed at 0 (just after arrival in the post-anesthesia care unit), then 2, 10, and 18 h after the operation.

Following are details of our method for ultrasound-guided caudal block. With the patient in a prone position, the location and structure of the sacral hiatus are confirmed on sonographic transverse and longitudinal images. Next, a 23-gauge block needle is inserted in the direction of the sacral canal through the sacral hiatus while monitoring real-time sonographic images (**Figure 16**), then the tip of the block needle is inserted into the sacral canal at least 1 cm ahead. After negative aspiration, a mixture of ropivacaine and fentanyl is injected. Injection of that mixture into epidural space is confirmed by ultrasound images showing that the block needle is properly inserted in the direction of the sacral canal through the sacral hiatus, while a small fraction of injection fluid in the depth of the sacral canal shows reverse spreading into the canal opening portion near the sacral hiatus.

All caudal block procedures in this study were guided by ultrasound and successfully performed without severe difficulties. Following surgery, the incidence rate of urinary catheter-induced discomfort was significantly reduced in Group CB as compared to Group NB (**Figure 17**). There were no complications related to caudal block anesthesia, including bleeding or hematoma at the injection site. No motor block of the extremities was observed and none of the patients required re-catheterization due to urinary retention after catheter removal. These results showed that ultrasound-guided single shot caudal block anesthesia can reduce the incidence and severity of postoperative urinary catheter-induced bladder discomfort.

Our findings of reduced difficulties and improved reliability with use of ultrasound guidance indicate that a caudal block can be used in adults for bladder discomfort treatment, as well as various other procedures performed in the lower abdomen region, including pelvic, bladder, perineal, genital, rectal, and anal surgery, namely, inguinal and femoral herniorrhaphy, cystoscopy, urethral surgery, prostatectomy, hemorrhoidectomy, vaginal hysterectomy, and other surgeries of the perineum, anus, and rectum. The effectiveness of a caudal block for postoperative analgesia in patients undergoing such operations is also promising.

We now consider that a caudal block can be accurately and safely performed in adults with ultrasound guidance. In addition, its application in combination with general anesthesia is expected to improve the quality of anesthesia, as shown with TAPB. In particular, a caudal block may be more suitable for high-risk cases, as the technique is simple with minimum hemodynamic effects.

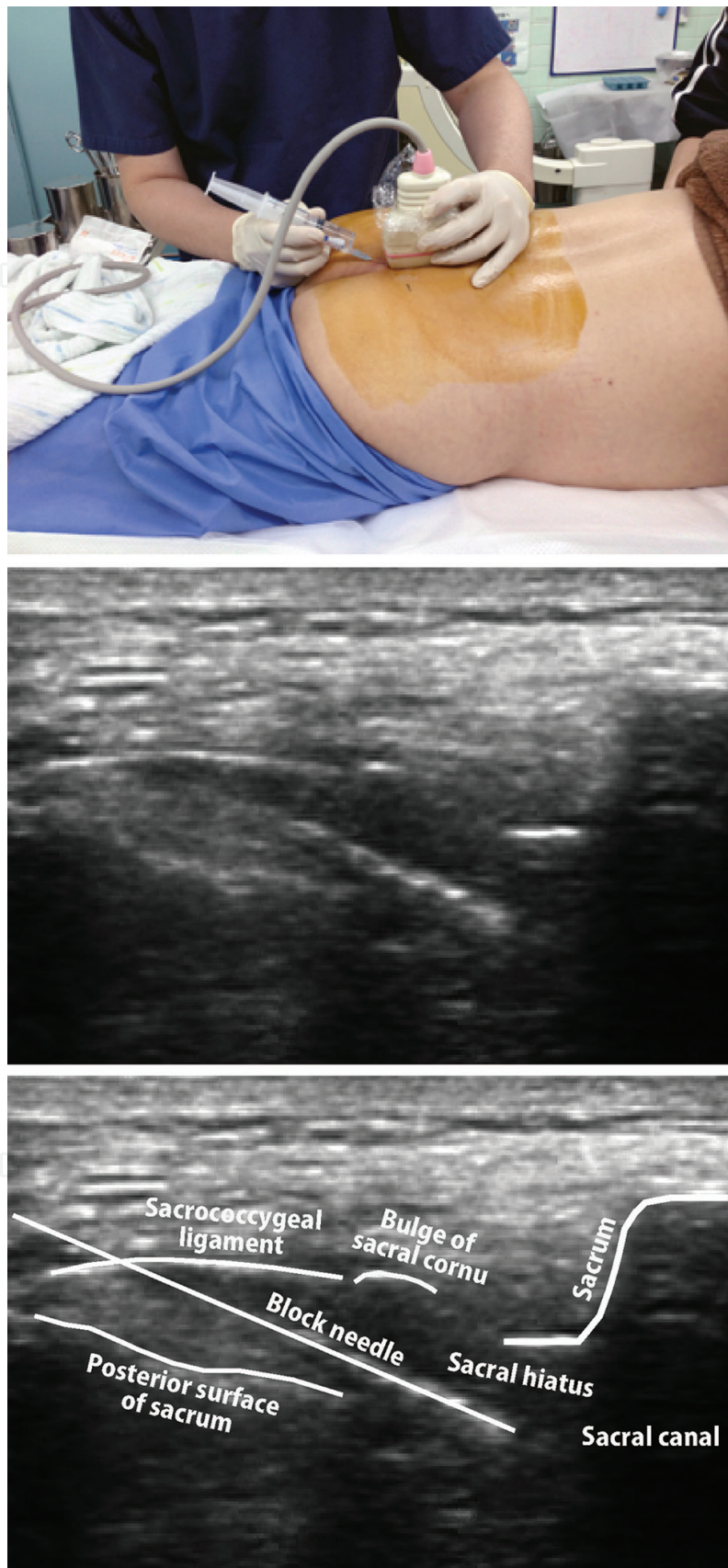


Figure 16. Ultrasound probe positioning and ultrasound images obtained during performance of caudal block.

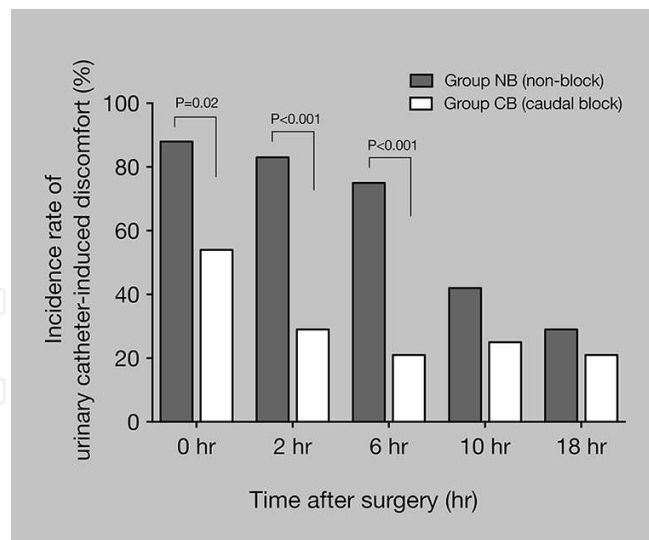


Figure 17. Effects of caudal block to alleviate catheter-induced bladder discomfort. The patients in Group CB ($n = 22$) received a caudal block with 8 ml of 0.3% ropivacaine and 100 μg of fentanyl after anesthesia induction, while those in Group NB ($n = 22$) did not receive a caudal block. The incidence rate of urinary catheter-induced bladder discomfort was significantly lower in Group CB when compared to Group NB at 0, 2, and 6 h after surgery.

10. Importance of optimal in-line positioning of ultrasound image monitor for accurate and quick nerve block

Although ultrasound guidance for providing regional anesthesia has great potential, as described above, it is not easy to perform for novice practitioners. When using ultrasound, the operator is required to mentally restructure two-dimensional images presented on a display into the three-dimensional relationship of the target with the needle. This spatial conversion represents a major hurdle for precise performance of an ultrasound-guided procedure. It has been shown that an ergonomic layout of the equipment utilized with the patient that allows the operator's gaze to run in a straight line from the puncture site to the ultrasound image display along the direction of needle insertion is important for accurate and quick spatial recognition of the needle position [28]. However, since the operating room can become crowded with numerous medical devices, the ultrasound machine is sometimes positioned out of the line of sight of the puncture field, which disturbs spatial recognition of the needle position for the operator, increasing the difficulty of the procedure. Based on these considerations, we speculated that the position of the ultrasound image display in relation to the operator is a vital factor for achieving success with ultrasound-guided procedures.

Imaging technology has progressed significantly in recent years and modern devices are widely used in the medical field. In particular, digital tablets, such as the iPad and iPad Mini (Apple Japan LLC, Tokyo, Japan), are gaining use as viewers for X-ray and 3-dimensional images during surgical procedures. These small lightweight displays can be easily placed in nearly any position by the operator and may be ideal for use during ultrasound-guided procedures.

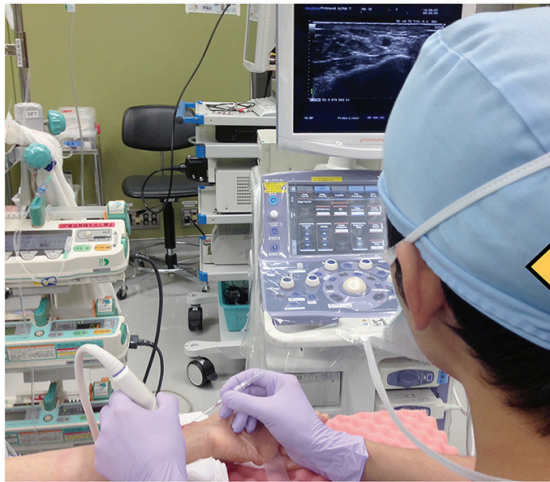To verify the importance of image position in ultrasound guided procedures, we developed a system for wireless real-time transfer of images from an ultrasound image display consisting of a wireless video transmitter (VT-100; Scalar Co., Tokyo, Japan) and an iPad Mini. The VT-100, a battery-operated, ultra-compact, and lightweight portable transmitter (approximately 290 g, including batteries) can simultaneously send video images from a single iPad Mini to other multiple iPads by Wi-Fi with a short delay of 0.067 s. However, the resolution of transferred images is somewhat low at 320×240 dots per inch (dpi), with a frame rate of more than 15 frames per second (fps). Thus, we have made fine adjustments to the image quality to allow the VT-100 to be suitable for ultrasound image transmission. The modified VT-100 is connected to an ultrasound machine (ProSound Alpha 7; Hitachi-Aloka Medical Ltd., Tokyo, Japan) via a video cable and ultrasound images are transferred to a single iPad Mini via Wi-Fi (**Figure 18**). Dedicated software (AirMicro; Scalar Co.) is installed on the iPad Mini for viewing images. Furthermore, the iPad Mini is attached to a special flexible arm with a holder for easy positioning in the area around the operating table.



Figure 18. iPad Mini (Apple Japan LLC, Tokyo, Japan), VT-100 wireless video transmitter encircled in red (Scalar Co., Tokyo, Japan), and ProSound Alpha 7 ultrasound equipment (Hitachi-Aloka Medical Ltd., Tokyo, Japan). With our method, ultrasound image signals from the ProSound Alpha 7 are transmitted by a conventional coaxial video cable to the VT-100, then sent wirelessly to the iPad Mini by Wi-Fi without any image reproduction delay.

We investigated success rate and time required for ultrasound-guided radial artery catheterization performed by novice residents when using this system in two image positions (**Figure 19**). The operators were asked to insert a catheter into the radial artery using a short-axis out-of-plane approach with a crossover method (**Figure 20**) with use of either the ultrasound machine placed at the head side of the patient across the targeted forearm (conventional method, $n = 20$) or the iPad ultrasound imaging transmission system (iPad Mini + VT-100 method, $n = 20$). When the latter was employed, the iPad was positioned so that the ultrasound images were viewed above the forearm in alignment with the operator's eyes and direction of needle puncture.

Conventional method



iPad Mini + VT-100 method

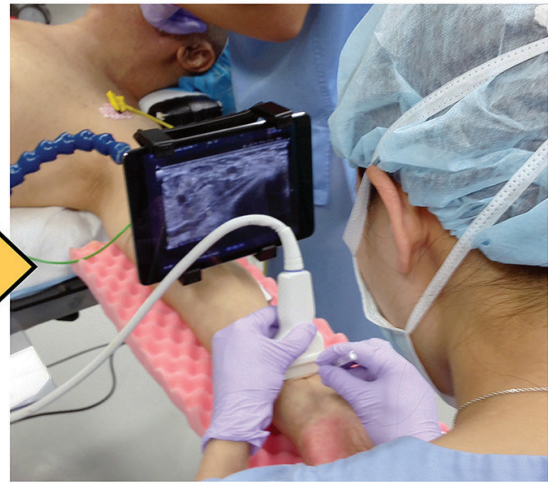

Figure 19. Positional relationships with conventional method and iPad Mini with VT100 method. With the conventional method, the ultrasound machine (ProSound Alpha 7) is placed at the head side of the patient and the puncture operator stands on the caudal side, with the patient forearm between them. With the iPad Mini with VT100 method, the axis running from the eye of the operator to the puncture needle and ultrasound image displayed on the iPad Mini are aligned as closely as possible along a straight line.

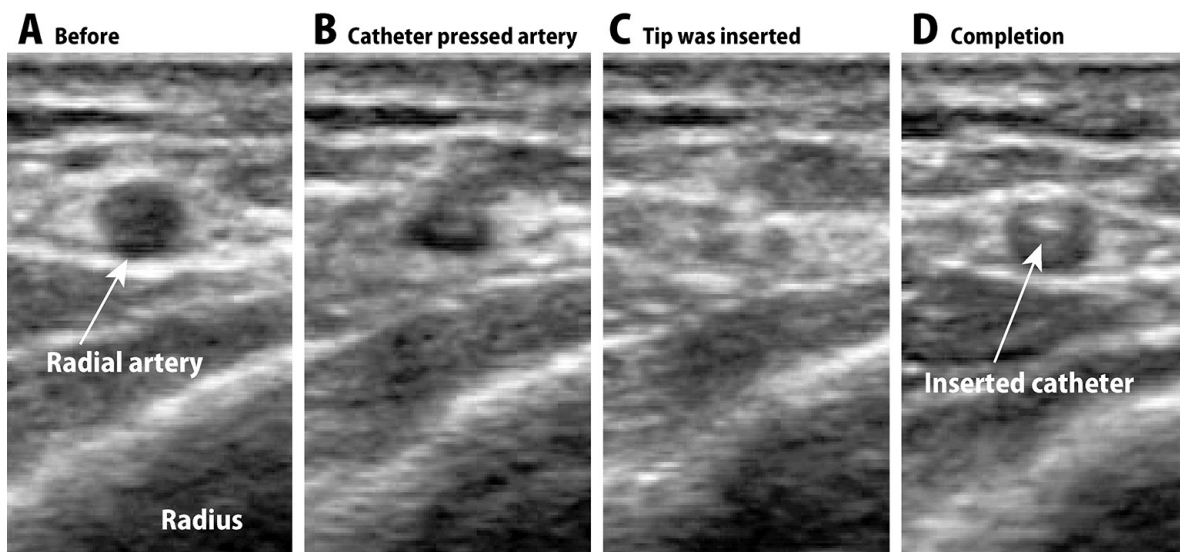


Figure 20. Representative series of four ultrasound images obtained during insertion of a radial artery catheter. A: before catheter insertion, B and C :during catheter insertion, D: completion of catheter insertion

We found that the success rate was significantly higher (100 vs. 70%, $p < 0.02$) and catheterization time significantly shorter (28.5 ± 7.5 vs. 68.2 ± 14.3 s, $p < 0.001$) with the iPad system (iPad Mini + VT-100 method) as compared to the ultrasound machine alone (conventional method). These results indicated that alignment of the visual axis of the operator, ultrasound images, and direction of needle puncture increased success rate and also reduced procedure time when performing ultrasound-guided catheterization (**Figure 21**).

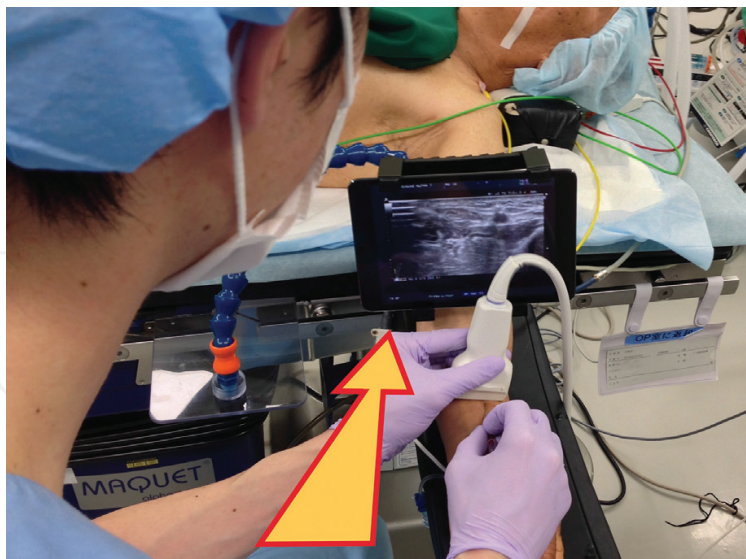


Figure 21. An ergonomic in-line arrangement of the image display, direction of needle insertion, and visual axis of the operator is crucial for successful and quick completion of ultrasound-guided procedures.

The position of the ultrasound image display is sometimes overlooked. However, we have found it to be a key point for successful and easy completion of ultrasound-guided procedures, especially when performed by practitioners with a low level of experience. For this purpose, our iPad system may be effective. In addition, it allows the ultrasound machine to be placed behind the operator, with only the display in front of their face, thus enabling a nerve block to be performed with overhand movements (**Figure 22**).

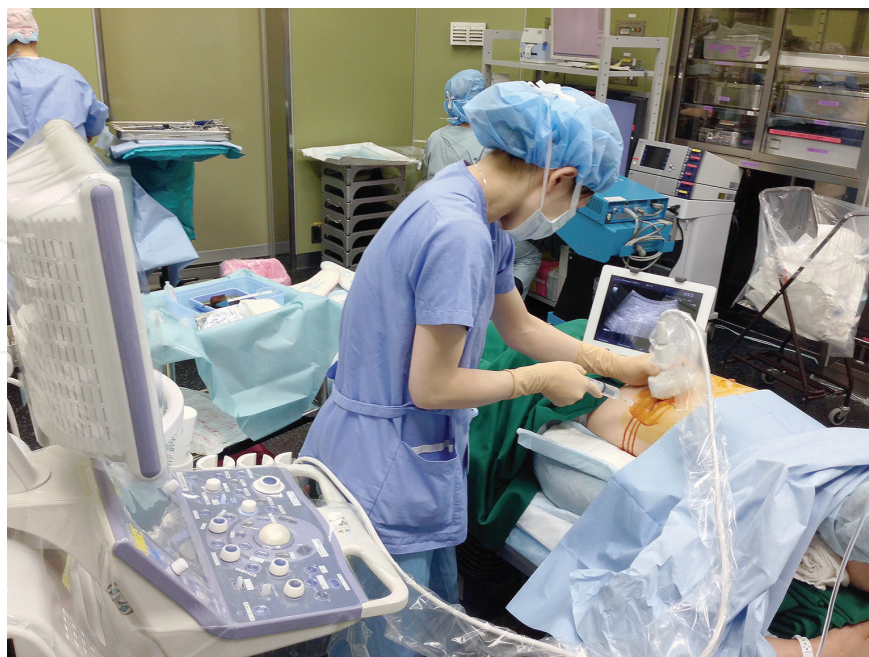

Figure 22. As shown in this representative image, the ultrasound machine is positioned behind the operator, who performs a paravertebral nerve block procedure on a prone patient while observing ultrasound images on an iPad.

11. Points of concern and disadvantages associated with performing regional anesthesia with general anesthesia

When using epidural anesthesia in combination with general anesthesia, it is highly recommended to insert the epidural catheter and then inject a test dose of the local anesthetic solution prior to the anesthesia induction, as this sequence allows for early recognition of severe complications, such as intrathecal or intravascular injection of the local anesthetic agent, or nerve injury caused by the epidural needle. In other recent cases when regional anesthesia was used, some anesthesiologists employed an ultrasound technique following anesthesia induction. With ultrasound imaging, the positions of the block needle, nerves, and blood vessels, as well as spread of the local anesthetic solution when performing regional anesthesia are clearly and accurately shown, thus ensuring the safety of the procedure even under an anesthetized condition in which the patient is unconscious. Nevertheless, there is no doubt that accidental nerve injury, as well as intravascular or unintended injection of the local anesthetic solution remain major threats for safety in all cases, which must be noted when performing regional anesthesia.

In a review conducted by the Japanese Society of Anesthesiologists of cases treated at certified training hospitals in Japan between 1999 and 2001, a higher incidence of intraoperative coronary ischemia was found in laparotomy patients anesthetized by inhalation general anesthesia in combination with regional anesthesia as compared to those who received general anesthesia alone [29]. Those findings indicated the possibility that a combined regional and general anesthesia technique might be unsuitable for patients with severe coronary diseases. On the other hand, TAPB and RSB techniques for a laparotomy have only been widely utilized in the most recent decade, thus it is reasonable to assume that cases of regional anesthesia included in that report were mainly epidural anesthesia. The combination of epidural anesthesia with general anesthesia can sometimes induce severe hypotension, which might have induced coronary ischemia in those patients. Furthermore, hypotensive effects might be more critical in patients with low output syndrome. However, as shown in our study of general anesthesia with TAPB, a peripheral nerve block does not usually induce hypotension, because it has a limited effect on the sympathetic nervous system as compared with epidural anesthesia. Thus, as long as an appropriate regional anesthesia method is carefully chosen, combined regional and general anesthesia should not be contraindicated in patients with severe coronary disease or low ejection fraction, though special caution is required for management of such high-risk patients.

12. Conclusion

Use of regional anesthesia in combination with general anesthesia provides important advantages for management of oxidative stress as well as control of hemodynamics during surgery. For improving the performance of regional anesthesia, addition of LMWD as an adjuvant to the local anesthetic solution is quite effective. In addition, ultrasound technology is very helpful to make regional anesthesia easier and safer to perform, while it is also valuable for

reevaluation of caudal block treatment in adults. Utilization of a caudal block technique along with ultrasound guidance may be effective for adult patients undergoing surgery in the lower abdomen region, especially high-risk cases, as the technique is simple with minimum hemodynamic effects. We have also found that placement of ultrasound images in a proper in-line position by use of an iPad and the VT-100 image transfer system helps to facilitate accurate and quick needle insertion to the target, especially for novice practitioners. When considering these advantages of regional anesthesia and its advancement with the help of ultrasound technology, it is expected that the combined use of regional and general anesthesia will become more common for anesthetic management in the near future. Even though additional time is needed, regional anesthesia in conjunction with general anesthesia should be considered in all cases

Author details

Masahiko Tsuchiya

Address all correspondence to: oxymasa@ea.mbn.or.jp; oxymasa@gmail.com

Department of Anesthesiology, Osaka City University Medical School, Osaka, Japan

References

- [1] Tsuchiya M, Kyoh Y. Key points for intraoperative management of percutaneous endoscopic lumbar discectomy (PELD) for anesthesiologists. *Minerva Anesthesiol* 2013; **79**: 1318–9.
- [2] Tsuchiya M, Kyoh Y, Mizutani K, Yamashita J, Hamada T. Ultrasound-guided single shot caudal block anesthesia reduces postoperative urinary catheter-induced discomfort. *Minerva Anesthesiol* 2013; **79**: 1381–8.
- [3] Kang MY, Tsuchiya M, Packer L, Manabe M. In vitro study on antioxidant potential of various drugs used in the perioperative period. *Acta Anaesthesiol Scand* 1998; **42**: 4–12.
- [4] Tsuchiya M, Asada A, Inoue M. Significance of reactive oxygen species in vivo. *Japan J Intens Care Med* 2003; **27**: 649–60.
- [5] Tsuchiya M, Sato EF, Inoue M, Asada A. Open abdominal surgery increases intraoperative oxidative stress: can it be prevented? *Anesth Analg* 2008; **107**: 1946–52.
- [6] Suehiro K, Tanaka K, Matsuura T, et al. Preoperative hydroperoxide concentrations are associated with a risk of postoperative complications after cardiac surgery. *Anaesth Intensive Care* 2014; **42**: 487–94.
- [7] Tsuchiya M, Tomoda M, Ueda W, Hirakawa M. Halothane enhances the phosphorylation of H1 histone and rat brain cytoplasmic proteins by protein kinase C. *Life Sci* 1990; **46**: 819–25.

- [8] Tsuchiya M, Tomoda M, Ueda W, Hirakawa M. Inhalational anesthetics activate protein kinase C. *Journal of Clinical and Experimental Medicine* 1989; **150**: 697–8.
- [9] Tsuchiya M, Tomoda M, Ueda W, Hirakawa M. Effect of halothan on protein kinase C activity. *Anesthesia and Resuscitation* 1990; **26**: 219–26.
- [10] Tsuchiya M, Okimasu E, Ueda W, Hirakawa M, Utsumi K. Halothane, an inhalation anesthetic, activates protein kinase C and superoxide generation by neutrophils. *FEBS Lett* 1988; **242**: 101–5.
- [11] Tomoda MK, Tsuchiya M, Ueda W, Hirakawa M, Utsumi K. Lidocaine inhibits stimulation-coupled responses of neutrophils and protein kinase C activity. *Physiol Chem Phys Med NMR* 1990; **22**: 199–210.
- [12] Tsuchiya M, Takahashi M, Tomoda M, Ueda W, Hirakawa M. Halothane impairs the bioenergetic functions of isolated rat liver mitochondria. *Toxicol Appl Pharmacol* 1990; **104**: 466–75.
- [13] Kevin LG, Novalija E, Riess ML, Camara AK, Rhodes SS, Stowe DF. Sevoflurane exposure generates superoxide but leads to decreased superoxide during ischemia and reperfusion in isolated hearts. *Anesth Analg* 2003; **96**: 949–55.
- [14] Tomoda M, Ueda W, Tsuchiya M, Hirakawa M. Effects of lidocaine on stimulation-coupled responses of neutrophils and protein kinase C activity. *Masui* 1992; **41**: 369–75.
- [15] Tsuchiya M, Tomoda M, Ueda W, Hirakawa M. Local anesthetics inhibit protein kinase C and active oxygen generation in neutrophils. *Journal of Clinical and Experimental Medicine* 1989; **150**: 569–70.
- [16] Tsuchiya M, Scita G, Freisleben HJ, Kagan VE, Packer L. Antioxidant radical-scavenging activity of carotenoids and retinoids compared to alpha-tocopherol. *Methods Enzymol* 1992; **213**: 460–72.
- [17] Tsuchiya M, Kagan VE, Freisleben HJ, Manabe M, Packer L. Antioxidant activity of alpha-tocopherol, beta-carotene, and ubiquinol in membranes: cis-parinaric acid-incorporated liposomes. *Methods Enzymol* 1994; **234**: 371–83.
- [18] Tsuchiya M, Kang MY, Tokai H, et al. New antioxidant assay system reveals potent antioxidant activity of calcium channel blockers and steroids. *Journal of the Japanese Society of Intensive Care Medicine* 1999; **6**: 103–7.
- [19] Niki E. Free radical initiators as source of water- or lipid-soluble peroxy radicals. *Methods Enzymol* 1990; **186**: 100–8.
- [20] Glazer AN. Fluorescence-based assay for reactive oxygen species: a protective role for creatinine. *FASEB J* 1988; **2**: 2487–91.
- [21] Budic I, Pavlovic D, Cvetkovic T, et al. The effects of different anesthesia techniques on free radical production after tourniquet-induced ischemia-reperfusion injury at children's age. *Vojnosanit Pregl* 2010; **67**: 659–64.

- [22] Tsuchiya M, Takahashi R, Furukawa A, Suehiro K, Mizutani K, Nishikawa K. Transversus abdominis plane block in combination with general anesthesia provides better intra-operative hemodynamic control and quicker recovery than general anesthesia alone in high-risk abdominal surgery patients. *Minerva Anesthesiol* 2012; **78**: 1241–7.
- [23] Mizutani K, Suwa K, Tsuchiya M. Illustration of O₂ and CO₂ recirculation to interpret respiratory and circulatory physiology. *J Clin Anesth* 2015; **27**: 363–5.
- [24] Ueda W, Hirakawa M, Mori K. Inhibition of epinephrine absorption by dextran. *Anesthesiology* 1985; **62**: 72–5.
- [25] Hamada T, Tsuchiya M, Mizutani K, et al. Levobupivacaine-dextran mixture for transversus abdominis plane block and rectus sheath block in patients undergoing laparoscopic colectomy: a randomised controlled trial. *Anaesthesia* 2016; **71**: 411–6.
- [26] Kingsnorth AN, Wijesinha SS, Gixti CJ. Evaluation of dextran with local anaesthesia for short-stay inguinal herniorrhaphy. *Ann R Coll Surg Engl* 1979; **61**: 456–8.
- [27] Buckley FP, Fink BR. Duration of action of nerve blocks produced by mixtures of local anesthetics and low molecular weight dextran: studies in rat infraorbital nerve blocks. *Anesth Analg* 1981; **60**: 142–5.
- [28] Tsuchiya M, Mizutani K, Funai Y, Nakamoto T. In-line positioning of ultrasound images using wireless remote display system with tablet computer facilitates ultrasound-guided radial artery catheterization. *J Clin Monit Comput* 2016; **30**: 101–6.
- [29] Irita K, Kawashima Y, Morita K, et al. Life-threatening coronary ischemia in the operating room: analysis of annual survey from 1999 to 2001 conducted by Japanese Society of Anesthesiologists. *Masui* 2003; **52**: 304–19.