

We are IntechOpen, the world's leading publisher of Open Access books Built by scientists, for scientists

4,800

Open access books available

122,000

International authors and editors

135M

Downloads

Our authors are among the

154

Countries delivered to

TOP 1%

most cited scientists

12.2%

Contributors from top 500 universities



WEB OF SCIENCE™

Selection of our books indexed in the Book Citation Index
in Web of Science™ Core Collection (BKCI)

Interested in publishing with us?
Contact book.department@intechopen.com

Numbers displayed above are based on latest data collected.
For more information visit www.intechopen.com



Intraductal Papillary Mucinous Neoplasms of the Pancreas: Challenges and New Insights

Natalia Zambudio Carroll, Betsabé Reyes and Laureano Vázquez

Additional information is available at the end of the chapter

<http://dx.doi.org/10.5772/66491>

Abstract

Cystic lesions of the pancreas are a common entity with almost a 25% incidence of the general population. These types of lesions are being increasingly diagnosed partly explained due to the technological advances over the past years. The management and treatment varies per cyst type. However, the most threatening cyst lesions are intraductal papillary mucinous neoplasms (IPMNs). These lesions represent nowadays a relatively new clinical entity and in many aspects remain poorly understood. The aim of this chapter is to provide a comprehensive review of the classification, diagnosis, treatment and follow-up strategy.

Keywords: IPMN, BD-IPMN, BD-IPMN, classification, malignancy risk, pathogenesis, management, surveillance

1. Introduction

In the face of this new “epidemic of pancreatic cysts,” it is clear that we need to be on top of newly emerging changes in our current daily practice. Pancreatic cancer has a fateful prognosis, despite recent improvements in surgery and chemotherapy. However, most cases of intraductal papillary mucinous neoplasms (IPMNs) are considered as premalignant lesions, thus making them a target for diagnosis and prompt treatment. On the other hand, we should never forget the short- and long-term risks of surgery. This is precisely why it is so challenging to adequately manage this pathology.

Biomarkers represent an interesting opportunity, but until they can be used on a regular clinical basis, we are obliged to say knowledgeable on new insights involving radiologic characteristics and potential malignancy prior to deciding, which is the best available individualized option for each patient.

2. Classification

2.1. Anatomic classification: involvement of the pancreatic ductal system

Most IPMN arise from the pancreatic main duct or its branch ducts (**Figure 1**). Most of these tumors are unifocal, 20–30% are multifocal, and 5–10% of the IPMN diffusely affect the entire duct system of the pancreas. Depending on the involvement of the pancreatic duct, IPMNs are classified as either main duct IPMN (MD-IPMN) or branch duct IPMN (BD-IPMN). If both, main and branch ducts are involved together, then it is defined as combined-type IPMN (**Figure 2**). The clinical pathologic behavior of combined-type IPMN is similar to that of MD-IPMN. MD-IPMN is frequently more associated with this malignant transformation than is BD-IPMN, requiring surgical resection in more than a half of the patients, while most patients with BD-IPMN can be observed for a long time after the diagnosis.

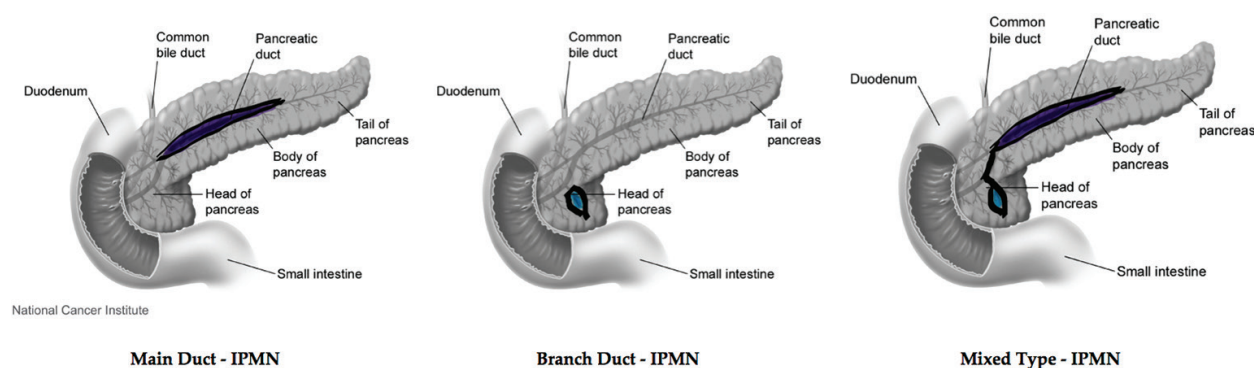


Figure 1. Types of IPMN: MD-IPMN, BD-IPMN, mixed type-IPMN. Modified from: Bliss D (Illustrator) 2001. Pancreas, Duodenum, and Small Intestine [image]. Available at: <https://visualsonline.cancer.gov/details.cfm?imageid=4364>.

<p>MD - IPMN:</p> <ul style="list-style-type: none"> - Cystic tumor - MPD: > 10mm 	<p>BD - IPMN:</p> <ul style="list-style-type: none"> - Cystic tumor in the branches - MPD: < 6 mm
---	---

Figure 2. Differences between MD-IPMN and BD-IPMN.

2.2. Histologic classification: IPMN subtype

Immunohistochemical staining with mucin antibodies enables differentiation between tumors with different prognoses. Four subtypes of IPMNs have been characterized: gastric, intestinal, pancreatobiliary, and oncocytic. Most of BD-IPMNs are composed of gastric-type epithelium. However, intestinal type is more common in MD-IPMN. In a recent report, the four subtypes of IPMNs were associated with significant differences in survival. Patients with gastric-type IPMN had the best prognosis, whereas those with intestinal and pancreatobiliary type had a bad prognosis [1–6].

2.3. World Health Organization (WHO)

The World Health Organization (WHO) classified IPMNs into three subgroups according to degree of dysplasia: (I) IPMN with low- or intermediate-grade dysplasia; (II) IPMN with high-grade dysplasia (carcinoma in situ); and (III) IPMN with an associated invasive carcinoma. IPMN associated with PDAC (pancreatic ductal adenocarcinoma arising in association with an IPMN) was further classified into two subtypes: tubular adenocarcinoma, composed of predominantly gland-forming neoplastic cells with fibrotic stroma and absence of significant extracellular stromal mucin and colloid carcinoma (mucinous noncystic carcinoma), composed of sparsely populated strips, clusters, or individual neoplastic cells residing within extensive pools of extracellular mucin [6]. In case of IPMN with low- to intermediate-grade of dysplasia, dysplastic changes in the columnar cells are minimal or absent. The prognosis is usually favorable [7].

3. Malignancy risk

There has been an increased prevalence of pancreatic cystic neoplasms, frequently being found in elderly asymptomatic patients. This is partially caused by the greater number of cross-sectional studies being performed. Though images obtained through the use of computed tomography (CT-scan) and magnetic resonance imaging (MRI), we are able to estimate the prevalence of pancreatic cysts in 2.5% of the population. This figure increases over time; around the age of 70 years or older, 10% of the population has pancreatic cysts and 20–50% of them are IPMN [8].

The real risk of malignancy may be very low, but the diagnosis is associated with anxiety and usually leads to further medical testing in order to confirm malignancy. The most frequently used tests are likely to include: consultations con gastroenterologists and/or oncologists, endoscopic ultrasound with or without percutaneous biopsy, and occasionally surgery [6, 8, 9]. This is one of the reasons why more and more studies are focusing on evaluating the malignancy rate for pancreatic cancer distinct from IPMN and also for pancreatic cancer arising from IPMN. Figures are rather variable, but over the course of several years, we have been able to see how the rates for malignancy, especially in SB-IPMN, are found to be lower.

Not only IMPNs are associated with pancreatic malignancies but also it is known that extrapancreatic malignancies are more frequently found in these patients.

3.1. Pancreatic malignancies

3.1.1. Pancreatic cancer arising from IPMN

3.1.1.1. MD-IPMN

The malignancy risk in this type of situation is very clear which makes the decision to perform surgery also much easier. Many studies have estimated the overall risk ranges between 36 and 92% [10–13]. Overall, the prognosis after resection is generally favorable as long as its invasion remains within minimally invasive or in T1a status (depth of stromal invasion <5 mm).

3.1.1.2. BD-IPMN

In this case, there are more controversial figures. Estimated rates here can range from 6 to 47% [8, 11–13]. In 2013, Gardner et al. [8] lower the current 25% lifetime risk of malignant transformation and presented the prevalence of mucin-producing adenocarcinoma in patients diagnosed with pancreatic cysts to be 33.2 per 100,000 patients. A linear increment was detected when studying male patients between the ages of 80–84. In that group, the prevalence was 38.6 per 100,000 patients. Only one systematic review by Crippa et al. [14] is considered to be the first meta-analysis focused in the risk of developing pancreatic malignancies, including malignant BD-IPMNs and PDAC, as well as the risk of death due to pancreatic malignancy in patients undergoing nonoperative management for BD-IPMNs. The estimated overall pancreatic malignancy rate is 3.7%, an incidence of malignancy in 7 cases per 1000 per years and an annual risk on only 0.7%. This is the rate that is entirely comparable with the 90-day postoperative mortality rate following pancreatic resections found at many high-volume centers. Thus, choosing surgery in these cases does not justify for avoiding the unlikely progression from “low-risk” BD-IPMN to invasive tumors.

3.1.2. Pancreatic cancer distinct from IPMN

There appears to be a “field defect,” which may give rise to both IPMN and pancreatic duct adenocarcinoma (frequently related to gastric subtype) occurring in 2–5% of patients diagnosed with IPMN [6, 10]. Also, Crippa et al. [14] lower the previous rates with an estimate of incidence of only 2 cases per 1000 per year and an annual risk of 0.2%.

3.2. Extrapancreatic malignancies

Colorectal, gastric, bile duct, renal cell, and thyroid cancers are relatively frequently associated with IPMNs [15–17].

4. Pathogenesis

IPMNs are mucinous cystic lesions of the pancreas that are characterized by neoplastic, mucin-secreting, and papillary cells projecting from the pancreatic ductal surface. They arise from the epithelial lining of the main pancreatic duct or its side branches. Intraductal proliferation of mucin-producing columnar cells is the main histologic characteristic of IPMNs, and

intraluminal growth causes dilatation of the involved duct and its proximal segment. They are usually found in the head of the pancreas as a solitary cystic lesion, but in 20–30% of the cases, they may be multifocal, and in 5–10% of cases, they may involve the pancreas diffusely [18–20]. In BD-IPMN, malignant tumors can be found in 6–46% and in MD-IPMN in 57–92%, making that MD-IPMN leads to worse prognosis [5].

4.1. Progression to pancreatic cancer

IPMNs are thought to follow an orderly progression from a benign neoplasm to invasive carcinoma of the pancreas, they range from premalignant lesions with low-grade dysplasia to invasive malignancy, and they have a clear tendency to become invasive carcinoma [5, 21–24]. It has been estimated a 5–6 year progression rate, depending on the subtype. They are graded according to the most atypical area in the lesion as:

- Low-grade dysplasia (adenoma).
- Moderate dysplasia (borderline).
- High-grade dysplasia (carcinoma in situ).
- Invasive carcinoma.

5. Clinical presentation

5.1. Risk factors

It has been described that previous history of diabetes, especially with insulin dependency, chronic pancreatitis, or a familial history of pancreatic ductal adenocarcinoma (PDAC), may have a higher risk for IPMN [25]. Also, several studies have noticed that the presence of autoimmune disease in general population is around 5%; however, in patients diagnosed with IPMN, the number rises up to 22%. IPMNs can be associated with systemic diseases such as: systemic lupus erythematosus and rheumatoid arthritis an inflammatory bowel disease, leading to think that IMPNs may be one manifestation of a more systemic disease [26].

5.2. Symptoms

Most IPMNs are diagnosed between 60 and 70 years of age. There is a slightly higher prevalence in men than women [7]. Some patients present symptoms at the time of diagnosis (7–43%), being more frequent the presence of abdominal pain, jaundice, and previous history of pancreatitis. Other symptoms are as follows: weight loss, nausea or vomiting, and diabetes [5, 6, 27].

6. Evaluation for malignancy

Several tests can be performed when confronted with a possible IPMN. Regarding this subject, some changes have occurred recently, most of them centering on the use of EUS-FNA

(endoscopic ultrasonography/fine-needle aspiration) and endoscopic retrograde cholangiopancreatography (ERCP) and analyses of the obtained fluid (**Figure 3**).

6.1. Cross-sectional imaging

Magnetic resonance cholangiopancreatography (MRCP) and computerized axial tomography scan (CAT scan) are useful as the first step, and perhaps the only one, if results are very clear (see management) (**Figure 4**). It is useful to describe:

- Anatomical characteristics: lymph node involvement and main pancreatic duct involvement.
- Mural nodules: IPMN with >3 mm nodules is highly suggestive of malignancy.

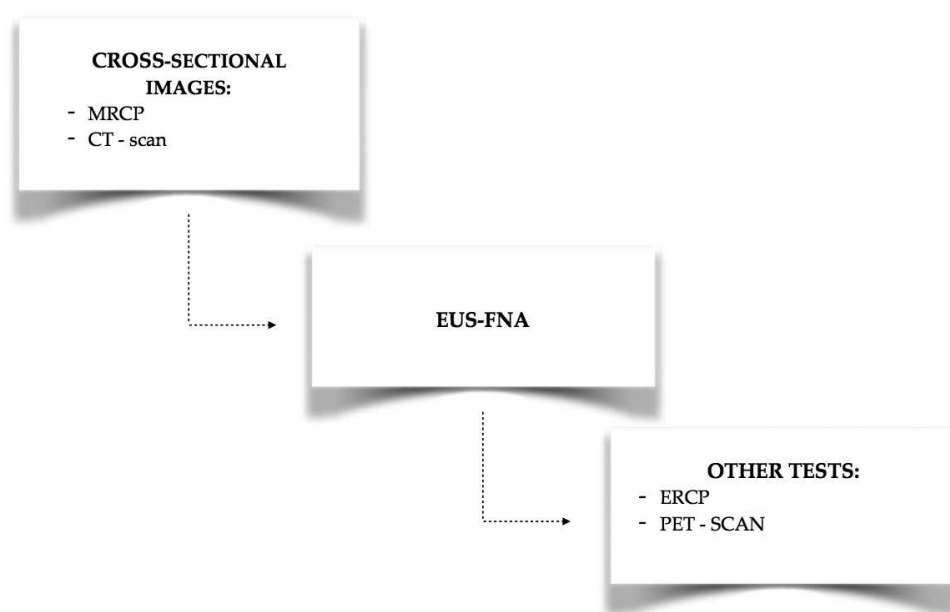


Figure 3. General sequence when diagnosing IPMNs.

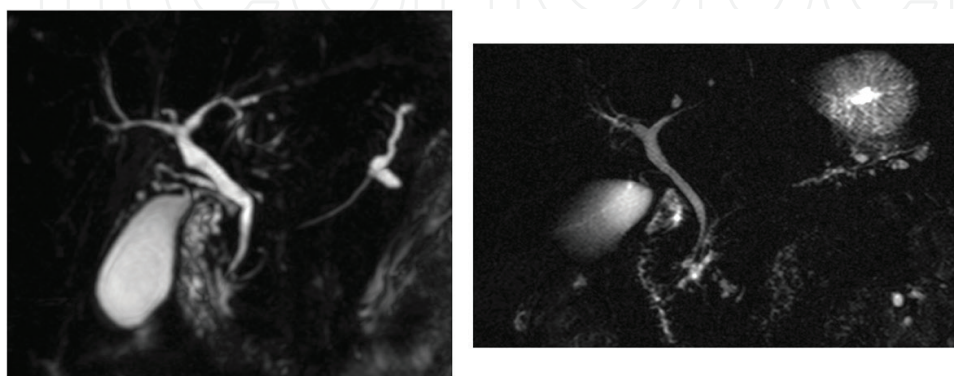


Figure 4. MRCP images of MD-IPMN (left) and BD-IPMN (right).

6.2. EUS-FNA

This technique has been evolving, and more hospitals are incorporating it into their routine diagnostic tests, helping to introduce its more general application and obtaining information by:

- Describing sonographic characteristics: mural nodes and invasion.
- Performing pancreatic and cyst fluid analysis: cellularity, CEA determination and molecular markers KRAS with or without GNAS mutation, TP53, PIK3CA, p16/CDKN21, SMAD4, or PTEN mutation (28).

On the 2012 international consensus guidelines [28], certain recommendations were made as to when to use EUS-FNA:

- Pancreatic cysts with worrisome features.
- Pancreatic small cyst with worrisome features.
- >3 cm cysts with no worrisome features, especially if elderly patients to verify the findings.
- Distinction of BD-IPMN versus serous cyst neoplasm (SCN) with CEA determination.

Nonetheless, the more recent American Gastroenterological Association (AGA) guideline on the management of pancreatic cysts [29] issues a conditional recommendation: “pancreatic cysts with at least two high-risk features, such as size ≥ 3 cm, a dilated main pancreatic duct, or the presence of an associated solid component, should be examined with endoscopic ultrasonography with fine-needle aspiration (EUS-FNA)” (**Figure 5**).

Macroscopically, highly viscous fluid is the first clue that the cyst is mucinous cyst. Furthermore, high concentration of CEA reflects the presence of a mucinous epithelium, and it is elevated in both IPMNs and MCNs. Thus, it is quite beneficial to distinguish mucinous cysts from non-mucinous. A cut-off CEA level of 192 ng/mL has the sensitivity of 73%, specificity of 84%. Due to connectivity to the pancreatic ductal system, amylase level may be elevated in IPMNs.

In conclusion, the most recent papers encourage the use of EUS-FNA in the initial diagnostic tests [15, 30] to identify smaller cysts with high grade or invasive pathology [30] and to detect mural nodules otherwise missed on cross-sectional imaging or malignant cytology in lesions >3 cm. The high specificity and accuracy of EUS strongly position it as the optimum tool for diagnosing malignant BD-IPMNs, particularly in patients without worrisome features and with smaller cysts [31]. It is particularly important to consider that inherent risks can be derived from this test, including complications associated with these endoscopic procedures such as difficulty in cytological interpretation of samples and relatively low sensitivity [31].

6.2.1. Biomarkers

DNA analysis of pancreatic cyst fluid demonstrated that KRAS mutation is highly specific (96%) for mucinous cysts, but the sensitivity is only 45%. KRAS is an early oncogenic mutation in the adenoma-carcinoma sequence but cannot discriminate a benign from malignant mucinous cyst. A recent study [32] demonstrated that the “GNAS mutation

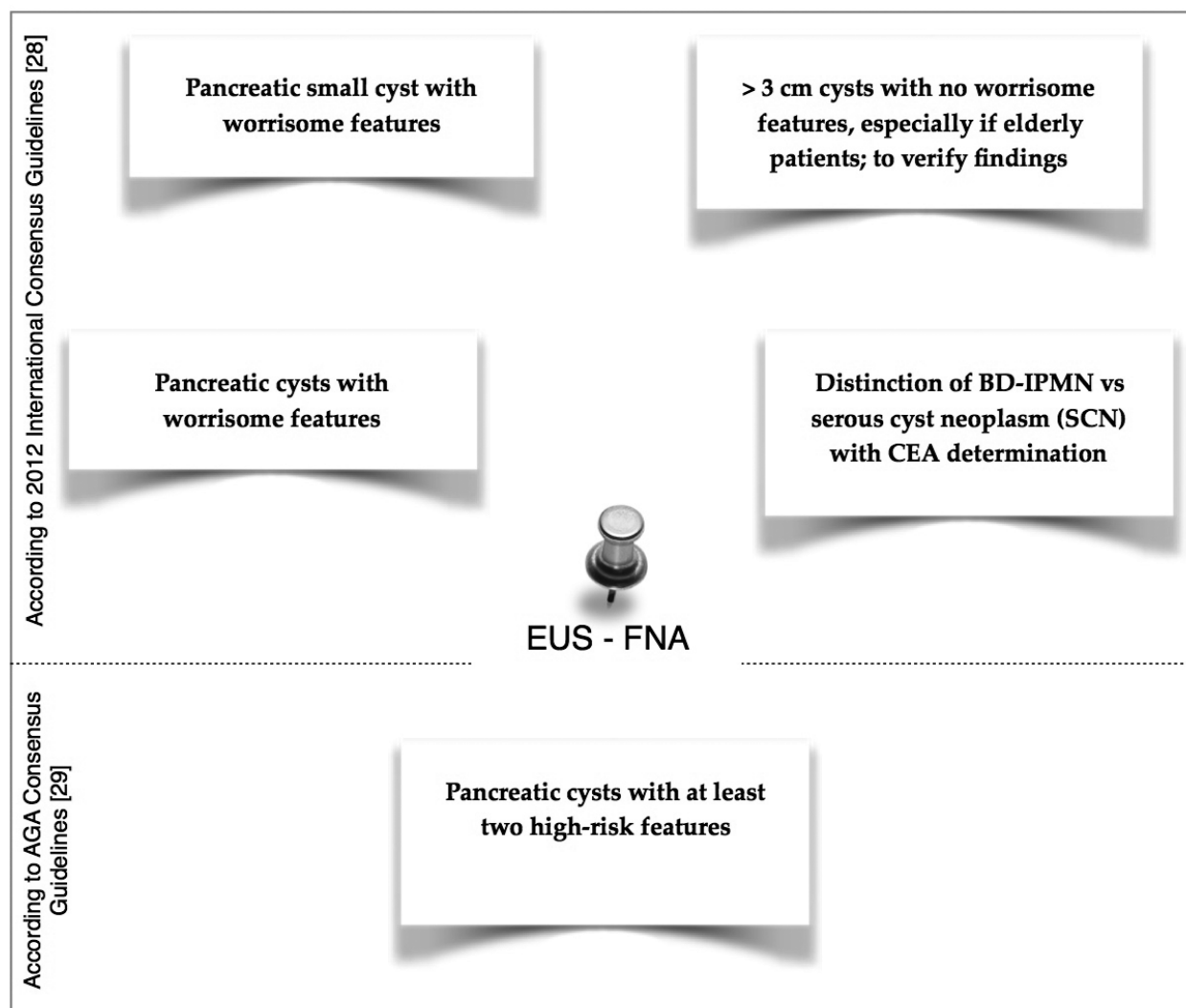


Figure 5. Use of EUS-FNA according to 2012 International Consensus Guidelines [28] and AGA Guidelines [29].

detected in cyst fluid can separate IPMN from MCN, but similar to KRAS mutations, it does not predict malignancy. The absence of a GNAS mutation also does not correlate with a diagnosis of MCN because not all IPMNs will demonstrate a GNAS mutation [33–35]. A GNAS mutation was present in 66% of IPMNs.” But a recent mutations study in GNAS at codon 201 has been identified in duodenal fluid samples even before the IPMN lesion, which was identified on radiologic imaging [36]. Moreover, one study reports that 33% of incipient IPMNs analyzed have a GNAS mutation, suggesting that a large proportion of incipient IPMNs are part of the IPMN pathway, and these mutations occur early in this process [6, 37].

A recent study identified glucose and kynurenine to be differentially expressed between non-mucinous and mucinous pancreatic cysts [38]. Metabolic abundances for both were significantly lower in mucinous cysts compared with non-mucinous cysts. The clinical utility of

these biomarkers will be addressed in future studies although it is clear that it will be of great utility when differentiating benign vs. malignant cysts.

6.3. Other procedures

6.3.1. ERCP

For sampling of fluid brushes in the 2012 International Consensus Guidelines for the management of IPMN, routine use of this test was not recommended and was left only for scientific purposes [28]. However, as professionals are becoming more familiarized with it and results are increasingly being more accurate, newer studies are encouraging cytology of the pancreatic juice and it is starting to be considered a reliable predictor of malignancy in IPMN [39]. Cytological examination alone is often non-diagnostic due to the low cellularity of the aspirated fluid. A positive or negative diagnosis can be obtained through a cytology analyses with a 100% specificity. Moreover, if a high-grade epithelial atypia is found in the cyst fluid, it is correlated with an 80% chance of malignancy [40].

6.3.2. PET scan

Positron emission tomography has been proposed as a useful technique for diagnosing and staging different malignancies. Several studies have investigated the outcomes in IPMN cases, concluding that dual-phase F-18 fluorodeoxyglucose positron emission tomography with computed tomography (FDG-PET/CT) has an overall specificity of 92–95% and a sensitivity of 88–94% when trying to differentiate malignant IPMNs vs. benign lesions. It has been proposed that PET scans should be performed in older patients, cases at increased surgical risk, or when the feasibility of parenchyma-sparing surgery demands a reliable preoperative exclusion of malignancy [41, 42].

7. Management

To date, three consensus guidelines have been proposed to manage pancreatic cystic lesions beginning with the original 2006 Sendai guideline, which was revised in 2012 by the International Association of Pancreatology (IAP) in Fukuoka, and the recent AGA guideline [43–45].

All guides agree that due to the higher risk of malignancy, all symptomatic cysts should be further evaluated or resected, depending on the clinical circumstances.

Invasive carcinoma in patients with asymptomatic cysts is very rare, especially in cysts <10 mm. In such cases, no further work-up will be needed; however, follow-up is still recommended [43–46]. For better characterization of the lesions, pancreatic protocol CT or gadolinium-enhanced MRI with magnetic resonance cholangiopancreatography (MRCP) is recommended for cysts >10 mm [47]. The most recent consensus among radiologists [10]

suggests that MRI is preferable for evaluating cysts due to its high-contrast resolution, the identification of septum, nodules, and duct communications. Also, MRI is the preferable follow-up test because it avoids excessive exposure to radiation [47].

According to Fukuoka guidelines (1), there are:

- **“Worrisome features”:**
 - Cyst of ≤ 3 cm.
 - Thickened enhanced cyst walls.
 - MPD of 5–9 mm.
 - Non-enhanced mural nodules.
 - Abrupt change in the MPD caliber with distal pancreatic atrophy.
 - Lymphadenopathy.
- **“High-risk stigmata”:**
 - Obstructive jaundice in a patient with a cystic lesion of the pancreatic head.
 - Enhanced solid component, MPD size of 10 mm.

All patients with cysts of 3 cm in size without “worrisome features” should undergo surveillance according to the size stratification. Patients with cysts of >3 cm and no “worrisome features” can also be considered for EUS to verify the absence of thickened walls or mural nodules, particularly if the patient is elderly. All smaller cysts with “worrisome features” should be evaluated by EUS to further risk stratify the lesion [48].

7.1. Surgery

If surgery is considered for a pancreatic cyst, patients are referred to a center with demonstrated expertise in pancreatic surgery. Surgery is the only treatment option in patients with IPMN of the pancreas with high-grade dysplasia or IPMNs that have progressed to invasive carcinoma (**Figure 6**).

7.1.1. Indications

- High-grade dysplasia or Invasive carcinoma.
- High-risk stigmata + positive cytology.
- High-risk stigmata confirmed by MRI and EUS.
- Symptomatic cyst.
- Younger patients with cyst >2 cm owing to cumulative risk.

Positive cytology on EUS-guided FNA has the highest specificity for diagnosing malignancy. If there is a combination of high-risk features on imaging, then this is likely to increase the

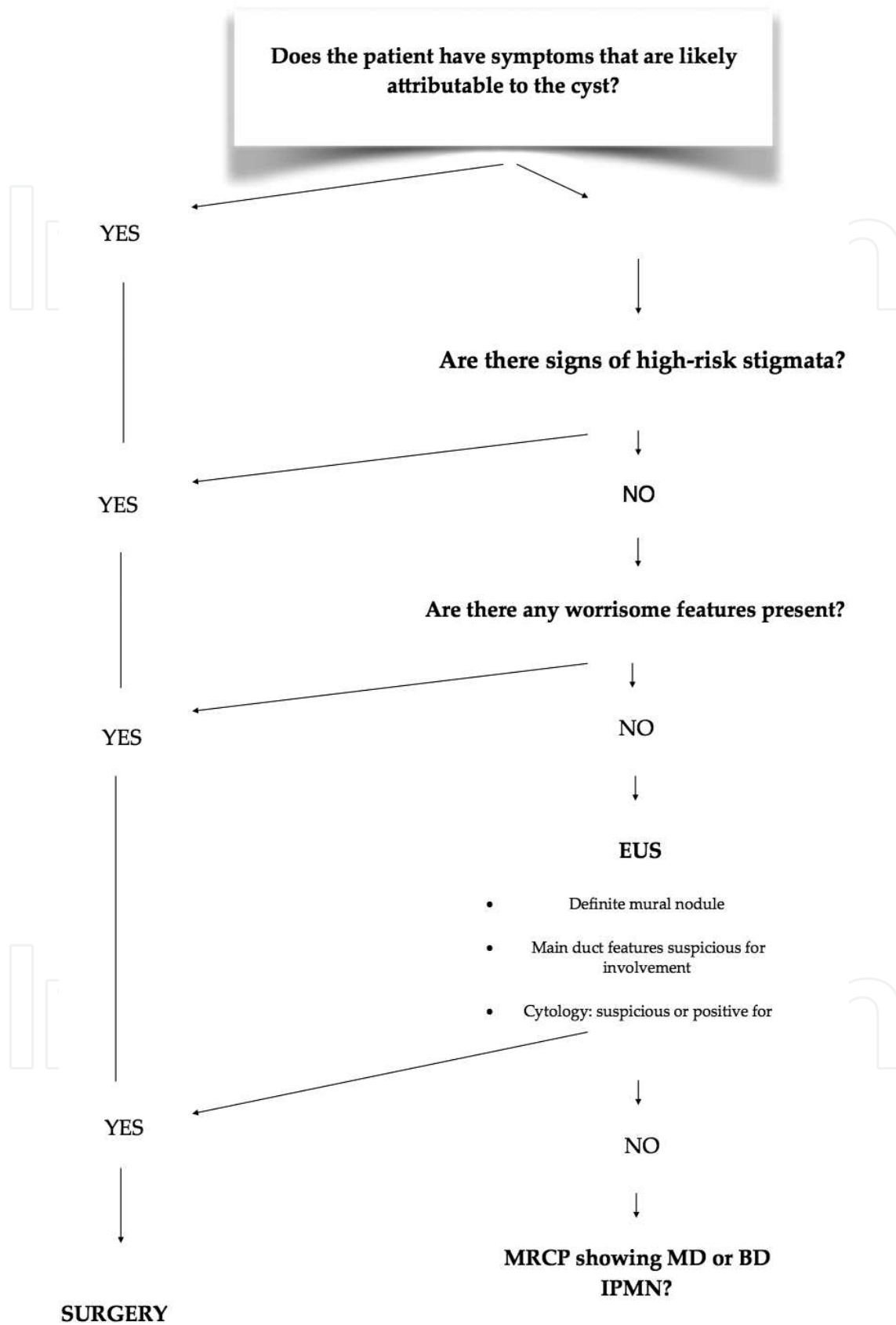


Figure 6. Proposed algorithm for surgery indications in IPMNs.

risk of malignancy. Even in the face of a negative cytology, if EUS and MRI confirm high-risk stigmata, the specificity is likely to be high. However, no currently available data can demonstrate the impact of multiple high-risk features. Molecular techniques to evaluate pancreatic cysts remain an emerging area of research [23, 49, 50], but had the benefits of surgery outweigh the risks in this selected population [51].

The most important aspect of resection is to achieve complete removal of a tumor with a negative margin. If a positive margin is found in a high-grade dysplasia, additional resection of the pancreas should be performed. However, there is no consensus regarding further resection in the case of a low- or moderate-grade dysplasia [51, 52].

Total pancreatectomy should be contemplated only in younger patients who can manage the comorbidities related to diabetes and exocrine insufficiency or in patients with a history of diabetes [53, 54]. The choice of surgery will be determined by the location of the tumor and the extent of involvement of the gland. It is not clearly established that multifocality corresponds to a higher risk of invasive cancer; in most cases with more than one lesion, the dominant or concerning lesions are resected; and the others are observed with follow-up imaging [1].

Regarding the BD-IPMN that occurs in elderly patients, the annual malignancy rate is only 2–3%. These factors support a conservative management with follow-up in patients who do not have risk factors predicting malignancy. Younger patients (<65 years) with a cyst size of >2 cm may be candidates for resection owing to the cumulative risk of malignancy [27]. BD-IPMN of >3 cm without these signs can be observed without immediate resection, particularly in elderly patients. The decision needs to be individualized and to depend not only on the risk of malignancy but also on the patient's conditions and cyst location [51].

7.2. Adjuvant therapy

It has not yet been determined whether or not to offer postresection adjuvant therapy to patients with IPMNs that have progressed to invasive carcinoma; it also undefined as to the optimal strategy for postoperative therapy (chemoradiotherapy versus chemotherapy alone) remains undefined [55]. A recent study by McMillan et al. [56] suggests that patients classified as AJCC stage II through IV, presenting with positive lymph nodes, positive resection margins or poorly differentiated tumors, may benefit from adjuvant chemoradiotherapy over chemotherapy alone in terms of overall survival, except for patients who had AJCC pathologic stage II disease.

8. Follow-up

The AGA recommends discussing the risks and benefits of a management strategy with the patient as a good clinical practice for nearly all diseases and interventions. Patients need to receive a full explanation of all therapeutical options so they can choose the best treatment in accordance with the most recent guidelines. Patients who have a limited life expectancy do not derive any benefit from surveillance, because it is inappropriate for patients who are not surgical candidates due to severe comorbidities.

The Fukuoka consensus has high sensitivity of the diagnosis of IPMN and prediction of malignancy [57], although the cyst size from the “high-risk stigmata” to “worrisome features” is still a matter of controversy [57–60]. A systematic review of the literature suggests that size >3 cm increased the risk of malignancy by approximately 3 times and the presence of a solid component increased the risk of malignancy approximately eight times [58].

8.1. MD-IPMN

The management depends on the degree of ductal dilation, ≥ 10 mm, if the duct is (Figure 7)

- **≥ 10 mm in diameter:** resection of MD-IPMN is recommended for patients who have good performance status with reasonable life expectancy. This recommendation is based on the high rate of malignancy in MD-IPMN [28].
- **5–9 mm:** we need additional evaluation with EUS and fine-needle aspiration. Surgery is then indicated if there is evidence of worrisome features. But the association of malig-

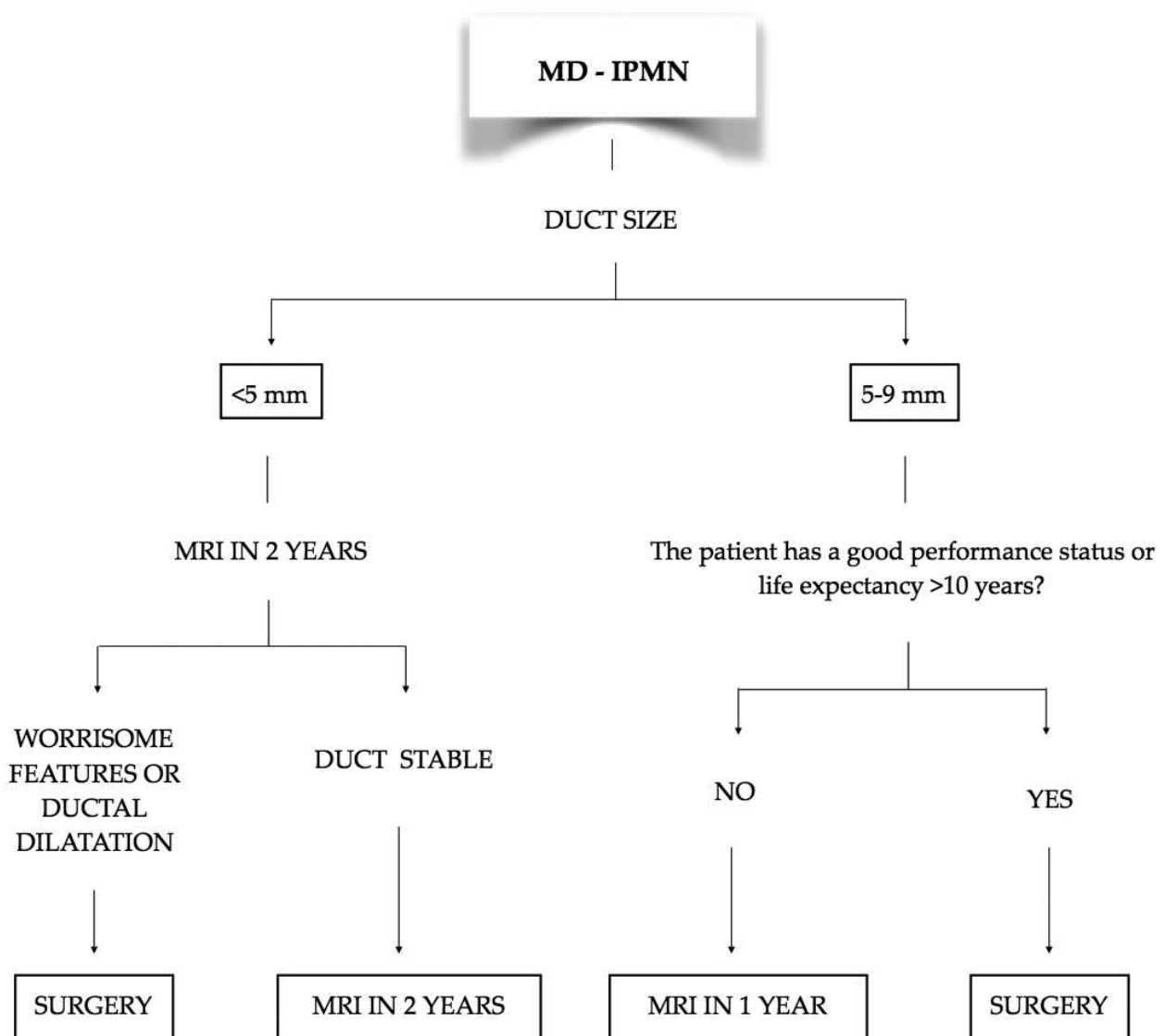


Figure 7. Follow-up for MD-IPMN <10 mm.

nancy with this degree of pancreatic duct dilation has not been well characterized. If the patient has a longer life expectancy, up to 10 years, he should be operated. For patients not undergoing surgery, we perform a magnetic retrograde cholangiopancreatography (MRCP) a year later. Surgery should be considered if the duct increases in size or if intramural nodules develop. If the duct is stable, we should repeat imaging every 2 years and continue it as long as the patient is a good surgical candidate.

- **<5 mm:** follow-up with MRCP in 2 years. As with other IPMNs, surgery is indicated if the duct increases in size or if intramural nodules develop. If the duct is stable on repeat imaging, we lengthen the surveillance interval to every 2–3 years and continue surveillance as long as the patient remains a good surgical candidate.

8.2. BD-IPMN

Resection is generally indicated if there are high-risk stigmata and if patient has symptoms attributable to the IPMN. Besides, surgery is indicated if there is evidence of worrisome features or positive cytology. We must always take into account the patient's age, life expectancy, and performance status [28] (**Figure 8**)

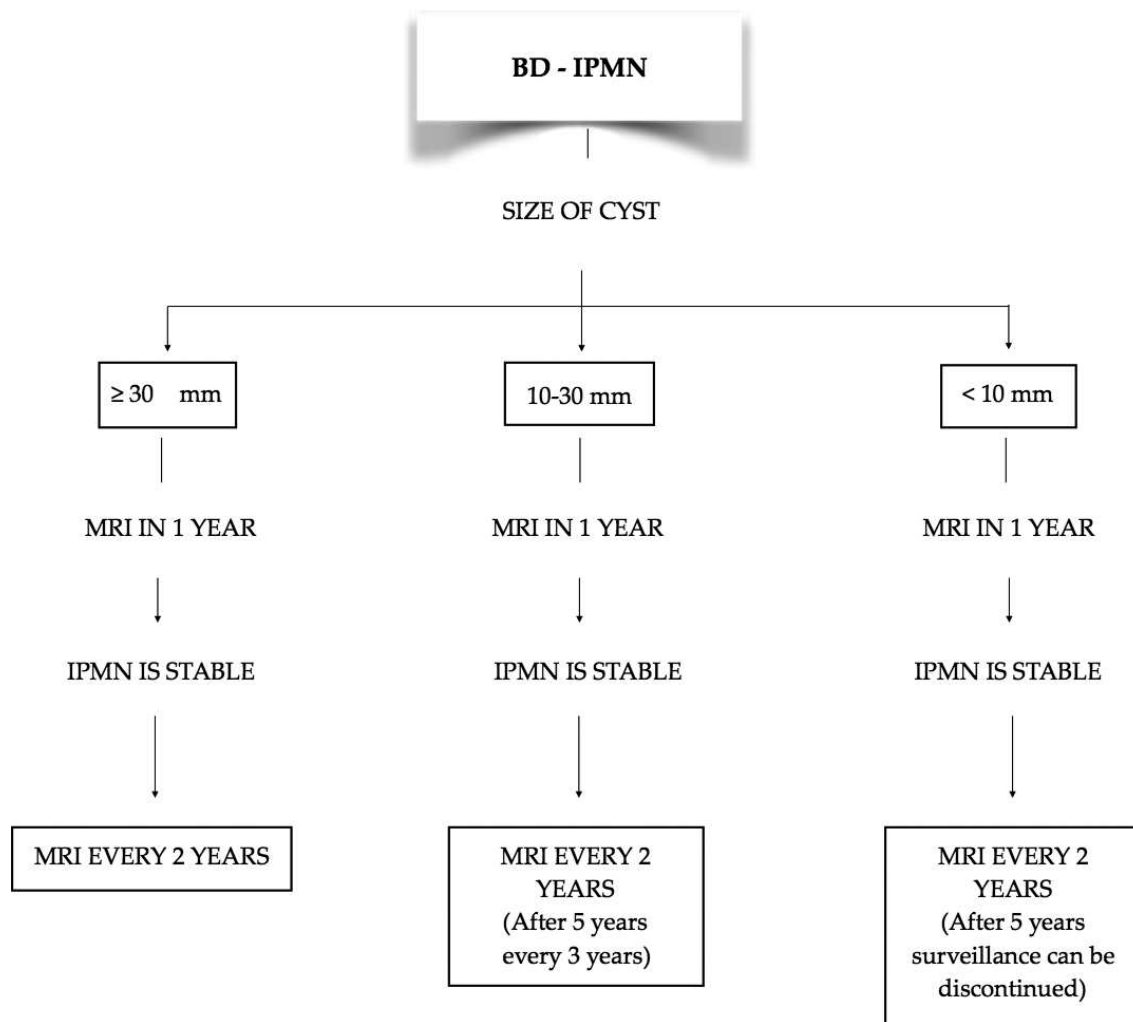
- **≥30 mm:** repeat MRCP in 1 year. If the IPMN is stable, continue surveillance with MRCP every 2 years.
- **10–30 mm:** repeat MRCP in 1 year. If the IPMN is stable, continue surveillance with MRCP every 2 years. After 5 years, the surveillance interval can be lengthened to every 3 years.
- **<10 mm:** repeat in 1 year. If the IPMN is stable, continue surveillance with MRCP every 2 years. After 5 years, surveillance can be discontinued.

Follow-up is made if the patient is a good surgical candidate. If, during surveillance, there are changes in the IPMN, a EUS-FNA should be performed.

MRI is the preferred surveillance imaging modality over computed tomography. The length of surveillance for IPMN is another concern for every clinician. If there is no change in size or characteristics, the AGA suggests that patients without worrisome pancreatic features undergo MRI for surveillance in 1 year and then every 2 years after, for a total of 5 years. The review of the literature suggests that the risk of malignant transformation of pancreatic cysts is approximately 0.24% per year. The risk of cancer in cysts without a significant change over a 5-year period is lower but this recommendation has very low evidence quality. Therefore, more studies are needed [45]. In addition, the Fukuoka consensus suggests for BD-IPMN follow-up: yearly follow-up if lesion is <10 mm in size, 6–12 monthly follow-up for lesions between 10 and 20 mm, and 3–6 monthly follow-up for lesions >20 mm [28]. The optimal surveillance approach, however, remains unclear.

8.3. Combined main duct and branch duct IPMN

Each lesion is managed, as it would be if it were the only lesion.



- If during surveillance there are any changes in the IPMN (increase in size, development of a solid component, or development/progression of main pancreatic ductal dilation), an EUS-FNA should be performed for further evaluation.
- The decision to recommend surgery or to continue surveillance is then based on the EUS-FNA results

Figure 8. Follow-up algorithm for BD-IPMN.

8.3.1. Surveillance following surgery

- Noninvasive IPMN: the risk of developing a recurrence in the remaining pancreas is at least 5%. So we have to perform the follow-up with MRCP by including a lengthening in

the surveillance interval if no changes are detected after several years. If there is another nonresected IPMN, follow-up should continue as stated above [23, 61].

- Invasive carcinoma: studies say that the risk of IPMN recurrence is 25–50% [62], and it recommended surveillance every 6 months [28]. If we diagnose patients, a recurrence of IPMN will need EUS for evaluation.

Acknowledgements

We would like to recognize the work of Doreen Carroll helping with the reviewing and editing of the article, and Dr. Lidia Alcalá Mata for the help obtaining MRCP images.

Author details

Natalia Zambudio Carroll^{1*}, Betsabé Reyes² and Laureano Vázquez¹

*Address all correspondence to: nataliazambudio@gmail.com

1 Department of Surgery, Hospital San Agustín, Linares, Spain

2 Department of Surgery, Hospital Nuestra Señora de la Candelaria, Tenerife, Spain

References

- [1] Tanaka M, Fernández-del Castillo C, Adsay V, Chari S, Falconi M, Jang J-Y, et al. International consensus guidelines 2012 for the management of IPMN and MCN of the pancreas. *Pancreatology*. 2012;12(3):183–97.
- [2] Kobari M, Egawa S, Shibuya K, et al. Intraductal papillary mucinous tumors of the pancreas comprise 2 clinical subtypes: Differences in clinical characteristics and surgical management. *Arch Surg*. 1999 Oct 1;134(10):1131–6.
- [3] Terris B, Ponsot P, Paye F, Hammel P, Sauvanet A, Molas G, et al. Intraductal papillary mucinous tumors of the pancreas confined to secondary ducts show less aggressive pathologic features as compared with those involving the main pancreatic duct. *Am J Surg Pathol* [Internet]. 2000;24(10):1374–1375.
- [4] Furukawa T, Hatori T, Fujita I, Yamamoto M, Kobayashi M, Ohike N, et al. Prognostic relevance of morphological types of intraductal papillary mucinous neoplasms of the pancreas. *Gut*. 2011 Apr 1;60(4):509–16.
- [5] Grützmann R, Post S, Saeger HD, Niedergethmann M. Intraductal papillary mucinous neoplasia (IPMN) of the pancreas: its diagnosis, treatment, and prognosis. *Dtsch Arztebl Int*. 2011 Nov;108(46):788–94.

- [6] Farrell JJ. Prevalence, diagnosis and management of pancreatic cystic neoplasms: current status and future directions. *Gut Liver*. 2015 Sep;9(5):571–89.
- [7] Shi C, Hruban RH. Intraductal papillary mucinous neoplasm. *Hum Pathol*. 2012;43(1):1–16.
- [8] Gardner TB, Glass LM, Smith KD, Ripple GH, Barth RJ, Klibansky DA, et al. Pancreatic cyst prevalence and the risk of mucin-producing adenocarcinoma in United States adults. *Am J Gastroenterol*. 2013 Oct;108(10):1546–50.
- [9] Nagata N, Kawazoe A, Mishima S, Wada T, Shimbo T, Sekine K, et al. Development of pancreatic cancer, disease-specific mortality, and all-cause mortality in patients with nonresected IPMNs: a long-term cohort study. *Radiology*. 2015 Jul 13;278(1):125–34.
- [10] Tanaka M. International consensus on the management of intraductal papillary mucinous neoplasm of the pancreas. *Ann Transl Med*. 2015 Nov 3(19):286.
- [11] Yamada S, Fujii T, Murotani K, Kanda M, Sugimoto H, Nakayama G, et al. Comparison of the international consensus guidelines for predicting malignancy in intraductal papillary mucinous neoplasms. *Surgery*. 2016 Mar;159(3):878–84.
- [12] Goh BKP, Lin Z, Tan DMY, Thng C-H, Khor CJL, Lim TKH, et al. Evaluation of the fukuoka consensus guidelines for intraductal papillary mucinous neoplasms of the pancreas: results from a systematic review of 1,382 surgically resected patients. *Surgery*. 2015 Nov;158(5):1192–202.
- [13] Fritz S, Buchler M, Klaus M, Bergmann F, Strobel O. Pancreatic main-duct involvement in branch-duct IPMNs: an underestimated risk. *Ann Surg*. 2014 Nov;260(5):848–56.
- [14] Crippa S, Capurso G, Cammà C, Fave GD, Castillo CF, Falconi M. Risk of pancreatic malignancy and mortality in branch-duct IPMNs undergoing surveillance: a systematic review and meta-analysis. *Dig Liver Dis*. 2016 May;48(5):473–9.
- [15] Han DH, Lee H, Park JY, Kwon W, Heo JS, Choi SH, et al. Validation of international consensus guideline 2012 for intraductal papillary mucinous neoplasm of pancreas. *Ann Surg Treat Res*. 2016 Mar;90(3):124–30.
- [16] Sugiyama M, Atomi Y. Extrapancreatic neoplasms occur with unusual frequency in patients with intraductal papillary mucinous tumors of the pancreas. *Am J Gastroenterol*. 1999 Feb;94(2):470–3.
- [17] Choi M, Kim S, Han S, Jang J. High incidence of extrapancreatic neoplasms in patients with intraductal papillary mucinous neoplasms. *Arch Surg*. 2006 Jan;141(1):51–6.
- [18] Brugge WR. Diagnosis and management of cystic lesions of the pancreas. *J Gastrointest Oncol*. 2015 Aug;6(4):375–88.
- [19] Farrell JJ, Brugge WR. Intraductal papillary mucinous tumor of the pancreas. *Gastrointest Endosc*. 2002 May;55(6):701–14.

- [20] Sahani DV, Lin DJ, Venkatesan AM, Sainani N, Mino-Kenudson M, Brugge WR, et al. Multidisciplinary approach to diagnosis and management of intraductal papillary mucinous neoplasms of the pancreas. *Clin Gastroenterol Hepatol*. 2009 Mar;7(3):259–69.
- [21] Yoon WJ, Brugge WR. Pancreatic cystic neoplasms: diagnosis and management. *Mod Manag Benign Malig Pancreat Dis*. 2012 Mar;41(1):103–18.
- [22] Brugge WR, Lauwers GY, Sahani D, Fernandez-del Castillo C, Warshaw AL. Cystic neoplasms of the pancreas. *N Engl J Med*. 2004 Sep 16;351(12):1218–26.
- [23] Salvia R, Castillo CF, Bassi C, Thayer SP, Falconi M, Mantovani W, et al. Main-duct intraductal papillary mucinous neoplasms of the pancreas: clinical predictors of malignancy and long-term survival following resection. *Ann Surg*. 2004 May;239(5):678–87.
- [24] Sohn TA, Yeo CJ, Cameron JL, Hruban RH, Fukushima N, Campbell KA, et al. Intraductal papillary mucinous neoplasms of the pancreas: an updated experience. *Ann Surg*. 2004 Jun;239(6):788–99.
- [25] Capurso G, Boccia S, Salvia R, Del Chiaro M, Frulloni L, Arcidiacono PG, et al. Risk factors for intraductal papillary mucinous neoplasm (IPMN) of the pancreas: a multicentre case-control study. *Am J Gastroenterol*. 2013 Jun;108(6):1003–9.
- [26] Roch AM, Rosati CM, Cioffi JL, Ceppa EP, DeWitt JM, Al-Haddad MA, et al. Intraductal papillary mucinous neoplasm of the pancreas, one manifestation of a more systemic disease? *Am J Surg*. 2016 Mar;211(3):512–8.
- [27] Weinberg BM, Spiegel BM, Tomlinson JS, Farrell JJ. Asymptomatic pancreatic cyst neoplasms: maximizing survival and quality of life using markov-based clinical nomograms. *Gastroenterology*. 2010 Feb;138(2):531–40.
- [28] Tanaka M, Fernández-del Castillo C, Adsay V, Chari S, Jang J-Y, Kimura W, et al. International consensus guidelines 2012 for the management of IPMN and MCN of the pancreas. *Pancreatol*. 2012;12:183–97.
- [29] American Gastroenterological Association Institute Guideline on the Diagnosis and Management of Asymptomatic Neoplastic Pancreatic Cysts. Vege V, Ziring B, Jain R, et al. *Gastroenterology* 2015;148:819–822
- [30] Nguyen AH, Toste PA, Farrell JJ, Clerkin BM, Williams J, Muthusamy VR, et al. Current recommendations for surveillance and surgery of intraductal papillary mucinous neoplasms may overlook some patients with cancer. *J Gastrointest Surg Off J Soc Surg Aliment Tract*. 2015 Feb;19(2):258–65.
- [31] Ridditid W, DeWi JM, Schmidt CM, Roch A, Stuart JS, Sherman S, et al. Management of branch-duct intraductal papillary mucinous neoplasms: a large single-center study to assess predictors of malignancy and long-term outcomes. *Gastrointest Endosc*. 2016 Sep;84(3):436–45

- [32] Michaels PJ, Brachtel EF, Bounds BC, Brugge WR, Bishop Pitman M. Intraductal papillary mucinous neoplasm of the pancreas. *Cancer Cytopathol.* 2006 Jun 25;108(3):163–73.
- [33] Pitman MB, Centeno BA, Daglilar ES, Brugge WR, Mino-Kenudson M. Cytological criteria of high-grade epithelial atypia in the cyst fluid of pancreatic intraductal papillary mucinous neoplasms. *Cancer Cytopathol.* 2014 Jan 1;122(1):40–7.
- [34] Molin MD, Matthaei H, Wu J, Blackford A, Debeljak M, Rezaee N, et al. Clinicopathological correlates of activating GNAS mutations in intraductal papillary mucinous neoplasm (IPMN) of the pancreas. *Ann Surg Oncol.* 2013 Nov;20(12):3802–8.
- [35] Sahara K, Castillo CF. Intraductal papillary mucinous neoplasms. *Curr Opin Gastroenterol.* 2015 Sep;31(5):424–9.
- [36] Kanda M, Sadakari Y, Borges M, Topazian M, Farrell J, Syngal S, et al. Mutant TP53 in duodenal samples of pancreatic juice from patients with pancreatic cancer or high-grade dysplasia. *Clin Gastroenterol Hepatol Off Clin Pract J Am Gastroenterol Assoc.* 2013 Jun;11(6):719–30.e5.
- [37] Matthaei H, Wu J, Molin M, Shi C, Perner S, Kristiansen G, et al. GNAS sequencing identifies IPMN-specific mutations in a subgroup of diminutive pancreatic cysts referred to as “incipient IPMNs.” *Am J Surg Pathol.* 2014 Mar;38(3):360–3.
- [38] Sakorafas GH, Smyrniotis V, Reid-Lombardo KM, Sarr MG. Primary pancreatic cystic neoplasms revisited. Part III. Intraductal papillary mucinous neoplasms. *Surg Oncol.* 2011 Jun;20(2):e109–18.
- [39] Hara T, Ikebe D, Odaka A, Sudo K, Nakamura K, Yamamoto H, et al. Preoperative histological subtype classification of intraductal papillary mucinous neoplasms (IPMN) by pancreatic juice cytology with MUC stain. *Ann Surg.* 2013;257(6):1103–11.
- [40] Kang MJ, Lee KB, Jang J-Y, Kwon W, Park JW, Chang YR, et al. Disease spectrum of intraductal papillary mucinous neoplasm with an associated invasive carcinoma: invasive IPMN versus pancreatic ductal adenocarcinoma-associated IPMN. *Pancreas.* 2013 Nov;42(8):1267–74.
- [41] Saito M, Ishihara T, Tada M, Tsuyuguchi T, Mikata R, Sakai Y, et al. Use of F-18 fluorodeoxyglucose positron emission tomography with dual-phase imaging to identify intraductal papillary mucinous neoplasm. *Clin Gastroenterol Hepatol.* 2013 Feb;11(2):181–6.
- [42] Sperti C, Pasquali C, Chierichetti F, Liessi G, Ferlin G, Pedrazzoli S. Value of 18-fluorodeoxyglucose positron emission tomography in the management of patients with cystic tumors of the pancreas. *Ann Surg.* 2001 Nov;234(5):675–80.
- [43] Fernández-del Castillo C, Targarona J, Thayer SP, Rattner DW, Brugge WR, Warshaw AL. Incidental pancreatic cysts: clinicopathologic characteristics and comparison with symptomatic patients. *Arch Surg.* 1960. 2003 Apr;138(4):427–34.

- [44] Tanaka M, Chari S, Adsay V, Carlos Castillo F-D, Falconi M, Shimizu M, et al. International consensus guidelines for management of intraductal papillary mucinous neoplasms and mucinous cystic neoplasms of the pancreas. *Pancreatology*. 2006;6(1-2):17-32.
- [45] Vege SS, Ziring B, Jain R, Moayyedi P, Adams MA, Dorn SD, et al. American Gastroenterological Association Institute guideline on the diagnosis and management of asymptomatic neoplastic pancreatic cysts. *Gastroenterology*. 2015 Apr;148(4):819-22.
- [46] Das A, Wells CD, Nguyen CC. Incidental cystic neoplasms of pancreas: what is the optimal interval of imaging surveillance [quest]. *Am J Gastroenterol*. 2008 Jul;103(7):1657-62.
- [47] Berland LL, Silverman SG, Gore RM, Mayo-Smith WW, Megibow AJ, Yee J, et al. Managing incidental findings on abdominal CT: White Paper of the ACR Incidental Findings Committee. *J Am Coll Radiol*. 2010 Oct;7(10):754-73.
- [48] Tanaka M. Controversies in the management of pancreatic IPMN. *Nat Rev Gastroenterol Hepatol*. 2011 Jan;8(1):56-60.
- [49] Hwang DW, Jang J-Y, Lee SE, Lim C-S, Lee KU, Kim S-W. Clinicopathologic analysis of surgically proven intraductal papillary mucinous neoplasms of the pancreas in SNUH: a 15-year experience at a single academic institution. *Langenbecks Arch Surg*. 2012;397(1):93-102.
- [50] Sugiyama M, Izumisato Y, Abe N, Masaki T, Mori T, Atomi Y. Predictive factors for malignancy in intraductal papillary-mucinous tumours of the pancreas. *Br J Surg*. 2003 Oct 1;90(10):1244-9.
- [51] Scheiman JM, Hwang JH, Moayyedi P. American Gastroenterological Association technical review on the diagnosis and management of asymptomatic neoplastic pancreatic cysts. *Gastroenterology*. 148(4):824-48.e22.
- [52] Jang J-Y, Kim S-W, Ahn YJ, Yoon Y-S, Choi MG, Lee KU, et al. Multicenter analysis of clinicopathologic features of intraductal papillary mucinous tumor of the pancreas: is it possible to predict the malignancy before surgery? *Ann Surg Oncol*. 2005;12(2):124-32.
- [53] Crippa S, Tamburrino D, Partelli S, Salvia R, Germain S, Bassi C, et al. Total pancreatectomy: indications, different timing, and perioperative and long-term outcomes. *Surgery*. 2011 Jan;149(1):79-86.
- [54] Stauffer JA, Nguyen JH, Heckman MG, Grewal MS, Dougherty M, Gill KRS, et al. Patient outcomes after total pancreatectomy: a single centre contemporary experience. *HPB*. 2009 Sep;11(6):483-92.
- [55] Swartz MJ, Hsu CC, Pawlik TM, Winter J, Hruban RH, Guler M, et al. Adjuvant chemoradiotherapy after pancreatic resection for invasive carcinoma associated with intraductal papillary mucinous neoplasm of the pancreas. *Int J Radiat Oncol Biol Phys*. 2010 Mar 1;76(3):839-44.

- [56] McMillan MT, Lewis RS, Drebin JA, Teitelbaum UR, Lee MK, Roses RE, et al. The efficacy of adjuvant therapy for pancreatic invasive intraductal papillary mucinous neoplasm (IPMN). *Cancer*. 2016 Feb 15;122(4):521–33.
- [57] Kim, Kyung Won KW. Imaging features to distinguish malignant and benign branch-duct type intraductal papillary mucinous neoplasms of the pancreas: a meta-analysis. *Ann Surg*. 2014 Jan;259(1):72–81.
- [58] Anand N, Sampath K, Wu BU. Cyst features and risk of malignancy in intraductal papillary mucinous neoplasms of the pancreas: a meta-analysis. *Clin Gastroenterol Hepatol*. 2013 Aug;11(8):913–21.
- [59] Wong J, Weber J, A. Centeno B, Vignesh S, Harris CL, Klapman JB, et al. High-grade dysplasia and adenocarcinoma are frequent in side-branch intraductal papillary mucinous neoplasm measuring less than 3 cm on endoscopic ultrasound. *J Gastrointest Surg*. 2013;17(1):78–85.
- [60] Nakata K, Ohuchida K, Aishima S, Sadakari Y, Kayashima T, Miyasaka Y, et al. Invasive carcinoma derived from intestinal-type intraductal papillary mucinous neoplasm is associated with minimal invasion, colloid carcinoma, and less invasive behavior, leading to a better prognosis. *Pancreas* 2011;40(4):581–7.
- [61] Kang MJ, Jang J-Y, Lee KB, Chang YR, Kwon W, Kim S-W. Long-term prospective cohort study of patients undergoing pancreatectomy for intraductal papillary mucinous neoplasm of the pancreas: implications for postoperative surveillance. *Ann Surg*. 2014;260(2):356–63.
- [62] Niedergethmann M, Grützmann R, Hildenbrand R, Dittert D, Aramin N, Franz M, et al. Outcome of invasive and noninvasive intraductal papillary-mucinous neoplasms of the pancreas (IPMN): a 10-year experience. *World J Surg*. 2008;32(10):2253–60.

