

We are IntechOpen, the world's leading publisher of Open Access books Built by scientists, for scientists

4,800

Open access books available

122,000

International authors and editors

135M

Downloads

Our authors are among the

154

Countries delivered to

TOP 1%

most cited scientists

12.2%

Contributors from top 500 universities



WEB OF SCIENCE™

Selection of our books indexed in the Book Citation Index
in Web of Science™ Core Collection (BKCI)

Interested in publishing with us?
Contact book.department@intechopen.com

Numbers displayed above are based on latest data collected.
For more information visit www.intechopen.com



Glaucoma Surgery and Aqueous Dynamics

Parul Ichhpujani

Additional information is available at the end of the chapter

<http://dx.doi.org/10.5772/66144>

Abstract

Reduction in intraocular pressure is the only proven method to treat glaucoma. When medical treatment does not achieve adequate intraocular pressure reduction with acceptable adverse effects, laser or incisional surgeries are introduced. In this chapter, we discuss the physiological basis for the established surgical procedures as well as the newer surgical procedures. Most new surgical innovations have been designed according to natural physiology by routing aqueous as nature intended, through the Schlemm's canal. This has been possible because of better understanding of the outflow system and the availability of micro-technology to manipulate it.

Keywords: trabeculectomy, glaucoma drainage device, minimally invasive glaucoma surgery, outflow resistance

1. Introduction

Glaucoma is defined as a group of disorders that result in death of ganglion cells due to axonal damage at the level of the lamina cribrosa of the optic nerve.

Intraocular pressure (IOP) is considered to be the only alterable risk factor for diagnosis and treatment of glaucoma. IOP reduction is attained either by increasing outflow or by reducing aqueous humor production [1]. Therefore, basic understanding of aqueous humor circulation is important for successful management of glaucoma. Aqueous humor pathways have been discussed in detail in a prior chapter in the book. This chapter focuses on the various surgical modalities available to reduce or bypass the outflow resistance.

2. Site of outflow resistance

Evidence suggests that the majority of outflow resistance in the trabecular meshwork is generated in the inner wall endothelium of Schlemm's canal and its underlying matrix in the juxtacanalicular trabecular meshwork [2]. Rosenquist et al. has shown that following trabeculectomy, close to half (49%) of outflow resistance is eliminated at a perfusion pressure of 7 mm Hg [3]. In another study, Grant has shown that nearly two-third (71%) resistance is eliminated at a perfusion pressure of 25 mm Hg [4]. Schuman et al. have shown that 35% of resistance is eliminated at a perfusion pressure at 10 mm Hg, when 1 O'clock hour of the tissue from the outer wall of Schlemm's canal was ablated using the excimer laser [5]. These studies suggest that one-third to half of the outflow resistance lies distal to the inner wall of Schlemm's canal at normal pressure and partly outflow resistance is related to pressure-dependent changes in the outflow pathway. As the intraocular pressure increases, Schlemm's canal collapses and reduces outflow and effective filtration.

3. Restoration of the outflow facility

Excision of sites causing increased outflow resistance would result in restoration of outflow. It is not possible for a surgeon to precisely pinpoint the area which needs to be excised for an individual patient, therefore, logically, surgeons would like to address all aspects of the outflow system.

The current gold standard, trabeculectomy, has done well for many medically refractory glaucoma patients. Despite its efficacy in lowering IOP, ease of the surgical procedure, it is fraught with potential sight threatening issues. Glaucomatologists and bioengineers are leaving no stone unturned to find a better alternative to address the flaws of trabeculectomy.

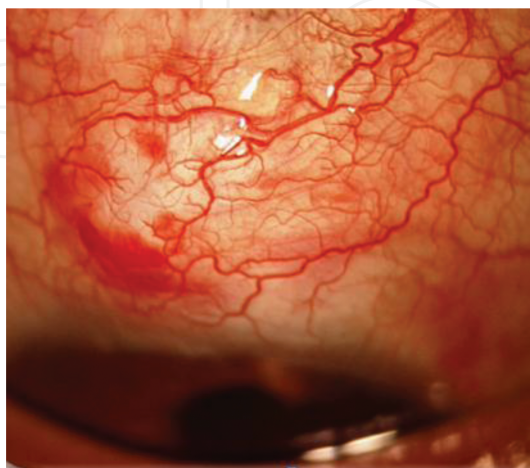


Figure 1. Failing trabeculectomy bleb with corkscrewing of conjunctival vessels secondary to scarring.

3.1. Surgeries addressing trabecular meshwork

- *Trabeculectomy*: Opening a pathway through the meshwork, either by removing tissue or punching a hole (trabeculectomy) encourages aqueous outflow into Schlemm's canal.

Despite modulation of the subconjunctival space into a porous matrix, the procedure is **not** a physiological bypass and remains dependent on the size of the ostium, tension in the sclera flap, as well as wound healing and its modulation [6].

A decrease in the hydraulic conductivity of the bleb capsule results in an increase in fluid pressure within the bleb, altering its mechanical and biochemical environment resulting in progressive scarring (**Figure 1**) and consequent bleb failure [7].

In addition, these incisional surgeries can result in decreased quality of life due to bleb-related foreign body sensation, induced astigmatism, and secondary cataracts.

- *Trabeculectomy with collagen implants*: The development of tissue engineering has offered a plausible solution to reduce postoperative fibrosis and scarring. The use of collagen-glycosaminoglycan copolymers leads to random and relatively loose reorganization of regenerating myofibroblasts, fibroblasts, and the secreted extracellular collagen matrix, resulting in reduced scar formation [8]. These implants offer a potential alternative to antifibrosis agents as they produce more loosely organized, yet more abundant bleb tissue than a bleb created without antimetabolites.

Ologen (Aeon Astron Corporation, Taipei, Taiwan) (also named iGen) is the commonly available collagen implant, which consists of >90% lyophilized porcine atelocollagen and <10% lyophilized porcine glycosaminoglycan. This implant also acts as a spacer to mechanically separate the subconjunctival and episcleral tissues to prevent fibrosis. The implant is placed subconjunctivally over the scleral flap posteriorly and only a small portion covers the scleral flap (**Figure 2**), else the implant would act as a mechanical tamponade and prevent outflow from the subscleral space [9].

- *iStent*: Trabecular bypass devices such as iStent reduce IOP by bypassing the thin layer of juxtacanalicular tissue, without the need for creating a hole in the sclera and a filtration bleb. iStent bypasses the meshwork, creating a direct route from the anterior chamber into Schlemm's canal (**Figure 3**).

There is also a second-generation model called the iStent inject (Glaukos Corporation), which has been CE marked for use in Europe. It contains a head facing the anterior chamber that is 230 μm in width with four inlets for the passage of aqueous into the device and out through Schlemm's canal.

Zhou and Smedley have shown in their cultured autopsy eye perfusion experiments that adding successive bypass shunts produces a step-wise increase in outflow. The first shunt has the maximum IOP reducing effect, reducing IOP from 21.4 ± 3.8 to 12.4 ± 4.2 mm Hg, successive addition of up to four stents placed into SC produced step-wise reduction in system pressure [10].

Hunter et al. showed in anterior segment perfusion models with the iStent inject that outflow facility increases from $0.16 \pm 0.05 \mu\text{L}/\text{min}/\text{mm Hg}$ to 0.38 ± 0.23 ($P < 0.03$, $n = 7$), and then an additional iStent inject further increased outflow facility to 0.78 ± 0.66 ($n = 2$) [11].

- *Ex-PRESS*: The Ex-PRESS device relies on nonphysiologic subconjunctival flow as its mechanism of IOP lowering. In eyes with prior failed trabeculectomies, Ex-PRESS can help to reestablish the aqueous flow without having to repeat the original procedure [12]. The Ex-PRESS fits easily in the middle ground between a repeat trabeculectomy and a larger glaucoma drainage device like a Baerveldt, Molteno, or an Ahmed tube shunt.
- *Viscocanalostomy*: In viscocanalostomy, inner wall of the endothelium is disrupted and communication is established between the lumen of the canal and the juxtacanalicular space. Bed of canal is scraped with a forceps or trabecular aspiration. This leads to the removal of a homogenous external trabecular membrane in one coherent plane that allows aqueous humor to egress through the remaining inner trabecular layers [13].

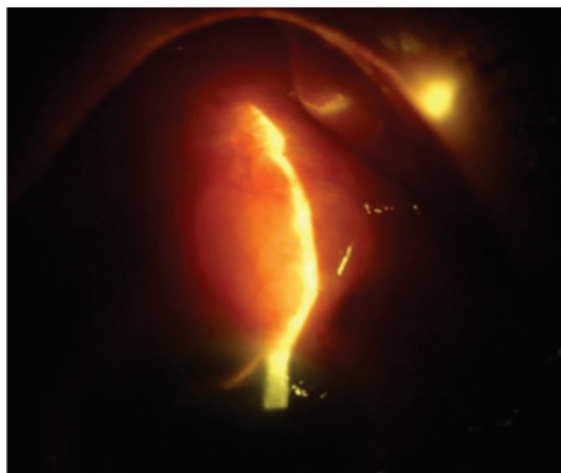


Figure 2. Ologen implant in subconjunctival space.

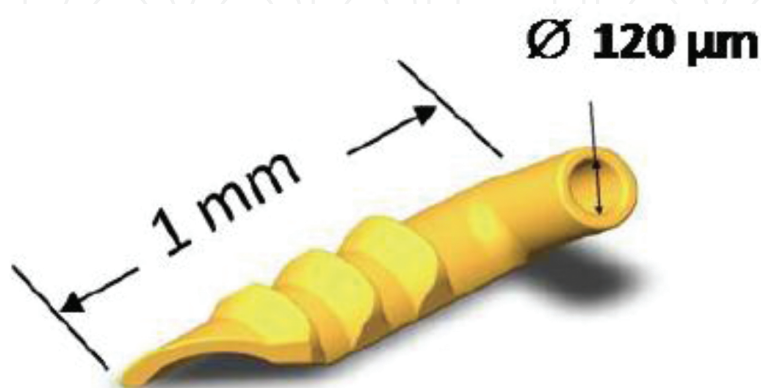


Figure 3. First-generation iStent.

3.2. Surgeries addressing Schlemm's canal

The detailed mechanism of aqueous humor dynamics across the endothelial lining of Schlemm's canal from the Juxtacanalicular trabecular meshwork (JCT) via giant vacuoles and pores has been discussed in detail in a prior chapter. The number of giant pores and vacuoles is less in glaucomatous eyes as compared to normal eyes, thus accounting for the increase in outflow resistance [14].

- *Viscocanalostomy*: Dilating Schlemm's canal with viscoelastic material may remove the stenosis-related resistance, as discussed earlier.
- *Canaloplasty*: Canaloplasty is an ab externo procedure that entails 360° intubation of Schlemm's canal (**Figure 4**), along with suture-assisted distension of the canal in order to restore physiologic outflow via the conventional pathway without the formation of a fistula or bleb. Potentially, the suture tension may increase TM permeability, similar to the action of pilocarpine [15] as well as help to maintain a patent canal lumen, similar to the intraocular tensioning suture [16].

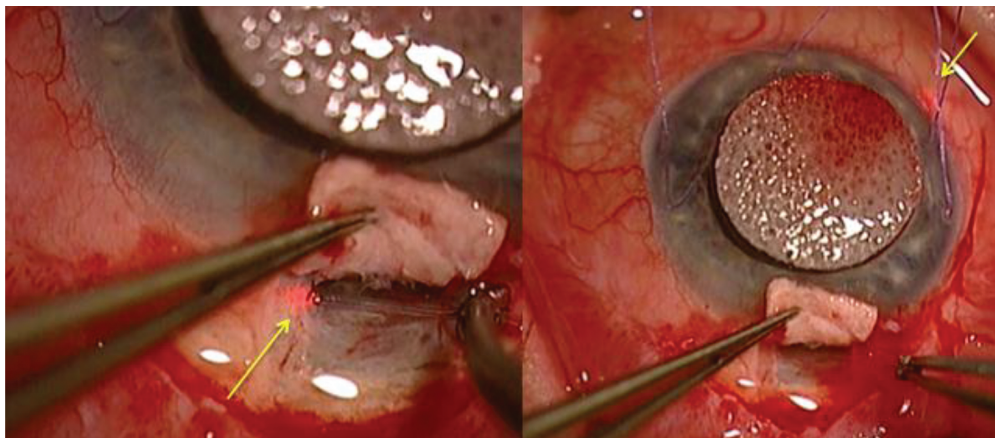


Figure 4. Nonpenetrating Schlemm's canaloplasty using the iScience cannula.

3.3. Surgeries addressing collector channels

The collector channels connecting the aqueous veins and the distal part of the outflow pathways originate in the outer wall of Schlemm's canal. These collector channels are not evenly distributed around Schlemm's canal circumferentially. The outflow is closer to areas with larger collector channels.

- *Minimally invasive glaucoma surgery (MIGS)*: The advent of microinvasive glaucoma surgery has brought new dimension to glaucoma treatment. Minimally invasive glaucoma surgery is likely to provide medication-sparing, conjunctival-sparing, ab interno, more physiological approach to IOP reduction for patients with mild-to-moderate glaucoma that is safer than traditional incisional glaucoma surgery.

MIGS stents, e.g., iStent, Hydrus, give better results when positioned close to a patent collector channel, thus increasing the possibility of surgical success.

- *Canaloplasty*: Schuman et al. have shown that when the IOP is elevated, trabecular meshwork herniates into the ostia of collector channels and reduces the passage for aqueous outflow. Cannulating the whole of Schlemm's canal, as in canaloplasty, and injecting viscoelastic material may "pop" open these herniations and enable 360° access to collector channel ostia for the egressing aqueous [17].

3.4. Surgeries addressing episcleral venous system

Theoretically, IOP should directly correlate with the episcleral venous pressure (EVP). However, when the entire TM is removed, 25% of total resistance still remains, underscoring the importance of EVP measurement in an accurate and reproducible way [18]. Episcleral venous pressure is highly variable and may range from 3 to 14 mm Hg. In addition, if the pressure gradient differential is low and resistance is also located distally in the episcleral venous system, restorative outflow surgery has less chance of being effective than if the pressure gradient differential is high.

In cases with elevated episcleral venous pressure, incisional filtration surgery can help lower the IOP, but it is associated with a high incidence of choroidal effusion or hemorrhage.

Preoperative IOP reduction may be attained by intravenous mannitol and other systemic antiglaucoma medications. Additionally, the flow through the scleral flap may be adjusted to allow for a higher IOP in the early postoperative period. Using a releasable suture allows controlled reduction of IOP. Drainage implants may also be a good choice if the flow through the implant is kept to a minimum in the early postoperative period.

Another way of classifying various surgical procedures depends on how the procedure influences the aqueous dynamics.

3.4.1. Surgeries that bypass conventional aqueous outflow pathway

- Trabeculectomy
- Nonpenetrating deep sclerectomy
- Glaucoma drainage devices:

Most conventional shunts consist of a tube designed to shunt aqueous from the anterior chamber to a distal plate via a tube to the posterior subconjunctival space, from where aqueous is directly absorbed into the sclera and episcleral vasculature to enter the orbital circulation, bypassing both the conventional and uveoscleral pathways. The primary tube-plate junction includes a rim through which the tube empties onto the explant plate surface to avoid closure of the tube orifice following eventual encapsulation of the device by fibrosis [19].

- Viscoanalostomy, canaloplasty

- Trabeculotomy
- Goniotomy
- Ab interno trabeculotomy or Trabectome surgery:

Selective removal of the TM and inner wall of SC is performed using the Trabectome; while leaving the rest of the outflow system (outer wall of SC, collector channels, and aqueous veins) relatively intact. A strip of TM and inner wall of SC spanning 80–100° is ablated and removed under direct gonioscopic visualization. The simultaneous aspiration of tissue debris reduces the inflammatory stimuli and opportunity for scarring among shards of incised or ruptured tissues remaining after traditional goniotomy or trabeculotomy [20].

3.4.2. Surgeries that increase the uveoscleral outflow

- ExPRESS shunt
- iStent
- Suprachoroidal gold SOLX shunt:

This shunt is an ab externo suprachoroidal trans-limbal shunt and works as a “controlled” cyclodialysis, draining aqueous into the suprachoroidal space. The anterior end of this 24-karat gold device is placed into the anterior chamber over the sclera spur via a scleral incision and the posterior end positioned in the suprachoroidal space (**Figure 5**). It includes several channels through its body. Aqueous flows both through the channels in the body of the shunt and around its body [21].

- Cypass:

This mini shunt is placed in the supraciliary and suprachoroidal space to increase uveoscleral outflow by creating a small cyclodialysis (**Figure 6**) [22].

Along the length of the stent are microholes that allow for circumferential egress of aqueous into the suprachoroidal space and the distal end of the stent allows longitudinal egress of fluid.

- Hydrus:

Hydrus is implanted using a preloaded injector via a clear corneal incision and is inserted into and sits within Schlemm’s canal, wherein it extends 3 clock hours. It does not block the collector channel ostia in the posterior portion of Schlemm’s canal as it has a scaffold design, and it has a 1 mm inlet portion, which resides within the anterior chamber. As a standalone procedure, it can be inserted through a 1–1.5 mm corneal incision. Once inserted into Schlemm’s canal, it can dilate it by four to five times the natural width of the canal [23].

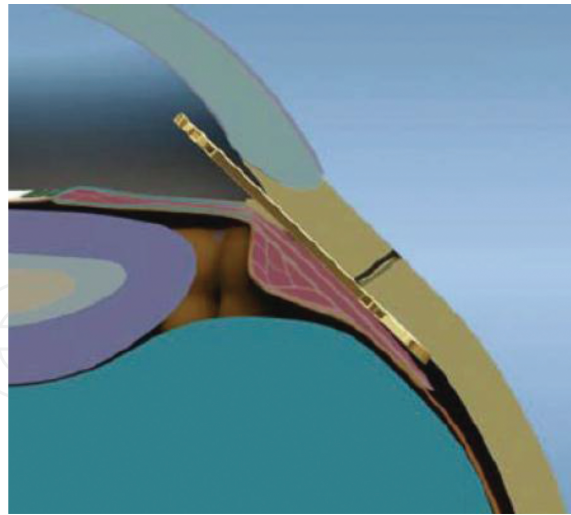


Figure 5. Gold SOLX shunt in suprachoroidal space.




Figure 6. CyPass shunt *in situ*.

3.4.3. Surgeries that decrease aqueous production

Cycloablative procedures reduce IOP by destroying the ciliary body epithelium that produces aqueous humor. Modalities include:

- Contact (transscleral) cycloablation
 - Cyclocryotherapy [24]

- Diode/Nd:YAG [25]
- Noncontact cycloablation
 - Nd:YAG/Diode
- Transpupillary argon green cyclophotocoagulation
- Endoscopic ablation

In endoscopic cyclophotocoagulation (ECP), the laser is applied under direct endoscopic view causing localized shrinkage of the ciliary processes due to thermal coagulation (**Figure 7**). This causes an initial reduction in blood supply to the ciliary processes, and a consequent reduction in aqueous production. Partial reperfusion of the ciliary body over 4–6 weeks means that the rates of hypotony and phthisis are lower than those associated with other methods of cyclodestruction.

Earlier cycloablative procedures were reserved only for refractory cases, but recent studies have shown that endocyclophotocoagulation can be used for the treatment of mild-to-moderate glaucoma. It is conjunctival-sparing, blebless, and can be combined with cataract surgery [26, 27].

Despite all the aforementioned advances, the quest for a perfectly predictable and physiological glaucoma procedure with rapid recovery and a greater margin of safety is ongoing.

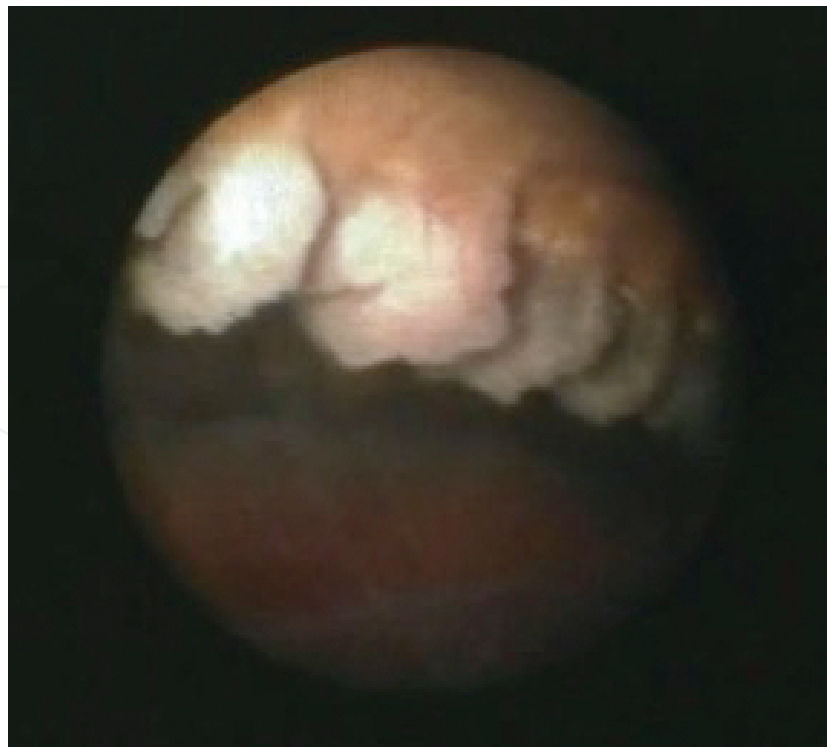

Figure 7. Shrinkage of ciliary processes following ECP.

Author details

Parul Ichhpujani

*Address all correspondence to: itsdrparul@gmail.com

Department of Ophthalmology, Glaucoma Services, Government Medical College and Hospital, Chandigarh, India

References

- [1] Ritch R, Shields M, Krupin T. *The Glaucomas: Clinical Science*. 2nd ed. St. Louis: Mosby; 1996.
- [2] Goel M, Picciani RG, Lee RK, Bhattachary SK. Aqueous humor dynamics: a review. *Open Ophthalmol J*. 2010; 4:52–59.
- [3] Rosenquist R, Epstein D, Melamed S, et al. Outflow resistance of enucleated human eyes at two different perfusion pressures and different extents of trabeculotomy. *Curr Eye Res*. 1989; 8:1233–1240.
- [4] Grant WM. Experimental aqueous perfusion in enucleated human eyes. *Arch Ophthalmol*. 1963; 69:783–801.
- [5] Schuman JS, Chang W, Wang N, de Kater AW, Allingham RR. Excimer laser effects on outflow facility and outflow pathway morphology. *Invest Ophthalmol Vis Sci*. 1999; 40(8):1676–1680.
- [6] Jea SY, Francis BA, Vakili G, Filippopoulos T, Rhee DJ. Ab interno trabeculectomy versus trabeculectomy for open-angle glaucoma. *Ophthalmology*. 2012; 119(1):36–42.
- [7] Rossier A, Uffer S, Mermoud A. Aqueous dynamics in experimental ab externo trabeculectomy. *Ophthalmic Res*. 2000; 32:165–171.
- [8] Hsu WC, Spilker MH, Yannas IV, Rubin PA. Inhibition of conjunctival scarring and contraction by a porous collagen-glycosaminoglycan implant. *Invest Ophthalmol Vis Sci*. 2000; 41:2404–2411.
- [9] Cillino S, Casuccio A, Di Pace F, Cagini C, Ferraro LL, Cillino G. Biodegradable collagen matrix implant versus mitomycin-C in trabeculectomy: five-year follow-up. *BMC Ophthalmology*. 2016;16:24. doi:10.1186/s12886-016-0198-0.
- [10] Zhou J, Smedley G. A trabecular bypass flow hypothesis. *J Glaucoma*. 2005; 14:74–83.

- [11] Hunter KS, Ffield T, Heitzmann H, Shandas R, Kahook MY. Characterization of micro-invasive trabecular bypass stents by ex vivo perfusion and computational flow modeling. *Clin Ophthalmol*. 2014; 8:499–506.
- [12] Buys YM. Trabeculectomy with Ex-PRESS: weighing the benefits and cost. *Curr Opin Ophthalmol*. 2013; 24(2):111–118.
- [13] Smit BA, Johnstone MA. Effects of viscoelastic injection into Schlemm's canal in primate and human eyes: potential relevance to viscocanalostomy. *Ophthalmology*, 2002; 109(4): 786–792.
- [14] Maepea O, Bill A. Pressures in the juxtacanalicular tissue and Schlemm's canal in monkeys. *Exp Eye Res* 1992; 54:879–883.
- [15] Flocks M. The anatomy of the trabecular meshwork as seen in tangential section. *AMA Arch Ophthalmol* 1956; 56(5):708–718.
- [16] Ashton N, Brini A, Smith R. Anatomical studies of the trabecular meshwork of the normal human eye. *Br J Ophthalmol* 1956; 40(5):257–282.
- [17] Lewis RA, von Wolff K, Tetz M, et al. Canaloplasty: circumferential viscodilation and tensioning of Schlemm's canal using a flexible microcatheter for the treatment of open-angle glaucoma in adults: interim clinical study analysis. *J Cataract Refract Surg*. 2007; 33:1217–1226.
- [18] Linner E, Rickenbach C, Werner H. Comparative measurements of the pressure in the aqueous veins and the conjunctival veins using different methods. *Acta Ophthalmol (Copenh)*. 1950; 28:469–478.
- [19] Minckler DS, Francis BA, Hodapp EA, Jampel HD, Lin SC, Samples JR, Smith SD, Singh K. Aqueous shunts in glaucoma. A report by the American Academy of Ophthalmology. *Ophthalmology* 2008; 115:1089–1098.
- [20] Minckler DS, Mosaed S, Dustin L, Francis BA. Trabectome (trabeculectomy-internal approach): additional experience and extended follow-up. *Trans Am Ophthalmol Soc*. 2008; 106:1–12.
- [21] Mastropasqua L, Agnifili L, Ciancaglini M, et al. In vivo analysis of conjunctiva in gold micro shunt implantation for glaucoma. *Br J Ophthalmol*. 2010; 94(12):1592–1596.
- [22] Helmut H, Ahmed IK, Grisanti S, et al. Early postoperative safety and surgical outcomes after implantation of a suprachoroidal micro-stent for the treatment of open-angle glaucoma concomitant with cataract surgery. *J Cataract Refract Surg*. 2013; 39(3): 431–437.
- [23] Grover DS, Godfrey DG, Smith O, Feuer WJ, Montes de Oca I, Fellman RL. Gonioscopy-assisted transluminal trabeculotomy, ab interno trabeculotomy: technique report and preliminary results. *Ophthalmology*. 2014; 121:855–861.

- [24] Bellows AR, Grant WM. Cyclocryotherapy in advanced inadequately controlled glaucoma. *Am J Ophthalmol.* 1973; 75:679–684.
- [25] Egbert PR, Fiadoyor S, Budenz DL, et al. Diode laser transscleral cyclophotocoagulation as a primary surgical treatment for primary open-angle glaucoma. *Arch Ophthalmol.* 2001; 119:345–350.
- [26] Siegel MJ, Boling WS, Faridi OS, et al. Combined endoscopic cyclophotocoagulation and phacoemulsification versus phacoemulsification alone in the treatment of mild to moderate glaucoma. *Clin Experiment Ophthalmol.* 2015; 43:531–539.
- [27] Francis BA, Berke SJ, Dustin L, Noecker R. Endoscopic cyclophotocoagulation combined with phacoemulsification versus phacoemulsification alone in medically controlled glaucoma. *J Cataract Refract Surg.* 2014; 40:1313–1321.