

We are IntechOpen, the world's leading publisher of Open Access books Built by scientists, for scientists

4,800

Open access books available

122,000

International authors and editors

135M

Downloads

Our authors are among the

154

Countries delivered to

TOP 1%

most cited scientists

12.2%

Contributors from top 500 universities



WEB OF SCIENCE™

Selection of our books indexed in the Book Citation Index
in Web of Science™ Core Collection (BKCI)

Interested in publishing with us?
Contact book.department@intechopen.com

Numbers displayed above are based on latest data collected.

For more information visit www.intechopen.com



Introductory Chapter: Endocarditis - A Diagnostic and Therapeutic Challenge

Michael S. Firstenberg

Additional information is available at the end of the chapter

<http://dx.doi.org/10.5772/66406>

1. Introduction

Infective endocarditis (IE), reflecting infections of the heart—as manifested by vegetations on the valvular structures, abscess cavities of the myocardium, invasive fistula, or infections on intracardiac prosthetic devices—represents a significant problem that continues to challenge clinicians. The epidemiology of infections reflects not only the dark side of the progresses in medical therapy but also some of the social problems that plague modern society. The changing microbiology also reflects how this complex disease has also paralleled the advances in medicine. Diagnostic tools continue to evolve with not only improvements in imaging technologies but also our understandings on how to appropriately use them to better understand the overall clinical picture. In addition, the role of therapies—especially early surgical intervention—has been demonstrated to have a significant impact on the management and outcomes of infected patients. The goal of this text is to highlight some of the current concepts in the clinical characteristics, presentation, diagnosis, and management options.

2. Epidemiology

The incidence of infectious endocarditis, without a doubt, has increased significantly over the years. The reasons for this are multifactorial and reflect the growing number of patients who are at risk due to their comorbidities. The list of comorbidities is extensive and includes advancing age, chronic immunosuppression, end-stage renal failure, and those with pre-existing intracardiac pathology. Furthermore, as patients are living longer and longer with more complex comorbidities, medical teams are seeing the pathological consequences of some

of the therapies that such patients require to prolong their lives. The dramatic increase in the use of cardiac support devices, such as pacemaker, defibrillators, intravascular monitoring devices, and left ventricular assist devices has presented unique and difficult challenges in management when patients are clinically dependent on them and then they become infected and may need to be removed. Clearly, endocarditis is one of those opportunistic problems that result from medical advances. However, without doubt, the largest populations of patients developing endocarditis are those with a history of intravenous drug abuse or those with a history of implanted cardiac devices [1, 2]. The undeniable worldwide epidemic of intravenous drug abuse has resulted in a dramatic increase in the incidence of younger patients presenting with polymicrobial invasive infections—often in the setting of overwhelming sepsis and difficult to manage social situations with established concerns of noncompliance. In this patient population, the primary cardiac infections might be the easiest of their presenting problems to manage long term. The other major patient population at significant risk is those with underlying cardiovascular pathologies requiring implantable support devices and lead system. In addition, the increasing long-term survival of patients with prosthetic heart valves, corrected congenital heart disease, and wider use of percutaneously implanted cardiac valves (i.e., TAVR) or repair devices (i.e., mitral clips) in high-risk surgical patients also place these patients at risk for device-related infection and the increasing incidence of endocarditis [3]. It is also becoming concerning, as discussed in this text, that infections in certain patient populations—such as those with end-stage renal disease requiring hemodialysis—are at substantial risk for endocarditis and life-threatening complications in ways that are only recently being appreciated and described in the literature. Nevertheless, guidelines for prophylactic antibiotics remain unclear in how “at risk” patients should be managed at the time of invasive procedures that might predispose to bacteremia and subsequent seeding of cardiac, native and prosthetic, structures [4–6]. To say that there is much controversy in this area is an understatement.

3. Microbiology

The microbiology of IE has also evolved over the years. The growing incidence of difficult-to-treat infections, methicillin-resistant *Staphylococcus*, polymicrobial infections with Gram-negative bacteria, primary or opportunistic fungi, and multidrug-resistant organisms has also increased the difficulties in managing this patient population—and is independently a predictor of worse outcomes and hence is often an indication for urgent surgery [7]. Advances in the ability of microbiology labs to better identify unusual organisms—including genetic material—have allowed for more accurately defining causative agents that otherwise would have been considered “culture negative.” Furthermore, as more aggressive approaches to the diagnosis and management of sepsis have resulted in a more assertive approach to insuring appropriate and timely cultures, antibiotics, and a search of an infectious focus, there might be a more accurate and timely diagnosis of extensive bacterial infections [8], while it is unclear whether such an aggressive approach toward “septic” patients has changed the incidence of endocarditis or whether the significant increase in case presentations is more of a function of

an overall awareness. Without doubt, as resistance patterns emerge within a community and a patient presents, for many reasons, with more unusual infectious, these patterns are also reflected in the microbiologic picture of endocarditis. In addition, the increase in immune modulating medications has also increased the incidence of fungal infections and very unusual pathogens [9]. Similarly, as patients with adult congenital heart disease and prosthetic material live longer, their overall risk of developing unusual infections that evolve into endocarditis also increases [10, 11].

In addition, as discussed in this text, there is a growing body of literature on concepts such as culture negative endocarditis and noninfectious endocarditis such as marantic or Libman-Sacks endocarditis [12].

4. Diagnosis

Positive blood cultures remain the *sine quo non* in the diagnosis of endocarditis—but the corollary is not always true as patients can present with significant valvular pathology and negative cultures. The Duke Criteria, discussed at length elsewhere and in this text, remain the cornerstones for the diagnosis of endocarditis [13]. Advances in imaging, much like advances in the microbiologic assessment, of patients has also contributed significantly to the diagnosis and management of infected patients [14]. While transthoracic and transesophageal imaging are still first-line diagnostic tests to evaluate potentially infected cardiac structures—and current guidelines help outline appropriateness criteria [2, 12]—there are growing indications and roles for alternative imaging modalities such as the computed tomography (CT), magnetic resonance imaging, and even 3D echocardiography [15]. As discussed in this text—advanced imaging modalities clearly have an expanding role in the diagnosis and management of patient with endocarditis. Early and frequent imaging can be extremely helpful in guiding and assessing the response to therapy.

5. Therapy

As well described and discussed at length in several chapters of this book, successful management of endocarditis requires a multidisciplinary approach. Clearly targeted and appropriate antibiotics are necessary. Prolonged courses of intravenous antibiotics are often prescribed, and fortunately, most patients can receive their therapies as an outpatient with close follow-up. While social and economic variables, not to mention restrictions by insurance companies and funding agencies, may limit options, fortunately from a medical standpoint, most patients will tolerate a prolonged course of antibiotics.

However, the critical decision-making regarding treatment for endocarditis is focused on appropriate interventional or surgical management. When associated with pacemaker lead systems or intracardiac devices, especially in the setting of large vegetations and resistant organisms or fungal infections, current guidelines advocate early and aggressive removal of

all artificial material. Obviously, this can be quite challenging from not only a technical standpoint when the patient is quite sick but also how to support a patient that may be pacemaker-dependent in the setting of an infected pacemaker lead system. While many such devices can be removed percutaneously, there is often concern that large vegetations or lead systems that are firmly adherent to cardiac structures such as the tricuspid valve may require open heart surgery with direct removal [16]. Again, such cases illustrate the importance of a multidisciplinary team approach to not only the timing of interventions but also the specific procedures that may be required to remove the offending hardware.

The greater challenge is the timing of surgical intervention in patients who may require valve surgery—either repair or replacement—especially in the setting of associated other intracardiac pathology. Historical paradigms of prolonged courses of antibiotics and delayed surgical intervention, often after completion of a course of antibiotics, have been challenged recently as current European and American Society guidelines are tending to advocate early and aggressive surgical intervention. It was believed previously that early surgery and patients with active infections and vegetations were associated with a prohibitive risk for reinfection and postoperative complications from operating on septic patients. This was the rationale for delayed surgery after a prolonged course of antibiotics [17]. However, this approach was frequently criticized as selecting only those patients who survived complication free to complete their course of antibiotics, while potentially undertreating those patients who may have benefited from aggressive debridement and infection source control and who ultimately died of either overwhelming septic complications or catastrophic neurological events. A randomized trial of 37 patients with left-sided endocarditis, severe valvular disease, and large vegetations compared early surgical intervention with conventional medical therapies and potential delayed interval surgery and concluded that early surgery had a significant impact in reducing further embolic events and death [18]. Unfortunately, as a function of the nature of the disease combined with associated comorbidities, randomized trials dealing with surgical management of infected endocarditis can be very difficult. Current guidelines acknowledge this fact and base their recommendations on the growing body of literature that consists predominantly of small series and high-quality observational studies [19]. Nevertheless, the current guidelines suggest early surgical intervention in those patients who present with the following characteristics:

1. Valvular dysfunction resulting in signs or symptoms of acute heart failure.
2. Early surgery is recommended with those patients with fungal infections or highly resistant organisms.
3. Those patients who present with cardiovascular complications directly associated with their infections, including new heart block, aortic or root or annular abscess cavities, or penetrating infectious complications such as fistula, might benefit from early surgery.
4. Surgery is indicated in the setting of persistent bacteremia or fever greater than 5–7 days in the absence of another identifiable primary source in the setting of appropriate targeted antibiotic therapy.

5. Enlarging vegetations despite appropriate antibiotic therapy or evidence of recurrent embolic complications.
6. Vegetations that are mobile and greater than 1 cm and/or with evidence of severe valve regurgitation.
7. Mobile vegetations that are greater than 1 cm especially in the setting of other relative indications for surgery and when involving the anterior leaflet of the mitral valve.

Similar recommendations are used to guide therapy in patients with prosthetic valve endocarditis [20]. However, it must be considered that overall, prosthetic valve endocarditis can be very difficult to successfully manage medically.

A growing challenge is the population presenting with right-sided endocarditis especially in the setting of poly-microbial or resistant organisms from intravenous drug abuse. Again, historically because of the concerns of recurrent infections or relapse, there was reluctance to intervene early, and many of these patients were treated medically. However, there is growing evidence that tricuspid valve surgery should be considered in those patients with worsening right heart failure from tricuspid regurgitation, failure of medical therapy, difficult to treat organisms, vegetations greater than 2 cm, and worsening pulmonary complications from presumed septic pulmonary emboli. Obviously, the challenge is not only patient selection but also surgical timing—again emphasizing the importance of a multidisciplinary team to sort out the clinical issues [21]. Historical management of tricuspid pathology was often “vegectomy” or “valvectomy” [22]. While there were some survivors of such therapy, without doubt, the developing of acute and chronic right heart failure and the consequences of it—such as hepatic congestion and failure—limit the practical application of such approaches [23]. Rarely is right-side infections managed with procedures that result in severe regurgitation—a pathophysiology that is often the initial indication for intervention.

Nevertheless, the growing consensus is that patients with severe valvular infections especially in the setting of failure of appropriate medical therapy, worsening vegetations, systemic complications, and especially worsening heart failure should be promptly evaluated and considered for early, if not urgent, surgical intervention. Obviously, the risks and benefits of surgery in a septic patient with associated comorbidities must be evaluated on a case-by-case basis and take into consideration vocal experiences and resources.

6. Social implications

Without doubt, the greatest challenges in dealing with patients with endocarditis are the growing population of patients presenting with a history of intravenous drug abuse—especially heroin. Recent data suggest a twofold increase in the number of active users of heroin between 2006 and 2013 [24]. The growing epidemic of drug abuse, worldwide, cannot be ignored nor denied. Endocarditis in the setting of IV drug abuse is particularly difficult to manage, while the etiology is often the use of infected needles or contamination of the drugs being directly injected into the vascular system. Patients who present with infections also have

other acquired comorbidities associated with their substance abuse that challenge their management and long-term prognosis. Hepatitis B and C as well as human immunodeficiency virus are often encountered in this patient population [25]. Chronic pain syndromes as well as their underlying drug addiction and associated personality and psychological disorders not only makes this population difficult to manage in the hospital setting but also raises the concern of long-term compliance with medical therapies. While there might be a general reluctance, for example, to use mechanical valves in younger patients, concerns about compliance with anticoagulation often leaves little choice. This is particularly true when patients present with a history of hepatitis and their long-term liver function (critical for clotting factors and Coumadin management) is unpredictable. Without doubt, this population is at risk for recurrent problems secondary to their substance abuse history. A recent study by Kim and colleagues illustrate the scope of this problem. Between 2002 and 2014, there was a twofold increase in the number of patients requiring surgery for infected endocarditis at their institution space (14.8% in 2002–26% in 2012). Of the 436 patients studied, over a mean follow-up of 29 months adverse events occurred in 20% including 10% developing re-infections—often as a function of continued substance abuse. While their findings demonstrated a lower operative mortality in patients with drug abuse predominately as a function of their age, propensity score analysis indicated that IV drug abuse was associated with an almost fourfold increase in valve-related complications and a 6.2-fold increase in reinfection. Because of the concerns of noncompliance, relapse of drug abuse, and poor socioeconomic status of many of these patients, surgical intervention in the setting of long-standing drug abuse is often viewed as intervening on an end-stage, often inherently fatal, disease. Some clinicians viewed attempts at curing these patients of their infections and substance abuse as being futile. In fact, while often discussed but rarely written, most programs will refuse surgical re-intervention except for extenuating circumstances in those patients who continue to demonstrate ongoing drug abuse who subsequently developed recurrent prosthetic valve infections. Prior to refusing potentially lifesaving, but high-risk, surgery in such patients or referral to palliative care, an open and honest discussion with an Institutional Ethics Team might be indicated.

Because of the cost of therapy that often includes prolonged hospitalizations, extensive diagnostic evaluations, complex surgery, or multiple surgical interventions, and often a prolonged recovery that can also be challenged by baseline comorbidities, disease complications, and access to potentially limited resources, the growing epidemic of endocarditis is clearly a problem. This is all in the background of whether the social programs that reduce the risk of infections, such as prophylactic antibiotics prior to dental procedures, are cost effective or even reduce the risk of infections at all [26, 27]

7. Conclusion

As technology has improved over the years, so has the ability to detect and guide the management of patients with infections. This has also paralleled the significant increase in the incidence of such infections as patients get older, develop more comorbidities (especially from lifestyle choices), have more implanted devices that can potentially get infected, and have more

procedures that might infect cardiac structures (both native and prosthetic). Endocarditis remains a formidable problem—both in terms of diagnosis and management. Risks are high and, without doubt, a team approach is crucial to the successful management of these patients (Figure 1) [28, 29].

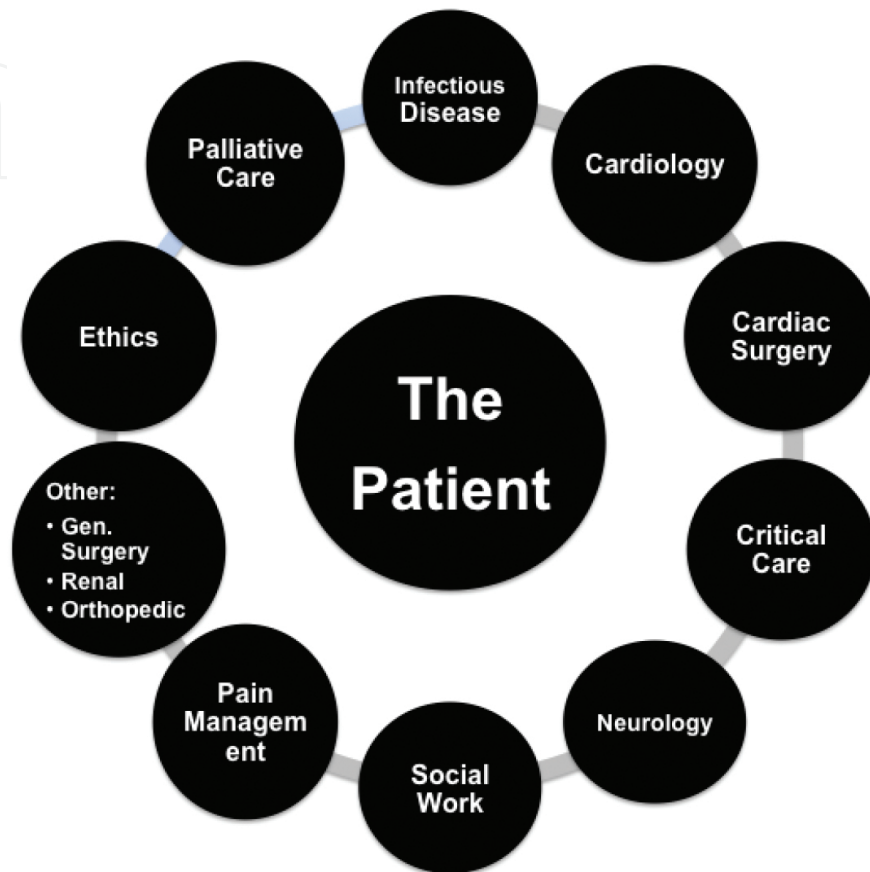


Figure 1. Components of an “Endocarditis Heart Team” —all focused on the patient.

While the goal of this text is not to be an all-inclusive reference on this topic—the hope is that it will provide a current update on some of the key topics that reflect the multiple, evolving, and difficult challenges in the assessment and therapies available for such a devastating problem.

Author details

Michael S. Firstenberg

Address all correspondence to: msfirst@gmail.com

Department of Surgery (Cardiothoracic), Northeast Ohio Medical University, Akron City Hospital—Summa Health System, Akron, Ohio, USA

References

- [1] Sousa, C., Botelho, C., Rodrigues, D., Azeredo, J. and Oliveira, R., 2012. Infective endocarditis in intravenous drug abusers: an update. *European Journal of Clinical Microbiology & Infectious Diseases*, 31(11), pp. 2905–2910.
- [2] Habib, G., Lancellotti, P., Antunes, M.J., Bongiorno, M.G., Casalta, J.P., Del Zotti, F., Dulgheru, R., El Khoury, G., Erba, P.A., Iung, B. and Miro, J.M., 2015. 2015 ESC Guidelines for the management of infective endocarditis. *European Heart Journal*, p. ehv319.
- [3] Latib, A., Naim, C., De Bonis, M., Sinning, J.M., Maisano, F., Barbanti, M., Parolari, A., Lorusso, R., Testa, L., Dato, G.M.A. and Miceli, A., 2014. TAVR-associated prosthetic valve infective endocarditis: results of a large, multicenter registry. *Journal of the American College of Cardiology*, 64(20), pp. 2176–2178.
- [4] Thornhill, M.H., Dayer, M.J., Jones, S., Prendergast, B., Baddour, L.M. and Lockhart, P.B., 2016. The effect of antibiotic prophylaxis guidelines on incidence of infective endocarditis. *Canadian Journal of Cardiology*.
- [5] Patanè, S., 2014. Is there a need for bacterial endocarditis prophylaxis in patients undergoing gastrointestinal endoscopy? *Journal of Cardiovascular Translational Research*, 7(3), pp. 372–374.
- [6] Dayer, M.J., Jones, S., Prendergast, B., Baddour, L.M., Lockhart, P.B. and Thornhill, M.H., 2015. Incidence of infective endocarditis in England, 2000–13: a secular trend, interrupted time-series analysis. *The Lancet*, 385(9974), pp. 1219–1228.
- [7] Slipczuk, L., Codolosa, N.J., Carlos, D., Romero-Corral, A., Pressman, G.S. and Figueredo, V.M., 2012. Systematic review and meta-analysis of infective endocarditis microbiology over 5 decades. *Circulation*, 126(Suppl 21), pp. A15138–A15138.
- [8] Dellinger, R.P., Levy, M.M., Rhodes, A., Annane, D., Gerlach, H., Opal, S.M., Sevransky, J.E., Sprung, C.L., Douglas, I.S., Jaeschke, R. and Osborn, T.M., 2013. Surviving Sepsis Campaign: international guidelines for management of severe sepsis and septic shock, 2012. *Intensive Care Medicine*, 39(2), pp. 165–228.
- [9] Tacke, D., Koehler, P. and Cornely, O.A., 2013. Fungal endocarditis. *Current Opinion in Infectious Diseases*, 26(6), pp. 501–507.
- [10] Abandeh, F.I., Bazan, J.A., Davis, J.A., Zaidi, A.N., Daniels, C.J. and Firstenberg, M.S., 2012. Bartonella henselae prosthetic valve endocarditis in an adult patient with congenital heart disease: favorable outcome after combined medical and surgical management. *Journal of Cardiac Surgery*, 27(4), pp. 449–452.
- [11] Pfahl, K.W., Orsinelli, D.A., Raman, S. and Firstenberg, M., 2013. The diagnosis and treatment of a mycotic coronary artery aneurysm: a case report. *Echocardiography*, 30(10), pp. E304–E306.

- [12] Liu J, Frishman W. Nonbacterial thrombotic endocarditis-pathogenesis, diagnosis and management. *Cardiology in Review*. April 26, 2016 .
- [13] Baddour, L.M., Wilson, W.R., Bayer, A.S., Fowler, V.G., Tleyjeh, I.M., Rybak, M.J., Barsic, B., Lockhart, P.B., Gewitz, M.H., Levison, M.E. and Bolger, A.F., 2015. Infective endocarditis in adults: diagnosis, antimicrobial therapy, and management of complications a scientific statement for healthcare professionals from the American Heart Association. *Circulation*, 132(15), pp. 1435–1486.
- [14] Bruun, N.E., Habib, G., Thuny, F. and Sogaard, P., 2014. Cardiac imaging in infectious endocarditis. *European Heart Journal*, 35(10), pp.624–632.
- [15] Habets, J., Tanis, W., Reitsma, J.B., van den Brink, R.B., Willem, P.T.M., Chamuleau, S.A. and Budde, R.P., 2015. Are novel non-invasive imaging techniques needed in patients with suspected prosthetic heart valve endocarditis? A systematic review and meta-analysis. *European Radiology*, 25(7), pp. 2125–2133.
- [16] Koutentakis, M., Siminelakis, S., Korantzopoulos, P., Petrou, A., Priavali, E., Mpakas, A., Gesouli, E., Apostolakis, E., Tsakiridis, K., Zarogoulidis, P. and Katsikogiannis, N., 2014. Surgical management of cardiac implantable electronic device infections. *Journal of Thoracic Disease*, 6(1), pp.S173–S179.
- [17] Aranki, S.F., Santini, F., Adams, D.H., Rizzo, R.J., Couper, G.S., Kinchla, N.M., Gildea, J.S., Collins Jr, J.J. and Cohn, L.H., 1994. Aortic valve endocarditis. Determinants of early survival and late morbidity. *Circulation*, 90(5 Pt 2), pp. II175–II182.
- [18] Kang, D.H., Kim, Y.J., Kim, S.H., Sun, B.J., Kim, D.H., Yun, S.C., Song, J.M., Choo, S.J., Chung, C.H., Song, J.K. and Lee, J.W., 2012. Early surgery versus conventional treatment for infective endocarditis. *New England Journal of Medicine*, 366(26), pp. 2466–2473.
- [19] Erbel, R.A., 2014. The New strategy in infective endocarditis: early surgery based on early diagnosis: are we too late, when early surgery is best? *Circulation*, pp. CIRCULATIONAHA-114.
- [20] Perrotta, S., Jeppsson, A., Fröjd, V. and Svensson, G., 2016. Surgical treatment of aortic prosthetic valve endocarditis: a 20-year single-center experience. *The Annals of Thoracic Surgery*, 101(4), pp. 1426–1432.
- [21] Yong, M.S., Coffey, S., Prendergast, B.D., Marasco, S.F., Zimmet, A.D., McGiffin, D.C. and Saxena, P., 2016. Surgical management of tricuspid valve endocarditis in the current era: a review. *International Journal of Cardiology*, 202, pp. 44–48.
- [22] Hughes CF, Noble N., 1988. Vegetectomy: an alternative surgical treatment for infective endocarditis of the atrioventricular valves in drug addicts. *Journal of Thoracic Cardiovascular Surgery*, 95, pp. 857–861
- [23] Dawood, M.Y., Cheema, F.H., Ghoreishi, M., Foster, N.W., Villanueva, R.M., Salenger, R., Griffith, B.P. and Gammie, J.S., 2015. Contemporary outcomes of operations for tricuspid valve infective endocarditis. *The Annals of Thoracic Surgery*, 99(2), pp. 539–546.

- [24] Wurcel, A.G., Anderson, J.E., Chui, K.K., Skinner, S., Knox, T.A., Snyderman, D.R. and Stopka, T.J., 2016, May. Increasing infectious endocarditis admissions among young people who inject drugs. In: *Open Forum Infectious Diseases* (Vol. 3, No. 3, p. 157). Oxford University Press.
- [25] Gundedly, P., Burgess, D.S., Boulay, J., Caldwell, G. and Thornton, A., 2014, December. 921 Prevalence of hepatitis C infection and epidemiology of infective endocarditis in intravenous drug users in central Kentucky. In *Open Forum Infectious Diseases* (Vol. 1, No. Suppl 1, pp. S266–S266). Oxford University Press.
- [26] Wray, D., Ruiz, F., Richey, R. and Stokes, T. 2008. Prophylaxis against infective endocarditis for dental procedures—summary of the NICE guideline. *British Dental Journal*, 204(10), pp. 555–557.
- [27] Sunder, S., Grammatico-Guillon, L., Baron, S., Gaborit, C., Bernard-Brunet, A., Garot, D., Legras, A., Prazuck, T., Dibon, O., Boulain, T. and Tabone, X., 2015. Clinical and economic outcomes of infective endocarditis. *Infectious Diseases*, 47(2), pp. 80–87.
- [28] Chambers, J., Sandoe, J., Ray, S., Prendergast, B., Taggart, D., Westaby, S., Arden, C., Grothier, L., Wilson, J., Campbell, B. and Gohlke-Bärwolf, C., 2014. The infective endocarditis team: recommendations from an international working group. *Heart*, 100(7), pp. 524–527.
- [29] Chirillo, F., Scotton, P., Rocco, F., Rigoli, R., Polesel, E. and Olivari, Z., 2013. Management of patients with infective endocarditis by a multidisciplinary team approach: an operative protocol. *Journal of Cardiovascular Medicine*, 14(9), pp. 659–668.