

# We are IntechOpen, the world's leading publisher of Open Access books Built by scientists, for scientists

4,800

Open access books available

122,000

International authors and editors

135M

Downloads

Our authors are among the

154

Countries delivered to

TOP 1%

most cited scientists

12.2%

Contributors from top 500 universities



WEB OF SCIENCE™

Selection of our books indexed in the Book Citation Index  
in Web of Science™ Core Collection (BKCI)

Interested in publishing with us?  
Contact [book.department@intechopen.com](mailto:book.department@intechopen.com)

Numbers displayed above are based on latest data collected.  
For more information visit [www.intechopen.com](http://www.intechopen.com)



---

# Effectiveness and Safety of Topical Phototherapy in the Treatment of Dermatological Diseases

---

Giorgio Delrosso and Paola Savoia

Additional information is available at the end of the chapter

<http://dx.doi.org/10.5772/65712>

---

## Abstract

Phototherapy consists in the use of ultraviolet (UV) radiation from artificial sources for therapeutic purposes. Despite the introduction of new and powerful drugs (including biological and target therapies), phototherapy remains an established, lower cost, and effective option for the treatment of many common skin diseases.

In systemic photochemotherapy or PUVA, photosensitizing agents of the family of Psoralens are used in combination with UVA, i.e. with long wave ultraviolet radiation. Psoralens strongly enhance the effect of UVA alone, as they interact with biological macromolecules, causing the production of oxygen free radicals within the photoactivated cells. However, systemic administration of psoralens can be problematic, causing possible negative interactions with other drugs and the onset of serious side effects.

To counteract these limitations, it has been developed the bath-PUVA therapy, which consists in the topical administration of psoralens by bathing the whole body surface in an alcoholic solution of 8-methoxypsoralen (8-MOP); immediately afterwards this pre-treatment, the patient is UVA-irradiated. This technique has several advantages over conventional PUVA, including the use of a reduced UVA dosage, thus resulting in minimal skin damage with complete elimination of skin photosensitivity within three hours after the treatment; furthermore, it virtually eliminates systemic side effects and drug interference due to the very limited percutaneous absorption of psoralens. Bath-PUVA is indicated and effective in the treatment of many chronic inflammatory dermatoses (including psoriasis, atopic and allergic dermatitis, lichen ruber planus, chronic urticaria, and mastocytosis), autoimmune skin diseases (including vitiligo, and alopecia aerata), and premalignant/malignant lymphoproliferative conditions (including actinic reticulosis, parapsoriasis, and early stages of mycosis fungoides). Chronic and refractory pruritus and graft-versus-host diseases can also benefit from bath-PUVA.

Another emerging PUVA technique is gel-PUVA, which is based on the application of a gel-based formulation of 8-MOP on affected skin areas, followed by UVA radiation. The formulation of 8-MOP-containing gels is conceived to increase bioavailability, limit its spread to adjacent skin and improve cosmetic aspects, while making negligible the

systemic absorption of the psoralen. Ultraviolet A (UVA) irradiation is administered by cabins or partial devices according to the extension of the body areas to be treated. Gel-PUVA has produced its best responses in morfea, palmo-plantar psoriasis, contact dermatitis and vitiligo.

The purpose of this chapter is to provide a detailed description of the various phototherapy techniques and discuss their possible applications to the treatment of specific acute and chronic skin diseases.

**Keywords:** phototherapy, dermatological diseases, bath-PUVA, gel-PUVA, psoralen

## 1. Introduction

Phototherapy consists in the use of ultraviolet (UV) radiation from artificial sources for therapeutic purposes and remains an established, lower cost, and effective option for the treatment of many common skin inflammatory and immune-related diseases [1–5]. **Table 1** displays the major dermatological diseases and skin conditions in which phototherapy has been proven to be an effective therapeutic strategy. In the systemic photochemotherapy (PUVA), UVA radiation occurs after the oral administration of photosensitizing agents of the family of Psoralens.

	Indications
Inflammatory dermatoses	Atopic dermatitis Actinic prurigo Contact dermatitis Hydroa vacciniforme Lichen ruber planus Physical and chronic urticaria Pruritus Psoriasis Seasonal and polymorphic light eruption
Premalignant and malignant skin diseases	Actinic reticulosis Lymphomatoid papulomatosis Mastocytosis Mycosis fungoides (Stage 1A–IIB) Patch or plaque parapsoriasis
Others	Alopecia areata Erythropoietic protoporphyria Vitiligo

**Table 1.** Indication to UVA and PUVA therapy.

## 2. Psoralens

Psoralen (also called psoralene) is the progenitor of a family of natural organic compounds known as linear furanocoumarin, that is, derivatives of coumarin by the addition of a furan ring. Its methoxylated derivatives are commonly used in phototherapy and comprise the 5-methoxypsoralen (5-MOP) and the 8-methoxypsoralen (8-MOP). 5-MOP (or 4-methoxyfuro[3,2-g]benzopyrane-7-one, Bergaptene) is generally extracted from bergamot and many other citrus essential oils, including those from lemon, sweet orange, bitter orange, and mandarin, whereas the 8-MOP (or 9-methoxyfuro[3,2-g][1]benzopyran-7-one, ammoidin, methoxsalen, and xanthotoxin) is extracted from *Ammi majus*, a plant of the Ammi Umbelliferae family [6]. The absorption spectrum of psoralens ranges between 320 and 360 nm, *in vitro*; *in vivo*, due to the interaction with biological structures, the spectrum extends toward a longer wavelength, around 400 nm. Using artificial sources with a conventional emission spectrum (such as Philips TL/09 lamps), the peak of sensitivity for 8-MOP is between 335 and 355 nm.

Photosensitization determined by psoralen occurs by means of two mechanisms [7, 8]:

- i. *Photoaddition reactions*: In the dark, psoralens intercalate between base pairs of the DNA double helix. Upon UVA excitation, intercalated psoralens get photoactivated; as a result of this reaction, they form [2 + 2]-cycloadducts, primarily with adjacent thymine bases, involving either their furan or pyrone moiety; more precisely, the [2 + 2]-type photoconjugation occurs between the 3,4-pyrone and/or 4',5'-furan double bond of the intercalated psoralen and the pyrimidine 5,6 double bond. The furan adduct is then capable of absorbing another UVA photon, resulting in interstrand cross-links [9]. DNA interstrand cross-links are among the most cytotoxic types of DNA damage; their repair is extraordinarily difficult for the cell since it requires the coordination of proteins from several pathways, including nucleotide excision repair, base excision repair, mismatch repair, homologous recombination, translation synthesis, and proteins involved in Fanconi anemia [10]. Monoadducts and cross-links inhibit DNA-readout processes, thus leading to necrosis or apoptosis of the photodamaged cells [11]. Psoralens are highly soluble in body fluids, and therefore they can form photoadducts with a variety of other molecules besides DNA, including RNAs, proteins, and polyunsaturated fatty acids; actually, most of the administered 8-MOP have been found to be conjugated to proteins rather than to nucleic acids or lipids [12]. Psoralen photoadducts to those molecules result in disruption and silencing of a variety of metabolic and signaling pathways, thus exerting a broad range of phototoxicity.
- ii. *Photodynamic reactions*: Photoactivation of psoralens in the presence of oxygen results in the formation of reactive oxygen species (ROS), including singlet oxygen and superoxide radical anions. Thus, psoralens activate both type 1 photodynamic mechanisms (i.e., the production of superoxide, hydrogen peroxide, and hydroxyl radical (HO•) by electron transfer) and type 2 mechanisms (i.e., the production of singlet oxygen ( $^1O_2$ ) by energy transfer) [13]. Reactive oxygen species are extremely

unstable and react with other molecules, causing a variety of cell damages, including lipid peroxidation, DNA breaks, and DNA-protein cross-links (PMID: 24721421). To counteract oxidative damage/stress, cells rely on a number of antioxidative defense systems, including natural radical scavengers (e.g., tocopherol and vitamin A) and different enzymes (e.g., superoxide dismutase, glutathione peroxidase, and catalase).

Adducted DNA by psoralens is also implicated in melanogenesis: modified nucleotides, in particular oligonucleotides composed by two thymidine residues, stimulate cells to express tyrosinase, a known key enzyme in melanin production, with variable effects in patients with vitiligo vulgaris [14–17]. The demonstrated ability of furocoumarines to bind proteins, including those of the lens, can induce cataract in long-term therapy. Finally, it has to be noticed that PUVA has also the ability to induce apoptosis of Langerhans cells, activated T-lymphocytes, neutrophils, macrophages, NK cells, fibroblasts, endothelial cells, and mast cells, thus exerting a beneficial effect for the most common dermatoses [18].

## 2.1. Dosage

Pharmacokinetic studies have shown that psoralens absorption is subject to individual variations, in terms of both mean plasma concentration and timing for reaching the maximum peak. In addition, in the same individual, plasma concentration varies during the day, although the maximum peak represents a constant [19–21].

Recommended doses are the following:

- i. 8-MOP: 0.6 mg/kg (or 25 mg/m<sup>2</sup>, for subjects weighing less than 60 kg) 2 h before exposure if in a micronized form or 1 h before if in liquid or gelatinous form. The dosage should then be adjusted according to the response.
- ii. 5-MOP: 1.2 mg/kg, 3.5 h before the treatment.

8-MOP administration results in a photosensitization which reaches its maximum, 2–4 h after the intake and disappears in 6–8 h. Psoralens are transported in the blood by serum proteins (mainly albumin), and are predominantly catabolized in the liver by cytochrome P450 (CYP450)-triggered oxidation. CYP450s make a large superfamily of heme-containing monooxygenases, which take care of the detoxification of many drugs [22]. Recent studies have shown that CYP3A11 is the major target cytochrome for psoralens metabolism in mice [23]. Another key cytochrome for detoxification or activation of many toxicologically important substrates is CYP2B1 [24]. Psoralens are oxidized by CYP3A11 at the furan ring to form a furan epoxide that binds to CYP 2B1 with a high stoichiometry [25]; after binding, CYP 2B1 produces dihydrodiols, which are the final catabolic products of linear furocoumarins [25]. In addition, 8-MOP up-regulates CYP1A1 expression, and can be a substrate for this CYP450 [26]. CYP450s are encoded by highly polymorphic genes [27] and their expression varies among individuals, in relation with alcohol intake and drug use; both these facts provide an easy explanation for individual variations in response to psoralen-related therapies. About 75% of furanocoumarins catabolic products produced by the liver are excreted in the urine as inactive hydroxylated- or glucurono-conjugates derivatives within

12 h; key proteins for this excretory function are the solute carrier (SLC) 22A family organic cation/carnitine transporters (OCTs/OCTNs) and the organic anion transporters (OATs). More specifically, the administration of furocoumarins up-regulates renal OCT1, OCT2, OCTN2, and OAT3 protein levels, as a result of increased gene expression in mice; in addition, oxidized linear furocoumarins induce high expression of mURAT1, mMRP4, and mGLUT9, which may also play important roles in renal transportation, and accumulation of psoralen metabolites as well as in related kidney injury. Notably, 8-MOP clearance in the lens is rather slow, it being detectable in this organ for 18 h after oral intake [28].

## 2.2. Cautions

In view of the prolonged photosensitivity induced by 8-MOP [29], it is mandatory to avoid exposition to the sunlight after the treatment; to this purpose, eyes and lips should be protected with glasses and sunscreen.

During treatment with psoralens, regular evaluation of liver function is needed and drug should be reduced or discontinued if there is any sign of liver damage. The most frequent pharmacological interactions are with other topical or systemic photoactive drugs (e.g., phenothiazine, chlorothiazide and derivatives, sulfonylureas, sulfonamides, neomycin, and bergamot essence). Diet with low (or free) coumarins should also be recommended, which are mainly contained in fig, cedar, lime, parsley, mustard, carrots and celery, and parsnips.

The most frequently observed side effects related to 8-MOP administration include severe burns, gastric distress, nausea, nervousness, insomnia, and depression.

Major contraindications to PUVA therapy are summarized in **Table 2**.

Contraindications		
Absolute	Major	Relative
Autoimmune diseases	Age >10 years	Age >16 years
Basal cell carcinoma syndrome	Actinic keratosis	Bullous skin diseases
Dysplastic nevus syndrome	Personal history of nonmelanoma skin cancer	Cataract
Personal history of melanoma	Previous exposure to UVA >1500 J/cm <sup>2</sup>	Photosensitization
Porphyry	Previous exposure to X-ray or arsenic	Photo type I
Pregnancy and lactation	Systemic immunosuppressive therapy	Poor compliance
Severe heart failure		Renal and/or hepatic failure
Systemic lupus erythematosus; Dermatomyositis		
<i>Xeroderma pigmentosum</i> and other congenital defects of DNA repair mechanisms		

\*Photo type I is characterized by pale white skin, blue or hazel eyes, and blond or red hair; patients with photo-type I always have burns, does not tan.

**Table 2.** Contraindications to PUVA therapy.

### 3. UV irradiation

The most frequently used lamps for phototherapy are fluorescent, low-pressure mercury vapor tubes (e.g., Philips TL/09, Philips CLEO-UVA or Sylvania F 85 tubes) with an emission spectrum ranging from 320 to 450 nm, and an emission peak at 352 nm. PUVA units are either whole-body cabins or small-panel irradiators for the treatments of hands and feet or other restricted areas of the body. To provide consistency and repeatability of treatment doses, it is fundamental to measure the emission by calibrated radiometers-photometers, sensitive to the spectrum emitted by the lamps. Treatment times are automatically calculated on the basis of variables such as (i) total or daily usage time of the lamps, (ii) environmental and patient's conditions (temperature, humidity, dust, and distribution of adipose tissue), and (iii) presence of other UV sources. When devices devoid of dosimeters are used, the dosage should be calculated according to the formula: Dose (mJ/cm<sup>2</sup>) = irradiance (mW/cm<sup>2</sup>) × time (seconds); special tables are then used to calculate the appropriate dosage, according to patient's phototype. In any case, it is recommended a semiannual or annual assessment of the UVA cabin or panel with external radiometer-photometer calibrated to the National Physics Laboratory, which will provide an adjustment for timing and doses [5, 6].

#### 3.1. Dose assessment

Dose assessment, according to the different published protocols, is based on (i) evaluation of the Fitzpatrick phototype, (ii) calculation of the minimal phototoxic dose (MPD), that is, the lowest UVA dose that produces a perceptible erythema after psoralen administration, and (iii) assessment of an attack dosage equal to 50% of MPD.

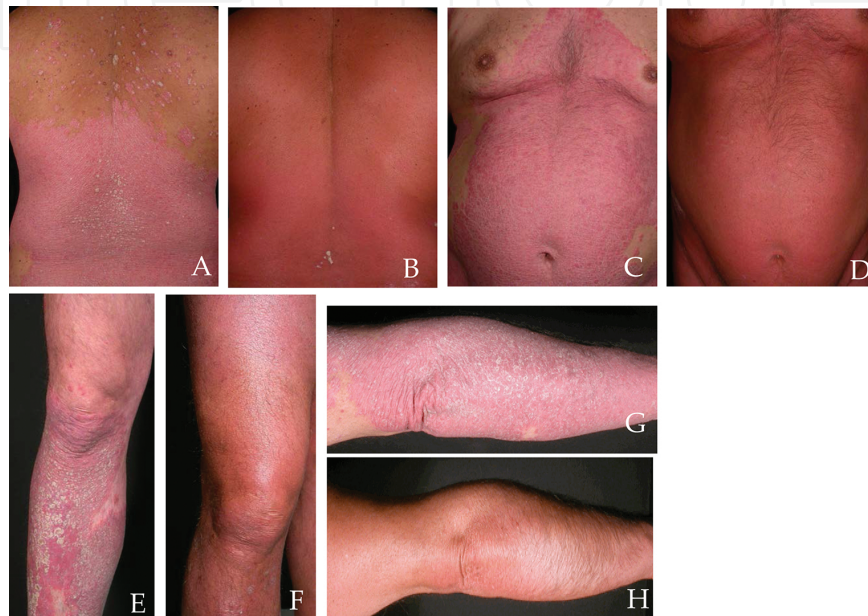The sessions are initially carried out three to four times a week and then reduced to two times a week after a clinical improvement has been obtained. The possibility of performing one session every 7–10 days as maintenance therapy can be considered. Side effects are resumed as shown in **Table 3**.

Side effects	
Early	Late
Gastric intolerance	Anti-DNA and antinucleus antibodies (low titer)
Hypertrichosis or alopecia	Carcinogenesis (actinic keratosis, NMSCs, melanomas)
Neomelanogenesis and stratum corneum thickening	Cataract
Pain	Disorder of pigmentation
Photo-induced dermatitis	Idiopathic guttate hypomelanosis
Phototoxic exanthema	Melanocytes dystrophies
Skin dryness and pruritus	
Teratogenicity	

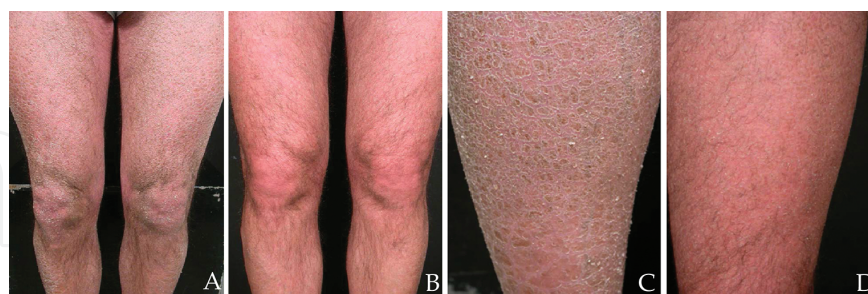**Table 3.** Side effects related to PUVA therapy.

#### 4. Topical photochemotherapy: bath-PUVA

Bath-PUVA therapy consists in the immersion of the whole body in a bath containing an 8-MOP alcoholic solution, at concentrations ranging from 1 to 3 mg/L, for a time varying from 15' to 20'. Then, the patient is exposed to increasing doses of UVA, which varies in relation to the phototype, with a minimal initial doses of 0.25–0.50 J/cm<sup>2</sup> and progressive increments of 0.25 J/cm<sup>2</sup> up to a maximum of 5–7 J/cm<sup>2</sup>.



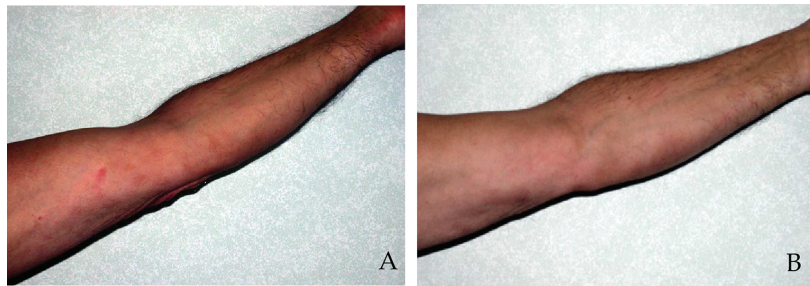
**Figure 1.** Plaque psoriasis before (A, C, E, G) and after (B, D, F, H) bath-PUVA therapy.



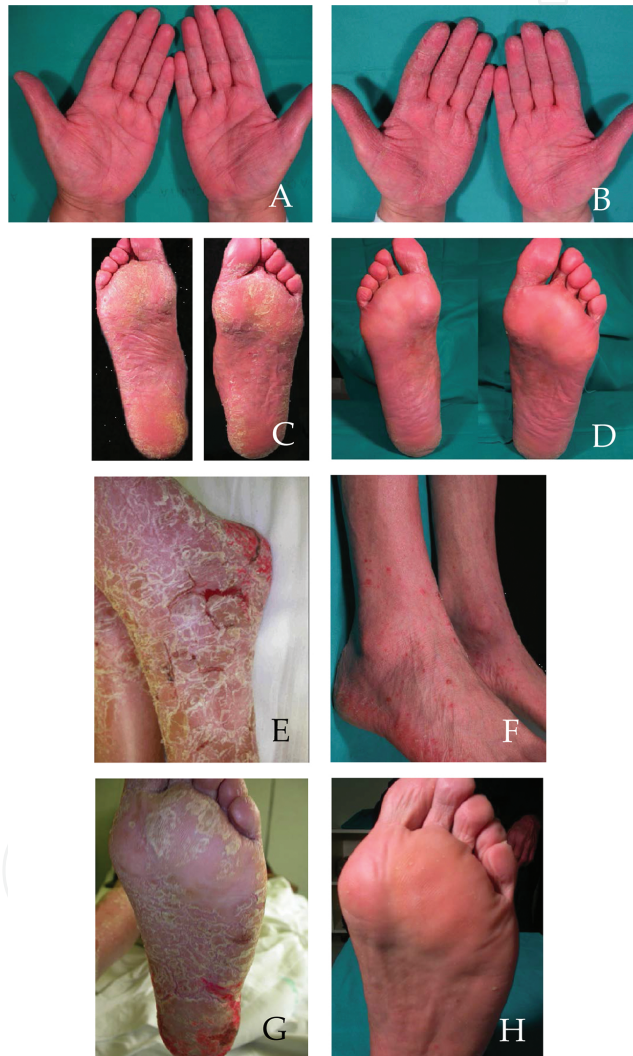**Figure 2.** Ichthyosis-like atopic dermatitis before (A and C) and after (B and D) bath-PUVA therapy.

This modality of treatment minimizes short- and long-term side effects due to the systemic administration of the drug [19, 30–33]. Three hours after treatment, photosensitivity is negligible, due to the low systemic absorption of 8-MOP; thus, patients can avoid the use of photoprotectants, including sunglasses [34, 35]. Gas chromatography and mass spectrometry analyses have shown that plasmatic trioxolaren concentrations range between 0.27 and 12.5 ng/ml after the ingestion of a 0.6 mg/kg dose and between 9 ng/ml and 25 ng/ml after bath-PUVA [20, 36].





**Figure 3.** Stage I mycosis fungoides before (A) and after (B) bath-PUVA therapy.



**Figure 4.** Palmoplantar psoriasis before (A and C) and after (B and D) gel-PUVA therapy; eczematized psoriasis before (E and G) and after (F and H) gel-PUVA therapy.

In the skin, the drug absorption peak occurs within 15–35 min; the maximum concentration is reached in the stratum corneum and the removal of this cell layer (by “stripping”) significantly enhances the possibility of drug penetration to the underlying layers. The higher psoralen

concentration in superficial layers of the epidermis justifies the increased effectiveness of this type of treatment in those diseases in which the epidermal involvement is massive [30, 36, 37]. The concentration measured by microanalytical techniques is instead of 1.7–6.6 ng/ml after oral intake and of 200–520 ng/ml after the bath.

Literature reports encourage results obtained with bath-PUVA in the treatment of several inflammatory [38–47] and lymphoproliferative skin diseases [48–52]. **Figures 1–4** report same examples of results obtained with bath-PUVA at our center.

#### 4.1. Treatment

Before treatment, an accurate collection of clinical data is mandatory; patient should be informed about the treatment modality, its potential benefits and risks, and the need to avoid other potentially photosensitizing agents. Skin should be carefully examined and nevi should be covered with high-protection sunscreen, as well as the lips and genital areas; patient should also wear sunglasses during treatment and up to 3 h afterwards. At the end of treatment, we recommended also a shower, to remove residual traces of the drug from the skin, and the application of topical emollients [53, 54]. The treatment requires special attention and the protocol described above must necessarily be adapted to each patient, on the basis of the phototype and other clinical characteristics.

### 5. Topical photochemotherapy: gel-PUVA therapy

The gel-PUVA therapy is a variant of the cream-PUVA therapy and consists in the application of a 0.05% of 8-MOP gel on restricted skin areas, 20–30 min before the irradiation. The preparation of the 8-MOP gel is galenical; the psoralen is dissolved, in order to obtain a higher bioavailability and better cosmetic aspects and to avoid the “border effect.” The UVA radiation could be realized through cabin or panels according to the extent of the body areas affected by the disease, with an irradiation spectrum of 320–370 nm. Dose calculation is performed manually, because panels are not equipped with dosimeter; hence, every 6 months, their calibration is mandatory. Usually, an initial dose of 0.25–0.50 J/cm<sup>2</sup> is used, with a progressive increase in 0.25–0.50 J/cm<sup>2</sup> for each session, up to a maximal dose of 9 J/cm<sup>2</sup>. Treatment sessions are performed three times/week for the first month of treatment and then reduced to two times/week in the second month and to one time/week in the third month. A weekly maintenance session could also be proposed.

Best responses to gel-PUVA treatment are described for morphea, palmoplantar psoriasis, contact dermatitis, and vitiligo [43, 55–57]. Inclusion and exclusion criteria are those described for systemic PUVA.

The amount of 8-MOP that is absorbed with this method is negligible [21, 58] and the only side effects that have been described are transitory erythema and pruritus, which can be easily managed with topical moisturizing creams. In a few cases, peripheral hyperpigmentation of the treated areas has also been reported [59].

In literature, also a topical psoralen-narrow-band UVB therapy has been described, based on the association of topical 8-MOP and narrow-band UVB irradiation [60–62].

## 6. Conclusions

Phototherapy and especially topic phototherapy are efficient treatment methods for a variety of dermatological diseases, able to induce complete and durable responses in several inflammatory, immune-mediated, and neoplastic skin diseases. Relapses are rare, due to the absence of tachyphylaxis. Although the cost of phototherapy is low, the relative discomfort and the time required to reach the site of the treatment should be considered.

For the risk of carcinogenesis, a number of factors should be taken into account, including dose, age at the treatment, other potentially carcinogenic drugs, photodamaged skin areas, and the type of treatment (a lower carcinogenic potential has been reported for bath-PUVA in respect to systemic PUVA). The analysis of 11 clinical trials, 10 of which were conducted on psoriatic patients (for a total of about 3400 patients), did not show an increased risk of melanoma [63–66] or of nonmelanoma skin cancer after UVA phototherapy [60, 66, 67]. However, another study [63, 66] conducted on patients previously treated with PUVA therapy and subsequently exposed to a high amount of UVB (for more than 300 treatments) demonstrated a small but significant increased risk of both squamous (relative risk (RR): 1.37) and basal cell carcinomas (RR: 1.45). The risk was further increased for patients who received less than 100 PUVA but more than 300 UVB treatments (RR: 2.75 for SCC and 3.00 per BCC). An increased risk to develop malignant melanoma has also been reported, based on the phototype and on the number of treatments; melanoma could arise more than 20 years after the start of therapy, showing a greater aggressiveness than in the general population. An increased risk to develop other cancers (colon, lung, pancreas, and kidney) has not been documented. The putative carcinogenic risk of narrow-band UVB is higher than for UVA, but its increased effectiveness requires lower cumulative doses, resulting in a reduced actual risk [60].

In summary, an accurate follow-up of patients is essential, in order to detect precancerous skin lesions, and identify suspicious melanocytic lesions, which must be excised. Accurate calculation of cumulative doses, number of treatments and their cumulative dosage, represents an absolute requirement for a correct planning of phototherapy. In addition, alternating PUVA therapy with other topical or systemic treatments can significantly reduce the carcinogenic potential of phototherapy.

## Author details

Giorgio Delrosso<sup>1,2</sup> and Paola Savoia<sup>1,2\*</sup>

\*Address all correspondence to: [paola.savoia@med.uniupo.it](mailto:paola.savoia@med.uniupo.it)

1 Azienda Ospedaliero-Universitaria “Maggiore della Carità” di Novara, Novara, Italy

2 “A. Avogadro” University of Eastern Piedmont, Novara, Italy

## References

- [1] Bie V: Remarks on Finsen's phototherapy. *Br Med J*. 1899; 2:825–830. PMID: 20758681
- [2] Benedetto AV, Roenigk HH Jr: Photochemotherapy (PUVA) in psoriasis. *J Am Osteopath Assoc*. 1976; 75:885–892. PMID: 777077
- [3] Roenigk HH Jr: Photochemotherapy for mycosis fungoides: Long term follow up study. *Cancer Treat Rep*. 1979; 63:669–673. PMID: 445519
- [4] Molin L, Skogh M, Volden G: Successful PUVA-treatment in the tumour stage of mycosis fungoides associated with the appearance of lesions in organs other than the skin. *Acta Derm Venereol*. 1978; 58:189–190. PMID: 76405
- [5] Rajatanavin N, Scharf MJ, Bernhard JD: Phototherapy and photochemotherapy in dermatologic diseases. *Compr Ther*. 1988; 14:11–18. PMID: 3053012
- [6] Bethea D, Fullmer B, Syed S, Seltzer G, Tiano J, Rischko C, Gillespie L, Brown D, Gasparro FP: Psoralen photobiology and photochemotherapy: 50 years of science and medicine. *J Dermatol Sci*. 1999; 19:78–88. PMID: 10098699
- [7] Cimino GD, Shi YB, Hearst JE: Wavelength dependence for the photoreversal of a psoralen-DNA cross-link. *Biochemistry*. 1986; 25:3013–3020. PMID: 3718936
- [8] Shi YB, Hearst JE: Wavelength dependence for the photoreactions of DNA-psoralen monoadducts. 2. Photo-cross-linking of monoadducts. *Biochemistry*. 1987; 26:3792–3798. PMID: 3651414
- [9] Noll DM1, Mason TM, Miller PS: Formation and repair of interstrand cross-links in DNA. *Chem Rev*. 2006; 106:277–301. PMID: 16464006
- [10] Vasquez KM: Targeting and processing of site-specific DNA interstrand crosslinks. *Environ Mol Mutagen*. 2010; 51:527–539. doi: 10.1002/em.20557. PMID: 20196133
- [11] Bethea D, Fullmer B, Syed S, Seltzer G, Tiano J, Rischko C, Gillespie L, Brown D, Gasparro FP: Psoralen photobiology and photochemotherapy: 50 years of science and medicine. *J Dermatol Sci*. 1999; 19:78–88. PMID: 10098699
- [12] Beijersbergen van Henegouwen GM1, Wijn ET, Schoonderwoerd SA, Dall'Acqua F: A method for the determination of PUVA-induced in vivo irreversible binding of 8-methoxypsoralen (8-MOP) to epidermal lipids, proteins and DNA/RNA. *J Photochem Photobiol B*. 1989; 3:631–635. PMID: 2477521
- [13] Garcia-Diaz M, Huang YY, Hamblin MR: Use of fluorescent probes for ROS to tease apart type I and type II photochemical pathways in photodynamic therapy methods. 2016 Jun 30. pii: S1046-2023(16)30200-6. doi: 10.1016/j.ymeth.2016.06.025. [Epub ahead of print]. PMID: 27374076
- [14] Szekeres E, Török L, Szücs M: Appearance of disseminated hyperpigmented lesions during PUVA therapy. *Hautarzt*. 1981; 32:33–35. PMID: 7228659

- [15] Schneider B, Vogel A, Zisiadis S, Panizzon R, Groh V: Hyperpigmented small spots induced by long-term PUVA therapy. A clinical, light and electron microscopic study. *Dermatologica*. 1982; 165:330–341. PMID: 7152069
- [16] Jung EG, Obert W: The incidence of PUVA lentigines. *Photodermatol*. 1986; 3:46–47. PMID: 3703703
- [17] Cruz A, Sánchez JL: Acral PUVA-induced pigmented macules. *Bol Asoc Med P R*. 1990; 82:460–462. PMID: 2080960
- [18] Situm M, Bulat V, Majcen K, Dzapo A, Jezovita J: Benefits of controlled ultraviolet radiation in the treatment of dermatological diseases. *Coll Anthropol*. 2014; 38:1249–1253. PMID: 25842770
- [19] Lowe NJ, Weingarten D, Bourget T, Moy LS: PUVA therapy for psoriasis: Comparison of oral and bath-water delivery of 8-methoxypsoralen. *J Am Acad Dermatol*. 1986; 14:754–760. PMID: 3711379
- [20] Thomas SE, O'Sullivan J, Balac N: Plasma levels of 8-methoxypsoralen following oral or bath-water treatment. *Br J Dermatol*. 1991; 125:56–58. PMID: 1873204
- [21] Tegeder I, Bräutigam L, Podda M, Meier S, Kaufmann R, Geisslinger G, Grundmann-Kollmann M: Time course of 8-methoxypsoralen concentrations in skin and plasma after topical (bath and cream) and oral administration of 8-methoxypsoralen. *Clin Pharmacol Ther*. 2002; 71:153–161. PMID: 11907489. doi: 10.1067/mcp.2002.121908
- [22] Guengerich FP: Cytochrome P450s and other enzymes in drug metabolism and toxicity. *AAPS J*. 2006; 8:E101–E111. doi: 10.1208/aapsj080112
- [23] Wang X1, Lou YJ, Wang MX, Shi YW, Xu HX, Kong LD: Furocoumarins affect hepatic cytochrome P450 and renal organic ion transporters in mice. *Toxicol Lett*. 2012; 20:67–77. doi: 10.1016/j.toxlet.2011.11.030. Epub 2011 Dec 7.
- [24] Cederbaum AI, Wu D, Mari M, Bai J: CYP2E1-dependent toxicity and oxidative stress in HepG2 cells. *Free Radic Biol Med*. 2001; 31:1539–1543. PMID: 11744327
- [25] Koenigs LL, Trager WF: Mechanism-based inactivation of cytochrome P450 2B1 by 8-methoxypsoralen and several other furanocoumarins. *Biochemistry*. 1998; 37:13184–38193. doi: 10.1021/bi981198r
- [26] Baumgart A1, Schmidt M, Schmitz HJ, Schrenk D: Natural furocoumarins as inducers and inhibitors of cytochrome P450 1A1 in rat hepatocytes. *Biochem Pharmacol*. 2005; 69:657–667. Epub 2005 Jan 12. PMID: 15670584.
- [27] Tverdohleb T, Dinc B, Knezevic I, Candido KD, Knezevic NN: The role of cytochrome P450 pharmacogenomics in chronic non-cancer pain patients. *Expert Opin Drug Metab Toxicol*. 2016 Jul 7 [Epub ahead of print]. PMID: 27388970

- [28] Wamer W, Giles A Jr, Kornhauser A: Kinetics of 8-methoxypsoralen and 5-methoxypsoralen distribution in guinea pig serum, epidermis and ocular lens. *Photodermatol.* 1987; 4:236–239. PMID: 3697346
- [29] Bech-Thomsen N, Wulf HC: A polychromatic action spectrum for photosensitivity to orally administered 8-methoxypsoralen in humans. *Clin Exp Dermatol.* 1994; 19:12–15. PMID: 8313631
- [30] Anigbogu AN, Williams AC, Barry BW: Permeation characteristics of 8-methoxypsoralen through human skin; relevance to clinical treatment. *J Pharm Pharmacol.* 1996; 48:357–366. PMID: 8794983
- [31] Reuther T, Gruss C, Behrens S, von Kobyletzki G, Neumann N, Lehmann P, Altmeyer P, Kerscher M: Time course of 8-methoxypsoralen-induced skin photosensitization in PUVA-bath photochemotherapy. *Photodermatol Photoimmunol Photomed.* 1997; 13:193–196. PMID: 9542757
- [32] von Kobyletzki G, Hoffmann K, Kerscher M, Altmeyer P: Plasma levels of 8-methoxypsoralen following PUVA-bath photochemotherapy. *Photodermatol Photoimmunol Photomed.* 1998; 14:136–138. PMID: 9779504
- [33] Delrosso G. *Photodermatology and phototherapy.* Interlinea Ed, Novara, Italy, 2016. ISBN 97888-6857-078-1
- [34] Dolezal E, Seeber A, Hönigsmann H, Tanew A: Correlation between bathing time and photosensitivity in 8-methoxypsoralen (8-MOP) bath PUVA. *Photodermatol Photoimmunol Photomed.* 2000; 16:183–185. PMID: 11019944
- [35] Tanew A, Kipfelsperger T, Seeber A, Radakovic-Fijan S, Hönigsmann H: Correlation between 8-methoxypsoralen bath-water concentration and photosensitivity in bath-PUVA treatment. *J Am Acad Dermatol.* 2001; 44:638–642. PMID: 11260539. doi: 10.1067/mjd.2001.112360
- [36] David M, Lowe NJ, Halder RM, Borok M: Serum 8-methoxypsoralen (8-MOP) concentrations after bath water delivery of 8-MOP plus UVA. *J Am Acad Dermatol.* 1990; 23:931–932. PMID: 2254480
- [37] Löffler H, Aramaki J, Friebe K, Happle R, Effendy I: Changes in skin physiology during bath PUVA therapy. *Br J Dermatol.* 2002; 147:105–109. PMID: 12100191
- [38] Grundmann-Kollmann M, Ochsendorf FR, Zollner TM, Tegeder I, Kaufmann R, Podda M: Cream psoralen plus ultraviolet A therapy for granuloma annulare. *Br J Dermatol.* 2001; 144:996–999. PMID: 11359387
- [39] Hannuksela M, Karvonen J: Trioxsalen bath plus UVA effective and safe in the treatment of psoriasis. *Br J Dermatol.* 1978; 99:703–707. PMID: 737133

- [40] Väättäinen N, Hollmen A, Fräki JE: Trimethylpsoralen bath plus ultraviolet A combined with oral retinoid (etretinate) in the treatment of severe psoriasis. *J Am Acad Dermatol*. 1985; 12:52–55. PMID: 3980803
- [41] Kerscher M, Volkenandt M, Meurer M, Lehmann P, Plewig G, Röcken M: Treatment of localised scleroderma with PUVA bath photochemotherapy. *Lancet*. 1994; 343:1233. PMID: 7909904
- [42] Hawk JL, Grice PL: The efficacy of localized PUVA therapy for chronic hand and foot dermatoses. *Clin Exp Dermatol*. 1994; 19:479–482. PMID: 7889668
- [43] Schiener R, Gottlöber P, Müller B, Williams S, Pillekamp H, Peter RU, Kerscher M: PUVA-gel vs. PUVA-bath therapy for severe recalcitrant palmoplantar dermatoses. A randomized, single-blinded prospective study. *Photodermatol Photoimmunol Photomed*. 2005; 21:62–67. PMID: 15752122. doi: 10.1111/j.1600-0781.2005.00134.x
- [44] Batchelor R, Clark S: Clearance of generalized papular umbilicated granuloma annulare in a child with bath PUVA therapy. *Pediatr Dermatol*. 2006; 23:72–74. PMID: 16445418
- [45] Vongthongsri R, Konschitzky R, Seeber A, Treitl C, Hönigsmann H, Tanew A: Randomized, double-blind comparison of 1 mg/L versus 5 mg/L methoxsalen bath-PUVA therapy for chronic plaque-type psoriasis. *J Am Acad Dermatol*. 2006; 55:627–631. PMID: 17010742. doi: 10.1016/j.jaad.2006.05.024
- [46] Delrosso G, Bornacina C, Farinelli P, Bellinzona F, Leigheb G, Colombo E: Bath PUVA and psoriasis: Is a milder treatment a worse treatment? *Dermatology* 2008; 216:191–193. PMID: 18182808. doi: 10.1159/000112924
- [47] Ghoreschi K, Thomas P, Penovici M, Ullmann J, Sander CA, Ledderose G, Plewig G, Kolb HJ, Röcken M: PUVA-bath photochemotherapy and isotretinoin in sclerodermatous graft-versus-host disease. *Eur J Dermatol*. 2008; 18:667–670. PMID: 18955201. doi: 10.1684/ejd.2008.0517
- [48] Weber F, Schmuth M, Sepp N, Fritsch P: Bath-water PUVA therapy with 8-methoxypsoralen in mycosis fungoides. *Acta Derm Venereol*. 2005; 85:329–332. PMID: 16191854. doi: 10.1080/00015550510032814
- [49] Hoetzenecker W, Guenova E, Hoetzenecker K, Yazdi A, Röcken M, Berneburg M: Successful treatment of recalcitrant lymphomatoid papulosis in a child with PUVA-bath photochemotherapy. *Eur J Dermatol*. 2009; 19:646–647. PMID: 19797036. doi: 10.1684/ejd.2009.0790
- [50] Friedland R, David M, Feinmesser M, Fenig-Nakar S, Hodak E: Idiopathic guttate hypomelanosis-like lesions in patients with mycosis fungoides: A new adverse effect of phototherapy. *J Eur Acad Dermatol Venereol*. 2010; 24:1026–1030. Epub 2010 Feb 17. PMID: 20180893. doi: 10.1111/j.1468-3083.2010.03571.x
- [51] Errichetti E, Piccirillo A, Ricciuti F, Ricciuti F: Steroid-resistant localized lymphomatoid papulosis treated with local bath-PUVA therapy. *Indian J Dermatol*. 2013; 58:163. PMID: 23716855 PMCID: PMC3657265. doi: 10.4103/0019-5154.108109

- [52] Kato H, Saito C, Ito E, Furuhashi T, Nishida E, Ishida T, Ueda R, Inagaki H, Morita A: Bath-PUVA therapy decreases infiltrating CCR4-expressing tumor cells and regulatory T cells in patients with mycosis Fungoides. *Clin Lymphoma Myeloma Leuk*. 2013; 13:273–280. PMID: 23332394. doi: 10.1016/j.clml.2012.12.002
- [53] Halpern SM, Anstey AV, Dawe RS, Diffey BL, Farr PM, Ferguson J, Hawk JL, Ibbotson S, McGregor JM, Murphy GM, Thomas SE, Rhodes LE: Guidelines for topical PUVA: A report of a workshop of the British photodermatology group. *Br J Dermatol*. 2000; 142:22–31. PMID: 10651690
- [54] Rodríguez-Granados MT, Carrascosa JM, Gárate T, Gómez-Díez S, Guimaraens-Juantorena D: Consensus document on bath-PUVA therapy. The Spanish Photobiology Group of the Spanish Academy of Dermatology and Venereology. *Actas Dermosifiliogr*. 2007; 98:164–170. PMID: 17504700
- [55] Grundmann-Kollmann M, Ochsendorf F, Zollner TM, Spieth K, Sachsenberg-Studer E, Kaufmann R, Podda M: PUVA-cream photochemotherapy for the treatment of localized scleroderma. *J Am Acad Dermatol*. 2000; 43:675–678. PMID: 11004625. doi: 10.1067/mjd.2000.105503
- [56] Engin B, Oguz O: Evaluation of time-dependent response to psoralen plus UVA (PUVA) treatment with topical 8-methoxypsoralen (8-MOP) gel in palmoplantar dermatoses. *Int J Dermatol*. 2005; 44:337–339. PMID: 15811091. doi: 10.1111/j.1365-4632.2004.02153.x
- [57] Grundmann-Kollmann M, Ochsendorf FR, Zollner TM, Tegeder I, Kaufmann R, Podda M: Cream psoralen plus ultraviolet A therapy for granuloma annulare. *Br J Dermatol*. 2001; 144: 996–999. PMID: 11359387
- [58] Pham CT, Koo JY: Plasma levels of 8-methoxypsoralen after topical paint PUVA. *J Am Acad Dermatol*. 1993; 28:460–466. PMID: 8445063
- [59] Nimkulrat P, Leenutaphong V, Sudtim S: Phototoxicity of new psoralen-containing gels and creams versus bath PUVA. *J Med Assoc Thai*. 2005; 88:1406–1411. PMID: 16519387
- [60] Archier E, Devaux S, Castela E, Gallini A, Aubin F, Le Maître M, Aractingi S, Bachelez H, Cribier B, Joly P, Jullien D, Misery L, Paul C, Ortonne JP, Richard MA: Carcinogenic risks of psoralen UV-A therapy and narrowband UV-B therapy in chronic plaque psoriasis: A systematic literature review. *J Eur Acad Dermatol Venereol*. 2012; 26:22–31. PMID: 22512677. doi: 10.1111/j.1468-3083.2012.04520.x
- [61] Rácz E, Prens EP, Kurek D, Kant M, de Ridder D, Mourits S, Baerveldt EM, Ozgur Z, van IJcken WF, Laman JD, Staal FJ, van der Fits L: Effective treatment of psoriasis with narrow-band UVB phototherapy is linked to suppression of the IFN and Th17 pathways. *J Invest Dermatol*. 2011; 131:1547–1558. PMID: 21412260. doi: 10.1038/jid.2011.53
- [62] Der-Petrossian M, Seeber A, Hönigsmann H, Tanew A: Half-side comparison study on the efficacy of 8-methoxypsoralen bath-PUVA versus narrow-band ultraviolet B phototherapy in patients with severe chronic atopic dermatitis. *Br J Dermatol*. 2000; 142:39–43. PMID: 10651692



- [63] Lee E, Koo J, Berger T: UVB phototherapy and skin cancer risk: A review of the literature. *Int J Dermatol*. 2005; 44:355–360. PMID: 15869531. doi: 10.1111/j.1365-4632.2004.02186.x
- [64] Kilinc Karaarslan I, Teban L, Dawid M, Tanew A, Kittler H: Changes in the dermoscopic appearance of melanocytic naevi after photochemotherapy or narrow-band ultraviolet B phototherapy. *J Eur Acad Dermatol Venereol*. 2007; 21:526–531. PMID: 17373982. doi: 10.1111/j.1468-3083.2006.02020.x
- [65] Stern RS; PUVA Follow up Study: The risk of melanoma in association with long-term exposure to PUVA. *J Am Acad Dermatol*. 2001; 44:755–761. PMID: 11312420. doi: 10.1067/mjd.2001.114576
- [66] Stern RS; PUVA follow-up study: The risk of squamous cell and basal cell cancer associated with psoralen and ultraviolet A therapy: A 30-year prospective study. *J Am Acad Dermatol*. 2012; 66:553–562. PMID: 22264671. doi: 10.1016/j.jaad.2011.04.004
- [67] Kim YS, Park YL, Lee JS, Whang KU: Multiple actinic keratosis, squamous cell carcinoma and basal cell carcinoma occurred after PUVA therapy in a Korean patient. *Photodermatol Photoimmunol Photomed*. 2014; 305:277–279. PMID: 24456558. doi: 10.1111/phpp.12114