

We are IntechOpen, the world's leading publisher of Open Access books Built by scientists, for scientists

4,800

Open access books available

122,000

International authors and editors

135M

Downloads

Our authors are among the

154

Countries delivered to

TOP 1%

most cited scientists

12.2%

Contributors from top 500 universities



WEB OF SCIENCE™

Selection of our books indexed in the Book Citation Index
in Web of Science™ Core Collection (BKCI)

Interested in publishing with us?
Contact book.department@intechopen.com

Numbers displayed above are based on latest data collected.

For more information visit www.intechopen.com



Cirrhotic Cardiomyopathy

Coskun Celtik, Nelgin Gerenli,
Halil Haldun Emiroglu and Nimet Cındık

Additional information is available at the end of the chapter

<http://dx.doi.org/10.5772/65318>

Abstract

Cirrhotic cardiomyopathy (CCMP) is a functional disorder characterized by electrophysiologic disturbances and diastolic and/or systolic dysfunction in patients with chronic liver disease, especially those with ascites and portal hypertension. This disorder is a well-defined entity in adults, but pediatric data are limited. Clinical and laboratory findings are generally latent. The diagnostic criteria are prolonged QT on electrocardiography due to metabolic and extrahepatic causes, in addition to some abnormal echocardiography findings. If echocardiographic findings are normal and only specific prolonged QT is present, this disorder is named as “latent CCMP”; otherwise, it is “manifest CCMP.” This disorder is important because it may lead to problems such as cardiac failure and dysrhythmia before or after liver transplantation. Moreover, it may worsen the prognosis.

Keywords: cirrhosis, portal hypertension, cardiomyopathy, prolonged QT, liver

1. Introduction

Portal hypertension (PHT) is an important disorder that increases morbidity and mortality rates. Many hemodynamic changes related to PHT occur in the human body. The majority of these changes are associated with hyperdynamic circulation, which is characterized by elevated heart rate and cardiac output accompanied by vasodilatation in the splanchnic area and systemic circulation and decreased systemic vascular resistance [1–9]. Moreover, disturbances of the autonomic nerve system and baroreceptors and the increased arterial

compliance in patients with cirrhosis aggravate the condition [10–12]. Hemodynamic changes that occur in portal hypertension are shown in **Table 1**.

Cardiovascular disorders associated with cirrhosis were first defined in alcoholic cirrhotic patients, in 1953 by Kowalski and Abelmann, but for many years, it was thought that these disorders were associated with chronic alcohol intake [10–12]. Similar disturbances were described in patients with cirrhosis who had hemochromatosis in some later research, but this time the changes were associated with hemochromatosis [13]. Consequently, cirrhotic cardiomyopathy was not known in those years.

Systemic circulation	
Plasma volume ↑	Cardiac flow (→) ↑
Total blood volume ↑	Arterial blood tension → ↓
Noncentral blood volume ↑	Heart rate ↑
Central arterial blood volume → ↓ (↑)	Systemic vascular resistance ↓
Heart	
Left atrial volume ↑	Right atrial tension → ↑
Left ventricle volume → (↓)	Right ventricle end-diastole tension →
Right atrial volume → ↑ ↓	Pulmonary arterial tension → ↑
Right ventricle volume → ↑ ↓	Pulmonary capillary wedge tension →
	Left ventricle end-diastole tension →
Pulmonary circulation	
Pulmonary blood flow ↑	Pulmonary vascular resistance ↓ (↑)
Renal circulation	
Renal blood flow ↓	Renal vascular resistance ↑
Cerebral circulation	
Cerebral blood flow ↓ →	
Skin, muscular, and skeletal circulation	
Skin blood flow → ↑	Muscular and skeletal circulation → ↑ ↓
↑, increased; ↓, decreased; →, not changed	

Table 1. The hemodynamic changes due to cirrhotic portal hypertension [6].

Caremele et al. first described cirrhotic cardiomyopathy in 1986. The authors demonstrated cardiac function disturbances due to cirrhosis in an experimental rat model and suggested the cirrhotic cardiomyopathy hypothesis. Their hypothesis was supported by subsequent research, and cardiac disorders due to cirrhosis and portal hypertension were named “cirrhotic cardiomyopathy” in 1989 [1–12, 14]. Although the name “hepatocardiac syndrome” was proposed by some authors instead of “cirrhotic cardiomyopathy,” this term was not accepted [14].

2. Definition

Cirrhotic cardiomyopathy (CCMP) is defined as a functional disorder characterized by electrophysiologic disturbances and diastolic and/or systolic dysfunction in patients with

cirrhotic PHT. Even though similar hemodynamic changes have been defined in long-term non-cirrhotic PHT, the development of CCMP in such patients has not been reported. Therefore, this term is usually used for patients with cirrhosis [10, 15–18].

3. Pathogenesis

In general, arterial vasodilatation, central hypovolemia, and hyperdynamic circulation which occur as a result of cirrhosis and portal hypertension lead to the development of CCMP together with hepatorenal syndrome and hepatopulmonary syndrome (**Figure 1**) [11, 19–23]. Effects of vasoactive agents are very important in pathogenesis of CCMP. Experimentally, some changes were defined in CCMP, such as downregulation of the density of β receptors, impaired β -adrenergic signaling, alternations of calcium-ion channels, and alternations in plasma membrane fluidity in cardiomyocytes. In addition, the increased serum bile acids, cytokines, and endotoxins have been shown to create negative effects on cardiomyocytes [9–12, 14, 22].

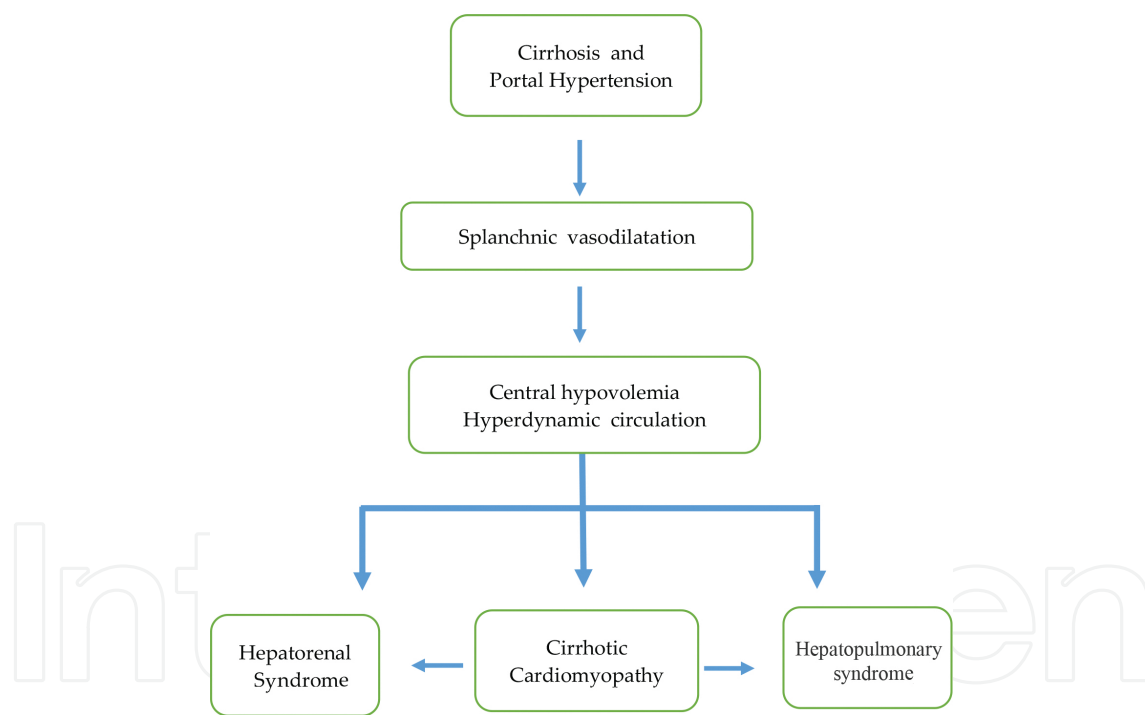


Figure 1. Cirrhotic cardiomyopathy pathogenesis.

Vasoconstrictor substances are high in the early stages of PHT, and vasodilator substances gradually increase in advanced stages; the balance tips in favor of vasodilators and a receptor insensitivity develops against vasoconstrictors [10–12, 19, 23–30]. As a result of these events, arterial vasodilatation results and the severity of PHT increases [19, 23–30].

The splanchnic vasodilatation that develops in PHT is combined with a hyperkinetic systemic circulation, low arterial tension, decreased peripheral resistance, and increased cardiac flow.

Although total plasma volume increases, as a result of collection of blood in the splanchnic area, effective blood capacity cannot be achieved, and central hypovolemia develops. After these changes, activation of the sympathetic nervous system and renin-aldosterone system occurs; vasopressin release from the hypothalamus increases, which results in fluid and salt retention [30–33].

The vasoconstrictor and vasodilator substances in the pathogenesis PHT become effective together. The most important vasoconstrictor substances are norepinephrine, angiotensin II, vasopressin, thromboxane (TX), and leukotrienes. The effects of these substances are related with activation of the sympathetic nervous system and renin-angiotensin-aldosterone system. Researches have shown that portal venous tension can be decreased using alpha-adrenergic antagonists (prazosin), beta-adrenergic antagonists (propranolol), angiotensin-II antagonists, cyclooxygenase isoenzyme blockers, and TX antagonists. Results of these researches support the pathogenesis [22, 29–34].

Endothelin (ET) can show vasoconstrictor or vasodilator effects according to the type. Endothelins are classified as ET-1, ET-2, and ET-3 according to their region in the body. ET-1 is mainly found in endothelial cells, the kidney, and the brain and ET-2 in the small intestine and kidney, and ET-3 is found in the blood. ET-1 and ET-2 create a vasoconstrictor effect, whereas ET-3 has a vasodilator effect. These two opposite effects are associated with the induction of nitric oxide and prostacyclin release. The most potent vasoconstrictor substance in the body is ET-1, and it is reported that this substance is very effective in the development of PHT complications [22, 29–34].

Nitric oxide (NO) is another very potent substance in the pathogenesis of PHT. NO is synthesized from arginine by nitric oxide synthetase (NOS) and causes vasodilatation by increasing cyclic guanosine monophosphate. NO initially increases to compensate against the elevated vasoconstrictor agents in the early stage of PHT, but secondary systemic and splanchnic vasodilatation develops because of excessive NO production. This event is a result of stimulation of NOS by cytokines such as TNF-alpha, which increases in cirrhosis [22, 30–36].

The other important vasodilator substances in the pathogenesis of PHT are carbon monoxide (CO), hydrogen sulfide (H₂S), prostaglandins, glucagon, and endocannabinoids. CO formed through the heme-oxygenase system is a weaker vasodilator agent than NO, but it is important for regulation of intrahepatic vascular tone. H₂S is formed by intestinal microbiota and increases the effects of other vasodilator substances and PHT severity [22, 30–36].

Prostaglandins are endogen vasodilators produced in the endothelium and are important for hyperdynamic circulation. Prostacyclin is produced from the vascular endothelium. It leads to vasodilatation, which increases the level of intracellular cyclic adenosine monophosphate (c-AMP) through the activation of adenylate cyclase. In recent studies, it was shown that indomethacin, a prostacyclin inhibitor, decreased the hyperdynamic circulation and balanced the vasoconstrictor effect [22, 30–36].

Glucagon is a hormone released from the pancreas. Glucagon levels increase as a result of low hepatic clearance and stimulation of pancreatic alpha cells in patients with cirrhosis. Glucagon also has the effect of reducing endogenous vasoconstrictor activity in addition to having a

vasodilator effect. The use of somatostatin and synthetic glucagon analogs for PHT therapy has been proposed in some studies; however, these agents may constitute a risk because they can aggravate the splanchnic vasodilatation in advanced stages [22, 30–36].

Endocannabinoids such as anandamide are vasodilator substances that increase in PHT, worsen hepatic microcirculation, and accelerate apoptosis. These substances act by stimulating CB1 and CB2 receptors in the vascular endothelium. It has been reported that endogenous cannabinoids show a negative inotropic effect on myocardial contractions, and therefore these substances are very important for the development of cirrhotic cardiomyopathy [39–41]. These negative effects can be blocked by CB-1 receptor antagonists (AM251) [22, 30–40].

4. Clinical finding and diagnosis

Cirrhotic cardiomyopathy (CCMP) represents a condition in which no real cardiac disease is present but a functional cardiac abnormality exists. With time, CCMP progresses to the chronic phase. In a resting state, there is no real disease, but with stress, the cardiac muscle does not contract appropriately and and/or electrophysiologic abnormalities appear [10–12]. There is no exact classification for CCMP and the criteria proposed by Moller et al. are still used (**Table 2**). These data are taken from an adult studies, pediatric data are very limited [41–45]. The most important points from these criteria are (1) at rest, normal, or increased left ventricular contractibility; (2) abnormal systolic contraction or diastolic relaxation with pharmacologic, physiologic, or surgical stress; and (3) cardiac electrical abnormalities [10, 11].

Diagnosis of CCMP in children with cirrhosis is difficult, because invasive methods are life-threatening and noninvasive tests are unreliable for them. In recent years, a new article was published in which CCMP criteria for children were reviewed [45]. According to this literature, a prolonged QT interval on electrocardiography (ECG) is an important finding after all non-liver causes are excluded, and shows latent cardiomyopathy due to cirrhotic changes. If there is the presence of echocardiographic abnormalities, this event is a manifest CCMP [45].

Cirrhotic cardiomyopathy is a latent disease in which there is no abnormality except under stress conditions. In such patients, there is no cardiac disease till end-stage disease. At end stage, infrequent arrhythmias or cardiac insufficiency may be seen. If these findings exist in an early cirrhotic stage, other causes of cardiomyopathy such as infections, metabolic disorders, endocrinopathies, ischemic or toxic causes, and genetic and systemic diseases should be investigated [46].

Cirrhotic cardiomyopathy is more likely dilated cardiomyopathy where some stress factors cause cardiac dysfunction. With stress, the clinical status of the patient deteriorates and decompensation may exist. These stress factors are exercise, infection, positional changes, feeding, paracentesis with high volumes, changes in intravascular volume, the use of vasoconstrictor drugs, transjugular intrahepatic portosystemic shunts (TIPS), or surgical procedures such as minor operations or liver transplantation [10–12]. Exercise tolerance in patients with cirrhosis is abnormal due to cardiac function abnormalities, and this correlates with the patient's Child score [47].

Systolic dysfunction criteria	Supporting criteria
<ul style="list-style-type: none"> Inadequate cardiac flow to pharmacologic agents, exercise, blood volume changes Resting ejection fraction under 55 % 	<ul style="list-style-type: none"> Electrophysiologic abnormalities Abnormal chronotropic response Electromechanical uncoupling/dyssynchronism
<p>Diastolic dysfunction</p> <ul style="list-style-type: none"> E/A ratio <1,0 (corrected according to age) Prolonged deceleration time (>200 milliseconds) Prolonged isovolumetric relaxation time (>80 milliseconds) 	<ul style="list-style-type: none"> Prolonged QT intervals Expanded left atrium Increased myocardial mass Increased BNP and pro-BNP levels Increased troponin I levels

BNP, brain natriuretic peptide; E/A ratio, the ratio between the early (E) and late atrial (A) phases of ventricular velocity

Table 2. Diagnostic criteria of cirrhotic cardiomyopathy.

There is a relationship between CCMP and hepatorenal syndrome (HRS), which has been reported in many articles published in recent years, so patients with HRS are at more risk [5, 25, 48].

Cardiac functions in patients with liver cirrhosis are determined by physical examination, ECG, and telecardiography besides of echocardiography. Cardiac functions such as systolic, diastolic, and electromechanical functions should be evaluated in suspected CCMP. ECG is sufficient for determining electrophysiologic function. Systolic and diastolic functions are checked using M-Mod, two- and three-dimensional echocardiography, and spectral and tissue Doppler echocardiography. Cardiac magnetic resonance imaging, radio nuclear angiography, and myocardial perfusion techniques are more advanced methods. Many times, for a diagnosis of CCMP, the findings on ECG and echocardiography are enough.

Firstly, systolic function worsens in the late stage of CCMP. After then, the diastolic functions gradually decay. Diastolic dysfunction is best shown with echocardiographic measurement of the E/A ratio. Deceleration time (DT) and the isovolumetric relaxation time (IVRT) also are used. The E/A ratio results from blood velocity from the left atrium to the left ventricle, the velocity of which during early systole causes the E wave and the same flow causes the A wave during late diastole.

The measurement of E and A waves is expressed as cm/sec and best is done from mitral valve projection. A normal E/A ratio in healthy individuals until the age of 50 years is 1–2 cm/s, but in older people, it decreases below 1 cm/s. An E/A ratio in healthy individuals aged less than 50 years below 1 cm/s shows diastolic dysfunction. However, the restrictive pattern can be observed in advanced stages depending on the severity of the disorder in the patients with CCMP; the E/A ratio may reverse in these cases and may be determined >2 [10, 11, 49] (**Figure 2**).

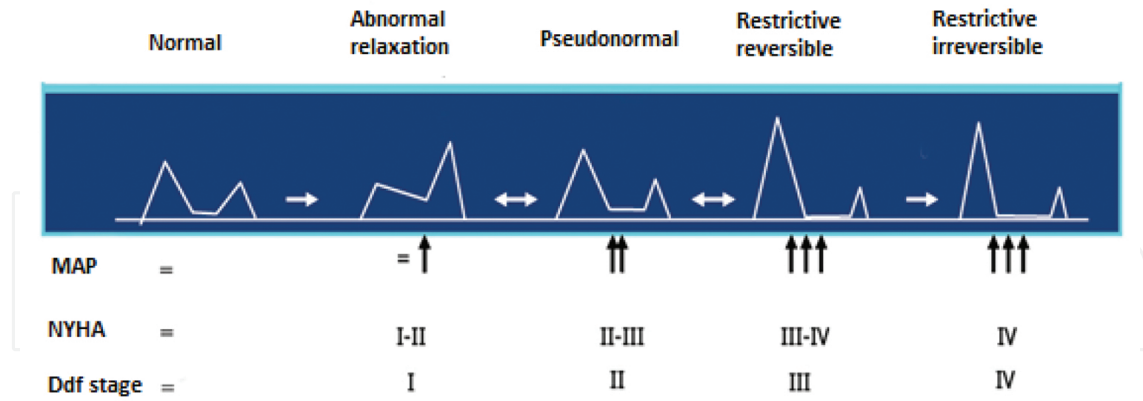


Figure 2. Diastolic dysfunction stages [49]. MAP, mean atrial pressure; NYHA, New York Heart Association; Ddf stage, diastolic dysfunction stage.

Indicator	Normal pattern	Abnormal relaxation (stage I)	Pseudonormal pattern (stage II)	Restrictive pattern (stages III-IV)
E/A	>1	<1	1-2	≥2
DT (msn)	160-210	>220	150-200	<150
IVGT (msn)	70-90	>95	60-95	<60

DT, deceleration time; E/A, transmitral early diastolic flow (E)/transmitral late diastolic flow (atrial) (A) ratio; IVGT, isovolumetric relaxation time (msn).

Table 3. Echocardiographic stages of left ventricular diastolic dysfunction [49].

There are different stages in CCMP. Clinical findings differ according to stage (**Table 3**). The E/A ratio worsens according to the severity of hepatic disease and it is worse in patients with ascites than in patients with non-ascites and normal persons. The E/A ratio improves after paracentesis and this event supports that ascites is the negative effect on cardiac functions [50-53]. There are no publications on these themes in children. There is no definitive normal value for the E/A ratio in children, but in some publications, it is proposed to be between 1.7 and 2.5 cm/s.

Electrical conduction abnormalities and arrhythmias can be seen in the patients according to severity of cirrhosis [8, 9] [54-58]. There are three types of electrophysiologic abnormalities caused by cirrhosis: (1) prolonged QT on ECG, (2) inadequate response to chronotropic stress, and (3) electromagnetic dyssynchronism [10, 11, 14]. The prolonged QT on ECG means a corrected QT interval (QTc) is longer than 0.440 value [41, 54, 55]. Prolonged QT shows abnormal myocardial repolarization as a sign of CCMP [10-12, 56-58]. QT prolongation

proportionally increases with cirrhotic stage [56]. Prolonged QT on ECG is frequently seen in patients with CCMP. The rate of determination of prolonged QT is 30–60 % in adults with CCMP and in 18–45 % of pediatric patients [5, 41, 44, 56].

Actually, a prolonged QT interval may cause life-threatening arrhythmias [55], but in many patients with CCMP, despite a prolonged QT interval, no significant clinical problem and arrhythmia are not observed. Cardiac arrhythmias in cirrhotic patients are frequently related to vasopressin use. There is no evidence that a prolonged QT interval in patients with CCMP causes life-threatening arrhythmias. Probably, some compensatory mechanisms in cirrhotic patients prevent the disturbances and the disease occurs latent until end stage.

5. Treatment

Treatment consists of preventing stress exposure in patients with CCMP; rest and oxygen supplementation are important [10, 59]. There is no need for pharmacotherapy when there is no cardiac insufficiency. Drugs have adverse effects and pharmacotherapy response is weak in patients with CCMP. In recent years, aldosterone antagonists, cannabinoid receptor antagonists, and spironolactone have been used, but only the effectiveness of beta-blockers has been proved [10, 35, 59]. Beta-blockers can decrease QT wave duration [10, 32, 33]. Diagnosis of CCMP at an early stage is important. Early diagnosis and proper treatment with cardioprotective agents are important for decreasing complications during and after liver transplantation. There are no exact data on prognosis for liver transplantation in patients with CCMP. Data from the past showed that CCMP worsens in the early period after liver transplantation, and later cardiac functions and cardiac electromechanical dysfunctions improve gradually by supplying hemodynamic stabilization of the patient [10, 59–64]. Liver transplantation can be a definitive treatment for CCMP. New pharmacologic agents are needed to help these patients because many patients do not have the chance to receive a transplant.

Author details

Coskun Celtik^{1*}, Nelgin Gerenli¹, Halil Haldun Emiroglu² and Nimet Cındık³

*Address all correspondence to: cceltik2001@yahoo.com

1 Pediatric Gastroenterology, Health Sciences University, Istanbul Umraniye Training and Research Hospital, Istanbul, Turkey

2 Pediatric Gastroenterology, Selcuk University, Faculty of Medicine, Konya, Turkey

3 Pediatric Cardiology, Health Sciences University, Istanbul Umraniye Training and Research Hospital, Istanbul, Turkey

References

- [1] Baik SK, Lee SS. Cirrhotic cardiomyopathy; causes and consequences. *J Gastroenterol Hepatol*, 2004;19(7): 185–190, DOI: 10.1111/j.1440-1746.2004.03639.x.
- [2] Mandell MS, Tsou MY. Cardiovascular dysfunction in patient with end-stage liver disease. *J Clin Med Assoc*, 2008;71(7): 331-335, DOI: 10.1016/S1726-4901(08)70134-5.
- [3] Liu H., Lee S. Cardiopulmonary dysfunction in cirrhosis. *J Gastroenterol Hepatol*, 1999;14(6): 600-608. DOI: 10.1046/j.1440-1746.1999.01920.x.
- [4] Lee, R., Glenn T., Lee S. Cardiac dysfunction in cirrhosis. *Best Pract Res Clin Gastroenterol*, 2007;21(1): 125-140. DOI: 10.1016/j.bpg.2006.06.003.
- [5] Baik S, Fouad T, Lee S. Cirrhotic cardiomyopathy. *Orphanet J Rare Dis*, 2007;2(15): 1-8. DOI: 10.1186/1750-1172-2-15.
- [6] Møller S., Henriksen J. Cardiovascular dysfunction in cirrhosis. Pathophysiological evidence of a cirrhotic cardiomyopathy. *Scand J Gastroenterol*, 2001;36(8): 785-794. DOI: 10.1080/00365520120972.
- [7] Liu H., Song D., Lee S. Cirrhotic cardiomyopathy. *Gastroenterol Clin Biol*, 2002;26(10), 842-847. DOI: GCB-10-2002-26-10-0399-8320-101019-ART4.
- [8] Blendis L., Wong F. Is there a cirrhotic cardiomyopathy? *Am J Gastroenterol*, 2000;95, 3026-3028. DOI: 10.1111/j.1572-0241.2000.03306.x.
- [9] Hamoudi WA, Lee SS. (2006): Cirrhotic cardiomyopathy. *Ann Hepatol*, 5, 132-139. PMID: 17060868.
- [10] Wong, F. Cirrhotic cardiomyopathy. *Hepatol Int*, 2009;3(1), 294-304. DOI: 10.1007/s12072-008-9109-7
- [11] Moller S, Henricsen JH. Cardiovascular complications of cirrhosis. *Postgrad Med J*, 2009;85,44-54. DOI: 10.1136/gut.2006.112177.
- [12] Swanson KL., Krowka MJ. Pulmonary complications associated with portal hypertension. In: Sanyal AJ, Shah VH, editors. *Portal Hypertension; Pathobiology, Evaluation, and Treatment*, Humana Press, Totowa, 2005. p. 455-468. ISBN 1-58829-386-6
- [13] Niederau C, Fischer R, Sonnenberg A, Stremmel W, Trampisch HJ, Strohmeyer G. Survival and causes of death in cirrhotic and in noncirrhotic patients with primary hemochromatosis. *N Engl J Med*. 1985;313(20),1256-1262. DOI: 10.1056/NEJM19851143132004
- [14] Milani, A., Zaccaria R., Bombardieri G., Gasbarrini A., Pola P. (2007): Cirrhotic cardiomyopathy. *Dig Liver Dis*, 39, 507-515. DOI: 10.1016/j.dld.2006.12.014
- [15] Sarin SK, Wadhawan M. Noncirrhotic portal hypertension and portal vein thrombosis. In: Sanyal AJ, Shah VH, editors. *Portal Hypertension: Pathobiology,*

Evaluation, and Treatment, Humana Press Inc, Totowa, NJ. 2005. p. 411-432. ISBN 1-58829-386-6

- [16] Molina, E. & K. Reddy. Noncirrhotic portal hypertension. *Clin Liver Dis*, 2001;5(3), 769-87. PMID: 11565140
- [17] Sarin SK, Kapoor D. Non-cirrhotic portal fibrosis; current concept and management. *J Gastroenterol Hepatol*, 2002;17(5), 526-534. DOI: 10.1046/j.1440-1746.2002.02764.x
- [18] Okudaira M., Ohbu M., Okuda K. Idiopathic portal hypertension and its pathology. *Semin Liver Dis*, 2002;22(1), 59-72. DOI: 10.1055/s-2002-23207.
- [19] Gunaratnam NT., Su GL. Pathogenesis and consequences of portal hypertension. In: Rose S, editor. *Gastrointestinal and Hepatobiliary Pathophysiology*, Fence Creek Publishing, Madison, 1998. p.315-326. ISBN: 1-59377-181-9
- [20] Møller S, Henriksen JH. Cardiovascular complications of cirrhosis. *Gut*, 2008;57(2), 268-278. DOI: 10.1136/gut.2006.112177
- [21] Ma Z., Lee S. Cirrhotic cardiomyopathy; getting to the heart of the matter. *Hepatology*, 1996;24 (2), 451-459. DOI: 10.1002/hep.510240226
- [22] Wiese S, Hove JD, Bendtsen F, Moller S. Cirrhotic cardiomyopathy: pathogenesis and clinical relevance. *Nat Rev Gastroenterol Hepatol*, 2014; 11(3), 177-186. DOI: 10.1038/nrgastro.2013.210
- [23] Treiber G., Csepregi A., Malfertheiner P. The pathophysiology of portal hypertension. *Dig Dis*, 2005;23 (1), 6-10. DOI: 10.1159/000084720
- [24] Bosch J., Garcia-Pagan JC. Complications of cirrhosis. I. Portal hypertension. *J Hepatol*, 2000; 32 (Suppl. 1), 141-156. DOI: 10.1016/S0168-8278(00)80422-5
- [25] Liu H., Gaskari S., Lee S. Cardiac and vascular changes in cirrhosis; pathogenic mechanisms. *World J Gastroenterol*, 2006;12(6), 837-42. DOI: 10.3748/WJG.v12.i6.837
- [26] Niederberger M., Schrier R. Pathogenesis of sodium and water retention in liver disease. *Prog Liver Dis*, 1992;10, 329-47. PMID:1296235
- [27] Møller S., Bendtsen F., Henriksen J. Splanchnic and systemic hemodynamic derangement in decompensated cirrhosis. *Can J Gastroenterol*, 2001;15 (2), 94-106. DOI: 10.1155/2001/603012
- [28] Møller S, Bendtsen F, Henriksen JH. Vasoactive substances in the circulatory dysfunction of cirrhosis. *Scand J Clin Lab Invest*, 2001;61, 421-429. DOI: 10.1080/00365510152567059
- [29] Møller S., Henriksen JH. Cirrhotic cardiomyopathy: a pathophysiological review of circulatory dysfunction in liver disease. *Heart*, 2002;87 (1), 9-15. DOI:10.1136/heart.87.1.9
- [30] Pinzani M, Vizzutti F. Anatomy and vascular biology of the cells in the portal circulation. In: Sanyal AJ., Shah VH, editors. *Portal Hypertension; Pathobiology*,

Evaluation, and Treatment, Humana Press Inc, Totowa, NJ, 2005, p.15-35. ISBN 1-58829-386-6

- [31] Ryckman FC., Alonso MH., Tiao G. Causes and management of portal hypertension in the pediatric population. In: Sanyal AJ, Shah VH, editors. Portal Hypertension; Pathobiology, Evaluation, and Treatment, Humana Press Inc, Totowa, 2005, p.383-410. ISBN 1-58829-386-6
- [32] Zambruni A, Trevisani F, Di Micoli A, Savelli F, Berzigotti A, Bracci E, Caraceni P, Domenicali M, Felling P, Zoli M, Bernardi M. Effect of chronic beta-blockade on QT interval in patients with liver cirrhosis. *J Hepatol*, 2008;48(3), 415–421. DOI: 10.1016/j.jhep.2007.11.012
- [33] Henriksen JH, Bendtsen F, Hansen EF, Møller S. Acute nonselective beta-adrenergic blockade reduces prolonged frequency adjusted Q-T interval (QTc) in patients with cirrhosis. *J Hepatol*, 2004;40(2), 239–246. DOI: 10.1016/j.jhep.2003.10.026
- [34] Pozzi M., Ratti L., Guidi C., Milanese M., Mancina G. Potential therapeutic targets in cirrhotic cardiomyopathy. *Cardiovasc Hematol Disord Drug Targets*, 2007;7(1), 21-26. DOI: 10.2174/187152907780059074
- [35] Mallat A., Lotersztajn S. Cannabinoid receptors as therapeutic targets in the management of liver diseases. *Drug News Perspect*, 2008;21(7), 363-8. DOI: 10.1358/dnp.2008.21.7.1255306
- [36] Liu H., Ma Z., Lee S. (2000): Contribution of nitric oxide to the pathogenesis of cirrhotic cardiomyopathy in bile duct-ligated rats. *Gastroenterology*, 118(5), 937-944. DOI: 10.1016/S0016-5085(00)70180-6
- [37] Pacher P., Bátkai S., Kunos G. Cirrhotic cardiomyopathy: an endocannabinoid connection? *Br J Pharmacol*, 2005;146 (3), 313-314. DOI: 10.1038/sj.bjp.0706332
- [38] Caraceni P., Domenicali M, Giannone F, Bernardi M. The role of the endocannabinoid system in liver diseases. *Best Pract Res Clin Endocrinol Metab*, 2009;23 (1), 65-77. DOI: 10.1016/j.beem.2008.10.009
- [39] Gaskari, S., Liu H., Moezi L., Li Y., Baik S., Lee S. Role of endocannabinoids in the pathogenesis of cirrhotic cardiomyopathy in bile duct-ligated rats. *Br J Pharmacol*, 2005;146 (3), 315-23. DOI: 10.1038/sj.bjp.0706331
- [40] Bátkai S., Pacher P. Endocannabinoids and cardiac contractile function; pathophysiological implications. *Pharmacol Res*, 2009;60 (2), 99-106. DOI: 10.1016/j.phrs.2009.04.003
- [41] Fishberger SB., Pittman NS., Rossi AF. Prolongation of the QT interval in children with liver failure. *Clin Cardiol*, 1999; 22(10), 658-60. DOI: 10.1002/clc.4960221013
- [42] Ozçay F, Tokel K, Varan B, Saygılı A. Cardiac evaluation of pediatric liver transplantation candidates. *Transplant Proc*, 2002; 34 (6), 2150-2152. DOI: 10.1016/S0041-1345(02)02886-5

- [43] Polat, T., Urganci N., Yalcin Y., Akdeniz C., Zeybek C., Erdem A., Celebi A. Evaluation of cardiac function by tissue Doppler imaging in children with chronic hepatitis. *J Pediatr Gastroenterol Nutr*, 2006;43 (2), 222-227. DOI: 10.1097/01.mpg.0000228101.12326.6f
- [44] Arikan C., Kilic M., Tungor G., Levent E., Yuksekkaya HA., Yagci RV., Aydogdu S. (2009): Impact of liver transplantation on rate-corrected QT interval and myocardial function in children with chronic liver disease. *Pediatr Transplant*, 13(3), 300-306. DOI: 10.1111/j.1399-3046.2008.00909.x
- [45] Celtik C, Durmaz O, Oner N, Yavuz T, Gökce S, Aydogan A, Nisli K, Emiroglu HH, Ömeroglu RE, Sökücü S. Investigation of cardiomyopathy in children with cirrhotic and noncirrhotic portal hypertension. *J Pediatr Gastroenterol Nutr*. 2015;60(2):177-81. DOI: 10.1097/MPG.0000000000000580.
- [46] Towbin JA, Lowe AM, Colan SD, Sleeper LA, Orav EJ, Clunie S, Messere J, Cox GF, Lurie PR, Hsu D, Canter C, Wilkinson JD, Lipshultz SE. Incidence, causes, and outcomes of dilated cardiomyopathy in children. *JAMA*, 2006;296 (15), 1867-1876. DOI: 10.1001/jama.296.15.1867
- [47] Terziyski K, Andonov V, Marinov B and Kostianev S. Exercise performance and ventilatory efficiency in patients with mild and moderate liver cirrhosis. *Clin Exp Pharmacol Physiol*, 2007;35 (2),135-140. DOI: 10.1111/j.1440-1681.2007.04751.x
- [48] Ruiz-del-Arbol L, Monescillo A, Arocena C, Valer P, Ginès P, Moreira V, Milicua JM, Jiménez W, Arroyo V. Circulatory function and hepatorenal syndrome in cirrhosis. *Hepatology*, 2005;42(2), 439-447. DOI: 10.1002/hep.20766
- [49] Tezel T. Evaluation of Diastolic Functions [Diyastolik fonksiyonların değerlendirilmesi]. Nobel Tıp Kitapevleri, Istanbul, Turkey 2007. p. 1-216. ISBN: 97897524205725.
- [50] Moller S, Henriksen JH. Cardiopulmonary complications in chronic liver disease. *World J Gastroenterol*, 2006;12(4), 526-538. DOI: 10.3748/WJG.v12.i4.526
- [51] Pozzi M, Carugo S, Boari G, Pecci V, de Ceglia S, Maggiolini S, Bolla GB, Roffi L, Failla M, Grassi G, Giannattasio C, Mancina G. Evidence of functional and structural cardiac abnormalities in cirrhotic patients with and without ascites. *Hepatology*, 1997;26(5), 1131-1137. DOI: 10.1002/hep.510260507
- [52] Valeriano, V., S. Funaro, R. Lionetti, O. Riggio, G. Pulcinelli, P. Fiore, A. Masini, S. De Castro & M. Merli. Modification of cardiac function in cirrhotic patients with and without ascites. *Am J Gastroenterol*, 2000;95 (11), 3200-3205. DOI: 10.1111/j.1572-0241.2000.03252.x
- [53] Finucci G, Desideri A, Sacerdoti D, Bolognesi M, Merkel C, Angeli P, Gatta A. Left ventricular diastolic function in liver cirrhosis. *Scand J Gastroenterol*, 1996;31(3), 279-284. DOI: 10.3109/00365529609004879

- [54] Miller MD, Porter CJ, Ackerman MJ. Diagnostic accuracy of screening electrocardiograms in long QT syndrome I. *Pediatrics*, 2001;108 (1), 8–12. DOI: 10.1542/peds.108.1.8
- [55] Friedman MJ, Mull CC, Shariieff GQ, Tsarouhas N. Prolonged QT syndrome in children: uncommon but potentially fatal entity. *J Emerg Med*, 2003;24(2), 173–179. DOI: 10.1016/S0736-4679(02)00721-7
- [56] Bernardi M, Calandra S, Colantoni A, Trevisani F, Raimondo ML, Sica G, Schepis F, Mandini M, Simoni P, Contin M, Raimondo G. Q-T interval prolongation in cirrhosis: prevalence, relationship with severity, and etiology of the disease and possible pathogenetic factors. *Hepatology*, 1998;27(1), 28-34. DOI: 10.1002/hep.510270106
- [57] Bal JS, Thuluvath PJ. Prolongation of QTc interval: relationship with etiology and severity of liver disease, mortality and liver transplantation. *Liver Int*, 2003;23, 243-248. DOI: 10.1034/j.1600-0676.2003.00833.x
- [58] Zambruni A, Trevisani F, Caraceni P, Bernardi M. Cardiac electrophysiological abnormalities in patients with cirrhosis. *J Hepatol*, 2006;44(5), 994-1002. DOI: 10.1016/j.jhep.2005.10.034
- [59] Gaskari S., Honar H., Lee S. Therapy insight; cirrhotic cardiomyopathy. *Nat Clin Pract Gastroenterol Hepatol*, 2006;3(6), 329-37. DOI: 10.1038/ncpgasthep0498
- [60] Acosta F, De La Morena G, Villegas M, Sansano T, Reche M, Beltran R, Roques V, Contreras RF, Robles R, Bueno FS, Ramirez P, Parrilla P. Evaluation of cardiac function before and after liver transplantation. *Transplant Proc*, 1999;31(6), 2369–2370. DOI: 10.1016/S0041-1345(99)00383-8
- [61] Myers R., Lee S. Cirrhotic cardiomyopathy and liver transplantation. *Liver Transpl*, 2000;6(4 suppl 1), 44-52. DOI: 10.1002/lt.500060510
- [62] Liu H., Lee S. What happens to cirrhotic cardiomyopathy after liver transplantation? *Hepatology*, 2005; 42(5), 1203-5. DOI: 10.1002/hep.20911
- [63] Torregrosa M, Aguadé S, Dos L, Segura R, González A, Evangelista A, Castell J, Margarit C, Esteban R, Guardia J, Genescà J. Cardiac alterations in cirrhosis; reversibility after liver transplantation, *J Hepatol*, 2005;42(1), 68-74. DOI: 10.1016/j.jhep.2004.09.008
- [64] Mandell MS, Lindenfeld J, Tsou MY, Zimmerman M. (2008): Cardiac evaluation of liver transplant candidates. *World J Gastroenterol*, 14(22), 3445-3451. DOI: 10.3748/wjg.14.3445

