

We are IntechOpen, the world's leading publisher of Open Access books Built by scientists, for scientists

4,800

Open access books available

122,000

International authors and editors

135M

Downloads

Our authors are among the

154

Countries delivered to

TOP 1%

most cited scientists

12.2%

Contributors from top 500 universities



WEB OF SCIENCE™

Selection of our books indexed in the Book Citation Index
in Web of Science™ Core Collection (BKCI)

Interested in publishing with us?
Contact book.department@intechopen.com

Numbers displayed above are based on latest data collected.
For more information visit www.intechopen.com



Endometriosis: When and How We Treat

Sidonia Maria Saceanu, Stefan Patrascu,
Anca Patrascu and Valeriu Surlin

Additional information is available at the end of the chapter

<http://dx.doi.org/10.5772/65296>

Abstract

Endometriosis is a chronic, nonmalignant and estrogen-dependent disease in which endometrial glandular epithelium and stroma are outside the uterine cavity (ovaries, peritoneum, or rectovaginal septum). The prevalence is estimated from 2 to 10% in women of childbearing age and it rises up to 50% in women with infertility. Despite maximal efforts, the therapy of first choice in the management of endometriosis is still unclear. The aim of this chapter is to present an update of its management, emphasizing the benefits and disadvantages of surgical methods. We performed a systematic literature search on the PubMed database of English literature (search terms: endometrioma, surgery, ovarian reserve, assisted reproductive technologies) from 2010 to 2014. For endometrioma, operative laparoscopy proved to be the gold standard. Surgical procedures consist of partial excision of the cyst wall and electro-coagulation of the rest. Stripping technique may be a better method for reducing the recurrence of pain symptoms, recurrence, and reoperation rates, but it raises concerns about ovarian reserve. For endometriosis, surgery often includes partial rectum or sacrouterine ligament resection. Hysterectomy is not obligatory and refused by the young patients. The approach should be laparoscopic and if necessary vaginal assisted. Good cooperation between various disciplines (gynecology, surgery, urology) is mandatory.

Keywords: endometriosis, endometrioma, laparoscopy, ovarian reserve, fertility

1. Introduction

1.1. Definitions

Endometriosis is a chronic, nonmalignant, and estrogen-dependent disease in which the endometrial glandular epithelium and stroma are found outside the uterine cavity (on the ovaries, peritoneum, or rectovaginal septum) [1].

The most frequently type of endometriosis is endometrioma. Concretely, an endometrioma is considered as the presence of endometrial tissue at the ovarian level organized as a cyst [2]. The incidence of endometrioma is estimated to be 20–45% of patients with endometriosis [3]. It can be diagnosed by ultrasound with relatively high sensitivity of 74%, but with a very high specificity of 94%; therefore, its prevalence could be estimated quite precisely [1, 4].

Although endometriosis usually affects ovaries and peritoneum, deep endometriosis, defined as infiltration of the peritoneum by a minimum of 5 mm can affect other structures like urinary tract, fallopian tubes, and bowels [1, 3].

Compared to ovarian endometriosis, very little is known about deeply infiltrating endometriosis. In this form, endometriosis can spread beyond organ borders and infiltrate various structures like sacrouterine ligament, the rectovaginal septum, the fornix of the vagina, the rectosigmoid, the urinary bladder or the ureter or also the small intestine [1–5].

1.2. Epidemiology

Despite its severity, endometriosis is a common benign gynecological disease [6].

The prevalence of endometriosis is estimated to range from 2 to 10% in women of childbearing age and its prevalence rises up to 50% in women with infertility [7]. It is one of the most common gynecological problems that can affect women in their reproductive years [4].

1.3. Pathogenesis

Endometriosis is a complex and multifactorial disease and its etiology and pathogenesis have not yet been completely clarified [8].

Many authors have described a group of risk factors like retrograde menstruation caused by the obstruction of menstrual flow, low immunity, exposure to diethylstilbestrol during neonatal period, genetic predisposition [2–4]. Another theory suggests that endometrial tissue is distributed from the uterus to other parts of the body through the lymph system or blood system [5–8]. Surgical implants have also been cited in many cases where endometriosis is found in abdominal laparotomy scars, like after a cesarean section [9, 10].

Other authors suggest that risk factors for endometriosis are smoking, duration of period bleeding, length of the menstrual cycle, number of pregnancies, and number of miscarriages [3–9].

In endometriosis, the ectopic endometrial tissue is morphologically similar to normal endometrium and it responds to ovarian hormones during cyclical changes similar to eutopic endometrium [11].

1.4. Diagnosis and evolution

Women with endometriosis may be asymptomatic, but the majority will present with pelvic pain, adnexal mass or subfertility/ infertility [3].

Definitive diagnosis is made through direct operative visualization by laparoscopy (**Figure 1**) or laparotomy and histological confirmation [9].

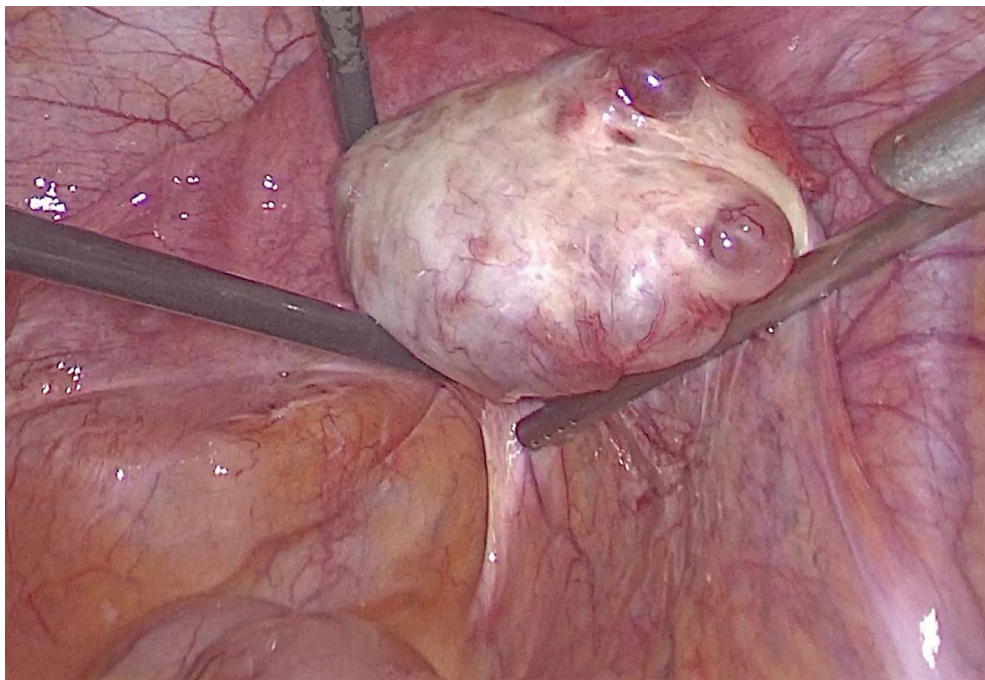


Figure 1. Twenty-four years old female patient, complaining of severe menstrual pain, with large endometrioma of the right ovary (5 cm).

On laparoscopy, endometriosis can appear as yellow-brown discolorations, raised flame-like patches, whitish opacifications or reddish irregularly shaped spots [1, 2].

Patients with endometriosis may present different clinical manifestations in different stages of the disease [10].

Endometriosis has four stages or types: stage I, minimal, with small lesions and shallow endometrial implants on the ovary; stage 2, mild, with light lesions and shallow implants on the ovary and the pelvic lining; stage 3, moderate, with deep and more implants on the ovary and pelvic lining; and stage 4, severe, with deep implants on the pelvic lining and ovaries [1–11].

Ovarian endometriomas, which are a common feature of endometriosis, create a complex situation for infertile patients [5].

In the opinion of many authors, endometriosis is one of the top three causes of female infertility and 30% to 40 % of women with endometriosis are infertile [5–6].

Fadhlaoui et al. showed that women with endometriosis have a reduced monthly fecundity rate (2–10%) compared with fertile couples (15–20%) at the same age [11]. The mechanisms underlying reproductive failure remain controversial, especially in cases where ovaries and fallopian tubes are normal [7].

The mechanism by which these endometriotic cysts lead to infertility may be related to mechanical stretching of the ovarian cortex as well as an inflammatory reaction with cytotoxic oxidative stress and increased fibrosis [1–3]. Surgery is the elective treatment for endometriomas and the most common technique is stripping of the endometrioma [11].

Both the presence and surgical excision of endometriomas appear to be damaging to ovarian function and ovarian reserve [6].

2. Treatment of endometriosis

2.1. Methods

We made a systematic literature search on the PubMed database of English literature (search terms was endometrioma, surgery, ovarian reserve, assisted reproductive technologies) from 2010 to 2014 and cross referencing. We gave priority to meta-analyses, randomized controlled trials reviews and cohort studies. We analyzed the benefits and disadvantages of surgical methods used to treat endometriosis.

2.2. Results

The treatment of endometriosis depends on the age of the patient, extent of disease, severity of symptom and the desired outcomes for fertility [1]. Despite maximal efforts, the therapy of first choice in the management of endometriosis is still unclear [12, 13].

2.2.1. Medical versus surgical therapy

Because endometriosis is a chronic disease, medical therapy should be, at least in theory, the first choice of treatment, while surgical procedures should be reserved for patients who do not respond to conservative treatments and whose symptoms affect their quality of life or cause infertility [8].

The aim of medical therapy is to achieve a hypoestrogenic status or to induce a pseudopregnancy [9]. Endometriosis implants can be regressively changed by means of suppression of ovarian function [11]. The drugs predominately used today are pure gestagens, progestatives, contraceptives, GnRH analogs, and danazol [5–7].

Every medical treatment is tolerable but should only be used as long as it is necessary [12]. This type of treatment should reduce the number of surgical interventions and improve the quality of life [13, 14].

Medical therapy can be also applied prior to surgery to decrease the size of endometriotic implants and the extent of the operation [1].

Another method consists of a combination of diagnostic laparoscopy with the removing of all visible endometriosis as far as possible followed by 3–6 months of endocrine therapy and a subsequent second-look laparoscopy with resection of residual foci, adhesiolysis, and reconstruction of organs [10–14].

So far there is no evidence that perioperative or postoperative hormonal treatment delays or prevents recurrence, reduce pelvic pain and patient's morbidity or increases pregnancy rates at a statistically significant level [15].

2.2.2. Rationale for surgery

Because endometriosis is a progressive and evolutive disease, which can cause anatomic destruction of the reproductive organs and infertility, surgical therapy has an important role [6–10].

The surgical treatment for endometriosis can be conservative or radical. The benefit of surgical treatment is to reduce or reverse the damaging effects of endometriomas on the ovarian cortex, but this effect is controversial [14]. Surgery's aim is to remove macroscopic endometriosis implants, the adhesions, and restore normal pelvic anatomy [10].

Evidence indicates that the primary benefit of surgical treatment of endometriosis is relief of pelvic pain [7–10].

Another argument in favor of surgical excision of endometriomas is related to the dangers of expected management, such as ovarian torsion, cyst rupture, and progression of endometriosis [6–10]. The risk of ovarian malignancy is debatable, as some authors reported that endometriosis can be associated with increased risk of clear cell ovarian cancer or low-grade serous ovarian cancer [3]. Future research should be focused on understanding the mechanisms that might lead to malignant transformation of endometriosis to help identify the women at risk [4].

2.2.3. Objectives of surgery

As it was mentioned before, surgical treatment may be conservative or radical.

The goal of conservative surgery is to remove or destroy endometrial abnormal proliferation without damaging the reproductive organs [8].

Radical surgery for endometriosis aims to eliminate all possible endometriosis implants found in pelvic and abdominal cavity, including hysterectomy and bilateral adnexectomy, and to excise of the deep endometriosis lesions that can involve the urinary and digestive organs, as well as the rectovaginal and/or vesicouterine space. However, this technique has to be of last resort because it is radical and definitive [16–19].

2.2.4. Laparoscopic versus open approach

Surgery can be done through open surgery or by laparoscopy [10]. Minimally invasive techniques were proved to be feasible in treating endometriosis [14].

Many studies including two randomized controlled trials, comparing medical treatment with laparoscopic excision of endometrioma concluded that laparoscopic excision is associated with a decrease in symptoms such as dysmenorrhea, dyspareunia, and nonmenstrual pelvic pain [10–15].

Compared to laparotomy, operative laparoscopy was proved to be the gold standard surgical approach for the diagnosis and treatment of endometriosis [12].

Concerning the open access, the decision to use this type of access is very important. It is recommended that laparotomy should be performed only in cases with massive endometriosis, in older patients or in cases where pelvic pain and discomfort are the main problems for the patients [10–15]. The selection should be done, because this type of treatment obviously takes longer operative time is more painful and it involves a longer hospital stay. The risks and side effects are also greater than for laparoscopy. It is therefore better to almost never use laparotomy as a treatment for endometriosis [14]. Therefore, laparotomy should only be reserved to very difficult cases.

Laparoscopy is a central component in the diagnosis of and therapy for endometriosis. Laparoscopy is initially used to diagnose endometriosis. Visualization of areas of endometriosis may be followed by excision or destruction by burning (**Figure 2**). This can be done simply with the diathermy or using the laser. However, the laser is expensive, time-consuming, and almost never used now by leading endometriosis surgeons [10–12].

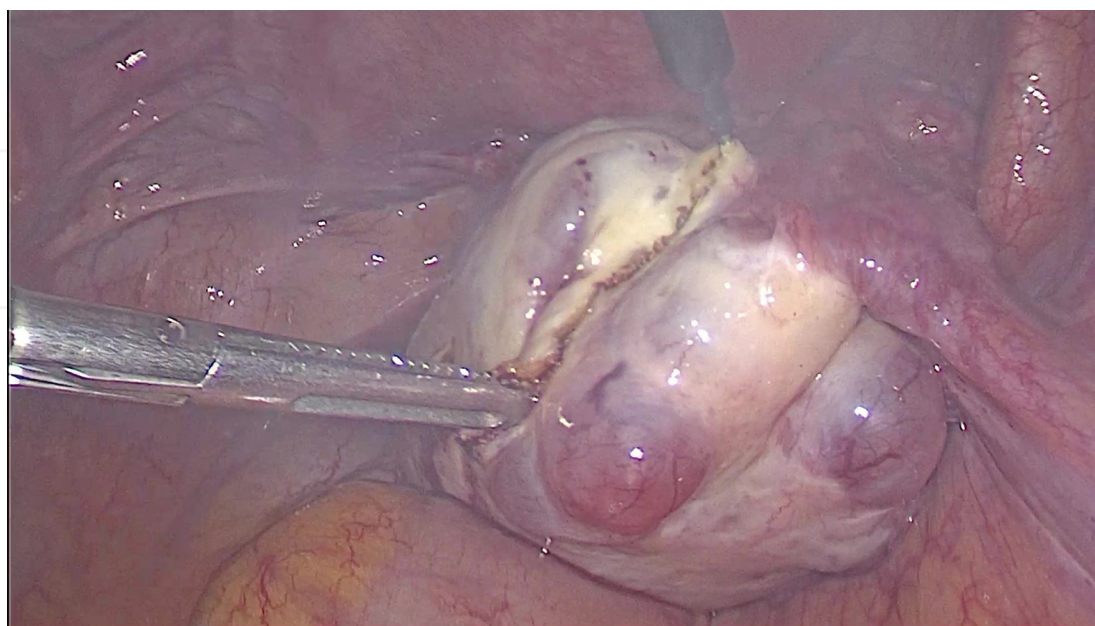


Figure 2. Laparoscopic incision of an endometriotic cyst of the ovary using diathermy.

Conventional laparoscopy has several proven advantages over laparotomy, like faster post-operative recovery, shorter length of hospital stay, cosmetic benefits, decreased blood loss, and fewer complications [16, 17]. However, laparoscopic management of advanced-stage endometriosis requires pelvic dissection, which can increase the surgeon fatigue, operating time, rate of conversion to laparotomy, intraoperative, and postoperative complications [18].

Robotic-assisted laparoscopic surgery tries to overcome the disadvantages of conventional laparoscopy by offering improved dexterity, better coordination, and visualization of organs and less surgeon fatigue [19].

Many studies acknowledge that laparoscopy is especially indicated for patients with moderate or severe endometriosis or for those who accuse pain or infertility [4].

The risk factors and disadvantages of laparoscopy include damage of organs adjacent to the affected areas and postoperative complications, such as adhesion formation or infection [8].

Some authors emphasized that the management of an endometrioma must focus on the complex pathology of this disease further confirming through ovarioscopy biopsies that endometriomas *in situ* have progressive smooth muscle cell metaplasia and fibrosis of the cortical layer. Additionally, they found no correlation between the size of the endometrioma and the degree of ovarian pathology [10–16].

Recently, in several studies, a new approach called transvaginal hydrolaparoscopy is mentioned. By this approach, an endometrioma could be confirmed by its appearance in gross anatomy and even removed in an early stage [8–12]. Transvaginal ovarioscopy, associated or not with ablation, is performed in numerous medical centers [15–18] and could be considered a variant of NOTES (natural orifice tranluminal endoscopic surgery).

2.2.5. Laparoscopic procedures

The surgical procedures that can be performed during an operative laparoscopy usually include the excision or destruction of ovarian endometriosis (endometriomas) (**Figure 3**), the removal or destruction of endometrial implants, adhesiolysis, oophorectomy, hysterectomy, the removal of deep rectovaginal and rectosigmoid endometriosis, surgery of the bowel (usually enterectomy) or bladder, laparoscopic uterine nerve ablation (LUNA), and presacral neurectomy (PSN) [1–8].

Although the ovarian endometrioma is described as an ovarian cyst, its pathology is rather complex and completely different from other benign ovarian cysts [18–20]. According to Huhedon, the majority of endometriomas are thought to be pseudocysts rather than intra-ovarian cysts, as the clear dissection plane between an endometrioma and ovarian cortex may not always exist, like in other benign ovarian cysts [19, 20].

While most endometrial implants can be treated using excision or/and coagulation, the most frequently used surgical procedures for the treatment of ovarian endometriosis are the excision of the cyst capsula or electro-coagulation of the cyst wall (**Figure 4**) [7–10]. During excision, the endometrioma is aspirated followed by the removal of the cyst wall from the ovary cortex. However, this technique could reduce ovarian reserve and decrease the chances of

fertility [10–14]. Concerning this last aspect, there is currently no randomized controlled trial to assess whether surgery is positively effective or not on pregnancy rates in moderate to severe endometriosis [19]. However, there are numerous nonrandomized uncontrolled studies with results indicating a postoperative pregnancy rate that varies widely from 30 to 67% [19–21].

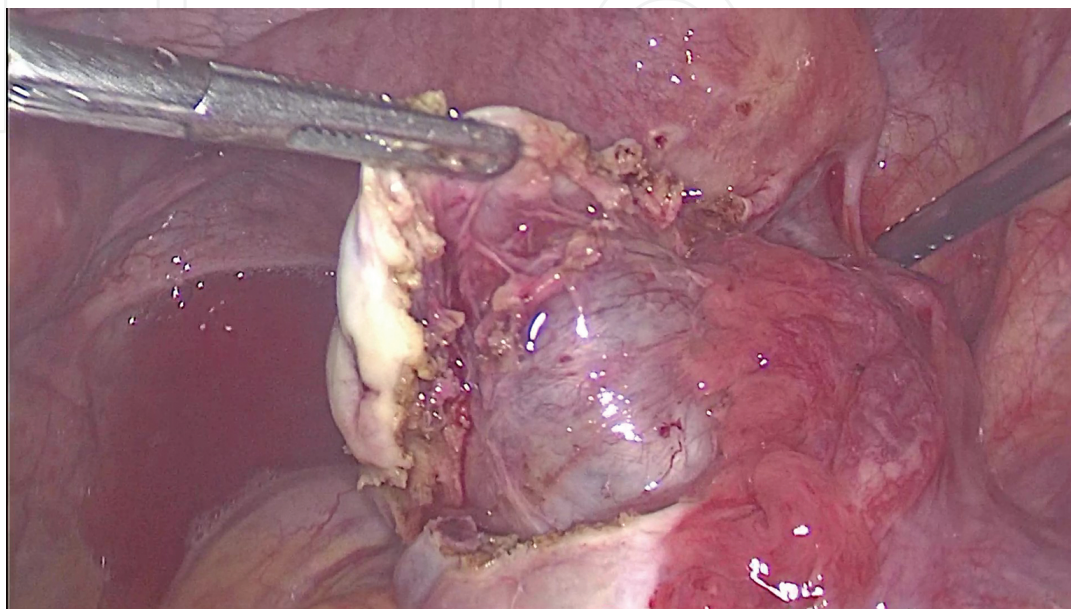


Figure 3. Excision of an endometrioma: cleavage plane between the endometrioma and ovary, progressive dissection through divergent traction.

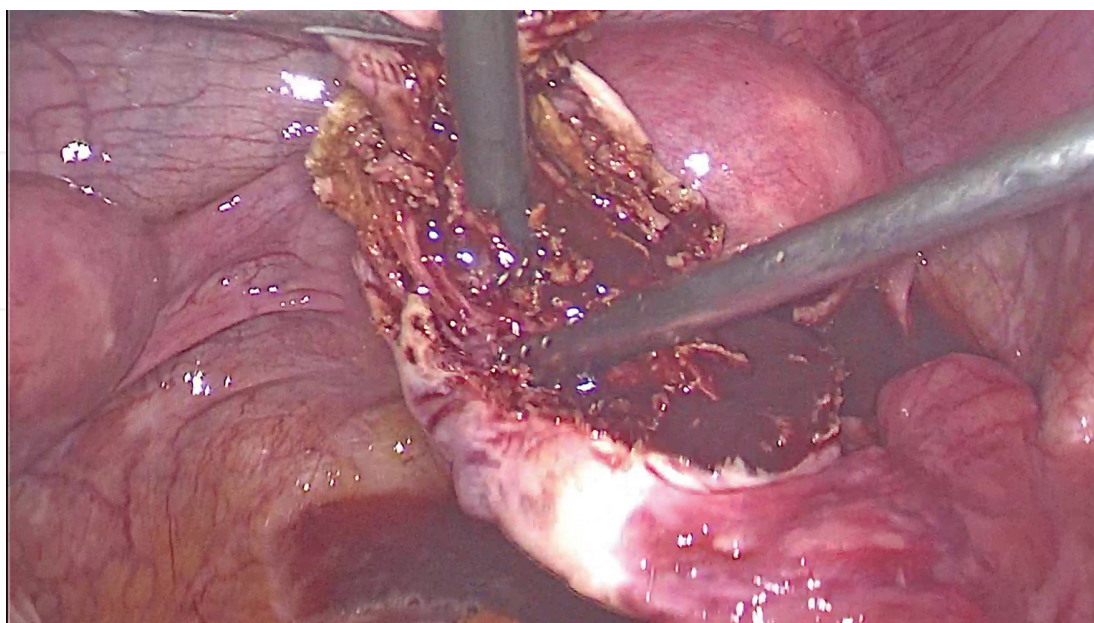


Figure 4. Enucleation of endometrioma of the right ovary.

The recommendations of the ESHRE guidelines for women with endometriomas who are undergoing surgery for infertility or pain, strongly support the laparoscopic excision rather than drainage and electrocoagulation of the endometrioma wall [21–23]. Several studies showed that the stripping technique is superior to drainage or ablative surgery because it reduces the recurrence of pain, and it is decreasing the recurrence and reoperation rates [18, 19].

According to the ESHRE Guideline, in infertile women with ovarian endometrioma bigger than 3 cm surgeons should perform excision of endometrioma capsule instead of ablative surgery because the studies show that it increases the spontaneous postoperative pregnancy rate (**Figure 5**) [20–23].

Technique of laparoscopic removal of endometrioma begins by incision of the ovary and finding the dissection plane between the endometrial cyst and the ovarian parenchyma. Dissection may progress carefully and slowly in this fashion until its completion. However, to facilitate dissection the cyst may be opened, its content evacuated by aspiration, and the walls of the cyst literally stripped away by divergent traction (traction and counter-traction) from the ovarian parenchyma. This is a commonly used technique [20–22]. In our opinion, evacuation of the cyst's contents should be performed carefully and complete, and at the end, the pelvic cavity immediately and thoroughly washed with saline or iodine–povidone solution to prevent iatrogenic spreading of endometriosis. The remaining ovarian parenchyma is coagulated by bipolar or monopolar cautery and could be left open or could be sutured [23]. We prefer to leave it open to allow drainage and avoid formation of intraovarian hematic collections that could lead to ovarian abscesses. Another possibility of surgical treatment is to electrocoagulate by diathermy or by laser energy the inner cavity of the cyst after evacuation instead of removing it [1, 4]. We consider that if the dissection is not amenable or hemostasis is difficult, those two methods could be combined in the sense that a part of the cyst wall could be left in the place but its inner surface coagulated as mentioned before.

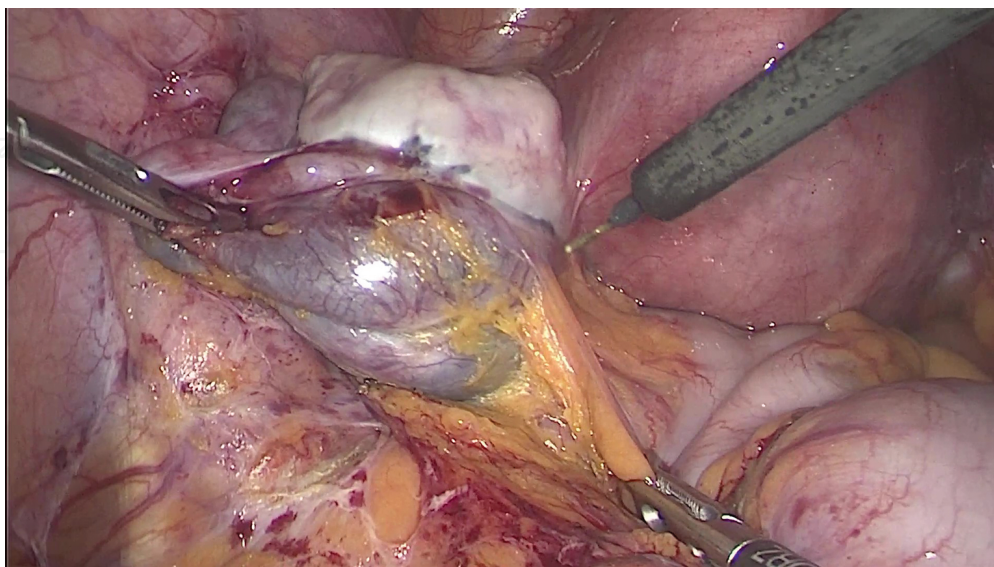


Figure 5. Excision of endometrioma using monopolar hook.

2.2.6. Ovarian reserve

As shown in this paper and in numerous studies, surgery performed on the ovaries may reduce the ovarian reserve and decrease the fertile potential in some women (especially infertile women with endometrioma or women with previous ovarian surgery) [4–8]. The ESHRE guideline for the management of women with endometriosis attempts to help these women and their physicians by suggesting surgical abstinence, excepting cases of absolute indication [7].

In patients with disease-related symptoms, unilateral cysts, normal AMH, or sonographic features raising the suspicion for malignancy, ESHRE guidelines recommend surgery [8]. Another situation, where surgery is mandatory, is in patients who already have children. However, in all cases with endometriosis that are suitable for surgery, women should be counseled on the potential for decrease in ovarian reserve [14, 17].

Nevertheless, the decision for surgery in patients who are diagnosed with infertility should be taken with a lot of caution because several studies indicated that an endometrioma does not appear to adversely affect IVF outcomes and in the same time surgical excision of an endometrioma does not appear to improve IVF outcomes [15].

The most recent articles suggest that asymptomatic infertile patients, older patients, as well as those with diminished ovarian reserve or bilateral endometriomas, or those with prior surgical treatment, would benefit from proceeding directly to IVF [16].

Concerning the size of an endometrioma, it should be stressed that female patients with endometriomas less than 3 cm do not qualify for surgical treatment because the procedure of removing such a cyst decreases the ovarian reserve and does not positively influence the pregnancy rate. Small ovarian cysts less than 3 cm in diameter can be punctured and drained [7–10].

In 2012, the Practice Committee of the American Society for Reproductive Medicine no longer recommended performing laparoscopy on asymptomatic women with infertility to check for endometriosis [10–13].

More articles are reporting a reduction in ovarian reserve and antimullerian hormone level after laparoscopic surgery for endometriomas. Frequently, during the surgery, normal ovarian tissue is excised with the endometrioma wall [10–14].

Ovarian surgery might reduce the number of oocytes retrieved, to reduce the peak estradiol levels and to increase total FSH requirement, in conclusion the fertility is very low reduced. It has been reported that ovarian surgery can lead to ovarian failure in 15% of the cases [20–22].

A study conducted by Donnez et al. showed that a combined technique of excisional (cystectomy) and laser ablative surgery without ovarian suture could be the best compromise for sparing ovarian reserve [4–7].

When revising the technique of laparoscopic cyst removal in regard of the ovarian reserve, many authors consider it more deleterious than the other technique of emptying the cyst and

thermal coagulation or laser vaporization of its wall. The main argument is that during dissection and stripping of the cyst, the surgeon cannot completely avoid removal or damaging of the healthy ovarian parenchyma. In order to establish the superiority of one technique over the other, Tsolakidas et al. performed a comparative study between the laparoscopic cystectomy and a more conservative procedure consisting of a combination of three methods (drainage of the cyst and vaporization by laparoscopy followed by 3 months of GnRh analogue). The results showed that antimullerian hormone level does not decline in women who underwent the more conservative procedure compared to those who underwent the stripping procedure [18–20].

The idea of combining the two standardized procedures of cystectomy and of fenestration and vaporization was explored by Donnez et al. In his method, when approaching the hilus of the ovary, the excision of the cyst is stopped and CO₂ laser is applied on the remaining tissue. He managed to demonstrate that six months later the volume of the operated on ovary and AFC does not differ significantly from the opposite side [21, 22].

Therefore, the decision to proceed with surgery should be considered carefully if the patient had previous ovarian surgery or she does not have any child [18].

Further surgical procedures should not be attempted if initial surgery is not followed by a pregnancy, because it appears that fecundability is reduced or unaffected [23].

Moreover, it seems that the pregnancy rates decrease by almost twofolds in case of multiple procedures compared to initial surgery (22 vs. 40%) [23]. Indication for further surgical interventions must take into account several factors such as age, symptoms, ovarian reserve, the need for histological confirmation for certain type of cysts, and availability of skilled surgeons [20].

2.2.7. Deeply infiltrating endometriosis

Usually, surgery for deeply infiltrating endometriosis is considered only if it is causing symptoms or if it might cause symptoms in the future. If surgical treatment is necessary, all the deep lesions must be excised in one operation to avoid the need for further surgery [19].

The therapy for symptomatic deeply infiltrating endometriosis is the resection with healthy margins. The operations often include partial rectum resection and partial resection of the sacrouterine ligament. Hysterectomy is not obligatory and is not wanted by the mostly young patients and a lot of doctors. The interventions can mostly be performed as laparoscopic and if necessary vaginal-assisted procedures (**Figure 6**) [20–23].

Concerning the deeply infiltrating endometriosis treatment, the 2012 National Institute for Health and Clinical Excellence (NICE) recommendations state that in case of conducting laparoscopy and finding possible stage-I or stage-II lesions, it is advisable to remove them, whereas for stage-III or stage-IV lesions, surgical treatment is the only method indicated [18–20].

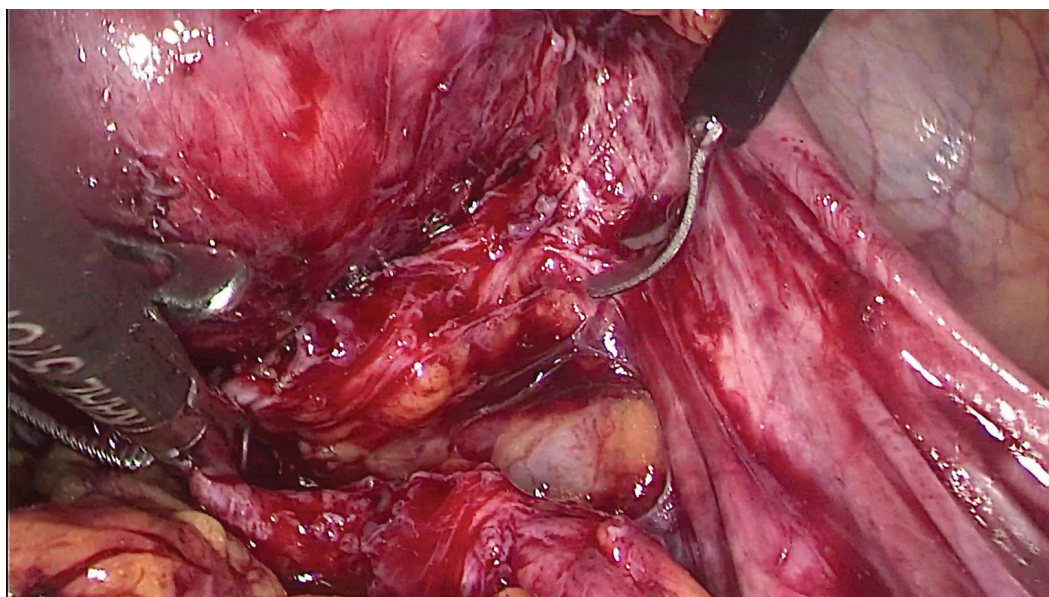


Figure 6. Dissection of deeply infiltrating endometriosis of the rectouterine pouch.

Auxiliary therapy after surgery is very important in order to eliminate or suppress residual lesions and prevent recurrence [21]. Advanced stage-III and stage-IV endometriosis will require surgical treatment consisting in the removal of the disease foci and restoring anatomical interrelations [22].

According to the American Society of Reproductive Medicine (ASRM), the treatment of stage-I and stage-II lesions with the use of laparoscopy slightly increases the percentage of pregnancies. In case of stage III and stage IV, correctly conducted laparoscopy significantly increases the percentage of pregnancies [18–23].

Laparoscopic uterine nerve ablation (LUNA) and laparoscopic presacral neurectomy (LPSN) are two procedures that involve cutting the nerves from the uterus in order to relieve chronic pain. Presacral neurectomy did provide better pain relief than laparoscopic treatment alone [10–12].

3. Conclusion

Pelvic endometriosis is a late diagnosed, complex, and in many aspects, a mysterious disease that still raises many questions and requires further research.

Nowadays, endometriosis can only be treated in up to 70% of cases with three major treatment options involving medical therapy, surgery, or combined treatment, with laparoscopy emerging as the main diagnostic and therapeutical tool for endometriosis and endometriomas. The most common surgical technique is stripping of the endometrioma; this technique can reduce ovarian reserve and decrease the chances of fertility.

There is controversial evidence regarding removal of endometriomas because of the potential impact on ovarian reserve, but there are also undisputable benefits of this type of surgery, such as pain relief.

Future research is needed to identify the optimal surgical techniques, as well as the prospects for new procedures such as aspiration with sclerotherapy or drainage with endometrial ablation by plasma laser energy, which may cause less ovarian damage while allowing the best clinical outcomes.

4. Disclosure

Sidonia Maria Saceanu, Stefan Patrascu, Anca Patrascu, Valeriu Surlin have nothing to disclose.

Acknowledgements

Stefan Patrascu, Anca Patrascu, Valeriu Surlin have a contribution to the paper equal to that of the first author (Sidonia Maria Seceanu).

Author details

Sidonia Maria Saceanu¹, Stefan Patrascu², Anca Patrascu³ and Valeriu Surlin^{2*}

*Address all correspondence to: vsurlin@gmail.com

1 Second Gynecology Department, University of Medicine and Pharmacy of Craiova, Craiova, Romania

2 First Clinic of Surgery, University of Medicine and Pharmacy of Craiova, Craiova, Romania

3 University of Medicine and Pharmacy of Craiova, Craiova, Romania

References

- [1] Ruan YQ, Liang WG, Huang SH. Analysis of laparoscopy on endometriosis patients with high expression of CA125. *Eur Rev Med Pharmacol Sci.* 2015;19:1334–1337. PMID: 25967705

- [2] Burghaus S, Klingsiek P, Fasching PA, Engel A, Häberle L, Strissel PL, Schmidt M, Jonas K, Strehl JD, Hartmann A, Lermann J, Boosz A, Thiel FC, Müller A, Beckmann MW, Renner SP. Risk factors for endometriosis in a German case-control study. *Geburtsh Frauenheilk.* 2011;71:1073–1079. DOI: 10.1055/s-0031-1280436.
- [3] Ke X, Qian H, Kang L, Wang J, Xie Y, Cheng Z. Clinical analyses of endometriosis after conservative surgery. *Int J Clin Exp Med.* 2015;8(11):21703–21706. PMID: 26885130
- [4] Roustan A, Perrin J, Debals-Gonthier M, Paulmyer-Lacroix O, Agostini A, Courbiere B. Surgical diminished ovarian reserve after endometrioma cystectomy versus idiopathic DOR: comparison of in vitro fertilization outcome. *Hum Reprod.* 2015;30(4):840–847. DOI: 10.1093/humrep/dev029.
- [5] Naufel DZ, Penachim TJ, de Freitas LL, Cardia PP, Prando A. Atypical retroperitoneal endometriosis and use of tamoxifen. *Radiol Bras.* 2014;47(5):323–325. DOI: 10.1590/0100-3984.2013.1774.
- [6] De la Hera-Lazaro CM, Muñoz-González JL, Perez RO, Vellido-Cotelo R, Díez-Álvarez A, Muñoz-Hernando L, Alvarez-Conejo C, Jiménez-López JS. Radical surgery for endometriosis: analysis of quality of life and surgical procedure. *Clin Med Insights Womens Health.* 2016;9:7–11. DOI: 10.4137/CMWH.S38170.
- [7] Younis A, Hawkins K, Mahini H, Butler W, Garelnabi M. Serum tumor necrosis factor- α , interleukin-6, monocyte chemotactic protein-1 and paraoxonase-1 profiles in women with endometriosis, PCOS, or unexplained infertility. *J Assist Reprod Genet.* 2014;31:1445–1451. DOI: 10.1007/s10815-014-0237-9.
- [8] Fadhlaoui A, Bouquet de la Jolinière J, Feki A. Endometriosis and infertility: how and when to treat? *Front Surg.* 2014;1:24. DOI: 10.3389/fsurg.2014.00024.
- [9] Jin X, Ruiz Beguerie J. Laparoscopic surgery for subfertility related to endometriosis: a meta-analysis. *Taiwan J Obstet Gynecol.* 2014;53(3):303–308. DOI: 10.1016/j.tjog.2013.02.004.
- [10] Keyhan S, Hughes C, Price T, Muasher S. An update on surgical versus expectant management of ovarian endometriomas in infertile women. *Biomed Res Int.* 2015:204792. DOI: 10.1155/2015/204792.
- [11] Słabuszewska-Józwiak A, Ciebiera M, Baran A, Jakiel G. Effectiveness of laparoscopic surgeries in treating infertility related to endometriosis. *Ann Agric Environ Med.* 2015;22(2):329–331. DOI: 10.5604/12321966.1152089.
- [12] Sanchez AM, Papaleo E, Corti L, Santambrogio P, Levi S, Viganò P, Candiani M, Panina-Bordignon P. Iron availability is increased in individual human ovarian follicles in close proximity to an endometrioma compared with distal ones. *Hum Reprod.* 2014;29(3):577–583. DOI: 10.1093/humrep/det466.
- [13] Dunselman GA, Vermeulen N, Becker C, Calhaz-Jorge C, D'Hooghe T, De Bie B, Heikinheimo O, Horne AW, Kiesel L, Nap A, Prentice A, Saridogan E, Soriano D, Nelen W; European Society of Human Reproduction and Embryology. ESHRE Guidelines:

management of women with endometriosis. *Hum Reprod.* 2014;29(3):400–412. DOI: 10.1093/humrep/det457.

- [14] Kitajima M, Defrère S, Dolmans MM, Colette S, Squifflet J, Van Langendonck A, Donnez J. Endometriomas as a possible cause of reduced ovarian reserve in women with endometriosis. *Fertil Steril.* 2011;96(3):685–691. DOI: 10.1016/j.fertnstert.2011.06.064.
- [15] Chiang HJ, Lin PY, Huang FJ, Kung FT, Lin YJ, Sung PH, Lan KC. The impact of previous ovarian surgery on ovarian reserve in patients with endometriosis. *BMC Womens Health.* 2015;15:74. DOI: 10.1186/s12905-015-0230-1.
- [16] Kitajima M, Dolmans M, Donnez O, Masuzaki H, Soares M, Donnez J. Enhanced follicular recruitment and atresia in cortex derived from ovaries with endometriomas. *Fertil Steril.* 2014;101(4):1031–1037. DOI: 10.1016/j.fertnstert.2013.12.049.
- [17] Kuroda M, Kuroda K, Arakawa A, Fukumura Y, Kitade M, Kikuchi I, Kumakiri J, Matsuoka S, Brosens IA, Brosens JJ, Takeda S, Yao T. Histological assessment of impact of ovarian endometrioma and laparoscopic cystectomy on ovarian reserve. *J Obstet Gynaecol Res.* 2012;38(9):1187–1193. DOI: 10.1111/j.1447-0756.2012.01845.x.
- [18] Qiu JJ, Liu YL, Liu MH, Chen LP, Xu DW, Zhang ZX, Yang QC, Liu HB. Ovarian interstitial blood flow changes assessed by transvaginal color Doppler sonography: predicting ovarian endometrioid cyst-induced injury to ovarian interstitial vessels. *Arch Gynecol Obstet.* 2012;285(2):427–433. DOI: 10.1007/s00404-011-1971-1.
- [19] Barri PN, Coroleu B, Tur N, Barri-Soldevila PN, Rodriguez I. Endometriosis-associated infertility: surgery and IVF, a comprehensive therapeutic approach. *Reprod Biomed Online.* 2010;21(2):179–185. DOI: 10.1016/j.rbmo.2010.04.026.
- [20] Brosens I, Gordts S, Puttemans P, Benagiano G. Pathophysiology proposed as the basis for modern management of the ovarian endometrioma. *Reprod Biomed Online.* 2014;28(2):232–238. DOI: 10.1016/j.rbmo.2013.09.024.
- [21] Pearce CL, Templeman C, Rossing MA, Lee A, Near AM, Webb PM, Nagle CM, Doherty JA, Cushing-Haugen KL, Wicklund KG, Chang-Claude J, Hein R, Lurie G, Wilkens LR, Carney ME, Goodman MT, Moysich K, Kjaer SK, Hogdall E, Jensen A, Goode EL, Fridley BL, Larson MC, Schildkraut JM, Palmieri RT, Cramer DW, Terry KL, Vitonis AF, Titus LJ, Ziogas A, Brewster W, Anton-Culver H, Gentry-Maharaj A, Ramus SJ, Anderson AR, Brueggmann D, Fasching PA, Gayther SA, Huntsman DG, Menon U, Ness RB, Pike MC, Risch H, Wu AH, Berchuck A. Ovarian Cancer Association Consortium. Association between endometriosis and risk of histological subtypes of ovarian cancer: a pooled analysis of case-control studies. *Lancet Oncol.* 2012;13(4):385–394. DOI: 10.1016/S1470-2045(11)70404-1.
- [22] Kim JY, Jee BC, Suh CS, Kim SH. Preoperative serum anti-mullerian hormone level in women with ovarian endometrioma and mature cystic teratoma. *Yonsei Med J.* 2013;54(4):921–926. DOI: 10.3349/ymj.2013.54.4.921.

- [23] Dunselman GA, Vermeulen N, Becker C, Calhaz-Jorge C, D'Hooghe T, De Bie B, Heikinheimo O, Horne AW, Kiesel L, Nap A, Prentice A, Saridogan E, Soriano D, Nelen W. European Society of Human Reproduction and Embryology. ESHRE guideline: management of women with endometriosis. *Hum Reprod.* 2014;29(3):400–412. DOI: 10.1093/humrep/det457.

IntechOpen

IntechOpen