

# We are IntechOpen, the world's leading publisher of Open Access books Built by scientists, for scientists

4,800

Open access books available

122,000

International authors and editors

135M

Downloads

Our authors are among the

154

Countries delivered to

TOP 1%

most cited scientists

12.2%

Contributors from top 500 universities



WEB OF SCIENCE™

Selection of our books indexed in the Book Citation Index  
in Web of Science™ Core Collection (BKCI)

Interested in publishing with us?  
Contact [book.department@intechopen.com](mailto:book.department@intechopen.com)

Numbers displayed above are based on latest data collected.

For more information visit [www.intechopen.com](http://www.intechopen.com)



---

# **Noninvasive Evaluation of Microcirculation under Normal and Pathological Conditions Using Contrast-Enhanced Ultrasonography (CEUS)**

---

Attila Tamas-Szora, Mihai A. Socaciu,  
Alexandru Florin Badea, Iulian Opincariu and  
Radu I. Badea

Additional information is available at the end of the chapter

<http://dx.doi.org/10.5772/64622>

---

## **Abstract**

The present chapter highlights the most important information about microcirculation and its evaluation using contrast-enhanced ultrasonography (CEUS). In the beginning it outlines some general considerations about microcirculation, together with its morphological and physiological particularities under normal and pathological circumstances. The ultrasonographic (US) evaluation of vascularity is based on the Doppler technique and the harmonic technique using contrast agents. Then it presents briefly the Doppler ultrasound (DUS) and discusses its most important current and emerging indications. CEUS is presented extensively, covering the fundamentals of sonographic contrast agents, harmonic imaging and quantification techniques. A special focus is placed not only on the current and emerging indications of CEUS but also on the advantages and limitations of the method. This chapter also incorporates information about experimental CEUS applications and future perspectives. CEUS is the recommended US method for the characterization of microcirculation. The results of the examination are displayed in real-time, under the eyes of the examiner, while the quantitative assessment of the contrast agent kinetics parameters is easy to perform. This method allows a precise definition of the healthy or pathologic state of an organ and the follow-up of treatment response.

**Keywords:** microcirculation, contrast agent, ultrasonography, Doppler ultrasonography, microvascular kinetics

## 1. Introduction

### 1.1. Microcirculation: general considerations: morphological and physiological particularities under normal circumstances

Microcirculation (MC) represents the segment of the circulatory system that includes vascular structures with a diameter  $<150 \mu\text{m}$ ; it is present in all tissues and organs (except for cornea and intervertebral disks). This dimensional threshold corresponds to small arteries, arterioles, capillaries and venules. The consensus on this definition is still under debate, therefore in the case of the small arteries (anatomically defined as small, but with a caliber  $>150 \mu\text{m}$ ) it is unclear whether they should be regarded as part of the MC [1]. The capillaries are organized as a circulatory network (bed) which provides an enormous access area for the blood to the parenchyma (**Figure 1**). There is an ordered distribution pattern of the capillaries, which is also organ-specific. The ordered spatial distribution of the capillaries, correlated with the degree of specialization of the structured cells into the parenchyma, represents the premise for the complex functions specific to each organ: liver, spleen, kidney, thyroid, etc. The main function of MC is to allow and modulate the transfer of nutrients and oxygen to the tissues according to their needs. An adequate operation of this process is a prerequisite for the structural and functional integrity of various tissues and organs. Another function of MC is to prevent the variations of hydrostatic pressure at the level of the capillaries, variations which interfere with normal tissue exchanges. Under normal circumstances, there are significant variations of the vessel caliber and blood volume. These are determined by a number of physiological parameters, such as temperature, arterial pressure, physical and mental activity, age. Other factors that influence MC are feeding, stress, medication, smoking and finally pathological changes. MC alterations include various pathological processes since they may represent both the determining factors and their consequences.

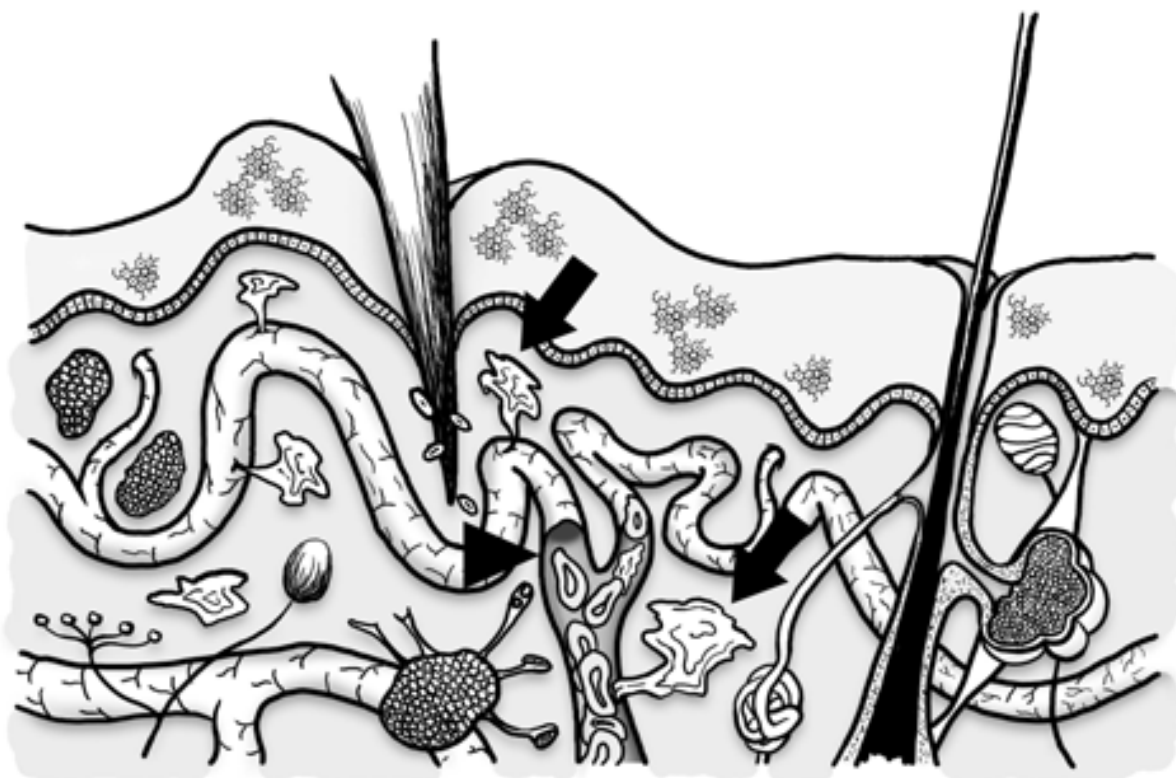


**Figure 1.** Microcirculation outline. A – arteriole; V – venule; C – capillaries.

### 1.2. Morphological and physiological particularities under pathological circumstances

Microcirculation, as described above, is an important element of the ensemble that makes up the different tissues and organs. Pathological states have a significant influence on MC.

Inflammation represents the first line of defense against traumatic, pathogenic or toxic injuries and is based on a complex local process that involves microvascular structures, cellular and immunological events. The consequences of these local changes may have an impact at a systemic level. During acute inflammation the alterations of the vascular caliber and blood flow occur immediately after the injury. The transient vasoconstriction of the arterioles represents the initial change and is followed by vasodilation and thus increased blood flow. Increased vascular permeability causes afterwards the slowing of the blood flow, stasis and interstitial edema. The extension of the inflammatory process in time (weeks, months) is characteristic for chronic inflammation. Within this process the active inflammatory alterations, tissue damage and tissue repair happen simultaneously (**Figure 2**).



**Figure 2.** Inflammation of the skin. Dilation (arrowhead) and increased permeability of the vessels are shown (arrows).

Angiogenesis (formation of new vessels) is a central phenomenon in chronic inflammation and represents the development of new vessels from the pre-existing vascular structures. The event is complex and involves various types of cells, growth factors, cytokines, adhesion molecules and signal transformation processes [2]. These factors thus contribute to blood vessels development, maintenance and remodeling.

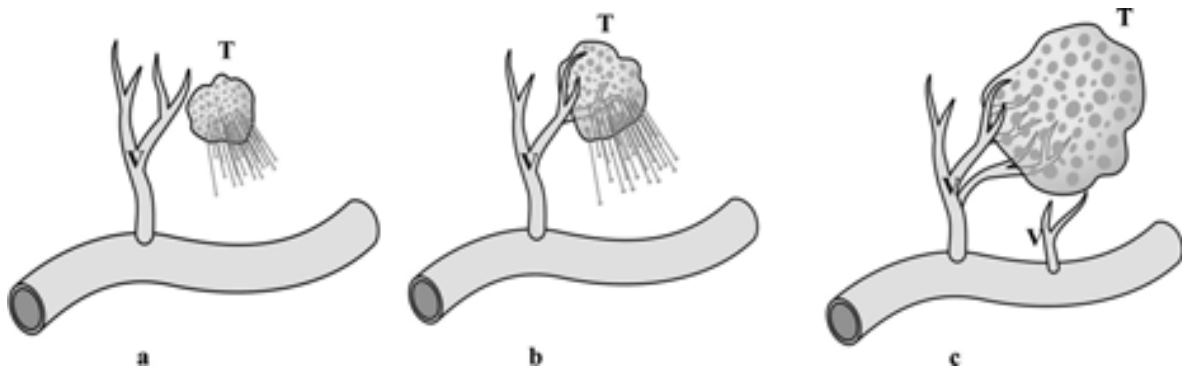
In physiological processes such as wound healing or during menstrual cycle, angiogenesis is temporarily activated. On the other hand, it also plays an important role in the onset, development and spread of malignancies [3, 4]. Tumors under 1–2 mm receive oxygen and nutrients by diffusion, but their further growth requires the development of new feeding vessels.

Without angiogenesis tumors cannot grow beyond this size and cannot metastasize. The development of benign tumor masses also requires a transient activation of angiogenesis. In their case the resulting vessels have a relatively linear pattern and ordered ramifications. Conversely, the progression of malignant tumors involves a permanent activation of angiogenesis in order to sustain tumor growth. As a result, new vessels are quickly multiplying and developing chaotically, forming a wide, tree-like spatial structure. This structure penetrates into the tumor and ensures a large diffusion area, in contact with the neoplastic cells. Even though the tumor vasculature originates from the normal vessels of the host tissue, the architecture is significantly different. Tumors present an anarchic, inhomogeneous, vascular network, often with dilated, saccular, tortuous structures and irregular ramifications (**Figure 3**). Tumor cells may be found in the endothelium and the blood flow is chaotic, bidirectional and unsteady [5–7]. From a functional point of view, the vessels present an abnormal permeability for large macromolecules, while tissue oxygenation and metabolic residue removal are inefficient. The perfusion rate in many of these tumors is slower than in normal tissues and the average flow rate of erythrocytes may be one level of magnitude lower than in physiologic conditions [8]. Unlike in normal vessels, in neoplastic vessels the characteristic relationship between vessel size and the erythrocyte flow rate is missing. Blood flow through the tumor bed is restrained by the increased downstream resistance and focal leakage. The heterogeneous features of tumor vascularity generate obstacles for the penetration of therapeutic agents and contribute to the development of the abnormal tumor environment. In this way the efficiency of various therapies is reduced while the most aggressive and potentially metastatic cancerous cells are being selected [8].

The main promoter of angiogenesis is the vascular endothelial growth factor (VEGF). In normal circumstances it is suppressed by the Von Hippel-Lindau (VHL) protein, while in the case of tumors it is overexpressed [9]. With the use of immunohistochemistry methods, the CD34 endothelial antigen is marked with specific antibodies and a parameter called microvascular density (MVD) is calculated by means of automatic measurement methods. This is an indicator of the degree of angiogenesis, and some studies indicate a correlation between MVD and cancer patients' survival [10]. The emerging use of MVD is represented by the evaluation of the tumor's response to systemic treatment. Studies performed to this date revealed the utility of MVD for the measurement of the effect of tumor angiogenesis disrupting therapies [11]. These therapies, called antiangiogenic therapies, are designed to reverse vascular and tumoral environment abnormalities and to determine the "normalization" of the tumor vessels' function [12]. As a consequence, there is an improvement in the cytotoxic agents' penetration and the radiation therapy outcome.

Ischemia represents the partial reduction (chronic ischemia) or complete suppression (acute ischemia) of the arterial flow in an organ or anatomical region. The causes are manifold: circulatory alterations such as embolism and thrombosis; degenerative and inflammatory arterial conditions—atherosclerosis and arteriosclerosis; arterial spasm; arterial hypotension. In acute ischemia there is a sudden and complete suppression of the circulation and the evolution toward infarction is variable, depending on the existence of collateral circulation. Chronic ischemia begins with the reduction of the capillaries caliber and blood flow in a more

or less well-defined area, depending on the feeding arterial network which may or may not be terminal. There are also associated phenomena to collateral feeding vessels formation. Within the necrotic, infarction area, there is no circulatory bed, only a more or less liquefied tissue, completely or partially replaced by fibrotic structures.

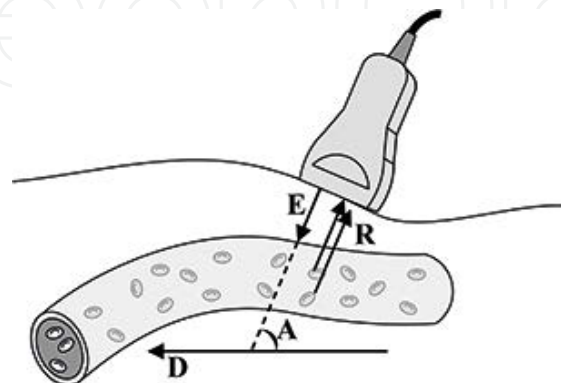


**Figure 3.** Angiogenesis outline. A small tumor (T) receives nutrients and oxygen by diffusion (a). As the tumor grows normal adjacent vessels (V) multiply quickly and penetrate into the tumor (b, c).

## 2. Current ultrasonographic techniques used for the evaluation of microcirculation: Doppler ultrasonography

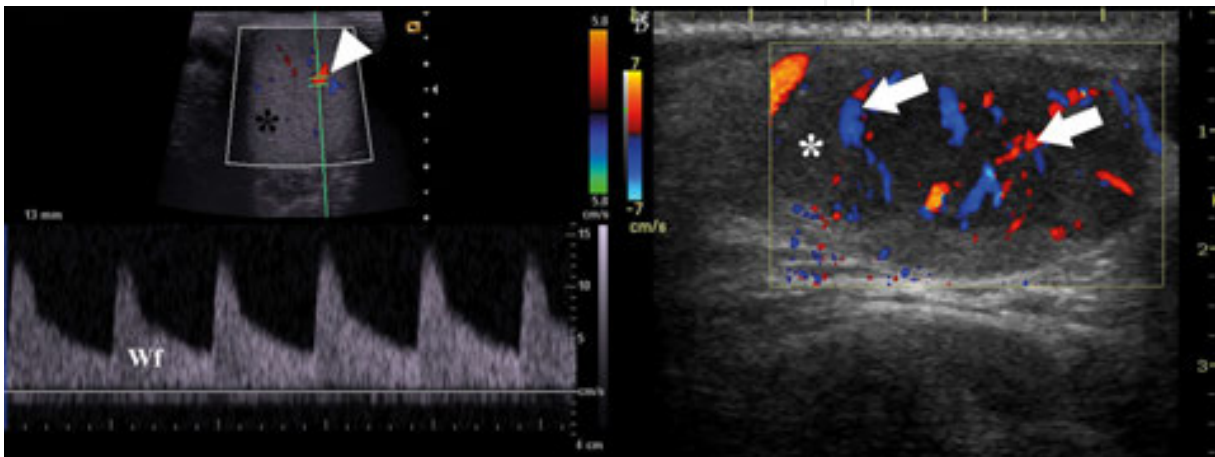
### 2.1. General principles

This technique detects blood flow down to velocities of 2 cm/s, allows the color coding of the flow (“color flow map” technique – CFM; “power Doppler”- PD), velocity and flow measurements (spectral Doppler). Only vascular structures with a diameter over 100  $\mu\text{m}$  can be analyzed [13, 14]. The physical principle that governs this method is the Doppler effect. For all types of waves (including sound waves) it entails the change of the received signal frequency, when the source of the wave and/or the receiver is moving toward or away from one another



**Figure 4.** Doppler effect outline. E – emitted sound wave fascicle; R – reflected fascicle; D – direction of movement of blood cells; A – angle between sound wave fascicle and blood cells direction of movement.

(**Figure 4**). The receiver's movement toward a stationary source leads to the detection of higher frequencies. If the receiver moves away from the source it encounters less cycles per second and it will register a wave with a lower frequency than that emitted by the source. In ultrasonographic (US) equipment both the source and the receiver are positioned close to one another inside the transducer. The emitted sound wave fascicle is reflected from the interfaces existing between/in various tissues and afterwards these waves are received and represent the basis for the formation of the US image (**Figure 5**). The movement of the blood cells toward the transducer determines an increase of the reflected wave's frequency, while the opposite movement determines a frequency decrease.



**Figure 5.** Examples of spectral and color Doppler. On the left: the left testicle (black asterisk) is investigated by spectral Doppler. The measurement sample (arrowhead) is placed inside an artery. The bottom portion of the image displays the spectral Doppler waveform (Wf), in which blood flow velocity (in cm/s) within the Doppler sample is plotted versus time. On the right: a superficial tumoral mass (white asterisk) is investigated with CFM. Flow toward the transducer is represented with shades of red and yellow, whereas flow in the opposite direction is indicated with shades of blue (arrows).

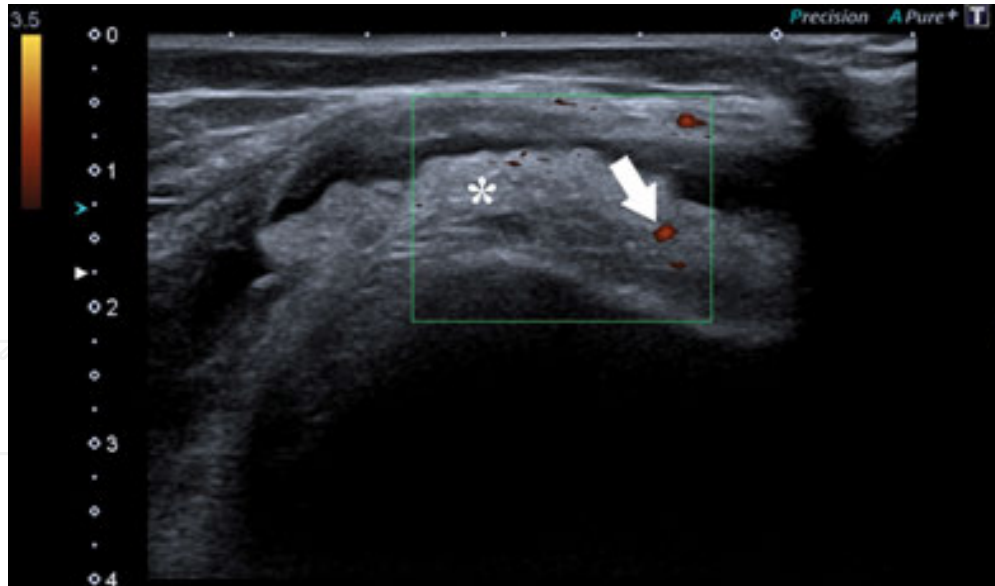
The difference between the received and the emitted sound wave, called differential frequency, is dependent on the emission frequency, propagation velocity of the waves into the tissues, the velocity of the detector and the angle between the detector's direction of movement and the sound wave fascicle. Placing a "measurement sample" inside a vessel will include groups of cells moving at different velocities, each group determining a signal with a particular differential frequency. Therefore, a complex US signal is generated from inside the blood column, which can be analyzed using a specter of frequencies with the help of Fourier techniques. The frequencies which compose the specter are then transformed into velocities using the Doppler equation.

## 2.2. The applicability of Doppler ultrasonography for the evaluation of normal and pathological circumstances

Within the limits of the spatial and temporal resolution offered by the latest equipment, DUS allows the characterization of the circulatory bed. The normal circulatory bed consists of fine vessels with a radial orientation, from the organ's hilum toward the capsule. This pattern is

more obvious in the case of large organs such as the liver or the spleen. Other organs such as the kidney, the thyroid and the testicle have a different appearance, also characteristic, of the normal vascularity, easy to identify and describe.

The features of the circulatory bed during inflammation have been investigated in various studies aimed to detect and measure vascular changes. Rheumatology is one of the beneficiary fields of these US techniques. The common indications include the evaluation of the inflammation, the appreciation of the therapeutic response and the differentiation between inflammatory and degenerative pathology. DUS may identify the augmentation of the blood flow in the inflammation of the synovial and periarticular structures, tendon insertion and sheath. The increase of the blood flow is associated with the histologic identification of the intra-articular pannus [15]. For the time being the detection of the Doppler signal represents an integrated part of the definitions of musculoskeletal conditions (**Figure 6**). Thus, synovitis is defined as an abnormal, hypoechoic, intra-articular structure that is only slightly compressible and which may present Doppler signal. A fluid collection is defined as an hypoechoic or anechoic intra-articular structure which can be dislodged and does not present Doppler signal. Detection of the Doppler signal is also included in the definitions of tenosynovitis and enthesopathy [15, 16]. The method provides high accuracy in showing active synovitis and accompanied by contrast agent (CA) administration it correlates very well with other imaging methods such as contrast-enhanced magnetic resonance imaging (CE-MRI) [17].

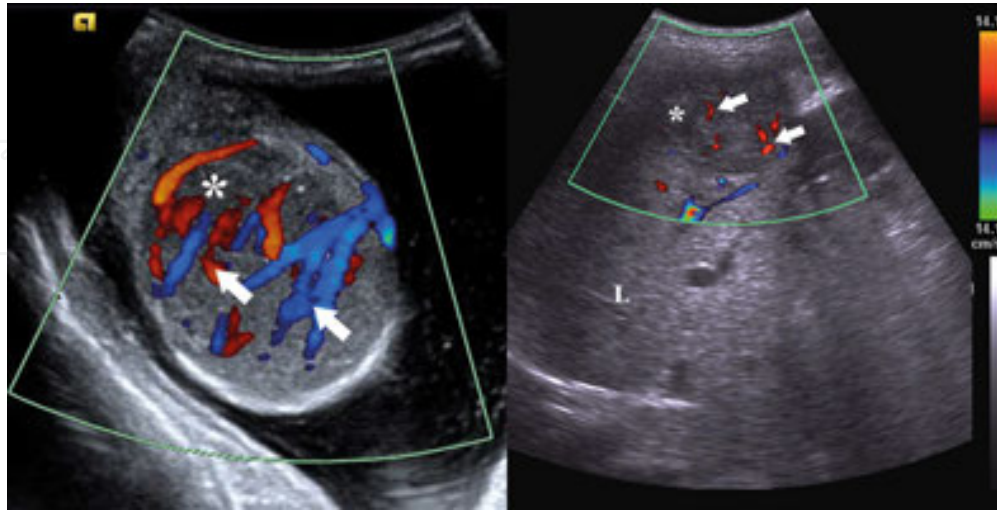


**Figure 6.** Example of hip synovitis in a child. Synovial thickening is indicated by the asterisk. Power Doppler identifies augmentation of blood flow in the inflamed synovia (arrow).

Another established application of DUS is in the male genital pathology. An increased vascular signal observed upon the CFM or PD examination of an enlarged, hypoechoic epididymis reveals the hyperemia characteristic of acute epididymitis. A similar appearance is identified



in the case of acute orchitis. Spectral Doppler shows a high velocity flow and low resistance in these situations (**Figure 7**).



**Figure 7.** Different alterations of the vasculature identified by CFM. The left image presents a patient with orchitis (acute inflammation). The testicle (asterisk) is examined with CFM and an increased vascular signal is observed (arrows). The right image portrays the evaluation of angiogenesis in a malignant tumor (HCC). The tumor (asterisk) is depicted in a superficial liver (L) segment and CFM identifies the tumor vasculature (arrows).

In tumors, DUS may identify specific circulatory patterns both in benign (e.g., focal nodular hyperplasia [FNH]) and malignant lesions (for instance, the “basket” circulatory pattern is specific to hepatocellular carcinoma (HCC)) (**Figure 7**). The detection of malignancy through DUS depends on the presence of an increased, asymmetric blood flow in a certain region, due to the higher number and size of the vessels. Studies performed on different types of tumors (e.g., skin melanomas) proved that DUS accurately identifies the process of neoangiogenesis and may constitute a prognosis criterion for the recurrence potential of aggressive tumors [18, 19].

As regards the ischemic tissues, the lack of Doppler signal reflects the deficit or absence of blood flow within the vessels of the affected area. This finding must be correlated with the clinical status of the patient and with other investigations, because, for example, in the case of renal infarction, the differentiation from a parenchymal pathology that evolves with hypoperfusion is difficult. This particular situation owes to the DUS limitations in identifying the slow flow at the level of the capillaries when low-frequency US equipment is used (3–5 MHz). Furthermore, the ischemic process is often associated and compensated with the development of a secondary circulatory network which presents reversed flows. Power Doppler mode may overcome this limitation, but it is excessively sensitive and nondiscriminative toward other types of movement such as tissue vibrations and surrounding organs’ motility.

Nevertheless, there are situations when DUS may provide indirect information regarding the capillary perfusion status. In a recent study a positive correlation has been established between skin perfusion pressure at the level of the feet and Doppler flow measurements within tibial arteries [20]. This finding has important implications both in the therapeutic approach of leg

ulcers and in the evaluation of skin grafts' viability [20]. The situation is identical in the case of organ transplantation.

The quantification of renal vascularity through spectral Doppler is another area that is of interest and up-to-date. There are numerous studies that have succeeded to correlate the alterations of the Doppler parameters with various conditions. The resistivity index (RI, calculated as [peak systolic velocity – end diastolic velocity]/peak systolic velocity) represents the most frequently used parameter to describe the alterations of renal vascularity in relationship with renal impairment. In adults the normal value at the level of the interlobar/arcuate arteries is between 0.6 and 0.7. Renal vasoconstriction encountered in cases of complete pyelocaliceal obstruction is reflected in the elevation of the RI above the normal limits. Although nonspecific,  $RI > 0.8-0.9$  has been demonstrated to be the strongest predictor for renal graft dysfunctionality [21].

Another Doppler application, namely the laser Doppler imaging technique, is still subject to continuous improvement. It is also based on the Doppler principle and uses a light fascicle emitted by a laser source which is reflected by circulating erythrocytes and static tissue structures. There are major advantages to this method in assessing the pathology of superficial structures, such as the skin, since it can measure at 95–100% accuracy the depth of a burn – a value that has not been reached by other methods, thus having implications in the therapeutic conduct [22].

### **2.3. Limitations and advantages of Doppler ultrasound**

Limitations of the Doppler technique consist mainly of the following:

- a. the variability from one examination to another, as well as inter- and intraobserver variability;
- b. the difficulty in obtaining the Doppler signal from a single target vessel in certain conditions such as a tumor with numerous feeding pedicles and a sinuous spatial trajectory;
- c. the dependence of spectral ultrasonography on the insonation angle (it has to be less than  $60^\circ$  in relation to the axis of the vessel);
- d. the need to standardize the exploration by using more parameters that must be identical during each examination (wall filter, color gain, scan frequency) in order to ensure the reproducibility of the method [23].

There are ways to quantify the Doppler signal which contribute to the improvement of reproducibility. The main measurable parameters in the case of the spectral method are blood velocity, its relative volume and flow rate. The data obtained by the color-coded technique may be postprocessed by quantifying the number of color pixels within a target area. In situations where an adequate examination protocol is available this information allows the evaluation of tumor response to chemotherapy. The percentage of colored pixels from the total number of pixels present in the target area (called "vascularity index") represents an approach similar to the digital evaluation of MVD used in immunohistochemistry [24]. The new 3D color-coded

Doppler techniques allow the creation of spatial models that illustrate tumoral circulation characteristics [25].

The most important advantages of the Doppler method are:

- a. it is noninvasive;
- b. it is available on a large scale since most ultrasound machines are equipped with Doppler functions;
- c. it offers the possibility to study broad anatomical areas.

### **3. New ultrasonographic techniques in the evaluation of clinical microcirculation. Intravenous contrast harmonic ultrasound**

#### **3.1. Contrast agents used in ultrasonography**

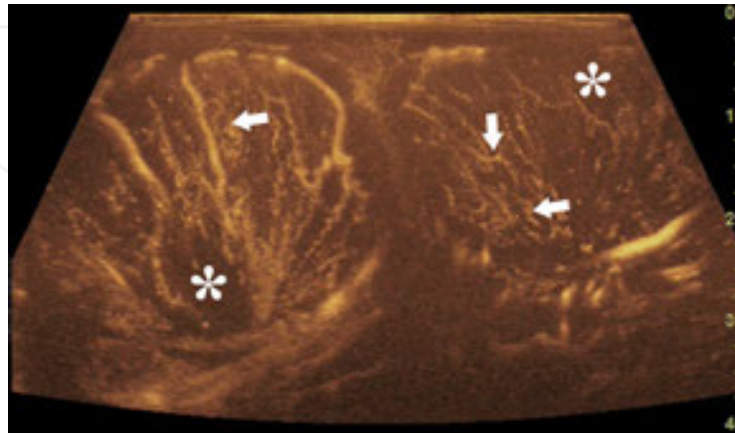
Ultrasonographic contrast agents (CAs) are basically echoenhancers that are administered to patients to improve the diagnostic yield.

Joyner mentioned the ultrasonographic contrast effect for the first time in 1960, and during the initial experiments used standard saline solution as a contrast agent for the identification of mitral valve echoes [26]. The saline solution is still used today to evaluate cardiac shunts. Currently the contrast agents consisting of gas microbubbles encapsulated in a lipid, protein or polymer shell are the most widespread and used. These remain strictly intravascular and the encapsulation ensures a longer life of the microbubbles, up to several minutes, unlike the unencapsulated ones which are rapidly dissolved into the blood pool. To ensure the slow diffusion into the blood, gases such as perfluorocarbon, sulfur hexafluoride or nitrogen are found in most of these agents. The size of the microbubbles ranges between 1 and 5  $\mu\text{m}$  and is comparable with that of erythrocytes. The CA is administered intravenously (i.v.), in a bolus dose of 2.4 ml (SonoVue, Bracco, Italy) or by continuous infusion. The newer, more sensitive equipment allows an efficient examination even with lower doses (e.g., 1 ml). For the injection, a special kit is used in which the CA is prepared by mixing with a saline solution and strongly shaking the recipient. The elimination of the CA components is made through the lungs and by hepatic metabolization.

#### **3.2. Harmonics based ultrasound imaging**

The high-pressure fluctuations of the sound wave determine a disproportionate change of the microbubbles' radius, thus triggering a nonlinear response. In this situation, the ultrasound waves reflected by the microbubbles are characterized by different frequencies compared to the incident wave, both higher and lower. These are called harmonics, and the second harmonic represents the foundation of "second harmonic imaging" techniques. These detect and convert into image only the second harmonic signal from the scattered ultrasound. To obtain a better contrast-to-tissue ratio, a low mechanical index (MI) is used (Figure 8). The MI is always

displayed on the ultrasound machine since it is a critical parameter in contrast-enhanced ultrasonography (CEUS). It represents the amount of negative acoustic pressure within an ultrasonic field. The examiner can modify the MI which in turn will prompt different microbubble responses and modulate the output signature of CAs.



**Figure 8.** Spectacle view of the testes (asterisks) after administration of CA. Harmonic imaging with low mechanical index (MI = 0.1) sharply identifies testicular microcirculation (arrows).

### 3.2.1. Techniques with a variable mechanical index

These incorporate two different approaches, based on low and high MI. The low MI technique (MI < 0.2) reduces the microbubble destruction and thus the evaluation of the perfusion can be performed over a relatively long period of time. The high MI (MI > 0.4) approach enables a more accurate characterization of the CA kinetics but could generate adverse biological responses.

Techniques with a low MI include pulse inversion imaging; amplitude/power modulation; power-modulated pulse inversion. The pulse inversion implies the emission down the same transmit line of two consecutive pulses, the second one being identical but 180° inverted with respect to the first pulse. Given the nonlinear response of the CA, the reflected ultrasound waves will be nonidentical and their sum will cause the cancellation of the fundamental part of the signal, the image being formed from the remaining signal. Although the technique has the advantage of sparing the microbubbles, it has the disadvantage of a decreased frame rate which is synonymous to a decreased temporal resolution.

The amplitude/power modulation technique requires the transmission of 2–3 pulses with identical phase and different magnitude. The signals received are combined in such a way that the sum of the pulses with low amplitude is subtracted from the high-amplitude pulse. Since pulses with low amplitude are weak harmonic generators, the difference between the received pulses is due to the nonlinear response of the CA. The technique of power-modulated pulse inversion is a combination of the two techniques described above. The pair of pulses transmitted in the same direction differs both in amplitude and phase, thereby providing a better detection of the nonlinear signals.

High MI-based techniques cause a rapid destruction of most of the microbubbles inside the examination window. The low and high MI techniques are commonly combined (“destruction-replenishment” technique); the examination starts with low MI and after the homogenization of the CA perfusion, the high MI mode is activated.

### 3.3. The safety of contrast microbubbles

Ultrasonographic contrast agents present a high safety profile and a low incidence of side effects. Compared to other imaging techniques (CT, MRI) they do not lead to renal toxicity and do not alter the thyroid function. The incidence of anaphylactic reactions is very low (<0.002%) [27]. The most important circumstances in which CA administration is forbidden are breast-feeding; recent acute coronary syndrome; right-to-left shunts and unstable ischemic heart disease. The *in vitro* studies have identified a number of possible biological effects resulting from the interaction of the ultrasound wave with microbubbles and cells; as such sonoporation (the appearance of small cracks in the cell membrane), hemolysis and cell death may be encountered. Studies in animal models have shown that the use of high MI ( $\approx 0.4$ ) may cause glomerular hemorrhage, but in the current clinical practice MI is set around a value of 0.1 [28]. Mortality associated with CA administration is low (1: 500,000) and studies that included large groups of patients concluded that there is no higher risk of death for patients who underwent CA administration compared to controls [29, 30].

## 4. The evaluation of microcirculation using i.v. contrast-enhanced harmonic ultrasound: experimental and animal models: clinical applications

### 4.1. General considerations

CEUS allows the assessment of microcirculation down to the level of very small diameter vessels – such as 40  $\mu\text{m}$  [31]. Although in the capillary bed the blood flow velocity is very low and sometimes interrupted, CEUS allows the visualization of the CA even in these situations.

Before CA administration, the system is set as follows: MI between 0.09 and 0.11; the ‘Time Gain Compensation’ buttons aligned in the middle position; the overall gain is reduced to the value at which tissue echoes begin to disappear; a single focus set under the region of interest (ROI) is used. The intravenous administration (e.g., through the cubital vein) of the extemporaneously prepared CA is followed by the administration of 10 mL of saline solution bolus. The assessment of the ultrasound images is continuous, beginning from the time of injection until the appearance of the first echoes – called “arterial phase” (10–20 s later), and afterwards until the echoes disappear completely (called “late” venous, tissue or combined phase). The use of the dual image, B mode and contrast mode, is recommended since it helps maintain the area of interest within the insonation plane. To correctly assess the lesions, the examination must be centered on a single structure which will be continuously evaluated for several minutes. To obtain additional information on synchronous lesions, a new CA injection must be administered (CA does not present toxic/lethal doses).

## 4.2. The analysis of the CA progression

It consists of continuous and real time observation, of the CA transition pattern through the ROI for at least 60–90 s, allowing the characterization of the CA kinetics, from the moment it enters into the circulatory bed (wash-in) and ending with its complete exit (wash-out). The separation between the two is given by the moment when the signal reaches maximum intensity. The digital recording of the examination as video clips facilitates the CA kinetics analysis through ROI, which can be quantified based on qualitative and quantitative parameters. Thus, the CA transition through the region of interest is divided into different temporal phases. The first is the arterial phase (from 10–20 to 30–45 s), which is marked by an abrupt increase of the signal intensity caused by the appearance of the microbubbles. The examination continues with the venous phase, which begins 30–45 s after the injection, and during which the signal intensity reaches a plateau and then gradually drops until it completely disappears. With the exception of the liver and lungs, most organs have a single blood supply (arterial). In the case of the liver the blood supply is ensured through the hepatic artery and the portal vein. This means that after the arterial phase there is an additional vascular intake phase – the portal venous phase (60–120 s) [32]. The liver and spleen display a particular behavior because they have the tendency to retain more microbubbles than other organs. This is due to the accumulation of CA at the level of the sinusoids (in the case of the liver) as well as its capture by the reticulohistiocytic system (in the case of liver and spleen). Consequently, the CA washing phase ('wash-out') is longer compared to other organs, and is called the late phase (up to 4–6 min).

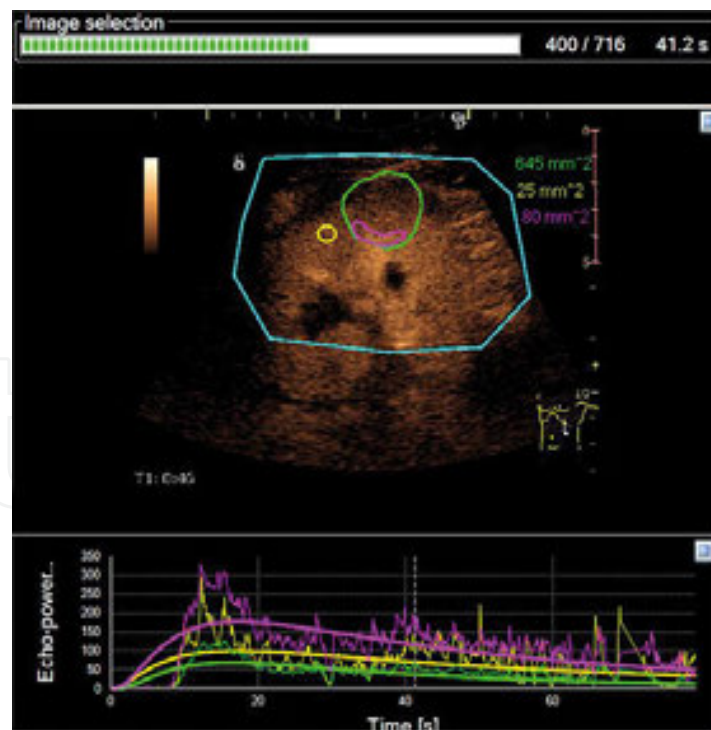
### 4.2.1. The semiquantitative analysis of the CA progression

Throughout a particular region it is performed by evaluating the following [33]:

- a. the moment of arterial phase occurrence (depends on the cardiac activity as well as on the distance between the vein wherein CA is administered and the organ subject to examination);
- b. the celerity and length of the arterial phase (conditioned by the capillary bed compliance);
- c. the direction of the CA penetration from the organ's hilum toward the capsule;
- d. the penetration and spatial distribution characteristics of the CA in the ROI (in relation with the size and number of the feeding vessels and their spatial distribution);
- e. the enhancement pattern (homogeneous or nonhomogeneous in relation to the permeability of the capillary bed);
- f. the time and speed of the contrast wash-out (in relationship with the arteriovenous shunts that may indicate the malignant nature of the region of interest);
- g. the wash-out direction;
- h. the wash-out pattern.

#### 4.2.2. The quantitative analysis of the CA progression

It is based on the graphic representation of the variation in time of the CA signal intensity within the blood column (**Figure 9**). This can be done using the ultrasound system or third-party software (e.g., ImageArena, TomTec). The representation is achieved by applying an equation adapted to the blood flow, which results in a time-intensity curve (TIC). The TIC is traced with utmost accuracy when the ROI is stationary. Because in daily practice, with the exception of superficial organ lesions (e.g., lymph nodes), most lesions are mobile during the examination due to the respiratory movements, postprocessing applications were designed to compensate these movements [34]. The TIC analysis is suitable both for techniques with a low MI (CA administered in bolus) and high MI (CA administered in a continuous infusion coupled with the “destruction-replenishment” technique), as it allows the examiner to set the time when the various parameters of the curve are calculated. The microbubble destruction technique, in the context of continuous infusion, leads to a more accurate characterization of the CA kinetics and allows repeated measurements for the same ROI as well as for other regions. The relative limitations of this technique are the lengthy examination time, the possible biological effects of high MI and the need to use special perfusion pumps [35]. The detailed analysis of the TIC curve is performed automatically by the software and is programmed to calculate mathematical parameters derived from the perfusion equation which are then integrated into the context by the examiner. They provide useful information for determining [36]:



**Figure 9.** CEUS of a renal tumor. The tumor is depicted in the renal cortex and entirely outlined in green; a smaller region of the tumor parenchyma is outlined in purple; the normal renal cortex is outlined in yellow. In the lower part of the image the TICs were plotted for each of the abovementioned ROIs based on the timing and intensity of the echoes.

- a. the circulatory bed volume – the maximum intensity of the signal referred to as "peak intensity" (PI) and respectively the "area under the curve" (AUC);
- b. the flow rate – the time elapsed from moment '0' until the point of maximum intensity – "time to peak" (TTP);
- c. the enhancement phase of the circulatory bed – "wash in time" (WIT – the time elapsed from the time of 5% enhancement until 95% enhancement);
- d. the wash-out phase of the circulatory bed – "wash out time" (WOT – representing the time from the systolic ascension until the full exit of CA from ROI);
- e. the rise time – "rise time" (RT);
- f. the average transit time through the region of interest – "mean transit time" (MTT).

### 4.3. Advantages and limitations of CEUS

Specific CEUS advantages consist of the following:

- a. lack of ionizing radiation;
- b. repeatability;
- c. the possibility to perform a bed-side examination;
- d. relatively low costs (as compared to other sectional imaging techniques);
- e. time needed for examination is short;
- f. the possibility to perform it on patients at risk or with contraindications to iodine agents or gadolinium administration;
- g. higher spatial and temporal resolution than CT or MRI;
- h. the ability to detect vessels even at very low velocities has been shown in some cases to be superior to contrast-enhanced CT (CECT) [37].

Moreover, CEUS is successful in providing hemodynamic information in areas where the slow flow and insonation angle represent an impediment to Doppler mode.

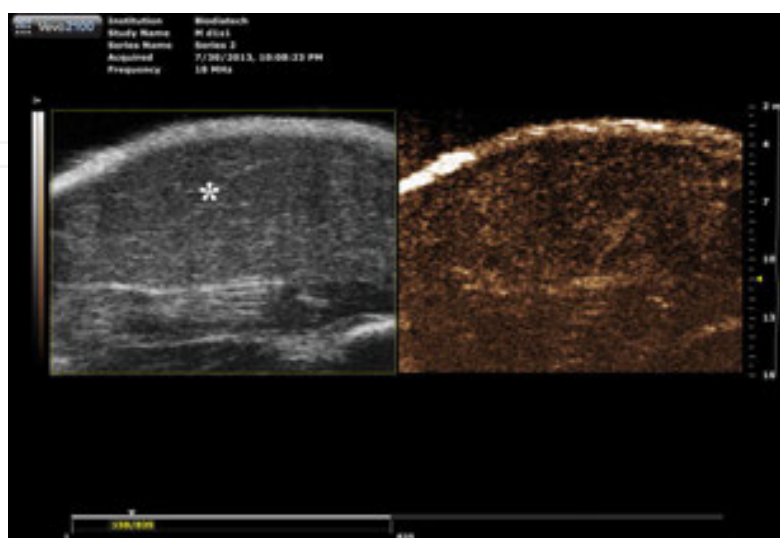
The limitations of CEUS are:

- a. the high costs of the systems able to operate in contrast mode (as compared to basic ultrasound systems);
- b. relatively steep and long learning curve;
- c. specific artifacts;
- d. the dependence on the patient's habitus (especially for deep lesions).



#### 4.4. Experimental animal models

The development of the emerging CEUS applications often involves building a model that is reproducible and based on easily controllable parameters. The animal models play an important role in the development of new therapies, as well as in the validation of the imaging techniques' capability to evaluate the response to treatment. Implementing such a model is a crucial step in the laborious process aimed for the final implementation of new diagnosis and therapeutic strategies in clinical practice. Murine models are the most commonly used. This is due to their relatively low cost, the possibility to obtain a wide range of transgenic animals and the ease of CEUS application to this species. The CEUS examination of the rats follows the same principles as in the case of human subjects. CA administration can be performed through the lateral tail vein [38]. This approach may be sometimes inefficient due to the increased skin rigidity and reduced vein caliber. Other authors have proposed alternative sites of administration, such as intracardiac [39]. Real-time US monitoring of the catheter's progression allows a precise placement of the needle tip and contributes to the success of the technique. This administration route is not without drawbacks, since the rat's accelerated heart rate can lead to catheter displacement outside the heart. Contrast agents developed for humans can be used effectively in animal models (e.g., SonoVue, Bracco Italy). There are also CAs specifically developed for animal studies, such as Micromarker (Bracco, Geneva). They offer the possibility to be combined with various components (e.g., Streptavidin), resulting in a molecular imaging method that addresses specific structures expressed on the endothelium (e.g., VEGFR-2) [40]. One of the basic murine models, which can be easily obtained and has wide applicability, uses the rat carcinosarcoma, known as the Walker 256 tumor. This can be grafted with high success rates in both superficial and intracavitary sites (e.g., intraperitoneal). The application of CEUS in these situations has implications for monitoring and quantifying the natural development of tumor MC and for assessing the success of tumoricidal therapies (**Figure 10**) [39].



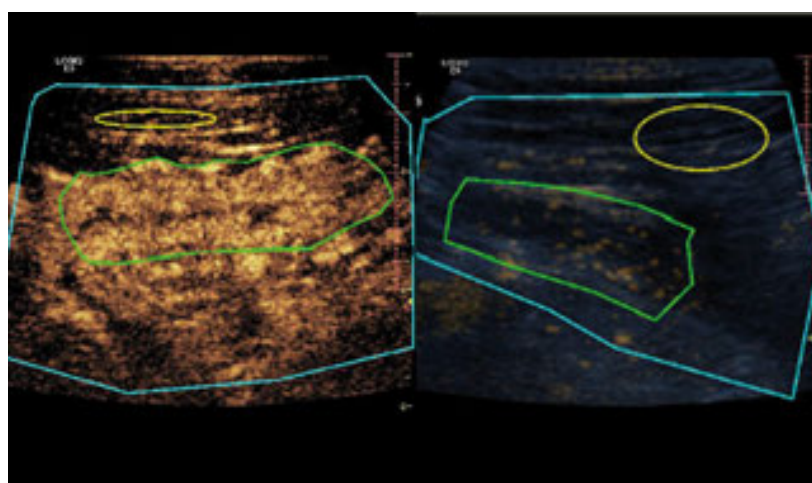
**Figure 10.** Appearance of an experimentally induced tumor by subcutaneous implantation in a Wistar animal model. On the left the tumor (asterisk) is depicted in B-mode US. On the right the CEUS examination is displayed.

#### 4.5. Modern clinical applications

From 2004 onwards the European Federation of the Societies of Ultrasonography in Medicine and Biology (EFSUMB) together with other entities such as The World Federation of Ultrasonography in Medicine and Biology (WFUMB) has made continuous efforts to publish guidelines and recommendations regarding the application of CEUS in hepatic and nonhepatic pathologies [27, 32].

Its applications in rheumatology, in the form of contrast-enhanced Doppler ultrasonography (Doppler CEUS) have been enhanced especially by the discovery of new treatments for active rheumatoid arthritis that target the microvasculature [41]. Compared to the classic Doppler technique, this application has significantly improved the detection of vascularity and the therapeutic decision in inflammatory pathologies of the small and large joints [42, 43]. However, low MI CEUS is superior to Doppler CEUS in detecting intra-articular microvasculature [44]. Also, the method provides valuable quantitative data through TIC, as revealed by some studies that observed positive correlations between the peak signal intensity and microvascular density (CD105+) in the case of psoriatic arthritis [45].

In the case of orchiepididymitis, the diagnosis is easily established by the clinical and DUS examination of the patient. Additionally, CEUS may point out much earlier an abscess formation, which appears as a nonenhancing structure, and consequently it improves the therapeutic approach [46].

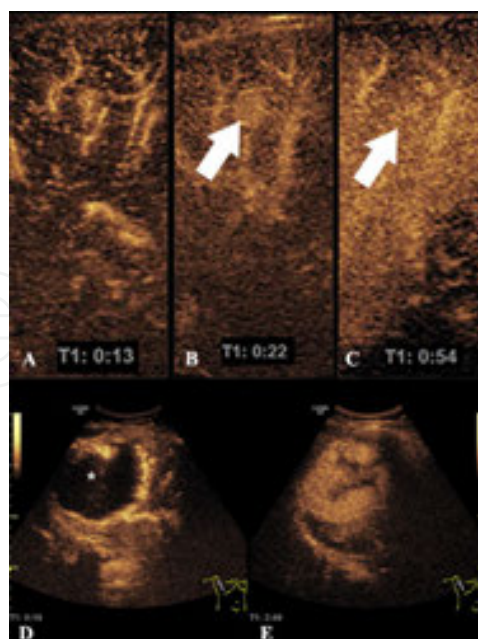


**Figure 11.** CEUS exploration of the intestinal wall in Crohn's disease, before (left image) and after treatment (right image). The intestinal wall is outlined in green and before treatment it is strongly enhancing, as opposed to the posttreatment findings where the enhancement pattern returned to a normal aspect. The adjacent fat (outlined in yellow) presented similar patterns.

The applications in the pathology of the digestive tract and its glands are numerous and diverse. One of these is the quantification of the intestinal wall vascularity in patients with Crohn's disease [47, 48]. In this particular situation, where angiogenesis is the key element of active disease, CEUS allows the assessment of the intestinal wall as well as of the adjacent fat, the results being strongly correlated with those of the MR [49]. The CA enhancement pattern

within the different bowel wall layers is correlated with the clinical parameters that characterize the disease activity. The evaluation of CA behavior through TIC curves allows the quantification of TTP, a parameter that is correlated with the values of the C reactive protein (CRP), which is a surrogate inflammation marker – a short TTP reflects the increased values of CRP encountered during the active stages of the disease [50]. Also, the elevation of TTP is an indicator of the inflammatory changes resolution [50]. The development of strictures is one of the possible complications of Crohn's disease in which CEUS can differentiate between the inflammatory substrate (strong enhancement) and the fibrotic one (weak enhancement) (**Figure 11**) [47, 51].

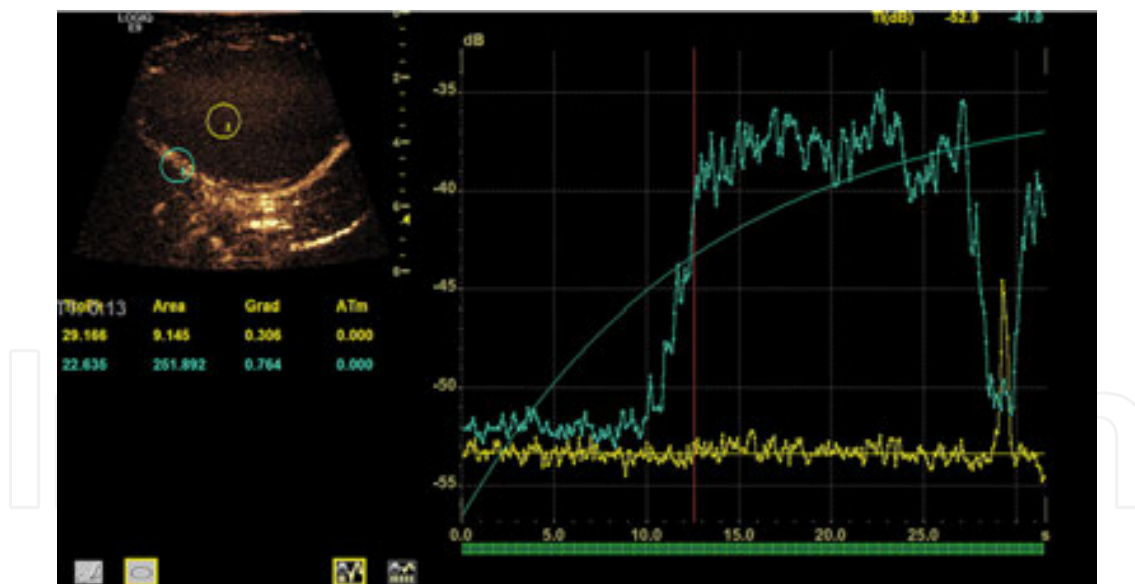
CEUS holds a distinct role in the appreciation of focal liver lesions since it is frequently successful in establishing an accurate diagnosis or facilitates the decision of further investigations. Benign lesions present a specific and constant enhancement pattern during the arterial and portal phases and no wash-out during the delayed phase [32]. Hemangiomas can be accurately diagnosed in over 95% of the cases since they have a typical CEUS pattern – nodular, peripheral enhancement during the arterial phase which progresses in a centripetal manner, the uptake being partial or complete (**Figure 12**). During the portal venous phase there is constant enhancement. A strong enhancement during the arterial phase is also found in focal nodular hyperplasia (FNH), but the progression is centrifugal and during the delayed phase the lesion may be hyper or isoenhancing compared to the adjacent parenchyma. During the late phases the typical central scar may be identified as a hypoenhancing area (**Figure 12**) [52].



**Figure 12.** CEUS of liver FNH and hemangioma. The FNH (arrows) presents hyperenhancement during the arterial (A, B) and venous phases (C) that progresses centrifugally. The hemangioma (asterisk) shows intense peripheral enhancement during the arterial phase (D) which progresses centripetally; the tumor is hyperenhanced in the late phase (E).

In malignant liver tumors there is an early and abrupt uptake of the CA within the circulatory bed followed by the CA wash-out from the region of interest in the end of the arterial phase or the beginning of the venous phase. This phenomenon is explained by the existence of arteriovenous communications. In over 97% of the cases HCC is hyperenhancing during the arterial phase and becomes hypoenhancing during the late phase [32]. Highly differentiated tumors may present delayed or absent wash-out, just like in the case of the well-differentiated HCC which can be isoenhancing in these phases. Cholangiocarcinoma displays a different behavior during the arterial phase, but during the subsequent phases a characteristic wash-out is identified. CEUS has implications not only in the diagnosis, but also in the treatment of tumors since it allows the guiding of local ablation techniques (ethanol injection or radio-frequency ablation) by easily identifying the tumor and confirming the efficiency of coagulation necrosis.

Renal tumors also benefit from this method. CEUS allows the differentiation between pseudotumors and tumors and allows the diagnosis of benign and malignant cystic masses [53]. The sensitivity of the method in identifying enhancement at the level of the fine septa is superior to that of CT, even though CT remains the standard method for the staging of malignant cystic tumors. CEUS is also useful in the noninvasive diagnosis of bladder tumors since it can differentiate between a blood clot and a mural tumor which is vascularized and therefore enhances after CA administration.



**Figure 13.** CEUS aspect of testicular infarction. In the upper left image, a yellow ROI is placed inside the testicular parenchyma and a blue ROI is placed upon the scrotal wall. The TICs for each ROI are plotted in the right half of the image. The testicular parenchyma (yellow) shows no enhancement in contrast with the normally enhancing scrotal wall (blue).

Regarding ischemic lesions, CEUS overcomes the limitations of DUS since it can differentiate between a slow circulatory bed and an ischemic area. The accuracy of the method is similar to that of contrast-enhanced CT and superior to DUS in the diagnosis of renal ischemia. Renal

infarction appears as a triangular shaped area, with the base toward the renal capsule and which does not enhance with CA, on the background of an enhancing renal parenchyma [54]. Infarction occurring in other organs provides similar CEUS findings (**Figure 13**).

## 5. Perspectives of the ultrasonographic evaluation of microcirculation

The discovery and use of new biological therapeutic agents not only for cancer treatment but also for other conditions have created the need to evaluate the treatment response in a noninvasive manner. In most cases, the effects of these therapies, especially in the early treatment phases, elude the analysis capacity of the morphological imaging techniques. Identifying the presence or absence of the therapeutic response in the initial phases of the treatment influences decisively the therapeutic itinerary of the patient – functional imaging is capable to assess these early changes. In the case of CEUS, the potential capability derives from the quantitative analysis of TIC. The parameters obtained through TIC before and after the initiation of a treatment with effects on microvasculature have the capacity to become surrogate markers of the therapeutic answer. A series of clinical trials have focused on their analysis and revealed relevant results [55]. For the low MI CEUS technique, the parameters that proved to be useful are WIT; WOT; MTT and AUC [36, 55, 56]. The disadvantage of this method is the lack of control on the CA concentration distributed at the level of the ROI, since it is manually injected. High MI techniques (destruction replenishment) manage to overcome this limitation by the automatic administration of the CA and by obtaining a stable plasmatic CA concentration. Other recent research directions have come to complete the ones already mentioned since they demonstrated the potential of the TIC parameters to become surrogate markers of tumor aggressiveness. The possibility to identify tumor aggressiveness in a noninvasive manner is extremely important due to the potential impact on the efficient individualization of the therapeutic strategy [56].

Recent technological discoveries allowed the development of 4D systems capable to follow the CA kinetics in real-time. These present the advantage of an integrated assessment of the CA kinetics within the whole tumoral mass or region of interest [57].

At the same time, the qualitative and quantitative data obtained through CEUS may be subjected to automatic complex analyses, such as CART (Classification and Regression Trees) that are based on artificial intelligence. They allow an integrated analysis of the CEUS parameters together with those provided by DUS, B mode US, CT/MRI and the creation of a complex, high accuracy, decision protocols [58].

The microbubbles used nowadays may be combined with various antibodies and therefore the technique may target specific structures. The binding may be performed with multiple antibodies at the same time. A recent study succeeded the triple marking of the CA against  $\alpha V\beta$ -integrin, P-selectin and endothelial growth factor of the human breast cancer endothelium and murine angiosarcoma [59]. Binding the CA with biomarkers improves the visualization of tumor angiogenesis and in the future these state-of-the-art methods will increase

the sensitivity of CEUS in detecting and staging cancers and in evaluating the microcirculation.

## 6. Conclusions

The ultrasonographic evaluation of vascularity is based on the Doppler technique and the harmonic technique using CAs. CEUS is the recommended US method for the characterization of microcirculation for which it provides a multivariate appreciation. The results of the examination are displayed in real-time under the eyes of the examiner, while the quantitative assessment of the CA kinetics parameters is easy to perform. These features allow a precise definition of the healthy or pathologic state of an organ and the follow-up of treatment response. The method is versatile and in the future it will open new perspectives for individualized, patient-centered therapy, with special benefits for oncologic patients.

## Author details

Attila Tamas-Szora<sup>1,2,3\*</sup>, Mihai A. Socaciu<sup>2,3</sup>, Alexandru Florin Badea<sup>1</sup>, Iulian Opincariu<sup>1</sup> and Radu I. Badea<sup>2,3</sup>

\*Address all correspondence to: [tamas-szora.attila@umfcluj.ro](mailto:tamas-szora.attila@umfcluj.ro)

1 Anatomy and Embryology Department, School of Medicine, University of Medicine & Pharmacy "Iuliu Hatieganu", Cluj Napoca, Romania

2 Imaging Department, School of Medicine, University of Medicine & Pharmacy "Iuliu Hatieganu", Cluj Napoca, Romania

3 Ultrasound Research and Education Department, Institute of Gastroenterology and Hepatology "Octavian Fodor", Cluj Napoca, Romania

## References

- [1] Levy BI, Ambrosio G, Pries AR, Struijker-Boudier HA. Microcirculation in hypertension: a new target for treatment? *Circulation*. 2001;104(6):735–740. Doi: 10.1161/hc3101.091158.
- [2] Alkim C, Alkim H, Koksal AR, Boga S, Sen I. Angiogenesis in inflammatory bowel disease. *International Journal of Inflammation* 2015;2015:1–10. Doi: 10.1155/2015/970890.

- [3] Folkman J. Tumor angiogenesis: therapeutic implications. *The New England Journal of Medicine*. 1971;285(21):1182–11826. Doi: 10.1056/nejm197111182852108.
- [4] Folkman J. Fundamental concepts of the angiogenic process. *Current Molecular Medicine*. 2003;3(7):643–651. Doi: 10.2174/1566524033479465.
- [5] Jain RK. Delivery of novel therapeutic agents in tumors: physiological barriers and strategies. *Journal of the National Cancer Institute*. 1989;81(8):570–576. Doi: 10.1093/jnci/81.8.570.
- [6] Allard WJ, Matera J, Miller MC, Repollet M, Connelly MC, Rao C, et al. Tumor cells circulate in the peripheral blood of all major carcinomas but not in healthy subjects or patients with nonmalignant diseases. *Clinical Cancer Research: An Official Journal of the American Association for Cancer Research*. 2004;10(20):6897–6904. Doi: 10.1158/1078-0432.ccr-04-0378.
- [7] Chaplin DJ, Olive PL, Durand RE. Intermittent blood flow in a murine tumor: radiobiological effects. *Cancer Research*. 1987;47(2):597–601.
- [8] Fukumura D, Duda DG, Munn LL, Jain RK. Tumor microvasculature and microenvironment: novel insights through intravital imaging in pre-clinical models. *Microcirculation*. 2010;17(3):206–225. doi: 10.1111/j.1549-8719.2010.00029.x.
- [9] Vira MA, Novakovic KR, Pinto PA, Linehan WM. Genetic basis of kidney cancer: a model for developing molecular-targeted therapies. *BJU International*. 2007;99(5):1223–1229. Doi: 10.1111/j.1464-410x.2007.06814.x.
- [10] Des Guetz G, Uzzan B, Nicolas P, Cucherat M, Morere JF, Benamouzig R, et al. Microvessel density and VEGF expression are prognostic factors in colorectal cancer. Meta-analysis of the literature. *British Journal of Cancer*. 2006;94(12):1823–1832. Doi: 10.1038/sj.bjc.6603176.
- [11] Medinger M, Esser N, Zirrgiebel U, Ryan A, Jurgensmeier JM, Drevs J. Antitumor and antiangiogenic activity of cediranib in a preclinical model of renal cell carcinoma. *Anticancer Research*. 2009;29(12):5065–5076.
- [12] Jain RK. Normalization of tumor vasculature: an emerging concept in antiangiogenic therapy. *Science*. 2005;307(5706):58–62. Doi: 10.1126/science.1104819.
- [13] Lassau N, Paturel-Asselin C, Guinebretiere JM, Leclere J, Koscielny S, Roche A, et al. New hemodynamic approach to angiogenesis: color and pulsed Doppler ultrasonography. *Investigative Radiology*. 1999;34(3):194–198. Doi: 10.1097/00004424-199903000-00007.
- [14] Yang WT, Tse GM, Lam PK, Metreweli C, Chang J. Correlation between color power Doppler sonographic measurement of breast tumor vasculature and immunohistochemical analysis of microvessel density for the quantitation of angiogenesis. *Journal of Ultrasound in Medicine*. 2002;21(11):1227–1235.

- [15] Schmidt WA. Technology Insight: the role of color and power Doppler ultrasonography in rheumatology. *Nature Clinical Practice Rheumatology*. 2007;3(1):35–42. Doi: 10.1038/ncprheum0377.
- [16] Wakefield RJ, Balint PV, Szkudlarek M, Filippucci E, Backhaus M, D'Agostino MA, et al. Musculoskeletal ultrasound including definitions for ultrasonographic pathology. *The Journal of Rheumatology*. 2005;32(12):2485–2487.
- [17] Szkudlarek M, Court-Payen M, Strandberg C, Klarlund M, Klausen T, Ostergaard M. Power Doppler ultrasonography for assessment of synovitis in the metacarpophalangeal joints of patients with rheumatoid arthritis: a comparison with dynamic magnetic resonance imaging. *Arthritis and Rheumatism*. 2001;44(9):2018–2023. Doi: 10.1002/1529-0131(200109)44:9<2018::AID-ART350>3.0.CO;2-C.
- [18] Botar Jid C, Bolboaca SD, Cosgarea R, Senila S, Rogoan L, Lenghel M, et al. Doppler ultrasound and strain elastography in the assessment of cutaneous melanoma: preliminary results. *Medical Ultrasonography*. 2015;17(4):509–514. Doi: 10.11152/mu.2013.2066.174.dus/.
- [19] Lassau N, Lamuraglia M, Koscielny S, Spatz A, Roche A, Leclere J, et al. Prognostic value of angiogenesis evaluated with high-frequency and colour Doppler sonography for preoperative assessment of primary cutaneous melanomas: correlation with recurrence after a 5 year follow-up period. *Cancer Imaging*. 2006;6:24–299. Doi: 10.1102/1470-7330.2006.0009.
- [20] Sekiya N, Ichioka S. Efficacy of ultrasonography at the ankle level for estimation of pedal microcirculation. *Annals of Vascular Diseases*. 2015;8(3):198–202. Doi: 10.3400/avd.oa.15-00078.
- [21] Gunnar H. Heine, Markus K. Gerhart, Christof Ulrich, Hans Kaler, Matthias Girndt. Renal Doppler resistance indices are associated with systemic atherosclerosis in kidney transplant recipients. *Kidney International*. 2005;68(2):878–885. Doi: 10.1111/j.1523-1755.2005.00470.x.
- [22] Hop MJ, Hiddingh J, Stekelenburg C, Kuipers HC, Middelkoop E, Nieuwenhuis MK, et al. Cost-effectiveness of laser Doppler imaging in burn care in the Netherlands. *BMC Surgery*. 2013;13(1):1. Doi: 10.1186/1471-2482-13-2.
- [23] Ricci S, Matera R, Tortoli P. An improved Doppler model for obtaining accurate maximum blood velocities. *Ultrasonics*. 2014;54(7):2006–2014. Doi: 10.1016/j.ultras.2014.05.012.
- [24] Hsu C, Chen CN, Chen LT, Wu CY, Hsieh FJ, Cheng AL. Effect of thalidomide in hepatocellular carcinoma: assessment with power Doppler US and analysis of circulating angiogenic factors. *Radiology*. 2005;235(2):509–516. Doi: 10.1148/radiol.235204027.



- [25] Kupeli A, Kul S, Eyuboglu I, Oguz S, Mungan S. Role of 3D power Doppler ultrasound in the further characterization of suspicious breast masses. *European Journal of Radiology*. 2016;85(1):1–6. Doi: 10.1016/j.ejrad.2015.10.019.
- [26] Gramiak R, Shah PM. Echocardiography of the aortic root. *Investigative Radiology*. 1968;3(5):356–366. Doi: 10.1097/00004424-196809000-00011.
- [27] Piscaglia F, Nolsoe C, Dietrich CF, Cosgrove DO, Gilja OH, Bachmann Nielsen M, et al. The EFSUMB Guidelines and Recommendations on the Clinical Practice of Contrast Enhanced Ultrasound (CEUS): update 2011 on non-hepatic applications. *Ultraschall in der Medizin*. 2012;33(1):33–59. Doi: 10.1055/s-0031-1281676.
- [28] ter Haar G. Safety and bio-effects of ultrasound contrast agents. *Medical & Biological Engineering & Computing*. 2009;47(8):893–900. Doi: 10.1007/s11517-009-0507-3.
- [29] Piscaglia F, Bolondi L. The safety of Sonovue in abdominal applications: retrospective analysis of 23188 investigations. *Ultrasound in Medicine & Biology*. 2006;32(9):1369–1375. Doi: 10.1016/j.ultrasmedbio.2006.05.031.
- [30] Kusnetzky LL, Khalid A, Khumri TM, Moe TG, Jones PG, Main ML. Acute mortality in hospitalized patients undergoing echocardiography with and without an ultrasound contrast agent: results in 18,671 consecutive studies. *Journal of the American College of Cardiology*. 2008;51(17):1704–1706. Doi: 10.1016/j.jacc.2008.03.006.
- [31] Leen E, Averkiou M, Arditi M, Burns P, Bokor D, Gauthier T, et al. Dynamic contrast enhanced ultrasound assessment of the vascular effects of novel therapeutics in early stage trials. *European Radiology*. 2012;22(7):1442–1450. Doi: 10.1007/s00330-011-2373-2.
- [32] Claudon M, Dietrich CF, Choi BI, Cosgrove DO, Kudo M, Nolsoe CP, et al. Guidelines and good clinical practice recommendations for Contrast Enhanced Ultrasound (CEUS) in the liver – update 2012. *Ultrasound in Medicine & Biology*. 2013;34(1):11–29. Doi: 10.1016/j.ultrasmedbio.2012.09.002.
- [33] Badea R, Ciobanu L. Contrast enhanced and Doppler ultrasonography in the characterization of the microcirculation. *Expectancies and Performances. Medical Ultrasonography*. 2012;14(4):307–317.
- [34] Palmowski M, Lederle W, Gaetjens J, Socher M, Hauff P, Bzyl J, et al. Comparison of conventional time-intensity curves vs. maximum intensity over time for post-processing of dynamic contrast-enhanced ultrasound. *European Journal of Radiology*. 2010;75(1):149–153. Doi: 10.1016/j.ejrad.2009.10.030.
- [35] Wei K, Jayaweera AR, Firoozan S, Linka A, Skyba DM, Kaul S. Quantification of myocardial blood flow with ultrasound-induced destruction of microbubbles administered as a constant venous infusion. *Circulation*. 1998;97(5):473–483. Doi: 10.1161/01.cir.97.5.473.
- [36] Dietrich CF, Averkiou MA, Correas JM, Lassau N, Leen E, Piscaglia F. An EFSUMB introduction into Dynamic Contrast-Enhanced Ultrasound (DCE-US) for quantifica-

- tion of tumour perfusion. *Ultraschall in der Medizin*. 2012;33(4):344–351. Doi: 10.1055/s-0032-1313026.
- [37] Tamai H, Takiguchi Y, Oka M, Shingaki N, Enomoto S, Shiraki T, et al. Contrast-enhanced ultrasonography in the diagnosis of solid renal tumors. *Journal of Ultrasound in Medicine*. 2005;24(12):1635–1640.
- [38] Huang YC, Shindel AW, Ning H, Lin G, Harraz AM, Wang G, et al. Adipose derived stem cells ameliorate hyperlipidemia associated detrusor overactivity in a rat model. *The Journal of Urology*. 2010;183(3):1232–1240. Doi: 10.1016/j.juro.2009.11.012.
- [39] Badea AF, Tamas-Szora A, Clichici S, Socaciu M, Tabaran AF, Baciut G, et al. Contrast enhanced ultrasonography (CEUS) in the characterization of tumor microcirculation. Validation of the procedure in the animal experimental model. *Medical Ultrasonography*. 2013;15(2):85–94. Doi: 10.11152/mu.2013.2066.152.afb1ats2.
- [40] Saini R, Sorace AG, Warram JM, Mahoney MJ, Zinn KR, Hoyt K. An animal model allowing controlled receptor expression for molecular ultrasound imaging. *Ultrasound in Medicine and Biology*. 2013;39(1):172–180. Doi: 10.1016/j.ultrasmedbio.2012.08.016.
- [41] Taylor PC. The value of sensitive imaging modalities in rheumatoid arthritis. *Arthritis Research & Therapy*. 2003;5(5):210–213.
- [42] De Zordo T, Mlekusch SP, Feuchtner GM, Mur E, Schirmer M, Klauser AS. Value of contrast-enhanced ultrasound in rheumatoid arthritis. *European Journal of Radiology*. 2007;64(2):222–230. Doi: 10.1016/j.ejrad.2007.07.011.
- [43] Hermann KG, Backhaus M, Schneider U, Labs K, Loreck D, Zuhlsdorf S, et al. Rheumatoid arthritis of the shoulder joint: comparison of conventional radiography, ultrasound, and dynamic contrast-enhanced magnetic resonance imaging. *Arthritis and Rheumatism*. 2003;48(12):3338–3349. Doi: 10.1002/art.11349.
- [44] Klauser A, Frauscher F, Schirmer M, Halpern E, Pallwein L, Herold M, et al. The value of contrast-enhanced color Doppler ultrasound in the detection of vascularization of finger joints in patients with rheumatoid arthritis. *Arthritis and Rheumatism*. 2002;46(3):647–653. Doi: 10.1002/art.10136.
- [45] Fiocco U, Stramare R, Coran A, Grisan E, Scagliori E, Caso F, et al. Vascular perfusion kinetics by contrast-enhanced ultrasound are related to synovial microvascularity in the joints of psoriatic arthritis. *Clinical Rheumatology*. 2015;34(11):1903–1912. Doi: 10.1007/s10067-015-2894-1.
- [46] Moschouris H, Stamatou K, Lampropoulou E, Kalikis D, Matsaidonis D. Imaging of the acute scrotum: is there a place for contrast-enhanced ultrasonography? *International Brazilian Journal of Urology*. 2009;35(6):692–702. Doi: 10.1590/s1677-55382009000600008.
- [47] Socaciu M, Ciobanu L, Diaconu B, et al. Non-invasive assessment of inflammation and treatment response in patients with Crohn's disease and ulcerative colitis using

- contrast-enhanced ultrasonography quantification. *J Gastrointest Liver Dis.* 2015;24(4):457–465. Doi: 10.15403/jgld.2014.1121.244.chr.
- [48] Neciu C, Badea R, Chiorean L, Badea AF, Opincariu I. Oral and I.V. contrast enhanced ultrasonography of the digestive tract—a useful completion of the B-mode examination: a literature review and an exhaustive illustration through images. *Medical Ultrasonography.* 2015 Mar;17(1):62–73. Doi: 10.11152/mu.2013.2066.171.cnr.
- [49] Schreyer AG, Finkenzeller T, Gossmann H, Daneschnejad M, Muller-Wille R, Schacherer D, et al. Microcirculation and perfusion with contrast enhanced ultrasound (CEUS) in Crohn's disease: first results with linear contrast harmonic imaging (CHI). *Clinical Hemorheology and Microcirculation.* 2008;40(2):143–155.
- [50] Girlich C, Schacherer D, Jung EM, Schreyer A, Büttner R. Comparison between a clinical activity index (Harvey–Bradshaw-Index), laboratory inflammation markers and quantitative assessment of bowel wall vascularization by contrast-enhanced ultrasound in Crohn's disease. *European Journal of Radiology.* 2012;81(6):1105–1109. Doi: 10.1016/j.ejrad.2011.02.054.
- [51] Wilson SR, Burns PN. Microbubble-enhanced US in body imaging: what role? *Radiology.* 2010;257(1):24–39. Doi: 10.1148/radiol.10091210.
- [52] Piscaglia F, Gianstefani A, Ravaioli M, Golfieri R, Cappelli A, Giampalma E, et al. Criteria for diagnosing benign portal vein thrombosis in the assessment of patients with cirrhosis and hepatocellular carcinoma for liver transplantation. *Liver Transplantation.* 2010;16(5):658–667. Doi: 10.1002/lt.22044.
- [53] Tamas-Szora A, Opincariu I, Manea C, Dobrotă F, Coman I, Buruiian M, Badea R. Radiological and imaging features of renal small cell carcinoma: a case report and literature review. *Romanian Journal of Functional & Clinical, Macro-& Microscopical Anatomy & of Anthropology.* 2015;14(2):275–280.
- [54] Bertolotto M, Martegani A, Aiani L, Zappetti R, Cernic S, Cova MA. Value of contrast-enhanced ultrasonography for detecting renal infarcts proven by contrast enhanced CT. A feasibility study. *European Radiology.* 2008;18(2):376–383. Doi: 10.1007/s00330-007-0747-2.
- [55] Hudson JM, Williams R, Tremblay-Darveau C, Sheeran PS, Milot L, Bjarnason GA, et al. Dynamic contrast enhanced ultrasound for therapy monitoring. *European Journal of Radiology.* 2015;84(9):1650–1657. Doi: 10.1016/j.ejrad.2015.05.013.
- [56] Tamas-Szora A, Socaciu M, Crisan N, Dobrota F, Prundus P, Bungardean C, et al. Investigation of renal cell carcinoma by contrast-enhanced ultrasound- predictive value of time intensity curve analysis in establishing local tumor invasion and stage: a pilot study. *Urology Journal.* 2015;12(3):2173–2181.

- [57] Maruyama H, Yoshikawa M, Yokosuka O. Current role of ultrasound for the management of hepatocellular carcinoma. *World Journal of Gastroenterology*. 2008;14(11):1710–1719. Doi: 10.3748/wjg.14.1710.
- [58] Badea AF, Bran S, Tamas-Szora A, Floareş A, Badea R, Baciut G. Solid parotid tumors: an individual and integrative analysis of various ultrasonographic criteria. A prospective and observational study. *Medical Ultrasonography*. 2013;15(4):289–298. Doi: 10.11152/mu.2013.2066.154.afb2.
- [59] Warram JM, Sorace AG, Saini R, Umphrey HR, Zinn KR, Hoyt K. A triple-targeted ultrasound contrast agent provides improved localization to tumor vasculature. *Journal of Ultrasound in Medicine*. 2011;30(7):921–931.

