

We are IntechOpen, the world's leading publisher of Open Access books Built by scientists, for scientists

4,800

Open access books available

122,000

International authors and editors

135M

Downloads

Our authors are among the

154

Countries delivered to

TOP 1%

most cited scientists

12.2%

Contributors from top 500 universities



WEB OF SCIENCE™

Selection of our books indexed in the Book Citation Index
in Web of Science™ Core Collection (BKCI)

Interested in publishing with us?
Contact book.department@intechopen.com

Numbers displayed above are based on latest data collected.
For more information visit www.intechopen.com



Epidemiology and Emergence of Schmallenberg Virus

Part 2: Pathogenesis and Risk of Viral Spread

Fernando Esteves, João Rodrigo Mesquita,
Cármem Nóbrega, Carla Santos, António Monteiro,
Rita Cruz, Helena Vala and Ana Cláudia Coelho

Additional information is available at the end of the chapter

<http://dx.doi.org/10.5772/64742>

Abstract

Schmallenberg virus (SBV) is a novel Orthobunyavirus causing mild clinical signs in cows and malformations in aborted and neonatal ruminants in Europe. SBV belongs to the family Bunyaviridae and is transmitted by biting midges. This new virus was identified for the first time in blood samples of cows in the city of Schmallenberg in North-Rhine Westphalia in November 2011. Since then, the virus spread to several European countries. Here, we describe the pathogenesis and the risk of viral spread in the Portuguese territory.

Keywords: Schmallenberg virus, emerging infections, epidemiology

1. Pathogenesis

The knowledge of Schmallenberg virus (SBV) pathogeny will allow to achieve a better understanding of its most obvious expression, reflected in their striking lesional pattern; however, until now, the pathogenic features of SBV are not well understood. Current assumptions about SBV pathogenesis in ruminants are frequently based on findings described for Akabane virus (AKAV), which, similar to SBV, causes in aborted or stillborn neonatal ruminants, arthrogryposis and hydranencephaly syndrome (AHS) [1].

The tropism of SBV to the central nervous system (CNS) is already well described in the literature, associated with several congenital malformations, being the most notorious in the

brain [2]. However, taking into consideration the results obtained by Balseiro et al. [3], regarding the presence of the virus in several tissues of naturally infected calves, SBV could also have tropism to other organs and tissues, namely muscle, skeletal and cardiac, spleen, placenta and umbilical cord [3].

As referred, SBV infection during gestational period affects the foetus, through a vertical transplacental transmission. The development of teratogenic defects and its severity is directly related with gestational time (GT) at the moment of infection and, consequently, neuronal cells development in the CNS, which are the SBV target [2, 3].

The severity of lesions in the CNS is also dependent of the foetal immune system development, characterized by cellular population of the thymus and lymph nodes and the production of antibodies, which in bovines occurs between days 40 and 175 of GT and in the lamb starts 19 days post gestation and lasts until 115 days after conception and depends also of the foetal CNS vulnerability (well defined in the cow as the period between days 60 and 180 of GT) [1, 2].

Thus, the severity of lesions in the brain and spinal cord depends on the complexity of the interaction between foetal neurogenesis, immunocompetency, virulence of the viral strain, intensity and time of infection [1–3].

If maternal infection occurs in early gestational period, before the foetus becomes immunocompetent (between the 90th and the 180th day of GT in cow; between the 25th and 50th day in sheep), severe dysplastic CNS lesions, including a distinctive micromyelia, without evidence of inflammation are described, as well as abortion, stillborn and congenital malformations, with no detectable viral RNA and antigen [2, 4, 5].

Infection in the first month of gestation could probably cause embryonic death and subsequent resorption or abortion, only proven by repeat oestrus and matings, observed by farmers and shepherds [4].

If maternal infection occurs in the late gestational period (after 180th day of GT in cow; after 50th day in sheep), inflammation—nonsuppurative polioencephalomyelitis (lymphohistiocytic) or meningoencephalomyelitis—can be present due to viral antigen recognition by the foetal immune system, with detectable viral RNA and antigen [1, 2, 4, 5].

Probably due to the rapid organogenesis consequent to the shorter GT in sheep (GT of 150–155 days), brain and spinal cord malformation are more severe in lambs than in calves [5]. As well as most viral infections, transplacental transmission could not result in notorious placentitis and most malformed newborns are stillborn at term [2].

1.1. CNS congenital malformations

The association of Schmallenberg virus with a range of congenital malformations, mostly in the CNS, is well known [2]. The brain is the most frequent target, but cerebellar and spinal cord defects are also referred by several authors [5]. The predominant malformations observed in the CNS of both lambs and calves are hydranencephaly, porencephaly, hydrocephalus, microencephaly, cerebellar hypoplasia and mild-to-marked dysplasia of the cerebellum, brain stem and spinal cord [4, 6].

According to Peperkamp et al. [5], defects occurring in the cerebrum might range from slight to moderate dysplasia, including microencephaly, porencephaly, hydrocephalus and lack of gyri (lissencephaly), to fully developed hydranencephaly.

Porencephaly refers to cystic fluid-filled cavities in the brain tissue, which communicate with the ventricular system, and is usually described as the cavitation of the cerebral hemispheres. One study performed by Herder et al. [1] revealed that the temporal and parietal lobes are more frequently affected, usually in a bilateral-symmetrical matter. Furthermore, porencephaly might be present in both temporal and parietal lobes, in a condition named multicystic encephalopathy.

Hydranencephaly is characterized by the destruction of brain hemispheres, many times with a complete or almost complete replacement of the cortex by cerebrospinal fluid, surrounded by a thin, almost transparent, membranous sac.

Cerebellar hypoplasia is one of the most frequently referred malformations in the CNS of SBV-infected animals, and, both in lambs and in calves, various degrees of cerebellar dysplasia might be present, even in animals presenting a normal cerebrum [5].

Morphologic alterations of the spinal cord are observed as a decrease in the cross-sectional area of the spinal cord, or micromyelia. This malformation is characterized by neuronal loss in the ventral horns, and is apparently positively correlated with the magnitude of musculoskeletal deformities [5].

Histologically, the described malformations might be accompanied by the presence or absence of inflammation, including encephalomyelitis, lymphohistiocytic meningoencephalomyelitis and glial nodules. Microscopic lesions include rarefaction and cavitation, degeneration, necrosis and loss of neurons, as well as mild to severe, diffuse astrogliosis and/or microgliosis [1, 7].

1.2. Other lesions (musculoskeletal)

Malformed newborns presented underweight due to the underdevelopment of body mass, skeletal muscles and variable severity of malformations. Frequently, bones undergo normal development but vertebral malformations and arthrogryposis occur due to the imbalance in foetal muscular activity, secondary to the loss of neurons in the brain and spinal cord and demyelination, affecting descending tracts in the ventral spinal cord white matter, ventral horn motor neurons in the spinal cord grey matter and ventral spinal nerve roots [2, 4, 8].

The lack of innervation, by lower motor neuron, to the skeletal muscle motor units prevents its normal development, resulting in muscular hypoplasia. Neuronal bilateral loss in cervical and lumbar intumescences causes bilateral arthrogryposis, and unilateral neuronal loss causes unilateral arthrogryposis [4, 5].

This neuronal loss in spinal cord could be grossly visible in severely affected cases, as a small dorsoventral flattened spinal cord, designated by micromyelia and, consequently, results in denervation of the axial and appendicular musculature with the failure of normal skeletal

muscle development, resulting in the lesions of vertebral column malformations and arthrogryposis [2].

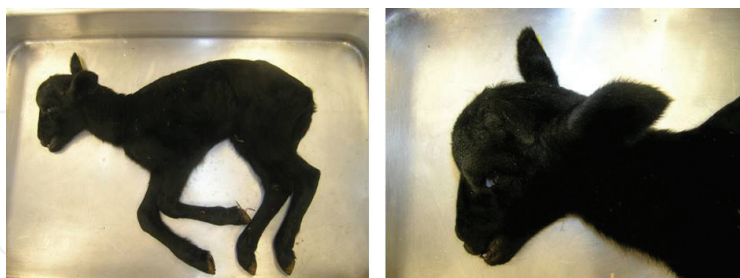

Figure 1. Newborn lamb with 6 days revealing prognathism and kyphosis.

Therefore, vertebral column malformations, namely torticollis, scoliosis and kyphosis (**Figure 1**) of the thoracic vertebral column, mostly combined with arthrogryposis are consequent to dysplastic CNS lesions and represent the most visible gross lesions [2]. Scoliosis, kyphoscoliosis and kyphosis without torticollis are less frequent and vertebral column malformations without arthrogryposis are rare (**Table 1**) [2].

Frequency	Arthrogryposis	Vertebral column malformations			
		Torticollis	Scoliosis	Kyphosis	Torticollis
Frequent	x	x	x	x	x
Less frequent			x	x	
Rare		x	x	x	x

Table 1. Most visible gross lesions.

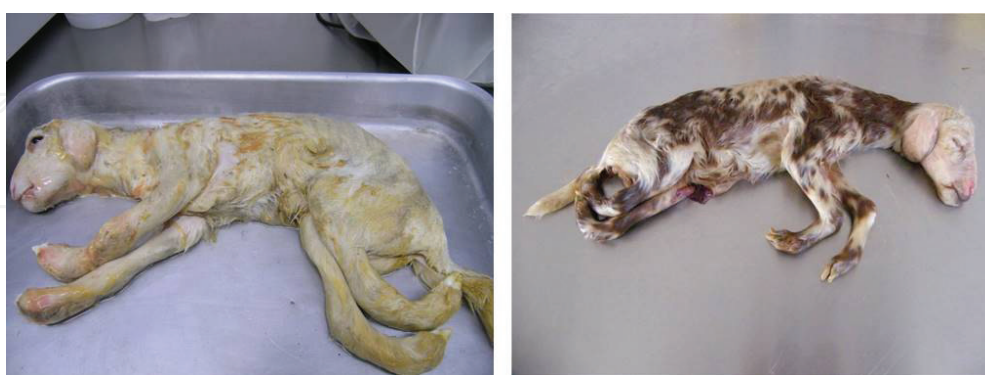

Figure 2. Stillborn lambs with severe arthrogryposis multiplex congenital affecting the four limbs.

The most frequent lesion observed in the limbs is the arthrogryposis multiplex congenital affecting the four limbs, symmetric and bilaterally (**Figures 2–4**), often accompanied by vertebral column malformations, as referred. Arthrogryposis could range from different

severities, affecting only the forelimbs (uni- or bilaterally) or only the hindlimbs (uni- or bilaterally; rarely) (Table 2) [2, 5].

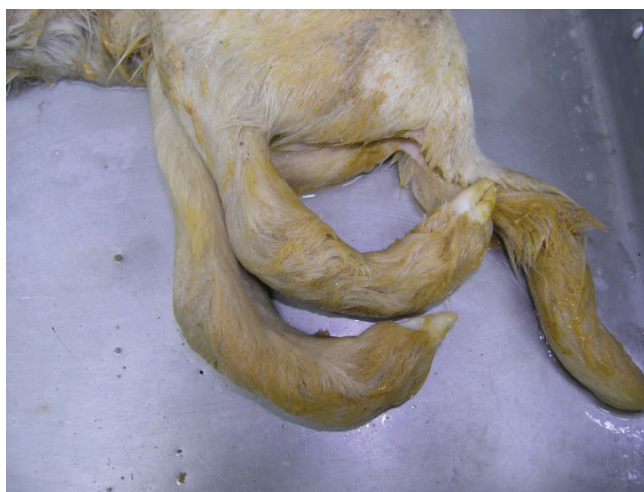

Figure 3. Arthrogryposis. Note the severe curving of joints.

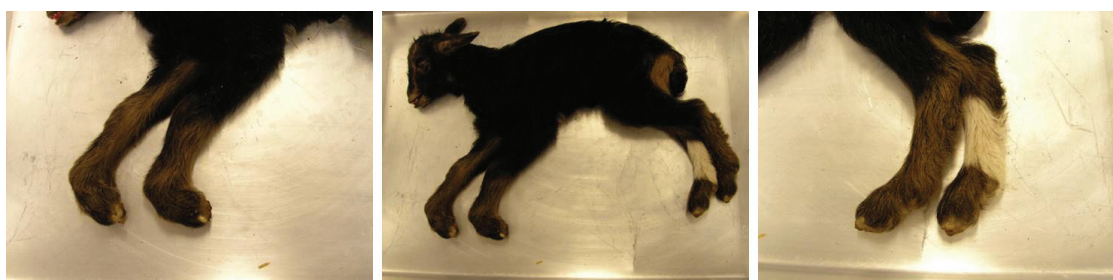

Figure 4. Newborn kid with three revealing arthrogryposis affecting only forelimbs bilaterally.

	Forelimb right	Forelimb left	Hindlimb right	Hindlimb left
Frequent	x	x	x	x
Less frequent	x	x		
Rare			x	x

Table 2. Frequency of arthrogryposis.

The histopathology of skeletal muscles of arthrogryptic limbs revealed hypoplasia of striated muscular tissue (severe reduction of muscle diameter) and myofibrillar hypoplasia, reflecting the extent of dysplastic spinal cord with neuronal loss in the cervical and lumbar intumescences [2, 4, 5]. Other musculoskeletal histopathologic lesions described include atrophy and loss of skeletal muscle mass (especially in the limbs and neck) (Figure 5), with the presence of fibrous or adipose tissue, as well as the depletion of fat deposits [5, 9].

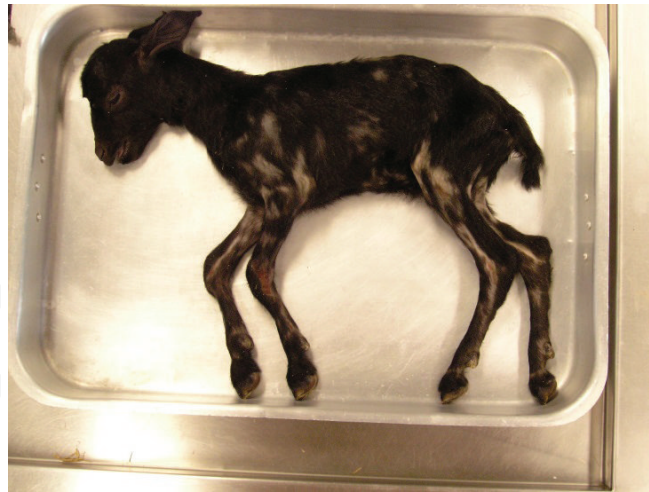

Figure 5. Newborn kid with 6 days revealing the loss of skeletal muscle mass.

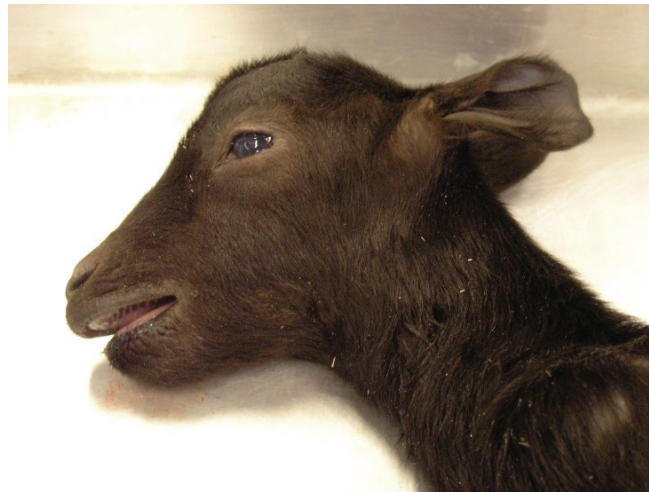

Figure 6. Newborn kid with 3 days revealing brachygnathia.




Figure 7. Stillborn lamb with prognathism.

Abnormal flattened skull with cranial vault reduced by thickened frontal, parietal and occipital bones was described [5]. Flattened ribcage could also be present, consequently to malformations of the thoracic vertebral column, as well as lordosis of the thoracolumbar part of the vertebral column [2].

Lesions of brachygnathia (**Figure 6**) and prognathism (**Figure 7**) are described in the consulted literature [5, 9].

Peperkamp et al. [5] reported hypoplasia of the lung lobes in ruminants affected with thoracic malformation but in other organs analysed, such as urinary bladder, thyroid gland, liver, spleen, heart muscle and vessels, uterus, ovaries, testes, peripheral nerves, placenta, oesophagus, abomasum, small and large intestine, pancreas, adrenal glands, celiac ganglion, trachea, skin, tongue and adipose tissue, no significant histopathological lesions were present [5, 9].

1.3. Characterization of inflammatory infiltrates

Inflammatory changes of the brain and meninges are more frequent in small ruminants than in calves, and are characterized by lymphohistiocytic perivascular cuffs with parenchymal T cells, B cells and microglia/macrophages. The CD3-positive T cells are the dominant cellular group. CD79 α -positive B cells are also found, but on a lesser extent and CD68-positive microglia/macrophages are less often detected [1].

1.4. Challenges in differential diagnosis

Taking into account the most prominent lesion of CNS congenital malformations, in ruminants, the first and most important challenge in the differential diagnosis (DD) is ruling out other viral-induced congenital malformations in ruminants, including bovine virus diarrhoea virus (BVDV), Border disease virus (BDV), blue tongue virus (BTV), Akabane virus, Aino virus (AV) and Cache Valley virus (CVV) [2, 5].

Also, molecular and serological diagnosis becomes more difficult when the infection of SBV occurs in early gestational period (aggravated in cows where the total GT is larger than sheep) for having more time to develop an effective immune response (foetal lambs have its immune system completely immunocompetent at mid-gestation, at the 90th day of GT) and performs the viral clearance in seropositive offspring, which could make them negative to the virus [4, 5]. Moreover, malformations in CNS and musculoskeletal system are frequently caused by teratogenic and genetic defects, as well as a significant number of inherited congenital syndromes that closely resemble SBV lesions, such as arthrogryposis multiplex congenital syndrome, arachnomelia, both with arthrogryposis [2]. Also, rare non-viral congenital syndromes can occur, such as congenital myoclonus, Perosomus elumbis, Cycloopia and none fragility described in bovine.

Unlike clinical signs, discrete, non-specific and variable, the lesions described above have a dramatic and showy expression, could be easily recognized by clinicians but none are pathognomonic for SBV, despite its great diagnostic value (**Table 3**). It is then extremely difficult to obtain a precise and definitive aetiological diagnosis [2, 5].

	SBV	BTV	BVDV and BDV	AKAV
Cerebral defects	Yes or no (less common in cow)	Yes	Yes	Yes in early GT
Spinal cord lesions with arthrogryposis	Yes	No	No	Yes in late GT
Vertebral malformations	Yes	No	No	No (rare)

Table 3. The value of congenital malformations in the DD of viral-induced congenital malformations.

Therefore, definitive diagnosis requires systematic necropsies, with the examination of the brain and spinal cord, which could be done in the field but the ideal practice would be the recourse to a specialty laboratory to obtain diagnostic accuracy and specificity namely the pathology laboratory, once the diagnosis could not be exclusively done based only in gross lesions, even if arthrogryposis is present [2, 10] and require histopathology of the entire CNS whose collection should be complete, which is labour intensive and requires specific material to be performed (**Figure 8**).

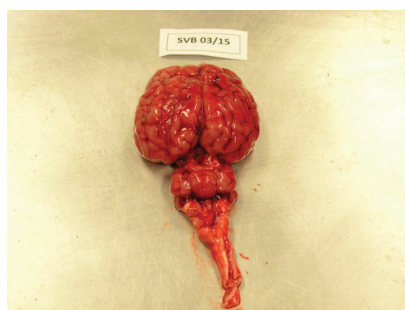


Figure 8. Complete collection of CNS of a newborn kid with 3 days.

Pathological diagnosis must be complemented by molecular genetics, serological and virological diagnosis [2, 3].

Dissemination of information about the disease, especially in the moment of the entrance into a given country, is crucial to alert professionals about the emergence of outbreaks, the data registration for each suspect or compatible case being crucial, as proposed in **Table 4**. In this registration, it is mandatory to include the date of occurrence, season and geographic region information, to relate with vector activity, since as in the winter, with too low temperatures for the vector activity, SBV may be soon ruled out [2].

Collection date (season)	Herd code	Parish	Municipality	Earmark mother	Species	Race	Gender	Abortion	Perinatal death	Stillborn
								Age of pregnancy	Age (days)	
Case 1										

Table 4. Data registration case identification proposal.

Biological fresh samples collected should include abortion material, foetus, placenta, umbilical cord (**Figure 9**) and maternal blood samples but, at the local, photos must be taken and description of gross lesions must be done, as proposed in **Tables 5** and **6**.

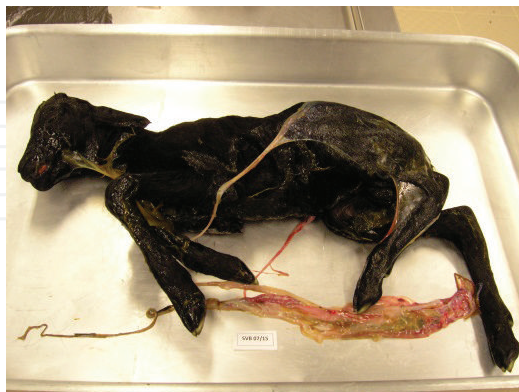

Figure 9. Complete abortion material collection, including foetus, placenta, umbilical cord of a stillborn lamb.

Arthrogryposis	Torticollis	Scoliosis	Kyphosis	Thickness of cranial bones	Flattened chest	Prognathism	Brachygnathia
Case 1							

Table 5. Musculoskeletal malformations registration.

Microcephaly	Cerebellar hypoplasia	Spinal cord hypoplasia	Lissencephaly	Hydranencephaly	Muscle atrophy	Other lesions	No gross lesions
Case 1							

Table 6. CNS malformations registration.

However, the shipment of biological fresh samples represents one of the greatest challenges in the diagnosis of SVB, once abortion is very common and the abortion products are found in the field, already in an advanced state of putrefaction and autolysis (**Figures 8** and **9**).

2. The vector of Schmallenberg virus in Portugal: lessons learned from the past and applications to the future

Blue tongue virus and African horse sickness virus (AHSV) are arboviruses that have circulated in Portugal in the past [11]. Both BTV and AHSV are double-stranded RNA viruses from the family Reoviridae that cause infectious, non-contagious illness, included in List A diseases by the Office International des Epizooties. BTV affects all species of ruminants [12], whereas

AHSV affects equines and occasionally dogs [10]. These arboviruses are transmitted by the bites of vector species of *Culicoides* [13]. Thus, so as with Schmallenberg, the incidence and geographical distribution of BTV and AHSV are associated to the distribution and abundance of *Culicoides*. *Culicoides imicola* constitutes the only field vector of AHSV while being the main vector of BTV in Europe and Africa [11].

Both BTV and AHSV have sporadically emerged into the southern European countries of the Mediterranean basin with the largest epidemic of BTV occurring between 1998 and 2002, and affecting Bulgaria, Greece, Turkey, Italy, Macedonia, Yugoslavia, Spain, France, Montenegro, Serbia and Bosnia and Herzegovina [14, 15]. Interestingly, BTV northern spread has shown novel territories of *C. imicola* expansion, which is believed to have been influenced by global warming [16].

Given the epizootic features of BTV, there was the constant need to record the distribution of *C. imicola* and to identify whether other potential vector species of the *Culicoides* genus are sufficiently distributed and in sufficient numbers to act as vectors for sustained arbovirus transmission, and also to map areas of higher risk for endemicity of BTV and AHSV due to the constant presence of adult *Culicoides* vectors [11]. These goals have for the past years been achieved by vector surveillance systems across Mediterranean Europe and bordering countries, thus producing detailed predictive risk maps of *Culicoides*-borne disease.

Discussing this topic shows the need to highlight two reports of *Culicoides* vector surveillance carried out in Portugal [11, 17], which mostly cover all territories and provide detailed information on the temporal distribution of *Culicoides* species in Portugal from 2000 to 2010, as independent entomological surveys.

Both studies have assumed similar sampling schemes, and divided mainland Portugal into 45 quadrats (or geographical units) each 50 km × 50 km so as to cover all territories in detail (Figure 10) and performed similar trapping strategies.

Capela et al. [11] sampled a total of 87 sites (including at least two livestock holdings or farms) within almost all geographical units. The authors took into account for variations in environmental conditions between sampling years, randomly dividing into two equal groups and sampling the first in 2000 and the second in 2001. Farms were included in the study if fulfilling the following criteria: located at least 10 km apart and 2.5 km from the coast, contained a minimum of five large livestock animals and did not use insecticides. Trapping was performed using Onderstepoort-type black light traps [18, 19] with 8-W UV light bulbs and down draught suction, set on each night between 1 h before sunset to approximately 08.00 h the following morning. Traps were set outside but within 25 m of livestock. Ribeiro et al. [17] sampled a total of 212 sites within all geographical units between 2005 and 2010. Farms were included in the study if fulfilling the following criteria: located at a minimum distance of 10 km from other sampled holdings and at least 2.5 km from the coast, and contain a minimum of five horses or ruminants (preferably cattle). Recruited farms were also not permitted to enforce insecticide application for the duration of the survey. Trapping was performed using Center for Disease Control (CDC) miniature light traps (model 1212; John W. Hock, Gainesville, FL, USA) with a

4-W UV light and a suction fan, set from dusk to dawn. Traps were set outside but within 30 m from livestock.

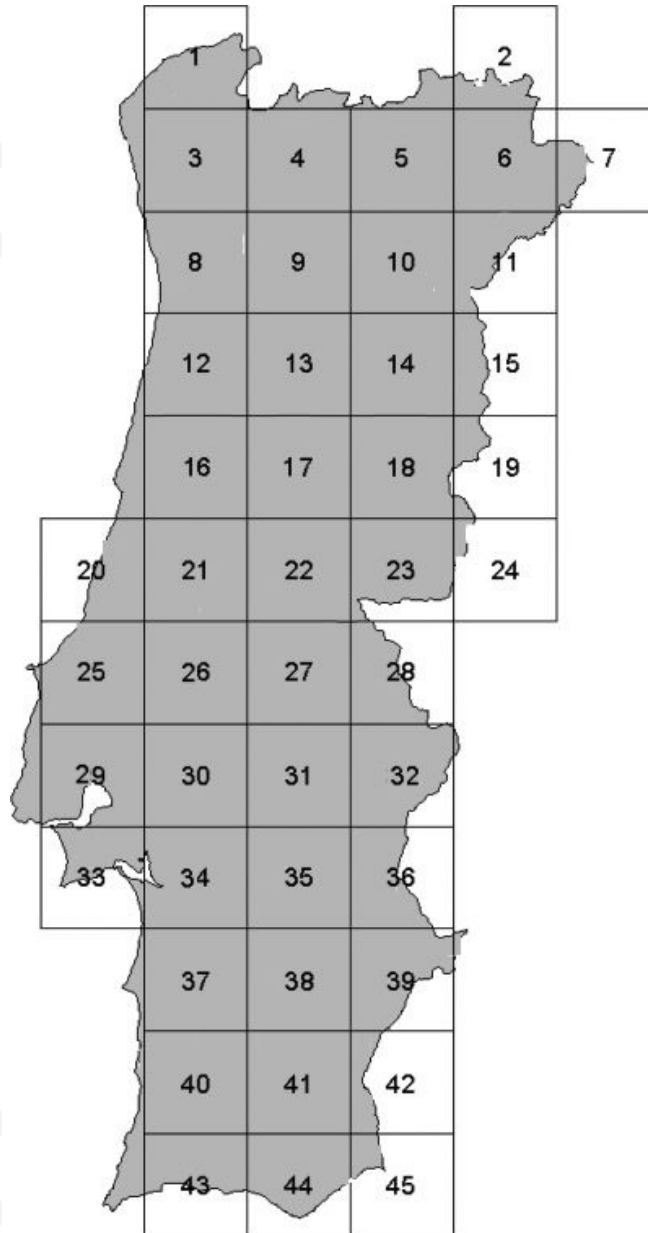


Figure 10. Sampling frames for *Culicoides* entomological surveys in Portugal since 2000 [11, 17].

2.1. Step one 2000–2001

During summer, 166 samples were collected containing 55,937 *Culicoides* spp. Individuals [11]. *Culicoides imicola* was the most frequently observed species, accounting for 66% of all individuals, followed by *C. obsoletus* (17.3%) and *C. pulicaris* (10.7%), and with *C. puncticollis* and other *Culicoides* complexes accounting for a very low proportion among all individuals. Despite being found at higher numbers, *C. imicola* was less prevalent across geographical units (found

in 64%) than either *C. obsoletus* (found in 82%) or *C. pulicaris* (found in 93%). *Culicoides imicola* was significantly more prevalent in south Portugal (91% of southern geographical units) than north Portugal (42% of northern geographical units). The most northern site positive for *C. imicola* in this study was at 41°38.4' N. *Culicoides imicola* was collected until the maximum altitude of 850 m above sea level. *Culicoides imicola* appeared to be absent from the north-west corner of Portugal and along the north-west coast. On the contrary, *C. imicola* was found to be highly abundant in the central eastern Portugal. During winter, 22,883 individuals of *Culicoides* spp. were collected with *C. pulicaris* accounting for 47% of the total *Culicoides* spp. catch, followed by *C. obsoletus* (6%) and *C. imicola* (1%).

2.2. Step two 2005–2010

Of the total 5800 catches, 3632 contained *Culicoides* species [17]. *Culicoides imicola* was the most frequently observed species, accounting for 74.8% of the individuals, followed by *C. obsoletus* (7.7%). The central region of the country accounted for the highest catches of *C. imicola*. *Culicoides imicola* was found to be less prevalent than *C. obsoletus* and comparing the distribution data with the one reported in 2000–2001 [20], *C. imicola* was found in five more geographical units, mainly in the northern regions. *Culicoides imicola* prevalence (per geographical unit) was higher in both central and southern regions when compared to the north. The most northern site positive for *C. imicola* in this study was at 41°92' N. *Culicoides imicola* was collected until the maximum altitude of 1694 m above sea level. *Culicoides imicola* was found to be highly abundant in the central region of the country. The largest collections of *C. imicola* occurred during the summer months of July, August and September, and the lowest during the winter months of December, January and February.

2.3. Overall analysis 2000–2010

When combined, both studies provide robust evidence that *C. imicola* has been the most prevalent *Culicoides* species in Portugal for the decade between 2000 and 2010, followed by members of the *Obsoletus* group, clearly showing the sustained presence of Schmallenberg virus vectors across the territory [11, 17].

Both studies also provide strong support to the notion that *C. imicola* is more prevalent in the central and south of Portugal, while the *Obsoletus* group is more widespread throughout the territory. Preferences in vector distribution have been related to different climate and habitat particularities, which are markedly distinct between the north and the central/south regions in Portugal [21]. Mainland Portugal geography is clearly demarcated by both the Atlantic at the north and the Mediterranean at the south with a borderline set across the territory and defined by Tagus, dividing the north with its forests, valleys and mountains, and the south with its vast lowlands where typical Mediterranean vegetation grows [17]. Climate is also diverse with maritime features and sharp differences between seasons in the north, and dry hot climate in the south. Higher prevalence of *C. imicola* in the south has been associated to the vector preference for breeding in moist nutrient-rich soils with high exposure to sun, typical features of southern regions of Portugal [17], and a preference not observed for *Obsoletus* group [20].

Both reports also show that over the 10-year time frame of 2000–2010, *C. imicola* has been detected more to the north but also at higher altitudes (850 m vs 1645 m) supporting that the vector is adapting and spreading to newer territories. Nonetheless, the authors report that the low numbers found suggest that these locations may be of borderline suitability, and the specimens caught could potentially have been wind-borne from more suitable regions [17, 22]. In conclusion, combined entomological data from both Capela et al. [11] and Ribeiro et al. [17] increase the understanding of the ecology of *Culicoides* vectors and *Culicoides* activity in Portugal. They provide important data on vectors that are known to have a significant impact on ruminants, in particular and within the scope of this review, of interest to Schmallenberg virus epidemiology in Portugal and in the support to design strategies to prevent disease spread in Portugal.

Author details

Fernando Esteves^{1,2}, João Rodrigo Mesquita^{1,2,3*}, Cármen Nóbrega^{1,2}, Carla Santos^{1,2}, António Monteiro^{1,2}, Rita Cruz^{1,2}, Helena Vala^{1,2,4} and Ana Cláudia Coelho⁵

*Address all correspondence to: jmesquita@esav.ipv.pt

1 Agrarian Superior School of Viseu, Polytechnic Institute of Viseu, Viseu, Portugal

2 Centre for the Study of Education, Technologies and Health (CI&DETS), Polytechnic Institute of Viseu, Viseu, Portugal

3 CIBIO/UP, Research Center in Biodiversity and Genetic Resources/University of Porto, Vairão, Portugal

4 Centre for the Research and Technology of Agro-Environmental and Biological Sciences (CITAB), Vila Real, Portugal

5 Department of Veterinary Sciences, University of Trás-os-Montes and Alto Douro, Vila Real, Portugal

References

- [1] Herder V, Hansmann F, Wohlsein P, Peters M, Varela M, Palmarini M, Baumgärtner W. Immunophenotyping of inflammatory cells associated with Schmallenberg virus infection of the central nervous system of ruminants. *PLoS One*. 2013;8(5):e62939.
- [2] Agerholm JS, Hewicker-Trautwein M, Peperkamp K, Windsor PA. Virus-induced congenital malformations in cattle. *Acta Vet Scand*. 2015;57:54.

- [3] Balseiro A, Royo LJ, Gómez Antona A, García Marín JF. First Confirmation of Schmallenberg Virus in Cattle in Spain: Tissue Distribution and Pathology. *Transbound Emerg Dis.* 2015, 62(5):e62–5. doi: 10.1111/tbed.12185.
- [4] Lievaart-Peterson K, Luttikholt S, Peperkamp K, Van den Brom R, Vellema P. Schmallenberg disease in sheep or goats: past, present and future. *Vet Microbiol.* 2015;181(1–2):147–53.
- [5] Peperkamp NH, Luttikholt SJ, Dijkman R, Vos JH, Junker K, Greijden S, Roumen MP, van Garderen E, Meertens N, van Maanen C, Lievaart K, van Wuyckhuise L, Wouda W. Ovine and bovine congenital abnormalities associated with intrauterine infection with Schmallenberg virus. *Vet Pathol.* 2015;52(6):1057–66. doi: 10.1177/0300985814560231 [Epub 2014 Nov 26].
- [6] van den Brom R, Luttikholt SJ, Lievaart-Peterson K, Peperkamp NH, Mars MH, van der Poel WH, Vellema P. Epizootic of ovine congenital malformations associated with Schmallenberg virus infection. *Tijdschr Diergeneeskd.* 2012;137(2):106–11.
- [7] Hahn K, Habierski A, Herder V, Wohlsein P, Peters M, Hansmann F, Baumgärtner W. Schmallenberg virus in central nervous system of ruminants. *Emerg Infect Dis.* 2013;19(1):154–155.
- [8] Varela M, Schnettler E, Caporale M, Murgia C, Barry G. Schmallenberg virus pathogenesis, tropism and interaction with the innate immune system of the host. *PLOS Pathog.* 2013;9(1):e1003133. doi: 10.1371/journal.ppat.1003133.
- [9] Herder V, Wohlsein P, Peters M, Hansman F, Baumgärtner W. *Vet Pathol.* 2012;49(4) 588–591.
- [10] Mellor PS, Boorman J. The transmission and geographical spread of African horse sickness and bluetongue viruses. *Ann Tropical Med Parasitol.* 1995;89:1–15.
- [11] Capela R, Purse BV, Pena I, Wittman EJ, Margarita Y, Capela M, Romão L, Mellor PS, Baylis M. Spatial distribution of *Culicoides* species in Portugal in relation to the transmission of African horse sickness and bluetongue viruses. *Med Vet Entomol.* 2003;17(2): 165–77.
- [12] Taylor WP. The epidemiology of bluetongue. *Rev Sci Tech Off Int Epizoot.* 1986;5:351–356.
- [13] Mellor PS, Boorman J, Baylis M. *Culicoides* biting midges, their role as arbovirus vectors. *Ann Rev Entomol.* 2000;45:307–340.
- [14] Mellor PS, Wittmann EJ. Bluetongue virus in the Mediterranean basin, 1998–2001. *Vet J.* 2002;164:20–37.
- [15] Baylis M. The re-emergence of bluetongue. *Vet J.* 2002;164:5–6.
- [16] Wittmann EJ, Baylis M. Climate change, effects on *Culicoides*-transmitted viruses and implications for the UK. *Vet J.* 2000;160:107–117.

- [17] Ribeiro R, Wilson AJ, Nunes T, Ramilo DW, Amador R, Madeira S, Baptista FM, Harrup LE, Lucientes J, Boinas F. Spatial and temporal distribution of *Culicoides* species in mainland Portugal (2005–2010). Results of the Portuguese Entomological Surveillance Programme. PLoS One. 2015;10(4):e0124019.
- [18] Nevill CG, Watkins WM, Carter JY, Munafu CG, et al. Comparison of mosquito nets, proguanil hydrochloride, and placebo to prevent malaria. BMJ. 1988;297(6645):401–403.
- [19] Venter GJ, Sweatman GK. Seasonal abundance and parity of *Culicoides* biting midges associated with livestock at Roma, Lesotho (Diptera: Ceratopogonidae). Onderstepoort J Vet Res. 1989;56(3):173–177.
- [20] Scientific Opinion of the Panel on Animal Health and Welfare on a request from the European Commission (DGSANCO) on Bluetongue. The EFSA Journal (2008) 735, 1–70.
- [21] Ramilo DW, Diaz S, Pereira da Fonseca I, Delécolle J- C, Wilson A, Meireles J, et al. First report of 13 species of *Culicoides* (Diptera: Ceratopogonidae) in mainland Portugal and azores by morphological and molecular characterization. PLoS One. 2012;7(4):e34896.
- [22] García-Lastra R, Leginagoikoa I, Plazaola JM, Ocabo B, Aduriz G, Nunes T, et al. Bluetongue virus serotype 1 outbreak in the Basque country (Northern Spain) 2007–2008. Data Support a Primary Vector Windborne Transport. Gubbins S, editor. PLoS One. 2012;7(3):e34421.

