

# We are IntechOpen, the world's leading publisher of Open Access books Built by scientists, for scientists

4,800

Open access books available

122,000

International authors and editors

135M

Downloads

Our authors are among the

154

Countries delivered to

TOP 1%

most cited scientists

12.2%

Contributors from top 500 universities



WEB OF SCIENCE™

Selection of our books indexed in the Book Citation Index  
in Web of Science™ Core Collection (BKCI)

Interested in publishing with us?  
Contact [book.department@intechopen.com](mailto:book.department@intechopen.com)

Numbers displayed above are based on latest data collected.  
For more information visit [www.intechopen.com](http://www.intechopen.com)



---

# The Use of Amniotic Membrane in the Management of Complex Chronic Wounds

---

Gregorio Castellanos, Ángel Bernabé-García,  
Carmen García Insausti, Antonio Piñero,  
José M. Moraleda and Francisco J. Nicolás

Additional information is available at the end of the chapter

<http://dx.doi.org/10.5772/64491>

---

## Abstract

Chronic wounds do not follow the usual wound healing process; instead, they are stuck in the inflammatory or proliferative phase. This is particularly evident in large, massive wounds with considerable tissue loss, which become senescent and do not epithelialize. In these wounds, we need to remove all the factors that prevent or delay normal wound healing. After that, soft tissue granulation is stimulated by local negative pressure therapy. Lastly, after the granulation is completed, the epithelialization process must be activated. Although a plethora of wound dressings and devices are available, chronic wounds persist as a unresolved medical concern. We have been using frozen amniotic membrane (AM) to treat this type of wounds with good results. Our studies have shown that AM is able to induce epithelialization in large wounds that were unable to epithelialize. AM induces several signaling pathways involved in cell migration and/or proliferation. Among those, we can highlight the mitogen-activated protein kinase (MAPK) and Jun N-terminal kinase (JNK) signaling pathways. Additionally, AM is able to selectively antagonise the anti-proliferative effect of TGF $\beta$  by modifying its genetic program on keratinocytes. The combined effect of AM on keratinocytes, promoting cell proliferation/migration and antagonising TGF $\beta$ -effect, is the perfect combination allowing chronic wounds to progress into epithelialization.

**Keywords:** soft-tissue chronic wounds, amniotic membrane, TGF- $\beta$ , epithelialization

---

## 1. Introduction

The evolution of knowledge about the biology of wound healing makes it possible to predict the sequence and prognosis of the events that occur in this complex process. However, there are wounds in which healing can be either prolonged over time or not fully achieved [1, 2].

Therefore, The keys to providing adequate and efficient treatment involve identifying, as soon as possible, the combination of either internal or external factors that contribute to the complexity of the wound and affect the healing process, and to detect at an early stage when it is likely that a wound would be slow or difficult to heal.

The actions undertaken should be aimed at reducing the aspects that lead to complexity, including factors related to the patient, the wound, relationships with healthcare personnel, and available resources. Only by assessing and understanding the interaction between these factors and their effect on healing will it be possible to develop efficient and appropriate strategies for improving results. Similarly, certain characteristics of the wound, such as its anatomical location, time duration, size, depth, and the state of the wound bed, are correlated with adequate healing [3–5].

The presence of necrotic tissue, crusts, slough, or foreign bodies in the wound bed, which are all obstacles for wound assessment, can lead to a delay in healing, and they can also be a focus of infection. Therefore, it is important to provide frequent, extensive, and efficient debridement until healthy tissue is found [6]. There are other situations that can have an influence and cause healing to fail, such as ischemia. Poor perfusion deprives tissue of an efficient oxygen and metabolic exchange, and causes an increase in vascular permeability, leukocyte retention, synthesis and the liberation of oxygen free radicals and proteolytic enzymes [7]. Inflammation in chronic wounds brings about a prolongation in healing time, resulting in an exacerbated inflammatory reaction, which in turn causes the hyperproduction of pro-inflammatory cytokines and proteolytic enzymes. This activity is combined with a decrease in the secretion of metalloproteinase tissue inhibitors, and it intensifies as the wound bed pH alters. As a consequence, we find that in the wound bed there is a sustained inflammation with matrix degradation, a limited bioavailability of growth factors and intense fibroblast aging, all of which reduce tissue repair, cell proliferation, and angiogenesis [8, 9].

In the same way, chronic wounds are characterized by the presence of one or more bacterial strains, with antibiotic-resistant microorganisms, and the presence of biofilms within which the bacteria are protected against the action of the silver-based antimicrobials [10–13].

The initial response to treatment is indicative of the viability of the tissue and its capacity to heal. When a patient's wound does not heal in the planned period of time using conventional treatment, it is essential to reassess the patient and modify the therapeutic guidelines [14, 15].

Thus, tissue wound healing usually follows a predictable sequence, although in some cases, it is prolonged over time or it is never achieved. The wound healing process is the result of a complex interaction between the patient and wound factors, the treatment adopted, and the skills and knowledge of healthcare professionals. Only by carrying out a detailed initial

assessment and repeated treatment assessment will it be possible to identify the factors that contribute to the complexity of the wound and to assess its potential state. The challenge for professionals is to utilize the most efficient therapeutic strategies at the right time and in the most cost-effective way, in order to reduce the complex nature of wounds, to treat the symptoms, and whenever possible, to achieve wound healing.

## **2. How should chronic and complex soft-tissue wounds be managed?**

### **2.1. Management and treatment strategies**

Chronic and complex soft-tissue wounds usually involve difficult healing, which means that they require an appropriate management-treatment strategy using a comprehensive and dynamic approach, applying new therapies to confront this old problem: wound healing [16]. In order to carry out this comprehensive approach, we should take into account the complex nature of the wound and its healing, its relationship with psychosocial factors and delays in wound healing, together with the economic cost for the patient, family, community, and the healthcare system. The steps to follow in order to achieve this approach should take into account the complete assessment of the patient, the control of causal factors, general healthcare, and the preparation of the wound bed.

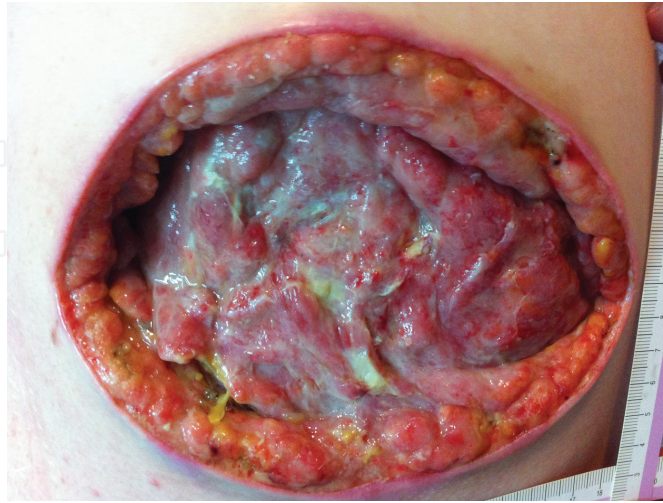### **2.2. Preparation of the wound bed**

The preparation of the wound bed is an essential and dynamic process that provides an appropriate framework for a structured approach to wound management. This notion stresses a comprehensive and systematic approach with the aim of assessing and eliminating barriers to the normal wound healing process. It develops the appropriate treatment strategies to be directed at the patient in general and for treating the underlying condition causing the wound. Its objective is to create an optimum healing setting, a well-vascularized wound, with a stable and balanced bed in terms of exudate production, aimed at reducing scar healing time and facilitating the efficiency of other therapeutic measures. The wound bed should be prepared in each phase of the wound healing process following an agreed-upon procedure.

The “Tissue, Inflammation-infection, Moisture, Edge” (T.I.M.E.) scheme, proposed by the European Wound Management Association (EWMA), is based on the research of the International Wound Bed Preparation Advisory Board (IWBPAB), which established an algorithm through the development of the acronym T.I.M.E., whose objective is to describe the characteristics of chronic wounds during wound bed preparation. Following on from this, the concept was updated by placing emphasis on the treatment of the cause of the wound and general patient factors during treatment, before dealing with local wound factors. This algorithm consists of four components that cover the different physiopathological alterations present in chronic wounds: the management and conditioning of non-viable tissue, the monitoring of inflammation and infection, the disequilibrium of moisture due to excess exudate, and the stimulation and progression of the wound edges. So we can see that the T.I.M.E. framework



involves the overall strategies that can be applied to the management of different kinds of wound with the aim of maximizing the ability to heal wounds [16–18] (**Figure 1**).



**Figure 1.** Complex and traumatic soft-tissue wound. Management and treatment of wound bed.

Wound treatment is initiated with a hydrodynamic washing using 0.9% saline solution at room temperature, with a 1–4 kg/cm effective washing pressure, without any damage being caused (a 20-ml syringe, with a 0.9-mm-diameter catheter), and the surrounding area is washed with a soapy antiseptic solution consisting of chlorhexidine digluconate.

For the monitoring of the non-viable tissues (necrotic tissue, crust, slough, and foreign bodies), episodic or continuous debridement is carried out until healthy tissue is found. It can be surgical, using tangential hydrodissection (Versajet™Plus, Smith & Nephew, London, United Kingdom); enzymatic, applying exogenous enzymes locally (collagenase, fibrolysin, trypsin, or chymotrypsin); chemical (cadexomer iodine); autolytic (due to the conjunction of three factors: hydration of the bed, fibrinolysis and the action of the endogenous enzymes on the devitalized tissue); or osmotic (hyperosmotic solutions). On occasions, an instillation therapy can also be used (VeraFlo™, KCI, Acelity LPI, San Antonio, TX) either in deep wounds with a viscous exudate or in uncontrolled infections on prosthetic materials, in order to eliminate the biofilm, reduce the pain, and reactivate healing. A noninvasive treatment option, for the debridement of chronic wounds, is low-frequency guided ultrasound [3].

In the management of the bacterial load (a contaminated or colonized lesion, with critical or infected colonization), foci of local and/or systemic infection have to be removed, which is why it is necessary to clean and debride the wound; take a wound culture; monitor the wound proteases; and use topical antimicrobials (silver, cadexomer iodine), systemic antibiotics according to the antibiogram data, anti-inflammatory drugs, and protease inhibitors if required.

It is important to monitor the exudate and achieve the equilibrium in the moisture, given that a dry wound makes it difficult for cell migration and exudate encourages infection and macerates the perilesional skin area. We should be aware that scarring is faster with wounds

in an optimally moist environment in which the physiological and atmospheric conditions of the wound bed are maintained, thus fostering basal keratinocyte migration. A moist environment also prevents cell desiccation, encourages cell migration, promotes angiogenesis, stimulates collagen synthesis, and facilitates intercellular communication. A moist wound environment preserves a slightly acid pH and a low oxygen tension on the surface of the wound [18–20].

Thus, the edges of the wound do not advance because there are keratinocytes that do not migrate, senescent cells, and alterations in the extracellular matrix secondary to the disequilibrium in protease activity.

### 2.3. Clinical protocols

The preparation of the wound bed requires specific management protocols, which can be grouped into three sections following the T.I.M.E. procedure:

- Nonsurgical debridement with moisture monitoring and dressing every 48 h (**Table 1**).
- Local infection with moisture monitoring and dressing every 72 h (**Table 2**).
- A granulation phase with moisture monitoring and dressing every 72 h (**Table 3**).

---

#### Protocol 1: (T/M= Tissue and moisture)

-Non-viable tissue and moisture monitoring

-Non-surgical debridement

-Dressing every 48 h

---

-Type of wound	-Necrotic tissue -Low exudate	-Sloughy tissue -Moderate exudate	-Infected sloughy tissue -High exudate
-Debridement	-Collagenase + hydrogel	-Collagenase	-Cadexomer iodine + alginate
-Moist dressing	-Hydrocellular with acrylic adhesive or silicone adhesive	-Hydrocellular with acrylic adhesive or silicone adhesive	-Hydrocellular with acrylic adhesive or silicone adhesive

---

**Table 1.** Preparing the wound bed: management protocol (T/M).

---

#### Protocol 2: (I/M = Infection and moisture)

-Infection and moisture monitoring

-Wounds with local infection

-Dressing every 72 h

---

-Type of wound	-Infection -Low exudate	-Infection -Moderate exudate	-Infection -High exudate
-Decrease in bacterial load	-Nanocrystalline silver or -Silver-impregnated activated carbon+ hydrogel	-Nanocrystalline silver or -Silver-impregnated activated carbon	-Nanocrystalline silver or -Silver-impregnated activated carbon + alginate
-Moist dressing	-Hydrocellular with acrylic adhesive or silicone adhesive	-Hydrocellular with acrylic adhesive or silicone adhesive	-Hydrocellular with acrylic adhesive or silicone adhesive

---

**Table 2.** Preparing the wound bed: management protocol (I/M).

**Protocol 3: (E/M = Edges and moisture)****-Epithelialization of edges and moisture monitoring****-Wounds in the granulation phase****-Dressing every 72 h**

-Type of wound	-Granulation tissue -Low or moderate exudate	-Granulation tissue -High exudate
-Granulation	-Collagen with silver protease modulator matrix or -Powder collagen	-Collagen with silver protease modulator matrix or -Powder collagen + alginate
-Moist dressing	-Hydrocellular with acrylic adhesive or silicone adhesive	-Hydrocellular with acrylic adhesive or silicone adhesive

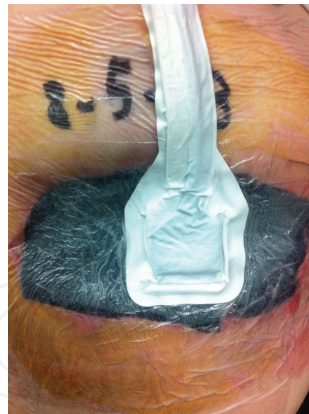**Table 3.** Preparing the wound bed: management protocol (E/M).

After finalizing the preparation of the wound bed, the wound remains open ready for its closure by secondary intention with granulation tissue and the re-establishment of the epidermis. At this point, the surgeon comes across two new problems: how to granulate the wound, and afterwards, how to epithelialize it.

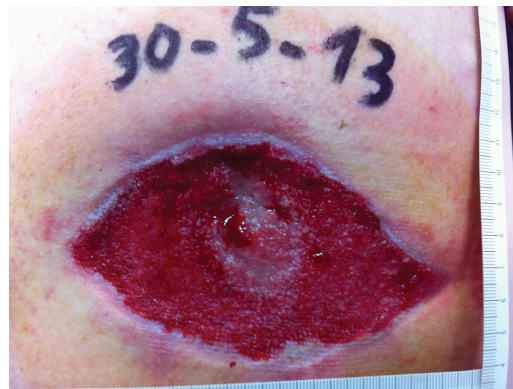**2.4. Wound granulation using negative topical pressure therapy**

For the granulation, we use a noninvasive topical negative pressure wound therapy (NPWT) (**Figure 2**), using aspirated drainage to eliminate the secretions, facilitate the closure and prevent complications. Its scientific fundamentals and physiopathology are based on the application of mechanical stress on the tissues, by creating a negative pressure on the surface of the wound [21]. The effect of the macrotension on the tissues is carried out using a sponge dressing (polyurethane-polyvinyl alcohol), with open pores, that contract under the negative pressure, bringing the edges closer together [22], eliminating the exudate, the non-viable tissue, and the soluble wound healing inhibitors (cytokines and matrix metalloproteinases) [23]. Other effects are a reduction in the edema, an increase in neutrophils and monocytes on the bacterial load and an improvement in local perfusion [24]. The effect of microtension, at the cell level, triggers cell stretching, which increases fibroblasts, the formation and division of new cells and the rapid growth of granulation tissue [25], the migration of fibroblasts to the area of the wound (displacing new cells to its surface), the formation of new blood vessels [26], and the formation of granulation tissue through mitosis stimulation. In this way, moist healing of the wound helps wound debridement (**Figure 3**).

The NPWT is contraindicated when either the wound has not been well explored, it has necrotic tissue with eschar or it has weakened blood vessels due to irradiation or suture. Also, NPWT is contraindicated in case of intestinal anastomosis, exposed nerves, the presence of tumors or untreated osteomyelitis. Equally, it is not advisable for either enterocutaneous or enteroatmospheric fistulas. Finally, active bleeding wounds and/or patients treated with anticoagulants are not suitable for NPWT treatment.



**Figure 2.** Complex and traumatic soft-tissue wound. Treatment with TNP therapy.



**Figure 3.** Complex and traumatic soft-tissue wound. Completed granulation after TNP therapy.

## 2.5. Epithelialization of the chronic and complex soft-tissue wounds

A large variety of wound coverings and procedures have become available over the past two decades, including several types of synthetic dressings and allo-skin or auto-skin substitutes, although their cost is too high for routine clinical practice [27, 28]. New technologies involving growth factors and bioengineered tissues are relatively new and have produced relatively good results; however, they are quite expensive.

## 2.6. Amniotic membrane and wound healing

Amniotic membrane (AM), the innermost layer of the placenta, has a fetal origin and can easily be separated from the placenta by blunt dissection. AM, due to its special structure, biological properties and immunological characteristics, is a tissue of particular interest as a biological dressing. AM exhibits low immunogenicity and well-documented reepithelialization effects. Moreover, AM shows anti-inflammatory, antifibrotic, antimicrobial, analgesic and nontumorigenic properties. This diversity of its effects is related to its capacity to synthesize and release biologically active molecules including cytokines and signaling factors such as tumor necrosis

factor (TNF)- $\alpha$ , transforming growth factor (TGF)- $\alpha$ , TGF- $\beta$ , basic fibroblast growth factor (b-FGF), epidermal growth factor (EGF), keratinocyte growth factor (KGF), hepatic growth factor (HGF), interleukin-4 (IL-4), IL-6, IL-8, natural inhibitors of metalloproteases,  $\beta$ -defensins, and prostaglandins among others [29–31]. Moreover, AM is a biomaterial that can be easily obtained, processed, and transported. On the other hand, AM may function as a substrate where cells can easily proliferate and differentiate [32]. When compared to skin transplantation, AM treatment offers considerable advantages. Its application does not produce rejection because it has low immunogenicity and does not induce uncontrolled proliferation [33]. All these effects are related to its capacity for the production and release of biologically active substances (see above).


AM has been applied in medicine for more than 100 years. In 1910, Davis [34] reported a comprehensive review of 550 cases of skin transplantation to various types of burns and wounds using natural AM obtained from labor and delivery at the Johns Hopkins University. In 1913, Sabella [35] and Stern [36] separately reported on the use of preserved AM in skin grafting for burns and ulcers. Since then, there have been several reports of the uses of AM in the treatment of wounds of different etiologies and other applications: first, in the reconstructive surgery of different tissues and organs including the mouth, tongue, nasal mucosa, larynx, eardrum, vestibule, bladder, urethra, vagina, and tendons [37–43]; second, as a peritoneum substitute in reconstruction procedures of pelvic exenteration surgery; third, in adherence prevention in the abdomen and pelvic surgery; and finally, as a covering of onphaloces and the like [34–37, 44].

In ophthalmology, the use of AM was reported for the first time in 1940 by De Rötth, who used fresh fetal membranes, namely amnion and chorion, at the ocular surface as a biological dressing in the management of conjunctival alterations [45]. Later, Sorsby et al. [46] used preserved AM as a temporary coating in the treatment of acute caustic ocular lesions. Even though the results were favorable, its use was abandoned for almost four decades. In 1995, with the reconstitution assays of rabbit corneas with limbic disorder using human preserved AM, by Kim and Tseng [47], there was a renewed widespread interest in the use of AM in ophthalmology. Several publications appeared related to the efficacy of the AM in various ocular surface conditions and in diseases like epidermolysis bullosa [44, 48, 49]. Nowadays, AM is a resource widely used in ophthalmology [49–51] and to a lesser degree in the treatment of wounds, burns lesions, and chronic ulcers of the legs [48, 52–54] and in other surgical and nonsurgical procedures [38–43, 55–59].

### 3. Using AM in chronic wound healing

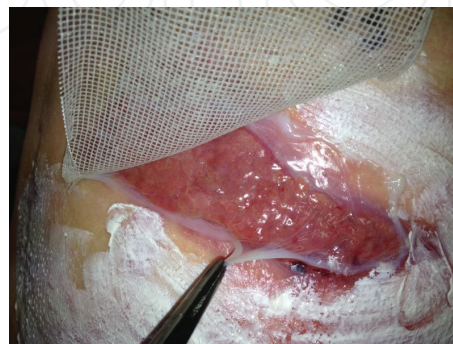
Once granulation of the wound is finalized, the process of epithelialization by using AM can be initiated. The source of AM for wound healing is donated placenta. AM has been used for wound healing either as intact AM without epithelium removal or as denuded AM, without the epithelium, [60, 61]. In some cases, AM was used fresh, and in others AM was preserved. Nowadays, it is known that the use of fresh AM is not practical for clinical use [62]. Methods



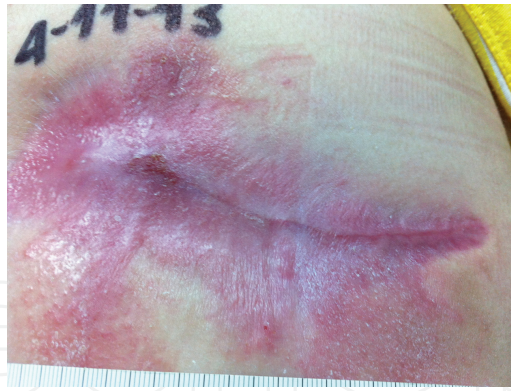

**Figure 4.** Amniotic membrane fixed to sterile petrolatum gauze (Tulgrasum®) ready for its application.

to remove the epithelium or preserve AM are very diverse and exceed the scope of this chapter. In our case, the placenta is obtained from an uncomplicated elective cesarean of a healthy mother, excluding patients with positive human immunodeficiency virus (HIV), hepatitis B virus (HBV), and hepatitis C virus (HCV) serology. Using an aseptic technique, AM is separated from the subjacent chorion by blunt dissection and stored in saline solution or phosphate buffered saline with antibiotics (cotrimoxazol, tobramycin, vancomycin, and amphotericin B). In this solution, AM is taken to the clean room [55]. Then, its processing, under sterile conditions, is carried out in a type II vertical laminar flow cabinet (HEPA filter). Then it is cut up into fragments measuring  $10 \times 10\text{cm}$ , which are then placed on a sterile scaffold of sterile petrolatum gauze (Tulgrasum®) and fixed with silk points at their ends (**Figure 4**). Finally, individual fragments are introduced into a bag with cryopreservative solution to freeze them in liquid nitrogen. These fragments cannot be used in the clinical practice until 3 months have passed, when there is a certainty that their donor has not been seroconverted to HIV, HBV, or HCV. After its defrosting in a  $37^\circ\text{C}$  bath, they are taken back to the surgical area and are applied on the wounds of the selected patient [55] (**Figures 5 and 6**).



**Figure 5.** Complex and traumatic soft-tissue wound. Application of the amniotic membrane.



**Figure 6.** Complex and traumatic soft-tissue wound. Complete epithelialization after amniotic membrane treatment.

### 3.1. Molecular mechanisms underlying AM-induced skin reepithelialization

The molecular mechanisms underlying AM-induced skin reepithelialization are largely unknown. AM might have a wound healing effect by improving keratinocyte migration from the wound edge and stimulating its differentiation, thereby generating an intact epithelium [63]. Niknejad et al. [64] reflected that the stimulatory effect on epithelialization from the wound bed and/or the wound edge is facilitated by growth factors and progenitor cells released by AM. In addition, it has been described that the preservation of the integrity of the basement membrane and stromal matrix increases the healing potency of AM and is crucial in promoting a fast reepithelialization [65].

Insausti et al. [55] had previously worked on HaCaT cells, a spontaneously immortalized human keratinocyte cell line, as a model to comprehend the molecular consequences of AM application on human wounds [66]. This research showed that HaCaT cells exhibited different molecular reactions upon stimulation with AM that were attributed to the effects of soluble AM-released factors on HaCaT cells [55]. The application of AM to keratinocytes induced the activation of the phosphorylation of ERK1/2, JNK1/2, and p38 [55]. Also, AM-conditioned medium induced similar responses, suggesting a trans-effect of AM on the triggering of these events. Additionally, the authors reported that HaCaT cells stimulated with AM showed an increased expression of *c-JUN*. Members of the AP1 family had been involved in keratinocyte migration and the wound healing process [67–70]. AM induced the phosphorylation of Jun N-terminal kinase (JNK)1 and two kinases in HaCaT cells [55]; JNK1 is a positive regulator of *c-JUN*, contributing to its phosphorylation and stabilization [71, 72]. Finally, the expression of *c-Jun* in the wounds treated with AM was very strong, and particularly evident at the basal epithelium near the leading edge and at the dermal leading edge or keratinocyte tongue, indicating that *c-Jun* expression might be an important event for epithelialization occurring at the AM-stimulated wound borders [55].

### 3.2. Chronic wound healing, AM, and TGF- $\beta$

Wound fluid derived from chronic venous leg ulcers is rich in pro-inflammatory cytokines such as TNF- $\alpha$ , interleukin-1 $\beta$  (IL-1 $\beta$ ), and TGF- $\beta$ 1 [73]. In addition, the quantities of these



cytokines drop as the chronic wound commences to heal, denoting a strong correlation between non-healing wounds and an increased level of pro-inflammatory cytokines [74]. TGF- $\beta$  has a critical role in regulating multiple cellular responses that occur in all phases of wound healing [75]. Of the many cytokines shown to influence the wound healing process, TGF- $\beta$  has the broadest spectrum of action because it affects the behavior of a wide variety of cell types and mediates a diverse range of cellular functions [76]. Platelets are thought to be the primary source of TGF- $\beta$  at the wound site; also, activation of latent TGF- $\beta$  occurs immediately after wounding [75]. The TGF- $\beta$  signaling pathway is considered as a promising target for the treatment of many pathological skin conditions including chronic non-healing wounds [75]. Keratinocytes, fibroblasts, and monocytes are among the targeted cells in the TGF- $\beta$  management of the wound [76]. Monocytes/macrophages and fibroblasts then contribute to autocrine-perpetuated high concentrations of TGF- $\beta$  at the wound site [76].

TGF- $\beta$  exerts its effect on cells by increasing the phosphorylation of members of the receptor activated (R-)Smad family (Smad2 and 3). Additionally, non-Smad pathways are also activated, including the extracellular-signal-regulated kinase (ERK), JNK, and p38 mitogen-activated protein (MAP) kinase pathways, the tyrosine kinase Src, and phosphatidylinositol 3-kinase (PI3K) [77, 78]. Once receptor-induced phosphorylation has taken place, R-Smads form complexes with the common-mediator (Co-) Smad4, which are translocated to the nucleus [79] where they, in cooperation with other transcription factors, co-activators, and corepressors, regulate the transcription of specific genes [80].

The effects of TGF- $\beta$  on full-thickness wound reepithelialization have been studied in a transgenic mouse. The study in the ear mouse model suggests that TGF- $\beta$  has an inhibitory effect on epithelialization when the wound involves all the layers of the skin [81]. Also, the overexpression of TGF- $\beta$ , at the epidermis level, causes a decrease in reepithelialization [82, 83]. Abolishing part of the TGF- $\beta$  signaling pathway has been suggested as a way to improve wound healing, so abolishing part of the TGF- $\beta$ -stimulated Smad pathways may enhance wound healing and benefit the effect of TGF- $\beta$  signaling over matrix synthesis by fibroblasts, for instance [76]. TGF- $\beta$  causes the growth arrest of epithelial cells. The mechanisms, which differ somewhat between different cell types, involve the inhibition of the expression of the transcription factor Myc and members of the Id family, and the transcriptional induction of the cell cycle inhibitors *CDKN2B* (*p15*) and *CDKN1A* (*p21*) [84].

In order to further unravel the molecular mechanism by which AM may contribute to the epithelialization and wound border proliferation in chronic post-traumatic wounds, Alcaraz et al. [85] analyzed the association between TGF- $\beta$  signaling and AM regulation in wound healing using keratinocytes. Strikingly, AM was capable of attenuating the TGF- $\beta$ -induced phosphorylation of Smad2 and Smad3 in HaCaT cells. Both the strength and duration of TGF- $\beta$  signaling, expressed as sustained phosphorylation of Smads, are essential to achieve proper cell responses to TGF- $\beta$ ; the impossibility to do so produces a loss of the cell cycle arrest in response to TGF- $\beta$  [86]. AM attenuates TGF- $\beta$ -induced Smad2 and Smad3 phosphorylation and hence attenuates *CDKN2B* (*p15*) and *CDKN1A* (*p21*) expression [85], which has been connected to cell cycle regulation [86]. Therefore, the presence of AM counteracts the cell cycle arrest induced by TGF- $\beta$  on keratinocytes, releasing them from the restrain imposed by TGF-

β [85]. The effect of AM on TGF-β-regulated genes is not indiscriminate, and not all genes are affected by the presence of AM. Interestingly, genes that positively participate in wound healing such as *SNAI-2* and *PAI-1* were synergistically up-regulated by the presence of AM and TGF-β [85]. Finally, the expression of c-Jun was maximal when both TGF-β and AM were present in either HaCaT or primary keratinocyte cells [85].

It has been suggested that AM might exert its wound healing effect by increasing keratinocyte migration speed from the wound edge [63]. Growth factors and progenitor cells released by AM [64] are supposed to mediate the epithelialization stimulatory effect. AM induces cell migration in a wound healing assay in keratinocytes and mesenchymal cells [85]. Furthermore, in keratinocytes, inhibition of cell proliferation with mitomycin C, affected the migrating properties of AM. In the same study, the use of JNK1 inhibitors prevented AM-induced cell migration in both cell types. Moreover, a closer inspection of the margins of the scratch wound healing assays showed a high expression of c-JUN in the AM-stimulated cells engaged in the migratory wave. The AM-induced high expression of c-JUN at the wound border was prevented by inhibitors SP600125 and PD98059, which is consistent with the fact that AM induces the activation of a signaling cascade that produces the phosphorylation of ERK1/2 and JNK1/2. A local increase of c-JUN was observed in the patient wound border when the wound had been treated with AM. This is coherent with the AM effect on cell migration. In fact, in the examination of patient wound borders a few days after AM application, a clear proliferation/migration was observed [85]. This correlates well with the robust expression of c-Jun at the wound border, which is particularly robust at the *stratum basale* of the epidermis that overlaps the keratinocyte tongue, the area where the migration of keratinocytes happens to epithelialize the wound [85]. Additionally, in that investigation, the authors revealed that the application of AM promotes healing in chronic wounds by refashioning the TGF-β-induced genetic program, stimulating keratinocyte migration and proliferation [85]. Additionally, there might be a synergy of AM and TGF-β signaling for the resolution of chronic wounds [85, 87]. Thus, stimulation of keratinocytes with both AM and TGF-β was synergistic when compared to both stimulus being added separately [85]. Moreover, the treatment of cells with TGF-β signaling inhibitors hampered the effect of AM, indicating that both AM and TGF-β signaling positively contribute to cell migration [87]. The down-regulation of Smad3 has been suggested as a possible way of improving wound healing [76]. In this sense, the effect of R-Smads, Smad2 or 3, seems to be different given that the overexpression of Smad2 increased AM-induced cell migration while the overexpression of Smad3 prevented it [87]. Notably, the ability of keratinocytes to sense TGF-β through Smad3 prevents the cell proliferation of keratinocytes and consequently prevents wound healing resolution when the levels of TGF-β are high [88].

Presently, in order to evaluate the effect of AM on chronic post-traumatic wounds, a clinical trial is being conducted in our hospital, with exceptional results. The TGF-β-stimulated Smad pathway has also been involved in the production of fibrosis and inflammation in response to TGF-β. Thus, interfering with TGF-β signaling may be a good way of interfering with fibrosis and improving the evolution of wound healing [76]. In different experimental models, the application of AM is able to ameliorate fibrosis [89–92]. Currently, we are exploring whether the application of AM is able to reduce fibrosis and inflammation in chronic wounds.

## 4. Summary

To summarize, AM is a biological dressing that stimulates proper epithelialization in chronic wounds. It has several advantages; among them, it is economical, easy to obtain, and in endless supply. Additionally, AM can be cryopreserved at a low temperature while preserving all its biological functions. Finally, it can be used as a treatment in the outpatient clinic, which reduces costs even more. Thus, AM must be taken into account as a consolidated treatment option for chronic wounds.

## Acknowledgements

We would like to thank other members of the different laboratories who contribute in our daily task of increasing our knowledge of AM and chronic wound healing. Ana M García, María D. López and Mónica Rodríguez working in the clean room and providing AM. Paola Romencín, José E. Millán, David García and Noemi Marín, working on AM and animal models, and Miguel Blanquer, working in the cell therapy group. Antonia Alcaraz, Catalina Ruiz-Cañada, Ania Mrowiec, Eva M. García, and Sergio Liarte working on molecular aspects of AM and wound healing using cell models. This work was supported by a grant from the Fundación Séneca de la Región de Murcia and a grant from the Instituto de Salud Carlos III, Fondo de Investigaciones Sanitarias. Plan Estatal I+D+i and the Instituto de Salud Carlos III-Subdirección General de Evaluación y Fomento de la Investigación (Grant no.: PI13/00794) [http://www.isciii.es/Fondos FEDER \(ERDF funds\) http://ec.europa.eu/regional\\_policy/es/funding/erdf/](http://www.isciii.es/Fondos FEDER (ERDF funds) http://ec.europa.eu/regional_policy/es/funding/erdf/). We are indebted to the Hospital Clínico Universitario Virgen de la Arrixaca for strongly supporting this research.

## Author details

Gregorio Castellanos<sup>1</sup>, Ángel Bernabé-García<sup>2</sup>, Carmen García Insausti<sup>3</sup>, Antonio Piñero<sup>1</sup>, José M. Moraleda<sup>3</sup> and Francisco J. Nicolás<sup>2\*</sup>

\*Address all correspondence to: [Franciscoj.nicolas2@carm.es](mailto:Franciscoj.nicolas2@carm.es)

1 Surgery Service, Virgen de la Arrixaca University Clinical Hospital, El Palmar, Murcia, Spain

2 Molecular Oncology and TGF $\beta$ , Research Unit, Virgen de la Arrixaca University Hospital, El Palmar, Murcia, Spain

3 Cell Therapy Unit, Virgen de la Arrixaca University Clinical Hospital, El Palmar, Murcia, Spain

## References

- [1] Troxler M, Vowden K, Vowden P. Integrating adjunctive therapy into practice: the importance of recognising 'hard-to-heal' wounds. *World Wide Wounds* (online) 2006; available from URL: <http://www.worldwidewounds.com/2006/december/Troxler/Integrating-Adjunctive-Therapy-Into-Practice.html>.
- [2] Falanga V, Saap LJ, Ozonoff A. Wound bed score and its correlation with healing of chronic wounds. *Dermatol Ther*. 2006;19(6):383–90.
- [3] Doerler M, Reich-Schupke S, Altmeyer P, Stucker M. Impact on wound healing and efficacy of various leg ulcer debridement techniques. *J Dtsch Dermatol Ges*. 2012;10(9):624–32.
- [4] Margolis DJ, Berlin JA, Strom BL. Risk factors associated with the failure of a venous leg ulcer to heal. *Arch Dermatol*. 1999;135(8):920–6.
- [5] Henderson EA. The potential effect of fibroblast senescence on wound healing and the chronic wound environment. *J Wound Care*. 2006;15(7):315–8.
- [6] Steed DL. Clinical evaluation of recombinant human platelet-derived growth factor for the treatment of lower extremity diabetic ulcers. Diabetic Ulcer Study Group. *J Vasc Surg*. 1995;21(1):71–8; discussion 9–81.
- [7] Mogford J., Mustoe T. Experimental models of wound healing. In: Falanga V., editor. *Cutaneous Wound Healing*. London: Martin Dunitz Ltd.; 2001. p. 109–22.
- [8] Medina A, Scott PG, Ghahary A, Tredget EE. Pathophysiology of chronic nonhealing wounds. *J Burn Care Rehabil*. 2005;26(4):306–19.
- [9] Shukla VK, Shukla D, Tiwary SK, Agrawal S, Rastogi A. Evaluation of pH measurement as a method of wound assessment. *J Wound Care*. 2007;16(7):291–4.
- [10] Bowler PG, Duerden BI, Armstrong DG. Wound microbiology and associated approaches to wound management. *Clin Microbiol Rev*. 2001;14(2):244–69.
- [11] Ngo Q, Vickery K, Deva AK. PR21 Role of Bacterial Biofilms in Chronic Wounds. *ANZ Journal of Surgery*. 2007;77:A66.
- [12] Percival SL, Bowler PG, Dolman J. Antimicrobial activity of silver-containing dressings on wound microorganisms using an in vitro biofilm model. *Int Wound J*. 2007;4(2):186–91.
- [13] Bjarnsholt T, Kirketerp-Moller K, Kristiansen S, Phipps R, Nielsen AK, Jensen PO, et al. Silver against *Pseudomonas aeruginosa* biofilms. *APMIS*. 2007;115(8):921–8.
- [14] Attinger CE, Janis JE, Steinberg J, Schwartz J, Al-Attar A, Couch K. Clinical approach to wounds: débridement and wound bed preparation including the use of dressings and wound-healing adjuvants. *Plast Reconstr Surg*. 2006;117(7 Suppl):72S–109S.

- [15] Baharestani M, de Leon J, Mendez-Eastman S, et al. Consensus statement: a practical guide for managing pressure ulcers with negative pressure wound therapy utilizing vacuum-assisted closure-understanding the treatment algorithm. *Adv Skin Wound Care*. 2008(21(Suppl 1)):1–20.
- [16] EWMA, editor. *Position Document: Wound Bed Preparation in Practice*. (EWMA). London: MEP Ltd.; 2004.
- [17] Falanga V. Classifications for wound bed preparation and stimulation of chronic wounds. *Wound Repair Regen*. 2000;8(5):347–52.
- [18] Sibbald RG, Williamson D, Orsted HL, Campbell K, Keast D, Krasner D, et al. Preparing the wound bed--debridement, bacterial balance, and moisture balance. *Ostomy Wound Manage*. 2000;46(11):14–22, 4–8, 30–5; quiz 6–7.
- [19] Falanga V. Wound bed preparation: science applied to practice. In: (EWMA). EWMA, editor. *Position Document: Wound Bed Preparation in Practice*. London: MEP Ltd.; 2004. p. 2–5.
- [20] Halim AS, Khoo TL, Saad AZ. Wound bed preparation from a clinical perspective. *Indian J Plast Surg*. 2012;45(2):193–202.
- [21] Morykwas MJ, Argenta LC, Shelton-Brown EI, McGuirt W. Vacuum-assisted closure: a new method for wound control and treatment: animal studies and basic foundation. *Ann Plast Surg*. 1997;38(6):553–62.
- [22] Banwell PE, Musgrave M. Topical negative pressure therapy: mechanisms and indications. *Int Wound J*. 2004;1(2):95–106.
- [23] Stechmiller JK, Kilpadi DV, Childress B, Schultz GS. Effect of vacuum-assisted closure therapy on the expression of cytokines and proteases in wound fluid of adults with pressure ulcers. *Wound Repair Regen*. 2006;14(3):371–4.
- [24] Timmers MS, Le Cessie S, Banwell P, Jukema GN. The effects of varying degrees of pressure delivered by negative-pressure wound therapy on skin perfusion. *Ann Plast Surg*. 2005;55(6):665–71.
- [25] Saxena V, Hwang CW, Huang S, Eichbaum Q, Ingber D, Orgill DP. Vacuum-assisted closure: microdeformations of wounds and cell proliferation. *Plast Reconstr Surg*. 2004;114(5):1086–96; discussion 97–8.
- [26] Greene AK, Puder M, Roy R, Arsenault D, Kwei S, Moses MA, et al. Microdeformational wound therapy: effects on angiogenesis and matrix metalloproteinases in chronic wounds of 3 debilitated patients. *Ann Plast Surg*. 2006;56(4):418–22.
- [27] Greaves NS, Iqbal SA, Baguneid M, Bayat A. The role of skin substitutes in the management of chronic cutaneous wounds. *Wound Repair Regen*. 2013;21(2):194–210.
- [28] Lorenz HP, Longaker M. *Wounds: biology, pathology, and management. Essential practice of surgery*. New York: Springer; 2003. p. 77–88.



- [29] Yang L, Shirakata Y, Shudou M, Dai X, Tokumaru S, Hirakawa S, et al. New skin-equivalent model from de-epithelialized amnion membrane. *Cell Tissue Res.* 2006;326(1):69–77.
- [30] Parolini O, Soncini M. Human placenta: a source of progenitor/stem cells? *J Reproduktionsmed Endokrinol.* 2006;3(2):117–126.
- [31] Parolini O, Alviano F, Bagnara GP, Bilic G, Buhring HJ, Evangelista M, et al. Concise review: isolation and characterization of cells from human term placenta: outcome of the first International Workshop on Placenta Derived Stem Cells. *Stem Cells.* 2008;26(2):300–11.
- [32] Miki T, Strom SC. Amnion-derived pluripotent/multipotent stem cells. *Stem Cell Rev.* 2006;2(2):133–42.
- [33] Insausti CL, Blanquer M, Bleda P, Iniesta P, Majado MJ, Castellanos G, et al. The amniotic membrane as a source of stem cells. *Histol Histopathol.* 2010;25(1):91–8.
- [34] Davis JS. A method of splinting skin grafts. *Skin transplantation.* 1910; 21:44.
- [35] Sabella N. Use of fetal membranes in skin grafting. *Med Records NY.* 1913;83:478–80.
- [36] Stern M. The grafting of preserved amniotic membrane to burned and ulcerated surfaces, substituing skin grafts: a preliminary report. *J Am Med Assoc.* 1913;60(13):973–4.
- [37] Ganatra MA. Amniotic membrane in surgery. *J Pak Med Assoc.* 2003;53(1):29–32.
- [38] Tolhurst DE, van der Helm TW. The treatment of vaginal atresia. *Surg Gynecol Obstet.* 1991;172(5):407–14.
- [39] Georgy M, Aziz N. Vaginoplasty using amnion graft: new surgical technique using the laparoscopic transillumination light. *J Obstet Gynecol.* 1996;16(4):262–4.
- [40] Morton KE, Dewhurst CJ. Human amnion in the treatment of vaginal malformations. *Br J Obstet Gynaecol.* 1986;93(1):50–4.
- [41] Fishman IJ, Flores FN, Scott FB, Spjut HJ, Morrow B. Use of fresh placental membranes for bladder reconstruction. *J Urol.* 1987;138(5):1291–4.
- [42] Brandt FT, Albuquerque CD, Lorenzato FR. Female urethral reconstruction with amnion grafts. *Int J Surg Investig.* 2000;1(5):409–14.
- [43] Zohar Y, Talmi YP, Finkelstein Y, Shvili Y, Sadov R, Laurian N. Use of human amniotic membrane in otolaryngologic practice. *Laryngoscope.* 1987;97(8 Pt 1):978–80.
- [44] Trelford JD, Trelford-Sauder M. The amnion in surgery, past and present. *Am J Obstet Gynecol.* 1979;134(7):833–45.
- [45] de Rötth A. Plastic repair of conjunctival defects with fetal membranes. *Arch Ophthalmol.* 1940;23(3):522–5.

- [46] Sorsby A, Symons HM. Amniotic membrane grafts in caustic burns of the eye: (burns of the second degree). *Br J Ophthalmol*. 1946;30(6):337–45.
- [47] Kim JC, Tseng SC. Transplantation of preserved human amniotic membrane for surface reconstruction in severely damaged rabbit corneas. *Cornea*. 1995;14(5):473-84.
- [48] Mermet I, Pottier N, Sainthillier JM, Malugani C, Cairey-Remonnay S, Maddens S, et al. Use of amniotic membrane transplantation in the treatment of venous leg ulcers. *Wound Repair Regen*. 2007;15(4):459–64.
- [49] Gomes JA, Romano A, Santos MS, Dua HS. Amniotic membrane use in ophthalmology. *Curr Opin Ophthalmol*. 2005;16(4):233–40.
- [50] Dua HS, Gomes JAP, King AJ, Maharajan VS. The amniotic membrane in ophthalmology. *Surv Ophthalmol*. 2004;49(1):51–77.
- [51] Baradaran-Rafii A, Aghayan HR, Arjmand B, Javadi MA. Amniotic membrane transplantation. *Iranian J Ophthalmic Res*. 2007;2(1):58–75.
- [52] Colucho G, Graham WP, Iii, Greene AE, Matheson DW, Lynch D. Human amniotic membrane as a physiologic wound dressing. *Arch Surg*. 1974;109(3):370–3.
- [53] Singh R, Chouhan US, Purohit S, Gupta P, Kumar P, Kumar A, et al. Radiation processed amniotic membranes in the treatment of non-healing ulcers of different etiologies. *Cell Tissue Bank*. 2004;5(2):129–34.
- [54] Hasegawa T, Mizoguchi M, Haruna K, Mizuno Y, Muramatsu S, Suga Y, et al. Amnia for intractable skin ulcers with recessive dystrophic epidermolysis bullosa: report of three cases. *J Dermatol*. 2007;34(5):328–32.
- [55] Insausti CL, Alcaraz A, Garcia-Vizcaino EM, Mrowiec A, Lopez-Martinez MC, Blanquer M, et al. Amniotic membrane induces epithelialization in massive posttraumatic wounds. *Wound Repair Regen*. 2010;18(4):368–77.
- [56] Sangwan VS, Matalia HP, Vemuganti GK, Fatima A, Ifthekar G, Singh S, et al. Clinical outcome of autologous cultivated limbal epithelium transplantation. *Indian J Ophthalmol*. 2006;54(1):29–34.
- [57] Díaz-Prado S, Rendal-Vázquez ME, Muiños-López E, Hermida-Gómez T, Rodríguez-Cabarcos M, Fuentes-Boquete I, et al. Potential use of the human amniotic membrane as a scaffold in human articular cartilage repair. *Cell Tissue Bank*. 2010;11(2):183–95.
- [58] Yeager AM, Singer HS, Buck JR, Matalon R, Brennan S, O'Toole SO, et al. A therapeutic trial of amniotic epithelial cell implantation in patients with lysosomal storage diseases. *Am J Med Genet*. 1985;22(2):347–55.
- [59] Redondo P, Giménez de Azcarate A, Marqués L, García-Guzman M, Andreu E, Prósper F. Amniotic membrane as a scaffold for melanocyte transplantation in patients with stable vitiligo. *Dermatol Res Pract*. 2011;2011:6.



- [60] Akle C, McColl I, Dean M, Adinolfi M, Brown S, Fensom AH, et al. Transplantation of amniotic epithelial membranes in patients with mucopolysaccharidoses. *Exp Clin Immunogenet.* 1985;2(1):43–8.
- [61] Wilshaw SP, Kearney JN, Fisher J, Ingham E. Production of an acellular amniotic membrane matrix for use in tissue engineering. *Tissue Eng.* 2006;12(8):2117–29.
- [62] Zelen CM, Snyder RJ, Serena TE, Li WW. The use of human amnion/chorion membrane in the clinical setting for lower extremity repair: a review. *Clin Podiatr Med Surg.* 2015;32(1):135–46.
- [63] Lee SH, Tseng SC. Amniotic membrane transplantation for persistent epithelial defects with ulceration. *Am J Ophthalmol.* 1997;123(3):303–12.
- [64] Niknejad H, Peirovi H, Jorjani M, Ahmadiani A, Ghanavi J, Seifalian AM. Properties of the amniotic membrane for potential use in tissue engineering. *Eur Cell Mater.* 2008;15:88–99.
- [65] Kubo M, Sonoda Y, Muramatsu R, Usui M. Immunogenicity of human amniotic membrane in experimental xenotransplantation. *Invest Ophthalmol Vis Sci.* 2001;42(7):1539–46.
- [66] Boukamp P, Petrussevska RT, Breitkreutz D, Hornung J, Markham A, Fusenig NE. Normal keratinization in a spontaneously immortalized aneuploid human keratinocyte cell line. *J Cell Biol.* 1988;106(3):761–71.
- [67] Angel P, Szabowski A, Schorpp-Kistner M. Function and regulation of AP-1 subunits in skin physiology and pathology. *Oncogene.* 2001;20(19):2413–23.
- [68] Yates S, Rayner TE. Transcription factor activation in response to cutaneous injury: role of AP-1 in reepithelialization. *Wound Repair Regen.* 2002;10(1):5–15.
- [69] Gangnuss S, Cowin AJ, Daehn IS, Hatzirodos N, Rothnagel JA, Varelias A, et al. Regulation of MAPK activation, AP-1 transcription factor expression and keratinocyte differentiation in wounded fetal skin. *J Invest Dermatol.* 2004;122(3):791–804.
- [70] Li G, Gustafson-Brown C, Hanks SK, Nason K, Arbeit JM, Pogliano K, et al. c-Jun is essential for organization of the epidermal leading edge. *Dev Cell.* 2003;4(6):865–77.
- [71] Ronai Z. JNKing Revealed. *Mol Cell.* 2004;15(6):843–4.
- [72] Sabapathy K, Hochedlinger K, Nam SY, Bauer A, Karin M, Wagner EF. Distinct roles for JNK1 and JNK2 in regulating JNK activity and c-Jun-dependent cell proliferation. *Mol Cell.* 2004;15(5):713–25.
- [73] Harris IR, Yee KC, Walters CE, Cunliffe WJ, Kearney JN, Wood EJ, et al. Cytokine and protease levels in healing and non-healing chronic venous leg ulcers. *Exp Dermatol.* 1995;4(6):342–9.

- [74] Trengove NJ, Bielefeldt-Ohmann H, Stacey MC. Mitogenic activity and cytokine levels in non-healing and healing chronic leg ulcers. *Wound Repair Regen.* 2000;8(1):13–25.
- [75] Finnsen KW, McLean S, Di Guglielmo GM, Philip A. Dynamics of transforming growth factor beta signaling in wound healing and scarring. *Advances Wound Care.* 2013;2(5):195–214.
- [76] Ashcroft GS, Roberts AB. Loss of Smad3 modulates wound healing. *Cytokine Growth Factor Rev.* 2000;11(1–2):125–31.
- [77] Moustakas A, Heldin CH. Non-Smad TGF-beta signals. *J Cell Sci.* 2005;118(Pt 16):3573–84.
- [78] Mu Y, Gudey SK, Landstrom M. Non-Smad signaling pathways. *Cell Tissue Res.* 2012;347(1):11–20.
- [79] Pierreux CE, Nicolas FJ, Hill CS. Transforming growth factor beta-independent shuttling of Smad4 between the cytoplasm and nucleus. *Mol Cell Biol.* 2000;20(23):9041–54.
- [80] Heldin CH, Moustakas A. Role of Smads in TGFbeta signaling. *Cell Tissue Res.* 2012;347(1):21–36.
- [81] Tredget EB, Demare J, Chandran G, Tredget EE, Yang L, Ghahary A. Transforming growth factor-beta and its effect on reepithelialization of partial-thickness ear wounds in transgenic mice. *Wound Repair Regen.* 2005;13(1):61–7.
- [82] Chan T, Ghahary A, Demare J, Yang L, Iwashina T, Scott PG, et al. Development, characterization, and wound healing of the keratin 14 promoted transforming growth factor-beta1 transgenic mouse. *Wound Repair Regen.* 2002;10(3):177–87.
- [83] Yang L, Chan T, Demare J, Iwashina T, Ghahary A, Scott PG, et al. Healing of burn wounds in transgenic mice overexpressing transforming growth factor-beta 1 in the epidermis. *Am J Pathol.* 2001;159(6):2147–57.
- [84] Heldin CH, Landstrom M, Moustakas A. Mechanism of TGF-beta signaling to growth arrest, apoptosis, and epithelial-mesenchymal transition. *Curr Opin Cell Biol.* 2009;21(2):166–76.
- [85] Alcaraz A, Mrowiec A, Insausti CL, Bernabe-Garcia A, Garcia-Vizcaino EM, Lopez-Martinez MC, et al. Amniotic membrane modifies the genetic program induced by TGFs, stimulating keratinocyte proliferation and migration in chronic wounds. *PLoS One.* 2015;10(8):e0135324.
- [86] Nicolas FJ, Hill CS. Attenuation of the TGF-beta-Smad signaling pathway in pancreatic tumor cells confers resistance to TGF-beta-induced growth arrest. *Oncogene.* 2003;22(24):3698–711.

- [87] Ruiz-Canada C, Bernabé-García A, Angosto D, Castellanos G, Insausti CL, Moraleda JM, et al. Amniotic membrane stimulates migration by modulating TFG- $\beta$  signaling. (In press).
- [88] Ashcroft GS, Yang X, Glick AB, Weinstein M, Letterio JL, Mizel DE, et al. Mice lacking Smad3 show accelerated wound healing and an impaired local inflammatory response. *Nat Cell Biol.* 1999;1(5):260–6.
- [89] Hodge A, Lourensz D, Vaghjiani V, Nguyen H, Tchongue J, Wang B, et al. Soluble factors derived from human amniotic epithelial cells suppress collagen production in human hepatic stellate cells. *Cytotherapy.* 2014;16(8):1132–44.
- [90] Cargnoni A, Gibelli L, Tosini A, Signoroni PB, Nassuato C, Arienti D, et al. Transplantation of allogeneic and xenogeneic placenta-derived cells reduces bleomycin-induced lung fibrosis. *Cell Transplant.* 2009;18(4):405–22.
- [91] Cargnoni A, Piccinelli EC, Ressel L, Rossi D, Magatti M, Toschi I, et al. Conditioned medium from amniotic membrane-derived cells prevents lung fibrosis and preserves blood gas exchanges in bleomycin-injured mice-specificity of the effects and insights into possible mechanisms. *Cytotherapy.* 2014;16(1):17–32.
- [92] Cargnoni A, Ressel L, Rossi D, Poli A, Arienti D, Lombardi G, et al. Conditioned medium from amniotic mesenchymal tissue cells reduces progression of bleomycin-induced lung fibrosis. *Cytotherapy.* 2012;14(2):153–61.