

# We are IntechOpen, the world's leading publisher of Open Access books Built by scientists, for scientists

4,800

Open access books available

122,000

International authors and editors

135M

Downloads

Our authors are among the

154

Countries delivered to

TOP 1%

most cited scientists

12.2%

Contributors from top 500 universities



WEB OF SCIENCE™

Selection of our books indexed in the Book Citation Index  
in Web of Science™ Core Collection (BKCI)

Interested in publishing with us?  
Contact [book.department@intechopen.com](mailto:book.department@intechopen.com)

Numbers displayed above are based on latest data collected.  
For more information visit [www.intechopen.com](http://www.intechopen.com)



---

## Reconstruction of TMJ with Prosthesis Joint

---

José Thiers Carneiro Junior, Dênis Pimenta e Souza,  
Diogo Souza Ferreira Rubim de Assis,  
Paulo Hemerson de Moraes and  
Francisco de Sousa Neves Filho

Additional information is available at the end of the chapter

<http://dx.doi.org/10.5772/63804>

---

### Abstract

Temporomandibular joint (TMJ) and the associated muscles turn possible mandibular movements as a complex engineering appliance that may be affected by signs and symptoms such as pain, including in head and neck areas, abnormal jaw movement and clicking or crepitus sounds, classified as temporomandibular disorders (TMD). Some procedures such as discopexy, eminectomy, or arthroplasties, which we consider conservative, can result in ankylosis, even resorption and joint degeneration, limiting surgical options to treat TMJ. The alloplastic prosthesis becomes an option. Total joint reconstruction using prosthesis becomes the treatment choice during the following conditions: previous surgeries including autogenous grafts fail; presence of arthritic diseases; fibrous or bony ankylosis; tumors involving the TMJ; loss of vertical posterior mandible dimension by other TMJ pathologies; and previous prosthetic joint fail. The use of TMJ prosthesis, when compared to other reconstructive procedures, provides immediate function, reducing the duration of surgery and hospitalization time. Disadvantages of the TMJ prosthesis include high cost, prosthesis failure, functional mandibular movements loss, such as protrusion and laterality, and limited fit of stock prosthesis.

**Keywords:** temporomandibular joint, customized temporomandibular joint prosthesis, prosthesis, prosthetic reconstruction, temporomandibular disorders

---

## 1. Introduction

The temporomandibular joint (TMJ) is responsible for the mandibular movements and consists a set of bones, muscles and ligaments. It is subject to various diseases such as congenital, acquired (traumatic), local and systemic diseases and can lead to signs and symptoms such as pain, including in head and neck areas, abnormal jaw movement and clicking or crepitus sounds, classified as temporomandibular disorders (TMD). The complex etiopathogenesis and the variability of symptoms complicate the adoption of standardized diagnostic and therapeutic approaches, as suggested by the number of treatment modalities that have been proposed, such as occlusal splints, physiotherapy, behavioral and physical treatments, drugs and surgery. A surgical approach to the disorders of the TMJ is reserved to a minority of cases who do not respond to traditional and conservative therapies. For these situations, joint reconstructive surgery becomes necessary [1] with autogenous graft bone or alloplastic joint reconstruction, which is a challenge for the maxillo-facial surgeon. We can use autogenous bone for the reconstruction of TMJ and the preferred donor region would be the costal arch. The costochondral graft rib is obtained with an inframammary incision, where it removes part of the 5th, 6th or 7th rib, with about 3–4 cm bone tissue and 5 mm to 1 cm chondral cartilage. These patients may present some complications such as perforation or pleural laceration, resulting in pneumothorax, hemothorax, infection and chronic pain in the donor area. There is also the disadvantage of not having growth potential of the control of this type of graft, occurring overgrowth with mandibular deviation after a few years [2].

TMJ prostheses do not have many complications such as autografts, what qualifies as an alternative to the joint reconstruction. The prostheses are primarily indicated for [3, 4] the following:

- patients who have undergone multiple surgeries TMJ unsuccessfully
- infections with destruction of the mandibular condyle
- chronic inflammation or pathological resorption of TMJ
- autoimmune diseases and collagen diseases (rheumatoid arthritis, psoriatic arthritis, Sjogren's syndrome, lupus, ankylosing spondylitis)
- TMJ ankylosis
- trauma sequelae with severe functional changes
- congenital deformities (hemifacial microsomia)
- tumors in the TMJ area

The advantages for using the TMJ prosthesis are the reduction of surgical time (because there is no need for donor site), shorter hospital stay and immediate function, there is no need for each-jaw blockade postoperatively. As for the disadvantages we can mention the lack of predictability for a revision surgery, the prosthesis size limit (in the case of prefabricated

prosthesis or stock), the loss of translational movement causing loss of laterality and protrusion due to detachment of the pterygoid lateral muscle and the high cost [5].

The following are desired characteristics in a joint prosthesis [6]:

- low level of wear and corrosion of materials
- biocompatibility
- low flow and material fatigue
- adaptability anatomical structures and their functions
- stability of the components
- absence of hypersensitivity to materials
- lightness
- functionality

These features do not stop being researched by companies Materials in order to physiologically rebuild the TMJ. Due to the low clinical longevity of these types of prosthesis, a strict follow-up still is needed, for evaluating the anatomical and functional status of patients undergoing this type of treatment. Regardless of whether the TMJ is reconstructed using alloplastic, allogenic or autogenous materials, the following should be the management goals [1]: (1) to improve mandibular function and form; (2) to reduce suffering and disability; (3) to contain excessive treatment and cost; and (4) to prevent morbidity.

## 2. History

The surgery for TMJ reconstruction began with Risdon, in 1933, inserting gold foil in the articular fossa in an attempt to prevent ankylosis relapse. Eggers in 1946 positioned one tantalum sheet in the pit on the mandibular head after treatment for ankylosis arthroplasty.

In subsequent years, different types of materials and techniques have been developed to repair the TMJ. The first consideration for the use of alloplastic materials has been for treating fibrous and bony ankylosis. Subsequently, they have also been used in attempts to treat osteoarthritis, disc degeneration and loss of articular severe vertical dimension [7].

The history of aloplásticas prostheses has been characterized by failures due to inappropriate designs, inattention to biomechanical principles and ignorance of the already described in the orthopedic literature. Because TMJ is a ginglymus-artrodial articulation and its function is closely associated with occlusion, ATM prosthesis requires features not seen in a conventional orthopedic prosthesis [5].

Nowadays, TMJ prostheses are designed to minimize these failures, using different materials in such different parts or prosthesis components.



### **3. Indications of prostheses total TMJ [5, 6, 8–10]**

- Ankylosis with excessive heterotopic bone formation
- Revision procedures where other treatments have failed (eg. alloplastic reconstruction with Teflon or silastic and autografts)
- Avascular necrosis
- Joints subjected to several previous unsuccessful attempts
- Fractures with extensive destruction
- Important functional deformities
- Benign neoplasms
- Reconstructions post-malignant tumor excision
- Degenerate or resorbed joints with severe anatomical discrepancies
- Development anomalies
- Inflammatory or resorptive disorders locations (osteoarthrosis)
- Autoimmune diseases (rheumatoid arthritis, psoriatic arthritis, ankylosing spondylitis, systemic lupus erythematosus, Sjogren syndrome, scleroderma)
- Severe chronic pain without clinical and surgical resolution of possibilities
- Severe restriction of mouth opening

TMJ prosthesis has special role in bone ankylosis where surgical outcomes cannot be predicted when using other techniques such as autogenous grafts, leading to heterotopic bone growth [11].

### **4. Advantages of the TMJ implants [12, 13]**

- Functionality immediately after surgery
- Symmetry and occlusal stability
- Simpler surgical technique
- Less morbidity (does not require donor area)

### **5. Contraindications of the prosthesis TMJ [5, 9, 10, 13]**

The following are contraindications to placement of ATM protheses:

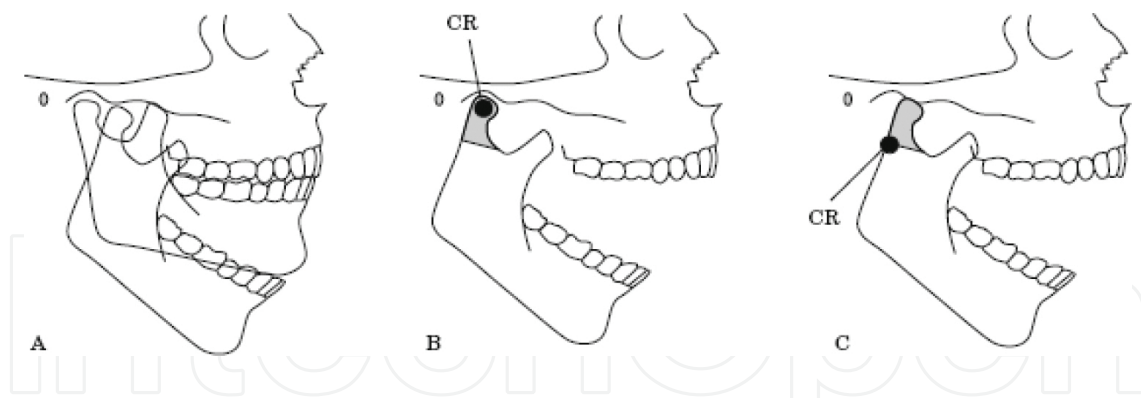
- Active or chronic infections.

- Patient conditions in which there is no sufficient bone quality or quantity to support the components.
- Systemic diseases with increased susceptibility to infections.
- Patients with extensive drilling on the glenoid fossa or bone defects in the articular eminence or zygomatic arch that could seriously compromise the support of artificial tank.
- Only partial reconstruction of TMJ.
- Allergic reaction to any material used in the prosthesis. Cr-Co-Mo devices should not be used in patients with sensitivity to nickel, as this is also a component of the material.
- Patients with neurological and mental problems who cannot or refuse to follow optimal postoperative care
- Patients with immature skeleton. Do not use in children.
- Patients with marked hyperfunctional habits (ex. dental clenching).
- Patients with foreign body reaction caused by previous implants.
- Patients with high expectation of decreased pain and improved functional activity complete articular.

There is a technical limitation of custom-made prosthesis model on esterolitografia when the patient has a pre-metal prosthesis, as this would need to be removed by additional surgery before the CT scan in order to avoid artifacts produced.

## 6. Disadvantages of TMJ prosthesis [13, 14]

- The main disadvantage of prostheses is the TMJ loss of translational movement. However, the new biomechanical concept of placing the pivot point inferior to the center of the natural condyle leads to a better translation mouth opening [15], even in patients unable to perform natural protrusive movements. This concept further enhances the mandibular function and would prevent overloads on the natural TMJ contralateral side unilateral prosthesis (**Figure 1**) [16].
- High cost, although the decrease in associated costs, with shorter hospital stay and faster recovery of the patient [13].
- Doubt as the durability of the prosthesis and its possible shortcomings, because among all models of prostheses known there is no giving this predictability. There is much attention as the fixation of the prosthesis to the remaining bone, because over time some screws used to attach can lose efficiency which would lead loss adjustment and lack of component stability [5, 17, 18].



**Figure 1.** Center of rotation of modern TMJ prosthesis according to concepts of Falkestron (1993). (A) Normal mouth opening; (B) opening mouth rotation center located in the area of the condyle; (C) opening mouth rotation center located 15 mm below the condylar center, imitating the condylar translation [16].

## 7. Considerations as prosthetic TMJ

The success and longevity of the TMJ alloplastic reconstruction are directly attributable to the stability of the prosthesis deployment location, biocompatibility, design, resistance to loads during function over time and correct and aseptic surgical technique [12, 18, 19].

Although the customized prosthesis is considered optimal, the accuracy of computed tomography (CT) used to make the model of the TMJ is of the order of 0.5 mm, resulting in a close fit of the prosthesis. It should also be still considered the dose of radiation while performing the CT scan, the high cost in the manufacture of three-dimensional prototype and the individual adjustment of this type of prosthesis that can consume more time [14].

The stock prosthetics require large number of different anatomical forms because of individual variability of bone structures shapes, mainly for the component of the glenoid fossa. This may hinder a little fit of the prosthesis and choosing the best component [14].

The prostheses of W. Lorenz<sup>TM</sup> and TMJ<sup>TM</sup> concepts have similar concepts, but different designs. The materials used in the two prostheses are nowadays the gold standard in orthopedic joint deployment with respect to wear resistance properties and structural stability, showing be reliable materials in prosthetic reconstructions [20, 21].

A major difficulty is knowing the best time to use a denture TMJ, and reconstruction with prosthetic joint should be considered as the final surgical stage and not be used for minor problems [18].

Autogenous grafts have shown better results than the aloplásticas aids in TMJ reconstructions for some authors. This does not mean that autologous grafts and flaps are exempt from complications and sequelae, but these are less frequent and more recoverable than those caused by dentures [22]. On the other hand, it is known that autografts (costochondral, sternoclavicular, myofascial temporal, ear cartilage, dermis or vertical osteotomy of mandibular branch) are used for TMJ reconstruction in similar conditions to the use of hearing aids, which may

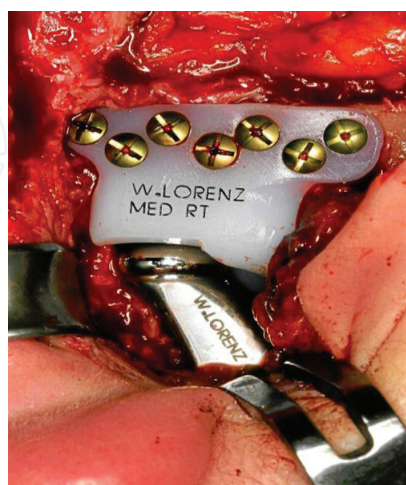occur also adverse response and possible failures in its use. There are known factors that contribute to the failure of dentures TMJ, as stated earlier, and success depends on an attempt to minimize these factors [6].

### 7.1. Stock prostheses

The stock prosthesis, compared to the customized one, requires less time for preoperative preparation. However the disadvantages is need a surgeon with experience because the anatomical variations still a challenge to the prostheses stability. Also the Stock prostheses is not appropriate for some patients with extensive tumors or severe deformities, intraoperative time consume to prepare the mandibular the fossa and mandibular ramus fit with the prosthesis. In contrast, the custom-made prosthesis is more expensive, but it is highly accurate, and it is also considered the prosthesis of choice in patients with major TMJ and mandibular defects [23, 24].

Some stock prostheses are relatively complex and unsuitable with fit and shape. The eminence area irregularities and the fossa bottom with complex depressions result in the instability of the prostheses. Surgeons must take care when removing irregularities by a bone bur and then place the fossa component directly because they got to preserve enough bone to retain the screws on zygomatic arch [24].

The latest inventory prostheses (W. Lorenz™) used nowadays have two components: a condylar composed of cobalt-chromium-molybdenum alloy (Cr-Co-Mo) and titanium alloy coating (Ti-6Al-4V), and a component of the composite cavity of ultra-high molecular weight polyethylene (PUAPM) (**Figure 2**). It also presents evidence of fixtures, with the compound condyle Aluminum and Radel™ plastic tank. Both components are available in various sizes as well as in specific designs for the right and left sides, being fixed to bone by titanium screws [9–21].



**Figure 2.** Installed stock prosthesis W. Lorenz. The metallic component of condylar articulating against PUAPM pit fixed with titanium screws is observed [21].

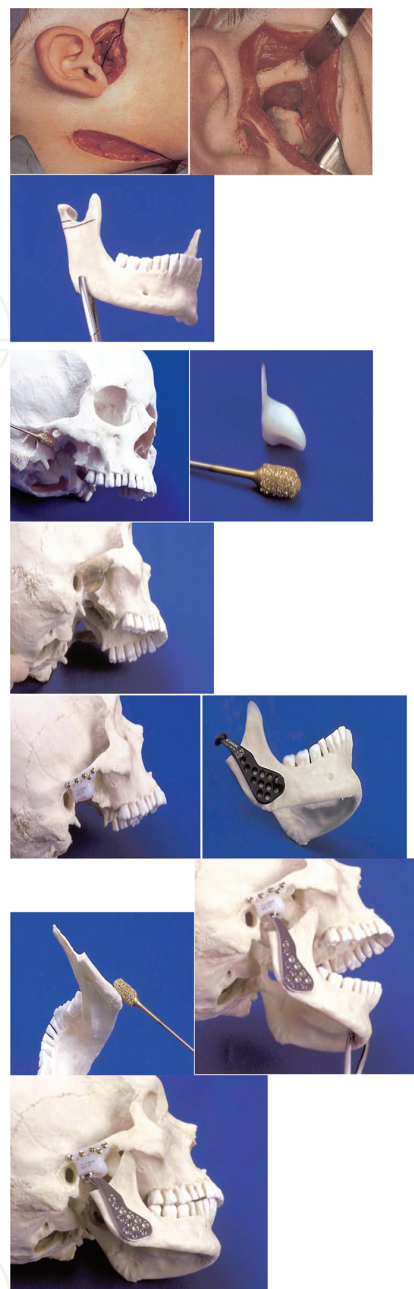The fossa PUAPM has a minimum of 4 mm thickness in the central region and has a cavity with larger walls to protect the condyle of the heterotopic bone invasion and to prevent its displacement or dislocation. The neck condylar appears as swan neck, avoiding the obstruction problem at the implant-bone interface inherent to the drawing at right angles other condylar prosthesis and is based on the innovation of Falkestrom and Van Loon designs with rotation point lower than that of natural TMJs, resulting in an imitation of translational movement when the mouth opening, which results in 15% interincisal aperture gain [1–21].

The system does not replace normal healthy bone, and chronic pain can continue to exist even after the placement of the prosthesis. The system can also loosen or break due to stress, activity or trauma. The presence of mandibular screws or prior zygomatic arch placement or pre-existing holes may compromise the fixation. Placing the unilateral prosthesis can result in detrimental effects on the contralateral joint. It should also be noted that there may be occlusal changes over time after installation of the prosthesis [9, 10].

The following are cited as adverse effects that may occur after placement of the prosthesis [9, 10]:

1. removal components due to changes caused by overloading or wearing, degenerative changes in the joint surfaces arising from disease or prior implants and corrosion or produce particles of implant material
2. loosening or displacement with or without removal of the implant
3. systemic or superficial infection
4. allergic reaction or foreign body implant components
5. wear fossa
6. edema or facial pain
7. dysfunction of the facial nerve
8. tissue excision
9. heterotopic bone formation
10. training neuroma
11. problems headset
12. dislocation of the prosthesis

The maximum inter-incisor opening ranges from 24.9 mm in the first postoperative month moving up to 36 mm [25], for the second postoperative year, on average, in monitored patients. They are recommended post-surgical care and local measures (surgical wound care and physical therapy), proper diet and medication as well as regular visits to follow-up. The technical scheme of placement of TMJ prostheses can be seen in sequence in **Figure 3** [9, 10].



**Figure 3.** Scheme of surgery and placement of the prosthesis W. Lorenz [9, 10].

The surgical technique for this type of procedure follows the sequence described [25]:

- naso-tracheal intubation directly or assisted by video
- local anesthetic infiltration with vasoconstrictor in pre-auricular region
- pre-auricular incision and dilatation of the tissues in layers
- osteotomy for the removal of the head of ankylosed jaw or mass (in the case of TMJ ankylosis) and realization of the ceiling planing of joint cavity with surgical drills and bone files to adapt the temporal feedback



- feedback fixing the pit/articular eminence with titanium screws, checking the stability and parallel to the zygomatic arch
- conducting submandibular incision (Risdon) with dilatation of the tissue plans for communicating the two surgical approaches
- blocking of patients using screws trans-gingival maxillo-mandibular intercuspitation during surgery not exist occlusal changes
- the condylar component is fixed and the lock to open maxilomandibular mobility check
- if the patient presents the restriction opening movement is carried out a second osteotomy, the coronoidectomy in order to eliminate interference with movement
- the time template is then replaced by the prosthetic fossa component
- sutures were made by planes of the two accesses with vicryl and nylon 5.0 yarn type and curative were kept locally for 48 h
- conducting physiotherapy with isometric exercises and occlusal rehabilitation

## 7.2. Customized temporomandibular joint prosthesis

Most patients presenting with indications for total TMJ alloplastic reconstruction have distorted anatomy caused by either numerous failed prior surgical interventions/materials or primary or secondary joint disease that compounds the stability problems in the TMJ area. This finding makes it extremely difficult to reconstruct these cases with an off-the-shelf or so-called “stock” device [26]. More recently, with the advent of CT scans with three-dimensional reconstruction (3D-CT) and esterolitografia, it was possible the manufacture of ATM-individualized dentures. This prosthesis (Bioconnect Temporomandibular prosthesis design and principles and materials) uses a powerful 3D printing technology to shape the desired metal geometry by melting metal powder layer by layer. The metal used in the creation of the customized implant (temporomandibular joint) is Titanium Ti – 6% Al – 4%, wt% (Ti64 degree 23) with a low oxygen content. An ideal combination is achieved by having a biocompatible metal, titanium, designed at any desired geometric shape for a perfect customized fit. With the advances in health technology, the work of the Direct Metal Laser Sintering (DMLS) has allowed treatment of clinical cases that were previously practically impossible to treat due to their complexity. With the use of the DMLS technology, the use of various materials and a high range of complexity on the customizations, reduced manufacture time is possible [27].

The fossa component is constructed from two basic materials – Ti64 degree 23 and ultra-high molecular weight polyethylene (UHMWPE). The UHMWPE have a relatively flat functional surface and had a posterior stop to provide a centric relation position for the condylar head of the prosthesis. The customized surgical guides are used specifically for each planning and cutting rails specific to each type of drill, saw or ultrasonic nozzle. Thus, it allows the surgeon to accurately replicate the trans-surgical what was accomplished in planning (**Figure 4**), while other prostheses that are made using plastic prototypes and conventional machining (computer numerical control, CNC) do not allow this essential advantage, thereby causing poor adaptations and failures.





**Figure 4.** Customized cutting guide; fossa component; mandibular component.

## 8. Discussion

Treatment with denture TMJ is still a matter of controversy. It is evident that a variety of etiologies and different treatments may be used in the reconstruction, as autogenous and alloplastic grafts, with the indication of TMJ prosthesis based on the surgeon's experience and results described in the literature [5, 6, 8–22, 28].

Previous surgery can be tried, but some patients do not respond satisfactorily to the prosthesis, being an excellent alternative for resolving these cases. One should be aware that the TMJ prosthesis is the final stage in joint reconstruction and should be proposed only for cases where there is no evidence for the possibility of other techniques [16, 29].

The occlusal stability has led to placement and longevity of the prosthesis. Changes of the occlusal plane, the Z-axis (lateral-lateral), II severe classes, spee curve inversions, overbites or accentuated overjet and multiple missing teeth could compromise the lock stability in trans-operative and post-operative functional balance, causing occlusal and adapting prosthesis overloads, interfering in the right condyle-fossa relationship, which on the long run could interfere with the functional outcome [5, 25].

The commitment of mandibular movements is extremely variable and dependent on the etiology and clinical condition presented. Patients with ankylosis have greater functional impairment mainly due to their severe functional limitation. Also in these patients, both placed prostheses—unilateral and bilateral form—best functional gains are achieved. In cases of patients with idiopathic resorption, trauma sequels and arthrosis of TMJ, the gains are more related to the stability of movement and decrease in symptoms such as headaches, muscle fatigue and local pain [25].

In some cases, there is loss of movement quality, especially the translation of Caused by damage of the lateral pterygoid muscle that was detachment of the site [15, 16]. Furthermore,

adaptation and gradient component with respect to the condylar fossa prosthesis cause greater amplitude during translational motion, thereby reducing the limitation of movement that occurred earlier. Note that the maximum opening and also the best efficiency of this type of prosthesis can be achieved by performing coronoidectomy, enabling the mouth opening without interference [5]. Even with the modifications proposed in the most modern prostheses, there are still significant functional loss and functional movement restriction and in particular lateral protrusion, which cannot be measured, and in most cases, values above 6 and 6 mm respectively. In older cases, where the prostheses have not had the spin axis changes, the conditions of laterality and protrusion were even more restricted [16].

Symptomatic conditions such as headaches, muscle fatigue, local pain, swelling and asymmetries can be improved after placement of the prosthesis. However, for all cases there will be some degree of limitation of the excursion of mandible head compared to a normal ATM. Also note that the prosthetic condyle-sump movement occurs across length and the surface thereof, so there is a certain rotation and translation that in cases of Of patients with bony ankylosis can be improved after surgery, since they have no moving none or very limited pre operatively [25].

The movement of the prosthesis occurs because of one's jaw movement, Realized other muscle groups, supra-hyoid, contralateral mandibular elevators, temporal, masseter and medial pterygoid (which keeps some degree functional even after detachment for prosthetic installation). The ability of functional adaptation of the jaw is a decisive factor in the prosthesis-jaw system [5, 11].

Dislocations of the metal component of the polyethylene tank, fixing losses of the prosthesis system to fracture and locoregional bone formation could occur, but there are frequent complications. Some case reports of these complication It has been caused to failure of the surgical technique, both the component adjustment, in osteotomies and wear bone, the choice of location of bone resection, the lack of stability of the components and their attachment to the bone and also in Setup component in improper angles [5, 6, 8-25, 30].

A good surgical technique combined with postoperative physiotherapy and functional with adequate maintenance, proper fixation and favorable angle means that there is clinical success [25]. Modern custom-made prostheses have a pit format that allows great adaptation to the temporal bone and are placed parallel to the zygomatic arch Restricting several movements. The component thickness is a decisive factor that hinders exaggerated bone formations and local ankylosis [21].

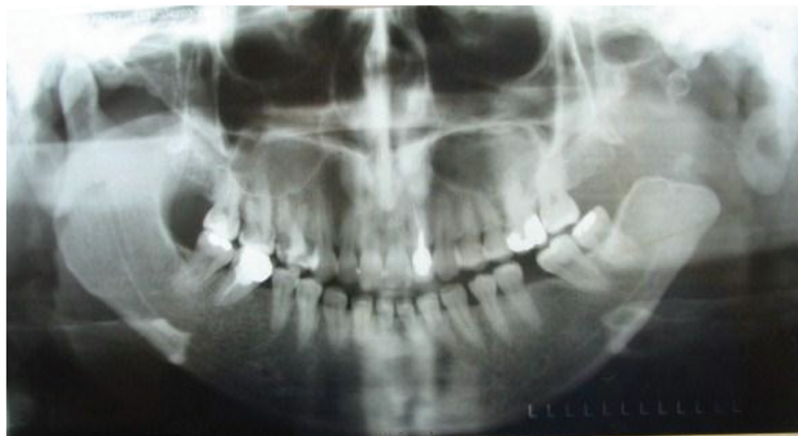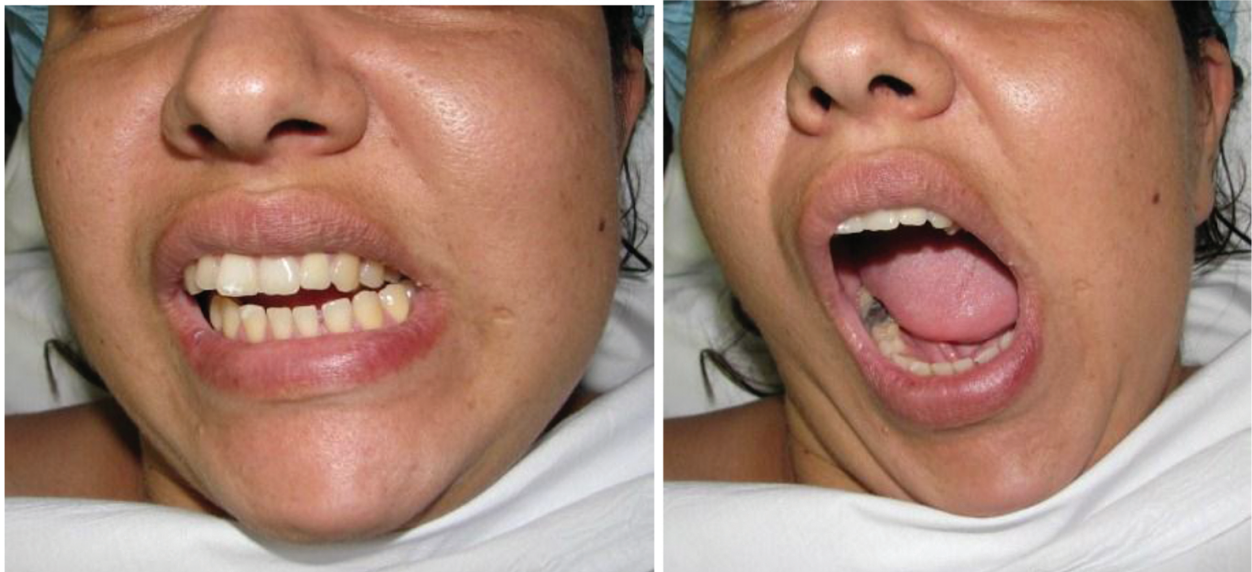The behavior of the TMJ contralateral to the prosthesis, in cases of execution of unilateral prosthesis, requires particular attention, because the functional balance achieved in short time is great, but the behavior of the anatomical structures is somewhat uncertain way, and condylar resorption, disc dislocations, muscle aches, some functional restriction by anatomical limitation of the contra-lateral prosthesis, chewing functional changes, periodontal and progressive joint degeneration may occur [25].

## 9. Conclusion

In conclusion, the TMJ prostheses have the reconstruction order to articulate and fulfill this role satisfactorily. Due to developments over time, their biomechanical principles and biocompatibility have made TMJ prostheses reliable and a safe alternative for the reconstruction of the joint. Long-term studies are needed, because clinical longevity of patients undergoing this type of prosthesis is still less [5, 12–25, 30].

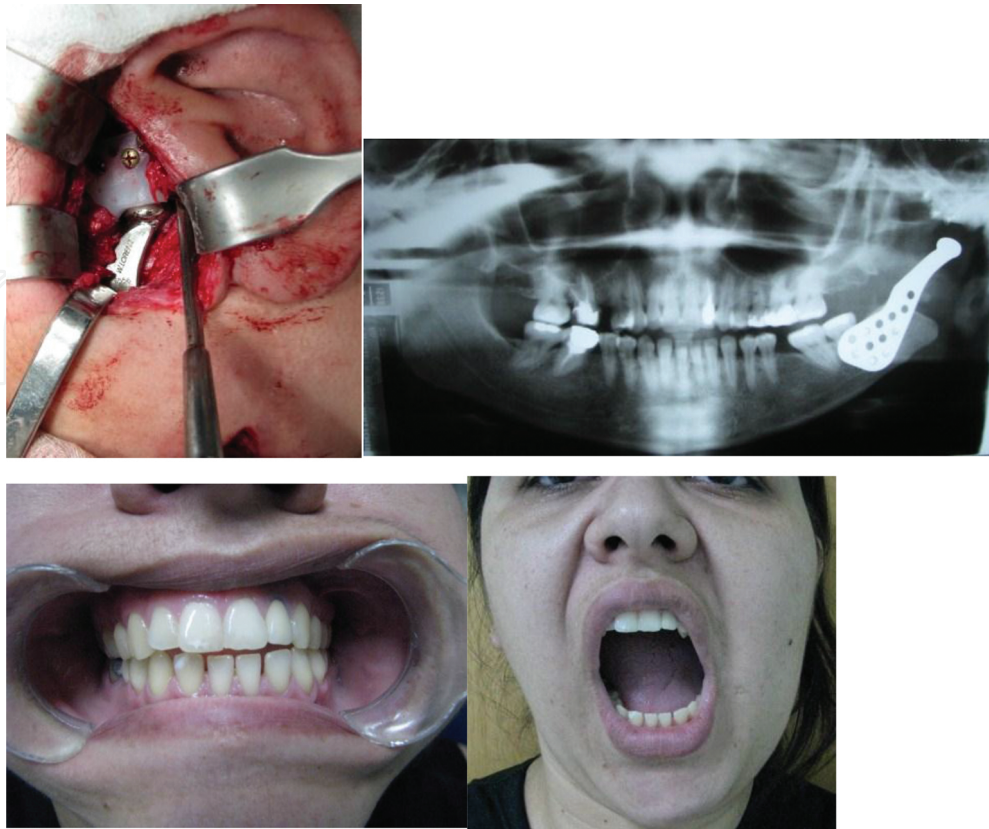## 10. Case report of alloplastic temporomandibular joint W. Lorenz

Case report orthognatic with alloplastic temporomandibular joint W. Lorenz.

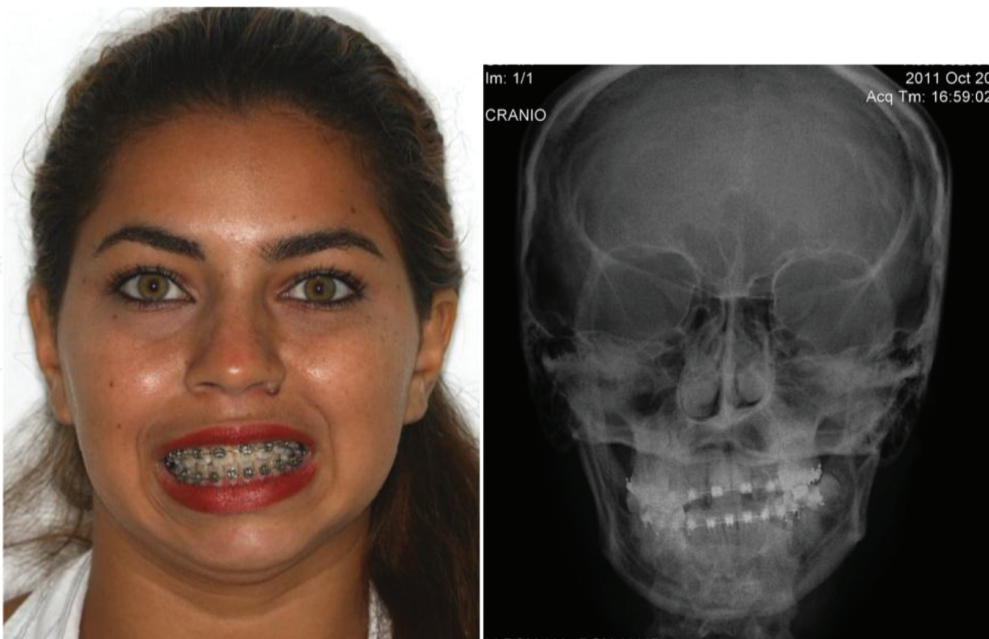

Patient with mandibular defect after remove Aneurysmal bone cyst deviation of the mandible.



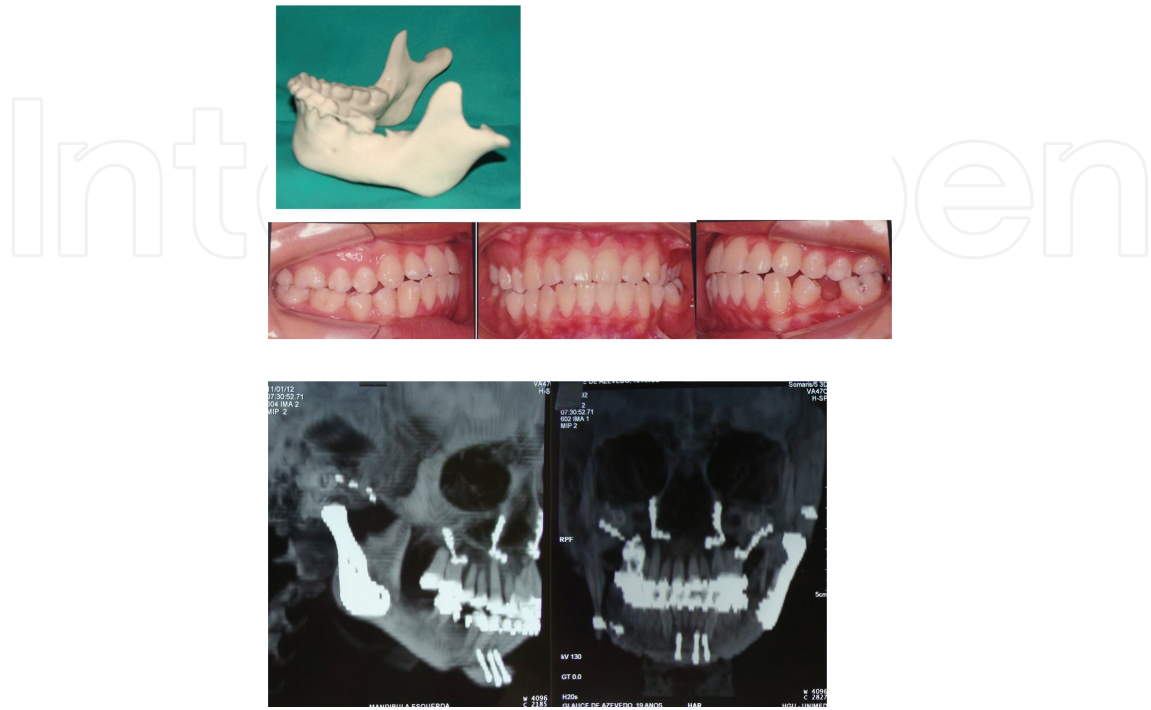


Provide adequate stability of occlusal bite. Decrease the deviation of the mandible.

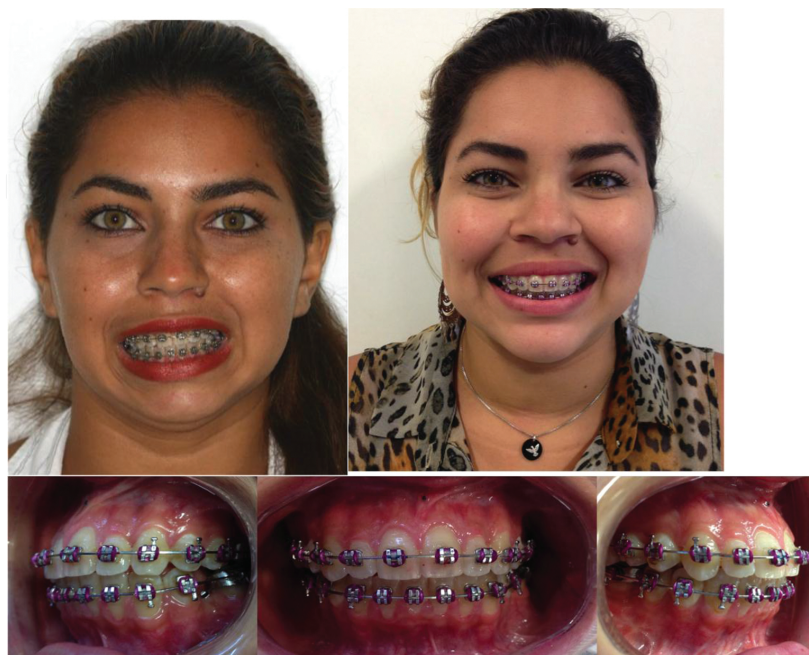

Patient with condylar resorption after trauma Occlusal plane alteration facial symmetry occlusal relationship before treatment.

### Concomitant Temporomandibular Joint and Orthognathic Surgery.



### Correction of Facial Asymmetry and occlusal bite.



## Author details

José Thiers Carneiro Junior<sup>1\*</sup>, Dênis Pimenta e Souza<sup>2</sup>, Diogo Souza Ferreira Rubim de Assis<sup>3</sup>, Paulo Hemerson de Moraes<sup>4</sup> and Francisco de Sousa Neves Filho<sup>1</sup>

\*Address all correspondence to: [jthiers53@uol.com.br](mailto:jthiers53@uol.com.br)

1 Federal University of Pará (UFPA), Belém, Brazil

2 University of São Paulo (USP), São Paulo, Brazil

3 Federal University of Maranhão (UFMA), Brazil

4 University of Campinas (UNICAM), Brazil

## References

- [1] Guarda-Nardini L, Manfredini D, Berrone S, Ferronato G. Total temporomandibular joint prosthesis as a surgical option for severe mouth opening restriction. A case report of a bilateral intervention. *Reumatismo* 2007;59: 322–7.
- [2] Politis C, Fossion E, Bossuyt M. The use of costochondral grafts in arthroplasty of the temporomandibular joint. *J Cranio Maxillofac Surg* 1987;15(6):345-54.
- [3] Kieh CL, DesPrez JD, Converse CF. Total prosthetic replacement of the temporomandibular joint. *Ann Plast Surg* 1979;(2):5-15.
- [4] Ko EWC, Huang CS, Chen YR. Temporomandibular joint reconstruction in children using costochondral grafts. *J Oral Maxillofac Surg* 1999;57(7):789-98; discussion 799-800.
- [5] Quinn P. Alloplastic reconstruction of the Temporomandibular Joint. In: Fonseca RJ. *Oral and Maxillofacial Surgery: Temporomandibular Disorders*, Philadelphia: WB Saunders Company; 2000. cap.17, p. 316-32.
- [6] Wolford LM, Pitta MC, Reichel-Fischel O, Franco PF. TMJ concepts/techmedica custom made TMJ total prosthesis: 5-year follow-up study. *Int J Oral Maxillofac Surg* 2003;32:268-74.
- [7] Morgan DH. Development of alloplastic materials for temporomandibular joint prosthesis: a historical perspective with clinical illustration. *Cranio* 1992;10(3):192-204
- [8] Saeed NR, Hensher R, McLeod NMH, Kent JN. Reconstruction of the temporomandibular joint autogenous compared with alloplastic. *Br J Oral Maxillofac Surg* 2002;(40): 296-9.

- [9] W. Lorenz Surgical. Total TMJ replacement system patient information. Jacksonville: W Lorenz; 2005. Folheto informative
- [10] W. Lorenz Surgical. Total TMJ replacement system interactive Cd-Rom. Dordrecht: W.Lorenz Surgical; 2005.
- [11] Guven O. Treatment of temporomandibular joint ankylosis by modified fossa prosthesis. *J Craniomaxillofac Surg* 2004;(32):236–42.
- [12] Adame CG. Temporomandibular reconstruction : alloplastic prostheses. *Rev Esp Cir Oral Maxillofacial* 2005;27(1):7–14.
- [13] Mercuri LG, Use of alloplastic prostheses for TMJ reconstruction. *J.Oral Maxillofac Surg* 2000;(58):70-5.
- [14] Van Loon JP, DeBont LGM, Boering G. Evaluation of Temporomandibular joint prostheses: review of the literature from 1946 to 1994 and implications for future prosthesis designs. *J Oral Maxillofac Surg* 1995;53:984-96.
- [15] Falkestrom CH. Biomechanical design of total temporomandibular joint replacement [thesis]. University of Groningen; 1993.
- [16] Van Loon JP, De Bont LGM, Stegenga B, Spijkervet FKL, Verkerke GJ. Groningen Temporomandibular joint prosthesis. Development and first clinical application. *Int J Oral Maxillofac Surg*. 2002;31:44-52.
- [17] Wolford LM. Temporomandibular joint devices: treatment factors and outcomes. *Oral Surg Oral Med Oral Pathol Oral Radiol Endod* 1997;83:143-9.
- [18] Wolford LM. Factors to consider in joint prosthesis systems. *Proc (Bayl Univ Med Cent)*. 2006;19(3):232-8
- [19] Mercuri LG, Wolford LM, Sanders B, White RD, Giobbie-Hurder A. Long-term follow-up of the CAD/CAM patient fitted total temporomandibular joint reconstruction system. *J Oral Maxillofac Surg* 2002;(60):1440-8.
- [20] Curry JT, Alexander R. Comparison of 2 temporomandibular joint total joint prosthesis systems. *J Oral Maxillofac Surg* 2004;62(2):261.
- [21] Westermarck A, Koppel D, Leiggener C. Condylar replacement alone is not sufficient for prosthetic reconstruction of the temporomandibular joint. *Int J Oral Maxillofac Surg* 2006;35:488-92.
- [22] Gonzalez GR. Temporomandibular reconstruction :autologous graft. *Rev Esp Cir Oral Maxillofac* 2005;27(1):15–28.
- [23] Westermarck A, Heden P, Aagaard E, Cornelius CP. The use of TMJ concepts prostheses to reconstruct patients with major temporomandibular joint and mandibular defects. *Int J Oral Maxillofac Surg* 2011;40:487–496.



- [24] ShanYong Z, Liu H, Yang C, Zhang X, Abdelrehem A, Zheng J, Jiao Z, Chen M, Qiu Y. Modified surgical techniques for total alloplastic temporomandibular joint replacement: One institution's experience. *J Cranio-Maxillo-Facial Surg* 2015;43:934–939.
- [25] Souza DP, Temprano AB, Shinohara EH, Lobo LF, Falchet PF. Clinical evaluation of patients with total temporomandibular joint replacement. *Rev Esp Cir Oral Maxilofac*. 2013;35(3):107–115.
- [26] De Moraes PH; Pozzer L, Olate S, Sato FRL, Moreira RWF. TMJ total joint prosthesis for condylar fracture malunion. *Int J Odontostomat*,2012;6(2):241–244
- [27] De Moraes PH, Olate S, Cantin M, Assis AF, Santos E, Silva FO, Silva LO. Anatomical reproducibility through 3D printing in cranio-maxillo-facial defects. *Int J Morphol*, 2015;33(3):826–830
- [28] Capote A, Rodriguez-Campo FJ, Escorial V, Munoz-Guerra M. Total tempomandibular joint reconstruction with alloplastic prosthesis. Review our experience. *J Cranio Maxillofac Surg* 2006;34(6 Suppl):S1.
- [29] Mercuri LG, Anspach, WE. Principles for the revision of failed TMJ prostheses. *Int J Oral Maxillofac Surg* 2003;(32):353–9.
- [30] Wolford LM., Dingwerth DJ, Talwar RM., Pitta MC. Comparison of 2 temporomandibular joint total joint prosthesis systems. *J Oral Maxillofac Surg* 2003a;61:685–90.