

# We are IntechOpen, the world's leading publisher of Open Access books Built by scientists, for scientists

4,800

Open access books available

122,000

International authors and editors

135M

Downloads

Our authors are among the

154

Countries delivered to

TOP 1%

most cited scientists

12.2%

Contributors from top 500 universities



WEB OF SCIENCE™

Selection of our books indexed in the Book Citation Index  
in Web of Science™ Core Collection (BKCI)

Interested in publishing with us?  
Contact [book.department@intechopen.com](mailto:book.department@intechopen.com)

Numbers displayed above are based on latest data collected.  
For more information visit [www.intechopen.com](http://www.intechopen.com)



---

# ECMO Cannulation Techniques

---

Chand Ramaiah and Ashok Babu

Additional information is available at the end of the chapter

<http://dx.doi.org/10.5772/64338>

---

## Abstract

An extracorporeal membrane oxygenation (ECMO) circuit consists of a pump and a membrane oxygenator. This circuit can interface with the human body in a variety of cannulation strategies to provide different forms and levels of support. These various support techniques can be divided into two broad categories: those designed to support the body's respiratory functions (lungs) and those designed to support the body's blood circulation (heart). In this chapter we discuss various cannulation techniques used.

**Keywords:** ECMO, VV ECMO, VA ECMO, arterial, venous

---

## 1. Introduction

We will briefly describe the types of extracorporeal membrane oxygenation (ECMO) support and cannulation options in two sections. In Section 3, we describe the techniques.

## 2. ECMO for respiratory support

Patients with preserved cardiac function but isolated lung dysfunction can be supported using venovenous (VV) ECMO. Classically VV ECMO support is provided using two separate cannulation sites. More recently a single-site venovenous ECMO cannula has become available for sizes suitable for adults and children which allows mobilization of the patient due to lack of a femoral cannula. Choice of cannula size is critical to enable good support of the patient. One would like to provide diversion of 80% of the cardiac output on VV ECMO. Due to sepsis physiology at play in some of these patients, cannulas that afford maximal flow for the patient's

---

body size are preferable. Regardless of cannula configuration, the basic principle is that venous blood is drained from the body, gas is exchanged, and the blood is returned into the right atrium. This will allow oxygenation and CO<sub>2</sub> removal prior to the blood entering the heart. The weakness of VV ECMO setup is that it is dependent on diverting a large portion of the cardiac output to allow support of arterial oxygen saturations. Also it is subject to recirculation from the return cannula into the drainage cannula, which will effectively limit its support. Proper cannulation technique can maximize circuit flow and limit recirculation.

### **2.1. Dual cannula VV ECMO support technique**

This can be done with bilateral femoral cannulas or with a single femoral cannula and an upper body return cannula.

### **2.2. Femoral-internal jugular (IJ) VV ECMO**

Guidance can be with transesophageal echo (TEE), but fluoroscopy is preferred. Stiff guide-wires are advanced into the right atrium from the right internal jugular (R IJ) as well as from one of the common femoral veins. A 25 French venous drainage cannula is inserted from the femoral vein to the abdominal Inferior vena cava (IVC) with the tip at least 2 cm below the diaphragm. This will act as the drainage cannula to the circuit. The return cannula is a 19 French “arterial” style cannula that is inserted from the right internal jugular vein into the right atrium. This acts as the return cannula. The separation distance between the tips of these two cannulas is important to minimize recirculation of the oxygenated blood.

### **2.3. Fem-fem VV ECMO**

Guidance can be with transesophageal echo (TEE), but fluoroscopy is preferred. Stiff guide-wires are advanced into the right atrium from right and left common femoral veins. A standard 25 French percutaneous venous drainage cannula is inserted from one of the femoral veins into the IVC, leaving its tip at least 2 cm below the diaphragm. This will act as the drainage cannula to the circuit. The return cannula must be a long cannula with a limited length of outflow ports. Standard percutaneous venous cannulas will not work for this application. Medtronic Bio-Medicus “venous” cannulas have a very short outflow segment but long total lengths and enable the use of a femoral return cannula. Insertion of a 19 French Bio-Medicus venous cannula from the other groin with all of its outflow ports in the superior right atrium will minimize recirculation and allow maximal flows.

### **2.4. Avalon single-site venovenous ECMO**

This cannula is best placed with fluoroscopic guidance, though it can be accomplished with transesophageal echo as well. Ultrasound-guided micropuncture access is gained to the right internal jugular vein. The wire provided with the Avalon introducer kit is advanced into the abdominal IVC. Serial dilation is performed, and the Avalon cannula is inserted over the wire. Initially the tip should be laced well into the IVC. The outflow port of the cannula should be aligned rotationally with the tricuspid valve orifice. This can be accomplished easily as the

outflow port external to the body is aligned with the internal outflow port. Thus, this part of the cannula is pointed medially on the patient's neck. Additionally, one should attempt to align the outflow port vertically with the tricuspid valve. This can be done by visualizing the outflow port by fluoroscopy as it is shown by a defect in the wire reinforcement. It can also be done by visualizing the outflow color jet on TEE after the ECMO circuit is started. The alignment of this is probably not critical, and one should balance this against deep insertion of the cannula into the IVC which may impair drainage from that segment of the cannula.

### **3. ECMO for cardiogenic shock**

Venoarterial (VA) ECMO can be used to support patients in cardiogenic shock from the following etiologies: acute exacerbation of chronic heart failure, acute Myocardial Infarction (MI), myocarditis, drug-induced or stress-induced cardiomyopathy, refractory cardiac arrest, and refractory arrhythmia. VA ECMO provides biventricular support and allows full restitution of cardiac output [1]. It also allows full respiratory support depending on the condition of the native heart. The critical weakness of VA ECMO is the lack of left ventricular (LV) unloading that we will discuss further.

#### **3.1. Peripheral femoral VA ECMO**

The most common cannulation technique for VA ECMO is via the femoral artery and vein. This can be done expeditiously under most conditions, including emergency cannulation during Cardiopulmonary resuscitation (CPR). Please see details of cannulation technique and cannula choice in the next section. The femoral venous cannula is inserted into the right atrium to provide excellent drainage of venous blood to the circuit. The femoral arterial cannula is left with its tip in the external iliac artery and provides retrograde flow in the aorta. It is preferable to place the venous and arterial cannulas on opposite limbs. The reason for this is the cut down to repair the artery during decannulation is made easier by not having a venous cannula in the way. Additionally the venous cannula can be decannulated without cut down if it is in a separate groin. A critical consideration with femoral cannulation is that of limb ischemia in the limb that has an arterial cannula. Many times the arterial cannula is large enough that it will obstruct flow in the common femoral artery and create a cold limb. Routine use of an antegrade distal limb perfusion cannula is recommended. This is done by accessing the superficial femoral artery (SFA) by antegrade needle access with a 5 French sheath. This technique is described in Section 3. The cannula is connected to the arterial circuit to allow limb perfusion. Adequate limb perfusion should be confirmed later by physical examination of the foot. Capillary refill and temperature are useful physical signs. However in the setting of high-dose vasopressors, they may not be accurate. Additionally, Doppler examination can be performed, and one may expect a true continuous signal as often there will be no pulse in the cannulated extremity. Most importantly, one can confirm the adequacy of the limb perfusion cannula with a dye injection in the cannula under fluoroscopy if there is any question of limb perfusion.

### 3.2. Central VA ECMO

There are times when one cannot place cannulas peripherally due to vascular disease or other concerns. Central cannulation should always be considered in these settings. However, bleeding risk is significantly greater once the chest cavity is opened and should only be done when required. This can be done via sternotomy or thoracotomy technique. If undertaking central cannulation, strong consideration must be given to left ventricular venting at the time of cannulation, simply because one has access at this time, and the need for venting is likely to arise. Additionally, if the etiology of cardiogenic shock is likely to be prolonged, one should give strong consideration to placement of temporary biventricular assist device (BiVAD) as this will be a more durable support strategy. If oxygenation support is required, an oxygenator can be placed in line to the Right ventricular assist device (RVAD) or Left ventricular assist device (LVAD). This can later be removed when the lungs have recovered.

Central ECMO is the easiest to deploy via sternotomy. Difficulty in peripheral cannulation is typically encountered with the artery, and the indication for central conversion is related to arterial outflow. We recommended attachment of a sidearm graft to the ascending aorta for outflow as this is much less prone to subsequent bleeding complications than direct cannulation. The minimal size graft used should be a 10 mm Dacron graft. A large cannula can be tunneled in the subxiphoid position and tied into place within the graft. Some groups will use a 3/8" by 3/8" connector in this setting, but this may require leaving some of the graft external to the skin which may be less preferable. If one is expecting to convert the patient to a durable LVAD, one should consider using the graft diameter of the planned durable LVAD. If one is planning to use a Thoratec device, a 14 mm Dacron graft should be utilized so as to ease the next operation. Venous drainage can still come from a percutaneous venous cannula (preferably the internal jugular vein for mobility). However, if those sites are not available, a venous cannula can be placed via the right atrial appendage. A lighthouse tip cannula of 32 French size or greater is used. This can be a right angle type cannula or a malleable cannula that can be formed to the desired shape. Not only is a purse string used to secure this with a tourniquet but an additional heavy silk tie or umbilical tape tied around the base of the appendage will allow additional hemostasis.

Left ventricular venting should be performed as described in the section on LV venting. If done via sternotomy, venting via the LV apex is the best choice. The patient must already be on ECMO support to allow lifting of the LV apex. We recommend usage of the Thoratec® CentriMag® 34 French Drainage Cannula Kit for this purpose. The sewing ring is attached to the epicardium using a running suture. The 34 French cannula provided is tunneled under the costal margin at the patient's anterior axillary line and advanced through this sewing ring. Great care must be taken to ensure all side holes are within the LV cavity, but the cannula is not inserted too far to contact a wall or the mitral valve and cause inadequate drainage. This cannula is connected in a "Y" configuration to the venous limb of the ECMO circuit. The cannula is secured to the sewing ring using multiple silk ties as well as the umbilical tapes provided by the manufacturer. Great care is required to ensure good placement of this cannula within the ventricular cavity. The proper entry location of the cannula is important for future

durable LVAD placement. Additionally, it should lie parallel to the septum. Proper tunneling angle is important for this as well.

Right anterior thoracotomy is also a viable approach for central ECMO cannulation if one wants to avoid sternotomy. The right atrium and ascending aorta are available here for direct cannulation. However, aortic sidearm graft attachment may be difficult from this location due to exposure. In this setting, direct cannulation through purse string may be required. Additionally, venting of the left side of the heart can be performed via placement of a cannula into the left atrium through the left atrial wall or the right superior pulmonary vein. This is done through a purse string, and a 20 French malleable vent can be used<sup>2</sup>. This can also be used to cross the mitral valve to place a true left ventricular vent. One downside to this approach is the potential for clot formation on this cannula that has significant length present in the intracardiac space.

### **3.3. Ambulatory peripheral VA ECMO**

Ambulatory ECMO can easily be accomplished by central cannulation as described above. However, central cannulation should be avoided unless absolutely necessary. Alternatively, one can perform venous drainage from the right internal jugular vein as described in “Techniques” section. Axillary artery outflow can be performed as described below. This will allow full-flow VA ECMO support without any femoral cannulas and can allow significant ambulation.

### **3.4. LV venting on ECMO**

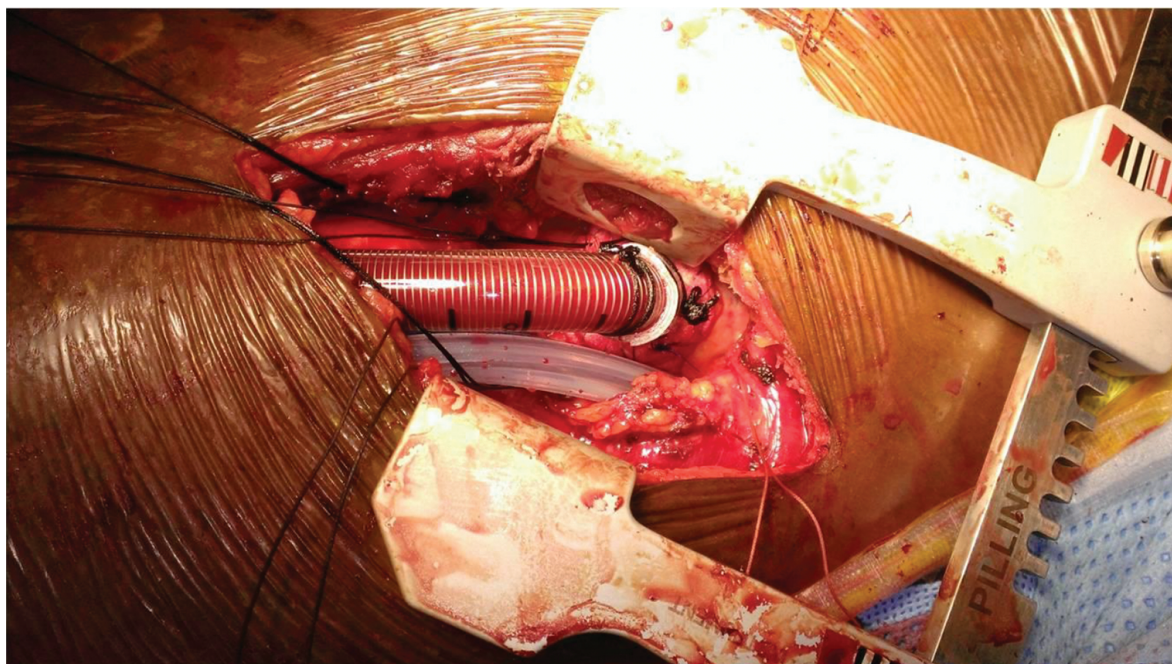
Left ventricular distention and the lack of LV unloading are some of the primary problems related to VA ECMO in the patient with LV failure. Though ECMO provides right atrial drainage, it cannot drain the left side of the heart directly. The blood, which bypasses the circuit in addition to the bronchial artery circulation, continues to fill the left atrium. The failing LV is unable to eject due to the high afterload created by the ECMO circuit. These factors combined lead to a full left ventricle and elevation of the left atrial pressure. Patients will in turn develop pulmonary edema and ongoing pulmonary hypertension which is deleterious to the right ventricle as well. LV distention is a common problem on ECMO and is often under-recognized. Venting of the left side can be performed in a variety of ways as detailed below. Two main categories of LV venting include percutaneous and surgical vents.

Percutaneous venting techniques are ideal when the need for venting is thought to be short in duration, and surgery may be less desirable due to antiplatelet therapy, liver dysfunction, and severe organ failure [2]. Classically balloon atrial septostomy has been performed, but this may not be universally efficacious. The use of the TandemHeart (CardiacAssist Inc., Pittsburgh, PA) transseptal cannula as a left atrial drainage to the ECMO circuit is another percutaneous technique. The transseptal cannula is inserted via the femoral vein and thus has the lowest bleeding risk of all techniques. Additionally there should not be any risk of limb ischemia. This cannula does create an atrial septal defect large enough to require closure at the time of LVAD implant. Operator expertise in transseptal puncture and hospital availability of the device are



two issues related to access to this technique. The Abiomed (Danvers, MA) Impella device is offered in a range of sizes and can be a very effective LV vent as well. LV venting does not require a large amount of flow, and typically the Impella CP device may provide adequate decompression of the LV cavity [3]. This is a micro-axial flow pump that traverses the aortic valve and pumps blood from the LV into the ascending aorta. It can be deployed from the femoral artery or the axillary artery. Again this can be a percutaneous technique, and thus bleeding risk may be lower than open surgery. However there is some risk of limb ischemia. Additionally there is an incidence of hemolysis and device migration/malposition that can occur.

Surgical vents can be placed via the LV apex or into the left atrium. Second or third interspace right anterior thoracotomy can be utilized not only for central ECMO cannulation and can also provide access to the interatrial groove for direct left atrial cannulation. A 20 French malleable vent can be placed into the left atrium through a purse string. This can even be advanced across the mitral valve. One must pay close attention to anticoagulation as this catheter may be at risk for developing thrombus due to its long intravascular length. An alternative method to provide direct LV cannulation is via a left anterolateral thoracotomy, similar to that performed for transapical Transcatheter aortic valve replacement (TAVR). A sewing cuff from Thoratec (Pleasanton, CA) (CentriMag® LV drainage cannula) is attached to the true apex of the heart with a running suture. The provided 34 French cannula is inserted via this sewing ring with its tip in the LV apex, and this is connected to the venous limb of the ECMO circuit. This cannula can support as much as 7 LPM of drainage, and it can be the basis of a temporary LVAD once ECMO support is no longer necessary (**Figure 1**) [4].



**Figure 1.** Apical LV vent/cannula via left anterior thoracotomy.

## 4. Technical aspects

### 4.1. Choice of cannulas

For venoarterial ECMO, one should choose cannulas that can provide a cardiac index of  $>2.4$  LPM/m<sup>2</sup>. In most adult patients, this will require 5 LPM or more. A 25 French venous cannula is adequate for most adults and will easily fit in most adults. A 19 French arterial cannula will support most adults. However, there are some patients, specifically smaller females, that cannot accommodate a cannula of this size and also do not require that degree of flow. In these cases lesser cannulas should be chosen based on ultrasound measurements of the common femoral artery and the desired flow rate for patient body size. For the antegrade superficial femoral artery cannula, a 5 French or 6 French sheath is adequate in every patient.

For venovenous ECMO one should typically choose the largest size cannulas that will fit into the planned cannulation sites. One desires about 80 % flow diversion on VV ECMO, and in septic patients, it can be difficult to predict the degree of flow required. As such, having larger cannulas can help to augment support as needed. In the case of single-site VV ECMO, we prefer to use the 31 French Avalon cannula in every patient, if the IJ vein will accommodate this. The only exception is when the VV ECMO is being used for CO<sub>2</sub> removal and not for oxygenation. In these cases smaller cannulas can be used. However VV ECMO most commonly is being used primarily for oxygenation support, where high flows are required. For dual-site VV ECMO, a 25 French drainage cannula is preferred, and a 19 French return cannula is preferred.

### 4.2. Peripheral cannulation: open vs percutaneous technique

Peripheral cannulation is the mainstay for most ECMO patients, regardless of disease process or support technique. Classically this was done by open technique, but now many centers have moved toward percutaneous technique as it may afford some advantages [5]. The authors feel that percutaneous technique should be applied whenever safe and feasible, though this may still be controversial. If placed with appropriate technique, cannulas placed percutaneously are likely more resistant to infectious issues. They are also less likely to have bleeding complications. Securing the cannulas so they cannot be dislodged is also easier with cannulas placed percutaneously. Even in the setting of ongoing CPR, if one is able to gain good visualization by ultrasound imaging, percutaneous cannulation can be a superior technique. Proper percutaneous cannulation requires an operator that is very familiar with ultrasound imaging of the femoral artery, femoral vein, and internal jugular vein. Open technique may be required when sidearm grafting is required due to vessel size or if percutaneous access to the vessels fails.

### 4.3. Percutaneous cannulation of the right internal jugular (R IJ) vein

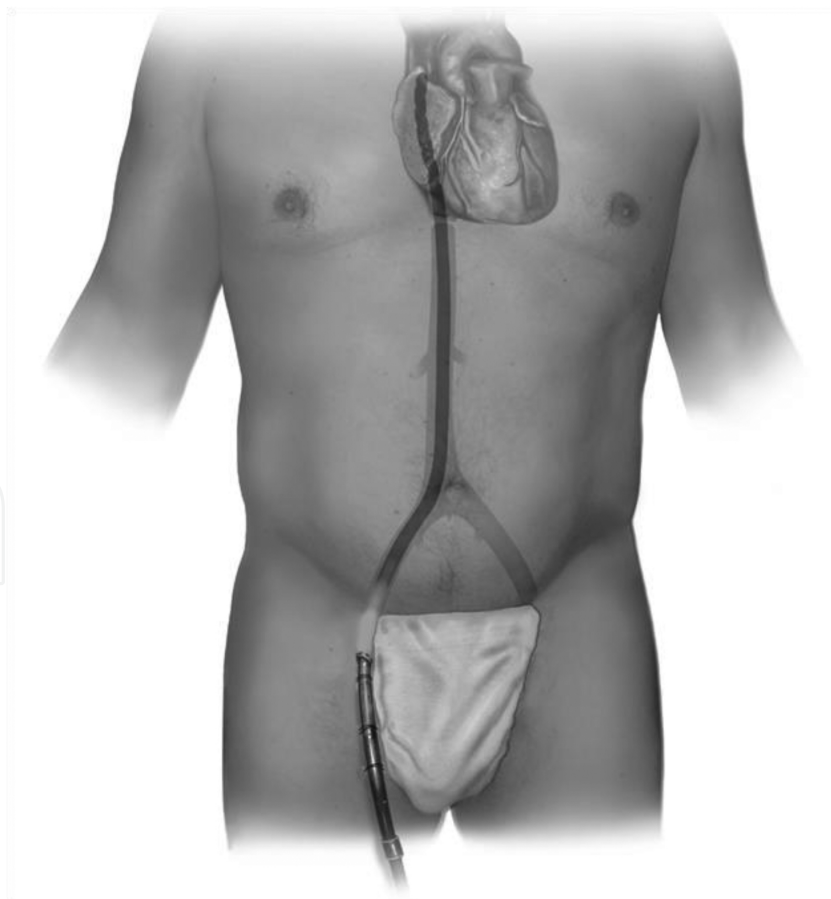
A 5 French micropuncture kit is used to access the R IJ vein under ultrasound guidance. A stiff wire similar to an Amplatz Extra Stiff 180 cm is passed through the micropuncture catheter under fluoroscopic guidance. R IJ cannulation is best done with fluoroscopy to ensure that the wire traverses into the abdominal IVC. If the wire does not go to the IVC, a pigtail or angled



catheter over the wire may be needed to direct the wire into the IVC. Again, fluoroscopy facilitates this much better than transesophageal echo. Once wire access is established into the IVC, the tract is dilated and the venous cannula is advanced. If the chosen venous cannula has a long segment of side holes as most do, the tip must be placed into the IVC so that all the side holes are inside the body. If the cannula has a limited section of side holes as with the Medtronic Bio-Medicus venous cannulas, then it can be left in the right atrium. This technique should not be used in the emergency setting and during CPR as it requires access to the neck and fluoroscopy to ensure safety.

#### 4.4. Percutaneous cannulation: femoral vein

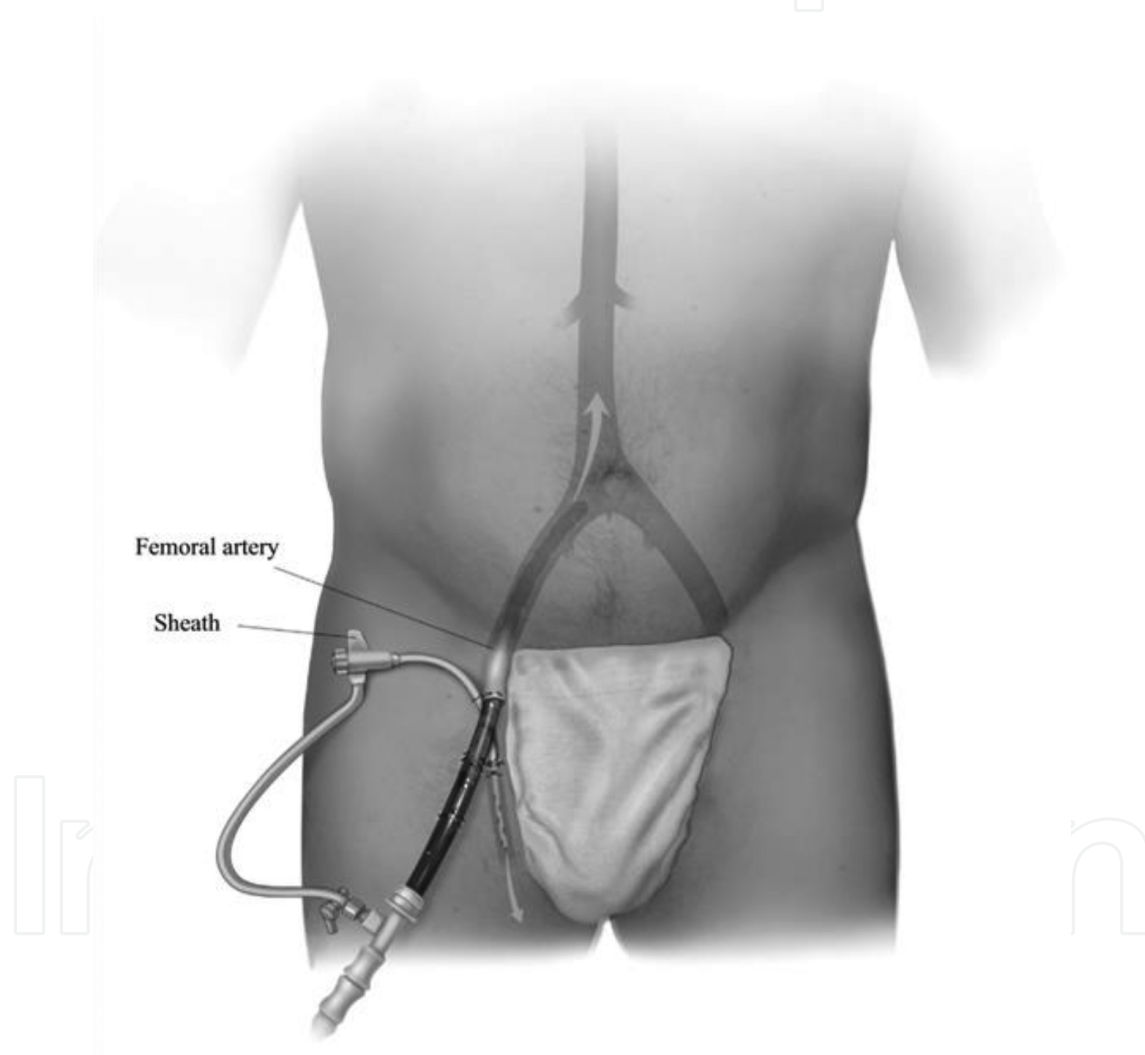
Under ultrasound guidance, a 5 French micropuncture kit is used to gain access to the common femoral vein on either side. A stiff wire such as Amplatz Extra Stiff 180 cm is advanced into the right atrium. Some type of guidance with transesophageal echo or fluoroscopy is preferred. However in the emergent setting, this can be done without guidance, accepting a lower level of safety. Serial dilation over the wire is performed, and the selected venous cannula is placed with its tip in the right atrium near the SVC junction (**Figure 2**).



**Figure 2.** Femoral venous cannulation for VA ECMO [4].

#### 4.5. Percutaneous cannulation for antegrade limb perfusion cannula

Under ultrasound guidance and PRIOR to access of the common femoral artery for cannulation, the antegrade limb perfusion cannula should be placed. Ultrasound is used to locate the bifurcation of the common femoral artery. The superficial femoral artery (SFA) is accessed in an antegrade fashion just past the bifurcation. The wire should pass freely down the leg. Fluoroscopy can be used to help guide this but not usually required. After the micropuncture catheter is placed, a guidewire is inserted and a 5 French sheath placed into the SFA. A segment of high-pressure tubing will later be used to connect this sheath to the Luer Lock port on the arterial cannula to allow circuit blood to perfuse the lower limb (**Figure 3**).



**Figure 3.** Femoral arterial cannulation with antegrade perfusion cannula [4].

#### 4.6. Percutaneous cannulation for common femoral artery

Ultrasound is used to measure the size of the common femoral artery. A cannula size is selected based on this dimension as well as the required flow rate. Ultrasound-guided access with a

5 French micropuncture is critical. A single stick to the artery with the micropuncture needle is preferred. Using large bore needles with failed punctures can lead to hematoma formation. A 0.035" stiff wire such as an Amplatz Extra Stiff 180 cm is advanced to the descending thoracic aorta under TEE or fluoroscopic guidance. Under emergent conditions this may have to be done without guidance. Serial dilation is performed, and the cannula is inserted deep enough that there is no risk that the side holes of the cannula can come outside the femoral artery (Figure 3).

#### 4.7. Open femoral cannulation and sidearm grafting

During CPR or in conditions where ultrasound guidance is not possible, cannulation via open approach may be required. An oblique incision is preferred, and the common femoral artery, common femoral vein, and superficial femoral artery are exposed. Purse strings are placed in each vessel and cannulas placed through skin tunnels for added security. This also allows for wound closure. Sidearm grafting of the femoral artery is also a good technique that can be used when the artery is small and may not accommodate an appropriate-sized cannula. The common femoral artery is controlled proximally and distally. An arteriotomy is made. A 10 mm Dacron graft is sewn to the artery in an end-to-side fashion using a small needle. This graft is de-aired and then can be cannulated with a 3/8" by 3/8" connector. This technique allows bidirectional flow in the femoral artery, and thus no distal perfusion cannula is required.

#### 4.8. Axillary artery direct cannulation

Although axillary artery can be cannulated directly for short-term access during cardiopulmonary bypass, it is not advisable in this situation. It can lead to arm ischemia and more bleeding problems.

#### 4.9. Axillary artery sidearm cannulation

Expose the axillary artery in standard technique paying extra attention toward hemostasis. Distal and proximal control can be obtained with clamps and/or vessel loops. Alternatively

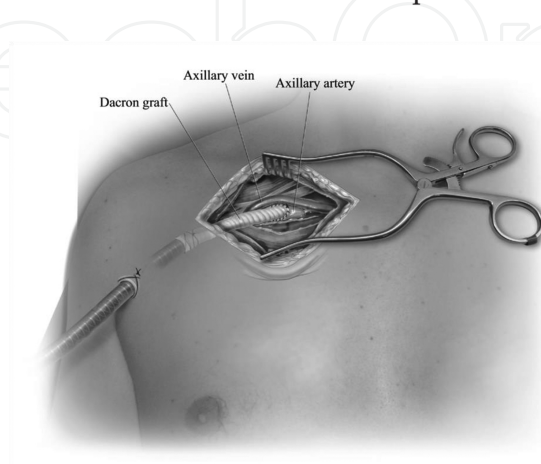


Figure 4. Axillary artery graft cannulation [4].

one can use a partial occlusion clamp without needing too much dissection, which is our preferred technique. A 10 mm Dacron graft is sewn to the artery using a small needle 6-0 or 5-0 polypropylene suture to minimize bleeding. Meticulous attention should be given toward hemostasis. A 32 French malleable venous cannula is tunneled from a small incision below the nipple in the anterior or midaxillary line into the axillary incision. Covering this with a glove tip or placing it inside a 36 French chest tube will prevent damage or debris from entering the lumen. The tip is cut off and inserted into the Dacron graft after de-airing. It is secured with multiple ties and positioned so that there is no kinking. A 32 French cannula will be connected to the arterial outflow of the ECMO circuit with a 3/8" by 3/8" connector (**Figure 4**).

#### **4.10. Aortic cannulation with sidearm graft**

Best exposure is using a full sternotomy but does lead to more bleeding problems early on. Upper hemi-sternotomy and right anterior thoracotomy can be used in some patients. After exposing the aorta, heparin is administered, and a partial clamp is placed after making sure there is no plaque by pre-op imaging by CT and ECHO or direct imaging using epiaortic ultrasound and digital palpation. Sew a 10 mm or larger graft in a beveled fashion using 4-0 or 5-0 polypropylene suture with small needles. A 32 French malleable venous cannula is tunneled up from the subxiphoid space (in the case of sternotomy) or anterior chest wall, one or two interspaces below the thoracotomy incision. Connection is made after de-airing between the graft and cannula with tip cut off. It is secured with multiple heavy ties. Secure it in such a way that there is no kinking of the graft and only the cannula is exiting the skin and not the graft.

#### **4.11. Central venous cannulation**

When using aortic approach for arterial cannulation, venous cannulation can also be done without having to resort to peripheral placement. Through the same incision, a 36 French malleable venous cannula or a 32 French angled metal-tipped cannula can be placed into the right atrium with purse-string sutures on the appendage. Care should be taken to place more than one suture, and leave all the side holes of the plastic cannula well inside the atrial cavity to avoid sucking air. The purse-string suture "keepers" are tied to the cannula with several heavy sutures. Cannula must be tunneled from the exit site prior to inserting into the atrium. Cannula is then de-aired and connected to the venous side of the ECMO circuit with a 3/8" by 3/8" connector (**Figure 3**).

### **5. Securing the cannula**

Cannulas are secured to the skin using #1 braided suture. Four sutures should be used to secure each cannula to avoid inadvertent dislodgement, which is universally catastrophic. Inspect the sutures every few days, and place additional sutures if necessary, especially after patient starts ambulation in cases of central ECMO.



## 6. Management of cannulation site bleeding

Percutaneous peripheral cannulation sites seldom bleed. Most of the bleeding is seen with manipulation and can be controlled with securing the cannula better. Sometimes a “U” stitch around the insertion site is required to stop the bleeding. Some bleeding is universally seen in all open incisions. Reversing the heparin with protamine and surgical hemostasis can control most bleeding. Topical hemostatic agents can be used on the anastomotic suture lines. If there is ongoing oozing, we prefer to place a negative therapy wound vacuum system. Bleeding usually stops within 24–48 h, and we return to the operating suite to close the incisions.

## 7. Conclusions

This chapter provides simple instructions for various types of cannulation options for VA and VV ECMO as well as LV venting. Types of cannulas used are not necessarily endorsement of the products but just what we use. Any other manufacturers’ cannula can be used with some modifications.

## Author details

Chand Ramaiah\* and Ashok Babu

\*Address all correspondence to: [chand.ramaiah@sth.org](mailto:chand.ramaiah@sth.org)

Saint Thomas West Hospital, Nashville, TN, USA

## References

- [1] Hryniewicz K, Sandoval Y, Samara M, Bennett M, Cabuay B, Chavez IJ, Seatter S, Eckman P, Zimbwa P, Dunn A, Sun B. Percutaneous veno-arterial extracorporeal membrane oxygenation for refractory cardiogenic shock is associated with improved short and long term survival, *ASAIO J*. 2016 Apr 4, [Epub ahead of print]
- [2] Alkhouli M, Narins CR, Lehoux J, Knight PA, Waits B, Ling FS. Percutaneous decompression of the left ventricle in cardiogenic shock patients on venoarterial extracorporeal membrane oxygenation. *J Card Surg*. 2016 Mar, 31(3):177–182. doi: 10.1111/jocs.12696. [Epub 2016 Jan 25].
- [3] Keenan JE, Schechter MA, Bonadonna DK, Bartz RR, Milano CA, Schroder JN, Darneshmand MA. Early experience with a novel cannulation strategy for left ventricular

decompression during non-postcardiotomy venoarterial ECMO. *ASAIO J.* 2016 Jan 5. [Epub ahead of print]

- [4] Babu, A. Techniques for venoarterial extracorporeal membrane oxygenation support and conversion to temporary left ventricular assist device. *Oper Tech Thorac Cardiovasc Surg.* 2014, 19(3):365–379
- [5] Napp LC, Kühn C, Hoepfer MM, Vogel-Claussen J, Haverich A, Schäfer A, Bauersachs J. Cannulation strategies for percutaneous extracorporeal membrane oxygenation in adults. *Clin Res Cardiol.* 2016 Apr, 105(4):283–296. doi: 10.1007/s00392-015-0941-1. [Epub 2015 Nov 25]
- [6] CentriMag® pump: <http://www.thoratec.com/medical-professionals/vad-product-information/thoratec-centrimag.aspx>
- [7] Centrimag® LV Drainage cannula: <http://www.thoratec.com/medical-professionals/resource-library/ifus-manuals/thoratec-centrimag.aspx#>
- [8] Micropuncture access kit: <https://www.cookmedical.com/products/e4790704-1c72-48bc-95f7-6c5bd6ea3b53/>
- [9] Avalon Dual lumen catheter: [http://www.maquet.com/globalassets/downloads/products/avalon-elite/avalonelite\\_mcp\\_br\\_10012\\_en\\_1\\_screen.pdf](http://www.maquet.com/globalassets/downloads/products/avalon-elite/avalonelite_mcp_br_10012_en_1_screen.pdf)
- [10] Biomedicus cannulas: <http://www.medtronic.com/mics/cannulae/products.html>

