

We are IntechOpen, the world's leading publisher of Open Access books Built by scientists, for scientists

4,800

Open access books available

122,000

International authors and editors

135M

Downloads

Our authors are among the

154

Countries delivered to

TOP 1%

most cited scientists

12.2%

Contributors from top 500 universities



WEB OF SCIENCE™

Selection of our books indexed in the Book Citation Index
in Web of Science™ Core Collection (BKCI)

Interested in publishing with us?
Contact book.department@intechopen.com

Numbers displayed above are based on latest data collected.

For more information visit www.intechopen.com



The Advantages and Limitations of Ultrasound Elastography in Diagnosis of Thyroid Carcinoma

Nazan Ciledag, Hidir Kaygusuz, Burcu Sahin,
Elif Aktas, Fatma Gul Buyukbayraktar Imamoglu and
Bilgin Kadri Aribas

Additional information is available at the end of the chapter

<http://dx.doi.org/10.5772/64407>

Abstract

Thyroid nodules have high prevalence in the general population. Only minorities of thyroid nodules are malignant; nevertheless, still biopsies are performed in differential diagnosis of malignant and benign thyroid nodules. Conventional ultrasound is widely used in diagnosis and characterization of thyroid nodules. There are several suspicious ultrasound features that predict thyroid cancer, such as solid consistence, marked hypoechogenicity, taller-than-wide shape, irregular or microlobulated or spiculated margins, no peripheral hypoechoic halo, and micro- or macrocalcifications. However, none of these signs have high sensitivity or specificity nor high degree of confidence for diagnosis or exclusion of thyroid carcinoma. Ultrasound elastography, recently developed, promising, noninvasive technique that evaluates tissue stiffness, has become one of the main focuses in thyroid imaging. There are two ultrasound elastography methods: strain ultrasound elastography (also known as real-time elastography or qualitative elastography) and shear wave elastography (quantitative elastography and acoustic radiation force impulse imaging). The purpose of this chapter is to present the principles of thyroid application, advantages, and limitations of both ultrasound elastography techniques.

Keywords: malignant thyroid nodules, ultrasound elastography, shear wave elastography, strain ultrasound elastography, acoustic radiation force impulse imaging

1. Introduction

Thyroid nodules are a common medical problem. Although the majority of the thyroid nodules are benign, malignancy has a prevalence of 5–15% [1, 2]. Conventional ultrasound is accurate in the detection of thyroid nodules. There are several suspicious ultrasound features that predict a malignant thyroid nodule, such as hypoechogenicity, marked hypoechogenicity, a microlobulated or spiculated margin, punctate micro- or macrocalcifications, a taller-than-wide shape, and intranodular vascularization [3, 4]. Although conventional ultrasound is an excellent tool for detecting thyroid nodules, it has a relatively low diagnostic performance for the differentiation between benign and malignant nodules [5–7]. For this reason, ultrasound-guided fine-needle aspiration (FNA) is required for the nodules greater than 10 mm or those with suspicious ultrasound signs that have a high specificity for malignancy (60–98%), but FNA cannot be performed for all thyroid nodules because they are extremely common and approximately 5% of them are malignant [8, 9]. Furthermore, even for nodules undergoing ultrasound-guided FNA, the sensitivity for malignancy may be suboptimal (54–90%) because the specimens may be inadequate, nonrepresentative, or indeterminate for histopathologic examination especially in the case of follicular lesions [10–13]. As a result, a significant number of patients eventually receive unnecessary thyroid surgery. Therefore, improvement of a noninvasive diagnostic method for malignant nodules diagnosis is needed.

As the malignancies change, the mechanical properties of the soft tissue, such as tissue hardness and tissue stiffness evaluation, have become a part of nodular characterization. Ultrasound elastography, which was introduced in the 1990s, provides real-time information regarding the tissue elasticity and allows *in vivo* assessment of the tissue's mechanical properties, mapping of tissue stiffness, and characterization of soft tissue lesions [14]. Ultrasound elastography has become a promising, noninvasive technique to depict malignant nodules. Ultrasound elastography is based on the principle that, under compression, the softer parts of tissues deform easier than the harder parts [15]. The American Thyroid Association guidelines in 2009 stated that ultrasound elastography is an emerging and promising technique that requires additional validation with prospective studies [16]. Real-time strain ultrasound elastography was the first technique used, based on the measurement of the degree of tissue deformation as a response to an external force with a compression induced by the ultrasound probe that was then replaced by carotid internal excitation allowing improvement in sensitivity. Calculated tissue elasticity is displayed as a color map (elastogram) overlay of the conventional B-mode image. Elastograms allow qualitative analysis of the nodule. As a semiquantitative parameter, the strain index or the strain value ratio is calculated from the comparison between the tissue elasticities in the regions of interest (ROI) within a lesion and the surrounding reference tissue therefore providing useful analytic information. However, real-time strain ultrasound elastography has some limitations such as high operator skill dependence, inevitable intra- or inter-observer variability, and the impossibility of quantitative analysis. To overcome these limitations, a new ultrasound elastography technique based on shear wave has been developed. In comparison to the above technique shear wave elastography is a quantitative, operator-independent and reproducible technique. Shear wave ultrasound elastography is based on the propagation of acoustic

force impulse induced by ultrasound beams through soft tissue to displace tissue and create shear waves that represent the local viscoelastic properties of the tissue and is displayed as Young's modulus (kPa) [18, 19]. Stiffer tissue exhibits a higher Young's modulus. Shear wave elastography allows quantitative nodules stiffness analysis in kilopascals to reinforce the predictive value of malignancy.

2. Physical principles and technique of ultrasound elastography

2.1. Real-time strain ultrasound elastography

Real-time strain ultrasound elastography is the most widely available type of ultrasound elastography. This is a dynamic imaging technique that reveals the physical properties of soft tissue by characterizing the differences in stiffness between the region of interest and the surrounding tissue through measuring the degree of tissue deformation under the application of external force applied by ultrasound probe or by physiological movements (e.g., carotid pulsation) (**Figure 1**). Tissue deformation occurring after compression and decompression period is calculated semiquantitatively via the Young's modulus and displayed graphically in color code or gray scale in the elastograms. The degree of deformation of the underlying soft tissue is calculated to estimate tissue stiffness with both the strain ratio/strain index values and elastographic maps (elastograms). In this technique, a vertical force should be performed uniformly and repeatedly in a vertical direction with a light pressure, and compression periods are followed by decompression resulting in changes in dimensions and shape, which are then used to calculate the stiffness of the tissue. The quality of the operator's free-hand pressure is

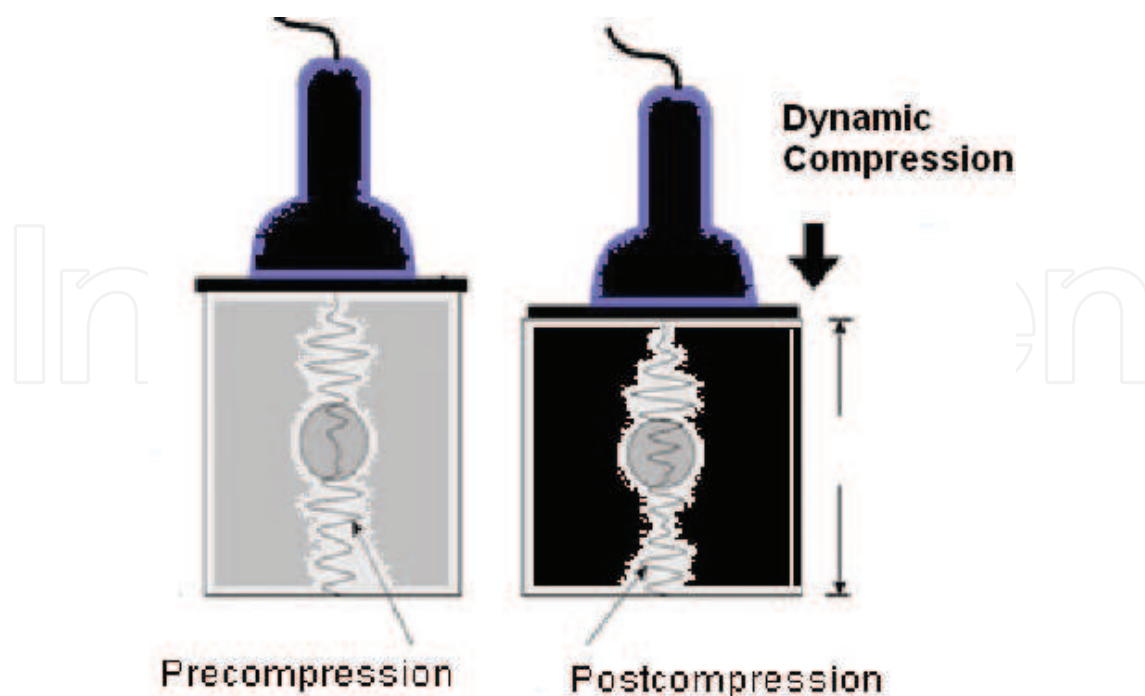


Figure 1. A diagram of the static ultrasound elastography.

visualized on the screen as a sine-wave or displayed with a numerical scale, allowing the operator to assess the validity of the compression cycles in real-time. For computing strain images without noise, a light and cyclic probe pressure must be performed [2, 17]. Stiff, rigid nodules exhibit less displacement compared with elastic, soft ones. An elliptic, or rounded region of interest (ROI), is used, large enough to include the entire nodule as well as a large portion of the surrounding thyroid and perithyroid tissue. This technique allows a qualitative and a semiquantitative assessment of nodule elasticity. Qualitative analysis of a nodule based on the prevalent color in the nodule can be obtained from visual scoring of colors within the color-coded elastographic map (elastogram) [17, 18]. Elastograms may be presented in gray scale or in color by different manufacturers. The hard tissue may be coded in light or red or blue code depending on the manufacturer.

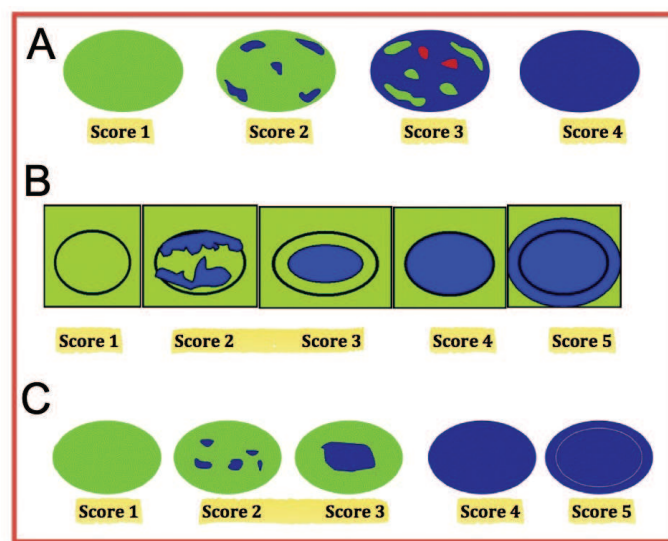


Figure 2. (A) Strain elastographic scores by Asteria et al. [19]. A score of 1 indicated elasticity in the entire examined area. A score of 2 indicated elasticity in a large part of the examined area. A score of 3 indicated stiffness in a large part of the examined area. A score of 4 indicated a nodule without elasticity. (B) Strain elastographic scores by Rago et al. [20]. A score of 1 indicated even elasticity in the whole nodule. A score of 2 indicated elasticity in a large part of the nodule. A score of 3 indicated elasticity only at the peripheral part of the nodule. A score of 4 indicated no elasticity in the nodule. A score of 5 indicated no elasticity in the nodule or in the area showing posterior shadowing. (C) Strain elastographic scores by Ueno et al. [21]. A score of 1 indicated even strain for the entire hypoechoic lesion (i.e., the entire lesion was evenly shaded in green). A score of 2 indicated strain in most of the hypoechoic lesion, with some areas of no strain (i.e., the hypoechoic lesion had a mosaic pattern of green and blue). A score of 3 indicated strain at the periphery of the hypoechoic lesion, with sparing of the center of the lesion (i.e., the peripheral part of lesion was green, and the central part was blue). A score of 4 indicated no strain in the entire hypoechoic lesion (i.e., the entire lesion was blue, but its surrounding area was not included). A score of 5 indicated no strain in the entire hypoechoic lesion or in the surrounding area (i.e., both the entire hypoechoic lesion and its surrounding area were blue).

The three principal scoring systems are those classified by Asteria et al. [19], Rago et al. [19], and Itoh et al. [21] (**Figure 2**). The first scoring system, based on the breast strain real-time ultrasound elastography scale of Itoh et al. [21], includes four different patterns [19]. Asteria's criteria defined a score of 1 as elasticity that is entirely soft in the nodule, 2 as mostly soft in the nodule, 3 as mostly hard in the nodule, and 4 as entirely hard in the nodule [19]. The thyroid nodules with scores 1 and 2 are considered benign and those with scores 3 and 4 are classified

as suspicious for malignancy [19]. However, some authors have found that assigning benignity to score 3 further increases the specificity of the method for cancer detection [22].

In Ueno's classification, color coding of elastograms was in five groups [21]. The score 1 indicated strain for the entire lesion (the entire lesion was evenly shaded in soft color code). The score 2 indicated strain in most of the lesion with some areas of no strain (a mosaic color pattern). The score 3 indicated strain at the periphery of the lesion, with sparing of the center of the lesion (the peripheral part of the lesion was soft, and the central part was harder). The score 4 indicated no strain in the entire lesion (the entire lesion was in hard color code, but its surrounding area was not included). The score 5 indicated no strain in the entire lesion or in the surrounding area (both the entire lesion and its surrounding area were in hard color code). Scores of 4 and 5 are classified as suspicious for malignancy.

Rago et al. used five-point scales based on Itoh et al.'s [21] study using strain elastography. A score of 1 defined elasticity that is entirely soft in the nodule, 2 as mostly soft in the nodule, 3 as peripherally soft, 4 as entirely hard in the nodule, and 5 as hard in the area under consideration as well as the entire nodule [20]. The first three scores are considered as suggestive of being benign and scores of 4 and 5 are classified as suspicious for malignancy.

Rubaltelli et al. used a modified Asteria scale for thyroid nodules [23]. It consists of a five-step system that divides Asteria score 3 into patterns 3A and 3B, with a scale description as follows. Pattern 1: the entire nodule section is diffusely elastic. Pattern 2: the formation appears to be largely elastic with the inconstant appearance of inelastic areas during the real-time imaging. Pattern 3: constant presence of large inelastic areas is seen at the periphery (Pattern 3A) or center (Pattern 3B) of the formation. Pattern 4: uniformly displayed inelasticity throughout the whole nodule. Lesions that present Pattern 1 or 2 are classified as probably benign, while Patterns 3 and 4 are indicative of probable malignancy.

For semiquantitative analysis of the elasticity (the strain ratio or strain index), two similar sized regions of interest (ROI) at similar depth from the transducer (depth difference should be less than 10 mm) are drawn over the target region (nodule strain) and the adjacent reference normal parenchyma (the strain of the softest part of the surrounding normal tissue), respectively, then the strain ratio is automatically calculated through the machine. Three different measurements should be undertaken, and their average should be considered as the final value [24].

Main causes of false positive results of strain ratio measurement are transverse scans of the thyroid lobe (due to the interference with carotid artery pulsations); the ROI including the carotid artery or other neighboring tissues (therefore, it is difficult to apply in multinodular goiter); nodules located in the lower pole or in the isthmus are difficult to compress and to compare with normal parenchyma; irregular shaped, large nodules (due to the lack of comparable size reference tissue, nonuniform nodule compression, areas with altering stiffness may lead to false results); performing real-time strain ultrasound elastography with a high pressure may alter results (during whole examination period, slight, constant pressure over tissue should be applied [24]); microcalcifications in benign nodules; subacute thyroiditis; fibrosis and atypical adenoma may induce false positive [25, 26]; microcarcinomas show lower strain ratio values, between 1.74 and 2.96, and may be easily misdiagnosed [24].

Among the cited causes for false negative results of strain ratio are the following: follicular carcinoma, very well-differentiated carcinoma, carcinoma with central necrosis and degeneration, small papillary carcinoma in lymphoma, and microcarcinoma [27].

Lyshchik et al. reported the cutoff value >4 for malignancy yielded sensitivity of 82%, specificity of 96%, and accuracy 92% [27]. Xing et al. reported the cutoff value >3.79 for malignancy yielded sensitivity of 97.8%, specificity of 85.7%, positive predictive value of 88%, and negative predictive value of 97.8% [25]. Ning et al. reported the cutoff value >4.25 for malignancy yielded sensitivity of 81.8%, specificity of 82.9%, and accuracy 88% [25]. Cantisani et al. reported the cutoff value >2.02 for malignancy yielded sensitivity of 93% and specificity of 92% [28].

An alternative approach for strain ratio evaluation of large nodules or thyroiditis cases (the ones with the lack of adjacent reference normal thyroid parenchyma) is the use of nodule to sternocleidomastoid muscle strain value assessment. In this approach, the adjacent muscle at similar depth was used as a reference tissue, instead of the normal thyroid parenchyma. Kagoya et al. [29] reported that, a value >1.5 showed 90% sensitivity and 50% specificity for cancer. Ciledag et al. [30] reported a cutoff value >2.31 provided 85.7% sensitivity, 82.1% specificity, and 82.4% accuracy .

2.2. Shear wave elastography

Shear wave ultrasound elastography is a recently developed imaging technique that is based on the propagation of acoustic force impulse induced by ultrasound beams through soft tissue to displace tissue and create shear waves (**Figure 3**) [31]. Shear waves are the transverse components of particle displacement that are rapidly attenuated by the tissue. These acoustic pulses can be focused at different depths in soft tissue at supersonic speed and enhanced by forming a Mach cone, which increases the shear wave propagation to obtain the Young's modulus. The Young's modulus gives a local assessment of tissue elasticity at the point of interest. It gives a local real-time measurement of tissue elasticity quantitatively in kilopascal units (kPa) as measured in shear wave velocity units (m/sec) and qualitatively in real-time

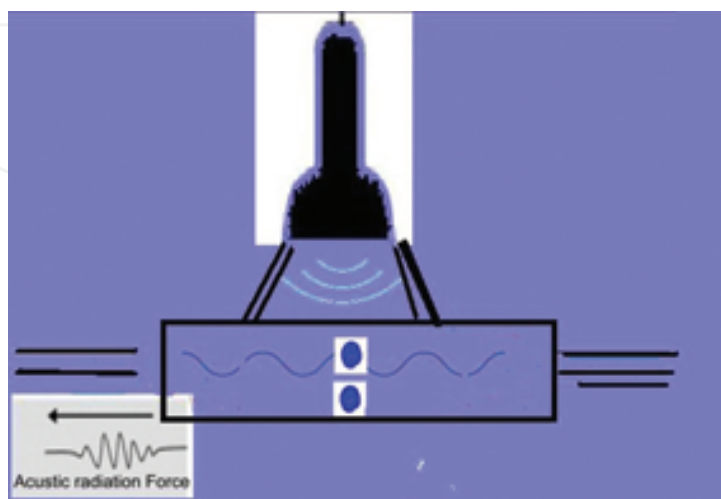


Figure 3. A diagram of the physical interaction of shear wave ultrasound.

color coded elastograms. On an elastogram within a given ROI, a variety of stiffness parameters can be measured, including the mean stiffness (E_{mean}), maximum stiffness (E_{max}), and standard deviation (SD). In both the shear wave imaging techniques, semiquantitative analysis of the elasticity (the strain ratio or the strain index) may be measured.

2.3. Methodology of shear wave elastography

There are two methods for shear wave elastography of the clinical practice of thyroid nodules: the supersonic shear wave and the acoustic radiation force impulse methods. Supersonic shear wave ultrasound elastography uses focused ultrasonic beams that propagate through the entire imaging area. The elasticity is expressed as in meters per second (m/s) and does not display color-coded images for elastography.

The examination is performed with the patient placed in the same manner as for the conventional ultrasound. The acoustic radiation force impulse imaging technique is integrated in a conventional ultrasound system using a 9–12 MHz linear transducer. The shear wave elastography (supersonic shear wave elastography) technique using a linear probe (4–15 MHz). The probe is gently placed on the cervical skin surface with slight pressure on the thyroid. The patient is asked to hold the breath and the quantitative evaluation is turned on. In acoustic radiation force impulse imaging technique, the ROI, should be placed in thyroid tissue or within the solid component of a nodule, avoiding cystic areas or those with calcifications. For the assessment of a nodule, it is recommended not to include the adjacent thyroid parenchyma. The displayed color-coded image shows soft tissue in blue and rigid tissue in red. After acoustic radiation force impulse activation, the velocity is displayed on the screen, with the depth measurement. Five to ten valid measurements should be performed to obtain reliable values. After activation of shear wave elastography, the quantitative information is assessed as the elasticity index in kiloPascal. In shear wave elastography it is important to set the machine for optimal image acquisition and set the elasticity index range on the thyroid preset protocol to 0–180 kPa. For shear wave elastography measurements, the whole nodule should be placed within the Q box with a small amount of surrounding thyroid tissue. Due to the technical limitations on cystic lesions, the shear wave velocity cannot be measured (shear waves do not propagate in fluids). At least three cine-loops, lasting 10 s each, for each lesion should be obtained for a reliable evaluation.

The major advantages of this technique are operator independence, reproducibility, and the ability of semiquantitative, quantitative, and qualitative evaluation of tissue elasticity without manual compression artifacts.

Shear wave elastography has been used to evaluate the elasticity values of different tissues such as breast, thyroid, lymph nodes, muscles, and the abdominal organs such as the liver and pancreas.

Limitations and causes of false results of shear wave elastography are the contact and the pressure applied on the neck of the patient via the operator's hand that could alter the measurements (a generous amount of ultrasound gel should be used to avoid this artifact); in shear wave elastography technique, the elasticity of the structures is influenced by the external

pressure applied, the stiffness rising with increasing pressure due to the nonlinear elastic effect artifact (due to this artifact, in the isthmus nodule, the stiffness is increased because of the neighboring trachea) [32]; in acoustic radiation force impulse imaging technique, the size of the nodule is a limitation because the ROI size is standard (5 mm × 6 mm or 2 cm × 2 cm) and cannot be changed (in acoustic radiation force impulse imaging technique, ROI contains both nodule and surrounding thyroid parenchyma so that the value of the velocity of the nodule will not be real); nodules with fluid areas or calcifications should be excluded due to the impossibility to place the ROI inside the parenchyma of the nodule [33, 34]. In the acoustic radiation force impulse imaging technique, penetration depth is limited to 5.5 cm, so large thyroids or very large and deep located nodules cannot be properly assessed [35]; the impossibility to measure velocities higher than 9 m/s is another limitation of acoustic radiation force impulse imaging technique, thus very hard nodules will not be measured properly [28].

Zhang et al. showed that for differentiation between benign and malignant nodules, the diagnostic performance of measured ultrasound (US) wave velocity is better for a nodule diameter greater than 20 mm [36]. Zhang et al. [36] reported the cutoff value >2.87 for malignancy yielded sensitivity of 75% and specificity of 82.2%. Han et al. [37] reported that the best cutoff value of velocity for differentiation between benign and malignant is 2.75 m/s.

Veyrieres et al. [34] reported the cutoff value of >66 kPa for malignancy yielded sensitivity of 80%, specificity of 90.5%, positive predictive value of 52.8%, and negative predictive value of 99.3%.

3. Clinical application of elastography in thyroid nodules

In clinical practice, elastography is usually performed as an extension of conventional ultrasound and not as an independent test. Therefore, a comparison of conventional ultrasound with elastography can be meaningless in view of its current clinical utility. The value of elastography should be evaluated by comparing the conventional US with a combination of conventional US and elastography.

4. Basic technique requirements for ultrasound elastography of thyroid nodules

During real-time ultrasound elastography, breath holding and no swallowing are of paramount importance for correct evaluation. A generous amount of gel and slight skin contact are needed. The image focus should be placed at or below the level of the nodule. The examiner applies slight and regular manual axial (anterior-posterior) vibration to the transducer. It is impossible to measure and quantify exactly the initial compression as well as the compression that induces repeated tissue strain.

For standardization of the compression and for the reproducibility, most manufacturers provide a strain quality indicator, either numeric or graphic. On Hitachi machines, the

compression quality scale should indicate levels 3–4. Only images obtained at these quality levels are fit for assessment. On Siemens machines, a quality factor above 50 for 3–4 successive frames has been recommended. Choosing the shortest, the exploratory ultrasound beam path to the nodule is important for optimal ROI placement to avoid strain decay with distance. The elastographic ROI should cover whole nodule. It is also important to exclude from the ROI, as much as possible, the vessels (mainly carotid), the esophagus, trachea, bones, and muscles. It is always important to keep in mind that real-time strain ultrasound elastography displays the relative strain of the structures in the ROI. The absolute value of the strain depends on the initial compression applied by the transducer (variable and nonquantifiable) and on the exploring repeated compression used to produce the images—again, variable. Strain values do not represent the elasticity modulus. As strain changes with the applied compression, its absolute (numeric) value (although measured and displayed by some machines) is completely inappropriate to compare two lesions or two individuals. Quite often there is interference between the pulsations induced by the hand or by the US beam and the ones coming from the carotid artery, which leads to image degradation. On the other hand, lateral systolic expansion of the carotid artery pulsation compresses the thyroid nodule against the trachea and induces anterior-posterior expansion of the gland that may be detected as strain. At least one commercially available application developed by Samsung Medison uses carotid artery pulsations as the sole strain inductor for elastography.

Technical causes of limitations of real-time strain ultrasound elastography of thyroid applications are

Scanning plane and interference with carotid pulsation is one of the limitations of ultrasound elastographic application of thyroid nodules. Transverse scans through the thyroid are more susceptible to interferences from carotid pulsation, and therefore, less suitable for real time strain ultrasound elastography. Longitudinal scans are less susceptible to carotid artery pulsations and also offer larger thyroid reference tissue.

Scan slice thickness should be around 5 mm since a thicker sample volume induces averaging the data of both small nodule and neighboring thyroid tissue, which lead to false elasticity results. This limitation is not an issue for highly focused transducers. Having a ROI as large as possible is important to include in much normal tissue, less than 50% green thyroid reference parenchyma in the ROI may result in false results. On the other hand, if possible, avoiding the inclusion of vessels, bones, and other nonthyroid tissues in ROI is important. Out-of-plane of the nodule during compression and color loss artifact in the nodule are other limitations.

Nodule location is very important in elastographic evaluations. Anterior nodules, protruding to the capsule, may be mislabeled as soft because strap muscles represent the reference tissue, not the thyroid parenchyma. Isthmic nodules are also difficult to assess because of the nodule compression difficulties between the hard planes (transducer and trachea) and lacking reference tissue. Also deeply located nodules present difficulties due to the stress decay phenomenon. Stress transmission is reduced as the distance from the transducer increases. Less tissue dislocation in deep portions of the thyroid will induce a hardening artifact. The nodules located in front of the common carotid artery are the most susceptible to pulsation interferences. Nodules within residual parenchyma lack reference tissue for comparison.

Elastography is not suited for nodules with a diameter less than 5 mm [38, 39], although the exact lower limit of the diameter for real-time strain ultrasound elastography usability is not known [40]. Elastography is also unsuitable for nodules larger than 3 cm or lobar size nodules cannot be encompassed by the reference thyroid tissue and are not suitable for real-time strain ultrasound elastography [40].

Intranodular calcification is associated with increased stiffness irrespective of underlying pathology and results in false elasticity values.

Fibrosis associated with subacute thyroiditis or Hashimoto thyroiditis may increase nodule stiffness [28, 41].

Necrosis, even without liquefaction, may induce soft areas. Intranodular colloid cystic changes: the presence of fluid inside the nodule changes the real-time strain ultrasound elastography appearance of the nodule [28, 38]. Only the solid component of the partially cystic nodules can be assessed accurately with real-time strain ultrasound elastography.

Nodule pathology is highly correlated with real-time strain ultrasound elastographic appearance of nodules. Of all thyroid cancers, mostly the papillary type is expected to appear hard, providing only 7% false negative results [40]. Follicular cancer may appear elastic and as do other types of malignancy. Contrarily, some benign nodules may be hard. Papillary carcinoma is harder than follicular or medullary carcinoma; therefore, there is no optimal cutoff value for predicting microcarcinoma. This leads to lower sensitivity but higher specificity [42]. Carneiro-Pla [43] reported that the majority of microcarcinomas were missed by the shear wave elastography examination.

Additional technical causes of limitations of real-time strain ultrasound elastography are [44] the physicians' skill and experiences, arbitrary selection of a color scale, neighbor arterial pulsation artifacts, using different qualitative scoring systems with lack of standardization, and manual, arbitrary selection of elastograms' representative image leading to subjectivity [28, 45].

In summary, the main causes for false-positive real-time strain ultrasound elastographic diagnoses of thyroid cancer are calcification, fibrosis, thyroiditis (subacute/chronic/Hashimoto thyroiditis), nodules larger than 3 cm or lobar size nodules, and deep location of nodules. Main causes for false negative real-time strain ultrasound elastographic diagnoses of thyroid cancer are follicular/medullary/nondifferentiated/metastatic cancer, anterior subcapsular/isthmic location of nodule, nodules larger than 3 cm, lobar size nodules with the lack of reference normal thyroid parenchyma around the nodule, or necrotic nodules [26].

5. Conclusion

Ultrasound elastography of thyroid nodules is an easy, completely painless, and rapid technique that assesses hardness as an indicator of malignancy. Ultrasound elastography is not an alternative imaging technique to conventional ultrasound, but it is an additional

methodology that can be integrated into the conventional ultrasound examination to increase the accuracy, the positive predictive value, and the negative predictive value of conventional ultrasound. The addition of this methodology can reduce the number of patients pursuing unnecessary biopsy. US elastography can also be considered as a reliable screening tool for characterizing thyroid nodules. An elasticity score of 1 is indicative of benign pathology in almost all cases and can be used to exclude many patients from further invasive assessments. Ultrasound elastography has a considerable potential in diagnosis of thyroid malignancies, especially in cytological indeterminate and nondiagnostic nodules.

Author details

Nazan Ciledag^{1*}, Hidir Kaygusuz¹, Burcu Sahin¹, Elif Aktas¹,
Fatma Gul Buyukbayraktar Imamoglu² and Bilgin Kadri Aribas¹

*Address all correspondence to: drnazangokbayrak@yahoo.com.tr

1 Radiology Department, Dr. Abdurrahman Yurtaslan Ankara Oncology Research and Education Hospital, Ankara, Turkey

2 Radiology Department, Ataturk Research and Education Hospital, Ankara, Turkey

References

- [1] W.M. Tumbridge, D.C. Evered, R. Hall, D. Appleton, M. Brewis, F. Clark, J.G. Evans, E. Young, T. Bird, and P.A. Smith. The spectrum of thyroid disease in a community: the Whickham survey. *Clinical Endocrinology* 1997; 7: 481–493.
- [2] V. Cantisani, H. Grazhdani, E. Drakonaki, V. D'Andrea, M. Di Segni, E. Kaleshi, F. Calliada, C. Catalano, A. Redler, L. Brunese, F. M. Drudi, A. Fumarola, G. Carbotta, F. Frattaroli, N. Di Leo, M. Ciccariello, M. Caratozzolo, and F. D'Ambrosio. Strain US elastography for the characterization of thyroid nodules: advantages and limitation. *International Journal of Endocrinology*. 2015, Article ID 908575, pp. 8 <http://dx.doi.org/10.1155/2015/908575>
- [3] Kim E.K., Park C.S., Chung W.Y., Oh K.K., Kim D.I., Lee J.T., et al. New sonographic criteria for recommending fine-needle aspiration biopsy of nonpalpable solid nodules of the thyroid. *American Journal of Roentgenology* 2002;178:687–691.
- [4] Moon W.J., Baek J.H., Jung S.L., Kim D.W., Kim E.K., Kim J.Y., Kwak J.Y., Lee J.H., Lee Y.H., Na D.G., Park J.S., and Park S.W. Ultrasonography and the ultrasound-based management of thyroid nodules: consensus statement and recommendations. *Korean Journal of Radiology* 2011;12:1–14.

- [5] J.D. Iannuccilli, J.J. Cronan, and J.M. Monchik. Risk for malignancy of thyroid nodules as assessed by sonographic criteria: the need for biopsy. *Journal of Ultrasound in Medicine* 2004;23(11): 1455–1464.
- [6] J.K. Hoang, K.L. Wai, M. Lee, D. Johnson, and S. Farrell. US features of thyroid malignancy: pearls and pitfalls. *Radiographics* 2007; 27 (3): 847–860.
- [7] H.G. Moon, E.J. Jung, and S.T. Park. Role of ultrasonography in predicting malignancy in patients with thyroid nodules. *World Journal of Surgery* 2007; 31(7): 1410–1416.
- [8] L. Yassa, E.S. Cibas, C.B. Benson, M.C. Frates, P.M. Doubilet, A.A. Gawande, F.D. Moore, B.W. Kim, V. Nose, E. Marquisee, P.R. Larsen, and E.K. Alexander. Long-term assessment of a multidisciplinary approach to thyroid nodule diagnostic evaluation. *Cancer*. 2007; 111:508–516. Doi: 10.1002/cncr.23116. PMID: 17999413.
- [9] L. Falvo, C. D’Ercole, S. Sorrenti, V. D’Andrea, A. Catania, A. Berni, P. Grilli, and E. De Antoni. Papillary microcarcinoma of the thyroid gland: analysis of prognostic factors including histological subtype. *European Journal of Surgery Supplement*. 2003; 588:28–32.
- [10] Y.Y. Tee, A.J. Lowe, C.A. Brand and R.T. Judson, Fine-needle aspiration may miss a third of all malignancy in palpable thyroid nodules: a comprehensive literature review. *Annals of Surgery* 2007; 246(5): 714–720.
- [11] Y. Peng and H.H. Wang. A meta-analysis of comparing fine-needle aspiration and frozen section for evaluating thyroid nodules. *Diagnostic Cytopathology* 2008; 36(12): 916–920.
- [12] Y.C. Oertel, L. Miyahara-Felipe, M.G. Mendoza, and K.Yu. Value of repeated fine needle aspirations of the thyroid: an analysis of over ten thousand FNAs. *Thyroid* 2007; 17(11): 1061–1066.
- [13] G.L. La Rosa, A. Belfiore, D. Giuffrida, C. Sicurella, O. Ippolito, G. Russo, and R. Vingeri. Evaluation of the fine needle aspiration biopsy in the preoperative selection of cold thyroid nodules. *Cancer* 1991; 67(8): 2137–2141.
- [14] S. Franchi-Abella, C. Elie, and J.M. Correas. Ultrasound elastography: advantages, limitations and artifacts of the different techniques from a study on phantom. *Diagnostic and Interventional Imaging* 2013; 94: 497–501.
- [15] B.S. Garra. Elastography: current status, future prospects, and making it work for you. *Ultrasound Quarterly* 2011; 27(3): 177–186.
- [16] J. Ophir, I. Céspedes, H. Ponnekanti, Y. Yazdi, and X. Li. Elastography: a quantitative method for imaging the elasticity of biological tissues. *Ultrasonic Imaging* 1991; 13(2): 111–134.
- [17] E. Ueno and A. Itoh. Diagnosis of breast cancer by elasticity imaging. *Eizo Joho Medical* 2004; 36(12): 2–6.

- [18] D.S. Cooper, G.M. Doherty, and B.R. Haugen et al. Revised American thyroid association management guidelines for patients with thyroid nodules and differentiated thyroid cancer. *Thyroid* 2009; 19(11): 1167–1214.
- [19] C. Asteria, A. Giovanardi, A. Pizzocaro, L. Cozzaglio, A. Morabito, F. Somalvico, A. Zoppo. US-elastography in the differential diagnosis of benign and malignant thyroid nodules. *Thyroid* 2008; 18(5): 523–531.
- [20] T. Rago, F. Santini, M. Scutari, A. Pinchera and P. Vitti. Elastography: new developments in ultrasound for predicting malignancy in thyroid nodules. *Journal of Clinical Endocrinology and Metabolism* 2007; 92(8): 2917–2922.
- [21] A. Itoh, E. Ueno, E. Tohno, H. Kamma, H. Takahashi, T. Shiina, M. Yamakawa, and T. Matsumura. Breast disease: clinical application of US elastography for diagnosis. *Radiology* 2006; 39(2): 341–350.
- [22] G. Azizi, J. Keller, M. Lewis, D. Puett, K. Rivenbark, and C. Malchoff, Performance of elastography for the evaluation of thyroid nodules: a prospective study. *Thyroid* 2013; 23(6): 734–740.
- [23] L. Rubaltelli, S. Corradin, A. Dorigo, M. Stabilito, A. Tregnaghi, S. Borsato, and R. Stramare. Differential diagnosis of benign and malignant thyroid nodules at elastosonography. *Ultraschall in der Medizin* 2009; 30(2): 175–179.
- [24] C.P. Ning, S.Q. Jiang, T. Zhang, L.T. Sun, Y.J. Liu, and J.W. Tian. The value of strain ratio in differential diagnosis of thyroid solid nodules. *European Journal of Radiology* 2012; 81: 286–291.
- [25] P. Xing, L. Wu, C. Zhang, S. Li, C. Liu, and C. Wu. Differentiation of benign from malignant thyroid lesions. Calculation of the strain ratio on thyroid sonoelastography. *Journal of ultrasound in medicine* 2011; 30: 663–669.
- [26] S.M. Dudea and C. Botar-Jid. Ultrasound elastography in thyroid disease. *Medical Ultrasonography* 2015; 17: 74–96. DOI: 10.11152/mu.2013.2066.171.smd
- [27] A. Lyshchik, T. Higashi, R. Asato, S. Tanaka, J. Ito, J.J. Mai, C. Pellot-Barakat, M.F. Insana, A.B. Brill, T. Saga, M. Hiraoka, and K. Togashi. Thyroid gland tumor diagnosis at US elastography. *Radiology* 2005; 237: 202–211.
- [28] V. Cantisani, P. Lodise, H. Grazhdani, E. Mancuso, E. Maggini, G. Di Rocco, F. D'Ambrosio, F. Calliada, A. Redler, P. Ricci, and C. Catalano. Ultrasound elastography in the evaluation of thyroid pathology. Current status. *European Journal of Radiology* 2014; 83: 420–428.
- [29] R. Kagoya, H. Monobe, and H. Tojima. Utility of elastography for differential diagnosis of benign and malignant thyroid nodules. *Otolaryngology – Head and Neck Surgery* 2010; 143: 230–234.

- [30] N. Çiledag, K. Arda, B.K. Aribas, E. Aktas, and S.K. Köse. The utility of ultrasound elastography and micropure imaging in the differentiation of benign and malignant thyroid nodules. *American Journal of Roentgenology* 2012; 198: W244–W249.
- [31] J Bamber, D. Cosgrove, C. F. Dietrich, J. Bojunga, F. Calliada, V. Cantisani, J.M. Correias, M. D’Onofrio, E.E. Drakonaki, M. Fink, M. Friedrich-Rust, O.H. Giljia, R.F. Havre, C. Jenssen, A.S. Klauser, R. Ohlinger, A. Saftioiu, F. Schaefer, I. Sporea, F. Piscaglia. EFSUMB guide-lines and recommendations on the clinical use of ultrasound elastography. Part 1. Basic principles and technology. *Ultraschall in der Medizin* 2013; 34(2): 169–184.
- [32] F. Magri, S. Chytiris, V. Capelli, S. Alessi, E. Nalon, M. Rotondi, S. Cassibba, F. Calliada, L. Chiovato. Shear wave elastography in the diagnosis of thyroid nodules: feasibility in the case of coexistent chronic autoimmune Hashimoto’s thyroiditis. *ClinEndocrinol* 2012; 76: 137–141.
- [33] H. Grazhdani, V. Cantisani, P. Lodise, G. Di Rocco, M.C. Proietto, E. Fioravanti, A. Rubini, A. Redler. Prospective evaluation of acoustic radiation force impulse technology in the differentiation of thyroid nodules: accuracy and interobserver variability assessment. *J Ultrasound* 2014; 17: 13–20.
- [34] J.B. Veyrieres, F. Albarel, J.V.Lombard, J. Berbis, F. Sebag, C. Oliver, P. Petit. A threshold value in Shear Wave elastography to rule out malignant thyroid nodules: a reality? *Eur J Radiol* 2012; 81: 3965–3972.
- [35] R.S. Goertz, K. Amann, R. Heide, T. Bernatik, M.F. Neurath, D. StrobelD. An abdominal and thyroid status with Acoustic Radiation Force Impulse Elastometry feasibility study: Acoustic Radiation Force Impulse Elastometry of human organs. *Eur J Radiol* 2011; 80: e226–e230.
- [36] Y.F. Zhang, H.X. Xu, Y. He, C. Liu, L.H. Guo, L.N. Liu, J.M. Xu. Virtual touch tissue quantification of acoustic radiation force impulse: a new ultrasound elastic imaging in the diagnosis of thyroid nodules. *PLoS One* 2012; 7: e49094.
- [37] R. Han, F. Li, Y. Wanga, Z. Ying, Y. Zhang. Virtual touch tissue quantification (VTQ) in the diagnosis of thyroid nodules with coexistent chronic autoimmune Hashimoto’s thyroiditis: A preliminary study. *Eur J Radiol* 2015; 84: 327–331.
- [38] Y. Hong, X. Liu, Z. Li, X. Zhang, M. Chen, Z. Luo. Real-time ultrasound elastography in the differential diagnosis of benign and malignant thyroid nodules. *J Ultrasound Med* 2009; 28: 861–867.
- [39] Y.R. Hong, Y.L. Wu, Z.Y. Luo, N.B. Wu, X.M. Liu. Impact of nodular size on the predictive values of gray-scale, color-Doppler ultrasound and sonoelastography for assessment of thyroid nodules. *J Zhejiang Univ-Sci B (Biomed & Bio- technol)* 2012; 13: 707–716.

- [40] Oliver C, Vaillant-Lombard J, Albarel F, J. Berbis, JB. Veyrieres, F. Sebag, P. Petit. What is the contribution of elastography to thyroid nodules evaluation? *Ann Endocrinol (Paris)* 2011; 72: 120–124.
- [41] C. Shuzhen. Comparison analysis between conventional ultrasonography and ultrasound elastography of thyroid nodules. *Eur J Radiol* 2012; 81: 1806–1811.
- [42] A.Y. Park, E.J. Son, K. Han, J.H. Youk, J. Kim, C.S. Park. Shear wave elastography of thyroid nodules for the prediction of malignancy in a large-scale study. *Eur J Radiol* 2015; 84: 407–412.
- [43] D. Carneiro-Pla. Ultrasound elastography in the evaluation of thyroid nodules for thyroid cancer. *Curr Opin Oncol* 2013; 25: 1–5.
- [44] Kim JK, Baek JH, Lee JH, J.L. Kim, E.J. Ha, T.Y. Kim, W. Bae Kim, Y.K. Shong. Ultrasound elastography for thyroid nodules: a reliable study? *Ultrasound Med Biol* 2012; 38: 1508–1513.
- [45] D.J. Lim, S. Luo, M.H. Kim, S.H. Ko, Y. Kim. Interobserver agreement and intraobserver reproducibility in thyroid ultrasound elastography. *American Journal of Roentgenology* 2012; 198: 896–901.

