

# We are IntechOpen, the world's leading publisher of Open Access books Built by scientists, for scientists

**4,800**

Open access books available

**122,000**

International authors and editors

**135M**

Downloads

Our authors are among the

**154**

Countries delivered to

**TOP 1%**

most cited scientists

**12.2%**

Contributors from top 500 universities



**WEB OF SCIENCE™**

Selection of our books indexed in the Book Citation Index  
in Web of Science™ Core Collection (BKCI)

Interested in publishing with us?  
Contact [book.department@intechopen.com](mailto:book.department@intechopen.com)

Numbers displayed above are based on latest data collected.

For more information visit [www.intechopen.com](http://www.intechopen.com)



---

## The Eye and the Chikungunya Virus

---

Dayron Fernando Martínez-Pulgarín, Diana Marcela Muñoz-Urbano and Diego Zamora-de la Cruz

Additional information is available at the end of the chapter

<http://dx.doi.org/10.5772/64474>

---

### Abstract

Ocular involvement in chikungunya virus (CHIKV) infection can be present as mild and vision-threatening ocular complications with unilateral or bilateral compromise in both gender and all ages. Precise prevalence and incidence are unknown, but ocular involvement of CHIKV infection is uncommon. Anterior uveitis is the most common syndromic manifestation; nevertheless the infection could manifest posterior segment repercussion, such as retinitis which is the other most usual clinical manifestation. At the beginning of the systemic disease, main ophthalmologic symptoms are conjunctival injection, retro-ocular pain, and photophobia. Ocular pathogenesis of CHIKV infection is not totally clarified; however, findings related to an immune dysregulation and proinflammatory processes are the most accepted theories. The diagnosis of CHIKV is based on polymerase chain reaction, virus isolation, or detection of viral antigens which should be used before the eighth day of systemic illness. After 8 days, chikungunya serologic tests such as IgM ELISA/rapid tests or IgG paired must be used. Actual management is focused according to the clinical context of each patient. While in most instances recovery of vision to normal occurs, CHIKV infection can result in blindness, the visual prognosis depends on various factors, but the common one is the early onset of corticosteroid treatment.

**Keywords:** Chikungunya virus, uveitis, retinitis, optic neuritis

---

### 1. Introduction

Ocular involvement in chikungunya virus (CHIKV) infection was unheard until the end of 2006 [1]. Since then, it has been demonstrated that CHIKV infection can cause both mild and vision-threatening ocular complications. Precise prevalence and incidence estimations of ocular manifestations in CHIKV infection are unknown, further have been reported to be uncommon [2–4].

---

In an attempt to determine the viral causes of anterior uveitis in a South Indian patient population, Babu et al. realized a retrospective nonrandomized study between January 2009 and July 2012; they found two cases of CHIKV-related anterior uveitis; among 36 patients included, the two of them had unilateral involvement [5].

The infection has plenty of ocular manifestations as reported in the case reports and case series; these could be present at the time of systemic illness or after resolution of systemic disease [1, 6, 7] but usually occurs after a latent period of a month to a year, but the presentation time also depends on the type of clinical presentation. Anterior uveitis and retinitis are the most common findings; with a typically benign clinical course, it has been reported that anterior uveitis affects more than 25% of the patients [2, 6, 8]. Posterior segment involvement may manifest as retinitis, choroiditis, neuroretinitis, and optic neuritis [1, 2, 7–11].

Commonly, in the acute phase of chikungunya fever, patients could manifest photophobia and retro-orbital pain [6, 12]; other ophthalmic manifestations of chikungunya virus infection include panuveitis, optic neuritis, keratitis, episcleritis, central retinal artery occlusion, exudative retinal detachment, lagophthalmos, and VIth nerve palsy [2, 6, 8, 13]; there are a variety of clinical manifestations that will be completely mentioned in other sections of this chapter.

Mittal et al. described a case series of 14 patients with confirmed CHIKV infection and optic neuritis; of them 42% had papillitis; 21% had retrobulbar neuritis; another 21% had optic tract involvement, and 16% had neuroretinitis [13]. Four years after this publication, Rose et al. reported an observational study involving 10 patients, who were confirmed cases of infection with CHIKV with acute optic neuritis. All 10 patients in the study presented with sudden onset decrease in vision and had a history of fever, joint pain, and skin rash. Among the 10 cases, 30% had bilateral disturbance and 70% had complaints only in one eye. The types of optic neuritis were unilateral papillitis (40%), bilateral papillitis (30%), retrobulbar neuritis (10%), perineuritis (10%), and neuroretinitis (10%) [10]. Meanwhile during 2011 a case of bilateral chikungunya neuroretinitis in a 65-year-old Asian-Indian, who presented with a month-old history of sudden, painless diminution of vision in both eyes and was treated with oral steroids and oral acyclovir for 3 weeks, was published, after which partial resolution was noted [14].

Meanwhile, Mahendradas et al. reported a different spectrum of ocular manifestations in nine patients with a positive serology for CHIKV: 55% had iridocyclitis, 33% had retinitis, and one patient of nine included had nodular episcleritis [8]. Conjunctivitis also been reported as a manifestation of CHIKV ocular infection, which looks like another viral infection and resolves spontaneously [9].

A report of the first known case of bilateral granulomatous panuveitis secondary to chikungunya fever in the United States, acquired by a US citizen traveling from an endemic region, was done by Scripsema et al.; they described a case of a 47-year-old woman presented with 10 days of bilateral decreased vision and photophobia with a concurrent febrile illness. Initially, she responded to corticosteroid treatment but developed recurrent inflammation 3 months after completing the initial treatment. Immunomodulatory therapy was initiated at the time of recurrence, and with this therapy alone, her inflammation has been controlled for 6 months.

In this article, the authors show that according to current reports of chikungunya fever-related uveitis with posterior inflammation, the distribution of presentation includes papillitis or optic neuritis (34%), neuroretinitis (12%), retrobulbar optic neuritis (14%), retinitis (11%), panuveitis (9%), choroiditis (7%), retrochiasmal or optic tract neuritis (7%), exudative retinal detachment (4%), and perineuritis (2%) [15].

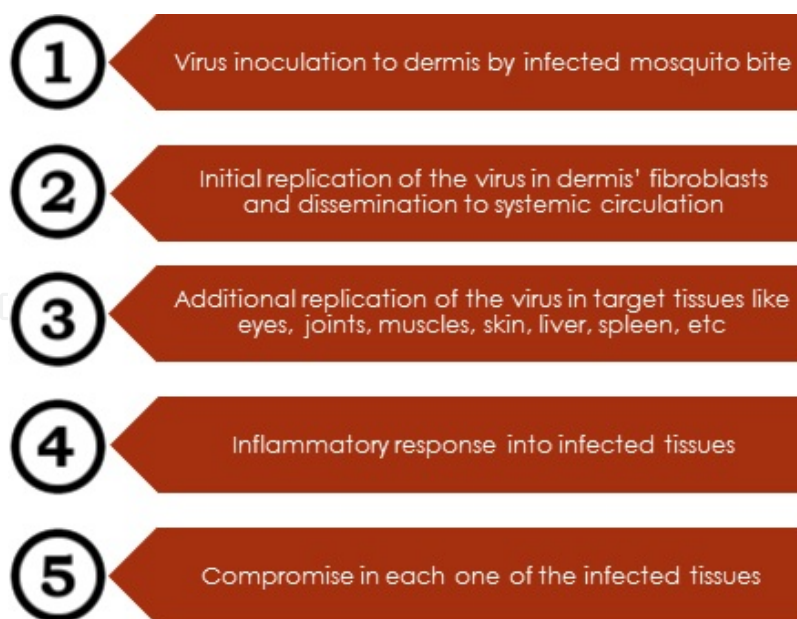
Kalpana et al. presented a case series of 58 patients with Fuchs heterochromic iridocyclitis (FHI) and found one case caused by CHIKV; nevertheless the authors explain that it is difficult to speculate the association of FHI and chikungunya virus in this patient [16]. Before this case series, during 2010 Mahendradas et al. published the first report where the presence of chikungunya virus RNA has been associated with a case of bilateral Fuchs heterochromic iridocyclitis, although the authors clear that it is not accurate if the chikungunya virus was the initiator of the disease or a coincidental finding [17].

Ocular involvement caused by chikungunya virus should be included in the differential diagnosis, especially in the endemic areas, of any patient presenting with ocular manifestations and a history of fever, even more when this is accompanied by suggestive symptoms of an infection caused by CHIKV [18]. This chapter describes the most important aspects of the ocular compromise caused by CHIKV, items that the clinicians should consider when approaching a patient with a suspected ocular involvement by the mentioned virus.

## 2. Ocular pathogenesis

Ophthalmologic involvement due to chikungunya virus infection is a state that affects plenty of structures of the eyeball including the eyelids, conjunctiva, cornea, sclera, episclera, iris, retina, optic nerve, etc. This diversity of ocular findings has been mainly associated with the most recent outbreaks of the virus because of genomic variations resulting in different virus strains with changes in activity and virulence. The outbreak of the disease in La Réunion, an island in Indian Ocean, is related to a different strain of the virus which has been associated with a higher replication rate than West African and Asian strains of chikungunya virus according to studies in animals [19, 20]. It is not pretty clear the exact pathogenic mechanism through chikungunya virus makes its disturbances in different tissues, especially the eye; however a group of successive steps has been proposed to describe the cycle of infection that applies for systemic and ocular disease (Figure 1) [19, 21].

The initial response of the body involves an elevation of type I interferon levels and a hypersensitivity reaction mediated by antibodies against viral antigens causing joint symptoms and the possible beginning of ocular compromise [21]. The existence of a huge controversy about the determination of target cells compromised by chikungunya virus has marked the research pattern in the last years in an attempt to create new therapeutic interventions. Some researches in recent years have determined that fibroblasts, endothelium and epithelium cells, and macrophages are susceptible to infection by chikungunya virus, especially by La Réunion strain, leading to apoptosis in some cases [22]. Different studies made in mice and humans have found that fibroblasts are the major cell target for chikungunya virus, including those in



**Figure 1.** Systemic and ocular pathogenic process of chikungunya virus infection. Based on Couderc T and Lecuit M. Chikungunya virus pathogenesis: From bedside to bench. *Antiviral Res.* 2015;121:120-131.

eyeball tissues, something that can be explained by their reticular network formed by gap junctions making possible dissemination from cell to cell; nevertheless the exact mechanism has not been described [23, 24].

In the eye, the cornea commitment depends on the infection of epithelial and endothelial cells, which are the target cells of chikungunya virus at this level. There is evidence about the potential risk of transmission of chikungunya virus through corneal graft transplantation. According to Courdec et al., they identified a group of corneal donors who were seropositive for CHIKV IgM and/or IgG, and their samples showed evidence of the presence of the virus after the conventional eye bank preservation methods, which were ineffective to inactivate the virus from the corneal samples, and conclude that CHIKV can be transmitted via ocular route in humans, coinciding with studies made in immunocompetent mice demonstrating that the corneal tissue infected with chikungunya virus in replication state that was inoculated onto scarified cornea leads to viral transmission in the studied mice [24]. This study also determined that the presence of replication-competent virus in the eye did not correlate with viral detection in the blood or the presence of antiviral antibodies. Other sites in the eyeball like the scleral connective tissue, stroma of smooth muscles of ciliary bodies, and stroma of the iris, the fibroblast is the ideal cell for the virus because of its high rate of replication that leads to a huge production of infectious viral particles. Besides, there have also been signals of infection between fibers of ocular muscles [25].

Involvement of the optic nerve is not pretty clear; nevertheless it is presumed that an immune dysregulation, superantigen induction, hypersensitivity reaction, and molecular mimicry between stimulating virus-derived antigens and normal or altered host tissue proteins may be the causes of the optic nerve damage [10, 13, 26, 27].

There are descriptions about fluctuations in the values of intraocular pressure when inflammatory processes in anterior segment occur. Hypotension may occur when a loss of integrity of the blood-aqueous barrier exists leading to an increased aqueous humor flow. Episodes of ocular hypertension happen when inflammation of trabecular system appears, leading to obstruction of aqueous humor flow [28].

There is a theory that serves as a complement for chikungunya pathogenesis, including the ocular compromise, and consists of an increased production of chemokines, like interleukin-8 (IL-8) and monocyte chemoattractant protein 1 (MCP1), by infected monocyte-derived macrophages. However, this last theory is just a hypothesis based on studies made using the Ross River virus, which is a virus that belongs to alphavirus family, as the chikungunya virus; therefore it can keep some behavior similarities with CHIKV [23, 29]. Primary cultures of B and T cells, monocytes, and monocyte-derived dendritic cells were found not to be susceptible to CHIKV infection in vitro [19, 22, 30].

In summary, ocular pathogenesis in context of CHIKV infection is a process that is not totally clarified, despite the progressively increase in research about this field in recent years; however, findings related to an immune dysregulation state and proinflammatory processes are the most accepted theories and could guide the course of ophthalmologic research about this field in the coming years.

### 3. Clinical findings

Ophthalmologic manifestations due to chikungunya infection are a set of pathologies that cause different degrees of damages, involving plenty of structures on anterior and posterior pole during the course of the systemic disease, even after its resolution with a latent period of a month to a year [6, 31], and can be present as both mild and vision-threatening ocular complications with unilateral or bilateral compromise in both gender and all ages [32], being retinitis and uveitis the most common syndromic manifestations. At the beginning of the systemic disease, main visible clinical symptoms are conjunctival injection, retro-ocular pain, and photophobia [2, 12, 33]; meanwhile other existing symptoms like blurred vision, floaters, epiphora, irritation, and diplopia usually appear after a latent period of a month to a year (during chronic phase) [16, 32, 34].

The time between beginning of fever and the onset of ophthalmologic symptoms is unknown; however some retrospective researches in an attempt to determine this interval have shown that involvement of visual acuity initiates approximately 4 weeks after fever begins, pain and floaters can be present after 12 weeks, and redness can appear 10–12 weeks after fever onset [8]; nevertheless these intervals can fluctuate according to the specific affected ocular structure and the degree of involvement. Also, the small number of patients used by researchers in these studies makes accurate data on these aspects too difficult to reach, but initial approximations like this allow the creation of bigger studies that make possible to find high-impact data.

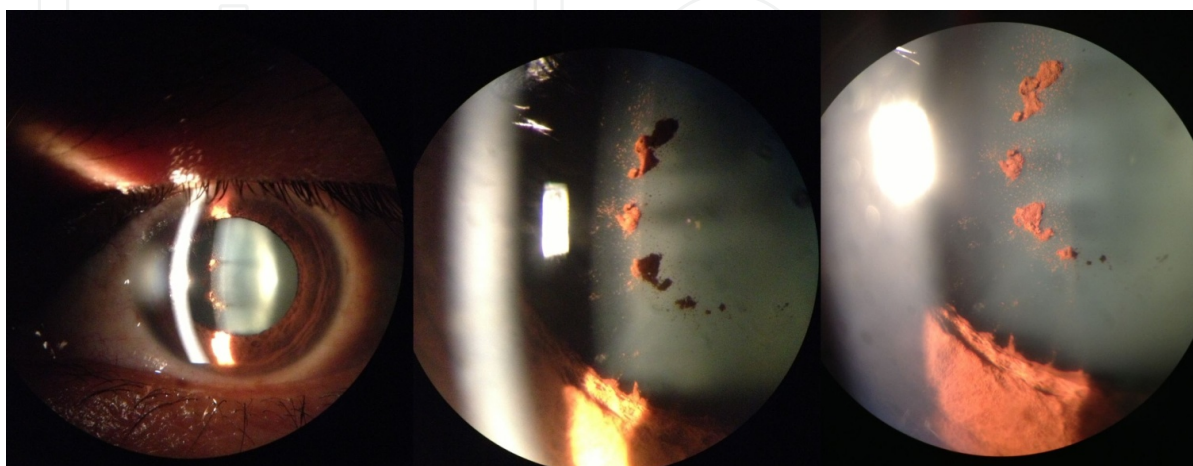
Ocular manifestations of chikungunya virus can keep some similarities with other viruses like dengue and Zika. Dengue ocular manifestations are uncommon but can be present particularly

in young adults with a mean age of early 30s and without any sex predilection, debuting when platelets are at lowest count, especially one week after fever onset [18]. The most common ocular findings due to dengue fever are subconjunctival hemorrhage, dengue maculopathy, anterior uveitis, vitreitis, retinal pigment epithelium mottling, foveolitis, retinochoroiditis, choroidal effusion, optic disk swelling, optic neuritis, neuroretinitis, panophthalmitis, retinal hemorrhages, and oculomotor nerve palsy [31, 32, 34].

Zika ocular manifestations are included in the category of “atypical”; however the ophthalmologic manifestations which have been described in literature until now are the non-mucopurulent conjunctivitis and the retro-ocular pain. In a Yap island population when an outbreak of Zika virus was informed, about 55% of cases were reported with the presence of non-mucopurulent conjunctivitis and 39% of cases with retro-ocular pain; uveitis and different ocular inflammatory processes were not reported [35]. Differential diagnosis with dengue and chikungunya viruses should be based in all manifestations and not purely based on ophthalmologic findings [36].

### 3.1. Anterior uveitis

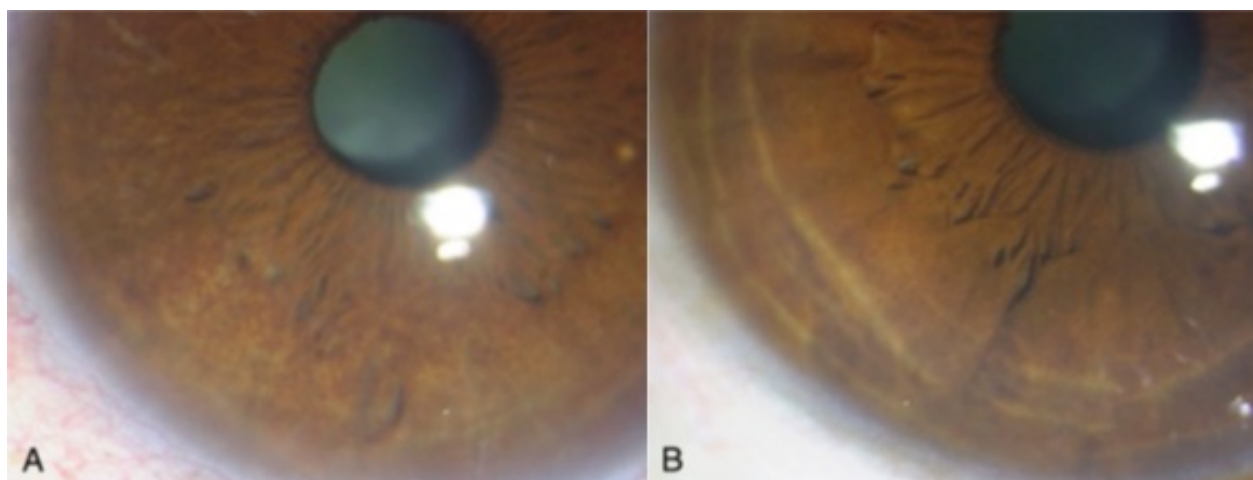
Anterior uveitis, including granulomatous and non-granulomatous variety, is the main ocular condition due to infection caused by chikungunya virus [2]. There is no evidence that demonstrates that uveitis secondary to chikungunya virus has a different behavior than uveitis caused by other etiologies, particularly those from other arboviruses such as dengue [37]. It is defined as an inflammation of the uveal tract, specifically the iris and pars plicata of the ciliary body. The presence of symptoms can be insidious or sudden, taking between a few weeks to a few months to resolve. Main clinical manifestations include pain, photophobia, conjunctival injection, hypopyon (the presence of inflammatory cells in anterior chamber and according to their number represents ocular disease activity), epiphora, and pigmented central globular keratic precipitates with an infiltrative and dendritic pattern on the surface of the corneal endothelium in some cases (Figure 2.) [38].



**Figure 2.** Pigmented keratic precipitates at cornea. Picture took by Diego Zamora-de la Cruz.

The visual acuity can be affected depending on severity and activity state of the uveitis; miosis can be present, making a predisposition to formation of posterior synechia, which is the main complication related to anterior uveitis [12, 39]. Funduscopy is usually normal, but it should always be realized for excluding anterior uveitis due to an infection by toxoplasma or acute retinal necrosis in posterior pole. It is possible to develop high intraocular pressure in the context of an open corneoscleral angle [32]. It is clearly established that chikungunya anterior uveitis can imitate a herpetic anterior variety [40]. However, we can differentiate both: In the first one the compromise is more bilateral [41], exists past history of fever with joint pain, have being in endemic areas [33, 42, 43], and there are positive serologic results [12, 32, 41].

Ocular compromise by CHIKV could manifest also as Fuchs heterochromic iridocyclitis (FHI), which is a disease of unknown etiology characterized by low-grade intraocular inflammation, iris heterochromia and/or atrophy, keratic precipitates with stellate morphology with fibrillary extensions, the absence of synechiae, development of cataract, and in few cases increased intraocular pressure; however this syndrome has been much more linked to other infections and noninfectious diseases than chikungunya virus (Figure 3.) [16].



**Figure 3.** Fuchs heterochromic iridocyclitis: (A) normal eye and (B) affected eye. Taken from Babu K, Adiga M, Govekar S, Kumar B, and Murthy K. Associations of Fuchs heterochromic iridocyclitis in a South Indian patient population. *Journal of Ophthalmic Inflammation and Infection*. 2013; 3(14). Reproduced with permission.

According to case reports, a past history of systemic symptoms of chikungunya was reported in the previous 1–6 weeks; the affectionation by FHI was more unilateral with a mean age of  $37.95 \pm 12.42$  years (range from 16 to 68 years), and the most common complaint of patients is blurred vision. Despite these results, it still remains unclear the exact time of the presence of viral antigen in the aqueous, so it can be difficult to assume a causal role of chikungunya virus in FHI cases [16, 17, 44].

### 3.2. Posterior uveitis

Posterior uveitis is less common than anterior uveitis in the context of infection by chikungunya virus, and it is defined as inflammation of the choroid and/or retina, vitreous, optic nerve



head, and retinal vessels. According to the Standardization of Uveitis Nomenclature (SUN) working group, posterior uveitis includes focal, multifocal, or diffuse choroiditis, chorioretinitis, retinochoroiditis, retinitis, neuroretinitis, and retinal vasculitis [39, 45, 46]. Clinical signs might be varied according to the structure involved. Decreased vision, central scotoma, peripheral field defects, and color vision defect can be present. Symptoms in the anterior segment like conjunctival injection, pain, and hypopyon are less frequent [32].

### 3.2.1. Retinitis

Retinitis onset occurs between 2 and 4 weeks after febrile period of systemic disease. According to some authors, this interval can support the hypothesis that ocular lesions could be an immune-mediated process rather than a direct viral effect [47]. It can be focal, multifocal, or diffuse. Patients consult with a history of sudden vision lost without pain. Active lesions are characterized by retinal whitish opacities, poorly demarcated by surrounding edema [39]. It is usually accompanied by mild vitreitis, retinal hemorrhages, compromise of retinal vessels, and the presence of areas of retinal whitening in the posterior pole [48]. Funduscopy allows visualizing focal and multifocal patches of retinitis macular edema, serous detachment at the macula, and localized involvement of the retinal vessel [49]. It is described that retinitis caused by chikungunya fever can simulate herpetic and West Nile virus retinitis; thus the importance of anamnesis lies in the identification of systemic symptoms of chikungunya infection, making possible the differentiation to other etiologies [50, 51].

### 3.2.2. Choroiditis

Choroiditis can be, as retinitis, focal, multifocal, or diffuse. It usually does not produce vitreitis in the absence of concomitant retinal involvement. Choroiditis active lesion is characterized by a round yellow nodule in any part of the choroid tissue, especially the iris. Vasculitis includes a compromise of arteries and veins (periarteritis and periphlebitis), and it is characterized by a perivascular irregular yellow or white cuff and can be associated with hemorrhages [39].

## 3.3. Optic neuritis

Optic neuritis is an inflammatory, infectious, or demyelinating process that involves optic nerve. According to funduscopy, it can be classified as retrobulbar neuritis, papillitis, or neuroretinitis. There exists another classification based on etiology, which is divided into demyelinating, parainfectious, infectious, and noninfectious optic neuritis. In the case of optic neuritis due to chikungunya infection, it belongs to parainfectious class, which occurs after the viral infection [39]. Optic neuritis is characterized by acute or subacute loss of vision, pain with ocular movements, and color vision defects. Papillitis is the most often clinical sign according to observational case series. Patients report the presence of blurred vision after a mean of  $11.0 \pm 14.0$  days of a symptom-free period, and the ocular symptoms had a mean duration of 14 days [10, 13].

### 3.4. Corneal involvement

Keratitis and keratouveitis are the main conditions that affect corneal tissue in the context of chikungunya infection. It is an inflammatory process of the cornea. There is no defined time between systemic symptoms and the onset of corneal compromise; however there are some studies which affirm that viral infection at the corneal cell can remain asymptomatic for some periods of time, approximately 1 month according to case reports [3, 25]. Blurred vision and ocular irritation are some of the associated symptoms, and involvement of corneal surface can include bilateral punctate superficial keratitis and stromal immune ring formation with underlying keratic precipitates which can resolve after 2 weeks of topical corticoid therapy (Figure 2) [2, 3].

### 3.5. Episcleritis

Episcleritis is defined as inflammation of the episclera, which is the most external layer of sclera. It is classified as simple or nodular. Regardless of the cause of the pathology, it has a pattern to recur in the same eye in posterior episodes [39]. Simple episcleritis is characterized by localized conjunctival injection with a duration of 12 hours approximately. Nodular episcleritis is represented by conjunctival injection that becomes bigger progressively with the presence of painful nodules localized almost all the time at the interpalpebral fissure. Episcleritis has a benign and self-limited course with a total conservation of vision and an excellent prognosis [8].

### 3.6. Panophthalmitis

Panophthalmitis in seropositive chikungunya patients is an unusual manifestation by this agent. It is characterized by an inflammatory process of all structures in the eye. The only case report on the literature of this manifestation related to chikungunya was in a middle-aged male patient who presented with painful progressive proptosis with loss of vision in the left eye over a period of 6 hours with a history of fever, rash, and severe joint pain in the previous five days. Moreover, the patient presented at physical examination visual acuity with no light perception, swelling, and redness of both eyelids, raised temperature over the lids, and proptosis. Despite panophthalmitis is a very rare manifestation, its rapid fulminating course and severity of symptoms make this one of the most feared ocular manifestations [52].

## 4. Ophthalmologic diagnosis

As discussed in the additional chapters, the diagnosis of CHIKV is based on polymerase chain reaction, virus isolation, or detection of viral antigens which should be used before the eighth day of systemic illness. After 8 days, chikungunya serologic tests such as IgM ELISA/rapid tests or IgG paired must be used because the viral load will have decreased [53].

Actually, it has not been possible to find any standard method for ocular CHIKV infection; however according to some authors, the collection of aqueous humor can be useful for the

determination of virus [12, 17], as it was previously documented in a patient who underwent cataract surgery [17]. Despite this report, it is not recommended to take samples of aqueous or vitreous humor if the illness does not threaten the integrity or eye function because of the possibility to cause a superimposed infection.

Collection of aqueous humor can be made through puncture that is performed before phacoemulsification surgery or by taking aqueous samples in the lens remains collection bag and supplemented with the implementation of reverse transcription polymerase chain reaction (RT-PCR) [12, 17].

Mahendradas et al. demonstrated that only the aqueous or vitreous humor and no other tissues such as the anterior lens capsule can become infected by the virus [17]. It is important to recognize clinically if the inflammation is related to the virus and latent preconditions as some other viral infections or systemic diseases that trigger the clinical manifestation.

Other tests could be used such as ELISA, immunochromatographic test, hemagglutination inhibition, or neutralization techniques, which allow diagnosing indirectly the virus infection through quantification of the IgM and IgG antibodies in serum; however, these are too much unspecific [12].

To date, the RT-PCR is considered as the gold standard test to identify the etiologic agent in ocular tissue involvement because of its high specificity and sensitivity rates. The RT-PCR must be taken when viremia is active (10<sup>9</sup>–10<sup>12</sup> viral copies per ml of blood) [52].

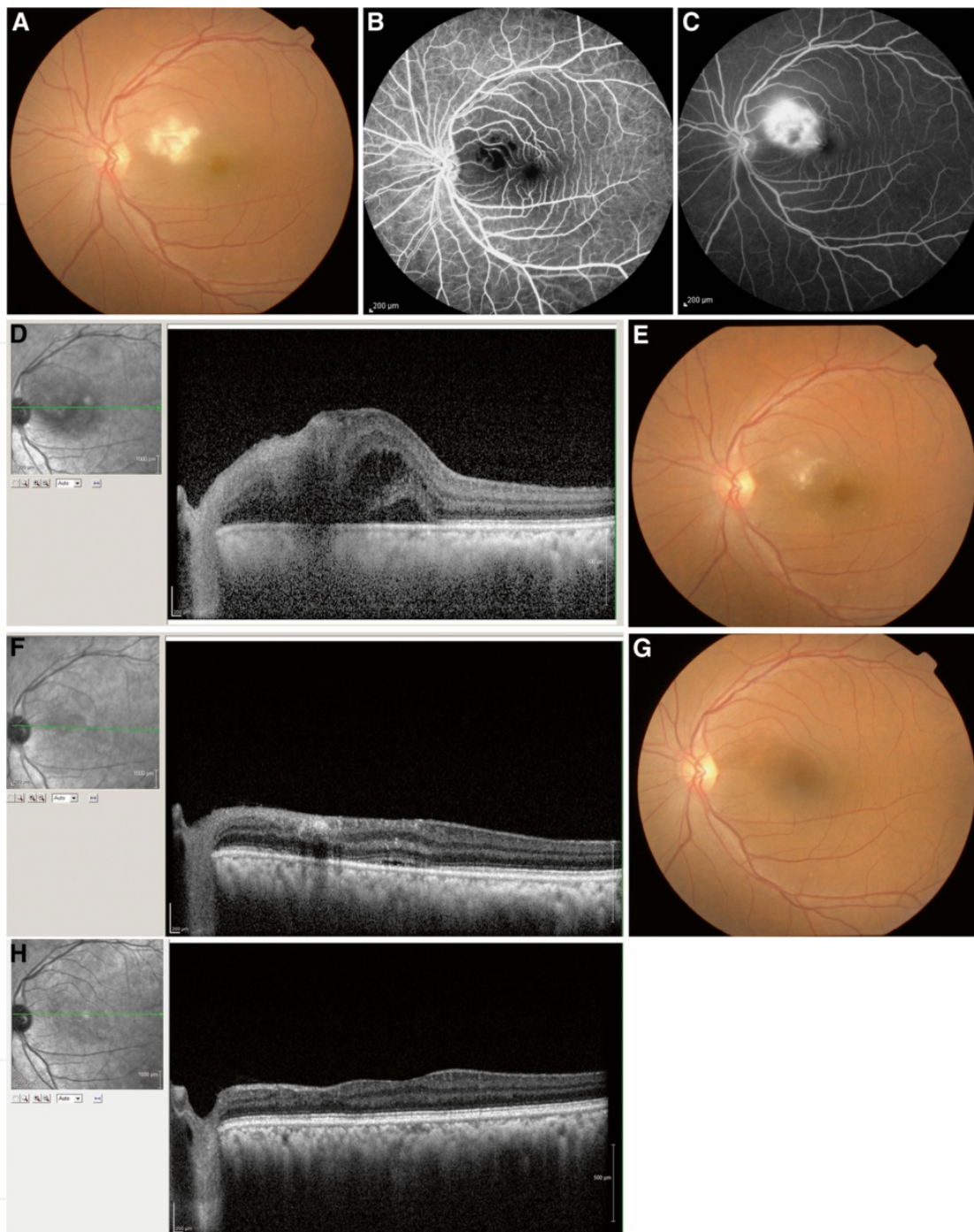
As reported by some authors [12, 17], cataract postoperative state of patients with chikungunya is similar to patients with chronic uveitis; therefore, it must be considered to continue topical and systemic steroids in the postoperative period.

The definitive diagnosis has to be made by integrating systemic clinical findings with serologic test for CHIKV. The differential diagnosis is usually made with anterior/posterior uveitis caused by herpes simplex virus (HSV) and retinitis due to West Nile virus [12].

The panophthalmitis is a global inflammatory process of the eyeball due to CHIKV which has been reported in the literature [52], but the association between chikungunya and panophthalmitis is doubtful and requires further investigation; according to Rajan and colleagues, no evidence of viral agent was found in the ocular tissue.

It is relevant to say that ocular diagnosis of CHIKV has to be always considered as an exclusion diagnosis, after probing more common etiologies of clinical manifestation mentioned above.

Fluoroangiography and spectral domain optical coherence tomography (SD-OCT) are additional tests that can be used for ocular chikungunya infection. The first one can reveal unspecific findings of neuroretinitis, macular edema, and even serous retinal detachments associated with chikungunya. The use of these tests is not recommended for diagnosis but to check evolution of inflammatory process. For instance, in retinitis cases analyzed with fluoroangiography, hypofluorescent areas in late stages of the study are observed; meanwhile SD-OCT revealed increased reflectivity in the nerve fiber layer zone which can be associated with serous retinal detachments (Figure 4). Nevertheless, it is so relevant to remind that the main goal of these studies is to follow up the patient's clinical course of the ocular disease [8, 12].



**Figure 4.** Retinitis findings in SD-OCT and fluoroangiography. (A) Fundus photograph of the left eye showing confluent area of retinal whitening suggestive of retinitis. (B) Fundus fluorescein angiography with early hypofluorescence in the posterior pole, and (C) late hyperfluorescence in the posterior pole. (D) Spectral domain optical coherence tomography (SD-OCT) revealed an increased reflectivity in the nerve fiber layer zone corresponding to the areas of retinitis with after shadowing and fluid-filled spaces in the outer retina with serous retinal detachment. (E) Fundus photograph showing resolving retinitis lesion 2 weeks after initiation of systemic steroid therapy. (F) SD-OCT showing decreased area of hyperreflectivity in the inner retina with resolving retinal detachment. (G) Fundus photograph after 4 months, showing complete resolution of retinitis. (H) SD-OCT showing resolution of retinitis with thinning of the inner retinal layers nasal to the fovea. Taken from Mahendradas P, Avadhani K, Shetty R. Chikungunya and the eye: a review. *Journal of Ophthalmic Inflammation and Infection*. 2013; 3(35). Reproduced with permission.

## 5. Treatment

There is no specific antiviral treatment for the CHIKV ocular infection to date. Actual treatment for ocular manifestations due to this virus is focused on control of symptoms and avoidance of complications resulting from inflammation of ocular tissues [12].

Systemically, the treatment is based on handling inflammation with corticosteroids and immunomodulators. The treatment is focused according to the clinical context of each patient. In a patient with an active viral process and an inflammatory ocular event, other causes of retinitis, scleritis, and uveitis must be excluded.

Murthy et al. reported a case of bilateral retinitis due to a systemic infection of CHIKV. Inflammation secondary to HSV was documented, and the treatment was made with intravenous and oral acyclovir, intravitreal ganciclovir, and oral corticoids and focused on decreasing the viral copies. The role of acyclovir in treatment against ocular CHIKV should be restricted to cases where CHIKV and HSV concomitant infection is present or when an inefficient response to anti-inflammatory therapy exists; however, this is still a controversial fact [46, 47].

As soon as ocular inflammation appears, it is convenient to assess the systemic condition of the patient, with the purpose of identifying contraindications for systemic steroids use, with the objectives to reduce eye inflammation and prevent irreversible blindness. Nowadays, treatment is focused only on treating uveitis complications due to CHIKV [8, 12, 38].

### 5.1. Local treatment

In all patients who experience active anterior segment inflammation, it is preferred to start treatment with prednisolone acetate 0.2%, eight times a day, with a reductive dose schedule every 5 days depending on patient response. It is preferred to add cyclopentolate 1.0% twice a day or tropicamide with phenylephrine every 8 hours, allowing not only the patient cycloplegia but also iris mobilization, avoiding the formation of posterior synechiae [41].

Occasionally, patients may experience increased intraocular pressure in the context of uveitis, which can be controlled by adding a topical treatment with timolol 0.5% twice daily. It is relevant to remind the mechanism by which the increase of intraocular pressure occurs. High levels of prostaglandins can increase production of aqueous humor, and the presence of trabeculitis leads to an obstruction of the aqueous humor flow, increasing intraocular pressure [41].

It is recommended to use some topical nonsteroidal anti-inflammatory drugs to create synergy with steroid and reduce rapidly the present symptoms. Some examples can include nepafenac every 12 hours, bromfenac every 6 hours, or topical ketorolac every 8 hours [41].

### 5.2. Systemic treatment

Once any contraindication to initiate steroids is excluded, intravenous steroids may be started if inflammatory events such as optical neuritis or any other threatening visual condition are documented. In the cases of increased refractory intraocular pressure to topical treatment, it is recommended to add acetazolamide 250 mg twice daily for three days, taking care of the renal function [41].

## 6. Visual prognosis

While in most instances recovery of vision to normal occurs, CHIKV infection can result in blindness; especially if it courses in association with optic neuritis or neuroretinitis, patients may present sudden loss of vision caused by chikungunya fever associated with optic neuritis [4, 10, 18]; this manifestation of the ocular infection may have a progressive visual loss and may occur rapidly over several hours or over days [10]. Some authors suggest that visual prognosis is good with anterior segment involvement, whereas that with posterior segment involvement (retinochoroiditis) is poor [2, 18, 32, 54], though later certain aspects that greatly influence the visual forecast will be mentioned.

The majority of patients with retinitis have a good visual outcome over a 10- to 12-week period [12]. It has been described that alterations like granulomatous and non-granulomatous uveitis, optic neuritis, and dendritic lesions are common lesions with good visual prognosis, but as noted above, the prognosis is influenced by several aspects, and this is dependent of each clinical context [2]. On the other hand, macular ischemia and optic disk changes account for the poor visual outcome seen in a minority of patients [12, 55].

Unlike previously exposed, Mahesh G et al. reported a case of a 48-year-old female with bilateral neuroretinitis; the patient received early systemic steroids since she had optic disk involvement, and visual recovery was very satisfactory [1]. Rapid visual recovery is usually the norm with immediate administration of systemic steroid therapy [10, 13]. An observational case series that included 14 patients with clinical features of CHIKV infection and associated optic neuritis reported complete or partial improvement of vision in 71% of patients with good response to steroids if given early in the course of illness; in this study, the researchers presented three patients in whom treatment was initiated 1 month after the onset of visual symptoms for whom there was no visual improvement [13].

Nonce, Chanana et al. [7] reported a case of a 16-year-old male patient with bilateral macular choroiditis following chikungunya virus infection that started treatment with oral prednisolone; he showed evidence of resolving choroiditis bilaterally within 6 weeks of treatment, but the vision did not improve further [7].

In an observational study involving 10 patients, whose cases of infection with CHIKV with acute optic neuritis were confirmed, the overall prognosis in terms of visual acuity, color vision, pupillary reaction, and visual field was favorable. They received intravenous methylprednisolone for 3 days, followed by oral prednisolone in a tapering dose; the authors emphasize the importance of prompt establishment of corticosteroid therapy to lead to rapid recovery of visual function in patients with acute presentation of optic neuritis, but it has no role when treatment is initiated at a late stage of the disease [10].

A retrospective study showed 14 consecutive cases who presented to the Vitreo Retina Department of the Minto Ophthalmic Hospital; of them one patient was positive for IgM chikungunya; she had bilateral anterior non-granulomatous uveitis and retinitis with optic nerve involvement in one eye; the patient showed a favorable response to oral prednisolone; the dose was tapered based on clinical response over a period of 6 weeks improving from an

average of 2/60 to 6/24 vision [49]. In a similar way, a case series that included nine chikungunya patients with ocular involvement found a benign course in the cases of iridocyclitis and episcleritis; they showed complete resolution, with preservation of vision, and patients that presented with retinitis showed gradual resolution over a period of 6 to 8 weeks with systemic acyclovir and the corticosteroids [8].

Other less fortunate cases have been reported, in which there is no any treatment that can improve final visual prognosis, such as one of the patients with acute necrotizing panophthalmitis; although the CHIKV was not isolated from vitreous tap, chorioretinal biopsy, and other eviscerated materials, the serological studies were positive with high titer of recent infection. The case resulted in a painful blind eye, which required evisceration [52].

During April of 2015, Hayek et al. reported the first case of a teen girl with CHIKV-induced stromal keratouveitis; she had complete resolution of the corneal infiltrate after 2 weeks of topical corticosteroid treatment [3]. As previously described, the visual prognosis depends on various factors, but the common one that is found in the scientific literature is the early onset of corticosteroid treatment. However there is no specific agent that was found effective against the chikungunya virus. Most of the infected patients with CHIKV are treated symptomatically, and it is not completely clear whether any therapy is effective in improving the visual prognosis [8].

## Author details

Dayron Fernando Martínez-Pulgarín<sup>1\*</sup>, Diana Marcela Muñoz-Urbano<sup>1</sup> and Diego Zamora-de la Cruz<sup>2</sup>

\*Address all correspondence to: dayronfernando@hotmail.com

1 Research Group and Incubator Public Health and Infection, Faculty of Health Sciences, Universidad Tecnológica de Pereira, Pereira, Risaralda, Colombia

2 Institute of Ophthalmology, Conde de Valenciana Foundation, México City, México

## References

- [1] Mahesh G., Giridhar A., Shedbele A., Kumar R., Saikumar S.J. A case of bilateral presumed chikungunya neuroretinitis. *Indian Journal of Ophthalmology*. 2009;57(2): 148-150. DOI: 10.4103/0301-4738.45508.
- [2] Lalitha P., Rathinam S., Banushree K., Maheshkumar S., Vijayakumar R., Sathe P. Ocular involvement associated with an epidemic outbreak of chikungunya virus infection. *American Journal of Ophthalmology*. 2007;144(4):552-556. DOI: 10.1016/j.ajo.2007.06.002.

- [3] Hayek S., Rousseau A., Bouthry E., Prat C.M., Labetoulle M. Chikungunya virus infection and bilateral stromal keratouveitis. *JAMA Ophthalmology*. 2015;133(7): 849-850. DOI: 10.1001/jamaophthalmol.2015.0698.
- [4] Rajapakse S., Rodrigo C., Rajapakse A. Atypical manifestations of chikungunya infection. *Transactions of the Royal Society of Tropical Medicine and Hygiene*. 2010;104(2):89-96. DOI: 10.1016/j.trstmh.2009.07.031.
- [5] Babu K., Kini R., Philips M., Subbakrishna D.K. Clinical profile of isolated viral anterior uveitis in a South Indian patient population. *Ocular Immunology & Inflammation*. 2014;22(5):356-359. DOI: 10.3109/09273948.2013.841482.
- [6] Khairallah M., Yahia S.B., Attia S. Arthropod vector-borne uveitis in the developing world. *International Ophthalmology Clinics*. 2010;50(2):125-144.
- [7] Chanana B., Azad R.V., Nair S. Bilateral macular choroiditis following chikungunya virus infection. *Eye (Lond)*. 2007;21(7):1020-1021. DOI: 10.1038/sj.eye.6702862.
- [8] Mahendradas P., Ranganna S.K., Shetty R., Balu R., Narayana K.M., Babu R.B., et al. Ocular manifestations associated with chikungunya. *Ophthalmology*. 2008;115(2): 287-291. DOI: 10.1016/j.ophtha.2007.03.085.
- [9] Parola P., de Lamballerie X., Jourdan J., Roveery C., Vaillant V., Minodier P., et al. Novel chikungunya virus variant in travelers returning from Indian ocean islands. *Emerging Infectious Diseases*. 2006;12(10):1493-1499.
- [10] Rose N., Anoop T.M., John A.P., Jabbar P.K., George K.C. Acute optic neuritis following infection with chikungunya virus in southern rural India. *International Journal of Infectious Diseases*. 2011;15(2):e147-150. DOI: 10.1016/j.ijid.2010.10.004.
- [11] Dunn J.P. Uveitis. *Primary Care: Clinics in Office Practice*. 2015;42(3):305-323. DOI: 10.1016/j.pop.2015.05.003.
- [12] Mahendradas P., Avadhani K., Shetty R. Chikungunya and the eye: a review. *Journal of Ophthalmic Inflammation and Infection*. 2013;3(35):1-9.
- [13] Mittal A., Mittal S., Bharati M.J., Ramakrishnan R., Saravanan S., Sathe P.S. Optic neuritis associated with chikungunya virus infection in south India. *Archives of Ophthalmology*. 2007;125(10):1381-1386.
- [14] Nair A.G., Biswas J., Bhende M.P. A case of bilateral chikungunya neuroretinitis. *Journal of Ophthalmic Inflammation and Infection*. 2012;2(1):39-40. DOI: 10.1007/s12348-011-0038-6.
- [15] Scripsema N.K., Sharif E., Samson C.M., Kedhar S., Rosen R.B. Chikungunya—associated uveitis and exudative retinal detachment: a case report. *Retinal Cases & Brief Reports*. 2015;9:352-356.
- [16] Babu K., Adiga M., Govekar S.R., Kumar B.V., Murthy K.R. Associations of Fuchs heterochromic iridocyclitis in a south Indian patient population. *Journal of Ophthalmic Inflammation and Infection*. 2013;3(14). DOI: 10.1186/1869-5760-3-14.



- [17] Mahendradas P., Shetty R., Malathi J., Madhavan H.N. Chikungunya virus iridocyclitis in Fuchs' heterochromic iridocyclitis. *Indian Journal of Ophthalmology*. 2010;58(6):545-547. DOI: 10.4103/0301-4738.71707.
- [18] Ranjan R., Ranjan S. Ocular pathology: role of emerging viruses in the asia-pacific region-a review. *Asia Pacific Journal of Ophthalmology*. 2014;3(5):299-307. DOI: 10.1097/APO.0000000000000021.
- [19] Couderc T., Lecuit M. Chikungunya virus pathogenesis: from bedside to bench. *Antiviral Research*. 2015;121:120-131. DOI: 10.1016/j.antiviral.2015.07.002.
- [20] Messaoudi I., Vomazke J., Totonchy T., Kreklywich C.N., Habberthur K., Springgay L., et al. Chikungunya virus infection results in higher and persistent viral replication in aged rhesus macaques due to defects in anti-viral immunity. *PLoS Neglected Tropical Diseases*. 2013;7(7). DOI: 10.1371/journal.pntd.0002343.
- [21] Weaver S.C., Lecuit M. Chikungunya virus and the global spread of a mosquito-borne disease. *The New England Journal of Medicine*. 2015;372(13):1231-1239. DOI: 10.1056/NEJMra1406035.
- [22] Sourisseau M., Schilte C., Casartelli N., Trouillet C., Guivel-Benhassine F., Rudnicka D., et al. Characterization of reemerging chikungunya virus. *PLoS Pathogens*. 2007;3(6):804-817.
- [23] Pardigon, N. The biology of chikungunya: a brief review of what we still do not know. *Pathologie Biologie*. 2009;57(2):127-132. DOI: 10.1016/j.patbio.2008.02.016.
- [24] Couderc T., Chretien F., Schilte C., Disson O., Brigitte M., Guivel-Benhassine F., et al. A mouse model for Chikungunya: young age and inefficient type-I interferon signaling are risk factors for severe disease. *PLoS Pathogens*. 2008;4(2). DOI: 10.1371/journal.ppat.0040029.
- [25] Couderc T., Gangneux N., Chretien F., Caro V., Le Luong T., Ducloux B., et al. Chikungunya virus infection of corneal grafts. *The Journal of Infectious Diseases*. 2012;206(6):851-859. DOI: 10.1093/infdis/jis296.
- [26] Schuffenecker I., Iteman I., Michault A., Murri S., Frangeul L., Vaney M.C., et al. Genome microevolution of chikungunya viruses causing the Indian Ocean outbreak. *PLoS Medicine*. 2006;3(7):1058-1070. DOI: 10.1371/journal.pmed.0030263.
- [27] Thorne J.E., Jabs D.A. The eye in rheumatic disease. *Duane's Ophthalmology*. 2013 ed. Lippincott Williams & Wilkin. Philadelphia. 2013. pp. 297-303.
- [28] Bodh S.A., Kumar V., Raina U.K., Ghosh B., Thakar M. Inflammatory glaucoma. *Oman Journal of Ophthalmology*. 2011;4(1):3-9. DOI: 10.4103/0974-620X.77655.
- [29] Luis Mateo L., Linn M.L., McColl S.R., Cross S., Gardner J., Suhrbier A. An arthrogenic alphavirus induces monocyte chemoattractant protein-1 and interleukin-8. *Intervirology*. 2000;43:55-60.

- [30] Teng T.S., Foo S.S., Simamarta D., Lum F.M., Teo T.H., Lulla A., et al. Viperin restricts chikungunya virus replication and pathology. *The Journal of Clinical Investigation*. 2012;122(12):4447-4460. DOI: 10.1172/JCI63120.
- [31] Khairallah M., Jelliti B., Attia S. Uveitis in the developing world. *Expert Review of Ophthalmology*. 2010;5(2):161-176.
- [32] Khairallah M., Chee S.P., Rathinam S.R., Attia S., Nadella V. Novel infectious agents causing uveitis. *International Ophthalmology*. 2010;30(5):465-483. DOI: 10.1007/s10792-009-9319-6.
- [33] Center for Disease Control and Prevention. Chikungunya fever diagnosed among international travelers. *Morbidity and Mortality Weekly Report*. 2007;56(12):276-277.
- [34] Khairallah M., Kahloun R. Ocular manifestations of emerging infectious diseases. *Current Opinion in Ophthalmology*. 2013;24(6):574-580. DOI: 10.1097/ICU.0b013e3283654e09.
- [35] Duffy M.R., Chen T., Hancock W.T., Powers A.M., Kool J.L., Lanciotti L.S., et al. Zika virus outbreak on Yap Island, Federated States of Micronesia. *New England Journal of Medicine*. 2009;360(24):2536-2543.
- [36] Hayes, E. B. Zika virus outside Africa. *Emerging Infectious Diseases*. 2009;15(9):1347-50. DOI: 10.3201/eid1509.090442.
- [37] Ng A.W., Teon S.C. Dengue eye disease. *Survey of Ophthalmology*. 2015;60(2):106-114. DOI: 10.1016/j.survophthal.2014.07.003.
- [38] Mahendradas P., Shetty R., Narayana K.M., Shetty B.K. In vivo confocal microscopy of keratic precipitates in infectious versus noninfectious uveitis. *Ophthalmology*. 2010;117(2):373-380. DOI: 10.1016/j.opthta.2009.07.016.
- [39] Kanski J.J., Bowling B. Uveitis. In: *Clinical Ophthalmology. A Systematic Approach*. 7th ed. Elsevier España; 2011. pp. 401-471.
- [40] Nalcacioglu-Yüksekkaya P., Ozdal P.C., Teke M.Y., Kara C., Ozturk F. Presumed herpetic anterior uveitis: a study with retrospective analysis of 79 cases. *European Journal of Ophthalmology*. 2014;24(1):14-20. DOI: 10.5301/ejo.5000331.
- [41] Mittal A., Mittal S., Bharathi J.M., Ramakrishnan R., Sathe P.S. Uveitis during outbreak of chikungunya fever. *Ophthalmology*. 2007;114(9):1798.
- [42] Jimenez-Canizales C.E., Medina-Gaitan D.A., Mondragon-Cardona A.E., Rodriguez-Morales A.J. Letter to editor: from imported to an endemic disease: impact of chikungunya virus disease in the hospital epidemiology, Tolima, Colombia, 2014-2015. *Recent Patents on Anti-Infective Drug Discovery*. 2015;10(1):64-66.
- [43] Rodriguez-Morales A.J., Cardenas-Giraldo E.V., Montoya-Arias C.P., Guerrero-Matituy E.A., Bedoya-Arias J.E., Ramirez-Jaramillo V., et al. Mapping chikungunya fever in municipalities of one coastal department of Colombia (Sucre) using geographic in-

- formation system (GIS) during 2014 outbreak: implications for travel advice. *Travel Medicine and Infectious Disease*. 2015;13(3):256-258. DOI: 10.1016/j.tmaid.2015.05.007.
- [44] Babu K., Murthy G.J. Chikungunya virus iridocyclitis in Fuchs' heterochromic iridocyclitis. *Indian Journal of Ophthalmology*. 2012;60(1):73-74. DOI: 10.4103/0301-4738.90495.
- [45] Jabs D.A., Nussenblatt R.B., Rosenbaum J.T. Standardization of Uveitis Nomenclature (SUN) Working Group: standardization of uveitis nomenclature for reporting clinical data. Results of the first international workshop. *American Journal of Ophthalmology*. 2005;140:509-516.
- [46] Sudharshan S., Ganesh S.K., Biswas J. Current approach in the diagnosis and management of posterior uveitis. *Indian Journal of Ophthalmology*. 2010;58(1):29-43. DOI: 10.4103/0301-4738.58470.
- [47] Murthy K.R., Venkataraman N., Satish V., Babu K. Bilateral retinitis following chikungunya fever. *Indian Journal of Ophthalmology*. 2008;56(4):329-331.
- [48] Khairallah M., Kahloun R., Yahia S.B., Jelliti B., Messaoud R. New infectious etiologies for posterior uveitis. *Ophthalmic Research*. 2013;49(2):66-72. DOI: 10.1159/000344009.
- [49] Vishwanath S., Badami K., Sriprakash K.S., Sujatha B.L., Shashidhar S.D., Shilpa Y.D. Post-fever retinitis: a single center experience from south India. *International Ophthalmology*. 2014;34(4):851-857. DOI: 10.1007/s10792-013-9891-7.
- [50] Shukla J., Saxena D., Rathinam S., Lalitha P., Joseph C.R., Sharma S., et al. Molecular detection and characterization of West Nile virus associated with multifocal retinitis in patients from southern India. *International Journal of Infectious Diseases*. 2012;16(1):53-59. DOI: 10.1016/j.ijid.2011.09.020.
- [51] Sivakumar R.R., Prajna L., Arya L.K., Muraly P., Shukla J., Saxena D., et al. Molecular diagnosis and ocular imaging of West Nile virus retinitis and neuroretinitis. *Ophthalmology*. 2013;120(9):1820-1826. DOI: 10.1016/j.ophtha.2013.02.006.
- [52] Ranjan P., Guliani B.P., Khairallah M., Mishra D. Acute necrotizing panophthalmitis in seropositive case of chikungunya: a case report and review of literature. *Journal of Clinical Ophthalmology and Research*. 2013;1(1):23-25..
- [53] PAHO/WHO. Preparedness and Response for Chikungunya Virus: Introduction in the Americas. 2011, Washington, D.C.
- [54] Khairallah M., Jelliti B., Jenzeri S. Emergent infectious uveitis. *Middle East African Journal of Ophthalmology*. 2009;16(4):225-238.
- [55] Gupta A., Gupta V., Herbort C.P., Khairallah M. Chikungunya in uveitis. In: *Uveitis: Text & Imaging*. 1st ed. New Delhi: Jaypee Brothers; 2008. pp. 706-712.