

We are IntechOpen, the world's leading publisher of Open Access books Built by scientists, for scientists

4,800

Open access books available

122,000

International authors and editors

135M

Downloads

Our authors are among the

154

Countries delivered to

TOP 1%

most cited scientists

12.2%

Contributors from top 500 universities



WEB OF SCIENCE™

Selection of our books indexed in the Book Citation Index
in Web of Science™ Core Collection (BKCI)

Interested in publishing with us?
Contact book.department@intechopen.com

Numbers displayed above are based on latest data collected.
For more information visit www.intechopen.com



The Cardiomyopathy of Sickle Cell Disease

Omar Niss and Charles T. Quinn

Additional information is available at the end of the chapter

<http://dx.doi.org/10.5772/64321>

Abstract

Cardiac morbidity, early mortality, and sudden death are the major consequences of sickle cell disease (SCD) in patients surviving into adulthood. Pulmonary hypertension (PH), elevated tricuspid regurgitant jet velocity (TRV), and diastolic dysfunction have all been identified to correlate with early mortality in adults with SCD. However, the unifying pathophysiology behind these abnormalities and its connection with early mortality and sudden death have not been recognized previously. We have found that SCD patients have a unique cardiomyopathy characterized by restrictive physiology (diastolic dysfunction, left atrial dilation and normal systolic function) superimposed on features of hyperdynamic circulation (left ventricular [LV] enlargement and eccentric LV hypertrophy). The restrictive cardiomyopathy of SCD causes pulmonary congestion and post-capillary PH. This can be detected by a mild elevation in TRV, which is likely a marker of the SCD-related cardiomyopathy rather than pulmonary arterial disease. Similar to other restrictive cardiomyopathies, the SCD cardiomyopathy predisposes to arrhythmias and sudden death, even when pulmonary pressures are not severely elevated. We have also found that diffuse myocardial fibrosis is common in SCD and may underlie the diastolic dysfunction, but more studies are needed to understand the mechanisms of SCD-related cardiomyopathy and to identify new therapies to decrease cardiac morbidity and improve the life expectancy of SCD patients.

Keywords: sickle cell, cardiomyopathy, restrictive physiology, pulmonary hypertension

1. Introduction

Improvements in the medical care of sickle cell disease (SCD) in the last few decades have led to a significant decrease in childhood mortality in developed countries [1]. As more patients live into adulthood, the cumulative burden of acute and chronic organ damage has become an

important determinant of quality of life, morbidity, and life expectancy. Although definitive data are lacking, the life expectancy of SCD patients does not appear to have improved in the last 15 years, and adult SCD-related mortality may have increased [2, 3]. Cardiopulmonary complications, including heart failure and arrhythmias, are the main causes of death in adults with SCD [4]. Sudden unexplained death is reported in 25–30% of SCD patients, and these are likely cardiopulmonary events [4, 5]. A number of studies conducted in the last two decades have examined the cardiac pathology and cardiac mortality in SCD and have identified risk factors for early mortality in SCD; however, a global understanding of the cardiac dysfunction in SCD is still lacking. Of the known adverse cardiac risk factors, elevation of the tricuspid regurgitant jet velocity (TRV) measured by echocardiography, pulmonary hypertension (PH), and diastolic dysfunction are the most consistent predictors of early mortality in adults with SCD [6–9]. The mechanisms and pathophysiology that link these risk factors to the cardiac phenotype of SCD, and that underlie unexplained complications such as arrhythmias and sudden death, are not clearly understood.

2. Pulmonary hypertension in SCD

PH has been recognized as a complication of SCD and a predictor of early mortality. Although the causes of PH in SCD are not fully known, several factors have been suggested to play a part in its pathogenesis, including endothelial dysfunction due to chronic hemolysis and secondary nitric oxide depletion, hypoxia, and chronic thromboembolic disease [10–12]. Hemodynamically, PH can be pre-capillary or pulmonary arterial hypertension (PAH) or post-capillary or pulmonary venous hypertension (PVH). PH is defined by a mean pulmonary artery pressure (PAP) ≥ 25 mmHg as measured by right heart catheterization [13]. Patients with PAH have a pulmonary capillary wedge pressure (PCWP) or left ventricular (LV) end-diastolic pressure ≤ 15 mmHg, while patients with PVH have PCWP > 15 mmHg [13]. The echocardiographic measurement of TRV, in combination with an estimated right atrial pressure, can be used to estimate the systolic PAP.

Multiple studies have shown that the prevalence of elevated PAP as estimated by echocardiography using a TRV value ≥ 2.5 m/s is 20–30% in SCD [8, 14, 15]. In addition, elevated TRV in SCD is associated with increased risk of early mortality in adults [8]. Although TRV measurements correlate with PAP, the use of TRV as a sole criterion results in overdiagnosis of PH [16]. Studies of right-sided heart catheterization, the gold standard to diagnose PH, have shown that only about 30% of SCD patients with elevated TRV have PH [17, 18]. When PH is present in SCD, PAP is usually only mildly elevated, and the pulmonary vascular resistance is not increased compared to other patient populations with PH [7, 18, 19], and this does not readily explain the associated risk of early mortality. Importantly, most SCD patients in these studies with confirmed PH actually had PVH, which is caused by left-sided heart disease, rather than PAH, which could be caused by endothelial dysfunction (**Figure 1**). In addition, therapeutic trials of PAH-directed therapy in SCD were not successful and currently these therapies are not recommended for treatment of PH in SCD [20, 21].

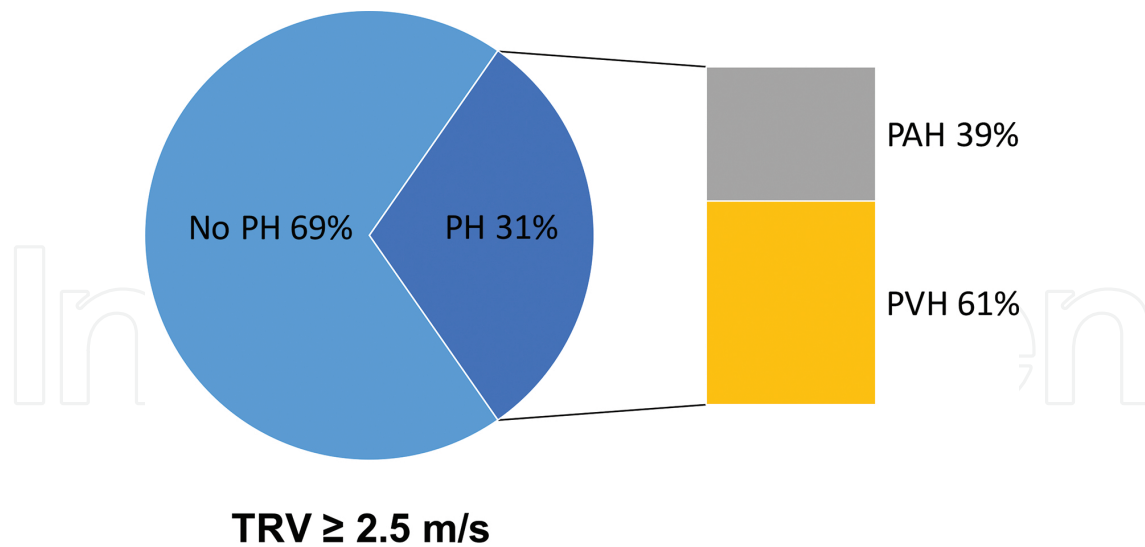


Figure 1. The percentage of SCD patients with TRV ≥ 2.5 m/s who had confirmed PH (PAH or PVH) by right-sided heart catheterization. Data are pooled from four different studies [7, 18, 22, 23].

These hemodynamic studies of SCD-related PH have improved our understanding of this complication. PH is less prevalent in SCD than was suggested by echocardiographic screening alone. It is also less severe and may be of a mixed origin, but most cases are caused by left-sided heart disease as evidenced by the higher frequency of PVH rather than pulmonary arterial disease. As a result, in 2013, The Fifth World Symposium on Pulmonary Hypertension changed the classification of SCD-related PH from “Group 1,” which indicates pulmonary arterial hypertension to “Group 5,” which refers to pulmonary hypertension with unclear or multifactorial mechanisms [13, 24]. Despite the poor diagnostic accuracy of TRV for PH, TRV is still a predictor of early mortality in adults with SCD; however, the exact cause of elevated TRV in the absence of PH and the mechanisms by which it confers increased mortality risk are poorly understood. However, elevated TRV is not associated with early mortality in children.

3. Diastolic dysfunction in SCD

Recently, diastolic dysfunction has also been recognized as an independent risk factor for mortality in SCD [9]. Diastolic dysfunction is common in SCD and was found in nearly all studies that evaluated diastolic function [17]. The prevalence and severity of diastolic dysfunction vary across studies, ranging from 11 to 77% depending on the criteria used to define diastolic dysfunction in each study. This wide range also reflects the challenges of diagnosing diastolic dysfunction and the lack of agreement on diagnostic criteria and classification of diastolic dysfunction in SCD. Nonetheless, common echocardiographic estimates of diastolic function are clearly abnormal in SCD. The ratio of early to late mitral flow velocities (E/A ratio), tissue Doppler annular velocities (e.g., E/e' and e'/a' ratios), and left atrial (LA) volumes are significantly abnormal in SCD, and some of these measures correlate with early mortality in SCD [9, 14, 25, 26]. Diastolic dysfunction can be detected early in life in SCD patients, and even

children may have severe diastolic dysfunction [25, 27–29]. This suggests that diastolic dysfunction likely precedes other non-anemia-related hemodynamic changes in SCD [17]. Diastolic dysfunction ranges in severity from an impaired relaxation of the ventricles to irreversible restrictive ventricular filling [30]. Progressive worsening of diastolic function eventually causes an increase in LV filling pressures and LA pressures. The elevated LA pressure, which correlates with chronic LA enlargement and an elevation in the diastolic estimate E/e' ratio, leads to an increase in PCWP and some degree of PH [31]. Diastolic dysfunction is the major cause of PVH in SCD [32]. Despite the significance of diastolic dysfunction in SCD, there is still a need to define diastolic dysfunction and identify diastolic function parameters that are least affected by the hyperdynamic state of SCD. There is also a lack of understanding of the mechanisms that predispose to diastolic dysfunction in SCD. Cardiac iron overload, which plays a major part in cardiac pathology and diastolic dysfunction in thalassemia [33], is rare in SCD [34, 35] and unlikely to be a major cause of diastolic dysfunction in most individuals. More studies are needed to identify the underlying cause of diastolic dysfunction in SCD [36].

4. Anemia-related hyperdynamic features

The complex effects of chronic anemia on the heart are the result of various compensatory cardiovascular mechanisms to anemia. Altered blood viscosity, tissue hypoxia, and increased sympathetic tone are some of the factors that drive cardiovascular hemodynamic changes in anemia [37]. Chronic anemia causes arteriolar dilation and decreased afterload, while the decreased venous tone increases the preload. The increased preload, coupled with increased sympathetic tone, leads to increased stroke volume and cardiac output. Together, these changes lead to a state of volume overload [38–40]. Chronic volume overload and increased cardiac load over time leads to cardiac enlargement and left ventricular hypertrophy (LVH) [41]. LVH is an adaptive mechanism to prolonged volume or pressure overload. In states of volume overload, LVH is eccentric and defined by increased LV internal dimension with a normal ratio of wall thickness to cavity diameter (a proportionate increase in wall thickness and LV internal diameter). In contrast, concentric hypertrophy, which results from pressure overload (e.g., aortic stenosis), is characterized by increased wall thickness without a change in the ventricular chamber radius [42]. Unlike the adaptive eccentric hypertrophy of volume overload, concentric hypertrophy can become maladaptive and may lead to ventricular stiffening and heart failure over time. Typical features of volume overload characterize the hearts of SCD patients: increased stroke volume and cardiac output, increased LV end-diastolic dimensions, and eccentric LVH [17]. It is also important to note that LV dilation in SCD is associated with an increased ejection fraction and stroke volume and is different from LV dilation of “failing” ventricles, typically seen in dilated cardiomyopathies, where LV dilation is associated with LV systolic dysfunction. While anemia-related hyperdynamic features are prominent in SCD, it is difficult to differentiate fully the effects of anemia from the effects of other pathologic processes of SCD, such as vaso-occlusion and inflammation, in the heart. The

contribution of anemic-hyperdynamic features to other pathologic cardiac features (i.e., diastolic dysfunction, elevated TRV, and PH) has yet to be established.

5. The cardiomyopathy of SCD

Until recently, there has not been a unifying cardiac pathophysiology identified to explain the cardiac features of SCD: mild PH, elevated TRV, diastolic dysfunction, LA dilation, and LV dilation with normal systolic function. We have reported that patients with SCD have a unique cardiomyopathy with restrictive physiology that is superimposed on hyperdynamic features [17]. This cardiomyopathy with restrictive physiology provides an explanation for most cardiac features of SCD.

5.1. Restrictive cardiac physiology

Restrictive physiology is essentially defined by a stiff myocardium that causes the ventricular pressure to rise precipitously with only small increases in volume [43]. It is primarily a disease of the heart muscle that causes decreased myocardial compliance and, therefore, diastolic dysfunction, resulting in elevation in ventricular filling pressures and LA pressures and restricted filling. Restrictive cardiomyopathies (RCM) can be primary, which constitutes 5% of primary cardiomyopathies [44], or secondary to infiltrative diseases (e.g., sarcoidosis or amyloidosis), radiation, or chemotherapy [45]. Progressive fibrosis of the myocardium leading to impaired ventricular relaxation and progressive diastolic dysfunction is the primary mechanism underlying the different forms of RCM. RCM is defined by diastolic dysfunction, atrial enlargement, normal systolic function, and ventricles of normal size [44]. Unlike systolic cardiomyopathies, e.g., dilated cardiomyopathy, which is characterized by enlarged ventricles with decreased systolic function, RCM is a primary diastolic cardiomyopathy and the ventricular volumes are normal or small in primary RCM. The outcome of primary RCM is poor without heart transplantation. Age and LA size are the strongest predictors of mortality in RCM [46]. PH, venous and arterial, is a well-known consequence of RCM that is associated with a worse outcome [47]. In addition, ischemia and arrhythmias, likely from fibrosis encasing the conducting pathways, are the most common causes of death in RCM [48]. Indeed, sudden unexpected death happens in about 30% of patients with RCM [44].

5.2. Cardiomyopathy with restrictive physiology in SCD

We reviewed the echocardiographic data on SCD patients at Cincinnati Children's Hospital Medical Center and conducted a meta-analysis of reported cardiac studies in SCD. Across all the studies, we observed a pattern consistent with a cardiomyopathy with combined features of restrictive physiology and hyperdynamic circulation. The primary features of the SCD-related cardiomyopathy are (1) diastolic dysfunction, (2) LA dilation, and (3) LV enlargement with normal systolic function [17]. One main difference between primary RCM and the restrictive cardiomyopathy of SCD is LV enlargement, which is not seen in primary RCM. Indeed, formal criteria for RCM exclude enlarged ventricles, but this distinction is made to

differentiate RCM from dilated cardiomyopathy. While small- or normal-size ventricles define primary RCM, which distinguishes it from the dilated cardiomyopathies with systolic dysfunction, the LV enlargement in SCD is associated with normal or even increased systolic function in SCD. Therefore, LV dilation is one of the hyperdynamic features that coexists with the features of restrictive physiology in the hearts of SCD patients.

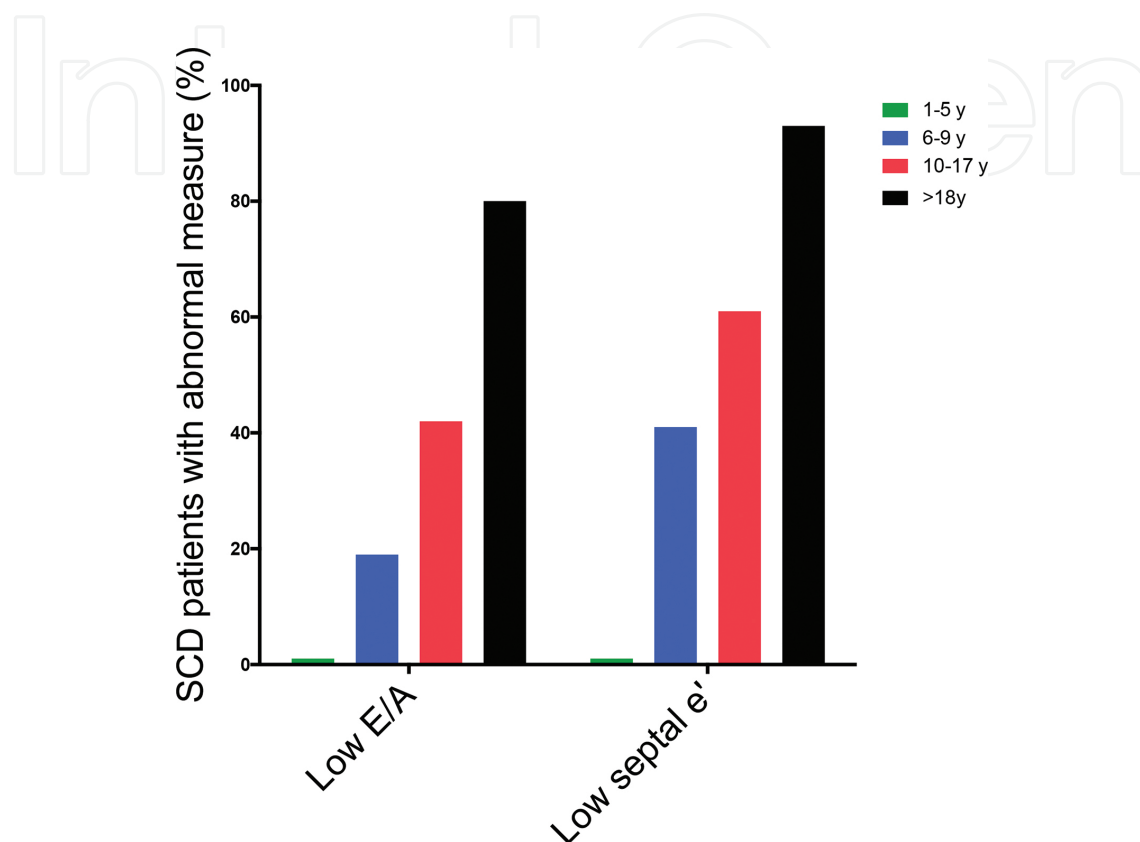


Figure 2. The percentage of SCD patients with low E/A ratio and septal e' (z-score less than -1) in the following age groups: 1–5 years, 6–9 years, 10–17 years, and older than 18 years.

In our echocardiographic study of 134 patients with SCD (age range from 3 to 22 years), diastolic dysfunction and LA enlargement were common [17]. Impaired relaxation, as reflected by abnormal tissue Doppler early velocity e' and decreased E/A ratio, worsened with age (**Figure 2**), while severe diastolic dysfunction, defined by severely abnormal E/ e' ratio, was seen in up to 14% of this group of young patients. In addition, LA enlargement was observed in 62% of patients and was the most enlarged heart chamber. While LV enlargement and eccentric LVH were also observed, LA enlargement was more common and disproportionate to LV enlargement, reflecting the different mechanisms underlying LV and LA enlargement. Similar to other studies in SCD, the systolic function was normal in our study [49].

The same cardiac pattern was observed in a meta-analysis of the published cardiac studies in SCD, combining data on more than 5000 patients from 68 different studies [17]. LV enlargement was more pronounced in the meta-analysis as it included older patients with more severe anemia. Consistent with previous studies, we confirmed that LA enlargement is an early

cardiac feature that precedes the enlargement of other cardiac chambers in SCD [27, 50–52]. Over time, LV enlargement and LVH become more prominent because of chronic volume overload [41, 49]. At that later stage, the SCD cardiomyopathy can be described by 4-chamber enlargement, diastolic dysfunction, and normal systolic function [36]. However, the restrictive physiology remains an important and an early hemodynamic feature of the SCD cardiomyopathy that can be masked by the 4-chamber enlargement in adults with SCD. Increased LV filling and LA pressures characterize restrictive physiology, which subsequently leads to mild PVH and TRV elevation. Indeed, TRV was significantly associated with the restrictive component of the SCD cardiomyopathy (diastolic dysfunction and LA enlargement), suggesting that TRV is likely a marker of the restrictive cardiomyopathy of SCD [17].

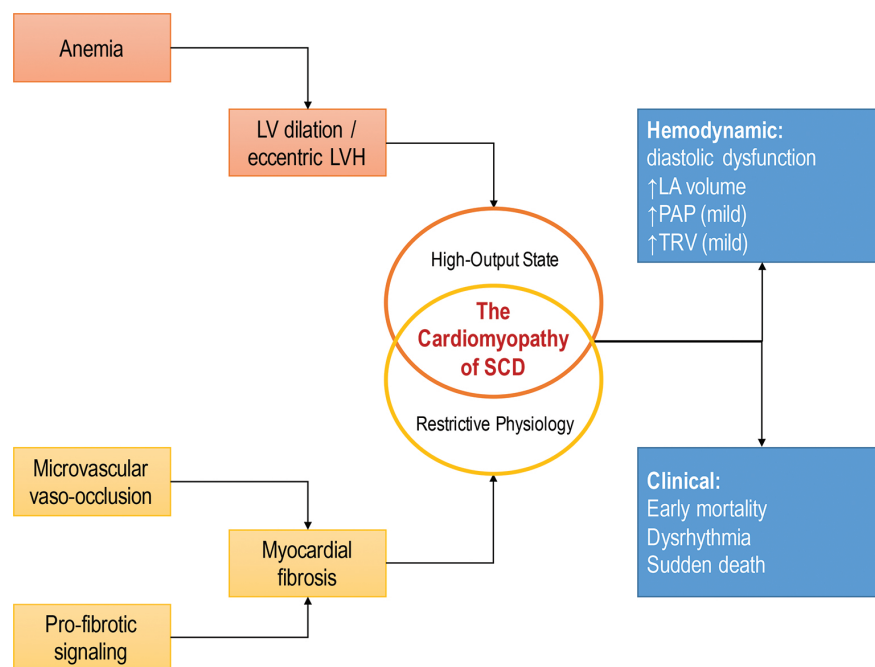


Figure 3. Schema of the proposed pathophysiologic construct of the cardiomyopathy of SCD.

In summary, the SCD-related cardiomyopathy is a restrictive cardiomyopathy, defined by diastolic dysfunction and LA enlargement, superimposed on hyperdynamic features of LV enlargement with normal systolic function. The SCD cardiomyopathy causes passive pulmonary congestion and mild PVH, which is common in SCD, and causes mild elevation in TRV that is detected by echocardiography (**Figure 3**). Interestingly, both PVH and PAH can result from diastolic failure and restrictive physiology [32]. This unique cardiomyopathy seen in most patients with SCD may coincide with PAH (confirmed by right heart catheterization with low PCWP and elevated pulmonary vascular resistance), possibly caused by endothelial dysfunction, in a small group of patients. However, the majority of SCD patients with cardiac dysfunction lack hemodynamic evidence of PAH, and most of their cardiac pathology can be explained by this unique SCD-related cardiomyopathy. The similarities in the patterns and frequency of mortality between SCD patients and patients with primary RCM are notable. The

high rate of arrhythmias and sudden death, especially at times of stress, are common consequences of restrictive physiology in RCM and are complications of SCD that have not been explained and can likely be attributed to the restrictive cardiomyopathy of SCD.

5.3. Myocardial tissue characterization in SCD: cardiac MRI and autopsy studies

The cause of diastolic dysfunction and restrictive physiology in SCD is unclear. Cardiac MRI (CMR) studies have shown that cardiac iron overload is rare in SCD patients, even when systemic iron overload is present [36, 53, 54], and is unlikely to be a primary mechanism underlying cardiac dysfunction in SCD. The small number of autopsy studies in SCD provided the earliest insight into cardiac histopathology in SCD. Some of the findings in autopsy specimens include chamber enlargement and increased heart weight, pulmonary vascular changes [55, 56], and myocardial fibrosis [36, 56, 57]. Different myocardial fibrosis patterns were noted: transmural fibrosis/scarring without evidence of atherosclerosis, patchy fibrosis, diffuse myocardial fibrosis, and fibrotic foci involving the conduction system predisposing to arrhythmias [36, 58].

Recent CMR studies have provided further information about the tissue characteristics of the sickle hearts using non-invasive techniques. One technique, late gadolinium enhancement (LGE), is useful in detecting scar tissue or focal macroscopic fibrosis based on differences in the volumes of distribution of the extracellular contrast agent, gadolinium [59]. In SCD, LGE detection has been variable. Most CMR studies detected LGE in a subset of patients, reaching up to 25% of evaluated patients in one study [36, 54, 60–63]. However, because this technique is based on detecting differences in enhancement between the affected area and surrounding myocardial tissue, it will not detect diffuse myocardial fibrosis, which was also seen in the autopsies of SCD patients [36]. These autopsy and CMR studies suggest that fibrosis is probably an overlooked pathology that contributes to cardiac dysfunction in SCD. Studies are ongoing using novel CMR techniques to better characterize myocardial tissue and assess myocardial fibrosis non-invasively in SCD. Indeed, early findings from our ongoing CMR study indicate that diffuse myocardial fibrosis is common in SCD [64]. This and future studies may shed some light on the pathogenic mechanisms that underlie the cardiomyopathy of SCD.

6. Screening, diagnosis, and treatment of cardiac dysfunction in SCD

Based on the high prevalence of abnormal TRV and its correlation with PH, echocardiographic screening for PH in SCD was adopted by some groups [8]. However, because of the low predictive value of TRV in diagnosing PH in SCD and the lack of interventions that have been shown to change the outcome, if PH is detected early, echocardiographic screening for PH in SCD has become controversial. The 2014 National Heart, Lung and Blood Institute (NHLBI) Expert Panel's report on evidence-based management of SCD patients did not find sufficient evidence to make a recommendation for echocardiographic screening of asymptomatic SCD patients [65]. On the other hand, The American Thoracic Society Clinical Practice Guidelines suggested performing echocardiography every 1–3 year and increasing the frequency of

screening depending on the presence of adverse risk factors (high TRV and elevated serum NT-pro-BNP or confirmed PH) [21]. However, these are experts' opinions that are not supported by strong evidence at this point. Despite incomplete information about its different causes, an elevated TRV is an adverse prognostic marker in adults with SCD, irrespective of PH, and this finding should prompt increased clinical vigilance. Although it is not clear when to begin screening and how often to continue it, at our pediatric institution, we perform a screening echocardiogram and electrocardiogram on asymptomatic individuals with SCD starting between the ages of 15 and 18 years. We screen for chamber enlargement, especially of the LA, systolic function, and diastolic abnormalities using mitral inflow and tissue Doppler annular velocities, and elevated TRV. If cardiac abnormalities are identified, the need for follow-up imaging and referral to a cardiologist is determined individually.

Similar to the difficulties in diagnosis and screening strategies, there is no proven treatment for cardiac dysfunction or PH in SCD. Few, small observational studies showed a potential effect of PAH-directed therapy in SCD-related PH [66–68], but randomized controlled trials did not demonstrate any benefit for these therapies in SCD. Small randomized controlled trials using the endothelin receptor antagonist bosentan in SCD patients with PH were terminated early due to slow enrollment [20], and a trial comparing sildenafil to placebo in SCD patients with elevated TRV was also terminated early because of adverse events [69]. Experts' guidelines recommend against the use of PAH-directed therapy in SCD [21, 65]. The role of disease-modifying therapies (i.e., hydroxyurea and transfusions) in the treatment of PH or SCD-related cardiomyopathy is also undetermined. Limited available data suggest that hydroxyurea may be beneficial in improving TRV elevation in young patients with SCD [70, 71]. However, transfusion therapy has not been studied in PH or cardiomyopathy. The American Thoracic Society expert's panel recommends using hydroxyurea for patients with increased mortality risk or chronic transfusions for patients who cannot take or were unresponsive to hydroxyurea. However, these recommendations are based on the overall beneficial effects of these disease-modifying therapies in ameliorating other aspects of SCD and not based on a demonstrated cardiopulmonary benefit [21]. Understanding the mechanisms underlying the SCD-related cardiomyopathy and different forms of PH in SCD will be important to identify directed therapies to slow or reverse cardiac dysfunction in SCD. Until then, optimizing general SCD care (e.g., beginning or optimizing hydroxyurea or chronic transfusion therapy) is the only therapeutic option with established benefits for SCD patients.

7. Conclusions

The SCD-related cardiomyopathy is a unique restrictive cardiomyopathy superimposed on LV enlargement and LVH due to hyperdynamic circulation. SCD-related cardiomyopathy is characterized by diastolic dysfunction, LA enlargement, and normal systolic function with LV enlargement. This restrictive cardiomyopathy leads to mild PH and mild elevation in TRV. Similar to other restrictive cardiomyopathies, the SCD-related cardiomyopathy may predispose to arrhythmias and sudden death. Diffuse myocardial fibrosis may be an underlying mechanism of the restrictive cardiac physiology of SCD. Definitely establishing the mecha-

nisms underlying diastolic dysfunction and the SCD-related cardiomyopathy may lead to specific, targeted therapy to slow or reverse the cardiomyopathy and decrease the morbidity and early mortality of SCD.

Author details

Omar Niss and Charles T. Quinn*

*Address all correspondence to: Charles.Quinn@cchmc.org

Cincinnati Children's Hospital Medical Center, Cincinnati, Ohio, United States

References

- [1] Quinn, CT, Rogers, ZR, McCavit, TL, et al. Improved survival of children and adolescents with sickle cell disease. *Blood*. 2010;115:3447–3452. DOI: 10.1182/blood-2009-07-233700.
- [2] Platt, OS, Brambilla, DJ, Rosse, WF, et al. Mortality in sickle cell disease. Life expectancy and risk factors for early death. *The New England Journal of Medicine*. 1994;330:1639–1644. DOI: 10.1056/NEJM199406093302303.
- [3] Lanzkron, S, Carroll, CP, Haywood, C, Jr. Mortality rates and age at death from sickle cell disease: U.S., 1979–2005. *Public Health Reports*. 2013;128:110–116.
- [4] Fitzhugh, CD, Lauder, N, Jonassaint, JC, et al. Cardiopulmonary complications leading to premature deaths in adult patients with sickle cell disease. *American Journal of Hematology*. 2010;85:36–40. DOI: 10.1002/ajh.21569.
- [5] Mancini, EA, Culbertson, DE, Yang, YM, et al. Causes of death in sickle cell disease: An autopsy study. *British Journal of Haematology*. 2003;123:359–365.
- [6] Castro, O, Hoque, M, Brown, BD. Pulmonary hypertension in sickle cell disease: Cardiac catheterization results and survival. *Blood*. 2003;101:1257–1261. DOI: 10.1182/blood-2002-03-0948.
- [7] Fonseca, GH, Souza, R, Salemi, VM, et al. Pulmonary hypertension diagnosed by right heart catheterisation in sickle cell disease. *The European Respiratory Journal*. 2012;39:112–118. DOI: 10.1183/09031936.00134410.
- [8] Gladwin, MT, Sachdev, V, Jison, ML, et al. Pulmonary hypertension as a risk factor for death in patients with sickle cell disease. *The New England Journal of Medicine*. 2004;350:886–895. DOI: 10.1056/NEJMoa035477.

- [9] Sachdev, V, Machado, RF, Shizukuda, Y, et al. Diastolic dysfunction is an independent risk factor for death in patients with sickle cell disease. *Journal of the American College of Cardiology*. 2007;49:472–479. DOI: 10.1016/j.jacc.2006.09.038.
- [10] Gladwin, MT, Barst, RJ, Castro, OL, et al. Pulmonary hypertension and no in sickle cell. *Blood*. 2010;116:852–854. DOI: 10.1182/blood-2010-04-282095.
- [11] Fijalkowska, I, Xu, W, Comhair, SA, et al. Hypoxia inducible-factor1alpha regulates the metabolic shift of pulmonary hypertensive endothelial cells. *American Journal of Pathology*. 2010;176:1130–1138. DOI: 10.2353/ajpath.2010.090832.
- [12] Anthi, A, Machado, RF, Jison, ML, et al. Hemodynamic and functional assessment of patients with sickle cell disease and pulmonary hypertension. *American Journal of Respiratory and Critical Care Medicine*. 2007;175:1272–1279. DOI: 10.1164/rccm.200610-1498OC.
- [13] Galie, N, Hoeper, MM, Humbert, M, et al. Guidelines for the diagnosis and treatment of pulmonary hypertension: The task force for the diagnosis and treatment of pulmonary hypertension of the european society of cardiology (esc) and the european respiratory society (ers), endorsed by the international society of heart and lung transplantation (ishlt). *European Heart Journal*. 2009;30:2493–2537. DOI: 10.1093/eurheartj/ehp297.
- [14] Cabrita, IZ, Mohammed, A, Layton, M, et al. The association between tricuspid regurgitation velocity and 5-year survival in a North West London population of patients with sickle cell disease in the United Kingdom. *British Journal of Haematology*. 2013;162:400–408. DOI: 10.1111/bjh.12391.
- [15] Caughey, MC, Hinderliter, AL, Jones, SK, et al. Hemodynamic characteristics and predictors of pulmonary hypertension in patients with sickle cell disease. *The American Journal of Cardiology*. 2012;109:1353–1357. DOI: 10.1016/j.amjcard.2011.11.067.
- [16] Arcasoy, SM, Christie, JD, Ferrari, VA, et al. Echocardiographic assessment of pulmonary hypertension in patients with advanced lung disease. *American Journal of Respiratory and Critical Care Medicine*. 2003;167:735–740. DOI: 10.1164/rccm.200210-1130OC.
- [17] Niss, O, Quinn, CT, Lane, A, et al. Cardiomyopathy with restrictive physiology in sickle cell disease. *JACC Cardiovascular Imaging*. 2016;9:243–252. DOI: 10.1016/j.jcmg.2015.05.013.
- [18] Parent, F, Bachir, D, Inamo, J, et al. A hemodynamic study of pulmonary hypertension in sickle cell disease. *The New England Journal of Medicine*. 2011;365:44–53. DOI: 10.1056/NEJMoa1005565.
- [19] D'Alonzo, GE, Barst, RJ, Ayres, SM, et al. Survival in patients with primary pulmonary hypertension. Results from a national prospective registry. *Annals of Internal Medicine*. 1991;115:343–349.

- [20] Barst, RJ, Mubarak, KK, Machado, RF, et al. Exercise capacity and haemodynamics in patients with sickle cell disease with pulmonary hypertension treated with bosentan: Results of the asset studies. *British Journal of Haematology*. 2010;149:426–435. DOI: 10.1111/j.1365-2141.2010.08097.x.
- [21] Klings, ES, Machado, RF, Barst, RJ, et al. An official american thoracic society clinical practice guideline: Diagnosis, risk stratification, and management of pulmonary hypertension of sickle cell disease. *American Journal of Respiratory and Critical Care Medicine*. 2014;189:727–740. DOI: 10.1164/rccm.201401-0065ST.
- [22] Fitzgerald, M, Fagan, K, Herbert, DE, et al. Misclassification of pulmonary hypertension in adults with sickle hemoglobinopathies using Doppler echocardiography. *Southern Medical Journal*. 2012;105:300–305. DOI: 10.1097/SMJ.0b013e318256b55b.
- [23] Sharma, S, Efirid, J, Kadali, R, et al. Pulmonary artery occlusion pressure may over-diagnose pulmonary artery hypertension in sickle cell disease. *Clinical Cardiology*. 2013;36:524–530. DOI: 10.1002/clc.22153.
- [24] Simonneau, G, Gatzoulis, MA, Adatia, I, et al. Updated clinical classification of pulmonary hypertension. *Journal of the American College of Cardiology*. 2013;62:D34–D41. DOI: 10.1016/j.jacc.2013.10.029.
- [25] Hankins, JS, McCarville, MB, Hillenbrand, CM, et al. Ventricular diastolic dysfunction in sickle cell anemia is common but not associated with myocardial iron deposition. *Pediatric Blood & Cancer*. 2010;55:495–500. DOI: 10.1002/pbc.22587.
- [26] Sachdev, V, Kato, GJ, Gibbs, JS, et al. Echocardiographic markers of elevated pulmonary pressure and left ventricular diastolic dysfunction are associated with exercise intolerance in adults and adolescents with homozygous sickle cell anemia in The United States and United Kingdom. *Circulation*. 2011;124:1452–1460. DOI: 10.1161/CIRCULATIONAHA.111.032920.
- [27] Blanc, J, Stos, B, de Montalembert, M, et al. Right ventricular systolic strain is altered in children with sickle cell disease. *Journal of the American Society of Echocardiography: Official Publication of the American Society of Echocardiography*. 2012;25:511–517. DOI: 10.1016/j.echo.2012.01.011.
- [28] Eddine, AC, Alvarez, O, Lipshultz, SE, et al. Ventricular structure and function in children with sickle cell disease using conventional and tissue Doppler echocardiography. *The American Journal of Cardiology*. 2012;109:1358–1364. DOI: 10.1016/j.amjcard.2012.01.001.
- [29] Zilberman, MV, Du, W, Das, S, et al. Evaluation of left ventricular diastolic function in pediatric sickle cell disease patients. *American Journal of Hematology*. 2007;82:433–438. DOI: 10.1002/ajh.20866.
- [30] Nagueh, SF, Appleton, CP, Gillebert, TC, et al. Recommendations for the evaluation of left ventricular diastolic function by echocardiography. *Journal of the American Society*

of Echocardiography: Official Publication of the American Society of Echocardiography. 2009;22:107–133. DOI: 10.1016/j.echo.2008.11.023.

- [31] Lam, CS, Roger, VL, Rodeheffer, RJ, et al. Pulmonary hypertension in heart failure with preserved ejection fraction: A community-based study. *Journal of the American College of Cardiology*. 2009;53:1119–1126. DOI: 10.1016/j.jacc.2008.11.051.
- [32] Gordeuk, VR, Castro, OL, Machado, RF. Pathophysiology and treatment of pulmonary hypertension in sickle cell disease. *Blood*. 2016;127:820–828. DOI: 10.1182/blood-2015-08-618561.
- [33] Kremastinos, DT, Farmakis, D, Aessopos, A, et al. Beta-thalassemia cardiomyopathy: History, present considerations, and future perspectives. *Circulation: Heart Failure*. 2010;3:451–458. DOI: 10.1161/CIRCHEARTFAILURE.109.913863.
- [34] Meloni, A, Puliyl, M, Pepe, A, et al. Cardiac iron overload in sickle-cell disease. *American Journal of Hematology*. 2014;89:678–683. DOI: 10.1002/ajh.23721.
- [35] Wood, JC. Cardiac iron across different transfusion-dependent diseases. *Blood Reviews*. 2008;22(Suppl 2):S14–S21. DOI: 10.1016/S0268-960X(08)70004-3.
- [36] Desai, AA, Patel, AR, Ahmad, H, et al. Mechanistic insights and characterization of sickle cell disease-associated cardiomyopathy. *Circulation Cardiovascular Imaging*. 2014;7:430–437. DOI: 10.1161/CIRCIMAGING.113.001420.
- [37] Metivier, F, Marchais, SJ, Guerin, AP, et al. Pathophysiology of anaemia: Focus on the heart and blood vessels. *Nephrology Dialysis Transplantation*. 2000;15(Suppl 3):14–18.
- [38] London, GM, Guerin, AP, Marchais, SJ, et al. Cardiac and arterial interactions in end-stage renal disease. *Kidney International*. 1996;50:600–608.
- [39] Muller, R, Steffen, HM, Brunner, R, et al. Changes in the alpha adrenergic system and increase in blood pressure with recombinant human erythropoietin (rhuepo) therapy for renal anemia. *Clinical and Investigative Medicine*. 1991;14:614–622.
- [40] Varat, MA, Adolph, RJ, Fowler, NO. Cardiovascular effects of anemia. *American Heart Journal*. 1972;83:415–426.
- [41] Lester, LA, Sodt, PC, Hutcheon, N, et al. Cardiac abnormalities in children with sickle cell anemia. *Chest*. 1990;98:1169–1174.
- [42] Katz, AM. Maladaptive growth in the failing heart: The cardiomyopathy of overload. *Cardiovascular Drugs Therapy*. 2002;16:245–249.
- [43] Kushwaha, SS, Fallon, JT, Fuster, V. Restrictive cardiomyopathy. *The New England Journal of Medicine*. 1997;336:267–276. DOI: 10.1056/NEJM199701233360407.
- [44] Webber, SA, Lipshultz, SE, Sleeper, LA, et al. Outcomes of restrictive cardiomyopathy in childhood and the influence of phenotype: A report from the pediatric cardiomy-

- opathy registry. *Circulation*. 2012;126:1237–1244. DOI: 10.1161/CIRCULATIONAHA.112.104638.
- [45] Nihoyannopoulos, P, Dawson, D. Restrictive cardiomyopathies. *European journal of echocardiography: The Journal of the Working Group on Echocardiography of the European Society of Cardiology*. 2009;10:iii23–iii33. DOI: 10.1093/ejehocard/jep156.
- [46] Rivenes, SM, Kearney, DL, Smith, EO, et al. Sudden death and cardiovascular collapse in children with restrictive cardiomyopathy. *Circulation*. 2000;102:876–882.
- [47] Murtuza, B, Fenton, M, Burch, M, et al. Pediatric heart transplantation for congenital and restrictive cardiomyopathy. *The Annals of Thoracic Surgery*. 2013;95:1675–1684. DOI: 10.1016/j.athoracsur.2013.01.014.
- [48] Walsh, MA, Grenier, MA, Jefferies, JL, et al. Conduction abnormalities in pediatric patients with restrictive cardiomyopathy. *Circulation: Heart Failure*. 2012;5:267–273. DOI: 10.1161/CIRCHEARTFAILURE.111.964395.
- [49] Poludasu, S, Ramkissoon, K, Saliccioli, L, et al. Left ventricular systolic function in sickle cell anemia: A meta-analysis. *Journal of Cardiac Failure*. 2013;19:333–341. DOI: 10.1016/j.cardfail.2013.03.009.
- [50] Caldas, MC, Meira, ZA, Barbosa, MM. Evaluation of 107 patients with sickle cell anemia through tissue doppler and myocardial performance index. *Journal of the American Society of Echocardiography: Official Publication of the American Society of Echocardiography*. 2008;21:1163–1167. DOI: 10.1016/j.echo.2007.06.001.
- [51] Colombatti, R, Maschietto, N, Varotto, E, et al. Pulmonary hypertension in sickle cell disease children under 10 years of age. *British Journal of Haematology*. 2010;150:601–609. DOI: 10.1111/j.1365-2141.2010.08269.x.
- [52] Simmons, BE, Santhanam, V, Castaner, A, et al. Sickle cell heart disease. Two-dimensional echo and Doppler ultrasonographic findings in the hearts of adult patients with sickle cell anemia. *Archives of Internal Medicine*. 1988;148:1526–1528.
- [53] Wood, JC, Tyszka, JM, Carson, S, et al. Myocardial iron loading in transfusion-dependent thalassemia and sickle cell disease. *Blood*. 2004;103:1934–1936. DOI: 10.1182/blood-2003-06-1919.
- [54] Westwood, MA, Shah, F, Anderson, LJ, et al. Myocardial tissue characterization and the role of chronic anemia in sickle cell cardiomyopathy. *Journal of Magnetic Resonance Imaging : JMRI*. 2007;26:564–568. DOI: 10.1002/jmri.21018.
- [55] Haque, AK, Gokhale, S, Rampy, BA, et al. Pulmonary hypertension in sickle cell hemoglobinopathy: A clinicopathologic study of 20 cases. *Human Pathology*. 2002;33:1037–1043.
- [56] Martin, CR, Johnson, CS, Cobb, C, et al. Myocardial infarction in sickle cell disease. *Journal of the National Medical Association*. 1996;88:428–432.

- [57] Darbari, DS, Kple-Faget, P, Kwagyan, J, et al. Circumstances of death in adult sickle cell disease patients. *American Journal of Hematology*. 2006;81:858–863. DOI: 10.1002/ajh.20685.
- [58] James, TN, Riddick, L, Massing, GK. Sickle cells and sudden death: Morphologic abnormalities of the cardiac conduction system. *Journal of Laboratory Clinical Medicine*. 1994;124:507–520.
- [59] Doltra, A, Amundsen, BH, Gebker, R, et al. Emerging concepts for myocardial late gadolinium enhancement mri. *Current Cardiology Reviews*. 2013;9:185–190.
- [60] Bratis, K, Kattamis, A, Athanasiou, K, et al. Abnormal myocardial perfusion-fibrosis pattern in sickle cell disease assessed by cardiac magnetic resonance imaging. *International Journal of Cardiology*. 2013;166:e75–76. DOI: 10.1016/j.ijcard.2013.01.055.
- [61] Junqueira, FP, Fernandes, JL, Cunha, GM, et al. Right and left ventricular function and myocardial scarring in adult patients with sickle cell disease: A comprehensive magnetic resonance assessment of hepatic and myocardial iron overload. *Journal of Cardiovascular Magnetic Resonance: Official Journal of the Society for Cardiovascular Magnetic Resonance*. 2013;15:83. DOI: 10.1186/1532-429X-15-83.
- [62] Raman, SV, Simonetti, OP, Cataland, SR, et al. Myocardial ischemia and right ventricular dysfunction in adult patients with sickle cell disease. *Haematologica*. 2006;91:1329–1335.
- [63] Nguyen, KL, Tian, X, Alam, S, et al. Elevated transpulmonary gradient and cardiac magnetic resonance-derived right ventricular remodeling predict poor outcomes in sickle cell disease. *Haematologica*. 2016;101:e40–43. DOI: 10.3324/haematol.2015.125229.
- [64] Niss, O, Taylor, MD, Moore, R, Fleck, R, Malik, P, Towbin, JA, Quinn, CT. 2015 Aspho abstracts. *Pediatric Blood & Cancer*. 2015;62:S21–S119. DOI: 10.1002/pbc.25540.
- [65] Yawn, BP, Buchanan, GR, Afenyi-Annan, AN, et al. Management of sickle cell disease: Summary of the 2014 evidence-based report by expert panel members. *The Journal of the American Medical Association*. 2014;312:1033–1048. DOI: 10.1001/jama.2014.10517.
- [66] Machado, RF, Martyr, S, Kato, GJ, et al. Sildenafil therapy in patients with sickle cell disease and pulmonary hypertension. *British Journal of Haematology*. 2005;130:445–453. DOI: 10.1111/j.1365-2141.2005.05625.x.
- [67] Minniti, CP, Machado, RF, Coles, WA, et al. Endothelin receptor antagonists for pulmonary hypertension in adult patients with sickle cell disease. *British Journal of Haematology*. 2009;147:737–743. DOI: 10.1111/j.1365-2141.2009.07906.x.
- [68] Morris, CR. New strategies for the treatment of pulmonary hypertension in sickle cell disease : The rationale for arginine therapy. *Treatments in Respiratory Medicine*. 2006;5:31–45.

- [69] Machado, RF, Barst, RJ, Yovetich, NA, et al. Hospitalization for pain in patients with sickle cell disease treated with sildenafil for elevated TRV and low exercise capacity. *Blood*. 2011;118:855–864. DOI: 10.1182/blood-2010-09-306167.
- [70] Olnes, M, Chi, A, Haney, C, et al. Improvement in hemolysis and pulmonary arterial systolic pressure in adult patients with sickle cell disease during treatment with hydroxyurea. *American Journal of Hematology*. 2009;84:530–532. DOI: 10.1002/ajh.21446.
- [71] Pashankar, FD, Carbonella, J, Bazy-Asaad, A, et al. Longitudinal follow up of elevated pulmonary artery pressures in children with sickle cell disease. *British Journal of Haematology*. 2009;144:736–741. DOI: 10.1111/j.1365-2141.2008.07501.x.