

We are IntechOpen, the world's leading publisher of Open Access books Built by scientists, for scientists

4,800

Open access books available

122,000

International authors and editors

135M

Downloads

Our authors are among the

154

Countries delivered to

TOP 1%

most cited scientists

12.2%

Contributors from top 500 universities



WEB OF SCIENCE™

Selection of our books indexed in the Book Citation Index
in Web of Science™ Core Collection (BKCI)

Interested in publishing with us?
Contact book.department@intechopen.com

Numbers displayed above are based on latest data collected.
For more information visit www.intechopen.com



Ocular Parasitic Infections – An Overview

Nancy Malla and Kapil Goyal

Additional information is available at the end of the chapter

<http://dx.doi.org/10.5772/64137>

Abstract

Eyes are said to be the windows of body, by which this beautiful world is visualized. Human eye has a unique structure and is vulnerable to numerous infections. Whenever anatomical structures are breached, host defenses come into play, but if infection is severe and not treated timely, it could lead to visual impairment or blindness. Parasitic infections are considered, the significant causes of ophthalmic diseases worldwide. In this chapter, an overview of ocular parasitic infections (OPI) is detailed out, with an initial brief introduction followed by description of anatomy of the human eye and various defense mechanisms to provide better understanding of the parasitic infections affecting different parts of human eye. The last part includes individual details of various human ocular parasitic infections.

Ocular infections can be classified based on either the etiological agent or according to the anatomical site of infection. The parasitic etiological agents include mainly protozoa, helminths and ectoparasites. Due to the complex life cycles of parasites and their tendency to cause wide range of pathologic lesions, different parasites/parasitic infections have been addressed separately, including brief epidemiology, clinical features, diagnosis and treatment.

Keywords: Eye, parasitic infections, protozoa, nematodes, cestodes, trematodes, ectoparasites

1. Introduction

The ocular parasitic infections (OPI) are considered significant causes of ocular pathologies worldwide [1]. The common protozoal parasites primarily infecting the ocular tissue(s) are *Acanthamoeba* species and *Toxoplasma gondii* [2–7]. In addition, case studies of eye diseases caused by *Leishmania*, *Trypanosoma cruzi*, *Entamoeba histolytica*, *Hartmannella*, *Plasmodium falciparum*, *Microsporidia* and *Giardia lamblia* have been rarely reported [1, 8, 9]. Among the helminths, ocular infections are caused primarily by nematode parasites (*Onchocerca volvulus*,

Loa loa, *Toxocara canis* and *Toxocara cati*) [1, 8, 10–12]. In addition, case studies of ocular infections caused by other nematodes (*Angiostrongylus cantonensis*, *Dirofilaria repens*, *Trichinella spiralis*, *Thelazia callipaeda*, *Baylisascaris procyonis*, *Wuchereria bancrofti* and *B. malayi*), cestodes (*T. solium cysticercus*, *Echinococcus granulosus*, and *Multiceps multiceps* larvae) and trematodes (*Fasciola hepatica* and *Schistosoma* species) have been reported from different geographical areas [1, 8, 13–15]. The ectoparasites infecting the eye include larvae of flies [16] (*Oestrus ovis*, *Rhinoestrus purpureus*, *Dermatobia hominis*, *Chrysomia bezziana*, *Lucilia* spp., *Cuterebra*, *Hypoderma*, *Cochliomyia*, *Wohlfahrtia*, *Gastrophilus*), *Phthirus pubis*, hard and soft ticks (belonging to class Arachnida) [1, 17]. Ocular pentastomiasis caused by the larval stage of Pentastomida, the crustacean-related parasites, is reported to cause permanent loss of vision due to the retinal detachment or lens subluxation [18]. Further, with the advent of HIV/AIDS (human immunodeficiency virus/acquired immune deficiency syndrome), few ocular infections have also been reported in HIV-infected patients [19, 20].

Ocular parasitic infections have been widely reported from different geographical areas (Table 1), mainly depending on the endemicity of the parasite(s). The prevalence depends primarily on the geographical distribution of the parasite, socioeconomic environment and immune status of the patient. The common modes of infection are direct contact (blepharoconjunctivitis caused by *Leishmania*, *Acanthamoeba* keratitis, microsporidial infections, infestation caused by lice and mites) [21–23], through blood stream (*Toxoplasma* chorioretinitis, retinal involvement in malaria, uveitis caused by *Toxocara*) [1, 23, 24], congenital transmission (*Toxoplasmosis*) and zoonotic transmission (primarily infectious diseases of animals that can naturally be transmitted to humans) [25]. In addition, few of the helminths that may lead to ocular infection are transmitted by vectors (onchocerciasis, dirofilariasis and thelaziasis), consumption of contaminated food (sparganosis, trichinellosis) and indirectly from the environment (fascioliasis, ascariasis and echinococcosis).

Adult and/or larval stages of the parasites may reside in human ocular tissues externally or in the ocular globe. The clinical symptoms and signs vary, depending on the etiological agent and the ocular tissue/part involved. However, local defense mechanisms and host immune responses play role in establishing the infection. The pathology in the eye can occur due to direct damage by the infecting pathogen, indirectly by toxic products, immune mediated or ectopic localization by ectoparasites. The clinical diagnosis usually mimics other pathologies due to numerous etiologies both infectious and non-infectious, which can cause conjunctivitis, keratitis, uveitis and endophthalmitis [26]. Thus, a high index of clinician suspicion is required for infective parasite etiology in patients having inflammation in the eye. In addition, eye can be involved in various systemic disorders and thorough ocular examination along with history of travel to the endemic area, risk factors and other associated medical illness that help in establishing the preliminary diagnosis. However, confirmatory diagnosis is usually achieved by direct demonstration of parasite in clinical samples and/or pathological changes observed by either slit lamp or biopsy examination [1, 8, 27, 28]. The antigen and antibody detection in ocular fluids and/or serum usually substantiates the clinical diagnosis in few parasitic infections (*Toxoplasmosis*, malaria, leishmaniasis, ocular gnathostomiasis, cysticercosis, toxocariasis, echinococcosis) [1, 10, 29, 30]. Molecular techniques including detection of parasite DNA by polymerase chain reaction (PCR) have added new dimensions in the diagnosis and species identification [31–36]. The treatment of choice is mostly surgical excision,

while in few infections, medical treatment is usually advised either in conjunction with surgical procedure (onchocerciasis, dirofilariasis [37], cysticercosis [38], echinococcosis [39], myiasis, infections due to ticks and mites) or for inoperable patients. Although surgical excision is usually reserved for worms that are large, it is also recommended for space-occupying lesions of the orbit. Drug resistance is posing problem for the effective medical treatment, thus necessitating the discovery of new antiparasitic drugs [32]. Prevention and control measures differ in various infections and usually include proper health education and awareness of various risk factors. The various experimental animal models for few of the ocular infections have been successfully established to study the pathogenic mechanisms, drug efficacy and local immune responses [40, 41].

Although issues mainly are the timely diagnosis and treatment, yet many challenges need to be considered/addressed.

2. Anatomy

Diagrammatic representation of human eye depicting significant ocular parasitic infections is shown in Figure 1.

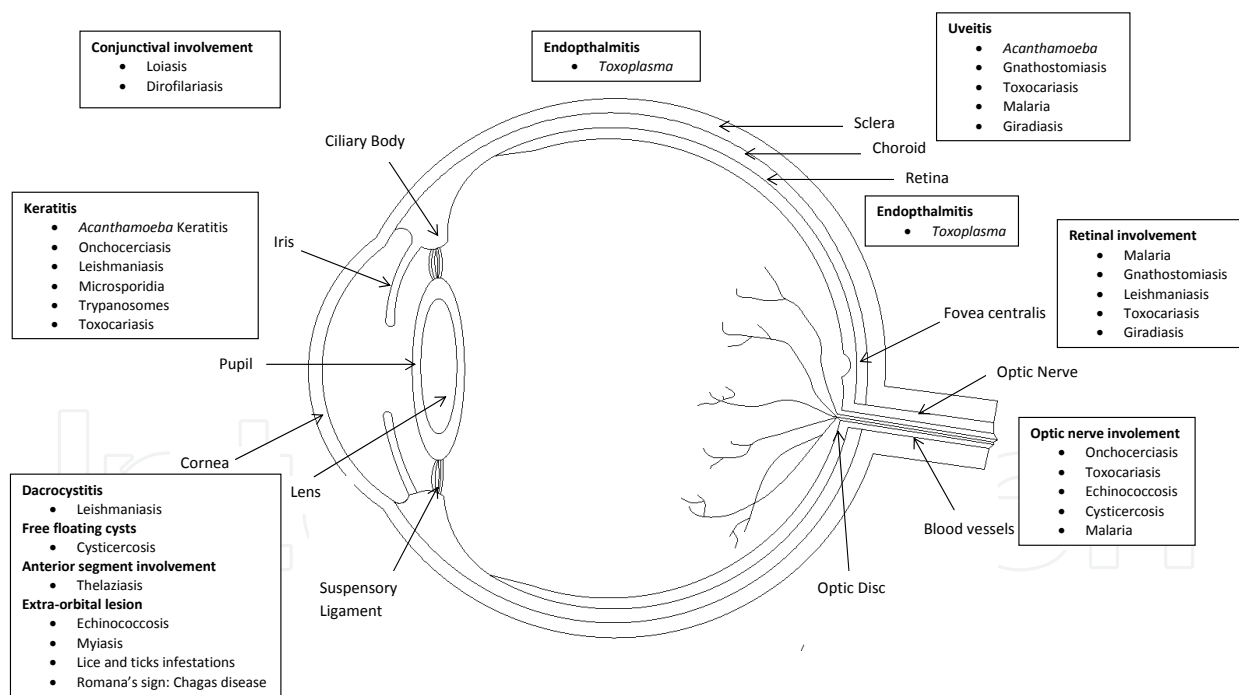


Figure 1. Human eye anatomy depicting significant ocular parasitic infections.

2.1. Orbits

The eye balls along with extraocular muscles, nerves, blood vessels and fat are situated in the bony cavities known as orbits. The periosteal covering of the bony orbit fuses with orbital

septum and duramater. Abscess due to infectious agent can localize in the space beneath the periosteum. The paranasal sinuses are separated from it by the floor, medial wall and roof of the orbit and may act as the source of orbital infection. Lamina papyracea are the thinnest bony walls, which separate orbit from ethmoidal sinuses. Thus, any breach in it causes the ingress of sinus microbiota to orbital tissue leading to infection. Orbital cellulitis can also be caused by direct extension of the infection from the ethmoidal sinuses to the orbital cavity. The lateral wall of the sphenoidal sinus constitutes the medial wall of the optic canal and infection of the former can percolate to the latter causing optic nerve damage and visual loss. There are various apertures present in the orbital cavity, which provides the route of communication with the adjacent structures. The superior and inferior orbital fissures, the lacrimal fossa, nasolacrimal duct and the optic canal constitute such important apertures [1, 42–46].

2.2. Blood supply

The ophthalmic artery and its branches constitute main arterial supply of orbit. The majority of the venous drainage occurs through superior ophthalmic vein, which drains into cavernous sinus that is located just posterior to the orbital apex. Veins from the facial region and many anterior ophthalmic veins anastomose and drain into cavernous sinus through superior orbital vein. Thus, cavernous sinus is prone to infection from facial region and also from the orbital region through the superior ophthalmic vein leading to a serious complication.

2.3. Eyelids

The eyelids impart two protective anatomical barriers, i.e., orbital septum and conjunctiva. Former divides the orbit from the eyelid into preseptal and postseptal spaces and provides a physical barrier to infectious agents and latter one is reflected back on itself, which provides protection by hindering the free movement of the material posteriorly from the anterior surface of the globe.

2.4. Lacrimal system

Lacrimal system consists of lacrimal gland, accessory gland and excretory system. Tears are secreted by lacrimal gland, which flows over the cornea and finally drain into nasal cavity by nasolacrimal duct through lacrimal sac. Any obstruction to the nasolacrimal duct can lead to regurgitation of the accumulated fluid onto the ocular surface leading to increased chances of infection.

2.5. Layers of eye ball

The basic structure of eye ball or globe consists of three concentric layers. The outermost covering is composed of sclera and cornea. The middle covering is composed of uveal tract, consisting of choroid, ciliary body and iris. The inner most covering is retina. The sclera is almost avascular except for the presence of superficial small blood vessels. The choroid is a highly vascular structure and provides nutrition and oxygenation to the retina beneath it. Due

to these qualities, choroid serves as a fertile area for the proliferation of various pathogens, which spread by hematogenous route.

2.6. Anterior and posterior chambers

Anterior segment of the eye in front of the vitreous humor comprises anterior one-third of the eye and is further divided into anterior chamber and posterior chamber. Anterior chamber is the space between posterior surface of cornea and the iris, whereas posterior chamber is the space between iris and the front of vitreous. The aqueous humor is produced by non-pigmented ciliary epithelium in the posterior chamber and drains through the pupillary aperture into the anterior chamber. Cornea is composed of well-organized collagen fibrils, which is avascular in nature. Lens is also an avascular crystalline structure, which continues to grow throughout life. Thus, aqueous humor fills these spaces and provides nutrition to the surrounding structures.

2.7. Vitreous humor

It is a gel-like substance present in front of retina and posterior to the lens in the posterior segment of the eye. It is optically clear and is composed of collagen framework interspersed with hyaluronic acid. During intraocular inflammation, it becomes hazy and may cause impairment of vision.

2.8. Retina and optic nerve

Retina constitutes the innermost covering of the eye ball and captures the light energy with the help of rods and cones. The outer half of the retina is supplied by central retinal artery, whereas inner half receives its blood supply from the choroid.

The optic nerve is formed by axons of the inner cell layer that exits the globe. It is covered by all the three meningeal coverings, which are direct extensions of the brain coverings. Thus, it is vulnerable to infections originating from both within cranial vault and within orbits.

3. Ocular defense mechanisms

The surface of the eye is well protected by both mechanical and immunological defense mechanisms. To breach the defense mechanism, some form of trauma is essential. The eyelids provide mechanical protection to the surface of eyeball. The eyelashes protect against airborne particles and trauma by initiating blink reflex. The cornea is also sensitive to tactile sensation and helps in the initiation of blink reflex, which is provided by dense sensory nerve endings. The lids direct the tears, particulate debris, allergens and microbes to the lacrimal excretory system by its sweeping action over the anterior surface of the eyeball. Bell's phenomenon also provides protection to cornea as globe is turned upwards and slightly outwards during eyelid closure to avoid corneal exposure [47]. Meibomian glands secrete lipids, which provide stability to the tear film. The epithelial surface of the cornea and conjunctiva provides ana-

tomical barrier to the pathogens. This function is further strengthened by the impermeability provided by the basement and cellular junctional complexes of the cornea. Indigenous flora of the eye also provides protection by creating a competition for colonization by the pathogens.

Immune defense mechanisms are provided by the vascular supply of the eye. Any breach in the anatomical defense system initiates the ocular inflammatory response, which helps in vasodilation and exudation of immunologically active substances and cells [1, 8, 48–52].

3.1. Defenses of the tear film

There are three layers of the tear film: oil, aqueous and mucous. Majority of the tear film is composed of aqueous layer and pH of the tear film helps in neutralization of toxic substances. Flow of tears help in mechanical flushing of the foreign particles and allergens into the lacrimal excretory system. Mucosal layer helps in entrapment of pathogens. Tear film contains various immunological active substances such as lactoferrin, lysozyme, β -lysin, ceruloplasmin, complement and immunoglobulins.

3.2. Conjunctival defenses

The conjunctival associated lymphoid tissue lies beneath the conjunctiva. It consists of both B and T lymphocytes. B and T cell precursors mature when exposed to foreign particles or allergens, then migrate to regional lymph nodes for further development, and thereafter return to the conjunctiva through blood stream to produce specific immunoglobulins and cellular defense responses.

3.3. Corneal defenses

Although the cornea is avascular, it is provided by limited defense mechanisms in the form of Langerhans cells (dendritic cells) and immunoglobulins. The surface of the cornea is covered by mucous glycoprotein, which helps in cross-linkage of the IgA and protects the anterior surface of the cornea. Immune defense mechanisms are activated whenever injury occurs, leading to recruitment of the polymorphonuclear cells, lymphocytes and fibroblasts.

3.4. Cellular immune responses

Langerhans cells are situated along the peripheral margin of the cornea and conjunctiva. These cells possess receptors, which help in phagocytosis and processing of certain antigens for presentation. Langerhans cells stimulate B and T cells to elicit a strong cellular immune response. During inflammation Langerhans cells migrate toward the cornea, causing increased release of inflammatory substances.

3.5. Leukocyte defense

Polymorphonuclear leukocytes are the hallmark of acute inflammation and are associated with oxygen-dependent pathways for the generation of free radicals that help in killing of the

invading pathogens. Another immune defense mechanism operated by the production of defensins is antimicrobial proteins active against wide range of pathogens.

3.6. Defensins

Ocular surface is constantly exposed to environment and foreign bodies, thus there are greater chances of infection. However, robust innate immune system at ocular surface protects the eye from infection. There are several peptides of defensins and cathelicidin families that are present in tear film and secreted by corneal and conjunctival cells. These are not only antimicrobial in nature but also help in the recruitment of immune cells and thus provide a link to adaptive immunity. The important defensins present in human eye are hBD-1 (human beta defensins), hBD-2, hBD-3, CAP37 (Cathelicidin-related antimicrobial peptide), LL37 (type of cathelicidin) and HNP-1, 2, 3 (human neutrophil defensins) [53].

4. Protozoan eye infections

4.1. Toxoplasmosis

Toxoplasmosis is caused by obligatory intracellular protozoan parasite known as *Toxoplasma gondii*. The mode of infection is either by the ingestion of oocysts shed in feces of the cats or other Felidae (definitive host) or by the consumption of tissue cyst present in the raw or uncooked meat. Life cycle of *Toxoplasma* includes three stages that are oocysts, tachyzoites and bradyzoites. It completes its life cycle in two phases, one as an intestinal phase in its homologous host, such as cats and another as an extraintestinal phase in its heterologous host, such as mouse, man and other animals. When cats feed on mouse brain containing tissue cysts of *T. gondii*, a large number of oocysts are released in the infected cat's feces. After 1–5 days, oocysts get matured and become infective to man and other animals. After ingestion, oocysts liberate sporozoites, which penetrate intestinal mucosa and reach to distant organs such as brain, eyes, liver, spleen, lymph nodes, heart, skeletal muscles and placenta by blood and lymphatic stream. *Toxoplasma* tissue cysts also occur in the skeletal muscles of the intermediate host such as sheep and pigs (Figure 2) [54]. In addition, developing fetus can acquire the infection transplacentally from the mother during pregnancy. Rarely, infection may also result from consumption of drinking water contaminated with oocysts. The ocular infection can be either congenital or acquired.

Approximately, one-third of the world's population is thought to be infected by *T. gondii*. It is common in hot and humid climates such as Central America, Asia and the Caribbean region (Table 1, Figure 3). In Europe, toxoplasmosis is common and the highest prevalence rates have been reported in France. Various risk factors such as geographical region, meat consumption, personal habits, animal reservoir and climatic conditions play a significant role in the transmission of infection. In recent years, due to indoor keeping of livestock and improvement in hygiene standards, the risk of acquiring infection has decreased tremendously in the developed nations. However, in the developing nations, risk has increased due to population growth, urbanization trends and increase in meat consumption. Drinking water, seawater and

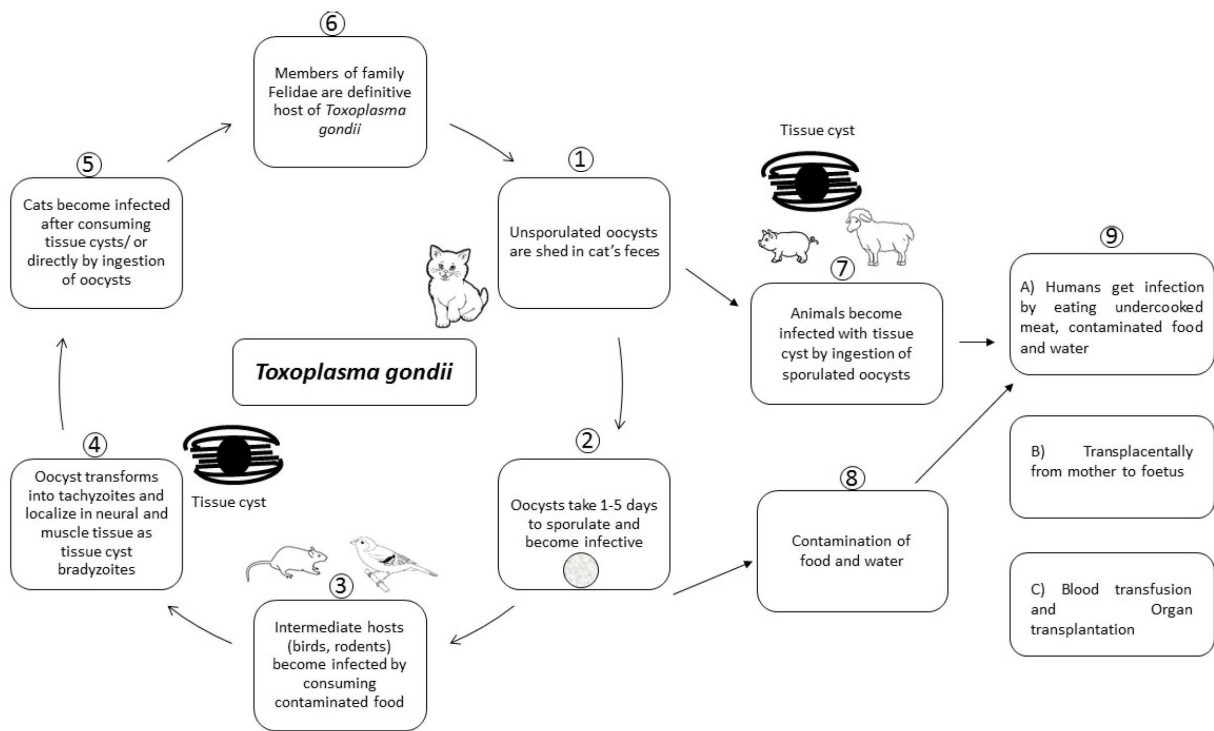


Figure 2. Life cycle of *T. gondii* (Diagrammatic representation).

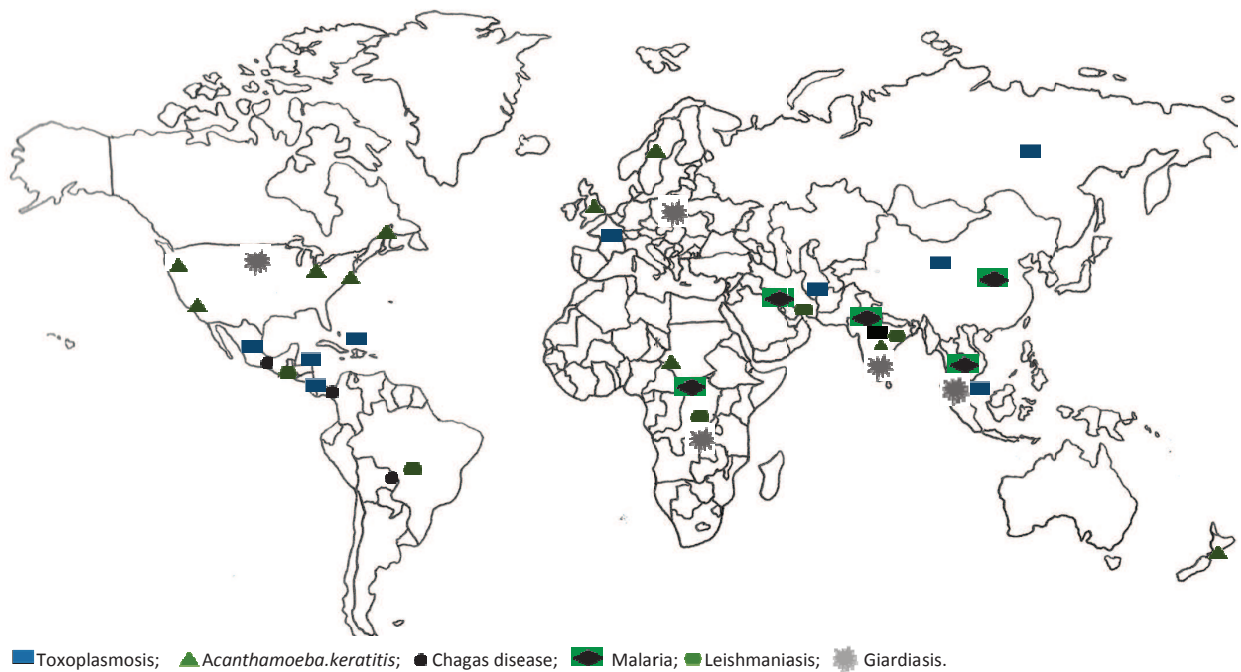


Figure 3. World map showing geographical areas endemic for ocular protozoal infections.

seafood contaminated with oocysts when consumed may account for many unreported cases. Therefore, exact prevalence would be much higher than reported in the literature [55–58].

Ocular toxoplasmosis usually manifests in immunocompromised *T. gondii*-infected individuals and in neonates who acquire infection transplacentally [4]. The main target organs in congenital toxoplasmosis are the brain, eyes and placenta. *T. gondii* disseminates through the blood stream, lodges at particular site(s) and develops into tissue cysts. The dendritic cells and macrophages act as “Trojan horses” to guide the parasite through blood-brain barrier to reach at its target site in brain [59]. Inside the host cell, it protects itself from the toxic host molecules by hiding inside the parasitophorous vacuole (structure produced by apicomplexan parasites that allows the parasite to develop inside host cell and protects from phagolysosomes). There are three main clonal lineages of *T. gondii*. Type I strains being the highest virulent, whereas types II and III are moderately virulent. However, at present more than 130 “atypical” genotypes are known, but their exact role in pathogenesis is not well established. Host genetic factors such as polymorphism in Toll-like receptors (TLR) (TLR2, 5 and 9) are also known to play a role in the susceptibility to and severity of ocular toxoplasmosis [60, 61].

Congenital ocular toxoplasmosis usually involves both the eyes, whereas acquired ocular toxoplasmosis is usually unilateral [62, 63]. Chorioretinitis is caused by necrotizing inflammation due to the rupture of an older cyst. Intense form of chorioretinitis may occur in newborns and patients infected with HIV. In addition, congenital toxoplasmosis patients may present with wide range of ocular symptoms such as strabismus, nystagmus and blindness. Acute, acquired infection may result in photophobia, scotoma and loss of central vision. Ptosis may occur due to oculomotor nerve involvement.

Diagnosis of ocular toxoplasmosis in children with congenital infection is established by recognizing distinctive clinical findings such as focal necrotizing retinitis, vitritis, anterior uveitis and cataract [64]. However, in cases with atypical presentation or having severe fulminant disease, diagnosis is usually established by analyzing the intraocular fluid for the presence of specific antibodies or the presence of parasite DNA by molecular techniques such as PCR or real-time PCR [65, 66]. PCR is performed by targeting the *Toxoplasma* B1 gene or other multiple repeat sequences [67–69]. Though, in general, PCR with amniotic fluid is known to have significantly high sensitivity (64%) and specificity (100%) for the diagnosis of toxoplasmosis [70], sensitivity of only 53 and 83% has been documented for the diagnosis of ocular toxoplasmosis [71]. PCR can be performed on either aqueous humor or vitreous fluid, but aqueous humor can be collected more easily. However, the DNA burden in aqueous humor is low, and in rare instances a confirmation would necessitate vitreous sampling [72].

Antibody detection in serum samples is widely used for establishing the diagnosis of toxoplasmosis [73–76], while its role is limited in establishing the diagnosis of the ocular toxoplasmosis. A rising titer of specific IgG over a period of 3 weeks helps in establishing the diagnosis [77]. The detection of specific antibodies in intraocular fluids by the enzyme-linked immunosorbent assay (ELISA) is the most commonly used test for the diagnosis of toxoplasmosis. The Goldmann-Witmer coefficient (GWC) calculation is a common method to estimate the local versus systemic *Toxoplasma*-specific IgG. This index helps in measuring the intraocular levels of specific antibodies against *Toxoplasma*. It is expressed as the level of *Toxoplasma*-specific IgG relative to the level of total IgG in the aqueous humor as a fraction of the level of *Toxoplasma*-specific IgG relative to the level of the total IgG in the serum. A value of 2 or above is considered as an evidence of intraocular infection. *Toxoplasma* specific IgG antibodies are produced in

response to the actively multiplying tachyzoites at local site of infection [72, 78]. The presence of *T. gondii*-specific IgM is the hallmark of a recently acquired systemic or, possibly, ocular infection. However, high rate of false-positive results due to the persistence of antibodies, decreases its utility as a diagnostic marker for recent ocular toxoplasmosis. In patients with reactivated ocular toxoplasmosis, it is not useful as *T. gondii*-specific IgM antibodies are either absent or present in very low quantity [79]. Saliva samples have also been tested for the detection of specific antibodies for the diagnosis of toxoplasma encephalitis in immunocompromised individuals, but it may play a limited role in ocular toxoplasmosis [74].

An algorithm for the laboratory confirmation of clinically suspected cases of ocular toxoplasmosis has been reported [72]. Reactivated form of ocular toxoplasmosis is considered in patients with typical lesions of toxoplasmic retinochoroiditis, specific IgG seropositive, specific IgM seronegative and responding to anti-*Toxoplasma* treatment. However, if patients are specific IgM seropositive, then additional laboratory tests are required. If doubt persists about diagnosis, paired serum and aqueous samples are required to be tested in parallel. The clinical diagnosis along with laboratory evidence is documented in 60-85% of cases and thus, laboratory evidence is lacking in 15-40% of clinically suspected patients. Analysis of aqueous humor is useful in patients presenting with atypical ocular lesions or not responding to specific treatment [72].

In immunocompetent individuals, toxoplasma retinochoroiditis usually resolves within 2–3 months [80]. Classic therapy or triple therapy with a combination of pyrimethamine, sulfadiazine and systemic corticosteroids is recommended for lesions involving or near to fovea, an area critical for vision. Classic therapy is usually associated with significant side effects, therefore other drugs such as trimethoprim-sulfamethoxazole, clindamycin, atovaquone and azithromycin are being evaluated for the treatment of ocular toxoplasmosis [81].

Trimethoprim-sulfamethoxazole (Bactrim) appears to be a safe and effective substitute for sulfadiazine, pyrimethamine and folinic acid for the treatment of ocular toxoplasmosis.

Progressive and recurring necrotizing retinitis, with vision-threatening complications such as retinal detachment, choroidal neovascularization and glaucoma, may occur at any time during the clinical course if the infection is not treated on time. Congenital toxoplasmosis can lead to cataract. The aim of the treatment is to arrest parasite multiplication during the active period of retinochoroiditis and to minimize damage to the retina and optic disc [64].

Animal model(s) can be used to study various aspects of ocular toxoplasmosis [40].

4.2. *Acanthamoeba* keratitis

Acanthamoeba keratitis (AK) is caused by *Acanthamoeba* spp., a free-living protest parasite [82]. The word “acanth” in Greek means “spikes” and has been added as a prefix to “amoeba” to denote the spine-like structures present on its surface. The parasite is present ubiquitously in the environment and exists in two forms, trophozoite and cyst forms. In humans, it can enter through eye, nasal passage or ulcerated broken skin (Figure 4). Infection of the eye can cause blinding keratitis and life-threatening granulomatous encephalitis. Various risk factors contributing to the development of AK are (1) wearing of contact lenses for long time, (2) poor

personal hygiene, (3) cleaning of lenses with contaminated water and (4) formation of biofilm on contact lenses [82].

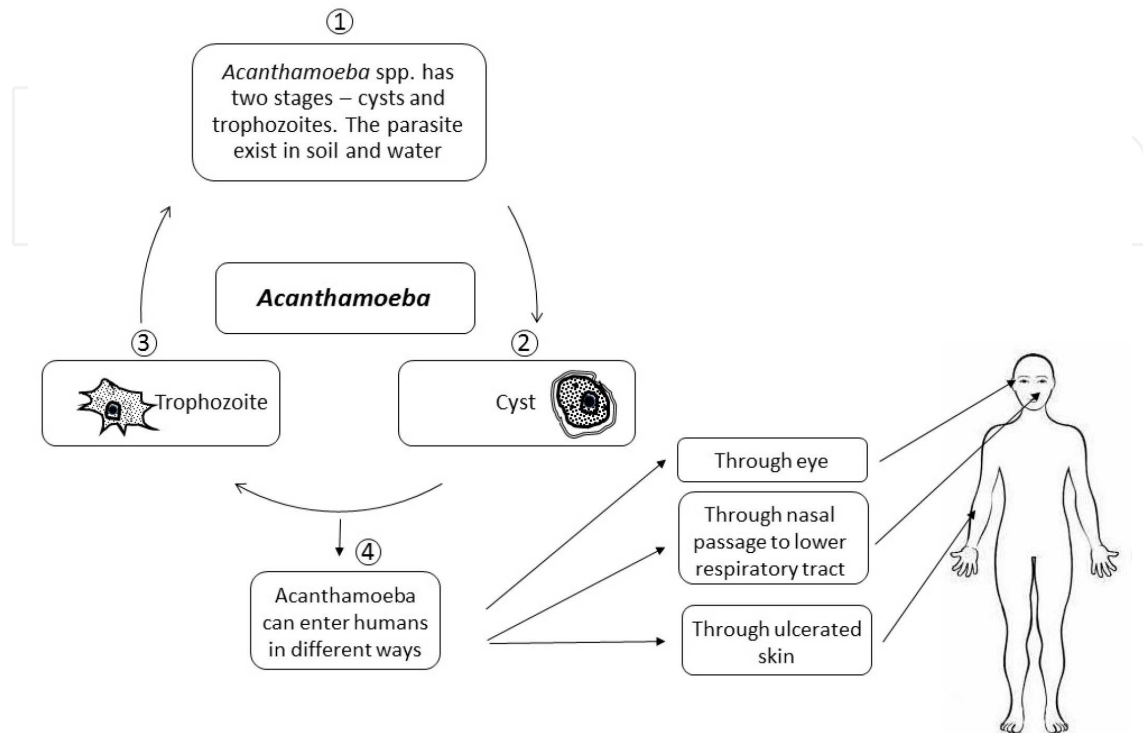


Figure 4. Life cycle of *Acanthamoeba* (Diagrammatic representation).

Acanthamoeba keratitis is common among the contact lens users, and its geographic distribution is depicted in Table 1 and Figure 3. However, in India the infection is reported even in non-contact lens users [7]. The incidence of *Acanthamoeba* keratitis in developed nations varies from 1 to 33 cases per million contact lens wearers. In developing nations where contact lens users are limited, the other suggested risk factors are trauma, exposure to contaminated water, use of traditional eye medicine, low socioeconomic background, splashing contaminated water into the eye following dust fall and corneal injury with mud [7, 22, 83]. The pathogenesis of *Acanthamoeba* involves following sequential events, i.e., breach in the epithelial barrier, invasion of stroma by amoeba, depletion of keratocytes, induction of inflammatory response, photophobia and finally necrosis of stroma leading to blindness [82].

The diagnosis of AK is difficult as it is usually confused with symptoms of bacterial, fungal or viral keratitis. However, history of contact lens use together with a history of excruciating pain is a strong indication toward the diagnosis of AK. For establishing the clinical diagnosis with high sensitivity, in vivo confocal microscopy can be used, which is a non-invasive procedure. The *Acanthamoeba* cysts appear as hyper-reflective, spherical structures that are well defined because of their double wall. However, trophozoites are difficult to distinguish from leukocytes and keratocyte nuclei [84, 85]. Laboratory confirmation is established by direct demon-

Ocular protozoal infections	Geographical distribution
Toxoplasmosis	Worldwide particularly in Central America, Asia, Caribbean region, Europe particularly in France
Acanthamoeba keratitis	Worldwide significantly in Chicago, San Francisco, Boston, Philadelphia, Sweden, Portland, New Zealand, United Kingdom, India, Africa
Chagas disease	Central and South America
Malaria	Africa, Central & South America, Middle East and Asia
Leishmaniasis	Africa, Mediterranean region, Middle East, Central and South America, parts of Asia
Microsporidiosis	Worldwide
Giardiasis	Southeast Asia, South Africa, Europe and USA
Ocular nematode infections	
Onchocerciasis	Africa, South America, Arabian peninsula
Loiasis	Central and West Africa
Dirofilariasis	Asia, Africa and Europe
Gnathostomiasis	South East Asia particularly Thailand, China, Japan and India, Central and South America particularly in Mexico, Guatemala, Peru and Ecuador
Thelaziasis	Asia Pacific region - China, India, Thailand, Indonesia, Japan and Korea
Toxocariasis	Worldwide particularly in Asia, Japan, Korea, Ireland, Alabama
Ocular cestode infections	
Cysticercosis	Indian subcontinent, Central and South America, Africa and Far East
Echinococcosis	South America, Middle East, Mediterranean countries, India and Australia
Ocular trematode infections	
Fascioliasis	France, Spain, Italy, Austria, Belgium, United Kingdom, Algeria, Tunisia, Iran, Uzbekistan, Korea, China, Argentina, Chile, Peru, Brazil, Guatemala
Schistosomiasis	Sub-Saharan Africa, China, South Asia
Philopthalmosis	Europe (Yugoslavia), Israel, Asia (Thailand, India, Sri Lanka, Japan) and America (i.e., Mexico, and the United States)
<i>Clinostomum lacramalitis</i>	Thailand
Fascioliasis	Iran
<i>Alaria mesocercariasis</i>	San Francisco, California
Ocular infections by ectoparasites	
Myiasis	Worldwide with greater abundance in poor socioeconomic regions of tropical and subtropical countries, Mediterranean basin and Middle East
Phthiriasis palpebrum	Case reports from Tunisia, Taiwan, India, Pakistan, China, Korea, Lebanon, Israel, Brazil, Turkey, United Kingdom, Belgium, Italy, Cyprus, United States of America (USA)
Tick infestation	Case reports from Ireland, Turkey and USA

Table 1. Ocular parasitic infections and geographical distribution

stration of parasite by immunofluorescence microscopy or by isolating the parasite in culture. Although culture remains the gold standard, it is tedious and time consuming. Multiplex real-

time PCR assays (multiplex assays targets more than one region and simultaneously can detect two or more target regions) have also been developed for the detection of different pathogenic free-living amoeba and/or different genotypes of *Acanthamoeba*. Although molecular techniques have high sensitivity and specificity, these are only available at apex laboratories and also require a well-established molecular laboratory [86]. Newer techniques such as Matrix-Assisted Laser Desorption Ionization Time-Of-Flight (MALDI-TOF) and ¹H-NMR spectroscopy [87] are also being tested for the rapid identification of *Acanthamoeba* in the clinical specimens [88].

Chances of recovery are good if the pathogen is restricted to cornea epithelium but can lead to vision loss, if it invades stroma leading to necrosis and intense inflammation. Medical treatment, if started early, can lead to a significant improvement within 2–3 weeks [89].

Preventive measures include thorough and adequate disinfection of contact lenses. It is recommended to remove contact lenses before any activity involving contact with water, including showering, using a hot tub, or swimming. Hands should be washed with soap and water and dried before handling contact lenses. Contact lenses should not be rinsed with tap water and should be cleaned and stored as per manufacturer's guidelines. It is suggested that the increased awareness about the other predisposing factors (corneal injury, fall of foreign body in eye) among the general public may enable early and frequent recognition and proper management of AK in patients other than contact lens wearers [7].

4.3. Chagas disease

Chagas disease or American trypanosomiasis is caused by *Trypanosoma cruzi* [90]. It is a chronic systemic disease, included in the WHO's list of most neglected tropical diseases. Approximately, 8 million people are known to be affected in Latin America (Table 1, Figure 3) [8]. The life cycle of the parasite is passed in two stages involving trypomastigotes and amastigotes forms as depicted briefly in Figure 5. *T. cruzi* passes its life cycle in two hosts: one in man or the reservoir host and other in the transmitting insect. The infection is transmitted by the blood-sucking triatomine bugs when infective metacyclic trypomastigotes in bug's feces are released onto the skin of humans. These infective trypomastigotes enter the human host when bite wound is either scratched or rubbed, or through permissive mucosal or conjunctival surfaces. Parasites circulate in the human body affecting various tissues and organs. If the initial bite of the triatomine bug is near the orbit, it may lead to severe palpebral and periorbital edema (Romana's sign) [91]. It causes a painless edema and constitutional symptoms of fever, malaise and anorexia are common. Ocular involvement (posterior uveitis) in congenital Chagas disease is recently reported. Although ocular fundus examination has been unobtrusive, small parafoveal retinal pigment epithelium defects have been reported in 7.6% of chagasic patients [92].

The diagnosis of acute Chagas disease is established by the direct demonstration of trypomastigotes in the blood/buffy coat preparation. Parasites can also be isolated by direct culturing of blood on NNN medium (Novy, MacNeal, Nicolle's medium). It may take 7 to 10 days for culture to become positive. Diagnosis may also be established by xenodiagnosis. During acute phase, the role of serology is limited in the diagnosis as antibodies take time to

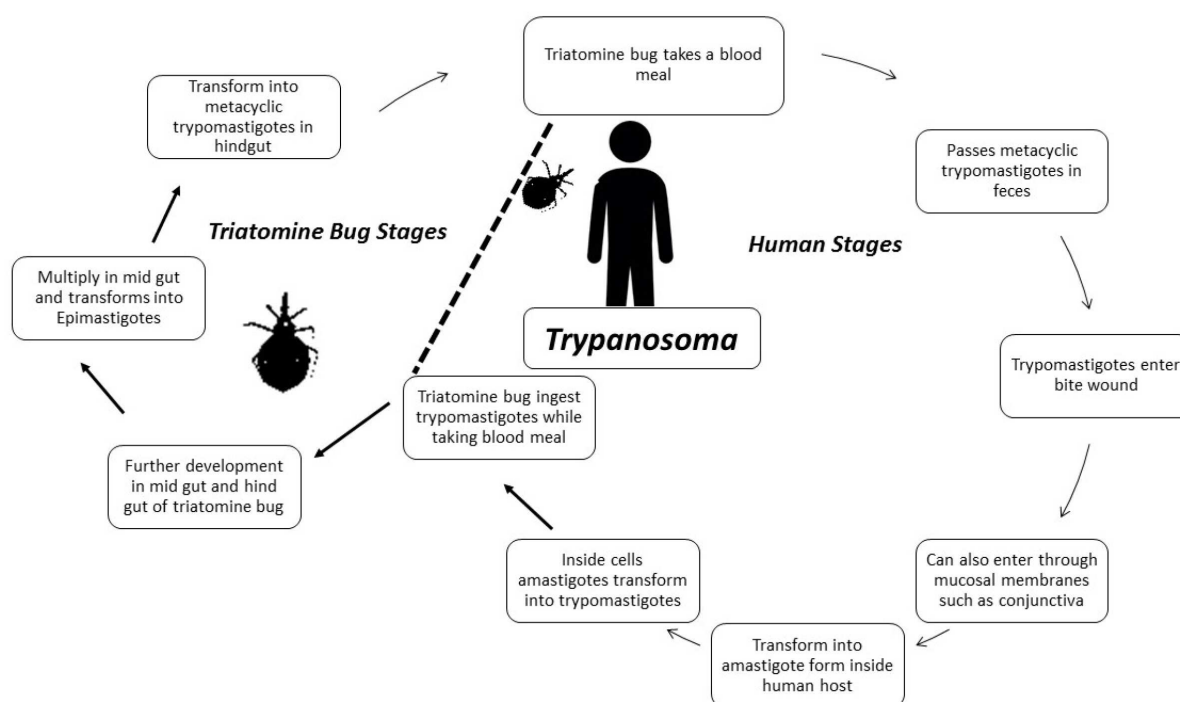


Figure 5. Life cycle of *Trypanosoma cruzi* (Diagrammatic representation).

develop and false positive results have also been known to be associated with serological tests due to cross-reaction of antibodies to non-pathogenic *Trypanosoma rangeli* [8, 91]. Furthermore, detailed examination by the ophthalmologist may aid in establishing the diagnosis. However, accumulation of retinal pigment epithelium defects have been shown in patients with intra-ocular involvement of intermediate and chronic Chagas disease in Paraguay/South America, but overall fundus examination has shown to be unobtrusive [92, 93].

Acute cases of Chagas disease are treated by nifurtimox and benznidazole. Benznidazole is given as 5–7.5 mg/kg per day orally in two divided doses for 60 days. Nifurtimox is given as 8–10 mg/kg per day orally in three or four divided doses for 90 days [91, 94].

Within few weeks, symptoms of acute Chagas disease such as Romana's sign fade away, but infection persists. The average life-time risk of developing complications of chronic phase is around 30%. It may take more than 20 years to develop chronic complications. However, trypanocidal therapy did not significantly reduce cardiac clinical deterioration through 5 years of follow-up as documented by randomized trial of benznidazole for chronic Chagas' cardiomyopathy [95, 96].

4.4. Leishmaniasis

Leishmaniasis is caused by protozoan parasite that belongs to genus *Leishmania*. Humans get infection by the bite of phlebotomine sand flies. There are different clinical forms of leishmaniasis, such as visceral leishmaniasis (VL), cutaneous, diffuse cutaneous and mucocutaneous caused by different species of *Leishmania*. Worldwide, approximately 1.3 million new cases

occur every year with a mortality of 20,000 to 30,000 persons per annum [97]. While taking the blood meal, infected sandfly injects promastigotes into humans. Further in the human body, the promastigotes are transformed into amastigote forms, and these are engulfed by tissue macrophages. Amastigote forms replicate inside the cells and further spread either systemically or through cutaneous route, depending on the species of the parasite (Figure 6). Ocular involvement due to leishmaniasis has been reported from various countries such as India, Sudan, Italy, Norway, Turkey and Iran (Table 1, Figure 3) [98–103]. Anterior uveitis is the most common ocular manifestation in VL, which can occur during the course of infection and can further progress to glaucoma [104, 105]. Focal retinal whitening, cotton wool spots, hemorrhages and increased vessel tortuosity have also been reported on fundus examination [106–110]. In severe cases, flame-shaped lesions also appear, which denote hemorrhage from the anterior capillaries of the nerve fiber layer. These findings have also been correlated with anemia and thrombocytopenia as these hemorrhages usually get resolved with treatment, leading to improvement in anemia/thrombocytopenia. Optic neuropathy has been reported due to mucosal leishmaniasis. Eyelid involvement has been documented in cutaneous and mucocutaneous leishmaniasis [111, 112]. Severe involvement can progress to ptosis and ectropion secondary to cutaneous leishmaniasis leading to keratopathy and altered vision [112]. However, eyelid is rarely involved by leishmaniasis and is reported in approximately only 2.5% of cases with cutaneous leishmaniasis [113]. The most common aspect of eyelid leishmaniasis is chalazion-like lesions, but other forms such as ulcerous, phagedenic, cancer-like forms and unilateral chronic granulomatous blepharitis may be observed. Chronic dacryocystitis has been reported in patients suffering from mucocutaneous leishmaniasis, which can effect formation of tear film, leading to dryness of eyes [114]. Endo-ocular lesions have been observed in patients having disseminated cutaneous leishmaniasis. A report from Brazil documented the presence of *Leishmania* in the aqueous humor along with iridocyclitis [115]. Although ocular manifestations are not very common, it is suggested that a person with ocular manifestation from endemic country should undergo fundus examination for early diagnosis [116].

Diagnosis of leishmaniasis can be achieved by the direct demonstration of parasites in the tissue smears and/or biopsy samples, culture technique(s), antigen and/or antibody detection and molecular technique(s). However, each technique has its own merits and demerits. Amastigotes can be easily identified in the cutaneous and mucocutaneous lesions but are not easily identified in cases with ocular disease [103, 117, 118]. Molecular techniques such as PCR/real-time PCR can identify the genome of parasite with greater sensitivity (100%) and specificity (100%) [119, 120]. The treatment of leishmaniasis depends on several factors such as clinical form of the disease. The antileishmanial drugs include pentavalent antimony, sodium stibogluconate, liposomal Amphotericin B, miltefosine and paromomycin [118, 121].

Ocular lesions do not heal without treatment and could lead to vision loss if conjunctiva is involved due to severe ulceration. Healing occurs without visual impairment if treatment is initiated early during the course of infection and vigorous treatment is required to prevent blindness [121, 122].

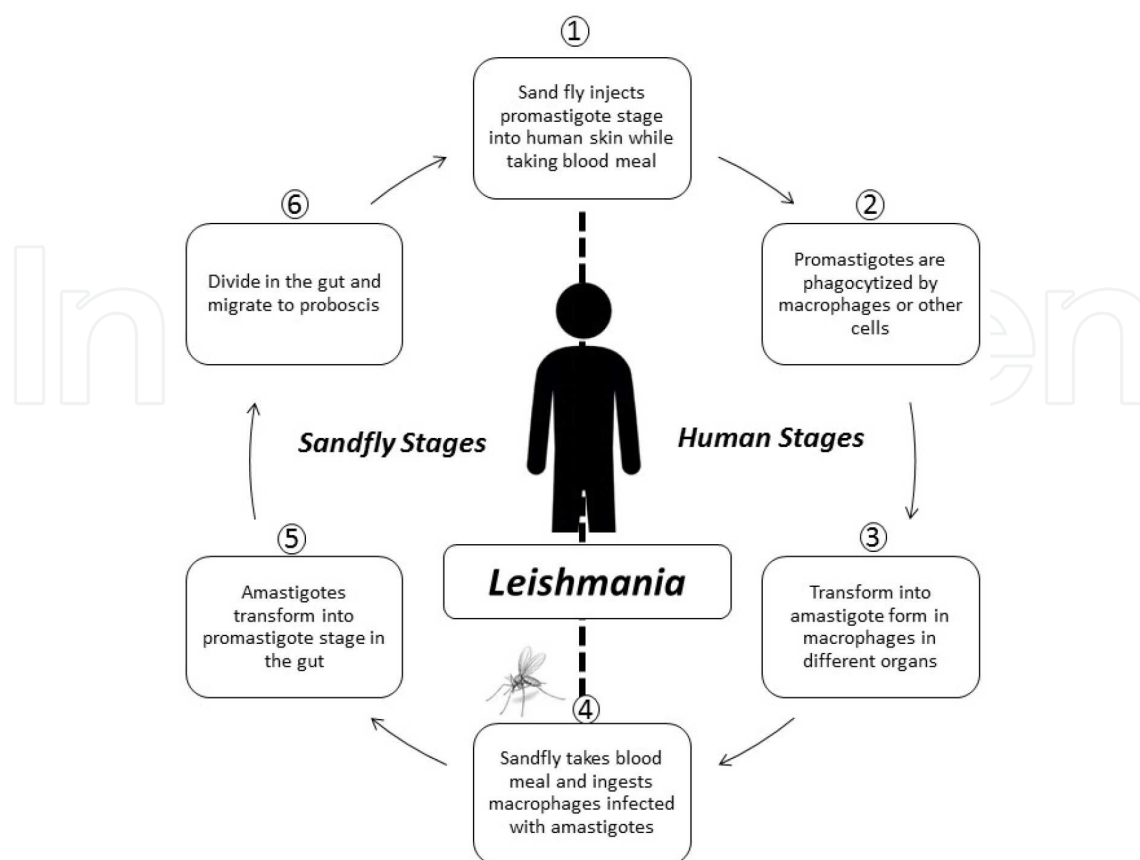


Figure 6. Life cycle of *Leishmania* (Diagrammatic representation).

4.5. Malaria

Malaria is caused by the parasites of Genus *Plasmodium* and is transmitted by the bite of female anopheles mosquitoes. The malarial parasite passes its life cycle in humans and mosquitoes. Inside human host, *Plasmodium* undergoes exoerythrocytic and erythrocytic schizogony as shown briefly in Figure 7. Malarial parasite multiplies by asexual method (schizogony) while residing inside liver cell and the red blood cells. After the parasites have undergone erythrocytic schizogony for a certain period, some of the merozoites give rise to gametocytes, which are taken up by mosquitoes during their blood meal. The gametocytes further develop into sporozoites that are infective to man. Sporozoites when introduced into humans are not directly infective for red blood cells, but undergo development initially in hepatic cells (exoerythrocytic schizogony) and later on invade red blood cells to complete erythrocytic schizogony. As per World Malaria Report 2014 [123], an estimated 3.3 billion people are at risk of developing malaria (Table 1, Figure 3). Complications of severe malaria due to *P. falciparum* mainly occur due to the sequestration of malarial parasite in the microvasculature leading to occlusion and hypoxia. Most of the ocular manifestations occurring in malaria are a result of the same mechanism. Sequestration is further amplified by auto agglutination and resetting [124, 125].

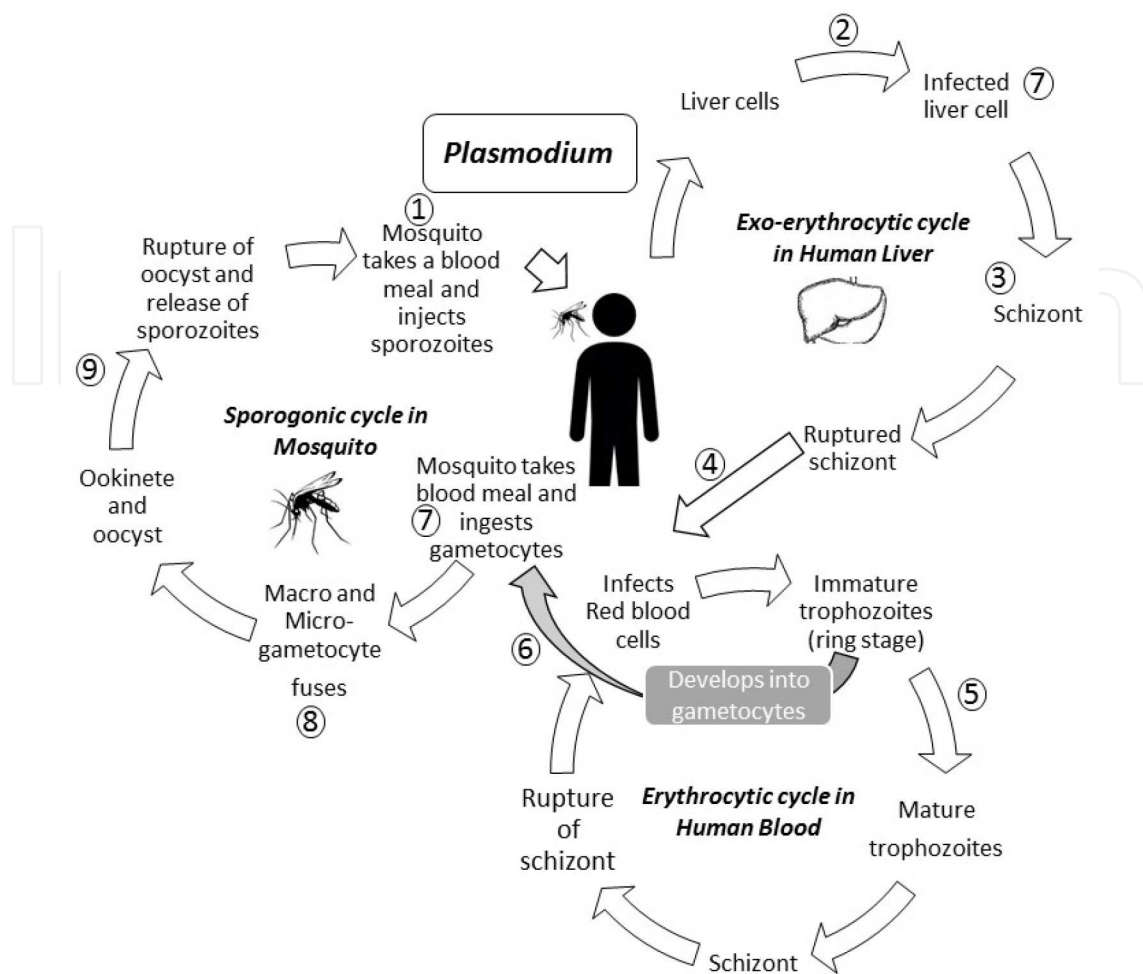


Figure 7. Life cycle of *Plasmodium* (Diagrammatic representation).

Wide range of ocular symptoms has been reported in patients suffering from malaria. Uncomplicated malaria is usually not associated with significant ocular findings but rarely may be associated with edema and hyperemia of the eyelids, chemosis of conjunctiva, conjunctival hemorrhage and anterior uveitis [126]. On the other hand, severe ocular manifestations may occur in cerebral malaria due to *P. falciparum* leading to visual field defects, cortical blindness, optic neuritis, papilledema and optic atrophy [127]. Ocular motor disturbances have also been reported. Occasionally, infarcts in brainstem may cause changes in pupillary reaction and disorders of eye movements. Patients with cerebellar syndromes may present as nystagmus [128, 129]. Characteristics features such as retinal whitening consisting of irregular patchy areas may be localized or diffused in all segments of retina [130]. Blood vessel changes manifest as discoloration (white or orange) occurring mainly in the peripheral fundus, whereas white-centered retinal hemorrhages may manifest as malaria retinopathy. Discoloration of retinal vessels occurs due to the absence of hemoglobin in parasitized erythrocytes, sequestered within retinal vasculature and thus cannot reflect normal red color. Retinal changes in cerebral malaria are considered as poor prognostic markers [131]. The prevalence of any retinopathy, papilledema, hemorrhages, vessel changes, macular whitening and peripheral whitening has

been reported in 61, 15, 46, 32, 46 and 44%, respectively, among children with cerebral malaria in Malawi [132].

Diagnosis of malaria is established by light microscopy or by rapid antigen detection kits. Light microscopic examination of Giemsa-stained peripheral blood smear is considered as gold standard for the diagnosis of malaria with a threshold of about 50–100 parasites/ μL [133]. However, in addition, ocular examination may provide clue to the diagnosis as specific retinal changes can be seen directly [129, 134, 135].

Treatment depends on the species of *Plasmodium* causing infection. Artemisinin combination therapy is recommended for malaria due to *P. falciparum*. Artemisinin combination therapy includes short-acting artemisinin derivative and long-acting antimalarial (sulphadoxine-pyrimethamine, lumefantrine). Chloroquine along with primaquine is recommended for malaria due to *P. vivax*. Ocular toxicity [136] is very well documented with chloroquine therapy. This includes corneal changes (cornea verticillata) and corneal deposits. Toxic maculopathy and scotoma has also been reported. Quinine overdose has also been known to cause decreased vision, retinal and macular degeneration, mild scotomas and color vision defects [136].

If not treated, malarial retinopathy is associated with serious consequences as reports indicate that the severity of retinopathy is related to prolonged death and coma. After antimalarial treatment and resolution of coma in severe malaria, malarial retinopathy resolves after some time [132, 137].

4.6. Microsporidiosis

Microsporidiosis is the term used to denote the infection caused by microsporidia belonging to phylum Microspora [23]. Microsporidia were once thought to be protists but are now known to be fungi. Although it is classified as a protozoal disease in ICD-10, their phylogenetic placement has been resolved to be within the fungi [138]. Microsporidiosis is considered as an opportunistic infection in AIDS/HIV-infected individuals and is prevalent worldwide (Table 1) [1]. Microsporidia are small, unicellular, spore forming, obligate intracellular pathogens. Important genera responsible for ocular manifestations are *Encephalitozoon* and *Nosema*. Another species, *Septata*, has also been reported to cause keratoconjunctivitis [139]. The prevalence of microsporidiosis ranges from 2 to 50% among severely immunocompromised, HIV-infected patients found in North America, western Europe and Australia. The prevalence data for microsporidiosis is limited among non-HIV-infected persons [9].

1. The life cycle of parasite involves three stages (Figure 8):
2. The resistant spore (infective form)
3. The spore injects the infective sporoplasm into the host cell. Inside the host cell, sporoplasm undergoes multiplication either in the cell cytoplasm or inside parasitophorous vacuole. Microsporidia develop to mature spores by sporogony that are released by disruption of cell membrane. The free mature spores are the infective forms.

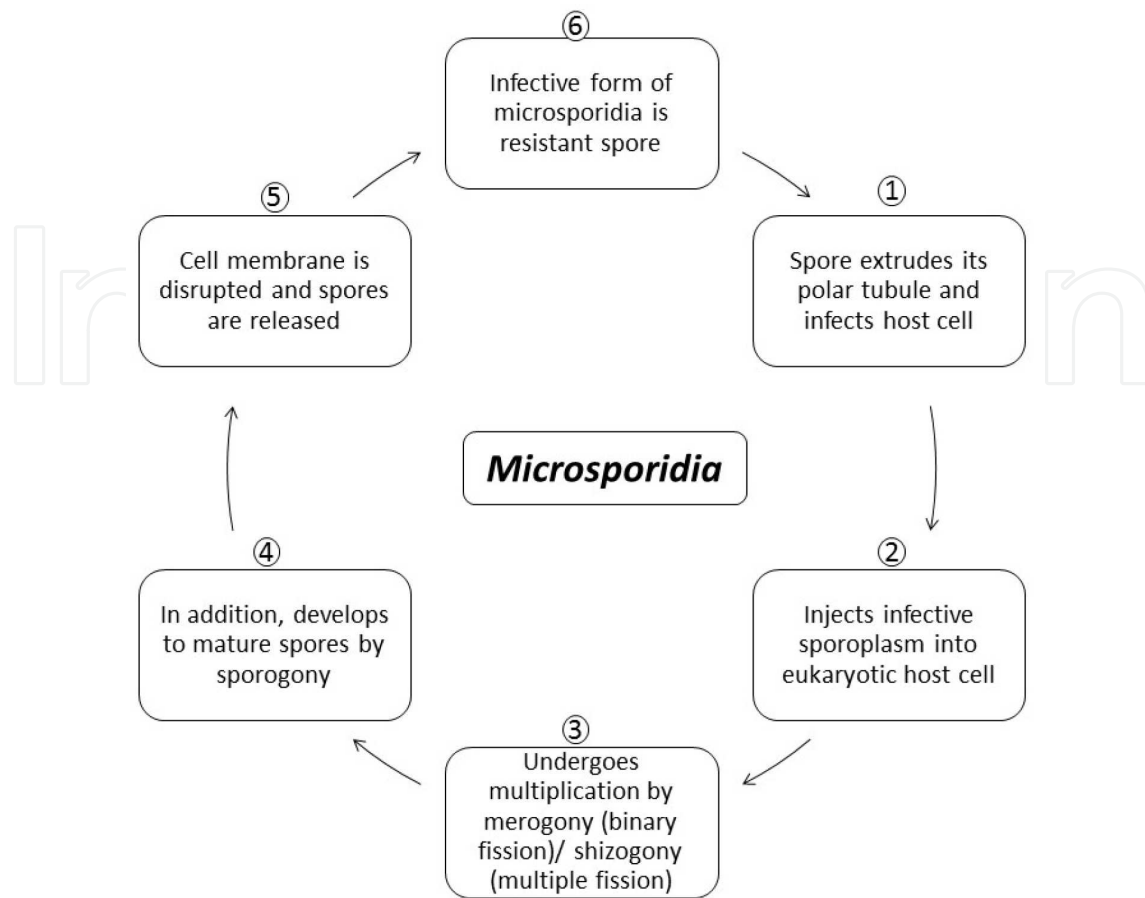


Figure 8. Life cycle of *Microsporidia* (Diagrammatic representation).

Ocular manifestations caused by *Microsporidia* are mainly limited to conjunctiva and cornea. Corneal involvement may lead to punctate epithelial keratitis, hyphema, necrotizing keratitis and corneal ulcer. Symptoms include foreign body sensation, photophobia and decrease in visual acuity [23].

Diagnosis is established by direct demonstration of the spores by microscopy or electron microscopy of the corneal scrapping or biopsy specimens. Isolation of the parasites in culture has also been attempted [140]. There are no reports on use of serological tests to detect antibodies in serum or tears in ocular microsporidiosis [9]. Lesions usually heal after 1–2 weeks as it is self-limiting. Treatment of microsporidial keratoconjunctivitis with polyhexamethylene biguanide does not offer any significant advantage but treatment with topical fumagillin showed significant improvement [141–143].

4.7. Giardiasis

Giardiasis is caused by *Giardia duodenalis* (syn. *G. lamblia* or *G. intestinalis*) [144]. The infection is transmitted by ingestion of contaminated water/food or directly by feco-oral route. The parasite exists in trophozoite and cyst forms as shown in Figure 9. In the trophozoite stage the parasite multiplies in the intestine of man by binary fission. When conditions become unfav-

orable in the small intestine, encystment occurs and cysts are released along with feces. After ingestion, within 30 minutes, cyst hatches out trophozoites that further multiply in the small intestine. It is found both in developing and developed nations (Table 1, Figure 3). Although it mainly causes diarrhea and malabsorption, in one-third of the patients, it can also result in long-term extra intestinal manifestations [145].

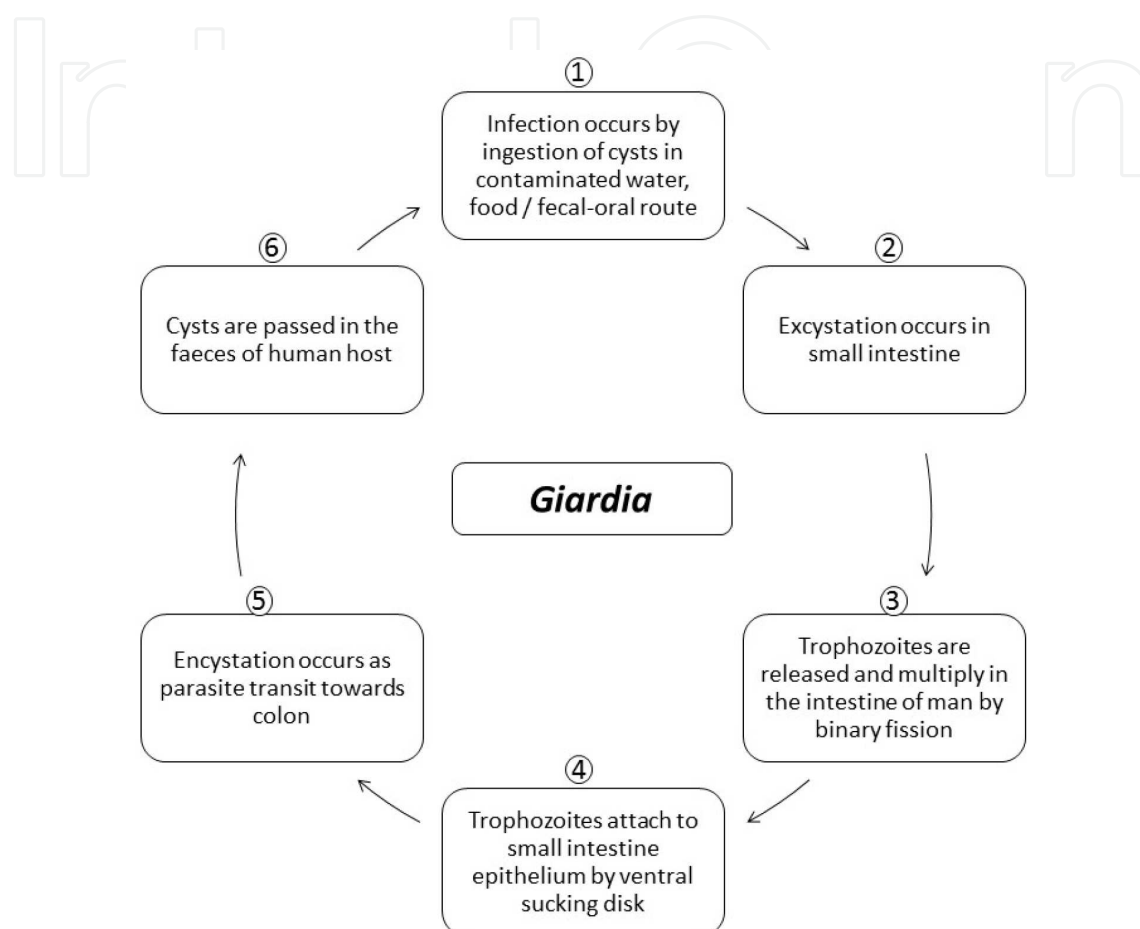


Figure 9. Life cycle of *Giardia lamblia* (Diagrammatic representation).

Barraquer was the first to report the ocular manifestation (iridocyclitis, choroiditis and retinal hemorrhages) in patients who were suffering from diarrhea due to *G. duodenalis*. Retinal changes in the form of "salt and pepper" degeneration have been reported in children suffering from giardiasis. Corsi et al. [146] reported salt and pepper retinal changes in 19.9% of the patients with giardiasis. This occurs due to the damage of the retinal cells and subsequent release of pigment granules in retina giving an appearance of blackish dots on a background of light yellow pink retina. The exact mechanism(s) by which giardiasis leads to ocular manifestations is still unknown, although possibility of direct invasion by the parasite is excluded (137). Further studies are desired to exactly pinpoint the mechanism by which retinal manifestations follow the occurrence of intestinal giardiasis. Alterations in the retinal pigment layer are most common but do not cause functional changes in retina, and these lesions do not progress or regress with time [146].

The diagnosis is established by direct demonstration of the parasite in the fecal samples by microscopy. Concentration techniques of the samples yield higher sensitivity. Nitroimidazole group of drugs are highly effective against *G. duodenalis*. Most commonly used drugs are metronidazole for 5–7 days or ornidazole/tinidazole in single dose [147]. Treatment of intestinal infection is recommended if present, but no specific treatment is required for ocular manifestations related to retina [146].

5. Nematode infections

5.1. Onchocerciasis

Onchocerciasis, also known as “river blindness”, is caused by *Onchocerca volvulus*, the filarial nematode. It is transmitted from person-to-person by the repeated bites of infected blackflies (*Simulium* species). These blackflies are mostly found near the flowing rivers and streams and transmit the infection to the people residing in nearby remote villages [148]. The life cycle of the parasite passes between black flies and humans as shown in Figure 10. While taking a blood meal, stage 3 larvae present in infected blackfly are transmitted onto human skin and penetrate into bite wound. In subcutaneous tissue, these larvae develop into adult filariae. Adult worm produces hundreds of thousands of embryonic larvae (microfilariae) that may persist for 3-5 years in the human host. These embryonic larvae migrate to the skin, eyes and other organs. The microfilariae are ingested by the female blackfly when it bites infected humans and develop further in the blackfly. During subsequent bites, it transmits infection to new human host [148, 149].

Onchocerciasis mainly occurs in tropical countries and majority of the cases (99%) have been reported from sub-Saharan Africa. It is also found in some countries of the Middle East and Latin America such as Brazil, Guatemala, Mexico and Venezuela (Table 1, Figure 11). Approximately, 25 million people are known to be affected by onchocerciasis worldwide, and it is known to cause visual impairment and blindness in approximately 800,000 and 300,000 people, respectively [148, 150]. The inflammatory response initiated against dying microfilariae causes gradual and progressive loss of vision due to sclerosal keratitis [149, 151]. Apart from causing keratitis, clinical features may also manifest as iridocyclitis, chorioretinitis and optic atrophy. Autoimmune mechanisms have also been postulated to cause inflammation in the posterior eye. Accumulation of retinal and retinoic acids, strong eosinophilic response and immune reaction against *Wolbachia* antigens [152] released by dying microfilariae also contributes to the ocular pathogenesis [153].

The filarial parasites of major medical importance in humans contain the symbiotic bacterium *Wolbachia*, and reports have revealed that targeting of these bacteria with antibiotics results in a reduction in worm viability, development, embryogenesis and survival. *Wolbachia* is present as an intracellular bacteria symbiont in all the developmental stages of *Onchocerca volvulus*. Clearance of the endosymbionts by antibiotic treatment causes inhibition of worm development. *Wolbachia* contributes directly to the metabolic activity of the nematode. Various

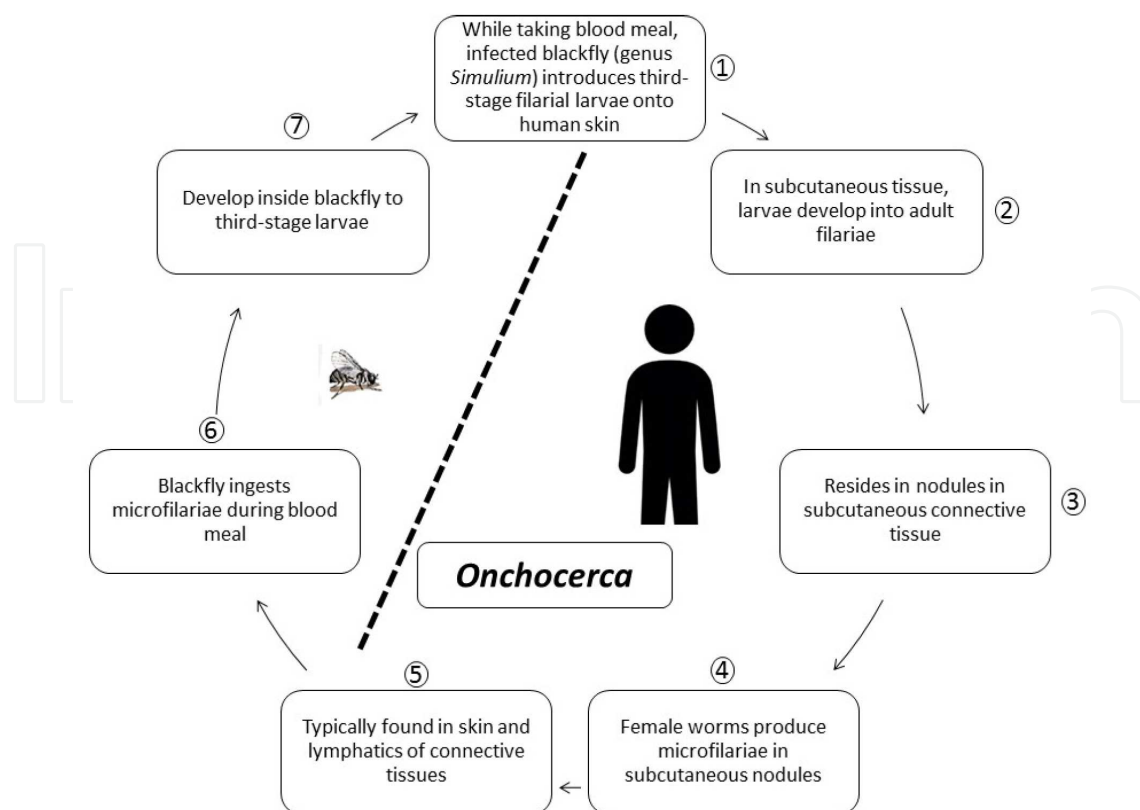


Figure 10. Life cycle of *Onchocerca volvulus* (Diagrammatic representation).

biochemical pathways such as heme, nucleotide and enzyme co-factor biosynthesis are intact in *Wolbachia* but absent or incomplete in nematode [154].

Diagnosis is difficult to establish in light infections. Skin snips can be subjected to microscopy for visualizing the larvae, but it yields very low sensitivity. Infections of the eye can be diagnosed with direct demonstration of the parasite by slit-lamp examination or by demonstrating the parasite in sclerocorneal punch biopsy. Newer techniques such as skin-snip PCR can establish the diagnosis if larvae are not visualized [155]. Antibodies can be detected by ELISA or EIA, but these tests cannot distinguish between past and current infections [156, 157]. Skin-snip PCR has 84–91% sensitivity and 100% specificity [149]. The sensitivity and specificity of serum antibody detection has been reported to be 78–99% and 95–100%, respectively [149]. A promising antigen detection by dipstick assay was recently developed, but its specificity was found to be low in high endemic areas due to cross reaction with urine filarial antigen [158, 159]. Xenodiagnosis (exposing possible infected tissue to a vector and then examining the vector for the presence of microorganism) has also provided clue in some cases.

If the infection is not treated on time, it can progress toward blindness [160]. Drug of choice for the treatment is ivermectin, given 150 to 200 $\mu\text{g}/\text{kg}$ body weight, every 6 months to prevent the skin damage and blindness. Treatment with ivermectin has been shown to decrease visual field loss and severity of keratitis. Ivermectin only kills the larvae but not the adult worms. Doxycycline can be used to kill the adult worm. The mechanism of action is that it kills the

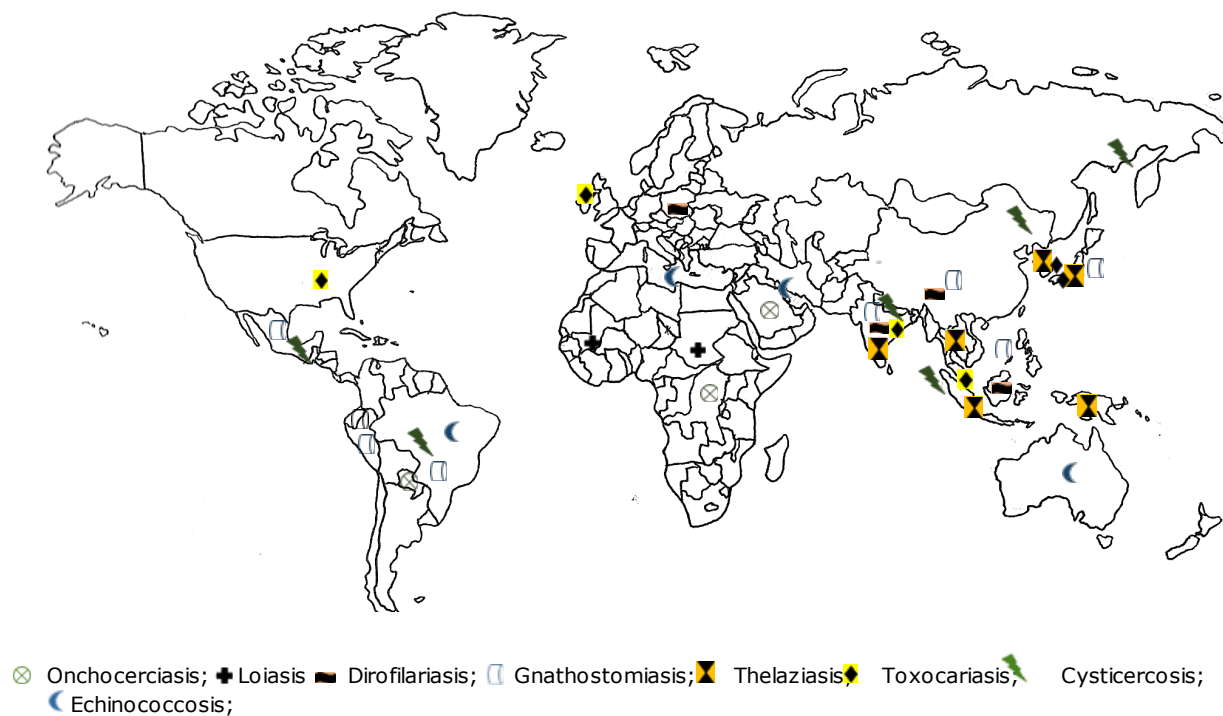


Figure 11. World map showing geographical areas endemic for ocular nematode and cestode infections.

Wolbachia bacteria residing in the worm, on which the adult worm depends for its survival. Treatment with a 6-week course of doxycycline has been shown to kill more than 60% of adult female worms and to sterilize 80–90% of females 20 months after treatment. Thus, treatment with ivermectin is advised one week prior to treatment with doxycycline to provide relief to patient [148, 161].

The best method to get the protection from insect bite is the use of insect repellent. Community-directed treatment with ivermectin (CDTI) along with vector control measures is the main approach to control onchocerciasis. Ivermectin kills microfilariae and also prevents adult worms from producing more microfilariae for few months following treatment, so reduces transmission [148].

5.2. Loiasis

Loiasis is caused by *Loa loa*, the African eyeworm. It is transmitted by the bite of tabanid flies, belonging to the genus *Chrysops*. It affects approximately 3 million people, residing in certain rain forests of Central and West Africa (Table 1, Figure 11) [162, 163]. The tabanid flies most commonly bite during day time and are more common during rainy season. The smoke of wood fires and movement of people attract them. These flies are more commonly found near rubber plantations and are attracted by the well-lit homes. The larvae are passed from flies to humans when humans are bitten by these flies [162]. The larvae develop into adults in the human host over one year and migrate through cutaneous and subcutaneous tissue (Figure 12). Migration of the adult worm is painless, but it is associated with mild tingling sensation. It may involve the nasal area, bulbar conjunctiva and eyelids [164].

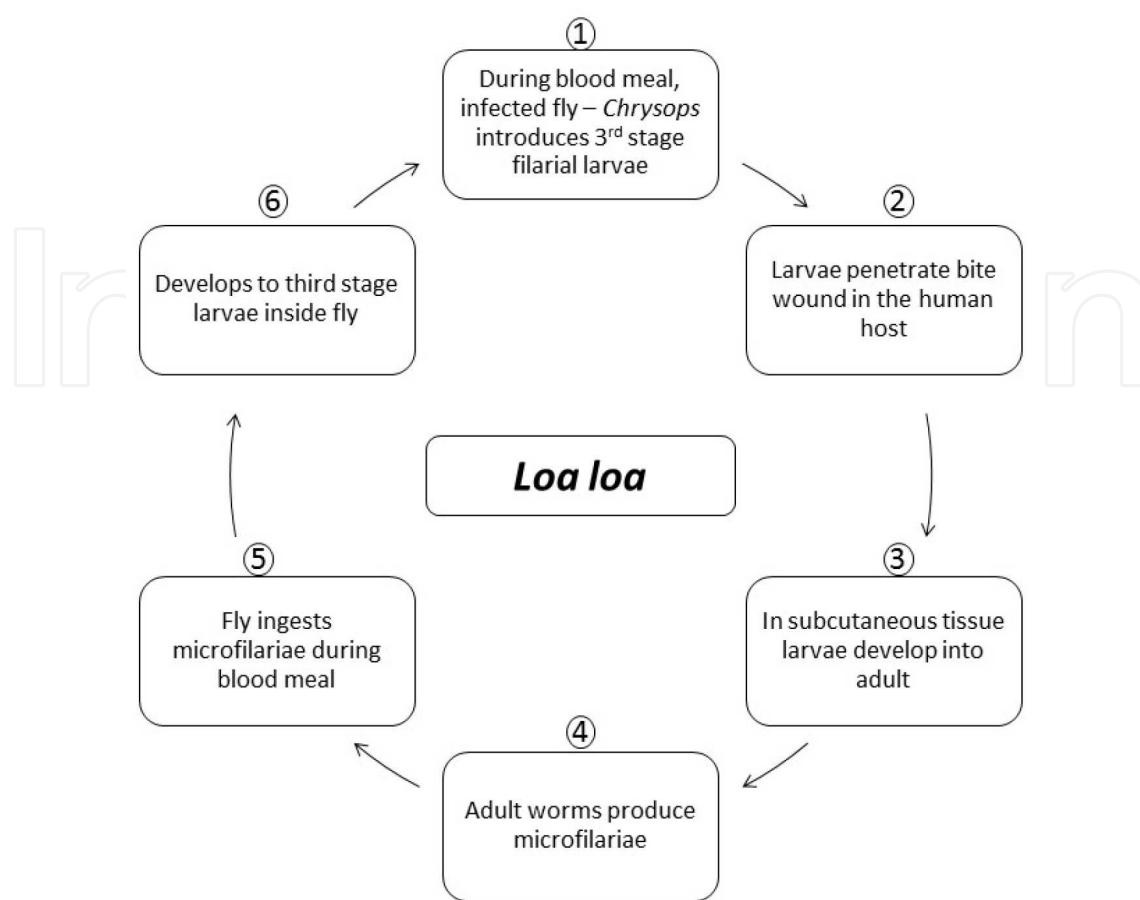


Figure 12. Life cycle of *Loa loa* (Diagrammatic representation).

Ocular manifestations may occur due to the presence of both microfilariae and adult worms. The adult worms may survive up to 15 years and have been found in the conjunctiva, vitreous, eyelid and anterior chamber. Calabar swellings [165] may occur as a result of localized angioedema due to intense atopic reaction. Retinal hemorrhages may occur due to aneurysmal dilatation of the retinal vessels due to the invasion of the retinal and choroid vessels by the microfilariae present in blood stream. Perivascular inflammation can also be present, and ocular examination under slit lamp examination is useful in establishing the diagnosis.

The diagnosis is usually confirmed by the direct demonstration of the microfilariae in the blood by visualizing Giemsa-stained slides under the microscope. However, many of the individuals having visible worm in the eye may test as amicrofilaraemic [166]. Blood should be drawn during the midday as this time coincides with the periodicity of the microfilariae in the blood. The microfilariae can also be demonstrated in unstained blood smear. Adult worm extraction establishes the diagnosis in patients having conjunctival involvement [167]. Antibody detection [168] may aid in establishing the diagnosis, but its presence cannot differentiate between recent and past infection. Eosinophilia and high IgE also indicate active infection [169].

Eye worm if not treated causes very little damage to eye as it lasts less than one week (often just hours). Surgical removal relieves eye symptoms, in addition medical treatment is required

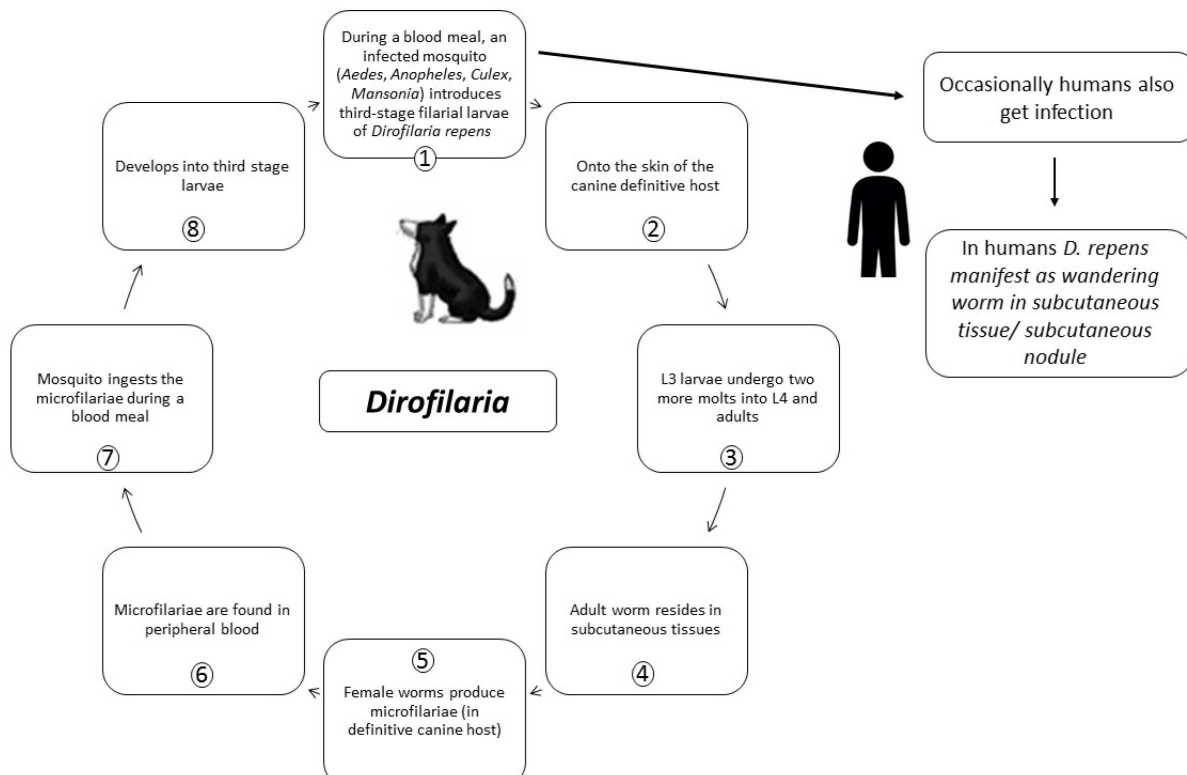


Figure 13. Life cycle of *Dirofilaria repens* (Diagrammatic representation).

for treating loiasis [170]. Therapy involves manual removal of adult worms and administration of diethylcarbamazine (DEC), which kills both adult worms and microfilariae.

5.3. Dirofilariasis

Dirofilariasis is caused by nematodes belonging to the genus *Dirofilaria*. The various species of *Dirofilaria* that are natural parasites of domestic and wild animals are *D. immitis*, *D. repens*, *D. tenuis* and *D. ursi* [37]. It is prevalent worldwide and is an important zoonotic infection. It is being reported in increasing numbers from Mediterranean countries such as Italy and have also been reported from France, Greece, Spain, Croatia, India, Serbia, Denmark, Russia and Tunisia (Table 1, Figure 11). The parasite passes its life cycle in canids as definitive host as shown in Figure 13. Mosquitoes act as intermediate host and vector for the transmission of infection from animals to human host. Mosquitoes take up microfilariae along with blood meal from the infected host, develop inside the mosquitoes and are subsequently transmitted to other hosts while taking a fresh blood meal. Larvae migrate from the subcutaneous tissue to the right side of the heart and/or to other parts of the body where maturation takes place. Depending on the site of lodgment, it can cause pulmonary, cardiovascular, subcutaneous or ocular infection [28].

There are several cases that document ocular involvement due to dirofilariasis [37, 171–173]. Ocular symptoms depend on the site of infection. Eyelid involvement [174] leads to edema,

pain, pruritus and congestion of conjunctiva, whereas intraocular [175] involvement leads to foreign body sensation, diplopia, photophobia and floaters.

Diagnosis can be established by the direct demonstration and identification of the adult worm. Intraocular presence of the parasite can be confirmed by ophthalmoscopy. Serological techniques are not useful in establishing the diagnosis due to the cross reaction with other parasitic helminths, particularly *Toxocara canis*. Recombinant proteins proved to exhibit 100% sensitivity and 90% specificity by ELISA for the diagnosis of pulmonary dirofilariasis [176].

Without treatment, worm remains in eye causing symptoms due to its presence [177]. Surgical excision is the treatment of choice; however use of diethylcarbamazine (DEC) has also been reported with some success [37, 178].

5.4. Gnathostomiasis

Gnathostomiasis is a food-borne zoonotic parasitic infection, caused by ingestion of raw or undercooked freshwater fish, pork, chicken, frog and snake [179, 180] contaminated with the third-stage larvae of *Gnathostoma* species. The life cycle of the parasite passes in pigs, cats and wild animals as definitive host, whereas small crustaceans act as first intermediate host and fish, frog or snake act as second intermediate host as depicted in Figure 14. In the infected person, larvae migrate through viscera and reach internal organs and subcutaneous tissues. Depending on the location of lodgment, it can cause cutaneous, visceral, ocular or cerebral gnathostomiasis. Majority of the cases have been reported from East Asia (Thailand, China, Japan and India) and Central and South America (Mexico, Guatemala, Peru and Ecuador) (Table 1, Figure 11). However, sporadic cases have been reported worldwide [181]. *Gnathostoma spinigerum* is the most common species causing infection in humans.

Ocular manifestations occur due to the migration of the parasite and its metabolites, leading to inflammatory response. Conjunctiva and corneal infection may lead to congestion of the conjunctiva and corneal ulceration, respectively. Intraocular involvement may lead to glaucoma, uveitis, retinitis and vitreous hemorrhage [182, 183]. In severe cases, retinal detachment has also been reported due to the fibrinous scarring along the migratory path.

Diagnosis is difficult to establish and high index of suspicion is required. Patients may present with marked eosinophilia [184] and elevated IgE levels [185]. ELISA for specific antibody detection and histopathological examination of the biopsy samples may assist in establishing the diagnosis [186–188]. ELISA for antibody detection reported to have low sensitivity, ranging from 59 to 87%, with a specificity of 79–96% [189, 190]. If parasite is not removed, it leads to persistence of visual disturbances such as floaters. Surgical treatment is curative and only modality available [191].

5.5. Thelaziasis

Thelaziasis is caused by nematode *Thelazia callipaeda*, transmitted to humans by drosophilid flies [192]. It is also known as oriental eyeworm due to its geographical distribution in Asia Pacific region (China, India, Thailand, Indonesia, Japan and Korea) and Russia [12, 193] (Table

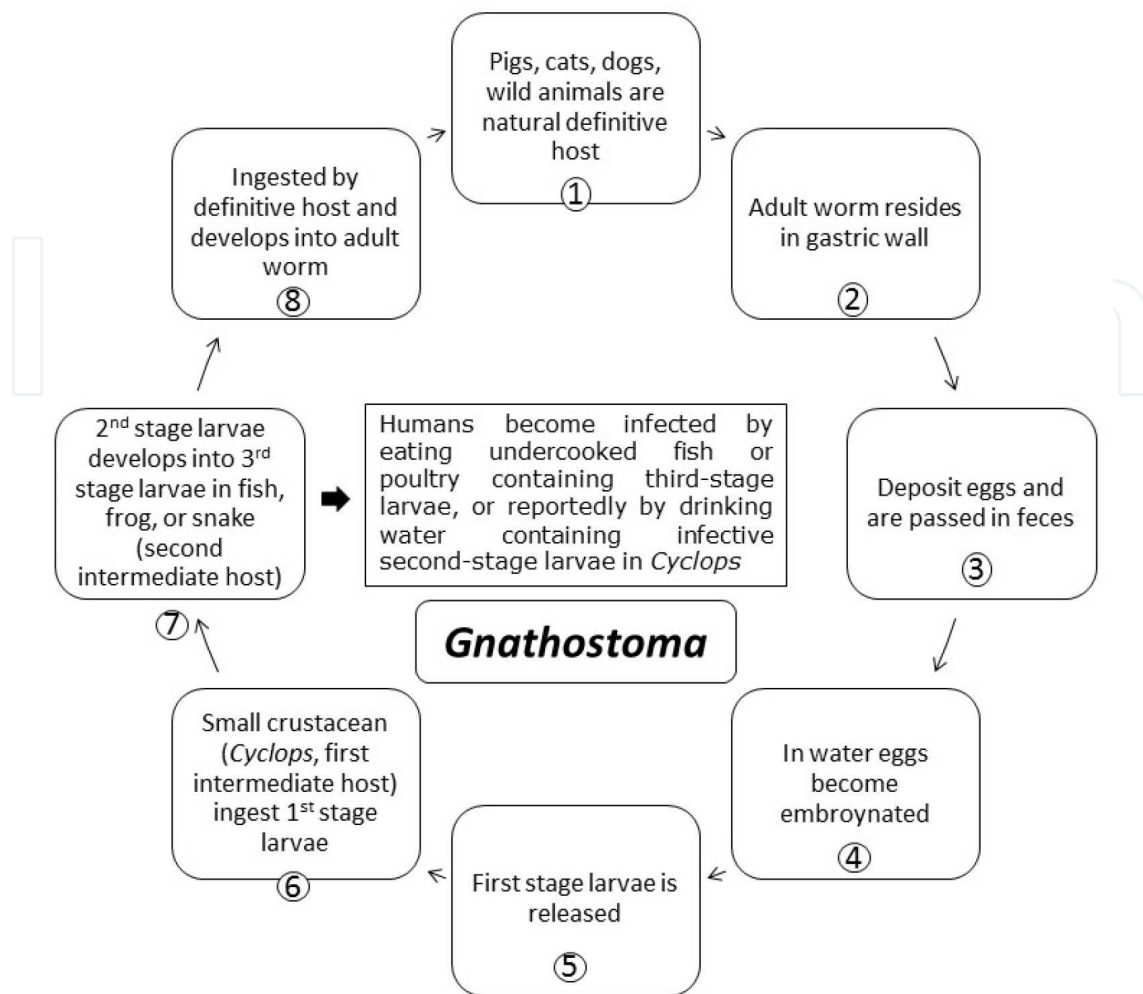


Figure 14. Life cycle of *Gnathostoma* (Diagrammatic representation).

1, Figure 11). The life cycle passes in dogs and other canids, cattle and horses as definitive host and flies act as intermediate host as shown in Figure 15. First-stage larvae are present in the lacrimal secretions of infected humans/animals. The arthropod vectors while feeding on infected lacrimal secretions ingest these larvae, which further develop into infective third-stage larvae. The vector transmits accidentally third-stage larvae when it feeds on lacrimal secretion of other persons/animals. Within 5–6 weeks, these larvae further develop into adult form in the eye of an infected person. These parasites mainly cause infection of the anterior segment of the eye, but intraocular infections involving vitreous and retina have also been reported. It is a disease associated with poor personal hygiene.

Without treatment, worm remains in eye causing symptoms due to its presence [194]. Treatment is surgical removal of worms along with the topical application of thiabendazole. Preventive measures include use of bed nets at night, maintenance of personal hygiene and keeping surroundings clean to control the vector population responsible for the transmission of infection [8].

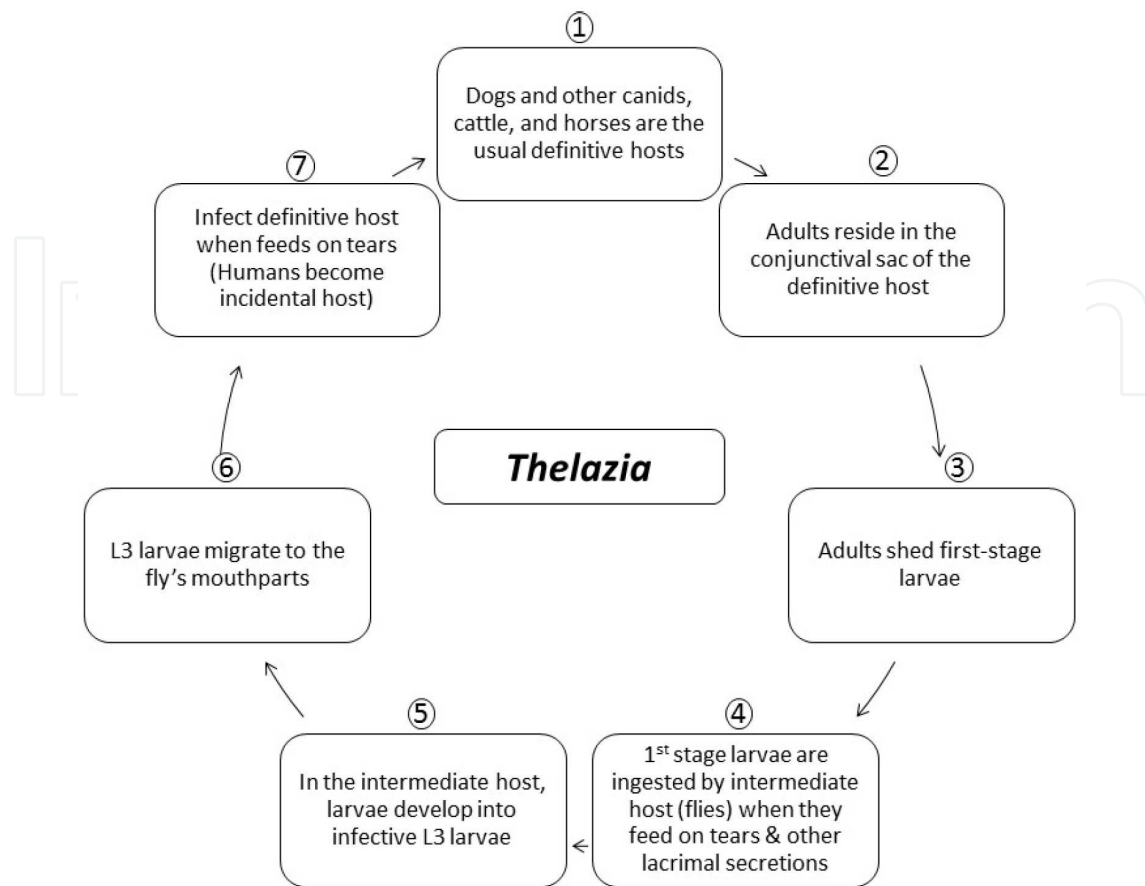


Figure 15. Life cycle of *Thelazia* (Diagrammatic representation).

5.6. Toxocariasis

Toxocariasis is caused by *Toxocara* species. *Toxocara canis* and *T. cati* are the most common species causing toxocariasis in humans worldwide, particularly in Asia, Japan, Korea, Ireland and Alabama [195–199] (Table 1, Figure 11). The life cycle of *Toxocara* involves dogs (*T. canis*)/cats (*T. cati*) as definitive host (dog/cat). Infection is transmitted by consumption of eggs of *Toxocara* parasites, passed in the feces of definitive host (dog/cat) as shown in Figure 16. After the ingestion of eggs, larvae hatch out from the eggs in the small intestine and penetrate mucosa to migrate to different organs such as liver, lung and trachea, leading to visceral larva migrans (VLM). Sometimes, target larvae may migrate to eyes causing ocular larva migrans (OLM) [200, 201]. Host immune response is weaker in ocular larva migrans than visceral larva migrans. Various ocular clinical manifestations such as keratitis, hypopyon, iritis, uveitis, posterior pole granuloma, vitreous abscess and retinal detachment, strabismus, vision loss are attributed due to vitritis, cystoid macular edema and tractional retinal detachment [11, 202–204]. Based on clinical and physical examination, ocular toxocariasis is classified as chronic endophthalmitis, posterior granuloma and peripheral granuloma [205]. Approximately 25–50% of ocular toxocariasis patients present as posterior pole granuloma, due to lodging of the parasite in small perifoveal end-arteries, and approximately in 50% of ocular toxocariasis patients peripheral granuloma is present. Acute lesion appears as hazy, white mass in the

peripheral fundus that may mimic the appearance of snowbank seen in patients with pars planitis.

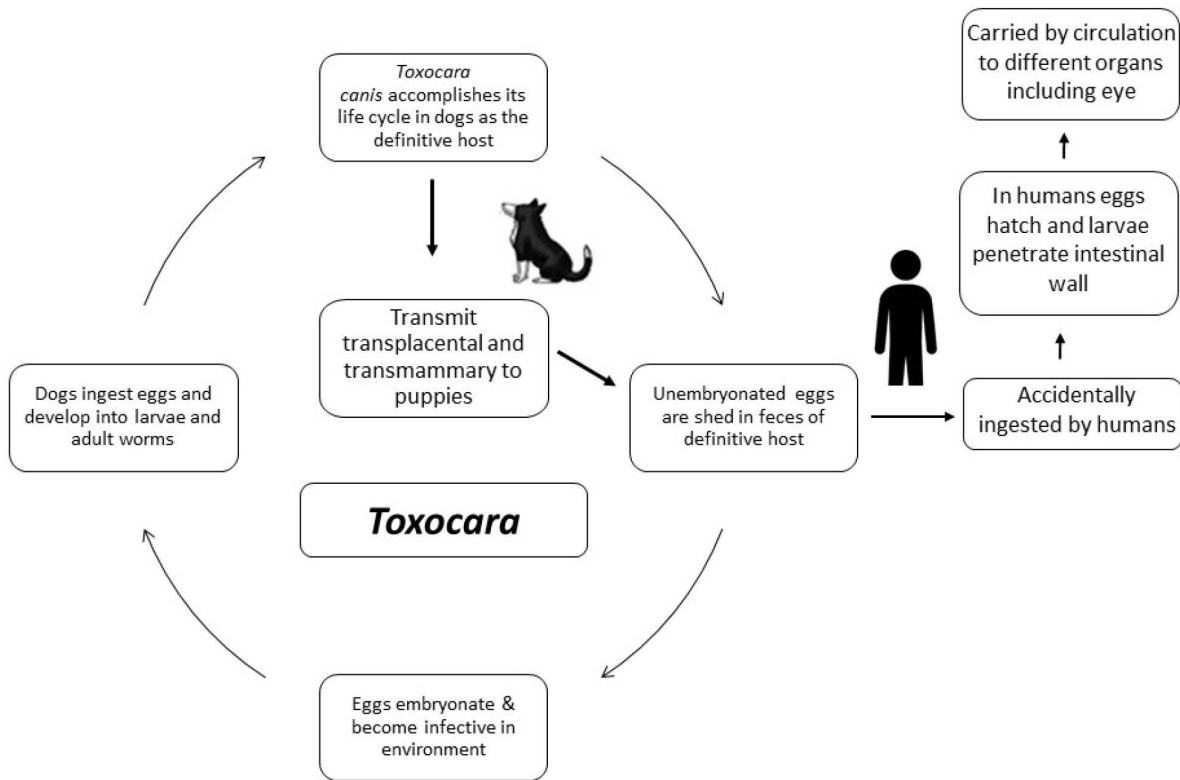


Figure 16. Life cycle of *Toxocara* (Diagrammatic representation).

High index of suspicion is required for establishing the diagnosis of OLM during ocular examination [205]. Marked eosinophilia along with positive serology by ELISA [206] helps in confirming the diagnosis [207]. Detection of specific antibodies in the vitreous fluid also helps in differentiating it from retinoblastoma [208]. ELISA based on the excretory-secretory antigens of *T. canis* reported to have a sensitivity of 78% [209]. ELISA developed by Seoul National University, using crude antigen of *Toxocara* larvae, showed a sensitivity of 92.2% and specificity of 86.6% [210]. PCR available in research laboratories [211] may help in the diagnosis of ocular toxocariasis. Nucleotide homology of 97–99% has been reported between Vietnamese *Toxocara canis* and other *Toxocara* geographical strains by comparing the nucleotide sequence of internal transcribed spacer 2 (ITS2) of ribosomal DNA of *T. canis* [212]. Although PCR has been shown to be the best diagnostic modality in animal models of ocular toxocariasis, molecular techniques are not available in hospitals of resource limiting countries [213]. Vision loss, eye inflammation or damage to the retina occurs if not treated. Prognosis is good with medical and surgical treatment [200].

Albendazole and mebendazole are the drugs of choices for the treatment of VLM [214, 215]. However, there is a limited role of antiparasitic drugs in the treatment of OLM. Photocoagulation along with steroids has been recommended for the treatment of OLM.

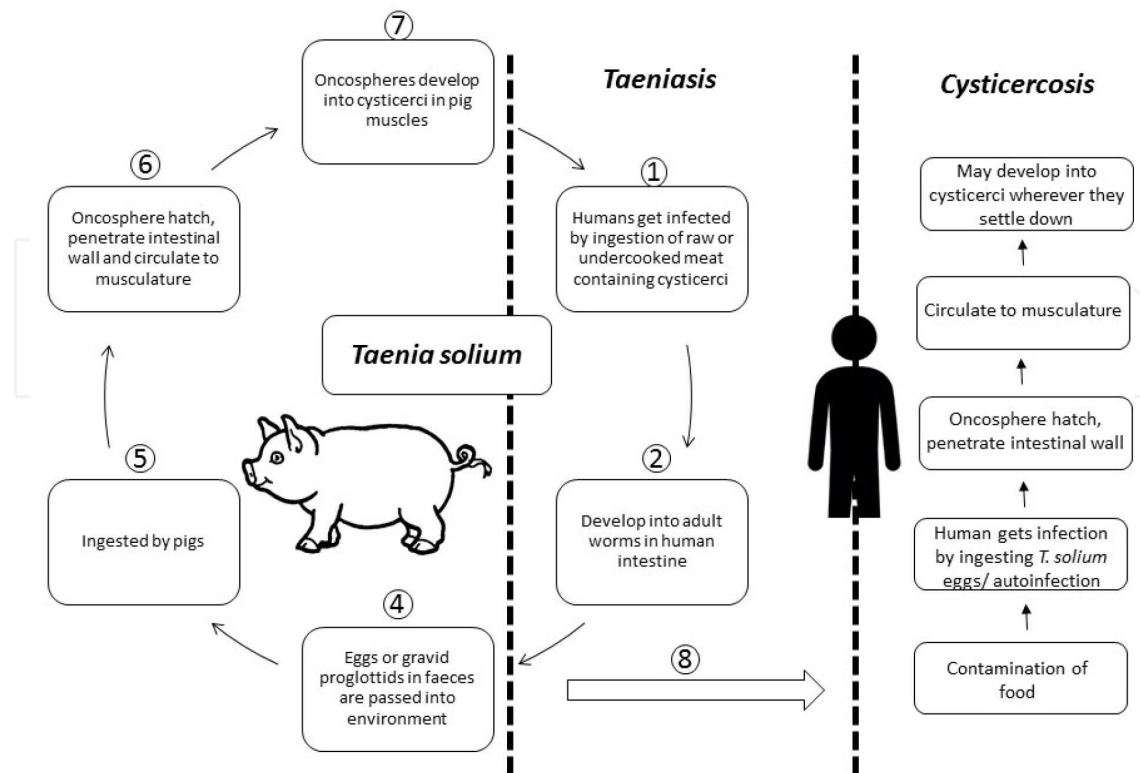


Figure 17. Life cycle of *Taenia solium* (Diagrammatic representation).

6. Cestodes infections

6.1. Cysticercosis

Cysticercosis is caused by the larval cysts of the tapeworm *Taenia solium*. Humans acquire cysticercosis infection by the consumption of food contaminated with the *Taenia solium* eggs, passed in feces of the infected humans, harboring the adult worms in their intestine as depicted in Figure 17 [216]. Autoinfection has also been reported in persons suffering from taeniasis that may result in cysticercosis. Eating of raw or uncooked pork results in adult worm infection, the taeniasis. It is considered as one of the important neglected parasitic infections (NPIs), prevalent in Asia, Africa and Latin America where poor sanitation conditions prevail (Figure 11) [217]. These larval cyst may lodge into different organs/tissues (brain, muscles, eyes or other tissues) [218], resulting in varying clinical symptoms.

Ocular involvement is well documented and several case reports have documented the orbital, intraocular, subretinal and optic nerve involvement due to cysticercosis [219, 220]. Free-floating cyst can be found in vitreous or anterior chamber of the eye. Cranial nerve or intraocular muscles lesions may result in gaze palsies [221–223].

Diagnosis is usually established by ophthalmoscopic examination along with imaging evidence of ultrasonography, CT scan or MRI scan. Although serology is easy to perform, it is usually negative in isolated ocular cysticercosis patient [224]. Molecular techniques such as

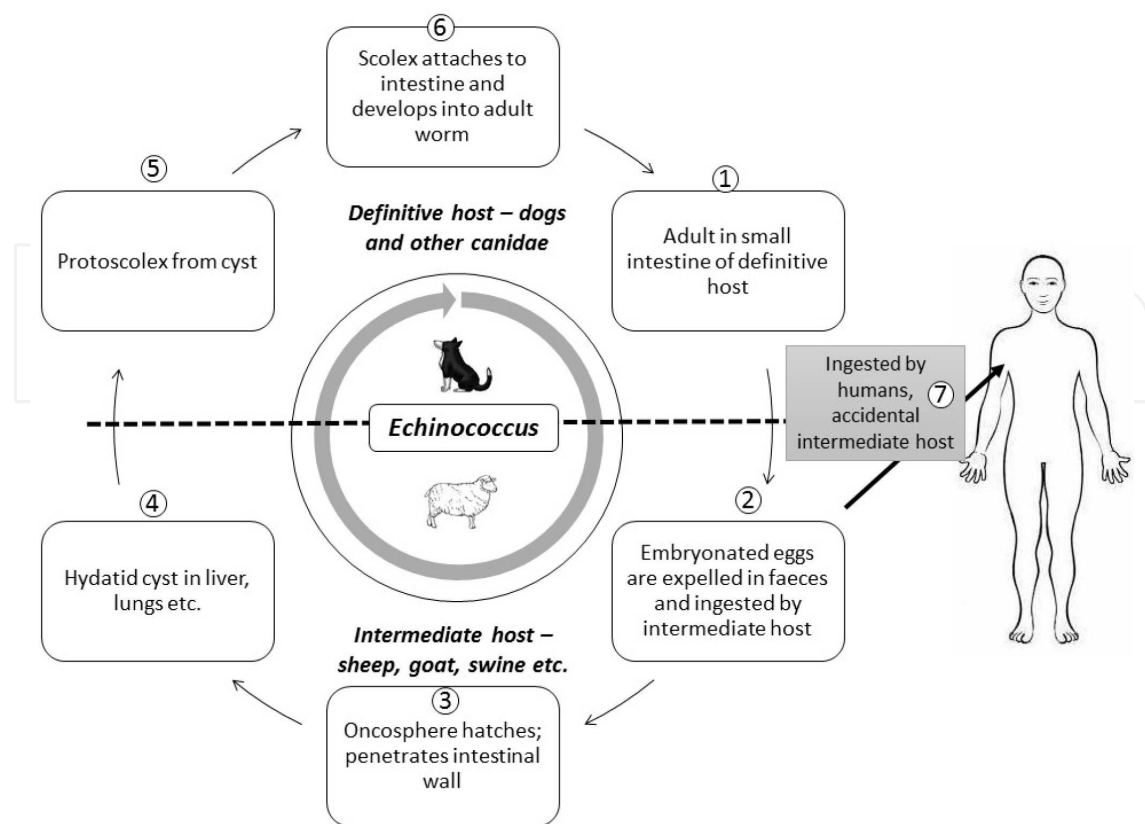


Figure 18. Life cycle of *Echinococcus* (Diagrammatic representation).

conventional PCR, real-time PCR [218] and loop-mediated isothermal amplification (LAMP) [225] can be utilized for establishing the diagnosis of ocular cysticercosis and for genotyping [30, 226]. However, it requires a sophisticated molecular laboratory setup, which is not available widely in developing nations.

Without treatment, symptoms related to visual disturbances persist. Symptoms resolve with surgical and medical treatment [227]. Albendazole along with steroids are the main drugs used in the treatment. Steroid treatment decreases the inflammatory response associated with the antihelminthic therapy around the lesions. Surgical removal of large cysts is recommended where there is an impairment of the vision [224].

6.2. Echinococcosis

Echinococcosis/hydatidosis is caused by infection of the larval stages of the *Echinococcus* spp [228], and ocular manifestations occur approximately in 1% of the cases suffering from hydatid disease [229]. Echinococcosis is mainly found in Asia, Africa, Latin America, Russia, Australia and the Mediterranean regions (Figure 11) [230]. It is acquired by the consumption of contaminated food and water with fecal matter containing eggs of *Echinococcus* parasites. The life cycle includes development of adult worms in small bowel of definitive hosts such as dogs and other canids. Eggs are passed in feces and contaminate environment as shown in Figure 18.

The symptoms and signs depend on the location of the cyst in the target organ. Most common ocular finding is the development of proptosis due to the presence of intraorbital space occupying lesion. This may further lead to exposure to keratitis and ulceration of the cornea. Other complications due to the local invasion of the expanding cyst may lead to erosion of orbital wall, optic atrophy and optic neuritis. Subretinal hydatid cyst has been reported. In severe cases, blindness may also occur [231].

The diagnosis depends on the clinical findings suggestive of hydatid cyst on ocular examination and confirmed by radiological techniques such as ultrasonography, CT scan and/or MRI [232, 233]. “Double wall” sign is a characteristic of orbital hydatid cyst seen by ultrasonography [232]. Serology may also aid in diagnosis. However, in majority of the commercially and in-house serological assays, hydatid fluid is the main antigenic component and sensitivity of IgG-ELISA reported in various studies varies from 64.8 to 100%, while specificity varies from 87.5 to 100%. Purified and recombinant antigens are also being tried for developing ELISA with high sensitivity and specificity [234]. Fine needle aspiration cytology can also be performed for establishing the diagnosis [235].

Symptoms persist if not treated [236]. Surgical removal of the cyst is the treatment of choice. Medical therapy includes administration of albendazole or mebendazole to prevent the recurrences due to the contents of the cyst leaking into the surgical sites [237]. If the cyst is accidentally ruptured, in situ irrigation with hypertonic saline should be performed. However, it causes local inflammatory reaction that may lead to atrophy of optic nerve [238].

7. Trematodes infections

7.1. Fascioliasis

Fascioliasis is a food-borne parasitic infection caused by trematodes that mainly affect liver. It is acquired by eating metacercariae of *Fasciola hepatica* encysted on leaves that are eaten raw. Two important species are *Fasciola hepatica* and *F. gigantica*. The life cycle includes release of eggs from adult flukes that further develop into miracidia, sporocysts, rediae, cercariae and metacercariae as shown in Figure 19. The parasite passes its life cycle in two different hosts: sheep, goat, cattle and man act as definitive host and snails of the genus *Lymnaea* act as intermediate host. The eggs are passed out in the feces of definitive hosts that mature in water. Ciliated miracidium develops inside each egg in 2–3 weeks. Miracidium after getting released from egg finds its way to its suitable intermediate host. Inside the lymph spaces of the molluscan host, the miracidium passes through stages of sporocyst, two generations of rediae and finally to the stage of cercariae. The mature cercariae escape from the snail into the water and encyst (metacercariae) in blades of grass or water-cress, which is ingested by herbivorous animals and occasionally by man. On entering the digestive tract, the metacercariae excyst in the duodenum and migrate through intestinal wall into peritoneal cavity. It further traverses through liver capsule, parenchyma and ultimately settle in the biliary passages, where it mature into adults. The eggs are liberated in the feces through bile, completing the life cycle.

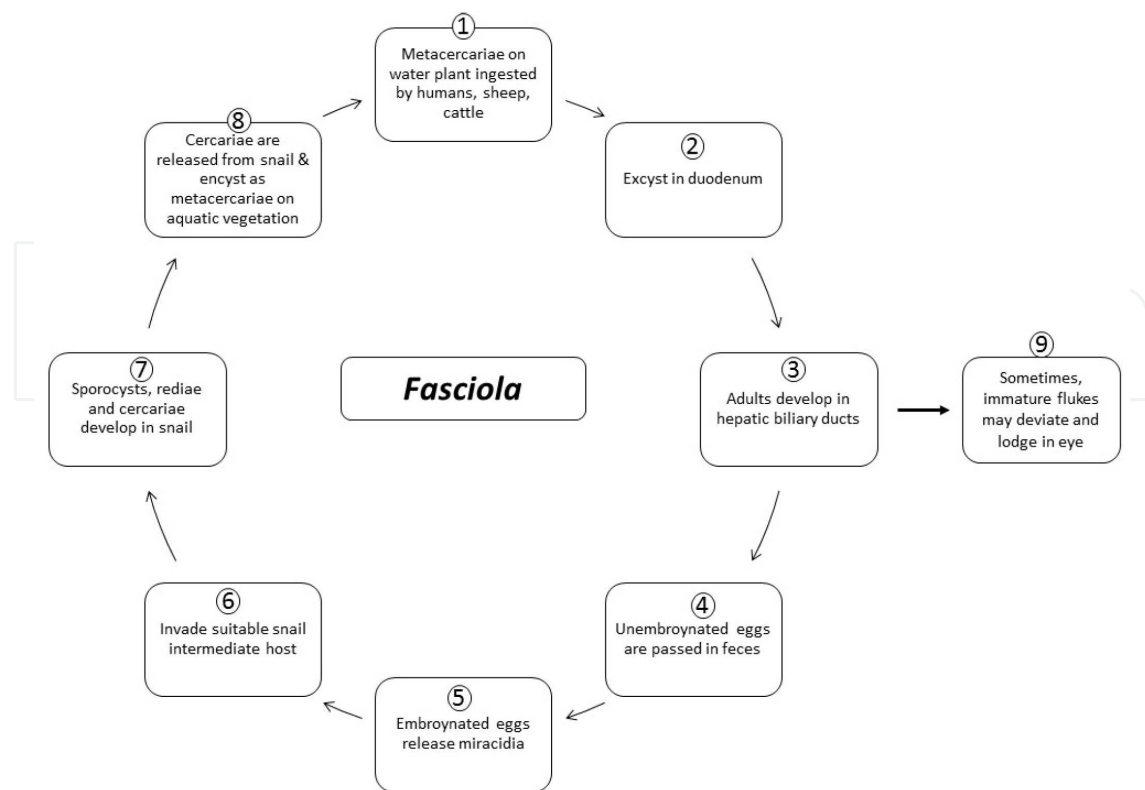


Figure 19. Life cycle of *Fasciola* (Diagrammatic representation).

Ophthalmofascioliasis is the term used for those cases in which eye infection is directly caused by migrant ectopic fasciolid fluke. All other patients with ocular manifestations due to fasciolids located in liver or other organs should be classified as fascioliasis with ocular implications. Although ocular involvement in fascioliasis is rare, cases have been reported from France, Spain, Italy, Austria, Belgium, United Kingdom, Algeria, Tunisia, Iran, Uzbekistan, Korea, China, Argentina, Chile, Peru, Brazil and Guatemala (Figure 20) [239]. Symptoms and signs usually relate to the affected eye and may cause conjunctival hyperaemia, corneal oedema, dilated episcleral vessels, paralysis of extraocular muscles, decrease in perception of light, deep anterior chamber with flare, uveitis and so on. Diagnosis is established directly by visualization of leaf-shaped like organism in the eye or by studying the morphological features of the surgically removed worm. Eosinophilia, positive serology by ELISA or presence of eggs in stools may aid in diagnosis. Severe complications may occur if not treated. Early surgical intervention is associated with rapid response and reasonable final visual acuity [14]. Thus, ophthalmological manifestations have been known to be cured with surgical treatment without any antiparasitic treatment [14]. However, triclabendazole is the drug of choice if medical treatment is required.

7.2. Schistosomiasis

Schistosomiasis, or bilharziasis, is caused by trematode flatworm of the genus *Schistosoma*. Freshwater snails release the larval forms in the water, which penetrate the skin of human host

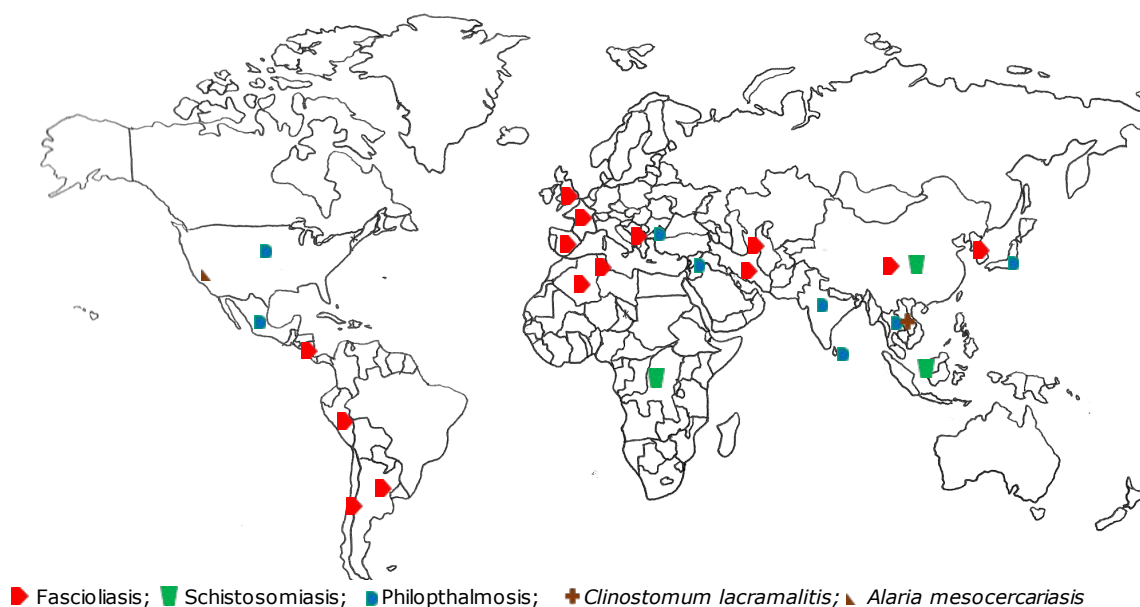


Figure 20. World map showing geographical areas endemic for ocular trematode infections.

while swimming, bathing, fishing and even domestic chores such as laundry and herding livestock. In the human body, the larvae mature into adult schistosomes, which reside in the blood vessels. Eggs released by females are passed out of the body in the urine or feces. It is prevalent in sub-Saharan Africa, China and South Asia (Figure 20) [8].

Ocular involvement is not the usual site that is involved in schistosomiasis, but cases have been reported where *Schistosoma* ova or even the adult worm can reach the systemic circulation and can lodge itself at ectopic sites such as eyes. Although schistosomiasis is very common, ocular cases are rare. It can cause uveitis or subretinal granuloma [240]. Diagnosis is established by direct demonstration of eggs/cercariae in the eye. Detection of eggs in the urine and feces may aid in establishing the diagnosis. Symptoms persist if not treated. Praziquantel is the drug of choice for all forms of schistosomiasis [8].

7.3. Other rare ocular infections by trematodes

The cases of acute nodular conjunctivitis and anterior chamber granuloma formation have been documented, which are caused by endemic water-borne trematode infection. The identification of the remnants of parasites aspirated from such cases revealed that these parasites belong to the genus *Philophthalmus* that are known to parasitize birds [25, 241]. Humans acquire infection accidentally while bathing or playing in contaminated water. Conjunctival nodules heal spontaneously, and anterior chamber nodules can be treated with topical/oral corticosteroids. Surgical removal is recommended in cases having large nodules. First human case of *Clinostomum lacramalitis* was reported in Thailand [242]. Human cases of intraocular infection with mesocercariae of *Alaria americana* and other *Alaria* mesocercariae have been reported in patients who had ingested undercooked contaminated frogs legs [243].

8. Eye infections caused by ectoparasites

8.1. Myiasis

Myiasis is an infection caused by larvae of flies. It is common in tropical and subtropical areas. It is known as ophthalmomyiasis when ocular structures are involved. Ophthalmomyiasis is categorized into three clinical categories (ophthalmomyiasis externa, ophthalmomyiasis interna and orbital myiasis), depending on the location of larvae in the eyes. Several genera have been reported to cause myiasis such as *Dermatobia*, *Gasterophilus*, *Oestra*, *Cordylobia*, *Chrysomyia*, *Wohlfahrtia*, *Cochliomyia* and *Hypoderma* [1]. Significantly, larvae causing ophthalmomyiasis belong to the genus *Hypoderma* [16]. Three cases of external ophthalmomyiasis, two due to *Oestrus ovis* and one due to *Cochliomyia hominivorax* were reported earlier from North India [17]. *Oestra ovis* also known as sheep nasal botfly is responsible for causing ophthalmomyiasis externa in shepherding areas [244–247]. It mainly involves eyelids, conjunctiva, lacrimal sac and nasolacrimal ducts. Most common clinical feature is the foreign body sensation and may be associated with conjunctivitis and keratitis.

Diagnosis is established by the identification of the maggots. Treatment usually involves the surgical removal of the maggots. Medical treatment involves just one oral dose (150 to 200 µg/kg of body weight) of ivermectin [16]. However, the use of ivermectin for the treatment of myiasis is an off-label treatment in many countries and should be used for selected cases. The side effects such as dermal eruptions, fever, dizziness, migraines and muscular pains are common. Antibiotics and steroids may also be required to prevent the inflammation and superadded bacterial infection. Ophthalmomyiasis interna [248] is caused by the invasion of the ocular structures leading to uveitis, lens dislocation and retinal detachment. Diagnosis is established by visualizing the migratory tracks along subretina by the ophthalmoscopy. Symptoms persist if not treated. Serious complications may also occur such as lens dislocation and retinal detachment due to invasion of tissue [1]. Steroid therapy is advocated if there is severe inflammation, and surgical removal is performed in severe cases. Orbital myiasis is seen in patients who are not able to maintain good personal hygiene [16]. Treatment is directed at removal of maggots and control of secondary infection. Preventive measures include maintenance of good sanitation conditions and proper disposal of waste material to control the flies in surrounding areas.

8.2. Lice

Important genera of the lice causing human infestation belong to *Pediculus* and *Phthirus*. Geographical areas where *Phthiriasis palpebrarum* is commonly found have been depicted in Table 1 and Figure 21. Eggs or nits laid down by lice glue themselves to body hairs or clothing fibers. Nymphs emerge from eggs and feed on the host, causing pruritis. Eyebrows and eyelashes are most commonly involved. Excoriation marks along with small erythematous papules aid in diagnosis. Nits can be found at the base of eyelashes, substantiating the clinical diagnosis. Symptoms persist if not treated. Eyelid disease is treated by petrolatum and non-eyelid involvement may be treated with lindane, permethrin, pyrethrin or malathion [1].

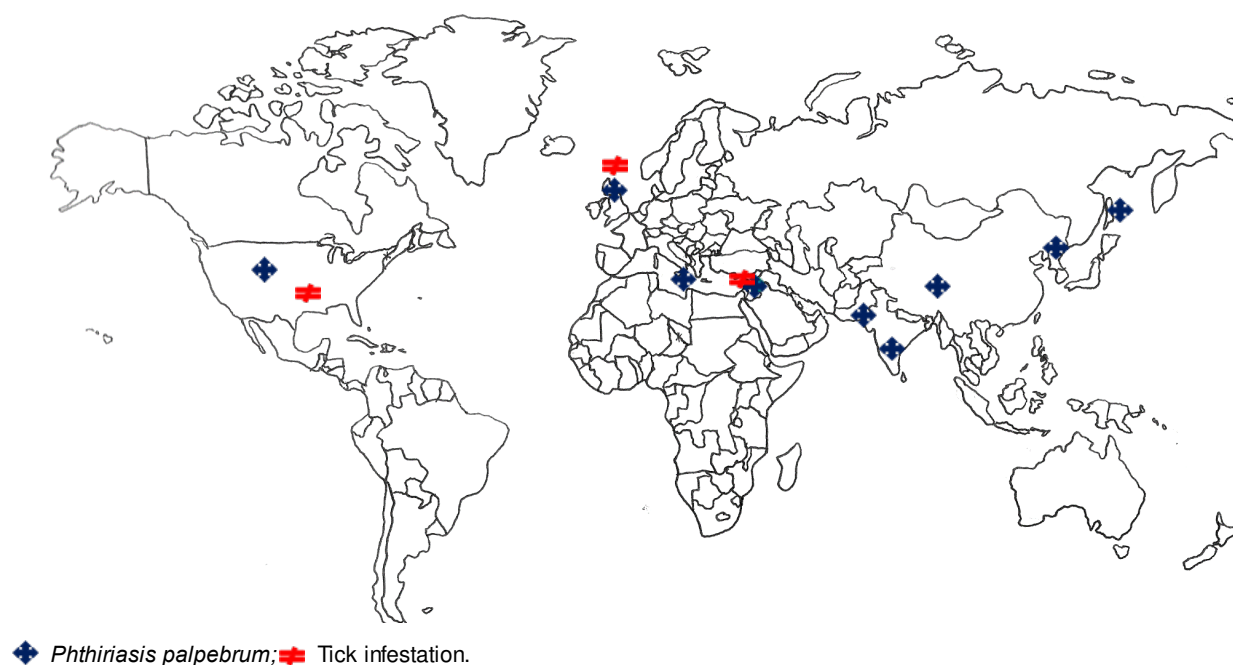


Figure 21. World map showing geographical areas endemic for ocular ectoparasites. *Phthiriasis palpebrarum*; Tick infestation.

8.3. Ticks

Ticks belonging to the class Arachnida are important vectors for the transmission of several infections to humans [1]. Geographical regions where ticks' infestation has been reported are depicted in Table 1 and Figure 21. Ticks complete their life cycle in three different stages, i.e. larva, nymph and adult, and all the life cycle stages require blood meals. Ticks have been reported to attach to ocular structures that may appear as meibomian gland mass. Symptoms persist if not treated. Treatment includes removal of ticks, and tick bite granuloma may resolve after several weeks.

9. Summary

Ocular parasitic infections are of medical importance worldwide because of significant morbidity rates, and if not diagnosed and treated on time could lead to vision loss. High index of clinical suspicion is required to establish the diagnosis for further confirmation by laboratory techniques followed by specific treatment. Direct demonstration of the parasite is possible in few ocular parasitic infections, while in few, specific clinical features such as changes in retina on direct ocular examination may point toward specific diagnosis. Serology has limited role in the diagnosis as most of the ocular parasitic infections are localized in the eye. Utility of different diagnostic techniques in various parasitic ocular infections has been summarized in Table 2. Although reports reveal that the serology for antibody detection and/or molecular techniques for parasite DNA detection, when applied directly on the ocular tissues, aqueous

or vitreous humor usually confirm the diagnosis, these techniques have its own merits and demerits. IgG immunoblot technique has been applied for the diagnosis of ocular toxoplasmosis with some success, and it is suggested that local antibody production is presumed to have occurred, if immunoreactive bands are detected in the aqueous humor but not in the serum [249]. Future reports in this direction may throw further light on its utility. Moreover, application of Western blotting technique may be possible only in limited diagnostic centers.

Report on “Diagnostic Approach to Ocular Toxoplasmosis” revealed in conclusion that the clinical diagnosis of ocular toxoplasmosis may be supported by laboratory tests in 60–85% of cases, depending on the time of sampling. Analysis of the aqueous humor is particularly helpful in patients with atypical lesions or in individuals who are irresponsive to specific therapy. Even so, a laboratory confirmation of the clinical diagnosis is not achieved in 15–40% of cases [72].

In general, it can be concluded that the clinical awareness and multiple approaches/techniques for the confirmatory diagnosis of clinically suspected ocular parasitic infections may yield higher sensitivity and diagnostic efficacy, as suggested earlier [250].

Treatment depends on the causative agent and may involve surgical removal and/or medical treatment with antiparasitic drugs (Table 2). In few infections, steroids are also prescribed to prevent the damage from the inflammatory response associated with the dying parasites. Preventive strategies depend on the type of parasitic infection and mainly include control of vector population for vector borne parasitic infections, maintenance of good personal hygiene and providing awareness to people about ocular parasitic infections through information, education and communication (IEC).

The need of increased awareness and clinical suspicion of OPI for prompt and specific diagnosis followed by application of sensitive and specific diagnostic technique(s) for confirmation and effective treatment are the main challenges.

The future research priorities need to be directed to study exact host-pathogen mechanisms, local immune responses and to establish more sensitive and specific diagnostic techniques. The molecular techniques can provide rapid diagnosis of multiple ocular parasitic infections and species identification for specific therapy. Multiplex PCR assay, if developed, can add new dimensions in the diagnosis. Efforts to develop animal models are desired that may further help to study the exact host-pathogen mechanisms, local immune responses and in developing new treatment strategies.

Ocular protozoal infections	Diagnosis	Treatment
Toxoplasmosis	Serology – IgM, IgG, IgA Molecular: PCR, Real-time PCR	a. Pyrimethamine and sulfadiazine plus corticosteroids b. Trimethoprim/sulfamethoxazole plus oral prednisolone c. Intravitreal clindamycin (1-1.5mg) injection and dexamethasone d. Surgery reserved for severe complicated cases

Ocular protozoal infections	Diagnosis	Treatment
Acanthamoeba keratitis	Microscopy, culture on non-nutrient plates (coated with bacteria)/ in flasks (PBS +Bacteria), PCR, Real-time PCR	<p>a. Biguanides – PHMB (0.02%)</p> <p>b. Chlorhexidine 0.02% in combination with aromatic diamidines such as 0.1% propamidine isethionate, 0.15% dibromopropamidine, hexamidine 0.1% and neomycin (Topical antimicrobials should be administered every hourly for first several days and there after frequency reduced to every 3 hours with a minimum duration of therapy of 3-4 weeks</p> <p>c. Surgical treatment includes keratoplasty or its variation known as DALK (Deep Anterior Lamellar Keratoplasty)</p>
Chagas disease	Blood smear, Buffy coat, culture, xenodiagnoses and PCR	<p>a. Benznidazole 5-10 mg/kg daily in 2-3 divided doses for 60 days</p> <p>b. Nifurtimox 15 mg/kg daily in 3 divided doses for 60-90 days</p>
Malaria	Thin and thick blood film for microscopy, antigen detection, PCR	<p>a. <i>Plasmodium vivax</i> – Chloroquine + primaquine</p> <p>b. <i>P. falciparum</i> – Artemisinin combination therapy (Artemisinin + sulfadoxine-pyrimethamine or artemisinin + lumefantrine) as per WHO guidelines</p>
Leishmaniasis	Microscopy of tissue smears, culture on NNN media, PCR	Pentavalent antimonial compounds, liposomal amphotericin B, miltefosine (dose is weight dependent), paromomycin, azoles such as ketoconazole, itraconazole and fluconazole
Microsporidiosis	Microscopy, Immunofluorescence assay, PCR	Topical fumagillin bicylohexylammonium (Fumidil B) 3 mg/mL in saline (fumagillin 70 µg/mL) eye drops: two drops every 2 hours for 4 days, then two drops four times daily (investigational use only in United States) plus albendazole 400 mg orally twice daily for management of systemic infection.
Giardiasis	Confirming by intestinal infection	Metronidazole, tinidazole, and nitazoxanide. Others include paromomycin, quinacrine, and furazolidone
Ocular nematode infections		
Onchocerciasis	Slit-lamp examination, Biopsy of the skin to identify larvae, skin nodules examination for identification of adult worms, PCR, antibody detection	<p>a. Ivermectin: given every 6 months for the life span of the adult worm or as long as infected person has evidence of skin or eye infection</p> <p>b. New treatment: Doxycycline, before starting treatment infection with <i>Loa loa</i> has to be ruled out</p> <p>c. Removal of adult worms</p>

Ocular protozoal infections	Diagnosis	Treatment
Loiasis		<ul style="list-style-type: none"> a. Surgical removal of the worm under the skin or across the eye b. Diethylcarbamazine (DEC) is the drug of choice c. Albendazole is given to patients not responding to DEC
Dirofilariasis		<ul style="list-style-type: none"> a. Surgical removal of the worm b. DEC is given for medical treatment
Gnathostomiasis	<ul style="list-style-type: none"> Identification of the removed worm Serology to detect antibodies 	<ul style="list-style-type: none"> a. Surgical removal of worm
Thelaziasis	<ul style="list-style-type: none"> b. Identification of worm removed from conjunctival sac c. Eggs and larvae may be seen by microscopy of tears and other eye secretions 	<ul style="list-style-type: none"> Removal of worm
Toxocariasis	<ul style="list-style-type: none"> Histological demonstration of toxocara larva Serology by ELISA 	<ul style="list-style-type: none"> d. Topical and systemic corticosteroids are useful in managing intraocular inflammation e. Role of anthelmintic therapy in ocular toxocariasis remains unclear f. Recommended drugs for systemic toxocariasis are: g. Albendazole 400mg given twice daily for 7-14 days h. Diethylcarbamazine - given at 3-4 mg/kg/day for 21 days
Ocular cestode infections		
Cysticercosis	<ul style="list-style-type: none"> Imaging with MRI, CT scan and USG Serology 	<ul style="list-style-type: none"> a. Antiparasitic drugs – Albendazole 15mg/kg/day for 4 weeks, Praziquantel b. Corticosteroids in tapering dose over a period of 1 month c. Surgery
Echinococcosis	<ul style="list-style-type: none"> Imaging 	<ul style="list-style-type: none"> a. Surgical removal b. Albendazole is given as an anti-infective prophylaxis
Ocular trematode infections		
Fascioliasis	<ul style="list-style-type: none"> Detection of adult worm in the eye Other features such as eosinophilia, stool examination and serology may help 	<ul style="list-style-type: none"> a. Surgical removal of worm b. Triclabendazole 10mg/kg body weight as a single dose

Ocular protozoal infections	Diagnosis	Treatment
Schistosomiasis	Stool and urine examination for detection of parasitic eggs or detection of eggs or cercariae in eye Serology	Praziquantel 40-60mg/kg per day in two to three divided doses for one day
Phlophthalmosis	Identification of the remnants of parasites aspirated from such cases	a. Conjunctival nodules heal spontaneously and anterior chamber nodules can be treated with topical/ oral corticosteroids. b. Surgical removal is recommended in cases having large nodules
Ocular infections by ectoparasites		
Myiasis	a. Identification of the maggots b. Visualizing the migratory tracks along sub retina	a. Surgical removal of the maggots b. Ivermectin 150-200 µg/kg of body weight in single dose c. Steroid therapy
Phthiriasis palpebrum	a. Excoriation marks along with small erythematous papules b. Nits can be found at the base of eyelashes	a. Eyelid disease is treated by petrolatum b. Non-eyelid involvement may be treated with lindane, permethrin, pyrethrin or malathion
Tick infestation	Biomicroscopy may reveal ticks	Removal of ticks

Table 2. Diagnosis and treatment of various ocular parasitic infections

Author details

Nancy Malla* and Kapil Goyal

*Address all correspondence to: drmallanancy@gmail.com

Department of Medical Parasitology, Postgraduate Institute of Medical Education and Research, Chandigarh, India

References

- [1] Klotz SA, Penn CC, Negvesky GJ, Butrus SI. Fungal and parasitic infections of the eye. *Clinical microbiology reviews*. 2000;13(4):662-85.

- [2] Chawla A, Armstrong M, Carley F. Acanthamoeba keratitis – an increasing incidence. *Contact lens & anterior eye : the journal of the British Contact Lens Association*. 2014;37(2):120.
- [3] Lorenzo-Morales J, Martin-Navarro CM, Lopez-Arencibia A, Arnalich-Montiel F, Pinero JE, Valladares B. Acanthamoeba keratitis: an emerging disease gathering importance worldwide? *Trends in parasitology*. 2013;29(4):181-7.
- [4] Montoya JG, Liesenfeld O. Toxoplasmosis. *Lancet*. 2004;363(9425):1965-76.
- [5] Sharma S, Pasricha G, Das D, Aggarwal RK. Acanthamoeba keratitis in non-contact lens wearers in India: DNA typing-based validation and a simple detection assay. *Archives of ophthalmology*. 2004;122(10):1430-4.
- [6] Gopinathan U, Sharma S, Garg P, Rao GN. Review of epidemiological features, microbiological diagnosis and treatment outcome of microbial keratitis: experience of over a decade. *Indian journal of ophthalmology*. 2009;57(4):273-9.
- [7] Sharma S, Garg P, Rao GN. Patient characteristics, diagnosis, and treatment of non-contact lens related Acanthamoeba keratitis. *The British journal of ophthalmology*. 2000;84(10):1103-8.
- [8] Nimir AR, Saliem A, Ibrahim IA. Ophthalmic parasitosis: a review article. *Interdisciplinary Perspectives on Infectious Diseases*. 2012;2012:587402.
- [9] Joseph J, Vemuganti GK, Sharma S. Microsporidia: emerging ocular pathogens. *Indian journal of medical microbiology*. 2005;23(2):80-91.
- [10] Malla N, Aggarwal AK, Mahajan RC. A serological study of human toxocariasis in north India. *The National medical journal of India*. 2002;15(3):145-7.
- [11] Fomda BA, Ahmad Z, Khan NN, Tanveer S, Wani SA. Ocular toxocariasis in a child: a case report from Kashmir, north India. *Indian journal of medical microbiology*. 2007;25(4):411-2.
- [12] Prabhakar SK, Vijaykumar GS, Mahesh BS, Shanthamallappa. Human ocular thelaziasis: a case report from Karnataka. *Indian journal of medical microbiology*. 2015;33(2):324-5.
- [13] Sachdeva RS, Manchanda SK, Abrol S, Wadhwa SC, Ramachandran KA. Freely mobile cysticercus in the anterior chamber. *Indian journal of ophthalmology*. 1995;43(3):135-6.
- [14] Dalimi A, Jabarvand M. Fasciola hepatica in the human eye. *Transactions of the Royal Society of Tropical Medicine and Hygiene*. 2005;99(10):798-800.
- [15] Joshi G, Parchand S, Dogra MR, Gupta PK, Khurana S, Gupta V, et al. Live juvenile strobilate tapeworm in the anterior chamber of the human eye. *Archives of ophthalmology*. 2012;130(11):1464-6.

- [16] Francesconi F, Lupi O. Myiasis. *Clinical microbiology reviews*. 2012;25(1):79-105.
- [17] Khurana S, Biswal M, Bhatti HS, Pandav SS, Gupta A, Chatterjee SS, et al. Ophthalmomyiasis: three cases from North India. *Indian journal of medical microbiology*. 2010;28(3):257-61.
- [18] Sulyok M, Rozsa L, Bodo I, Tappe D, Hardi R. Ocular pentastomiasis in the Democratic Republic of the Congo. *PLoS neglected tropical diseases*. 2014;8(7):e3041.
- [19] Tan SY, Liu SW, Jiang SB. HIV/AIDS and ocular complications. *International Journal of Ophthalmology*. 2009;2(2):95-105.
- [20] Couture S, Agrawal R, Woods K, Lockwood D, Pavesio CE, Addison PKF. A case of panuveitis with hypopyon due to presumed ocular leishmaniasis in a HIV patient. *Journal of Ophthalmic Inflammation and Infection*. 2014;4(21):1-5.
- [21] Bacon AS, Dart JK, Ficker LA, Matheson MM, Wright P. Acanthamoeba keratitis. The value of early diagnosis. *Ophthalmology*. 1993;100(8):1238-43.
- [22] Lalitha P, Lin CC, Srinivasan M, Mascarenhas J, Prajna NV, Keenan JD, et al. Acanthamoeba keratitis in South India: a longitudinal analysis of epidemics. *Ophthalmic Epidemiology*. 2012;19(2):111-5.
- [23] Lowder CY. Ocular microsporidiosis. *International ophthalmology clinics*. 1993;33(1):145-51.
- [24] Lim SJ, Lee SE, Kim SH, Hong SH, You YS, Kwon OW, et al. Prevalence of *Toxoplasma gondii* and *Toxocara canis* among patients with uveitis. *Ocular immunology and inflammation*. 2014;22(5):360-6.
- [25] Otranto D, Eberhard ML. Zoonotic helminths affecting the human eye. *Parasites & vectors*. 2011;4:41.
- [26] Hirst LW. Ocular infections – diagnosis. *Australian family physician*. 1991;20(2):133-4, 7-45, 49.
- [27] Rao NA. A laboratory approach to rapid diagnosis of ocular infections and prospects for the future. *American journal of ophthalmology*. 1989;107(3):283-91.
- [28] Khurana S, Singh G, Bhatti HS, Malla N. Human subcutaneous dirofilariasis in India: a report of three cases with brief review of literature. *Indian journal of medical microbiology*. 2010;28(4):394-6.
- [29] Cortez RT, Ramirez G, Collet L, Giuliari GP. Ocular parasitic diseases: a review on toxocariasis and diffuse unilateral subacute neuroretinitis. *Journal of pediatric ophthalmology and strabismus*. 2011;48(4):204-12.
- [30] Sharma M, Beke N, Khurana S, Bhatti HS, Sehgal R, Malla N. An Ocular cysticercosis case: caused by Asian Genotype of *Taenia solium*. *Indian journal of Medical Microbiology*. 2015;33(4):583-585.

- [31] Hogan RN, Jakobiec FA. Molecular pathological diagnosis of ocular infections. *International ophthalmology clinics*. 1996;36(3):223-46.
- [32] Rathinam SR, Annamalai R, Biswas J. Intraocular parasitic infections. *Ocular immunology and inflammation*. 2011;19(5):327-36.
- [33] Pasricha G, Sharma S, Garg P, Aggarwal RK. Use of 18S rRNA gene-based PCR assay for diagnosis of acanthamoeba keratitis in non-contact lens wearers in India. *Journal of Clinical Microbiology*. 2003;41(7):3206-11.
- [34] Basu S, Sharma S, Kar S, Das T. DNA chip-assisted diagnosis of a previously unknown etiology of intermediate uveitis – *Toxoplasma gondii*. *Indian journal of ophthalmology*. 2010;58(6):535-7.
- [35] Sharma S. Diagnosis of infectious diseases of the eye. *Eye*. 2012;26(2):177-84.
- [36] Rathinam SR, Arya LK, Usha KR, Prajna L, Tandon V. Novel etiological agent: molecular evidence for trematode-induced anterior uveitis in children. *Archives of ophthalmology*. 2012;130(11):1481-4.
- [37] Nath R, Gogoi R, Bordoloi N, Gogoi T. Ocular dirofilariasis. *Indian journal of Pathology & Microbiology*. 2010;53(1):157-9.
- [38] Pushker N, Bajaj MS, Chandra M, Neena. Ocular and orbital cysticercosis. *Acta ophthalmologica Scandinavica*. 2001;79(4):408-13.
- [39] Gomez Morales A, Croxatto JO, Crovetto L, Ebner R. Hydatid cysts of the orbit. A review of 35 cases. *Ophthalmology*. 1988;95(8):1027-32.
- [40] Malla N, Goyal M, Pillai P, Ganguly NK, Mahajan RC. Experimental ocular toxoplasmosis with RH strain of *Toxoplasma gondii*. *Japanese journal of experimental medicine*. 1988;58(6):279-81.
- [41] Takayanagi TH, Akao N, Suzuki R, Tomoda M, Tsukidate S, Fujita K. New animal model for human ocular toxocariasis: ophthalmoscopic observation. *The British journal of ophthalmology*. 1999;83(8):967-72.
- [42] Malhotra A, Minja FJ, Crum A, Burrowes D. Ocular anatomy and cross-sectional imaging of the eye. *Semin Ultrasound CT MR*. 2011;32(1):2-13.
- [43] Kaplan HJ. Anatomy and function of the eye. *Chemical Immunology and Allergy*. 2007;92:4-10.
- [44] Paalman MH. Anatomy in the eye. *Anatomical Record*. 2000;261(6):221.
- [45] Kolb H. *Gross Anatomy of the Eye*. 2005 May 1 [Updated 2007 May 1]. In: Kolb H, Fernandez E, Nelson R, editors. *Webvision: The Organization of the Retina and Visual System* [Internet]. Salt Lake City (UT): University of Utah Health Sciences Center; 1995. Available from: <http://www.ncbi.nlm.nih.gov/books/NBK11534/>
- [46] Iveson-Iveson J. Anatomy and physiology: the eye. *Nursing Mirror*. 1979;148(8):31-3.

- [47] Shitole S, Jakkal T, Khaire B. Inverse Bell's phenomenon: rare ophthalmic finding following ptosis surgery. *Journal of clinical and diagnostic research: JCDR*. 2015;9(3):ND01-2.
- [48] Kageyama M, Nakatsuka K, Yamaguchi T, Owen RL, Shimada T. Ocular defense mechanisms with special reference to the demonstration and functional morphology of the conjunctiva-associated lymphoid tissue in Japanese monkeys. *Archives of Histology and Cytology*. 2006;69(5):311-22.
- [49] Lerman S. Free radical damage and defense mechanisms in the ocular lens. *Lens and eye toxicity research*. 1992;9(1):9-24.
- [50] Bito LZ. Species differences in the responses of the eye to irritation and trauma: a hypothesis of divergence in ocular defense mechanisms, and the choice of experimental animals for eye research. *Experimental Eye Research*. 1984;39(6):807-29.
- [51] Chandler JW, Gillette TE. Immunologic defense mechanisms of the ocular surface. *Ophthalmology*. 1983;90(6):585-91.
- [52] Lemp MA, Blackman HJ. Ocular surface defense mechanisms. *Annals of ophthalmology*. 1981;13(1):61-3.
- [53] McDermott AM. Defensins and other antimicrobial peptides at the ocular surface. *The ocular surface*. 2004;2(4):229-47.
- [54] Cunningham ET, Jr., Belfort R, Jr., Muccioli C, Arevalo JF, Zierhut M. Ocular toxoplasmosis. *Ocular immunology and inflammation*. 2015;23(3):191-3.
- [55] Kijlstra A, Petersen E. Epidemiology, pathophysiology, and the future of ocular toxoplasmosis. *Ocular immunology and inflammation*. 2014;22(2):138-47.
- [56] Robert-Gangneux F, Darde ML. Epidemiology of and diagnostic strategies for toxoplasmosis. *Clinical microbiology reviews*. 2012;25(2):264-96.
- [57] Petersen E, Kijlstra A, Stanford M. Epidemiology of ocular toxoplasmosis. *Ocular immunology and inflammation*. 2012;20(2):68-75.
- [58] Ho-Yen DO. Epidemiology of toxoplasmosis. *Archives of pediatrics*. 2003;10(Suppl 1):3-4.
- [59] Lachenmaier SM, Deli MA, Meissner M, Liesenfeld O. Intracellular transport of *Toxoplasma gondii* through the blood-brain barrier. *Journal of neuroimmunology*. 2011;232(1-2):119-30.
- [60] Peixoto-Rangel AL, Miller EN, Castellucci L, Jamieson SE, Peixe RG, Elias Lde S, et al. Candidate gene analysis of ocular toxoplasmosis in Brazil: evidence for a role for toll-like receptor 9 (TLR9). *Memorias do Instituto Oswaldo Cruz*. 2009;104(8):1187-90.
- [61] Pleyer U, Schluter D, Manz M. Ocular toxoplasmosis: recent aspects of pathophysiology and clinical implications. *Ophthalmic Research*. 2014;52(3):116-23.

- [62] Holland GN. Ocular toxoplasmosis: a global reassessment. Part II: disease manifestations and management. *American journal of ophthalmology*. 2004;137(1):1-17.
- [63] O'Connor GR. Manifestations and management of ocular toxoplasmosis. *Bulletin of the New York Academy of Medicine*. 1974;50(2):192-210.
- [64] Park YH, Nam HW. Clinical features and treatment of ocular toxoplasmosis. *The Korean journal of parasitology*. 2013;51(4):393-9.
- [65] Harper TW, Miller D, Schiffman JC, Davis JL. Polymerase chain reaction analysis of aqueous and vitreous specimens in the diagnosis of posterior segment infectious uveitis. *American journal of ophthalmology*. 2009;147(1):140-7 e2.
- [66] Cassaing S, Bessieres MH, Berry A, Berrebi A, Fabre R, Magnaval JF. Comparison between two amplification sets for molecular diagnosis of toxoplasmosis by real-time PCR. *Journal of Clinical Microbiology*. 2006;44(3):720-4.
- [67] Robert-Gangneux F, Sterkers Y, Yera H, Accoceberry I, Menotti J, Cassaing S, et al. Molecular diagnosis of toxoplasmosis in immunocompromised patients: a 3-year multicenter retrospective study. *Journal of Clinical Microbiology*. 2015;53(5):1677-84.
- [68] Filisetti D, Sterkers Y, Brenier-Pinchart MP, Cassaing S, Dalle F, Delhaes L, et al. Multicentric comparative assessment of the bio-evolution *Toxoplasma gondii* detection kit with eight laboratory-developed PCR assays for molecular diagnosis of congenital toxoplasmosis. *Journal of Clinical Microbiology*. 2015;53(1):29-34.
- [69] Hashoosh DA, Majeed IA. Comparison of two assays in the diagnosis of toxoplasmosis: immunological and molecular. *Eastern Mediterranean Health Journal*. 2014;20(1):46-50.
- [70] Remington JS, Thulliez P, Montoya JG. Recent developments for diagnosis of toxoplasmosis. *Journal of Clinical Microbiology*. 2004;42(3):941-5.
- [71] Bou G, Figueroa MS, Marti-Belda P, Navas E, Guerrero A. Value of PCR for detection of *Toxoplasma gondii* in aqueous humor and blood samples from immunocompetent patients with ocular toxoplasmosis. *Journal of Clinical Microbiology*. 1999;37(11):3465-8.
- [72] Garweg JG, de Groot-Mijnes JD, Montoya JG. Diagnostic approach to ocular toxoplasmosis. *Ocular Immunology and Inflammation*. 2011;19(4):255-61.
- [73] Khurana S, Bagga R, Aggarwal A, Lyngdoh V, Shivapriya, Diddi K, et al. Serological screening for antenatal toxoplasma infection in India. *Indian Journal of Medical Microbiology*. 2010;28(2):143-6.
- [74] Singh MP, Dubey ML, Sud A, Malla N. Antibody response to *Toxoplasma gondii* in saliva samples from human immunodeficiency virus-infected patients. *British Journal of Biomedical Science*. 2005;62(2):81-4.

- [75] Zargar AH, Masoodi SR, Laway BA, Sofi BA, Wani AI. Seroprevalence of toxoplasmosis in women with repeated abortions in Kashmir. *Journal of Epidemiology & Community Health*. 1998;52(2):135-6.
- [76] Thokar MA, Malla N, Wattal C. Serological study of patients clinically suspected to have toxoplasmosis in Kashmir. *Indian Journal of Medical Research*. 1988;88:29-34.
- [77] Delair E, Monnet D, Grabar S, Dupouy-Camet J, Yera H, Brezin AP. Respective roles of acquired and congenital infections in presumed ocular toxoplasmosis. *American Journal of Ophthalmology*. 2008;146(6):851-5.
- [78] de Boer JH, Luyendijk L, Rothova A, Kijlstra A. Analysis of ocular fluids for local antibody production in uveitis. *The British Journal of Ophthalmology*. 1995;79(6):610-6.
- [79] Garweg JG, Jacquier P, Boehnke M. Early aqueous humor analysis in patients with human ocular toxoplasmosis. *Journal of Clinical Microbiology*. 2000;38(3):996-1001.
- [80] Lima GS, Saraiva PG, Saraiva FP. Current therapy of acquired ocular toxoplasmosis: a review. *Journal of Ocular Pharmacology and Therapeutics : The Official Journal of the Association for Ocular Pharmacology and Therapeutics*. 2015;31(9):511-7.
- [81] Holland GN, Lewis KG. An update on current practices in the management of ocular toxoplasmosis. *American Journal of Ophthalmology*. 2002;134(1):102-14.
- [82] Siddiqui R, Khan NA. Biology and pathogenesis of *Acanthamoeba*. *Parasites & Vectors*. 2012;5:6.
- [83] Bharathi JM, Srinivasan M, Ramakrishnan R, Meenakshi R, Padmavathy S, Lalitha PN. A study of the spectrum of *Acanthamoeba* keratitis: a three-year study at a tertiary eye care referral center in South India. *Indian Journal of Ophthalmology*. 2007;55(1):37-42.
- [84] Vaddavalli PK, Garg P, Sharma S, Sangwan VS, Rao GN, Thomas R. Role of confocal microscopy in the diagnosis of fungal and *Acanthamoeba* keratitis. *Ophthalmology*. 2011;118(1):29-35.
- [85] Winchester K, Mathers WD, Sutphin JE, Daley TE. Diagnosis of *Acanthamoeba* keratitis in vivo with confocal microscopy. *Cornea*. 1995;14(1):10-7.
- [86] Goldschmidt P, Degorge S, Benallaoua D, Saint-Jean C, Batellier L, Alouch C, et al. New tool for the simultaneous detection of 10 different genotypes of *Acanthamoeba* available from the American Type Culture Collection. *The British Journal of Ophthalmology*. 2009;93(8):1096-100.
- [87] Hauber S, Parkes H, Siddiqui R, Khan NA. The use of high-resolution (1)H nuclear magnetic resonance (NMR) spectroscopy in the clinical diagnosis of *Acanthamoeba*. *Parasitology Research*. 2011;109(6):1661-9.
- [88] Lorenzo-Morales J, Khan NA, Walochnik J. An update on *Acanthamoeba* keratitis: diagnosis, pathogenesis and treatment. *Parasite*. 2015;22:10.

- [89] Kumar R, Lloyd D. Recent advances in the treatment of *Acanthamoeba* keratitis. *Clinical Infectious Diseases: An Official Publication of the Infectious Diseases Society of America*. 2002;35(4):434-41.
- [90] Grayson M. Chagas disease. *Nature*. 2010;465(7301):S3.
- [91] Coura JR, Borges-Pereira J. Chagas disease: 100 years after its discovery. A systemic review. *Acta Tropica*. 2010;115(1-2):5-13.
- [92] Frohlich SJ, Mino de Kaspar H, Peran R, Vera de Bilbao N, Schinini A, Rojas de Arias A, et al. Intraocular involvement of Chagas disease (American trypanosomiasis). Studies in Paraguay/South America. *Der Ophthalmologe: Zeitschrift der Deutschen Ophthalmologischen Gesellschaft*. 1997;94(3):206-10.
- [93] Frohlich SJ, Mino de Kaspar H, Peran R, Rojas de Arias A, Sanchez Insfran N, Moreno Azorero R, et al. Eye involvement in Chagas disease (American trypanosomiasis). 1996/1997 studies in Paraguay. *Der Ophthalmologe: Zeitschrift der Deutschen Ophthalmologischen Gesellschaft*. 1998;95(3):168-71.
- [94] Bern C. Chagas' disease. *The New England Journal of Medicine*. 2015;373(5):456-66.
- [95] Morillo CA, Marin-Neto JA, Avezum A, Sosa-Estani S, Rassi A, Jr., Rosas F, et al. Randomized trial of benznidazole for chronic Chagas' cardiomyopathy. *The New England Journal of Medicine*. 2015;373(14):1295-306.
- [96] Chagas disease. Available at <http://www.nytimes.com/health/guides/disease/chagas-disease/overview.html>
- [97] Leishmaniasis. Available at: <http://www.who.int/mediacentre/factsheets/fs375/en/>
- [98] Badri Prasad B, Shakya A, Poonam L, Smriti K. Caruncular Leishmaniasis – an unusual case. *Orbit*. 2015;34(4):232-3.
- [99] Philips CA, Kalal CR, Kumar KN, Bihari C, Sarin SK. Simultaneous occurrence of ocular, disseminated mucocutaneous, and multivisceral involvement of leishmaniasis. *Case Reports in Infectious Diseases*. 2014;2014:837625.
- [100] Khalil EA, Musa AM, Younis BM, Elfaki ME, Zijlstra EE, Elhassan AM. Blindness following visceral leishmaniasis: a neglected post-kala-azar complication. *Tropical Doctor*. 2011;41(3):139-40.
- [101] Veraldi S, Bottini S, Curro N, Gianotti R. Leishmaniasis of the eyelid mimicking an infundibular cyst and review of the literature on ocular leishmaniasis. *International Journal of Infectious Diseases: IJID: Official Publication of the International Society for Infectious Diseases*. 2010;14(Suppl 3):e230-2.
- [102] Salvanos P, Kabanarou SA, Xirou T, Kourentis C, Feretis E. Proliferative vitreoretinopathy in a child with visceral leishmaniasis. *European Journal of Ophthalmology*. 2010;20(1):231-3.

- [103] Sadeghian G, Nilfroushzadeh MA, Moradi SH, Hanjani SH. Ocular leishmaniasis: a case report. *Dermatology Online Journal*. 2005;11(2):19.
- [104] el-Hassan AM, el-Sheikh EA, Eltoum IA, Ghalib HW, Ali MS, Zijlstra E, et al. Post-kala-azar anterior uveitis: demonstration of *Leishmania* parasites in the lesion. *Transactions of the Royal Society of Tropical Medicine and Hygiene*. 1991;85(4):471-3.
- [105] Dechant W, Rees PH, Kager PA, Klauss V, Adala H. Post kala-azar uveitis. *The British Journal of Ophthalmology*. 1980;64(9):680-3.
- [106] De Cock KM, Rees PH, Klauss V, Kasili EG, Kager PA, Schattenkerk JK. Retinal hemorrhages in kala-azar. *The American Journal of Tropical Medicine and Hygiene*. 1982;31(5):927-30.
- [107] Montero JA, Ruiz-Moreno JM, Sanchis E. Intraretinal hemorrhage associated with leishmaniasis. *Ophthalmic Surgery, Lasers & Imaging: The Official Journal of the International Society for Imaging in the Eye*. 2003;34(3):212-4.
- [108] Biswas J, Mani B, Bhende M. Spontaneous resolution of bilateral macular haemorrhage in a patient with kala-azar. *Eye*. 2000;14(Pt 2):244-6.
- [109] Mookerjee GC, Sen G, Chaudhuri MD, Chakraborty K. Acute kala-azar with haemorrhagic retinopathy. *Journal of the Indian Medical Association*. 1975;65(3):86-8.
- [110] Maude RJ, Ahmed BU, Rahman AH, Rahman R, Majumder MI, Menezes DB, et al. Retinal changes in visceral leishmaniasis by retinal photography. *BMC Infectious Diseases*. 2014;14:527.
- [111] Oliveira-Neto MP, Martins VJ, Mattos MS, Pirmez C, Brahin LR, Benchimol E. South American cutaneous leishmaniasis of the eyelids: report of five cases in Rio de Janeiro State, Brazil. *Ophthalmology*. 2000;107(1):169-72.
- [112] Chaudhry IA, Hylton C, DesMarchais B. Bilateral ptosis and lower eyelid ectropion secondary to cutaneous leishmaniasis. *Archives of Ophthalmology*. 1998;116(9):1244-5.
- [113] Yaghoobi R, Maraghi S, Bagherani N, Rafiei A. Cutaneous leishmaniasis of the lid: a report of nine cases. *Korean Journal of Ophthalmology: KJO*. 2010;24(1):40-3.
- [114] Baddini-Caramelli C, Matayoshi S, Moura EM, Araf D, Santo R, Voegels R, et al. Chronic dacryocystitis in American mucocutaneous leishmaniasis. *Ophthalmic Plastic and Reconstructive Surgery*. 2001;17(1):48-52.
- [115] Ferrari TC, Guedes AC, Orefice F, Genaro O, Pinheiro SR, Marra MA, et al. Isolation of *Leishmania* sp. from aqueous humor of a patient with cutaneous disseminated leishmaniasis and bilateral iridocyclitis (preliminary report). *Revista do Instituto de Medicina Tropical de Sao Paulo*. 1990;32(4):296-8.
- [116] Petersen CA, Greenlee MH. Neurologic Manifestations of *Leishmania* spp. *Infection. Journal of Neuroparasitology*. 2011;2:N110401.

- [117] Ozdemir Y, Kulacoglu S, Cosar CB, Onder F, Kural G. Ocular leishmaniasis. *Eye*. 1999;13(Pt 5):666-7.
- [118] el Hassan AM, Khalil EA, el Sheikh EA, Zijlstra EE, Osman A, Ibrahim ME. Post kala-azar ocular leishmaniasis. *Transactions of the Royal Society of Tropical Medicine and Hygiene*. 1998;92(2):177-9.
- [119] Leite RS, Souza NA, Barbosa AD, Ferreira AL, de Andrade AS. Evaluation of conjunctival swab as a mass-screening tool for molecular diagnosis of canine visceral leishmaniasis. *Parasitology Research*. 2015;114(6):2255-62.
- [120] Shirian S, Oryan A, Hatam GR, Panahi S, Daneshbod Y. Comparison of conventional, molecular, and immunohistochemical methods in diagnosis of typical and atypical cutaneous leishmaniasis. *Archives of Pathology & Laboratory Medicine*. 2014;138(2): 235-40.
- [121] Abrishami M, Soheilian M, Farahi A, Dowlati Y. Successful treatment of ocular leishmaniasis. *European Journal of Dermatology: EJD*. 2002;12(1):88-9.
- [122] Zadeh MM, Manshai K, Shaddel M, Oormazdi H. Ocular leishmaniasis. *Iranian Journal of Ophthalmology*. 2006;19(3):1-5.
- [123] World Malaria Report. 2014 (Available at: http://www.who.int/malaria/publications/world_malaria_report_2014/en/).
- [124] Sherwood JA. Progress toward understanding the pathogenesis of sequestration in falciparum malaria. *Blood Cells*. 1990;16(2-3):620-8.
- [125] Sherwood JA, Roberts DD, Spitalnik SL, Marsh K, Harvey EB, Miller LH, et al. Parasitized erythrocyte antigens and thrombospondin adhesion in the immunology and pathogenesis of falciparum malaria. *Transactions of the Association of American Physicians*. 1986;99:206-13.
- [126] Lagraulet J, Robet C, Bard J. The ocular complications of malaria. *Bulletin de la Société de pathologie exotique*. 1967;60(3):217-21.
- [127] Bhattacharjya BP, Guha GS. Ocular manifestations in malaria. *Indian Medical Gazette*. 1946;81:79.
- [128] Ross JV. Ocular complications associated with malaria. *Eye Ear Nose Throat Monthly*. 1953;32(12):707-11.
- [129] Schemann JF, Doumbo O, Malvy D, Traore L, Kone A, Sidibe T, et al. Ocular lesions associated with malaria in children in Mali. *The American Journal of Tropical Medicine and Hygiene*. 2002;67(1):61-3.
- [130] Maude RJ, Hassan MU, Beare NA. Severe retinal whitening in an adult with cerebral malaria. *The American Journal of Tropical Medicine and Hygiene*. 2009;80(6):881.
- [131] Looareesuwan S, Warrell DA, White NJ, Chanthavanich P, Warrell MJ, Chantaratherakitti S, et al. Retinal hemorrhage, a common sign of prognostic significance in cere-

- bral malaria. *The American Journal of Tropical Medicine and Hygiene*. 1983;32(5):911-5.
- [132] Beare NA, Taylor TE, Harding SP, Lewallen S, Molyneux ME. Malarial retinopathy: a newly established diagnostic sign in severe malaria. *The American Journal of Tropical Medicine and Hygiene*. 2006;75(5):790-7.
- [133] Wongsrichanalai C, Barcus MJ, Muth S, Sutamihardja A, Wernsdorfer WH. A review of malaria diagnostic tools: microscopy and rapid diagnostic test (RDT). *The American Journal of Tropical Medicine and Hygiene*. 2007;77(6 Suppl):119-27.
- [134] Hidayat AA, Nalbandian RM, Sammons DW, Fleischman JA, Johnson TE. The diagnostic histopathologic features of ocular malaria. *Ophthalmology*. 1993;100(8):1183-6.
- [135] Lewallen S, Taylor TE, Molyneux ME, Wills BA, Courtright P. Ocular fundus findings in Malawian children with cerebral malaria. *Ophthalmology*. 1993;100(6):857-61.
- [136] Nwosu S. Ocular complications of malaria treatment. *Nigerian Journal of Clinical Practice*. 2012;15(1):95-7.
- [137] Beare NA, Southern C, Chalira C, Taylor TE, Molyneux ME, Harding SP. Prognostic significance and course of retinopathy in children with severe malaria. *Archives of Ophthalmology*. 2004;122(8):1141-7.
- [138] Keeling P. Five questions about microsporidia. *PLoS Pathogens*. 2009;5(9):e1000489.
- [139] Lowder CY, McMahon JT, Meisler DM, Dodds EM, Calabrese LH, Didier ES, et al. Microsporidial keratoconjunctivitis caused by *Septata intestinalis* in a patient with acquired immunodeficiency syndrome. *American Journal of Ophthalmology*. 1996;121(6):715-7.
- [140] Shadduck JA, Meccoli RA, Davis R, Font RL. Isolation of a microsporidian from a human patient. *The Journal of Infectious Diseases*. 1990;162(3):773-6.
- [141] Diesenhouse MC, Wilson LA, Corrent GF, Visvesvara GS, Grossniklaus HE, Bryan RT. Treatment of microsporidial keratoconjunctivitis with topical fumagillin. *American Journal of Ophthalmology*. 1993;115(3):293-8.
- [142] Das S, Wallang BS, Sharma S, Bhadange YV, Balne PK, Sahu SK. The efficacy of corneal debridement in the treatment of microsporidial keratoconjunctivitis: a prospective randomized clinical trial. *American Journal of Ophthalmology*. 2014;157(6):1151-5.
- [143] Sanjay S. Clinical trial of 0.02% polyhexamethylene biguanide versus placebo in the treatment of microsporidial keratoconjunctivitis. *American Journal of Ophthalmology*. 2011;151(1):183.
- [144] Savioli L, Smith H, Thompson A. *Giardia* and *Cryptosporidium* join the "Neglected Diseases Initiative". *Trends in Parasitology*. 2006;22(5):203-8.

- [145] Halliez MC, Buret AG. Extra-intestinal and long term consequences of *Giardia duodenalis* infections. *World Journal of Gastroenterology*. 2013;19(47):8974-85.
- [146] Corsi A, Nucci C, Knafelz D, Bulgarini D, Di Iorio L, Polito A, et al. Ocular changes associated with *Giardia lamblia* infection in children. *The British Journal of Ophthalmology*. 1998;82(1):59-62.
- [147] Gardner TB, Hill DR. Treatment of giardiasis. *Clinical Microbiology Reviews*. 2001;14(1):114-28.
- [148] Onchocerciasis. (Available: <http://www.who.int/mediacentre/factsheets/fs374/en/>).
- [149] Udall DN. Recent updates on onchocerciasis: diagnosis and treatment. *Clinical Infectious Diseases: An Official Publication of the Infectious Diseases Society of America*. 2007;44(1):53-60.
- [150] Parasites – Onchocerciasis. (Available at: <http://www.cdc.gov/parasites/onchocerciasis/epi.html>).
- [151] Hall LR, Pearlman E. Pathogenesis of onchocercal keratitis (River blindness). *Clinical Microbiology Reviews*. 1999;12(3):445-53.
- [152] Higazi TB, Filiano A, Katholi CR, Dadzie Y, Remme JH, Unnasch TR. Wolbachia endosymbiont levels in severe and mild strains of *Onchocerca volvulus*. *Molecular and Biochemical Parasitology*. 2005;141(1):109-12.
- [153] Brattig NW. Pathogenesis and host responses in human onchocerciasis: impact of *Onchocerca filariae* and Wolbachia endobacteria. *Microbes and Infection*. 2004;6(1):113-28.
- [154] Tamarozzi F, Halliday A, Gentil K, Hoerauf A, Pearlman E, Taylor MJ. Onchocerciasis: the role of Wolbachia bacterial endosymbionts in parasite biology, disease pathogenesis, and treatment. *Clinical Microbiology Reviews*. 2011;24(3):459-68.
- [155] Harnett W. DNA-based detection of *onchocerca volvulus*. *Transactions of the Royal Society of Tropical Medicine and Hygiene*. 2002;96(Suppl 1):S231-4.
- [156] Boatman BA, Toe L, Alley ES, Nagelkerke NJ, Borsboom G, Habbema JD. Detection of *Onchocerca volvulus* infection in low prevalence areas: a comparison of three diagnostic methods. *Parasitology*. 2002;125(Pt 6):545-52.
- [157] Pischke S, Buttner DW, Liebau E, Fischer P. An internal control for the detection of *Onchocerca volvulus* DNA by PCR-ELISA and rapid detection of specific PCR products by DNA Detection Test Strips. *Tropical Medicine & International Health*. 2002;7(6):526-31.
- [158] Ayong LS, Tume CB, Wembe FE, Simo G, Asonganyi T, Lando G, et al. Development and evaluation of an antigen detection dipstick assay for the diagnosis of human onchocerciasis. *Tropical Medicine & International Health*. 2005;10(3):228-33.

- [159] Nde PN, Pogonka T, Bradley JE, Titanji VP, Lucius R. Sensitive and specific serodiagnosis of onchocerciasis with recombinant hybrid proteins. *The American Journal of Tropical Medicine and Hygiene*. 2002;66(5):566-71.
- [160] Onchocerciasis. Available at <http://www.cdc.gov/parasites/onchocerciasis/>
- [161] Onchocerciasis. (Available at: http://www.cdc.gov/parasites/onchocerciasis/health_professionals/).
- [162] Parasites – Loiasis. (Available at: <http://www.cdc.gov/parasites/loiasis/epi.html>).
- [163] Kelly-Hope LA, Bockarie MJ, Molyneux DH. Loa loa ecology in central Africa: role of the Congo River system. *PLoS Neglected Tropical Diseases*. 2012;6(6):e1605.
- [164] Bhedasgaonkar S, Baile RB, Nadkarni S, Jakkula G, Gogri P. Loa loa macrofilariasis in the eyelid: case report of the first periocular subcutaneous manifestation in India. *Journal of Parasitic Diseases*. 2011;35(2):230-1.
- [165] Cho HY, Lee YJ, Shin SY, Song HO, Ahn MH, Ryu JS. Subconjunctival Loa loa with Calabar swelling. *Journal of Korean Medical Science*. 2008;23(4):731-3.
- [166] Dupont A, Zue-N'dong J, Pinder M. Common occurrence of amicrofilaraemic Loa loa filariasis within the endemic region. *Transactions of the Royal Society of Tropical Medicine and Hygiene*. 1988;82(5):730.
- [167] Geldelman D, Blumberg R, Sadun A. Ocular Loa loa with cryoprobe extraction of subconjunctival worm. *Ophthalmology*. 1984;91(3):300-3.
- [168] Klion AD, Vijaykumar A, Oei T, Martin B, Nutman TB. Serum immunoglobulin G4 antibodies to the recombinant antigen, Ll-SXP-1, are highly specific for Loa loa infection. *The Journal of Infectious Diseases*. 2003;187(1):128-33.
- [169] Boussinesq M. Loiasis. *Annals of Tropical Medicine and Parasitology*. 2006;100(8):715-31.
- [170] Loiasis. Available at: <http://www.cdc.gov/parasites/loiasis/treatment.html> (Accessed on 30 March 2016).
- [171] Kalogeropoulos CD, Stefaniotou MI, Gorgoli KE, Papadopoulou CV, Pappa CN, Paschidis CA. Ocular dirofilariasis: a case series of 8 patients. *Middle East African Journal of Ophthalmology*. 2014;21(4):312-6.
- [172] Sahdev SI, Sureka SP, Sathe PA, Agashe R. Ocular dirofilariasis: still in the dark in western India? *Journal of Postgraduate Medicine*. 2012;58(3):227-8.
- [173] Sekhar HS, Srinivasa H, Batru RR, Mathai E, Shariff S, Macaden RS. Human ocular dirofilariasis in Kerala Southern India. *Indian Journal of Pathology & Microbiology*. 2000;43(1):77-9.
- [174] Font RL, Neafie RC, Perry HD. Subcutaneous dirofilariasis of the eyelid and ocular adnexa. Report of six cases. *Archives of Ophthalmology*. 1980;98(6):1079-82.

- [175] Gorezis S, Psilla M, Asproudis I, Peschos D, Papadopoulou C, Stefaniotou M. Intravitreal dirofilariasis: a rare ocular infection. *Orbit*. 2006;25(1):57-9.
- [176] Perera L, Perez-Arellano JL, Cordero M, Simon F, Muro A. Utility of antibodies against a 22 kD molecule of *Dirofilaria immitis* in the diagnosis of human pulmonary dirofilariasis. *Tropical Medicine & International Health*. 1998;3(2):151-5.
- [177] Dirofilariasis. Available at: <http://www.cdc.gov/parasites/dirofilariasis/faqs.html> (Accessed On 30 March 2016).
- [178] Mittal M, Sathish KR, Bhatia PG, Chidamber BS. Ocular dirofilariasis in Dubai, UAE. *Indian Journal of Ophthalmology*. 2008;56(4):325-6.
- [179] Diaz JH. Gnathostomiasis: an emerging infection of raw fish consumers in *Gnathostoma* nematode-endemic and nonendemic countries. *Journal of Travel Medicine*. 2015;22(5):318-24.
- [180] Wiwanitkit V. Gnathostomiasis and sushi ingestion. *American Journal of Dermatopathology*. 2012;34(6):675.
- [181] Sujata DN, Renu BS. Intraocular gnathostomiasis from coastal part of Maharashtra. *Tropical Parasitology*. 2013;3(1):82-4.
- [182] Pillai GS, Kumar A, Radhakrishnan N, Maniyelil J, Shafi T, Dinesh KR, et al. Intraocular gnathostomiasis: report of a case and review of literature. *The American Journal of Tropical Medicine and Hygiene*. 2012;86(4):620-3.
- [183] Bhattacharjee H, Das D, Medhi J. Intravitreal gnathostomiasis and review of literature. *Retina*. 2007;27(1):67-73.
- [184] Buppajarntham A, Apisarnthanarak A, Khawcharoenporn T, Rutjanawech S, Mundy LM. Asymptomatic eosinophilia due to gnathostomiasis. *International Journal of Infectious Diseases: IJID: Official Publication of the International Society for Infectious Diseases*. 2014;23:14-5.
- [185] Saksirisampant W, Chawengkiattikul R, Kraivichain K, Nuchprayoon S. Specific IgE antibody responses to somatic and excretory-secretory antigens of third stage *G. spinigerum* larvae in human gnathostomiasis. *Journal of the Medical Association of Thailand*. 2001;84(Suppl 1):S173-81.
- [186] Saenseeha S, Penchom J, Yamasaki H, Laummaunwai P, Tayapiwatana C, Kitkhuande A, et al. A dot-ELISA test using a *Gnathostoma spinigerum* recombinant matrix metalloproteinase protein for the serodiagnosis of human gnathostomiasis. *The Southeast Asian Journal of Tropical Medicine and Public health*. 2014;45(5):990-6.
- [187] Laummaunwai P, Sawanyawisuth K, Intapan PM, Chotmongkol V, Wongkham C, Maleewong W. Evaluation of human IgG class and subclass antibodies to a 24 kDa antigenic component of *Gnathostoma spinigerum* for the serodiagnosis of gnathostomiasis. *Parasitology Research*. 2007;101(3):703-8.

- [188] Herman JS, Chiodini PL. Gnathostomiasis, another emerging imported disease. *Clinical Microbiology Reviews*. 2009;22(3):484-92.
- [189] Anantaphruti MT. ELISA for diagnosis of gnathostomiasis using antigens from *Gnathostoma doloresi* and *G. spinigerum*. *The Southeast Asian Journal of Tropical Medicine and Public Health*. 1989;20(2):297-304.
- [190] Maleewong W, Morakote N, Thamasonthi W, Charuchinda K, Tesana S, Khamboonruang C. Serodiagnosis of human gnathostomiasis. *The Southeast Asian Journal of Tropical Medicine and Public Health*. 1988;19(2):201-5.
- [191] Nawa Y, Katchanov J, Yoshikawa M, Rojekittikhun W, Dekumyoy P, Kusolusuk T, et al. Ocular Gnathostomiasis: a comprehensive review. *J Trop Med Parasitol*. 2010;33:77-86.
- [192] Joseph A, Joseph A. Ocular thelaziasis (a case report). *Indian Journal of Ophthalmology*. 1985;33(2):113-4.
- [193] Yospaiboon Y, Sithithavorn P, Maleewong V, Ukosanakarn U, Bhaibulaya M. Ocular thelaziasis in Thailand: a case report. *Journal of the Medical Association of Thailand*. 1989;72(8):469-73.
- [194] Thelaziasis. Available at: <http://www.cdc.gov/dpdx/thelaziasis/tx.html>
- [195] Jee D, Kim KS, Lee WK, Kim W, Jeon S. Clinical features of ocular toxocariasis in adult Korean patients. *Ocular Immunology and Inflammation*. 2016;24(2):207-16.
- [196] Yokoi K, Goto H, Sakai J, Usui M. Clinical features of ocular toxocariasis in Japan. *Ocular Immunology and Inflammation*. 2003;11(4):269-75.
- [197] Zhou M, Chang Q, Gonzales JA, Chen Q, Zhang Y, Huang X, et al. Clinical characteristics of ocular toxocariasis in Eastern China. *Graefes archive for clinical and experimental ophthalmology = Albrecht von Graefes Archiv fur klinische und experimentelle Ophthalmologie*. 2012;250(9):1373-8.
- [198] Woodhall D, Starr MC, Montgomery SP, Jones JL, Lum F, Read RW, et al. Ocular toxocariasis: epidemiologic, anatomic, and therapeutic variations based on a survey of ophthalmic subspecialists. *Ophthalmology*. 2012;119(6):1211-7.
- [199] Centers for Disease C, Prevention. Ocular toxocariasis – United States, 2009-2010. *MMWR Morbidity and Mortality Weekly Report*. 2011;60(22):734-6.
- [200] Ahn SJ, Ryoo NK, Woo SJ. Ocular toxocariasis: clinical features, diagnosis, treatment, and prevention. *Asia Pacific Allergy*. 2014;4(3):134-41.
- [201] Arevalo JF, Espinoza JV, Arevalo FA. Ocular toxocariasis. *Journal of Pediatric Ophthalmology and Strabismus*. 2013;50(2):76-86.

- [202] Ament CS, Young LH. Ocular manifestations of helminthic infections: onchocerciasis, cysticercosis, toxocariasis, and diffuse unilateral subacute neuroretinitis. *International Ophthalmology Clinics*. 2006;46(2):1-10.
- [203] Teyssoit N, Cassoux N, Lehoang P, Bodaghi B. Fuchs heterochromic cyclitis and ocular toxocariasis. *American Journal of Ophthalmology*. 2005;139(5):915-6.
- [204] Stewart JM, Cubillan LD, Cunningham ET, Jr. Prevalence, clinical features, and causes of vision loss among patients with ocular toxocariasis. *Retina*. 2005;25(8):1005-13.
- [205] Martinez-Pulgarin DF, Munoz-Urbano M, Gomez-Suta LD, Delgado OM, Rodriguez-Morales AJ. Ocular toxocariasis: new diagnostic and therapeutic perspectives. *Recent Patents on Anti-Infective Drug Discovery*. 2015;10(1):35-41.
- [206] Lee TH, Ji YS, Lee SH. ELISA-confirmed bilateral ocular toxocariasis with different features. *Optometry and Vision Science: Official Publication of the American Academy of Optometry*. 2015;92(8):e176-9.
- [207] Schneier AJ, Durand ML. Ocular toxocariasis: advances in diagnosis and treatment. *International Ophthalmology Clinics*. 2011;51(4):135-44.
- [208] de Visser L, Rothova A, de Boer JH, van Loon AM, Kerkhoff FT, Canninga-van Dijk MR, et al. Diagnosis of ocular toxocariasis by establishing intraocular antibody production. *American Journal of Ophthalmology*. 2008;145(2):369-74.
- [209] Jacquier P, Gottstein B, Stingelin Y, Eckert J. Immunodiagnosis of toxocarosis in humans: evaluation of a new enzyme-linked immunosorbent assay kit. *Journal of Clinical Microbiology*. 1991;29(9):1831-5.
- [210] Jin Y, Shen C, Huh S, Sohn WM, Choi MH, Hong ST. Serodiagnosis of toxocariasis by ELISA using crude antigen of *Toxocara canis* larvae. *The Korean Journal of Parasitology*. 2013;51(4):433-9.
- [211] Tian JX, O'Hagan S. *Toxocara* polymerase chain reaction on ocular fluids in bilateral granulomatous chorioretinitis. *International Medical Case Reports Journal*. 2015;8:107-10.
- [212] Van De N, Trung NV, Duyet le V, Chai JY. Molecular diagnosis of an ocular toxocariasis patient in Vietnam. *The Korean Journal of Parasitology*. 2013;51(5):563-7.
- [213] Zibaei M, Sadjjadi SM, Karamian M, Uga S, Oryan A, Jahadi-Hosseini SH. A comparative histopathology, serology and molecular study, on experimental ocular toxocariasis by *Toxocara cati* in Mongolian gerbils and Wistar rats. *BioMed Research International*. 2013;2013:109580.
- [214] Seong S, Moon D, Lee DK, Kim HE, Oh HS, Kim SH, et al. A case of ocular toxocariasis successfully treated with albendazole and triamcinolon. *The Korean Journal of Parasitology*. 2014;52(5):537-40.

- [215] Frazier M, Anderson ML, Sophocleous S. Treatment of ocular toxocariasis with albendazole: a case report. *Optometry*. 2009;80(4):175-80.
- [216] Prasad KN, Prasad A, Verma A, Singh AK. Human cysticercosis and Indian scenario: a review. *Journal of Biosciences*. 2008;33(4):571-82.
- [217] Coral-Almeida M, Gabriel S, Abatih EN, Praet N, Benitez W, Dorny P. *Taenia solium* Human Cysticercosis: a systematic review of sero-epidemiological data from endemic zones around the world. *PLoS Neglected Tropical Diseases*. 2015;9(7):e0003919.
- [218] Yera H, Dupont D, Houze S, Ben M'rad M, Pilleux F, Sulahian A, et al. Confirmation and follow-up of neurocysticercosis by real-time PCR in cerebrospinal fluid samples of patients living in France. *Journal of Clinical Microbiology*. 2011;49(12):4338-40.
- [219] Jain RS, Kumar S, Bhana I, Agarwal R. Ocular cysticercosis with vitreous hemorrhage: a rare complication of a common disease. *Springerplus*. 2015;4:217.
- [220] Goyal S, Sandhu PS, Sharma A, Malik MA, Bansal P, Kaur J. Inferior rectus muscle ocular cysticercosis: a case report. *Saudi Journal of Ophthalmology*. 2015;29(2):175-7.
- [221] Mohan N, Panda KG, Padhi TR. Bug inside the eye: ocular cysticercosis. *JAMA Ophthalmology*. 2014;132(12):1468.
- [222] Sohoni CA. Neuro-ocular cysticercosis causing total retinal detachment and cataract. *Journal of Family Medicine and Primary Care*. 2013;2(3):300-1.
- [223] Labh RK, Sharma AK. Ptosis: a rare presentation of ocular cysticercosis. *Nepalese Journal of Ophthalmology*. 2013;5(1):133-5.
- [224] Sharma AK. Ocular cysticercosis: diagnosis and treatment. *Nepalese Journal of Ophthalmology*. 2014;6(2):240-1.
- [225] Nkouawa A, Sako Y, Nakao M, Nakaya K, Ito A. Loop-mediated isothermal amplification method for differentiation and rapid detection of *Taenia* species. *Journal of Clinical Microbiology*. 2009;47(1):168-74.
- [226] Swastika K, Dewiyani CI, Yanagida T, Sako Y, Sudarmaja M, Sutisna P, et al. An ocular cysticercosis in Bali, Indonesia caused by *Taenia solium* Asian genotype. *Parasitology International*. 2012;61(2):378-80.
- [227] Ocular cysticercosis treatment and management. Available at: <http://emedicine.medscape.com/article/1204683-treatment>
- [228] Stojkovic M, Junghanss T. Cystic and alveolar echinococcosis. *Handbook of Clinical Neurology*. 2013;114:327-34.
- [229] Karakas HM, Tokoglu F, Kacar M, Boyacigil S. Retrobulbar hydatid cyst: assessment of two cases. *Australasian Radiology*. 1997;41(2):179-80.
- [230] Budke CM, Carabin H, Ndimubanzi PC, Nguyen H, Rainwater E, Dickey M, et al. A systematic review of the literature on cystic echinococcosis frequency worldwide and

its associated clinical manifestations. *The American Journal of Tropical Medicine and Hygiene*. 2013;88(6):1011-27.

- [231] Arora MM, Dhanda RP, Bhagwat AG, Kalevar VK. Intra-ocular hydatid cyst. *The British Journal of Ophthalmology*. 1964;48:507-9.
- [232] Betharia SM, Sharma V, Pushker N. Ultrasound findings in orbital hydatid cysts. *American Journal of Ophthalmology*. 2003;135(4):568-70.
- [233] Aksoy FG, Tanrikulu S, Kosar U. Inferiorly located retrobulbar hydatid cyst: CT and MRI features. *Computerized Medical Imaging and Graphics*. 2001;25(6):535-40.
- [234] Manzano-Roman R, Sanchez-Ovejero C, Hernandez-Gonzalez A, Casulli A, Siles-Lucas M. Serological diagnosis and follow-up of human cystic echinococcosis: a new hope for the future? *BioMed Research international*. 2015;2015:428205.
- [235] Mirfazaelian H, Bagheri B, Daneshbod Y. Fine needle aspiration cytology diagnosis of an ocular hydatid cyst. *Cytopathology*. 2014;25(6):416-7.
- [236] Echinococcosis. Available at: <http://www.cfsph.iastate.edu/Factsheets/pdfs/echinococcosis.pdf>
- [237] Al-Muala HD, Sami SM, Shukri MA, Hasson HK, Alaboudy AT. Orbital hydatid cyst. *Annals of Maxillofacial Surgery*. 2012;2(2):197-9.
- [238] Selcuklu A, Ozturk M, Kulahli I, Dogan H. Successful surgical management of an intraorbital hydatid cyst through a transmaxillary approach: case report. *Skull Base: Official Journal of North American Skull Base Society*. 2003;13(2):101-5.
- [239] Mas-Coma S, Agramunt VH, Valero MA. Neurological and ocular fascioliasis in humans. *Advances in Parasitology*. 2014;84:27-149.
- [240] Dickinson AJ, Rosenthal AR, Nicholson KG. Inflammation of the retinal pigment epithelium: a unique presentation of ocular schistosomiasis. *The British Journal of Ophthalmology*. 1990;74(7):440-2.
- [241] Mimori T, Hirai H, Kifune T, Inada K. *Philophthalmus* sp. (Trematoda) in a human eye. *The American Journal of Tropical Medicine and Hygiene*. 1982;31(4):859-61.
- [242] Tiewchaloern S, Udomkijdech S, Suvouttho S, Chunchamsri K, Waikagul J. *Clinostomum* trematode from human eye. *The Southeast Asian Journal of Tropical Medicine and Public Health*. 1999;30(2):382-4.
- [243] McDonald HR, Kazacos KR, Schatz H, Johnson RN. Two cases of intraocular infection with *Alaria mesocercaria* (Trematoda). *American Journal of Ophthalmology*. 1994;117(4):447-55.
- [244] Dono M, Bertoni MR, Poggi R, Teneggi E, Maddalo F, Via F, et al. Three cases of ophthalmomyiasis externa by sheep botfly *Oestrus ovis* in Italy. *New Microbiologica*. 2005;28(4):365-8.

- [245] Grammer J, Erb C, Kamin G, Wild M, Riedinger C, Kosmidis P, et al. Ophthalmomyiasis externa due to the sheep botfly *Oestrus ovis* (Diptera: Oestridae) in south-west Germany. *German Journal of Ophthalmology*. 1995;4(3):188-95.
- [246] Gupta VP, Baveja UK. Ophthalmomyiasis externa caused by the sheep nasal botfly *Oestrus ovis*. *Indian Journal of Ophthalmology*. 1988;36(1):41-2.
- [247] Harvey JT. Sheep botfly: ophthalmomyiasis externa. *Canadian Journal of Ophthalmology (Journal canadien d'ophtalmologie)*. 1986;21(3):92-5.
- [248] Mason GI. Bilateral ophthalmomyiasis interna. *American Journal of Ophthalmology*. 1981;91(1):65-70.
- [249] Ho-Yen DO, Chapman DJ, Ashburn D. Immunoblotting can help the diagnosis of ocular toxoplasmosis. *Molecular Pathology*. 2000;53(3):155-8.
- [250] Fekkar A, Bodaghi B, Touafek F, Le Hoang P, Mazier D, Paris L. Comparison of immunoblotting, calculation of the Goldmann-Witmer coefficient, and real-time PCR using aqueous humor samples for diagnosis of ocular toxoplasmosis. *Journal of Clinical Microbiology*. 2008;46(6):1965-7.