

# We are IntechOpen, the world's leading publisher of Open Access books Built by scientists, for scientists

**4,800**

Open access books available

**122,000**

International authors and editors

**135M**

Downloads

Our authors are among the

**154**

Countries delivered to

**TOP 1%**

most cited scientists

**12.2%**

Contributors from top 500 universities



**WEB OF SCIENCE™**

Selection of our books indexed in the Book Citation Index  
in Web of Science™ Core Collection (BKCI)

Interested in publishing with us?  
Contact [book.department@intechopen.com](mailto:book.department@intechopen.com)

Numbers displayed above are based on latest data collected.

For more information visit [www.intechopen.com](http://www.intechopen.com)



---

# Ectopic Expression of Human Herpesvirus 1 Thymidine Kinase Induces Male Infertility

---

Mo Chen, Li-yi Cai, Takako Kato and Yukio Kato

Additional information is available at the end of the chapter

<http://dx.doi.org/10.5772/64390>

---

## Abstract

The herpesvirus family comprises several widespread infectious pathogens. They infect a variety of animal hosts, including humans and cause complex clinical outcomes. Recently, the possible correlation between genital infection by human herpesviruses (HHVs) and male infertility has attracted considerable attention. In this chapter, we investigated the mechanism of HHV-1-induced infertility in transgenic (Tg) rats and its possible correlation with infertility in human males. Ectopic expression of HHV-1 thymidine kinase (TK) in the testis of Tg rats increased male infertility. In addition, truncated TK proteins were found in postmeiotic spermatids of Tg rat testis, leading to progressive degeneration of germ cells and vacuolization of the seminiferous epithelium. These findings suggest the possibility that a similar process occurs within HHV-infected human germ cells.

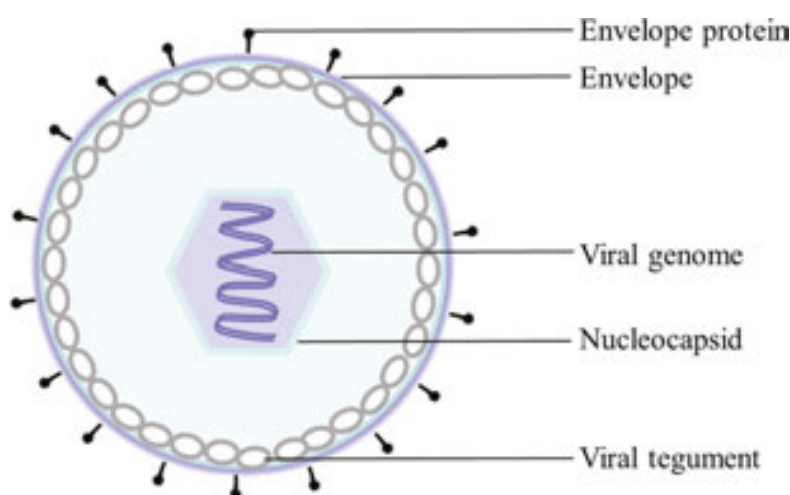
**Keywords:** herpesvirus, thymidine kinase, genital infection, male infertility, spermatogenesis

---

## 1. Introduction

Herpesviruses belong to a family of double-stranded DNA (dsDNA) viruses commonly causing herpes in animals. They present a unique four-layered structure. The outermost layer corresponds to the envelope, a lipid bilayer membrane interspersed with glycoproteins. This encases the tegument, a protein coat that surrounds the icosahedral nucleocapsid containing the viral linear DNA genome (**Figure 1**) [1]. At present, over 130 herpesvirus species have been identified, eight of which are known as human herpesviruses (HHVs): HHV-1 and HHV-2 (commonly called herpes simplex virus-1 and -2; HSV-1 and HSV-2), HHV-3 (varicella-

zoster virus; VZV), HHV-4 (Epstein-Barr virus; EBV), HHV-5 (cytomegalovirus; CMV), HHV-6 (human herpesvirus 6, including HHV-6A and HHV-6B), HHV-7 (human herpesvirus 7), and HHV-8 (Kaposi's sarcoma-associated herpesvirus; KSHV). HHVs are divided into three subfamilies ( $\alpha$ -,  $\beta$ - and  $\gamma$ -herpesviruses) based on their unique properties (**Table 1**) [2]. HHVs are widespread among humans to the extent that more than 90% of adults are thought to be infected with at least one variety [2]. HHVs generally infect ectoderm-derived tissues, such as skin, mucoepithelial tissue and nervous tissue; however, they usually show preference for specific target cells/tissues and ensuing clinical outcomes (**Table 1**) [2]. In addition, many people carrying the virus may be asymptomatic due to the latency of associated transcripts, which help HHVs evade the host's immune response [3]. Moreover, HHVs hide in specific cells during latent infection periods (**Table 1**).



**Figure 1.** HHVs structure. HHVs have a unique four-layered structure: a core of double-stranded DNA is surrounded by the nucleocapsid, which is enclosed by the envelope. The envelope is attached to the capsid through the tegument. Glycoproteins cover the surface of the envelope.

During the last decade, numerous studies have demonstrated that genital infections are often associated with human infertility, especially in males [4]. Most recently, genital infections caused by herpesviruses have attracted considerable attention [5–7]. Although herpes genitalis can be mainly caused by HHV-1 and HHV-2 [8], other HHVs have also been frequently detected in the genital organs of infertile male patients [9–11]. Although not fully demonstrated, there is a possible correlation between human male infertility and HHVs.

Our laboratory recently developed a line of transgenic (Tg) rats expressing a chimeric gene with the promoter of porcine follicle-stimulating hormone  $\beta$  subunit (FSH $\beta$ ) and the open reading frame of HHV-1 thymidine kinase (TK). Unexpectedly, we observed that Tg rats showed infertility upon ectopic expression of HHV-1-TK in the testis, independent of the FSH $\beta$  promoter [12]. Indeed, we found that the accumulation of HHV-1-TK protein in postmeiotic spermatids was the cause of male infertility [13]. In this study, we used the Tg rat model to elucidate the HHV-mediated mechanism responsible for male infertility.

Virus	Common name	Major target	Diseases	Clinical syndromes	Site of latency
HHV-1 <sup>a</sup>	HSV-1 Herpes simplex virus-1	Mucoepithelial	Oral herpes, genital herpes	Oral and genital herpes, gingivostomatitis, keratoconjunctivitis, encephalitis, pneumonitis, esophagitis, hepatitis	Sensory and cranial nerve ganglia
HHV-2 <sup>a</sup>	HSV-2 Herpes simplex virus-2	Same as above	same as above	Oral and genital herpes, herpes, gingivostomatitis, keratoconjunctivitis, meningitis, encephalitis, pneumonitis, esophagitis, hepatitis	Same as above
HHV-3 <sup>a</sup>	VZV Varicella zoster virus	Same as above	Chickenpox, shingles	Shingles (extradermatomal), pneumonitis, disseminated infection, hepatitis, retinitis, meningitis, hemolysis, leukopenia, thrombocytopenia	Same as above
HHV-4 <sup>y</sup>	EBV Epstein-Bar virus	B cells and epithelial cells	Infectious mononucleosis, Burkitt's lymphoma, CNS lymphoma, posttransplant lymphoproliferative syndrome (PTLD), nasopharyngeal carcinoma, HIV-associated hairy leukoplakia	Mononucleosis, posttransplant lymphoproliferative disorders, pneumonitis, hepatitis, encephalitis, hemolysis, leukopenia, thrombocytopenia	Memory B cells
HHV-5 <sup>b</sup>	CMV Cytomegalovirus	Monocyte, lymphocyte and epithelial cells	Infectious mononucleosis-like syndrome, retinitis	Lymphadenopathy, hepatitis, pneumonitis, cns vasculitis/ encephalitis, retinitis, esophagitis, hemolysis, leukopenia, thrombocytopenia	Monocytes, macrophages, lymphocytes, others

Virus	Common name	Major target	Diseases	Clinical syndromes	Site of latency
HHV-6A/B <sup>β</sup>		T cells, NK cell, epithelial cells and others	HHV-6A: multiple sclerosis, encephalitis, glioma HHV-6B: sixth disease (roseola infantum or exanthem subitum), multiple sclerosis, encephalitis, hepatitis, pneumonitis, glioma	HHV-6A: meningoencephalitis, encephalitis, perceptual-motor dysfunction, hemiplegia, lymphoproliferative disorder HHV-6B: rash, fever, meningoencephalitis, encephalitis, perceptual-motor dysfunction, hemiplegia, lymphoproliferative disorder, pneumonitis, hepatitis, thrombocytopenia, leukopenia,	T, B, NK cells, monocytes, macrophages, liver, salivary endothelial, neuronal cells
HHV-7 <sup>γ</sup>		T cells	Sixth disease (roseola infantum or exanthem subitum), pityriasis rosea	Rash, fever, encephalitis?, hepatitis?	CD4+ T cells, salivary epithelial, lung, skin cells
HHV-8 <sup>γ</sup>	KSHV Kaposi's sarcoma-associated herpesvirus	Lymphocyte and others	Kaposi's sarcoma, primary effusion lymphoma, some types of multicentric Castleman's disease	Fever, mononucleosis, skin lesions, encephalitis?	B cells

1.  $\alpha$ -herpesvirus: rapid reproduction and cell lysis in vitro, rapid cell lysis and spread in vivo, primary target mucoepithelial cells, latency in sensory ganglia.

2.  $\beta$ -herpesvirus: long replication cycle in vivo and in vitro, limited host range, large infected cells, latency in mononuclear cells, secretory cells, some epithelial cells, and others.

3.  $\gamma$ -herpesvirus: replication in lymphoblastoid cells, lytic cycle in some fibroblasts and epithelial cells.

**Table 1.** Main characteristics of HHVs.

## 2. HHVs infection and male human infertility

Human infertility is a widespread problem that has been increasing in recent decades. It affects 20–30% of couples in the world [14], and 40–50% is attributed to male infertility [15, 16]. Many risk factors can disrupt male reproductive capacity and cause infertility. Among these are

infections with pathogens [17], such as viruses [7], mycoplasma [18], chlamydia [19], and bacteria [20].

Recently, a number of studies have detected HHVs in the semen and/or spermatozoa of ~90% of infertile male patients, although regional variations must be taken into account (**Table 2**) [6, 9–11, 21–31]. Many investigators have tried to confirm the relationship between male infertility and HHVs infection by combining viral infection rates with statistical analysis of semen and/or sperm samples derived from PCR-based viral DNA analysis, antigen-antibody reaction, and immunocytochemistry of spermatozoa. However, only in a few cases, a significant difference in sperm counts, motility, and/or abnormality has been found between HHVs carriers and non-carriers [6, 9, 11, 27].

Although many studies have revealed a high prevalence of HHVs in male infertility patients, it is still difficult to conclude that HHVs infection is the causative agent. To address this issue, the capacity of HHVs to infect the testis and interfere with spermatogenesis should be proven regardless of the presence or absence of HHVs in the semen and spermatozoa. This would require direct evidence of a molecular mechanism for HHV-induced infertility. In this respect, studies in Tg animal models offer the opportunity to better understand human male infertility.

Country or area (year)	Carrier% (carrier/subject)	HHV-1 (HSV-1)	HHV-2 (HSV-2)	HHV-3 (VZV)	HHV-4 (EBV)	HHV-5 (CMV)	HHV-6A/B	HHV-7	HHV-8
Italian (1999) [22]	91 (30/33)	–	–	–	–	–	–	–	91
Germany (2001) [6]	17.1 (43/252)	3.2	0	7.1	3.6	4	0.4*	0	
Athens (2003) [9]	56.6 (64/113)	49.5	–	16.8	7.1	–	–	–	
UK (2006) [25]	3 (1/33)				3				
USA (2007) [10]	18.7 (45/241)	3.7	–	0.4	8.7	3.7	–	–	
Coast (2007) [31]	14.3 (9/63)					14.3			
Greece (2009) [11]	–	2.1	–	3.2	39.1	56.5	66.3	0	–
Germany (2009) [23]	6.5 (11/170)					6.5			

Country or area (year)	Carrier% (carrier/ subject)	HHV-1 (HSV-1)	HHV-2 (HSV-2)	HHV-3 (VZV)	HHV-4 (EBV)	HHV-5 (CMV)	HHV-6A/B	HHV-7	HHV-8
Russia (2011) [26]	11 (10/91)	–	–	–	–	11	–	–	–
Spain (2012) [24]	54 (59/109)	29	–	45	43	8.2	3.6	–	–
Denmark (2012) [28]	27.8 (55/198)	0.4	0.1	0	6.3	2.7	13.5	4.2	0
China (2013) [21]	38.5 (59/153)	25.4	–	–	3.9	21.6	1.9	–	–
Iran (2013) [27]	22.9 (16/70)	22.9	14.3	–	–	–	–	–	–
France (2015) [29]	1.7 (3/184)	–	–	–	–	–	1.7	–	–
Russia (2014) [30]	17.7 (41/232)	–	–	–	3.4	5.2	6.5	–	–

HHV-6A/B does not discriminate between HHV-6A and HHV-6B in all of the references.

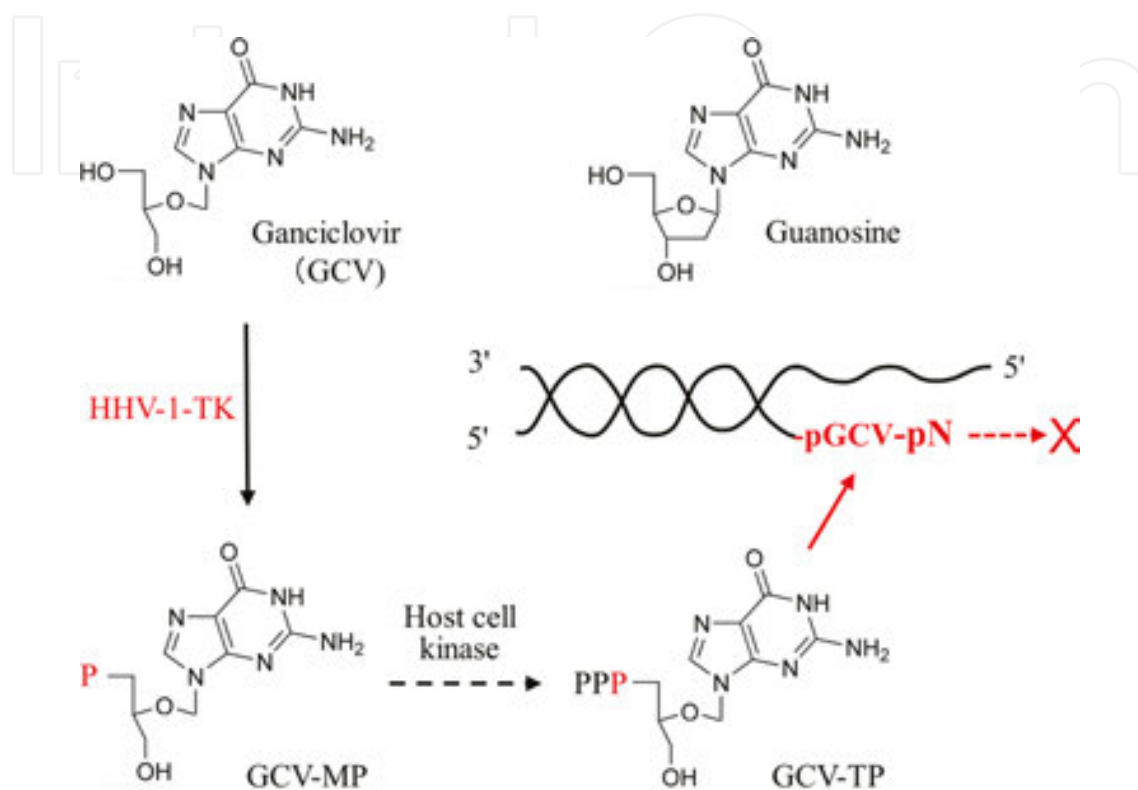
\* Significant difference of sperm count or sperm motility in infertile and fertile group.

**Table 2.** Summary of HHVs infection profiles from selected studies.

### 3. HHV-1-TK as a reporter system

TK (EC 2.7.1.21) is a key enzyme in the pyrimidine salvage pathway that catalyzes the transfer of the ATP  $\gamma$ -phosphate to thymidine to produce dTMP. HHV-1-TK is a phosphotransferase specifically required for viral DNA synthesis. HHV-1-TK shows broad substrate specificity, including pyrimidines (thymidine, deoxycytidine) and their analogs (azidothymidine), as well as purines (guanosine) and their analogs (acyclovir, ganciclovir [GCV], bucciclovir and penciclovir). The ability to transform synthetic precursors, such as GCV, into toxic nucleotide analogs has resulted in effective cancer therapy agents [32, 33]. GCV consists of a guanine linked to an acyclic sugar moiety at position 3'. HHV-1-TK converts GCV into GCV-monophosphate, which is further phosphorylated into GCV-triphosphate by the host's kinases. GCV-triphosphate has high affinity for DNA polymerase and functions as a competitive inhibitor of guanosine triphosphate (dGTP), becoming incorporated into the nascent DNA strand (**Figure 2**). GCV causes a distortion in the DNA sugar phosphate backbone, which

blocks DNA replication [34–36] and induces cell apoptosis, thus selectively eliminating HHV-1-TK-positive cells [37, 38]. Moreover, HHV-1-TK-expressing cells trigger apoptosis of neighboring cells due to the transfer of GCV-triphosphate via gap junctions in a phenomenon called “bystander killing” [39]. Therefore, HHV-1-TK can be used as a marker/reporter gene for removing specific target cells.



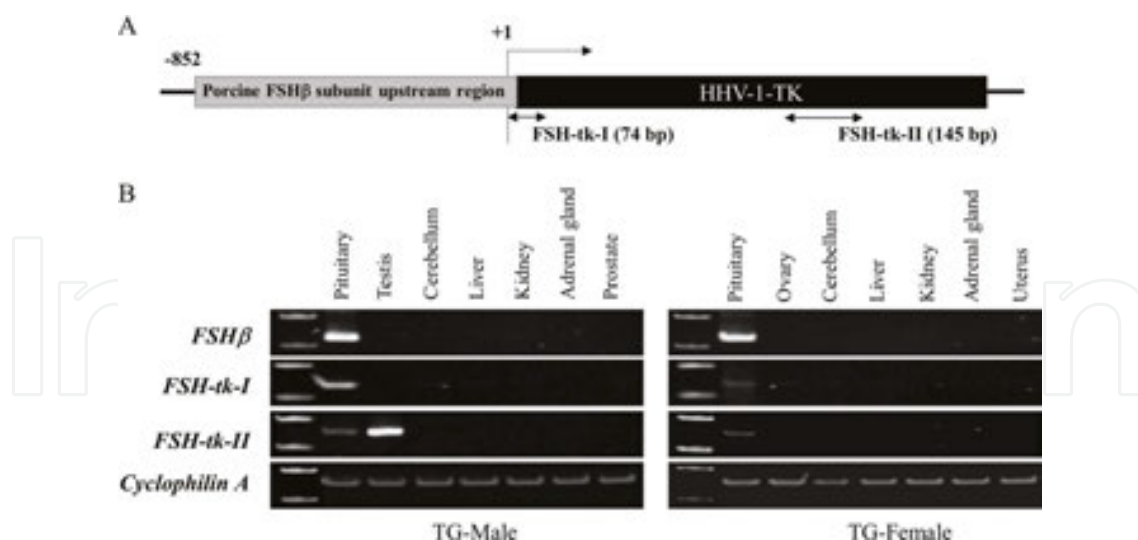
**Figure 2.** Incorporation of GCV disrupts extension of replicating DNA strands. In HHV-1-TK-positive cells, GCV is phosphorylated into GCV-monophosphate and then converted into GCV-triphosphate. GCV-triphosphate has high affinity for DNA polymerase and is utilized as a dGTP analog. However, the acyclic sugar moiety distorts the sugar phosphate backbone, resulting in irregular extension of the replicating DNA strand.

## 4. Infertility in HHV-1-TK in Tg animals

### 4.1. Ectopic expression of HHV-1-TK

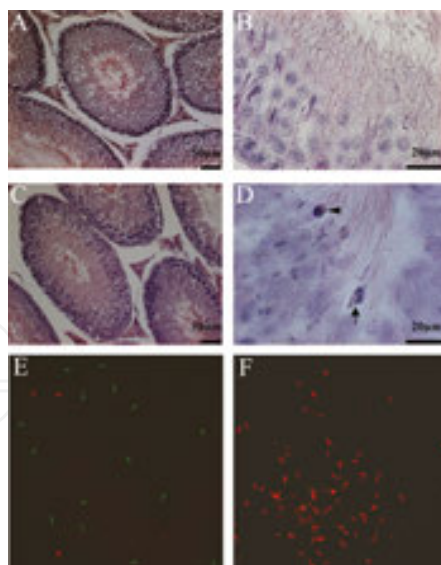
The use of HHV-1-TK offers a valuable tool for the ablation of specific cell types as well as in gene therapy. In the early 1990s, Tg rats were engineered to express HHV-1-TK under the control of the FSH $\beta$  promoter (**Figure 3A**) in the anterior lobe of the pituitary gland [12]. However, the experiment was interrupted due to observed infertility of male rats. The same happened with Tg mice [40]. Moreover, Ellison and Bishop showed that ectopic expression of HHV-1-TK fused to the human immunodeficiency virus long terminal repeat (HIV-1-LTR) gene caused male infertility in Tg mice [41]. In the present work, we observed ectopic expression of HHV-1-TK gene in the testis of Tg rats (**Figure 3B**).





**Figure 3.** Ectopic expression of HHV-1-TK in transgenic (Tg) rats. (A) HHV-1-TK (blue box) was fused to the 5'-upstream region (-852/+10 bp) of porcine FSH $\beta$  (light blue). Arrows indicate the region amplified using specific primer sets (FSH-tk-I and FSH-tk-II); product sizes are shown in parentheses. (B) Total RNAs of pituitary, gonads (testis and ovary), cerebellum, liver, kidney, adrenal glands, prostate, and uterus of Tg rats (male and female) were analyzed by real-time polymerase chain reaction (RT-PCR) using specific primers for rat FSH $\beta$  subunit, HHV-1-TK (I), HHV-1-TK (II) and cyclophilin A (control). Reproduced and modified from [12] with permission from the Society for Reproduction and Development.

Whereas the testes of 3-month-old normal rats exhibited morphologically normal germ cells through all stages of maturation, histological analysis of Tg rats revealed developmentally

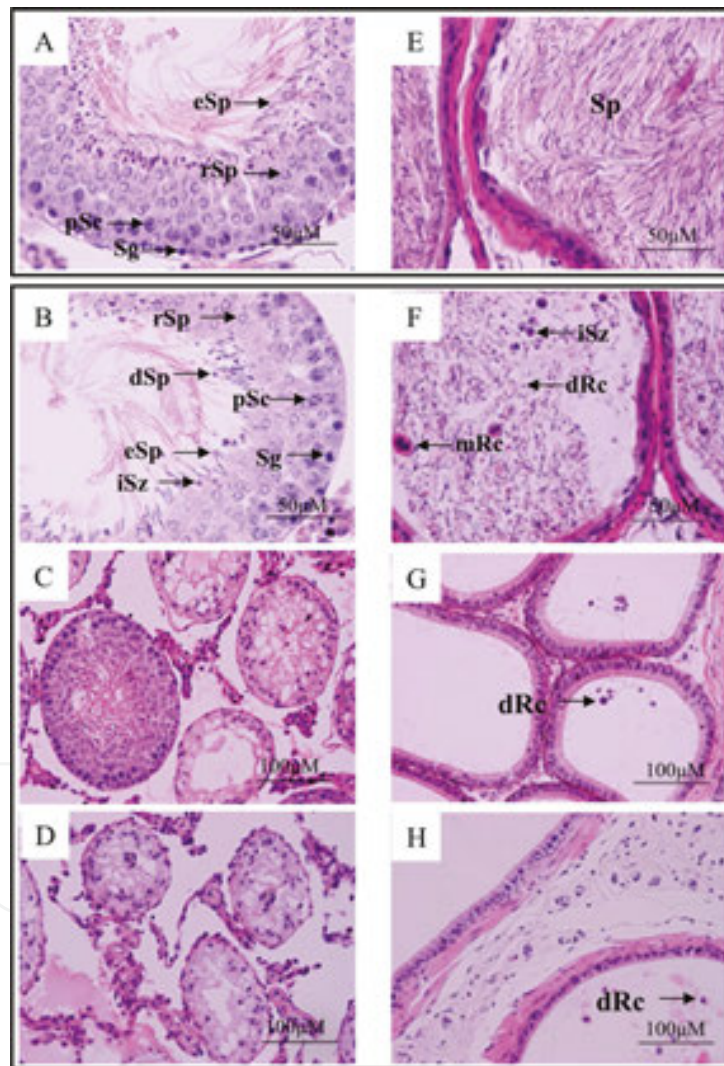


**Figure 4.** Histological analysis of rat testis and motility of epididymal spermatozoa. (A–D) Sections stained with hematoxylin and eosin showing testicular spermatogenesis in normal (A and B) and Tg (C and D) 3-month-old rats. Arrowhead, elongated arrested round spermatid; arrow, multinucleated cell. (E and F) Spermatozoa obtained from the epididymis of normal (E) and Tg (F) rats stained with SYBR-14 and propidium iodide from a LIVE/DEAD sperm viability kit. Green and red indicate live and dead spermatozoa, respectively. Reproduced and modified from [12] with permission from the Society for Reproduction and Development.

arrested spermatozoa and multinuclear cells, together with altered elongated spermatozoa (**Figure 4**) [12]. Loss of sperm motility and viability was also observed (**Figure 4F**). Compared with normal rats, testis and epididymis weights were also decreased by 35 and 57%, respectively. In contrast, prostate and seminal vesicles weights were similar [12].

#### 4.2. Disruption of spermatogenesis

Histological analysis revealed that in Tg rats abnormal spermatogenesis could be observed as early as 3 months in development. Although spermatocytogenesis and meiosis seemed to progress normally (**Figure 5B**), the number of spermatozoa in the epididymis decreased dramatically (**Figure 5F**). Furthermore, large numbers of degenerated germ cells

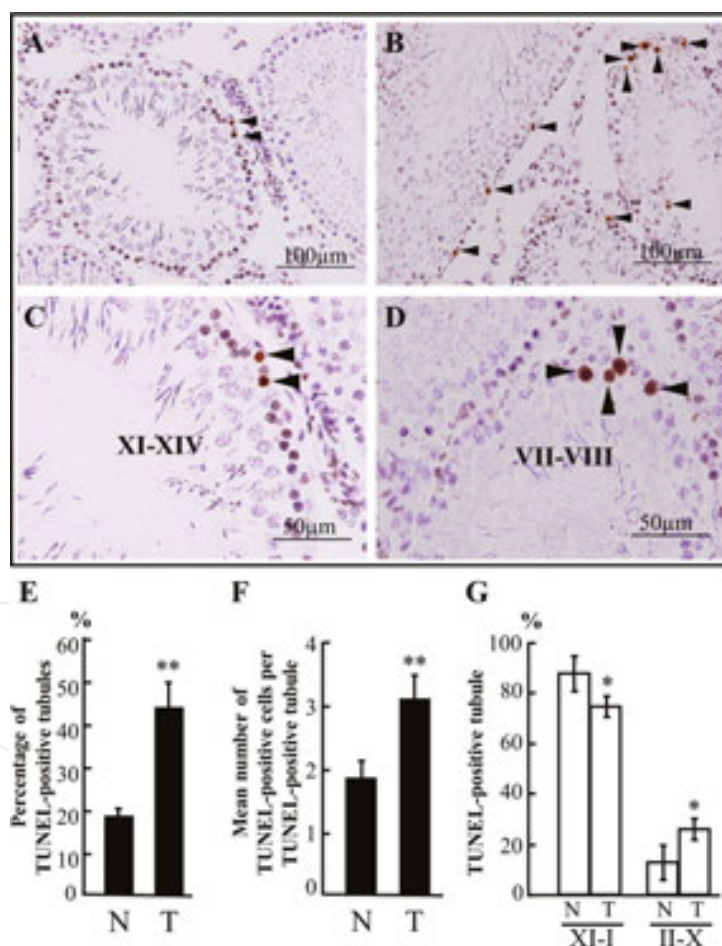


**Figure 5.** Histological analysis of testis and epididymis in normal and Tg rats. A–D. Sections of normal (A) and 3-, 6-, and 12-month-old (B–D, respectively) Tg rat testis stained with hematoxylin and eosin. (E–H) Sections of normal (E) and 3-, 6- and 12-month-old (F–H, respectively) Tg rat epididymis stained with hematoxylin and eosin. *Abbreviations:* spermatogonium (Sg), pachytene spermatocyte (pSc), immature spermatozoon (iSz), spermatid (Sp), round spermatid (rSp), elongated spermatid (eSp), degenerated spermatid (dSp), multinucleated round cell (mRc), and degenerated round cell (dRc). Reproduced and modified from [13] with permission from the European Teratology Society.

and immature/malformed spermatozoa were present (**Figure 5F**), indicating that maturation was likely to be disrupted. Degenerated germ cells with large vacuoles and cells lost throughout the tubules were observed in the testis of 6-month-old Tg rats (**Figure 5C**). In 12-month-old Tg rats there was a complete loss of germ cells and only Sertoli cells remained in the tubules (**Figure 5D**). In the epididymis of 6- and 12-month-old Tg rats, spermatozoa could hardly be observed (**Figure 5G–H**). Thus, Tg rats showed a spermatid-stage-specific defect in maturation and an age-dependent loss of germ cells.

#### 4.3. HHV-1-TK accumulation increases the number of apoptotic germ cells

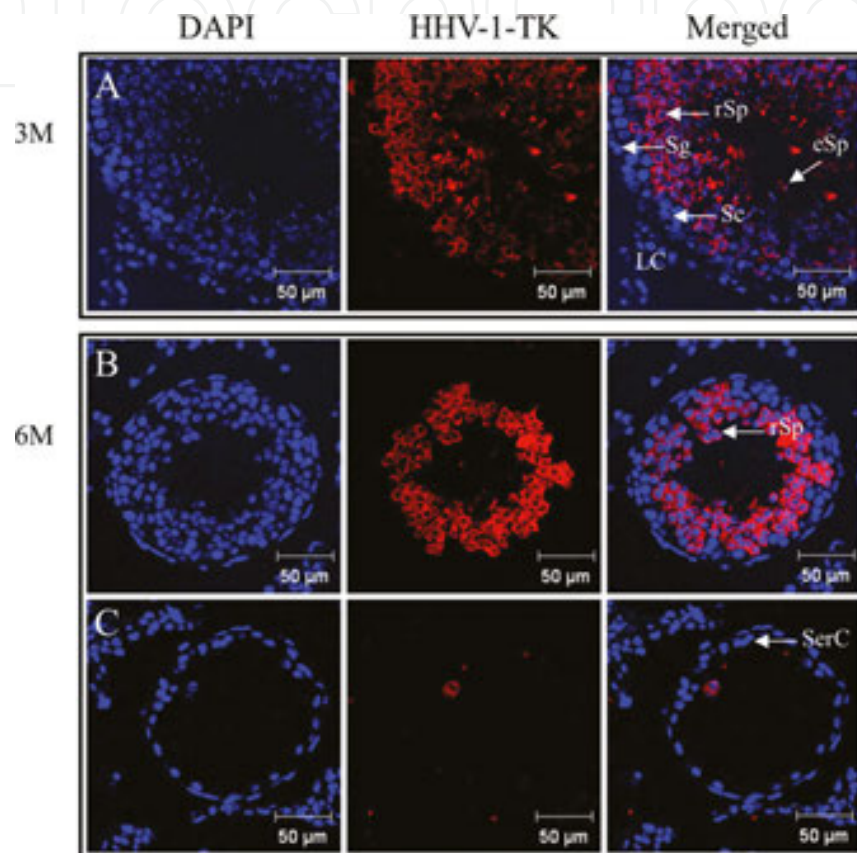
Whereas spermatocytogenesis and meiosis were confirmed in Tg rats, degeneration of germ cells by necrosis and apoptosis was frequently observed in the seminiferous tubules. In addition, terminal deoxynucleotidyl transferase dUTP nick end labeling (TUNEL) assay showed a stage-independent increase in TUNEL-positive tubules and cells (**Figure 6**).



**Figure 6.** Terminal deoxynucleotidyl transferase dUTP nick end labeling (TUNEL) assay of spermatozoa. (A–D) TUNEL assay of normal (A and C) and Tg (B and D) 3-month-old rats. Representative TUNEL-positive cells are indicated by arrowheads. (E) Percentage of TUNEL-positive tubules. (F) Mean number of TUNEL-positive cells per TUNEL-positive tubule (\*\* $p < 0.01$ ). (G) TUNEL-positive tubules of normal (N) and Tg (T) rats at stages XI-I and II-X (\* $p < 0.05$ ). Reproduced and modified from [13] with permission from the European Teratology Society.

#### 4.4. HHV-1-TK accumulation in postmeiotic spermatids

Tg rat testes (3- and 6-month-old) were simultaneously stained with anti-HHV-1-TK and nuclear DAPI stain (**Figure 7**). We observed that HHV-1-TK protein accumulated in the cytoplasm of postmeiotic spermatids while it was absent from spermatogonia, spermatocytes, Leydig cells and Sertoli cells. Furthermore, germ cells were obviously reduced in 6-month-old Tg rat testes (**Figure 7B-C**).

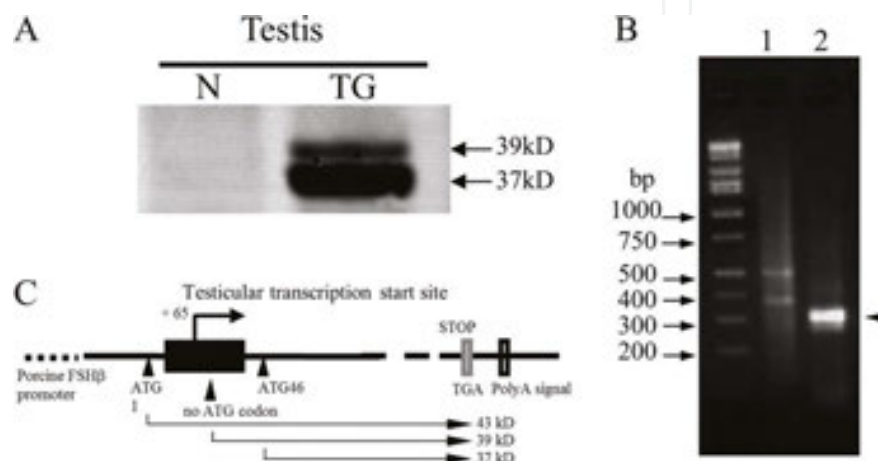


**Figure 7.** Immunohistochemistry of Tg rat testis. Immunostaining of 3-month-old Tg rat testis with anti-HHV-1-TK antibody and nuclear DAPI stain. HHV-1-TK localizes to the cytoplasm of round spermatids, but not to other testis cells. (B and C). Immunostaining of 6-month-old Tg rat testis. Germ cells decrease markedly. HHV-1-TK is observed in round spermatids (B) but not in Sertoli cells (C). *Abbreviations:* spermatogonium (Sg), spermatocyte (Sc), elongated spermatid (eSp), round spermatid (rSp), Leydig cell (LC), and Sertoli cell (SerC). Reproduced and modified from [13] with permission from the European Teratology Society.

### 5. Mechanism of ectopic expression of HHV-1-TK

Ectopic expression of HHV-1-TK protein was confirmed in postmeiotic spermatids by immunohistochemistry. This suggested the existence of alternative promoters directing specific and ectopic expression in postmeiotic spermatids. Western blot analysis of HHV-1-TK in Tg rat testis revealed for the first time two bands at 37 and 39 kDa, corresponding to truncated products of the full-size 43 kDa HHV-1-TK protein (**Figure 8A**) [13].

Analysis of the transcription start site by RNA ligase-mediated rapid amplification of cDNA ends (5'-RLM RACE) (**Figure 8B**) showed that the start site corresponded to the first intron of the HHV-1-TK gene (**Figure 8C**). This suggested that the second in frame ATG might have produced the 37 kDa band. Ellison and Bishop reported that HIV-1-LTR-driven HHV-1-TK ectopic expression was abolished by deleting the region between the multiple cloning site and the second ATG [41]. They suggested that removing this portion conferred DNA methylation-independent expression in the testis. Indeed, the corresponding region (144 bases) is GC-rich (67%) and contains 17 CpG sites. Currently, a HHV-1-TK vector free of the GC-rich region is available.



**Figure 8.** Identification of HHV-1-TK isoforms and transcription initiation sites in Tg rat testis. (A) Detection of HHV-1-TK in Tg rat testis by western blot analysis reveals two truncated isoforms (37 and 39 kDa) that do not correspond to the canonical form (43 kDa). (B) 5'-RLM-RACE analysis. Lane 1, PCR using a 5'-RACE outer primer set; lane 2, PCR with a 5'-RACE inner primer set. Products (approximately 300 bp) are indicated with an arrowhead. (C) Diagram showing the HHV-1-TK transcription initiation site (arrow), translation start sites (arrowheads and ATG with residue number), stop codon (grey box) and poly A signal (solid box). The closed box indicates a putative testis-specific promoter region within HHV-1-TK. Reproduced and modified from [13] with permission from the European Teratology Society.

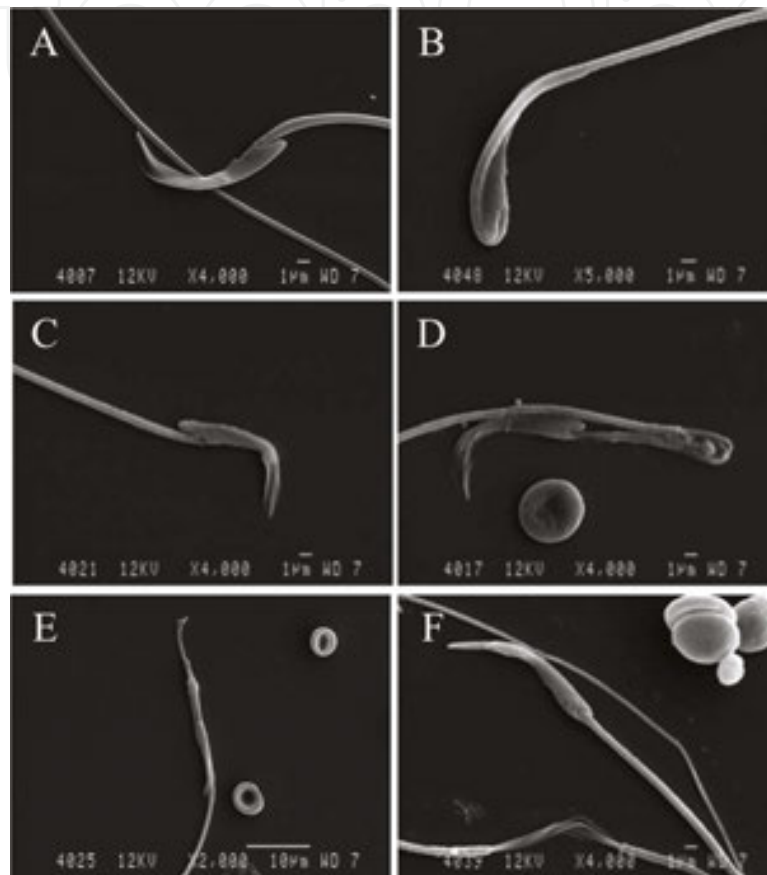
Ectopic, testis-specific, expression of HHV-1-TK in Tg rats and mice raises the possibility that the same mechanism could also affect humans carrying HHV-1. Therefore, the transcriptional regulation exhibited by ectopic expression of HHV-1-TK in Tg rats and the effects of HHV-1-TK accumulation on spermatogenesis may be revelatory of the same mechanisms in humans.

## 6. HHV-1-TK accumulation disrupts spermatogenesis and causes male infertility

### 6.1. Ultrastructural abnormalities of spermatozoa in Tg rat testis

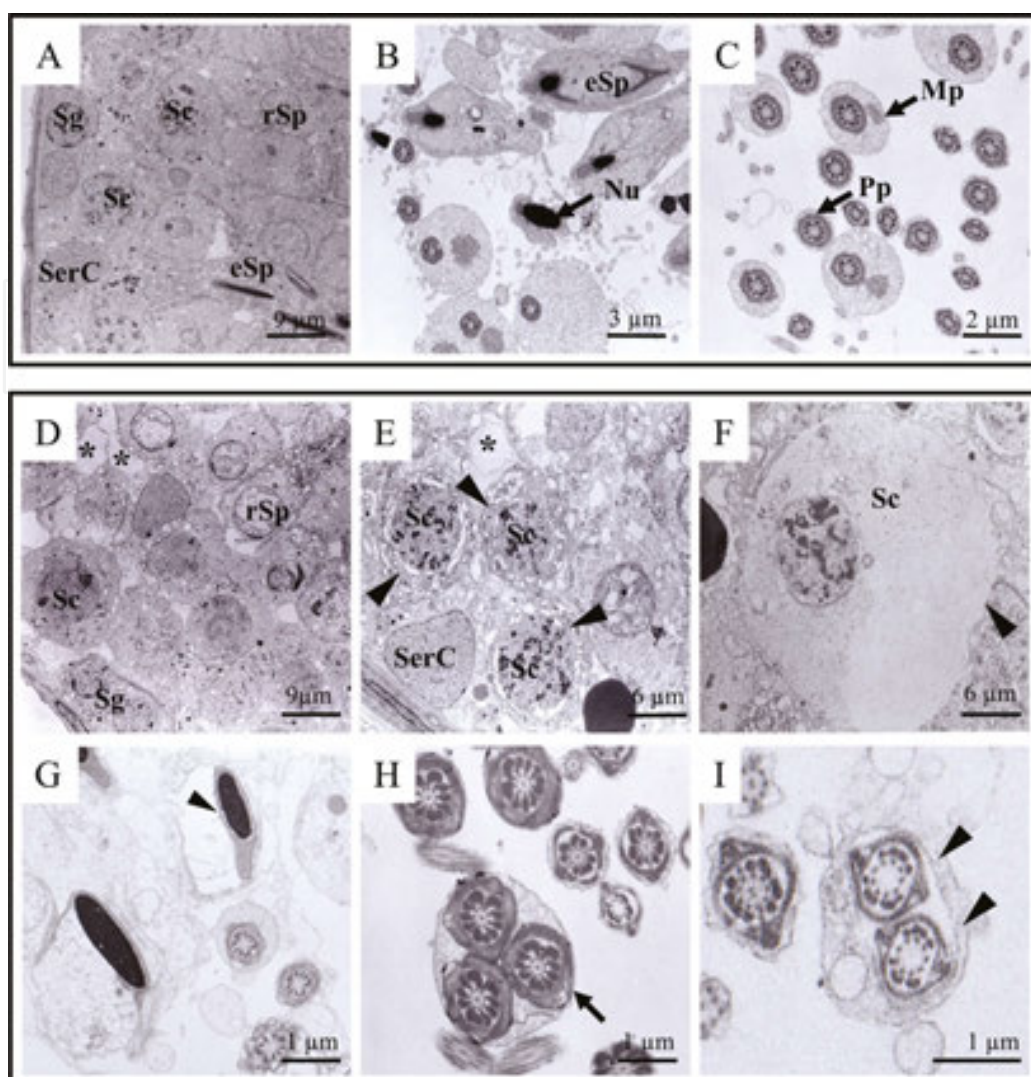
Scanning electron microscopy revealed abnormal ultrastructure of epididymal spermatozoa in 10-week-old Tg rats [13]. We observed that the head and tail regions of spermatozoa from 10-week-old normal rats exhibited smooth surface and a regular morphological conformation

(**Figure 9A**). Indeed, the morphology of these spermatozoa was different from those of Tg rats (**Figure 9B–F**). Spermatozoa with malformed heads, the consequence of a defective acrosome or reduced genome, were observed at high frequency among Tg rats (**Figure 9B–F**). Transmission electron microscopy (TEM) revealed that the cell membrane was missing from segments of the head (**Figure 9C**), midpiece (**Figure 9D**), and flagellum (**Figure 9F**). There were spermatozoa with looped tails (**Figure 9D**).



**Figure 9.** Scanning electron microscopy of Tg rat spermatozoa. Spermatozoa from caudal epididymis of 10-week-old rats visualized by scanning electron microscopy. (A) Normal rat sperm shows smooth head and tail. B–F. Tg rats present a deformed head (B), a microhead and absence of cell membrane (C), looped flagella and absence of cell membrane (D), defective acrosome and reduced genome (E), and absence of cell membrane in the flagellum (F). Reproduced and modified from [13] with permission from the European Teratology Society.

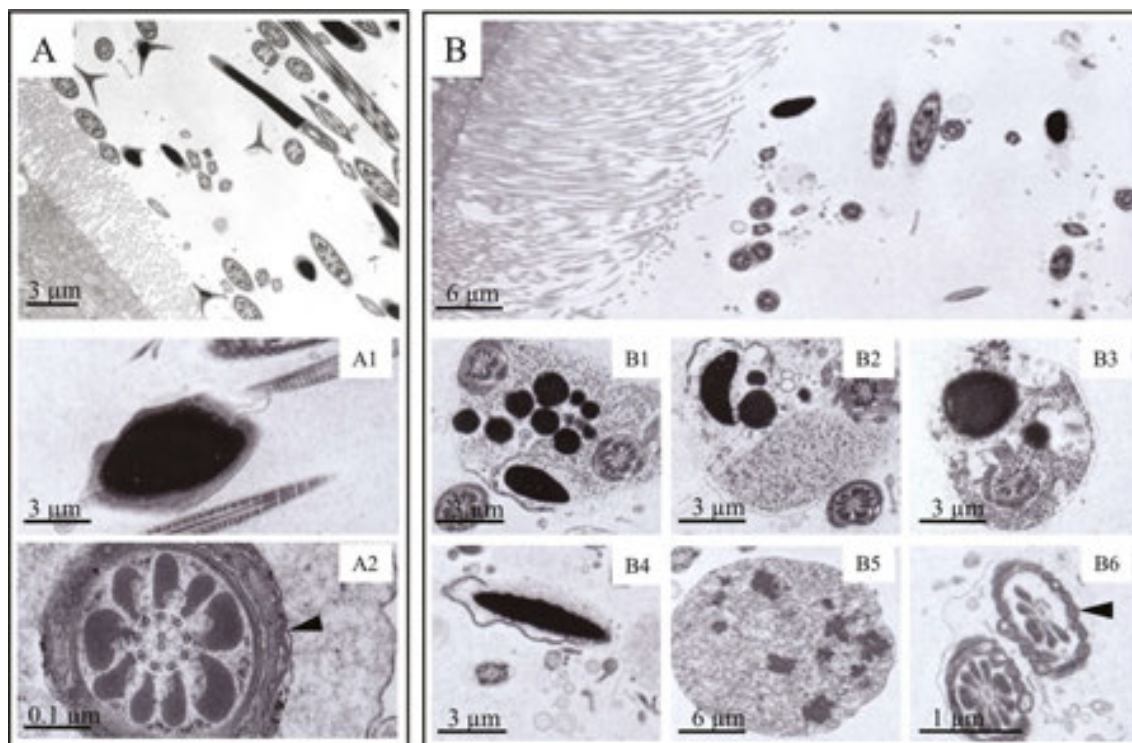
TEM of 3-month-old rat testis showed that in contrast with normal rats (**Figure 10A–C**), Tg rats displayed massive vacuoles within the seminiferous epithelium (**Figure 10D–E**, asterisks). These frequently presented degenerated spermatocytes in the seminiferous tubules (**Figure 10E–F**, arrowheads), in spite of confirmed spermatocytogenesis and meiosis. Moreover, TEM also showed elongated spermatids with disorganized heads partially devoid of cell membrane (**Figure 10G**, arrowhead), multiple flagella (**Figure 10H**, arrow), and absence of the inner arms of flagellar axonemes (**Figure 10I**, arrowheads) in the lumen of seminiferous tubules. In addition, vacuolization was also observed in the cytoplasm of spermatocytes (**Figure 10F**).



**Figure 10.** TEM of rat germ cells. Sections of 3-month-old normal (A–C) and Tg (D–I) rats analyzed by TEM. (A–C) Normal condensed nuclear, midpiece, and principle piece are indicated by arrows. (D–F) Numerous phagocytotic vacuole compartments and massive vacuoles are present within the cytoplasm of Sertoli cells (D–E, asterisks), together with degeneration of spermatocytes (E–F, arrowheads). (G–I) Spermatozoa within the lumen of seminiferous tubules show various ultrastructural abnormalities, such as disorganized heads with a disrupted cell membrane (G, arrowhead), multiple flagella (H–I, arrow), and absence of inner arms of flagellar axonemes (I, arrowheads). Abbreviations: normal condensed nuclear (Nu), midpiece (Mp), principle piece (Pp), spermatogonium (Sg), spermatocyte (Sc), Sertoli cell (SerC), round spermatid (rSp), elongated spermatid (eSp). Reproduced and modified from [42] with permission from the Society for Reproduction and Development.

TEM also revealed the low number of spermatozoa in the epididymis of Tg rats (**Figure 11B**) as compared to normal rats (**Figure 11A**). Spermatozoa from normal rats displayed intact cell membranes and normal-shaped heads with complete chromatin condensation (**Figure 11A1**). Instead, those of Tg rats presented a number of defects: several immature spermatids detaching from Sertoli cells and sloughing into the epididymis (**Figure 11B**), degenerated round spermatids (**Figure 11B1**) and many types of abnormal elongated spermatids (**Figure 11B2–B4**). In addition, whereas normal rats presented the typically assembled flagellar axonemes composed of nine outer doublet microtubules and a pair of central microtubules (**Figure 11A2**), most

spermatozoa from Tg rats were dead and showed various ultrastructural defects, including breakage of the surface membrane (**Figure 11B5**) and a decline in the number of outer dense fibers (**Figure 11B6**).

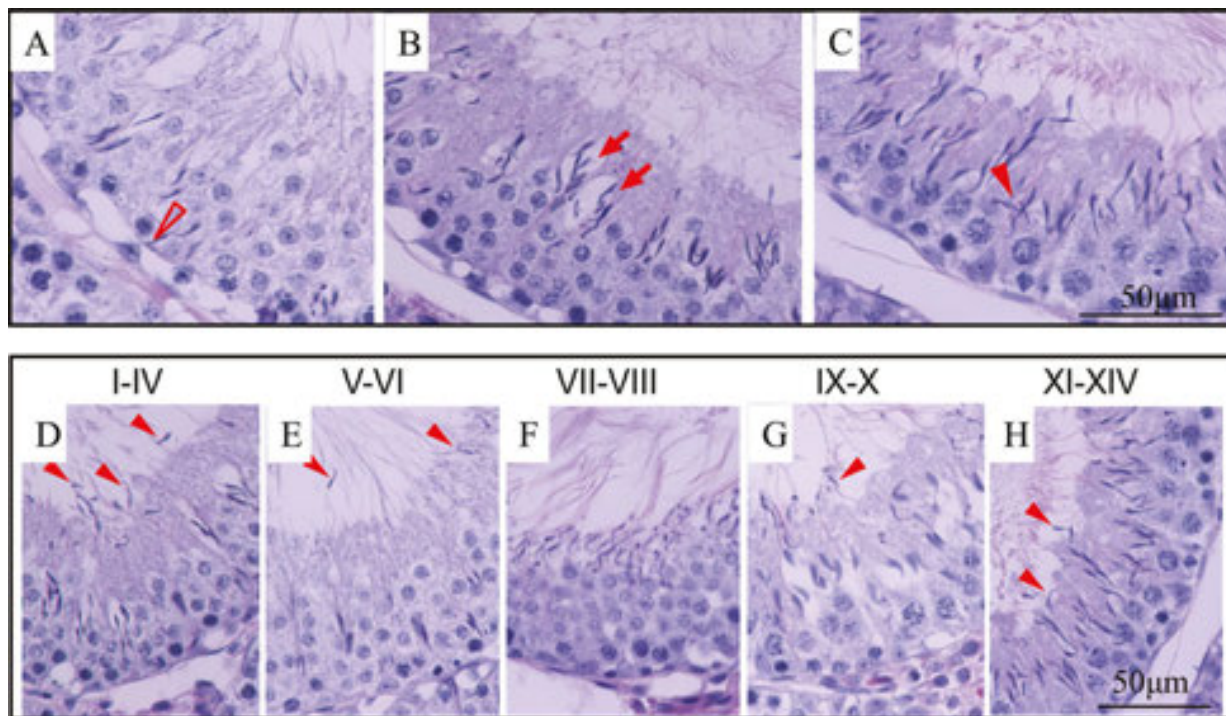


**Figure 11.** TEM of epididymal spermatozoa. TEM sections of epididymal spermatozoa from 3-month-old rats. (A) Spermatozoa from normal rats show intact acrosomes with condensed nuclear material (A1) as well as proper assembled flagellar axonemes displaying nine outer doublet microtubules and a pair of central microtubules (A2, arrowhead). (B) Spermatozoa in the epididymis of Tg rats appear dead, and display various ultrastructural defects, such as absence of acrosomes, disorganization of surface membranes, and degeneration of midpiece and tail (B1–B4). In addition, residual bodies of degenerated germ cells (B5) and missing outer doublet microtubules are frequently observed (B6, arrowhead). Reproduced and modified from [42] with permission from the Society for Reproduction and Development.

## 6.2. Disruption of Sertoli-germ junctions

Hematoxylin and eosin staining revealed various abnormal morphologies in Tg rat testis. Cytoplasmic vacuolation of Sertoli cells (**Figure 12A**, open arrowhead), disconnection between Sertoli and germ cells (**Figure 12B**, arrows), and disordered arrangement of elongated spermatids (**Figure 12C**, arrowhead) were present in many seminiferous tubules. In addition, immature spermatozoa falling off from the seminiferous epithelium were observed during all stages of spermatogenesis (**Figure 12D–H**, arrowheads). Furthermore, sperm development was disrupted and germ cells with different levels of maturity were observed simultaneously (**Figure 12D–H**). These results indicate that cell junctions between germ and Sertoli cells may have been affected. This hypothesis may be confirmed by analyzing gene expression profiles of Tg rat testis.





**Figure 12.** Histological analysis of Tg rat seminiferous tubules. Sections of 3-month-old Tg rat testis stained with hematoxylin and eosin. The following defects are observed: cytoplasmic vacuolation of Sertoli cells (A, open arrowhead), disconnection between Sertoli and germ cells (B, arrows), and disordered arrangement of elongated spermatids (C, solid arrowhead). (D–H) Immature spermatozoa falling off from the seminiferous epithelium (arrowheads) are observed at different maturation stages (I–XIV) and germ cell development is disrupted.

## 7. Alterations in gene expression profiles of Tg rat testis

Changes in gene expression evoked by HHV-1-TK accumulation in Tg rat testis were examined by cDNA microarray analysis. We found that 200 genes, 0.67% of all transcripts on DNA chips, were differently expressed between Tg and normal rats. We sorted the genes by their functional categories, such as apoptosis, cell cycle, development, oxidative stress, proteolysis, signal transduction, transcription, translation, transport, metabolism, immune response, and cell adhesion. The highest number of affected genes was linked to metabolism, with 8 genes up-regulated and 16 down-regulated by at least 1.5-fold in Tg rat testis (**Table 3**) [42].

RT-PCR was performed for 10 genes involved in cell adhesion, signal transduction, and transport: *Cnot7*, *Fgf7*, *Egfl6*, *Testin*, *Ostf1*, and *Atp2a2* (all up-regulated); and *Sh3bp4*, *Lamc2*, *Versican*, and *Mamdc1* (all down-regulated). As listed in **Table 4**, *Cnot7*, *Fgf7*, *Testin*, *Ostf1*, *Versican*, and *Mamdc1* were significantly up- or down-regulated, confirming microarray data. *Testin* is a signaling molecule responsible for monitoring Sertoli-germ cell adherens junctions. Increased secretion of testin by Sertoli cells causes disruption of these junctions [43, 44]. *Versican* is expressed in adult mouse brain, heart, lung, spleen, skeletal muscle, skin, tail, kidney, and

testis. It is suggested to play a role in cellular attachment, migration, and proliferation by interacting with cell surfaces and extracellular matrix molecules [45]. *Mamdc1*, a novel member of adhesion molecules of the immunoglobulin superfamily, is expressed in human Leydig cells of the testis. *Mamdc1* mRNA was shown to be up-regulated by pro-inflammatory cytokines, such as tumor necrosis factor- $\alpha$  and interferon- $\gamma$ , involved in cell adhesion, migration, and recruitment to inflammatory sites [46]. However, the function of *versican* and *mamdc1* in spermatogenesis has not yet been established. Expression of *Fgf7*, *Ostf1*, and *Cnot7* [47] also increased significantly, indicating a stress response in Tg rat testis. The roles of these genes are listed in **Table 5**.

Biological process	Gene number of expression changed		
	Decreased	Increased	Total
Apoptosis	1	4	5
Cell cycle	2	4	6
Development	3	16	19
Oxidative stress	0	1	1
Proteolysis	3	7	10
Signal transduction	2	11	13
Transcription	6	6	12
Translation	1	1	2
Transport	12	11	23
Immune response	1	2	3
Metabolism	8	16	24
Cell adhesion	3	4	7
Others	54	21	75
Total	96	104	200

Note: The affected genes were classified into 12 functional categories according to "Gene ontology".

Gene ontology classification of genes whose expression changes by at least .5-fold in Tg with respect to normal rats, as revealed by cDNA microarray analysis. Reproduced and modified from [42] with permission from the Society for Reproduction and Development.

**Table 3.** Number of affected genes in testes of HHV-1-TK Tg rats revealed by cDNA microarray.

Notably, the contraceptive adjuvin has been reported to induce morphological alterations in the seminiferous tubules similar to the ones we observed here, and target directly testin and actin-myosin [48]. However, the exact mechanism by which HHV-1-TK disrupts spermatogenesis and adherens junctions will require further work.

Gene product			Microarray analysis	Real-time PCR results	
Gene title	Gene symbol	Category	Ratio of TG value/N value	Expression levels TG/N	<i>p</i> value
<b>Up-regulated genes in TG rat testes</b>					
CCR4-NOT transcription complex, subunit 7	Cnot7	Signal transduction	18.40	1.30	<0.05
Fibroblast growth factor 7	Fgf7	Development	6.10	2.00	<0.05
EGF-like-domain, multiple 6	Egfl6	Cell adhesion	3.70	0.91	NS
Testin gene	Testin	Cell adhesion	2.30	2.00	<0.05
Osteoclast stimulating factor 1	Ostf1	Transcription	1.68	1.30	<0.05
ATPase, Ca <sup>2+</sup> transporting, cardiac muscle, slow twitch 2	Atp2a2	Transport	1.67	0.96	NS
<b>Down-regulated genes in TG rat testes</b>					
SH3-domain binding protein 4	Sh3bp4	Transport	0.06	0.91	NS
Lamimin, gamma 2	Lamc2	Cell adhesion	0.09	0.90	NS
Chondroitin sulfate proteoglycan 2	Versican	Cell adhesion	0.10	0.55	<0.05
MAM domain containing glycosylphosphatidylinositol anchor 2	Mamdc1	Cell adhesion	0.62	0.67	<0.05

Reproduced and modified from [42] with permission from the Society for Reproduction and Development.

**Table 4.** Expression level of genes assayed by microarray analysis and real-time PCR.

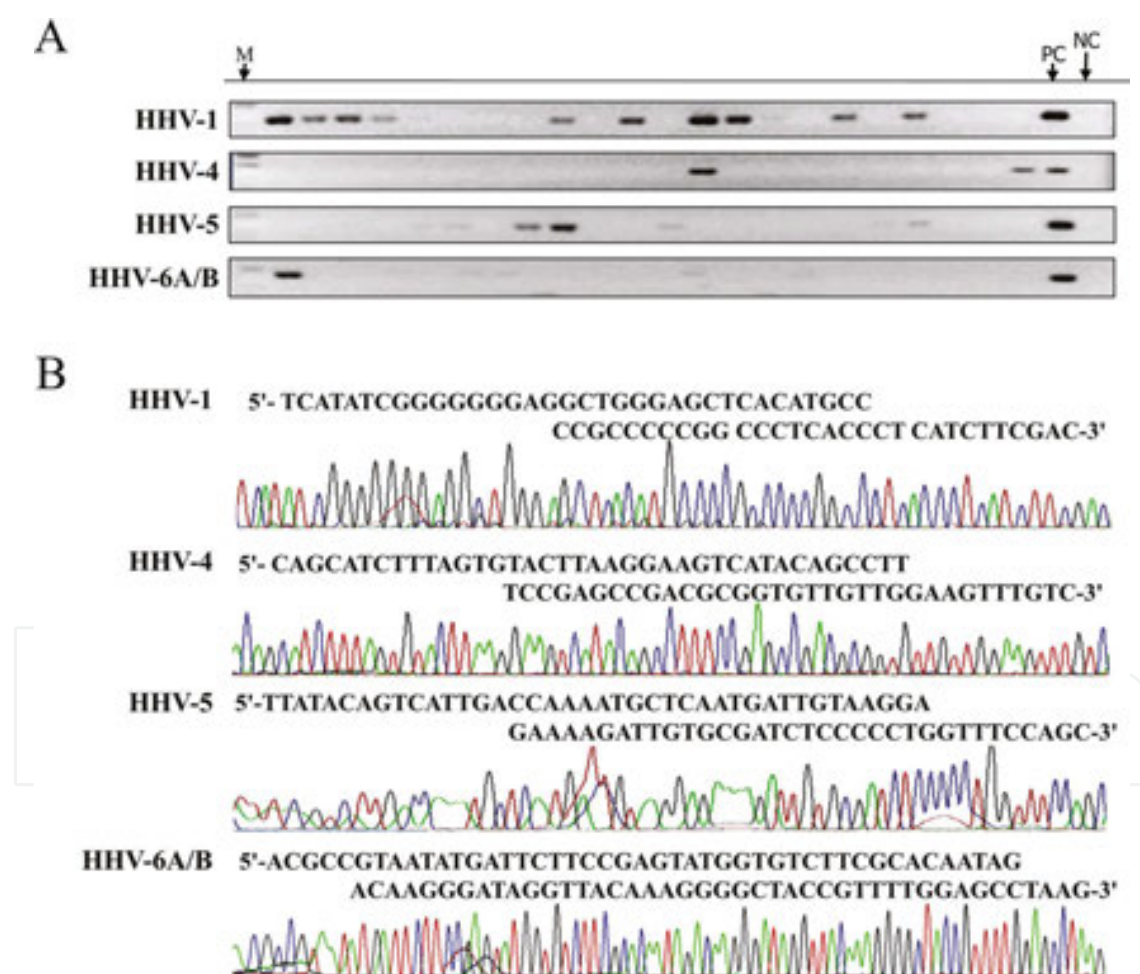
Gene name	Gene symbol	Category	Molecular function	Biological process
<b>Up-regulated genes in TG rat testes</b>				
CCR4-NOT transcription complex, subunit 7	Cnot7	Signal transduction	Has 3-5 poly(A) exoribonuclease activity, nucleic acid binding, transcription factor activity, catalytic component of the CCR4-NOT complex, cell proliferation factor, mRNA degradation, miRNA-mediated repression	spermatogenesis, tumor cell metastasis suppressor, bone metabolism, embryonic development, tumor suppressor

Gene name	Gene symbol	Category	Molecular function	Biological process
<b>Up-regulated genes in TG rat testes</b>				
Fibroblast growth factor 7	Fgf7	Development	chemoattractant activity, growth factor activity, mitogenic and cell survival activities activation of MAPKK activity actin cytoskeleton reorganization neurotrophin TRK receptor signaling pathway	embryonic development, cell growth, morphogenesis, tissue repair, tumor growth and invasion
Testin gene	Testin	Cell adhesion	regulation of cell motility, poly(A) RNA binding, zinc ion binding	cell adhesion, cell spreading, reorganization of the actin cytoskeleton, negative regulation of cell proliferation, tumor suppressor
Osteoclast stimulating factor 1	Ostf1	Transport	SH3 domain binding	induces bone resorption, enhancing osteoclast formation
<b>Down-regulated genes in TG rat testes</b>				
Chondroitin sulfate proteoglycan 2	Versican	Cell adhesion	interaction of integrins, anti-cell adhesion, regulation of cell motility, growth and differentiation, a key factor in inflammation hyaluronic acid binding,	embryonic development, embryonic cell migration important in the formation of the heart, neural crest cell migration, inhibit nervous system regeneration, axonal growth, tumor growth
MAM domain containing glycosyphosphatidylinositol anchor 2	Mamdc1	Cell adhesion	GPI-anchored protein, cell-cell interaction	neuron development and differentiation, neuronal migration, axon outgrowth, axon-target recognition

**Table 5.** The role of genes changed expression level significantly in Tg rats.

## 8. HHV-1-TK in human testis

Nested PCR for 4 types of HHVs was performed on 153 DNA samples prepared from human semen (**Figure 13**). Bands of 99, 150, 165, and 135 bp were observed for HHV-1, HHV-4, HHV-5, and HHV-6A/B (HHV-6A and 6B were detected together by common domains), respectively (**Figure 13A**). Samples showing positive bands by more than one PCR target indicated concomitant infection with multiple types of HHVs (**Figure 13A**). We identified nucleotide sequences corresponding to HHV-1, HHV-4, HHV-5, and HHV-6A/B (**Figure 13B**) in 39, 6, 33, and 3 patients, respectively, as summarized in **Table 6**. We observed double infection with HHV-1/HHV-5 (15 carriers), HHV-1/HHV-4 (1), HHV-1/HHV-6A/B (2) and HHV-4/HHV-5 (4). HHV-4 carriers presented a double infection 83% of the time, while for other HHVs it ranged from 46 to 66%.



**Figure 13.** Detection of HHVs genomic DNA in human semen by PCR. (A) Agarose gel electrophoresis of PCR products using HHV-specific primers and human semen as template DNA. PC (positive control) and NC (negative control) indicate reactions with control viral fragments and without DNA template, respectively. M, size marker. (B) Sequence profiles of representative PCR products. Viral sequences are shown below the nucleotide sequence. Reproduced and modified from [21] with permission from the Society for Reproduction and Development.

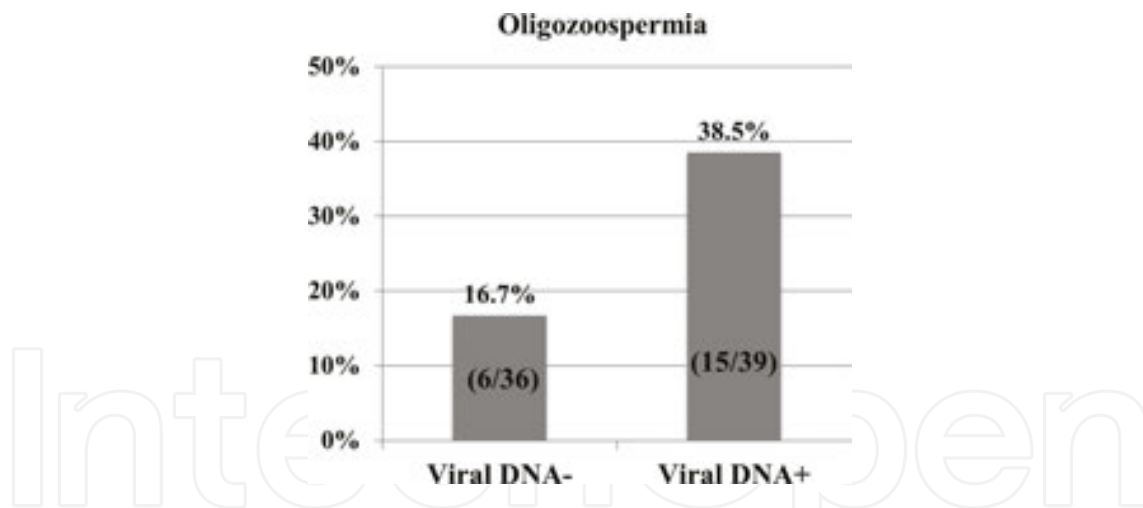
Number of virus infection in patients (153)				
Type	HHV-1	HHV-4	HHV-5	HHV-6A/B
Total	39 (25%)	6 (4%)	33 (22%)	3 (2%)
Number of double virus infection				
Type	HHV-1	HHV-4	HHV-5	HHV-6A/B
HHV-1	–	1	15	2
HHV-4	1	–	4	0
HHV-5	15	4	–	0
HHV-6A/B	2	0	0	–
Total	18/39 (46%)	5/6 (83%)	19/33 (58%)	2/3 (66%)

HHV-6A and 6B were detected together by common domains.

Reproduced and modified from [21] with permission from the Society for Reproduction and Development.

**Table 6.** Number of cases with single and double viral infection.

The viral DNA-positive group showed a higher incidence of oligozoospermia compared with the viral DNA-negative group (38.5 vs. 16.7%,  $P < 0.05$ ; **Figure 14**). Therefore, to further confirm the relationship between HHVs infection and changes to semen parameters, large-scale analysis according to WHO Guidelines (5<sup>th</sup> edition) is strongly suggested.



**Figure 14.** Comparison of oligozoospermia between viral DNA-negative and -positive groups. Analysis of oligozoospermia rates between viral DNA-negative (36 patients) and -positive (39 patients) according to WHO Guidelines (5<sup>th</sup> edition). Reproduced and modified from [21] with permission from the Society for Reproduction and Development.

## 9. Future perspectives

HHV-1 infection might strongly associate with human male infertility, possibly by testis-specific expression of the viral TK gene. However, conclusive evidence that HHV-1-TK causes male infertility is still missing.

As described above, HHV-1-TK is known as a suicide gene that kills target cells specifically in the presence of GCV. However, male infertility normally occurs in the presence of HHV-1 but absence of GCV. Degeneration of spermatogenesis was observed as early as 3 months in Tg rats ectopically expressing HHV-1-TK. With the exception of Sertoli cells, it later resulted in loss of germ cells, possibly by “bystander killing.” In contrast, no abnormality in the pituitary gland of Tg rats was observed. This difference may indicate tissue-specific action of HHV-1-TK in the testis, which does not occur in the pituitary gland. At present, it is unclear why HHV-1-TK targets testis over other tissues and how it induces degeneration of spermatogenesis. Further work is required to elucidate this and other features of HHV-related infertility.

Expression of HHV-1-TK may be the main cause of infertility in HHV-1-infected human males. To firmly establish a causative link, several players require identification: (1) target molecule(s) of HHV-1-TK; (2) the HHV-1-TK-dependent mechanism responsible for failed spermatogenesis; and (3) the mechanism dictating postmeiotic spermatid-specific expression of HHV-1-TK. The identification of target molecule(s) is particularly important, since there is no evidence that enzymatically active HHV-1-TK is required, raising speculation it may only serve as a binding protein. Even if HHV-1-TK functioned as an enzyme, the substrate(s) might be testis-specific. Currently, the only known activity of HHV-1-TK is to catalyze the transfer of the  $\gamma$ -phosphate from ATP to substrate nucleotides and analogs. Recently, a stable-isotope substrate ( $[\gamma\text{-}^{18}\text{O}_4]\text{ATP}$ ) for kinases has been developed [49]. Mass spectrometry could reveal the identity of  $[\gamma\text{-}^{18}\text{O}_4]\text{ATP}$ -labeled products obtained by incubating recombinant HHV-1-TK with testis homogenates. The identified HHV-1-TK target(s) may help elucidate the mechanisms determining failed spermatogenesis and postmeiotic spermatid-specific expression of HHV-1-TK. Moreover, knowing the target(s) molecular properties may help design appropriate analogs for pharmacological use. The significance of our results is particularly clear in view of expected novel male contraceptives and drugs for HHV-related male infertility.

## Author details

Mo Chen<sup>1,2</sup>, Li-yi Cai<sup>3</sup>, Takako Kato<sup>1,2</sup> and Yukio Kato<sup>3,4\*</sup>

\*Address all correspondence to: [yukato@isc.meiji.ac.jp](mailto:yukato@isc.meiji.ac.jp)

1 Organization for the Strategic Coordination of Research and Intellectual Property, Meiji University, Kawasaki, Kanagawa, Japan

2 Institute for Endocrinology, Meiji University, Kawasaki, Kanagawa, Japan

3 Center for Reproductive Medicine, Affiliated Wuxi Hospital for Maternal & Child Health Care of Nanjing Medical University, Wuxi, PR China

4 Department of Life Science, School of Agriculture, Meiji University, Kawasaki, Kanagawa, Japan

## References

- [1] Roizman B, Carmichael LE, Deinhardt F, de-The G, Nahmias AJ, Plowright W, Rapp F, Sheldrick P, Takahashi M, Wolf K. Herpesviridae. Definition, provisional nomenclature, and taxonomy. The Herpesvirus Study Group, the International Committee on Taxonomy of Viruses. *Intervirology*. 1981;16:201–17.
- [2] Fishman JA. Overview: cytomegalovirus and the herpesviruses in transplantation. *American Journal of Transplantation*. 2013;13 Suppl 3:1–8. DOI: 10.1111/ajt.12002
- [3] Grinde B. Herpesviruses: latency and reactivation – viral strategies and host response. *Journal of Oral Microbiology*. 2013;5:22766. DOI: 10.3402/jom.v5i0.22766
- [4] Ochsendorf FR. Sexually transmitted infections: impact on male fertility. *Andrologia*. 2008;40:72–5. DOI: 10.1111/j.1439-0272.2007.00825.x
- [5] el Borai N, Inoue M, Lefevre C, Naumova EN, Sato B, Yamamura M. Detection of herpes simplex DNA in semen and menstrual blood of individuals attending an infertility clinic. *The Journal of Obstetrics and Gynaecology Research*. 1997;23:17–24.
- [6] Bezold G, Schuster-Grusser A, Lange M, Gall H, Wolff H, Peter RU. Prevalence of human herpesvirus types 1-8 in the semen of infertility patients and correlation with semen parameters. *Fertility and Sterility*. 2001;76:416–8.
- [7] Garolla A, Pizzol D, Bertoldo A, Menegazzo M, Barzon L, Foresta C. Sperm viral infection and male infertility: focus on HBV, HCV, HIV, HPV, HSV, HCMV, and AAV. *Journal of Reproductive Immunology*. 2013;100:20–9. DOI: 10.1016/j.jri.2013.03.004
- [8] Barton IG, Kinghorn GR, Najem S, Al-Omar LS, Potter CW. Incidence of herpes simplex virus types 1 and 2 isolated in patients with herpes genitalis in Sheffield. *The British Journal of Venereal Diseases*. 1982;58:44–7.
- [9] Kapranos N, Petrakou E, Anastasiadou C, Kotronias D. Detection of herpes simplex virus, cytomegalovirus, and Epstein-Barr virus in the semen of men attending an infertility clinic. *Fertility and Sterility*. 2003;79 Suppl 3:1566–70.
- [10] Bezold G, Politch JA, Kiviat NB, Kuypers JM, Wolff H, Anderson DJ. Prevalence of sexually transmissible pathogens in semen from asymptomatic male infertility patients with and without leukocytospermia. *Fertility and Sterility*. 2007;87:1087–97. DOI: 10.1016/j.fertnstert.2006.08.109
- [11] Neofytou E, Sourvinos G, Asmarianaki M, Spandidos DA, Makrigiannakis A. Prevalence of human herpes virus types 1-7 in the semen of men attending an infertility clinic and correlation with semen parameters. *Fertility and Sterility*. 2009;91:2487–94. DOI: 10.1016/j.fertnstert.2008.03.074
- [12] Cai LY, Kato T, Ito K, Nakayama M, Susa T, Aikawa S, Maeda K, Tsukamura H, Ohta A, Izumi S, Kato Y. Expression of porcine FSHbeta subunit promoter-driven herpes



- simplex virus thymidine kinase gene in transgenic rats. *Journal of Reproduction and Development*. 2007;53:201–9.
- [13] Cai LY, Kato T, Nakayama M, Susa T, Murakami S, Izumi S, Kato Y. HSV type 1 thymidine kinase protein accumulation in round spermatids induces male infertility by spermatogenesis disruption and apoptotic loss of germ cells. *Reproductive Toxicology*. 2009;27:14–21. DOI: 10.1016/j.reprotox.2008.11.052
- [14] Himmel W, Ittner E, Kochen MM, Michelmann HW, Hinney B, Reuter M, Kallerhoff M, Ringert RH. Management of involuntary childlessness. *British Journal of General Practice*. 1997;47:111–8.
- [15] Brugh VM 3rd, Lipshultz LI. Male factor infertility: evaluation and management. *Medical Clinics of North America*. 2004;88:367–85. DOI: 10.1016/S0025-7125(03)00150-0
- [16] Hirsh A. Male subfertility. *British Medical Journal*. 2003;327:669–72. DOI: 10.1136/bmj.327.7416.669
- [17] Gimenes F, Souza RP, Bento JC, Teixeira JJ, Maria-Engler SS, Bonini MG, Consolaro ME. Male infertility: a public health issue caused by sexually transmitted pathogens. *Nature Reviews Urology*. 2014;11:672–87. DOI: 10.1038/nrurol.2014.285
- [18] Sethi S, Singh G, Samanta P, Sharma M. *Mycoplasma genitalium*: an emerging sexually transmitted pathogen. *Indian Journal of Medical Research*. 2012;136:942–55.
- [19] Nwankwo EO, Sadiq MN. Prevalence of *Chlamydia trachomatis* infection among patients attending infertility and sexually transmitted diseases clinic (STD) in Kano, North Western Nigeria. *African Health Sciences*. 2014;14:672–8. DOI: 10.4314/ahs.v14i3.24
- [20] Boitrelle F, Robin G, Lefebvre C, Bailly M, Selva J, Courcol R, Lornage J, Albert M. Bacteriospermia in assisted reproductive techniques: effects of bacteria on spermatozoa and seminal plasma, diagnosis and treatment. *Gynécologie Obstétrique & Fertilité*. 2012;40:226–34. DOI: 10.1016/j.gyobfe.2012.01.003
- [21] Chen M, Cai LY, Kanno N, Kato T, Lu J, Jin F, Wang H, Sekita M, Higuchi M, Yoshida S, Yako H, Ueharu H, Izumi S, Kato Y. Detection of human herpesviruses (HHVs) in semen of human male infertile patients. *Journal of Reproduction and Development*. 2013;59:457–62. DOI: 10.1262/jrd.2013-023
- [22] Monini P, de Lellis L, Fabris M, Rigolin F, Cassai E. Kaposi's sarcoma-associated herpesvirus DNA sequences in prostate tissue and human semen. *The New England Journal of Medicine*. 1996;334:1168–72.
- [23] Eggert-Kruse W, Reuland M, Johannsen W, Strowitzki T, Schlehofer JR. Cytomegalovirus (CMV) infection-related to male and/or female infertility factors?. *Fertility and Sterility*. 2009;91:67–82. DOI: 10.1016/j.fertnstert.2007.11.014
- [24] Michou V, Liarmakopoulou S, Thomas D, Tsimaratou K, Makarounis K, Constantoulakis P, Angelopoulou R, Tsilivakos V. Herpes virus infected spermatozoa following

- density gradient centrifugation for IVF purposes. *Andrologia*. 2012;44:174–80. DOI: 10.1111/j.1439-0272.2010.01121.x
- [25] Thomas R, Macsween KF, McAulay K, Clutterbuck D, Anderson R, Reid S, Higgins CD, Swerdlow AJ, Harrison N, Williams H, Crawford DH. Evidence of shared Epstein-Barr viral isolates between sexual partners, and low level EBV in genital secretions. *Journal of Medical Virology*. 2006;78:1204–9.
- [26] Naumenko VA, Tyulenev YA, Yakovenko SA, Kurilo LF, Shileyko LV, Segal AS, Zavalishina LE, Klimova RR, Tsibizov AS, Alkhovskii SV, Kushch AA. Detection of human cytomegalovirus in motile spermatozoa and spermatogenic cells in testis organotypic culture. *Herpesviridae*. 2011;2:7. DOI: 10.1186/2042-4280-2-7
- [27] Monavari SH, Vaziri MS, Khalili M, Shamsi-Shahrabadi M, Keyvani H, Mollaei H, Fazlalipour M. Asymptomatic seminal infection of herpes simplex virus: impact on male infertility. *Journal of Biomedical Research*. 2013;27:56–61. DOI: 10.7555/JBR.27.20110139
- [28] Kaspersen MD, Larsen PB, Kofod-Olsen E, Fedder J, Bonde J, Hollsborg P. Human herpesvirus-6A/B binds to spermatozoa acrosome and is the most prevalent herpesvirus in semen from sperm donors. *PLoS One*. 2012;7:e48810. DOI: 10.1371/journal.pone.0048810
- [29] Godet AN, Soignon G, Koubi H, Bonnafous P, Agut H, Poirot C, Gautheret-Dejean A. Presence of HHV-6 genome in spermatozoa in a context of couples with low fertility: what type of infection?. *Andrologia*. 2015;47:531–5. DOI: 10.1111/and.12299
- [30] Naumenko V, Tyulenev Y, Kurilo L, Shileiko L, Sorokina T, Evdokimov V, Yakovleva V, Kovalyk V, Malolina E, Kulibin A, Gomberg M, Kushch A. Detection and quantification of human herpes viruses types 4-6 in sperm samples of patients with fertility disorders and chronic inflammatory urogenital tract diseases. *Andrology*. 2014;2:687–94. DOI: 10.1111/j.2047-2927.2014.00232.x
- [31] Diafouka F, Foulongne V, Hauhouot-Attoungbre ML, Monnet D, Segondy M. Cytomegalovirus DNA in semen of men seeking fertility evaluation in Abidjan, Cote d'Ivoire. *European Journal of Clinical Microbiology & Infectious Diseases*. 2007;26:295–6. DOI: 10.1007/s10096-007-0271-y
- [32] Greco O, Dachs GU. Gene directed enzyme/prodrug therapy of cancer: historical appraisal and future perspectives. *Journal of Cellular Physiology*. 2001;187:22–36. DOI: 10.1002/1097-4652(2001)9999:9999<::AID-JCP1060>3.0.CO;2-H
- [33] Spencer DM. Developments in suicide genes for preclinical and clinical applications. *Current Opinion in Molecular Therapeutics*. 2000;2:433–40.
- [34] Chen H, Beardsley GP, Coen DM. Mechanism of ganciclovir-induced chain termination revealed by resistant viral polymerase mutants with reduced exonuclease activity.

- Proceedings of the National Academy of Sciences of the United States of America. 2014;111:17462–7. DOI: 10.1073/pnas.1405981111
- [35] Smee DF, Martin JC, Verheyden JP, Matthews TR. Anti-herpesvirus activity of the acyclic nucleoside 9-(1,3-dihydroxy-2-propoxymethyl)guanine. *Antimicrobial Agents and Chemotherapy*. 1983;23:676–82.
- [36] St Clair MH, Lambe CU, Furman PA. Inhibition by ganciclovir of cell growth and DNA synthesis of cells biochemically transformed with herpesvirus genetic information. *Antimicrobial Agents and Chemotherapy*. 1987;31:844–9.
- [37] Moolten FL. Tumor chemosensitivity conferred by inserted herpes thymidine kinase genes: paradigm for a prospective cancer control strategy. *Cancer Research*. 1986;46:5276–81.
- [38] Tomicic MT, Thust R, Kaina B. Ganciclovir-induced apoptosis in HSV-1 thymidine kinase expressing cells: critical role of DNA breaks, Bcl-2 decline and caspase-9 activation. *Oncogene*. 2002;21:2141–53. DOI: 10.1038/sj.onc.1205280
- [39] Hamel W, Magnelli L, Chiarugi VP, Israel MA. Herpes simplex virus thymidine kinase/ganciclovir-mediated apoptotic death of bystander cells. *Cancer Research*. 1996;56:2697–702.
- [40] al-Shawi R, Burke J, Wallace H, Jones C, Harrison S, Buxton D, Maley S, Chandley A, Bishop JO. The herpes simplex virus type 1 thymidine kinase is expressed in the testes of transgenic mice under the control of a cryptic promoter. *Molecular and Cellular Biology*. 1991;11:4207–16.
- [41] Ellison AR, Bishop JO. Herpesvirus thymidine kinase transgenes that do not cause male sterility are aberrantly transcribed and translated in the testis. *Biochimica et Biophysica Acta*. 1998;1442:28–38.
- [42] Cai LY, Kato T, Chen M, Wang H, Sekine E, Izumi S, Kato Y. Accumulated HSV1-TK proteins interfere with spermatogenesis through a disruption of integrity of sertoli-germ cell junctions. *Journal of Reproduction and Development*. 2012;58:544–51.
- [43] Cheng CY, Silvestrini B, Grima J, Mo MY, Zhu LJ, Johansson E, Saso L, Leone MG, Palmery M, Mruk D. Two new male contraceptives exert their effects by depleting germ cells prematurely from the testis. *Biology of Reproduction*. 2001;65:449–61.
- [44] Cheng CY, Mruk DD. Cell junction dynamics in the testis: Sertoli-germ cell interactions and male contraceptive development. *Physiological Reviews*. 2002;82:825–74. DOI: 10.1152/physrev.00009.2002
- [45] Naso MF, Morgan JL, Buchberg AM, Siracusa LD, Iozzo RV. Expression pattern and mapping of the murine versican gene (*Cspg2*) to chromosome 13. *Genomics*. 1995;29:297–300. DOI: 10.1006/geno.1995.1251
- [46] Hellquist A, Zucchelli M, Lindgren CM, Saarialho-Kere U, Jarvinen TM, Koskenmies S, Julkunen H, Onkamo P, Skoog T, Panelius J, Raisanen-Sokolowski A, Hasan T, Widen

- E, Gunnarson I, Svenungsson E, Padyukov L, Assadi G, Berglind L, Makela VV, Kivinen K, Wong A, Cunningham Graham DS, Vyse TJ, D'Amato M, Kere J. Identification of MAMDC1 as a candidate susceptibility gene for systemic lupus erythematosus (SLE). *PLoS One*. 2009;4:e8037. DOI: 10.1371/journal.pone.0008037
- [47] Aslam A, Mittal S, Koch F, Andrau JC, Winkler GS. The Ccr4-NOT deadenylase subunits CNOT7 and CNOT8 have overlapping roles and modulate cell proliferation. *Molecular Biology of the Cell*. 2009;(20):3840–50. DOI: 10.1091/mbc.E09-02-0146
- [48] Mruk DD, Cheng CY. Testin and actin are key molecular targets of adjuvin, an anti-spermatogenic agent, in the testis. *Spermatogenesis*. 2011;1:137–46. DOI: 10.4161/spmg.1.2.16449
- [49] Molden RC, Goya J, Khan Z, Garcia BA. Stable isotope labeling of phosphoproteins for large-scale phosphorylation rate determination. *Molecular & Cellular Proteomics*. 2014;13:1106–18. DOI: 10.1074/mcp.O113.036145

