

We are IntechOpen, the world's leading publisher of Open Access books Built by scientists, for scientists

4,800

Open access books available

122,000

International authors and editors

135M

Downloads

Our authors are among the

154

Countries delivered to

TOP 1%

most cited scientists

12.2%

Contributors from top 500 universities



WEB OF SCIENCE™

Selection of our books indexed in the Book Citation Index
in Web of Science™ Core Collection (BKCI)

Interested in publishing with us?
Contact book.department@intechopen.com

Numbers displayed above are based on latest data collected.

For more information visit www.intechopen.com



Herpesviruses in Periapical Pathoses: An Updated Systematic Review

Aleksandar Jakovljević, Miroslav Andrić,
Aleksandra Knežević, Katarina Beljić-Ivanović,
Maja Miletić, Tanja Jovanović, Ljiljana Kesić and
Jelena Milašin

Additional information is available at the end of the chapter

<http://dx.doi.org/10.5772/64004>

Abstract

Apical periodontitis represents a chronic inflammation and destruction of periradicular tissue caused by polymicrobial infection of endodontic origin. The aim of this systematic review was to make an update on findings related to Epstein-Barr virus (EBV) and human cytomegalovirus (HCMV) presence in periapical pathoses and to correlate these findings with clinical, histopathological and radiographic features of periapical lesions. Methods were based on the preferred reporting items for systematic reviews and meta-analyses (PRISMA) statement. A search was performed using PubMed, Web of Science and SCOPUS. Search key words included the following medical subjects heading terms: (periapical disease OR apical periodontitis OR periapical lesions OR periapical abscess) AND (viruses OR herpesvir*). A manual search involved references from articles retrieved for possible inclusion. The search, evaluation, and critical appraisal of articles were performed by two independent judges. Collected data were analyzed using the measures of descriptive statistics. The final review has included twenty nine articles related to herpesviral presence periapical pathoses. Qualitative analysis indicated that EBV HCMV, and HHV-8 were the most prevalent species in periapical pathoses. Our findings suggest that there is wide variety of herpesviruses detection rates in periapical pathoses in relation to their clinical, histopathological and radiographic features.

Keywords: periapical disease, apical periodontitis, periapical abscess, human cytomegalovirus, Epstein-Barr virus

1. Introduction

Apical periodontitis represents an inflammatory process within the periapical tissues. It is characterized by chronic inflammation and destruction of tooth-supporting tissues around the apex of a tooth root [1]. It represents a remarkably prevalent condition [2]. In Europe, the prevalence of apical periodontitis is estimated at 34–61% of individuals and 2.8–4.2% of the teeth [3] and increases with age [4]. Although various chemical and physical factors are able to induce periapical inflammation, overwhelming evidences indicate that polymicrobial infection of endodontic origin is essential for its development [5, 6].

The relationship between periapical inflammation and root canal bacterial infection is well established [7–9]. In the classic study by Kakehashi et al. [7], rats subjected to surgical exposure and maintained in a conventional microbial environment uniformly developed pulpal necrosis and periapical inflammation. In contrast, germ-free animals exhibited no periapical destruction and formed reparative dentin at damaged sites. Subsequent study by Sundquist [8] confirmed the causative relationship between pulpal infection and periapical lesion development. He showed that traumatized but non-infected necrotic pulps did not result in periapical pathoses, whereas pulpal necrosis associated with pathogenic bacteria led to periapical breakdown [8]. These studies confirmed that pulpal infection appears to be an absolute essential for the development and progression of periapical inflammation.

Endodontic infection develops only in root canals of teeth devoid of vital pulp and their defence mechanisms. This may be consequence of pulpal necrosis because of dental caries, trauma to the tooth, attrition, abrasion, and iatrogenic operative procedures, but also due to removal of the pulp tissue for the previous root canal treatment [6]. Microorganisms can reach the pulp through various routes. The major pathways of pulpal contamination are direct pulp exposure, exposed dentinal tubules, lateral and apical accessory canals, and blood-transmitted bacteria. Once the infection is established in the root canal, bacteria may contact the periradicular tissues via apical and later foramina or root perforations and induce an acute or chronic inflammatory response [10].

Endodontic infections develop in a previously sterile place which does not contain any microorganisms. Therefore, any species found in the root canal has the potential to be an endodontic pathogen or at least to play a role in the ecology of the microbial community. However, the virulence and pathogenicity of individual species vary considerably and can be affected in the presence of other microbes [11]. Culture-dependent and culture-independent microbiological studies have identified more than 1000 different bacterial species/phylotypes in the oral cavity [12]. Subsequent studies by Siqueira [13, 14] revealed that over 460 different microbial species/phylotypes make the current list of endodontic pathogens. At high phylogenetic levels, endodontic bacteria fall into 15 phyla, with the most common species/phylotypes belonging to the phyla *Firmicutes*, *Bacteroides*, *Actinobacteria*, *Fusobacteria*, *Proteobacteria*, *Spirochetes*, and *Synergistetes* [15–17]. These microbiota are organized in a structure resembling biofilm [18, 19]. The biofilm community represents a complex biological system that is structurally and dynamically organized. Population of cells is strategically positioned for

optimal metabolic interaction, and the resultant architecture favours the physiology and ecological role of the community [11].

Traditionally, endodontic infections have been classified as either primary or secondary. Primary root canal infection is caused by microorganisms that initially invade and colonize the necrotic pulp tissue, while secondary infection is caused by microorganisms that were not present in the primary infection, but were introduced in the root canal at some time after professional intervention. Additionally, persistent infection is caused by microorganisms that were members of primary or secondary infection which resisted intracanal antimicrobial procedures [6]. Secondary or persistent infections are the major causes of persistent apical periodontitis, which is basically a direct consequence of failure of endodontic treatment [13].

Periapical inflammation is a direct result of interactions between the bacteria inside the infected root canal system and the host's immune system. Apical inflammatory process serves two purposes: one is to try to remove the bacteria, while the other is to prevent microbial invasion into the periapical tissues [1, 10]. The initial response to bacterial presence will be an acute inflammatory reaction, known as acute apical periodontitis. It is of short duration and occurs within a previously healthy periapical region. If bacterial irritation in pulp and periapical tissues remains constant, it may then follow several possible courses such as further intensification, abscess formation, spreading of the infection through bone and/or soft tissues (i.e. cellulitis), or it may become chronic (i.e. chronic apical periodontitis). Continued presence of irritants in the apical part of the root canal system shifts acute inflammation gradually to a chronic inflammatory reaction, known histologically as a periapical granuloma [5, 20].

Histopathologically, the periapical granuloma consists of granulomatous tissue with inflammatory cells infiltrate, fibroblasts, and well-developed fibrous capsule [1, 10, 21]. Nair et al. [22, 23] performed serial sectioning of histological samples and had shown that more than 45% of all chronic apical granulomas were epithelialized.

The extra-epithelial tissues predominantly consist of inflammatory cells infiltrate [24–32]. Cellular composition of periapical lesions varies significantly, depending on the stage of lesion development and its progression, histological characteristics, presence or absence of clinical symptoms, and methods used for detection and quantification of inflammatory cells [33]. The main finding is that lymphocytes and macrophages are the predominant population of infiltrating cells. Among the lymphocytes, T cells are likely to be more numerous at certain stages than B cells [24–26], and CD4+ helper cells may outnumber CD8+ cytotoxic cells [29–31]. Additionally, T-helper type 1 (Th 1) lymphocytes characterize early forms of apical periodontitis. This suggests a role for Th 1 cells in the initiation and expansion of periapical lesions [34, 35]. The abundance of B lymphocytes, plasma cells, CD8+ cytotoxic/suppressor T cells, and Th 2 cells in late periapical granulation tissues suggests that these cells participate in lesion stabilization and possible healing [34, 35].

Periapical cysts (radicular cysts) are believed to be a direct sequel of chronic apical granulomas although not every granuloma develops into a cyst [1, 5, 36]. The reported incidence of cysts among apical periodontitis lesions varies from 6 to 55%. Although more than 50% of all lesions are epithelialized, investigation based on serial sectioning showed that the incidence of cysts

among those lesions may be well below 20% [23, 37, 38]. There are two distinct categories of periapical cysts. A periapical pocket cyst is a sac-like epithelium-lined cavity that is open to and continuous with the root canal. On the other hand, a periapical true cyst has the cavity completely enclosed in an epithelial lining and there is no communication with the root canal [23, 38]. The four major histological components of true apical cysts are the cyst cavity, a complete epithelial lining of the cystic wall, extra-epithelial tissue and the collagenous capsule. The tissue between the epithelial lining and the fibrous capsule usually consists of numerous blood vessels and inflammatory cells [5, 26]. More than half of cystic lesions are true apical cysts, and the remainder are apical pocket cysts [23, 38].

Apart from its chronic forms, apical periodontitis can manifest itself in different clinical ways, including the development of an acute abscess [39]. An abscess is defined as a localized collection of pus inside the cavity formed by tissue liquefaction. The acute apical abscess is the most common form of dental abscess and is usually a sequel of an endodontic infection [40]. Along with Gram-negative dark-pigmented anaerobic bacteria of the genera *Prevotella*, *Porphyromonas*, and *Fusobacterium*, Gram-positive cocci, specifically peptostreptococci and streptococci, comprise the most frequently detected bacteria in apical abscess samples [41–44]. Apical abscesses may be either acute or chronic, and an acute apical abscess may be either a primary or secondary lesion. The purulent exudate formed in response to root canal infection spreads through the medullary bone to perforate the cortical bone and discharge into submucous or subcutaneous soft tissue. The spread of endodontic infections into fascial spaces is determined by the location of the root tip of the involved tooth in relation to its overlying buccal or lingual cortical plane, the thickness of the overlying bone, and the relationship of the apex to the attachments of surrounding muscles [45, 46]. Delayed or inappropriate treatment of acute apical abscess may result in spreading of infection and cause severe and/or life-threatening complications such as deep neck infections [47], mediastinitis [48], necrotizing fasciitis [49], orbital and brain abscess [50, 51], and cervical spondylodiscitis with spinal epidural abscess [52].

Although there is a clear implication of microbiological factors in the development of apical periodontitis, host-related factors, otherwise known as disease modifiers, are able to influence the outcomes of apical periodontitis. In this regard, the influence of various systemic conditions and genetic background of patients in the development of apical periodontitis have been extensively investigated [53, 54]. The results of studies conducted so far are not conclusive, but suggest an association between apical periodontitis and systemic disease such as diabetes mellitus. There is evidence associating diabetes mellitus with higher prevalence of apical periodontitis, greater size of periapical lesions, greater likelihood of asymptomatic infections, and delayed periapical repair [55–57]. On the other hand, some data suggest that chronic periapical disease may contribute to diabetic metabolic dyscontrol [58]. Although diabetic patients are apparently more prone to develop severe forms of apical periodontitis, no study so far reported the prevalence of endodontic abscesses in diabetic patients.

Genetic polymorphisms are another factor which can make individuals more prone to develop acute infections. Previously reported studies have hypothesized that polymorphisms in cytokine genes may contribute to an individual's increased susceptibility to periapical tissue

destruction [59, 60]. Single nucleotide polymorphisms in variety of cytokine-encoding genes, including those for tumour necrosis factor (TNF)- α , interleukin (IL)-1 β , IL-6, IL-8, IL-10, were correlated with clinical and radiographic features of apical periodontitis lesions and development of acute apical abscesses [61–63].

Apart from bacteria, various species of other microorganisms, including herpesviruses, have been associated with periapical pathosis. In 1958, Rauch [64] assumed that, apart from bacteria, another causative factor contributing to development of periapical granuloma may be a viral one. In this in vitro study, samples were taken from infected root canals and periapical tissue by means of paper point method. He used monkey kidney cells to inoculate them with the medium in which the paper points were stored. However, using this method, isolates from 10 patients were negative. Subsequent study by Shindell [65] analysed the presence of viruses in HeLa and human amnion cell cultures inoculated by periapical tissues of four patients. He also reported negative results from this experiment and concluded that based on his and previously reported results by Rauch, periapical granulomas are not associated with viral infection.

Over the past 25 years, data on possible involvement of herpesviruses in the development of periodontal tissue diseases have gradually accumulated in scientific literature. By the mid-1990s, Parra and Slots [66] and Contreras and Slots [67] detected several viral transcripts in periodontal pockets using polymerase chain reaction (PCR). They concluded that periodontal tissue breakdown occurs more frequently and progresses more rapidly in herpesvirus-infected than in herpesvirus-free periodontal sites. The same group of authors proposed herpesviruses as a putative pathogen in destructive periodontal disease. After these findings, Sabeti et al. [68, 69] hypothesized that concomitant herpes viral infection may contribute to the pathogenesis of apical periodontitis in the same way as it has been proposed for marginal periodontitis. Epidemiological studies carried out since the mid-2000s have identified Epstein–Barr virus (EBV) and human cytomegalovirus (HCMV) as the frequently detected species of the *Herpesviridae* family in apical periodontitis [70].

Of the approximately 120 identified herpesviruses, eight major types with distinct biological and clinical characteristics are known to infect humans, namely herpes simplex virus (HSV), varicella-zoster virus (VZV), EBV, HCMV, human herpesvirus (HHV)-6, HHV-7, and HHV-8 (Kaposi's sarcoma virus). The name of this virus family is derived from the Greek word *herpain*, meaning "to creep", which reflects the features of those viruses, namely latent and recurring infections. Till now, more than 5000 different strains of herpesviruses have been identified. Membership in the family *Herpesviridae* is based on a four-layer structure of the virion. The prototypical structure of herpesviruses consists of a double-strained DNA genome encased within an icosahedral capsid, a proteinaceous tegument, and a lipid-containing envelope embedded viral glycoproteins [71–73]. Of particular importance is that these viruses share the property to persist during the host lifetime and hold the ability to be reactivated at some point in time, under the influence of several stimuli. Humans are the only source of infection for these eight herpesviruses.

Despite the fact that numerous studies have analysed the relationship between herpesviral infection and apical periodontitis, its exact role in the etiopathogenesis of periapical lesions

has not yet been completely elucidated. Up to now, two distinct theories have emerged. The findings of Slots et al. [74–76] within the past 15 years have established a hypothesis that herpesviruses may be implicated in the pathogenesis of apical periodontitis as a direct result of viral infections or as a result of a virally induced impairment of local host defence that favours bacterial overgrowth. These hypotheses are based on direct cytopathogenic effects of herpesviral infection on fibroblasts, keratinocytes, endothelial cells, inflammatory cells, and possibly bone cells. Study by Ongradi et al. [77] showed impaired functions of neutrophils in subjects who carried herpesviruses in oral lymphocytes and epithelial cells in comparison with virus-free persons. Moreover, it has been shown that fibroblast infected with herpesviruses may hamper tissue turnover and repair in regenerative periodontal therapy [78]. Herpesvirus infection induces host's antiviral innate and adaptive immune responses. These immune responses are incapable of eradicating viral infection, but they are effective in controlling viral replication and preventing clinical manifestations of a disease. Indirectly, herpesvirus-induced impairment of local host's defence causes upgrowth of resident bacteria in apical periodontium. Contreras and Slots [71] have reported that herpesviral proteins expressed on eukaryotic cells may act as new bacterial binding sites. Additionally, these interactions between herpesviruses and endodontic bacteria are probably bidirectional, since bacterial enzymes or other inflammatory-inducing factors have the potential to turn over herpesviral infection into active stage [76].

In contrast to herpesviral–bacterial hypothesis, Ferreira et al. [79, 80] hypothesized that the occurrence of herpesviruses might be just an epiphenomenon to bacterial infection that caused inflammation of periapical tissues and consequent influx of virus-infected inflammatory cells to the periapical area. Since herpesviruses can persistently occur in the human body by infecting defence cells, the mere presence of viral DNA in clinical samples does not necessarily imply a role in disease pathogenesis.

In our previous systematic review [70], herpesviral infection has been correlated with clinical features of apical periodontitis. Pooled results of six studies included in meta-analysis showed that the occurrence of HCMV or EBV did not significantly differ between symptomatic and asymptomatic apical periodontitis. The necessity for updated systematic review comes from several reasons. In the last 2 years, several studies reported new data on herpesviral occurrence in apical periodontitis lesions. Moreover, in previous systematic review, data of herpesviruses infection were not correlated with radiographic and histopathological features of apical periodontitis. Additionally, previous report did not analyse the occurrence of herpesviruses in samples of acute apical abscess.

All these issues pointed to the necessity to make an updated systematic review on herpesviral occurrence in periapical pathoses and to correlate these findings with clinical, histopathological, and radiographic features of apical periodontitis and acute apical abscess. In addition, the occurrence of herpesviral infection in relation to levels of proinflammatory mediators, the presence of different strains of herpesviruses and herpesviral–bacterial co-infection in periapical pathoses will be analysed.

2. Materials and methods

To address the research questions, we designed and implemented a systematic review based on the PRISMA (preferred reporting items for systematic reviews and meta-analyses) statement. The search, evaluation of relevant articles, and their critical appraisal were performed by two independent judges (A.J. and M.A.) blinded to each other.

In the first round, a comprehensive literature search was performed using electronic databases: PubMed, Web of Science, and Scopus. All mentioned databases provide the article title, abstract, and key words. Search key words included the following medical subjects heading (MeSH) terms: (periapical disease OR apical periodontitis OR periapical lesions OR periapical abscess) AND (viruses OR herpesvir*). A manual search involved reference lists from identified articles for possible inclusion of additional relevant studies. The language of the publication was restricted to English. Electronic and manual searches were last conducted on December 20, 2015.

In the second round, the title and abstract of retrieved articles were screened. For studies appearing to be relevant and for those with insufficient data in the title and abstract to make a clear decision, the full texts were obtained. After the full-text assessment, articles were submitted to final eligibility evaluation by the same two judges. Inclusion and exclusion criteria are presented in **Tables 1** and **2**. Only articles that met all eligibility criteria were marked as accepted and included in the third round.

-
- Article types: original scientifically papers, case series, and short communications
 - Studies in which human subjects were in good general health (American Society of Anesthesiology status classification system I and II) and without immunosuppressive and antiviral therapy 6 months prior to examination
 - Documented data of herpesviral infection in apical periodontitis and periapical abscess tissue samples
 - Clear statement of the method (reverse transcriptase PCR, real-time PCR, nested PCR, multiplex PCR, immunohistochemistry, in situ hybridization, and flow cytometry) used for viral detection
 - Studies with at least 5 patients without periodontally involved teeth (no probing depth >4 mm)
-

Table 1. Eligibility—inclusion criteria.

-
- Article types: in vitro study, animal study, case report, and review article
 - The publication was based on a population that was part of another study
 - Prevalence rates and data that allowed their calculation were absent
-

Table 2. Eligibility—exclusion criteria 1.

In the third round, each article was critically appraised by authors who were evaluating the methodological quality of all selected articles. Articles excluded from this phase and the reasons for exclusion are presented in **Table 3**. From remaining 29 articles, data on clinical,

histopathological, and radiographic characteristics of study subjects, occurrence of herpesviruses among examined sample, viral diagnostic methods, etc. were extracted and tabulated. Collected data were qualitatively analysed using measures of descriptive statistics. Any different findings in each round were settled by discussion, and discrepancies between reviewers were resolved by consensus with a third party.

Reasons for exclusion	Author, year [reference numbers]
In vitro study design	Rauch 1958 [64]; Shindelle 1962 [65]
Case report study design	Gregory et al. 1975 [106];
No documented data of herpesviral DNA, cDNA, and/or mRNA in tissue sample.	Goon et al. 1988 [107]; Wadden 1991 [108]; Ramchandani et al. 2007 [109]; Gupta et al. 2015 [110];

cDNA, complementary DNA; mRNA, messenger RNA.

Table 3. Articles excluded after critical appraisal.

3. Results

The electronic database and manual searches last updated on December 20, 2015, yielded 57 hits from PubMed, 63 hits from Web of Science and 87 hits from Scopus. The total number of articles after duplicates were removed was 150. A manual reference list search did not provide any relevant titles that were not found already by the electronic database research. Thirty-seven articles were considered relevant to the topic after abstract screening. Full texts of these 37 articles were evaluated using the eligibility criteria listed in **Tables 1** and **2**. Eight articles did not meet one or more of the eligibility criteria. These articles were excluded, and the reasons for exclusion are listed in **Table 3**. Twenty-nine articles were accepted for the final review (**Table 4**). Twenty-four articles were related to herpesviral finding in chronic periapical lesions, and five articles analysed the occurrence of herpesviruses in acute apical abscess lesions. A literature search flow diagram is presented in **Figure 1**. All studies in the final review were cross-sectional.

Author, year [reference numbers]	Specimens number and type	Specimens collected in conjunct with	Method of analysis
Rider et al. 1995 [81]	n = 20, radicular cysts	Cyst enucleation	Immunohistochemical analysis
Heling et al. 2001 [82]	n = 46, pulp tissue—irreversible pulpitis (11); pulp tissue—necrotic	Apicoectomy, Tooth extraction	PCR (DNA)

Author, year [reference numbers]	Specimens number and type	Specimens collected in conjunct with	Method of analysis
	pulp (17); periapical lesions (10); control pulpal tissue (8)		
Sabeti et al. 2003a [68]	n = 16, periapical lesions (14); control specimens (2)	Apicoectomy	RT-PCR (RNA, cDNA)
Sabeti et al. 2003b [69]	n = 14, periapical lesions;	Apicoectomy	RT-PCR (RNA, cDNA)
Sabeti et al. 2003c [83]	n = 5, periapical lesions;	Apicoectomy	RT-PCR (RNA, cDNA)
Sabeti et al. 2004 [84]	n = 34, periapical lesions;	Apicoectomy	RT-PCR (RNA, cDNA)
Slots et al. 2004 [85]	n = 44, periapical pathosis;	Apicoectomy	RT-PCR (RNA, cDNA)
Kabak et al. 2005 [86]	n = 57, periapical lesions;	Apicoectomy Tooth extraction	Immunohistochemical analysis
Yildirim et al. 2006 [87]	n = 24, granulomatous tissue (12); control pulpal tissue (12)	Tooth extraction	PCR (DNA)
Saboa-Dantas et al. 2007 [88]	n = 35, granulomas (n = 29); cysts (6)	Tooth extraction	Immunohistochemical analysis
Andric et al. 2007 [89]	n = 43, periapical cysts (n = 33); odontogenic keratocysts—control specimens (n = 10);	Apicoectomy	PCR (DNA)
Yazdi et al. 2008 [90]	n = 50, apical periodontitis;	Apicoectomy	RT-PCR (RNA, cDNA)
Sunde et al. 2008 [91]	n = 40, apical periodontitis;	Apicoectomy	Real-time PCR (DNA), In situ hybridization, Immunohistochemical analysis
Sabeti et al. 2009 [92]	n = 15, periapical lesions;	Tooth extraction	Flow cytometry
Li et al. 2009 [93]	n = 72, apical periodontitis (30); previously treated teeth with apical periodontitis (23); healthy pulp control (19)	Apicoectomy, Tooth extraction	RT-PCR (RNA, cDNA), Nested PCR, PCR (DNA)
Chen et al, 2009 [94]	n = 50, acute apical abscess (31); healthy pulp control (19)	Needle aspiration	PCR, Nested PCR (DNA)

Author, year [reference numbers]	Specimens number and type	Specimens collected in conjunct with	Method of analysis
Hernandi et al. 2010 [95]	n = 80, apical periodontitis (40); healthy pulp control (40)	Apicoectomy	RT-PCR (RNA, cDNA), Nested PCR, PCR (DNA)
Ferreira et al. 2011a [79]	n = 50, acute apical abscess (23); healthy pulp control (5)	Needle aspiration	PCR, Multiplex nested PCR (DNA)
Ferreira et al. 2011b [80]	n = 33, acute apical abscess (33)	Needle aspiration	PCR, Multiplex nested PCR (DNA)
Hernandi et al. 2011 [96]	n = 80, apical periodontitis (40); healthy pulp control (40)	Apicoectomy	RT-PCR (RNA, cDNA), Nested PCR, PCR (DNA)
Sabeti et al. 2012 [97]	n = 15, periapical lesions	Apicoectomy	Real-time RT-PCR (RNA, cDNA)
Hernandi et al. 2013 [98]	n = 78, apical periodontitis (58); gingival tissue (20);	Apicoectomy	Nested PCR, Real-time PCR (DNA)
Ozbek et al. 2013 [99]	n = 28, periapical lesions;	Apicoectomy	Real-time PCR (DNA)
Verdugo et al. 2015 [100]	n = 48, apical periodontitis (33); saliva (15);	Apicoectomy	PCR, Real-time PCR (DNA)
Ozbek et al. 2015a [101]	n = 33, acute apical abscess (27); healthy pulp control (6)	Needle aspiration	Real-time PCR (DNA))
Makino et al. 2015 [102]	n = 42, periapical lesions (32); gingival tissue (10);	Apicoectomy	Real-time PCR (DNA), In situ hybridization, Immunohistochemical analysis
Ozbek et al. 2015b [103]	n = 31, acute apical abscess (21); healthy pulp control (10);	Needle aspiration	Real-time PCR (DNA))
Popovic et al. 2015 [104]	n = 60, periapical lesions;	Tooth extraction	PCR (DNA)
Jakovljevic et al. 2015 [105]	n = 125, apical periodontitis (100); healthy pulp control (25)	Apicoectomy	PCR (DNA), RFLP

PCR, polymerase chain reaction; RT-PCR, reverse transcriptase polymerase chain reaction; HCMV, human cytomegalovirus; EBV, Epstein-Barr virus; DNA, deoxyribonucleic acid; cDNA, complementary deoxyribonucleic acid; mRNA, messenger ribonucleic acid.

Table 4. Articles included in the final review.

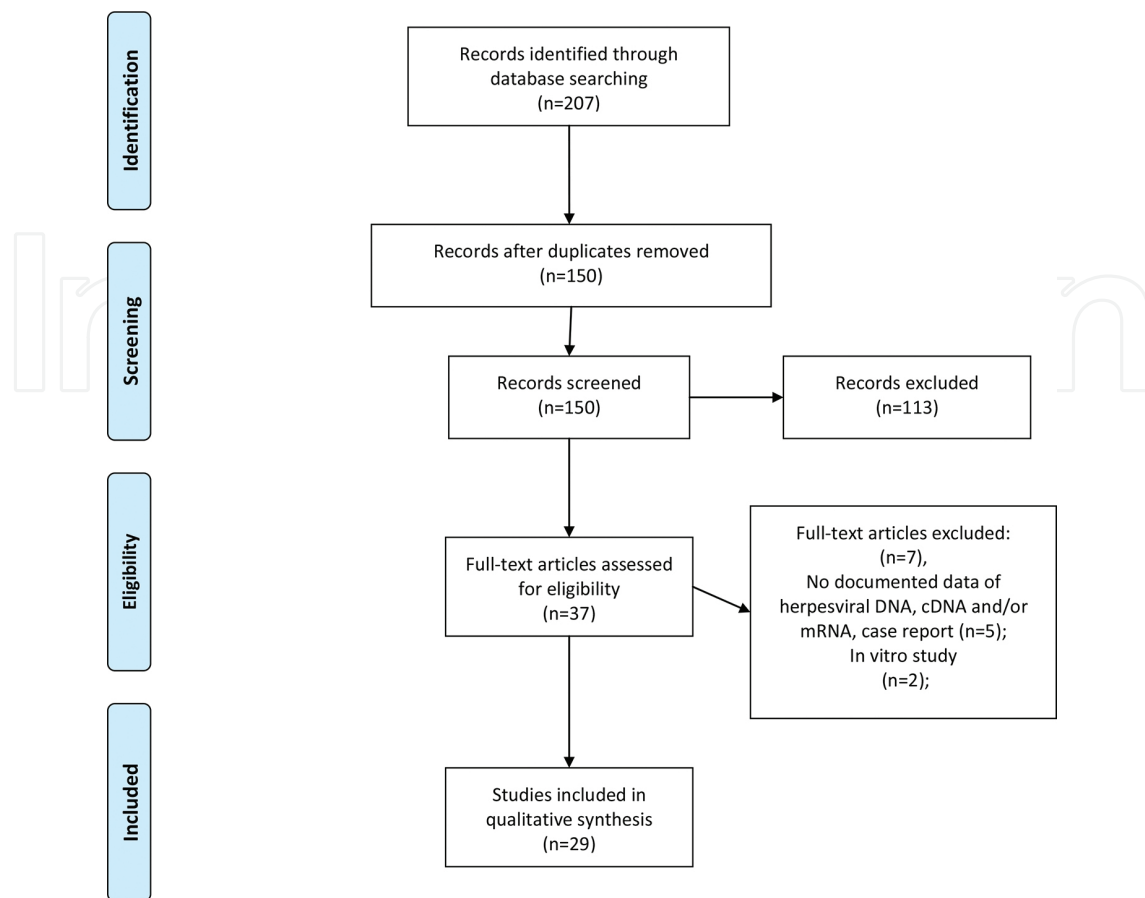


Figure 1. Flow diagram of systematic review process.

3.1. The occurrence of herpesviruses in samples of periapical pathoses compared to healthy control tissues

Twelve included studies investigated the occurrence of herpesviruses in samples of apical periodontitis lesions and healthy control tissues [68, 82, 87–89, 93, 95, 96, 98, 100, 103, 105]. Healthy pulp tissue samples, obtained from surgically extracted third molars or teeth extracted due to orthodontic reasons, were used as control specimen in the majority of studies [82, 87, 93, 95, 96, 105]. Few studies used gingival tissues as control specimens [98, 102]. Sabeti et al. [68] and Verdugo et al. [100] also reported usage of tissues from healthy periapical sites and saliva as controls.

Four studies [93, 95, 96, 105] reported significantly increased occurrence of herpesviruses in periapical lesions compared to control pulp tissues. Hernadi et al. [98] and Makino et al. [103] shown similar occurrence of herpesviruses between periapical lesions and gingival tissue.

Four studies compared the occurrence of herpesviruses between acute apical abscess samples and healthy pulp tissue [79, 94, 101, 103]. Although herpesviruses were more frequently detected in abscess samples compared to the pulp tissue samples, these differences were not significant (Table 6).

3.2. The occurrence of herpesviruses in symptomatic and asymptomatic apical periodontitis and acute apical abscesses

The majority of studies included in final review investigated the relationship between the presence of herpesviruses and clinical features of periapical lesions. The common approach was to compare the occurrence of herpesviruses in groups of symptomatic and asymptomatic lesions based on the presence of pain, sensitivity to percussion and palpation, and discomfort on biting at the time of sample collection. The summarized results of these studies are given in **Table 5**.

Author, year [reference number]	Study group	Symptomatic lesions	Asymptomatic lesions	Control group	Lesion size	Dual infection
Rider et al. 1995 [81]	n = 20, radicular cysts	HSV-1+ (0%) HSV-2+ (0%)		n = 2 HSV-positive controls— infected lung tissues		
Heling et al. 2001 [82]	n = 36, pulp tissue— irreversible pulpitis (11); necrotic pulp (17); periapical lesions (10);	HSV-1+ (0%) HSV-2+ (0%)		n = 8; control pulpal tissue; HSV-1+ (0%) HSV-2+ (0%)		
Sabeti et al. 2003a [68]	n = 14, periapical lesions;	n = 13 HCMV+ (92, 3%) EBV+ (61, 5%) HSV-1+ (0%)	n = 1 HCMV+ (100%) EBV+ (0%) HSV-1+ (0%)	n = 2; periapical tissue from healthy place;	<5 × 7 mm HCMV+ (85, 7%) EBV+ (28, 6%) ≥5 × 7 mm HCMV+ (100%) EBV+ (85, 7%)	HCMV \ EBV+ (57, 1%)
Sabeti et al. 2003b [69]	n = 14, periapical lesions;	n = 7 HCMV+ (100%) EBV+ (85, 7%)	n = 7 HCMV+ (14, 3%) EBV+ (14, 3%) HSV-1+ (14, 3%)		<5 × 7 mm HCMV+ (50%) EBV+ (0%) ≥5 × 7 mm	Symptomatic HCMV \ EBV+ (100%)

Author, year [reference number]	Study group	Symptomatic lesions	Asymptomatic lesions	Control group	Lesion size	Dual infection
					HCMV+ (50%) EBV+ (66, 7%)	Asymptomatic HCMV\EBV+ (14, 3%)
Sabeti et al. 2003c [83]	n = 5, periapical lesions;	n = 5, HCMV+ (100%) EBV+ (100%) HSV-1+ (0%)			≥5 × 7 mm HCMV+ (100%) EBV+ (100%)	Symptomatic HCMV\EBV+ (100%)
Sabeti et al. 2004 [84]	n = 34, periapical pathosis;	n = 23, HCMV\EBV+ (69, 6%) HCMV\EBV- (0%)	n = 11, HCMV\EBV+ (36, 4%) HCMV\EBV- (54, 5%) HSV+ (18, 2%)		≥5 × 7 mm HCMV/ EBV+ (79, 2%)	HCMV\EBV+ (58, 8%)
Slots et al. 2004 [85]	n = 44, periapical pathosis;	n = 25, HCMV+ (100%) EBV+ (76%)	n = 19, HCMV+ (37%) EBV+ (26%)		Range from 2 × 2 to 15 × 16 mm	Symptomatic HCMV\EBV+ (76%) Asymptomatic HCMV\EBV+ (26%)
Kabak et al. 2005 [86]	n = 57, periapical lesions;	n = 57, HSV-1+ (8, 8%)				
Yildirim et al. 2006 [87]	n = 12, granulomatous tissue;	n = 12, HCMV+ (58%) EBV+ (67%)		n = 12, control pulpal tissue;		Symptomatic HCMV\EBV+ (33%)
Saboa-Dantas et al. 2007 [88]	n = 26, HIV-seronegative		n = 26, granulomas HCMV+	n = 9, HIV-seropositive;		HIV-seronegative HCMV\EBV+

Author, year [reference number]	Study group	Symptomatic lesions	Asymptomatic lesions	Control group	Lesion size	Dual infection
	granulomas (n = 22); cysts (n = 4);		(18, 75%) EBV+ (43, 75%); cysts HCMV+ (0%) EBV+ (0%);	granulomas HCMV+ (66, 7%) EBV+ (50%); cysts HCMV+ (50%) EBV+ (50%);		(7, 7%) HIV- seropositive HCMV\EBV+ (33, 3%)
Andric et al. 2007 [89]	n = 33, periapical cysts	n = 16, HCMV+ (38, 9%)	n = 17, HCMV+ (61, 1%)	n = 10, odontogenic keratocysts; HCMV+ (60%)	Range from 11 to 80 mm	
Yazdi et al. 2008 [90]	n = 50, apical periodontitis;	n = 28, HCMV+ (53, 6%) EBV+ (3, 6%)	n = 22, HCMV+ (22, 7%) EBV+ (4, 5%)		Average lesion size 4.55 × 4.8 mm	Symptomatic HCMV\EBV+ (0%) Asymptomatic HCMV\EBV+ (4, 5%)
Sunde et al. 2008 [91]	n = 40, apical periodontitis;	n = 18, HCMV+ (0%) EBV+ (72%)	n = 22, HCMV+ (0%) EBV+ (28%)			
Sabeti et al. 2009 [92]	n = 15, periapical lesions;	n = 15, HCMV+ (67%)			Range from 3.0 to 8.5 mm	
Li et al. 2009 [93]	n = 53, apical periodontitis (30); previously treated teeth	n = 32 HCMV DNA/ mRNA+ (15, 7%)/ (27, 5%) EBV DNA/ mRNA+	n = 21 HCMV DNA/ mRNA+ (16, 1%)/ (32, 3%) EBV DNA/ mRNA+	n = 19, healthy pulp control; HCMV DNA/ mRNA+ (42, 1%)/ (10, 5%)	≥5 mm HCMV DNA/ mRNA (13, 9%)/ (33, 3%) EBV DNA/ mRNA+ (50%)/ (36, 1%)	

Author, year [reference number]	Study group	Symptomatic lesions	Asymptomatic lesions	Control group	Lesion size	Dual infection
	with apical periodontitis (23);	(43, 1%)/ (21, 6%)	(45, 2%)/ (32, 3%)	EBV DNA/ mRNA+ (0%)/ (0%)	<5 mm HCMV DNA/ mRNA (0%)/ (29,4%) EBV DNA/ mRNA+ (47, 1%)/ (35,3%)	
Hernandi et al. 2010 [95]	n = 40, apical periodontitis;	n = 17, HCMV DNA/ mRNA+ (6%)/ (0%) EBV DNA/ mRNA+ (82%)/ (71%)	n = 13, HCMV DNA/ mRNA + (13%)/ (0%) EBV DNA/ mRNA+ (65%)/ (35%)	n = 40, healthy pulp control; HCMV DNA/ mRNA + (0%)/ (0%) EBV DNA/ mRNA+ (2, 5%)/ (2, 5%)	≥5 mm HCMV DNA/ mRNA (14%)/ (0%) EBV DNA/ /mRNA+ (91%)/ (76%) ≤5 mm HCMV DNA/ mRNA (0%)/(0%) EBV DNA/ mRNA+ (53%)/(21%)	Symptomatic HCMV\EBV DNA+ (6%) Asymptomatic HCMV\EBV DNA+ (9%) Control group HCMV \EBVDNA+ (0%)
Hernandi et al. 2011 [96]	n = 40, apical periodontitis;	n = 17, HHV 6+ (29, 4%) HCMV+ (2, 5%) EBV+ (35%)	n = 23, HHV 6+ (13%) HCMV+ (7, 5%) EBV+ (37, 5%)	n = 40, healthy pulp control; HHV 6+ (2, 5%) HCMV+ (0%) EBV+ (2, 5%)	≥5 mm n = 21 HHV 6+ (23, 8%) HCMV+ (14, 8%) EBV+ (90, 5%) ≤5 mm n = 19 HHV 6+ (15, 8%) HCMV+ (5, 3%) EBV+ (52, 6%)	HHV 6\EBV+ (17, 5%) HCMV\EBV+ (7, 5%)

Author, year [reference number]	Study group	Symptomatic lesions	Asymptomatic lesions	Control group	Lesion size	Dual infection
Sabeti M et al. 2012 [97]	n = 15, periapical lesions;	n = 9, HCMV+ (55%) EBV+ (88, 9%)	n = 6, HCMV+ (0%) EBV+ (0%)			Symptomatic HCMV\EBV+ (44, 4%)
Hernandi et al. 2013 [98]	n = 58, apical periodontitis;	n = 28, HCMV+ (14, 3%) EBV+ (89, 3%)	n = 30, HCMV+ (10%) EBV+ (63, 3%)	n = 20, gingival tissue;	≥5 mm n = 31 HCMV+ (16, 1%) EBV+ (93, 5%) ≤5 mm n = 27 HCMV+ (7, 4%) EBV+ (55, 6%)	
Ozbek et al. 2013 [99]	n = 28, apical periodontitis;	n = 16, HCMV + (37, 5%) EBV+ (18, 7%)	n = 12, HCMV + (25%) EBV+ (8, 3%)		≤5 mm Symptomatic HCMV+ (37, 5%) EBV+ (18, 7%) Asymptomatic HCMV\EBV+ (25%) (16, 7%) EBV+ (8, 3%)	Symptomatic HCMV\EBV+ (25%) Asymptomatic HCMV\EBV+ (16, 7%)
Verdugo et al. 2015 [100]	n = 33, apical periodontitis;	n = 20, HCMV+ (15%) EBV+ (70%)	n = 13, HCMV+ (0%) EBV+ (38, 5%)	n = 15, saliva; HCMV+ (6, 7%) EBV+ (40%)		Symptomatic HCMV\EBV+ (15%)
Makino et al. 2015 [102]	n = 32, apical periodontitis;	n = 32, granulomas; EBV+ (78, 1%)		n = 20, gingival tissue; EBV+ (0%)		
Popovic et al. 2015 [104]	n = 60, apical periodontitis;	n = 31, HCMV + (70, 9%)	n = 29, HCMV + (24, 1%) EBV+ (0%)		≤5 mm Symptomatic HCMV+ (12, 5%)	Symptomatic HCMV\EBV+ (35, 5%)

Author, year [reference number]	Study group	Symptomatic lesions	Asymptomatic lesions	Control group	Lesion size	Dual infection
		EBV+ (41, 9%)			EBV+ (12, 5%) Asymptomatic HCMV+ (0%) EBV+ (0%) >5 mm Symptomatic HCMV+ (91, 3%) EBV+ (52, 2%) Asymptomatic HCMV+ (38, 9%) EBV+ (0%)	
Jakovljevic et al. 2015 [105]	n = 100, apical periodontitis;	n = 34, HCMV+ (52, 9%) EBV+ (79, 4%)	n = 66, HCMV + (54, 5%) EBV+ (74, 2%)	n = 25, healthy pulp control; HCMV+ (28%) EBV+ (24%)	>5 mm n = 69 HCMV+ (57, 9%) EBV+ (78, 3%) ≤5 mm n = 31 HCMV+ (54, 8%) EBV+ (71%)	HCMV \ EBV+ (41%)

^[68]($p = 0.03$; Chi-squared test)—dual HCMV/EBV infection in lesions of 5 mm × 7 mm or greater in radiographic size.
^[69]($p = 0.007$; $p = 0.04$; Chi-squared test, Yates)—dual HCMV/ EBV infection in symptomatic periapical lesions.
^[84]($p < 0.001$; Chi-squared test)—presence of herpesviruses more in large versus small size periapical lesions.
^[84]($p < 0.001$; Chi-squared test)—dual HCMV/ EBV infection in large periapical lesions.
^[85]($p < 0.0001$; Chi-squared test)—dual HCMV/ EBV infection in symptomatic versus asymptomatic periapical lesion.
^[87]($p < 0.040$; $p < 0.040$ Mann–Whitney U-test)—dual HCMV/ EBV infection in periapical lesions versus healthy pulpal control.
^[88]($p = 0.001$; Chi-squared test, Yates)—HCMV infection in periapical lesions of HIV-positive versus HIV-negative patients.
^[90]($p = 0.03$; Chi-squared test)—HCMV infection in symptomatic versus asymptomatic periapical lesions.
^[91]($p = 0.025$; Chi-squared test)—EBV infection in symptomatic versus asymptomatic periapical lesions.
^[93]($p < 0.05$; Chi-squared test)—EBV DNA and RNA in endodontic pathoses versus healthy pulp control.
^[95]($p < 0.0001$; $p < 0.0001$; Chi-squared test, Yates)—EBV DNA and RNA in apical periodontitis lesions versus healthy pulp control.
^[95]($p < 0.0001$; $p < 0.0001$; Chi-squared test, Yates)—EBV DNA and RNA in symptomatic versus asymptomatic periapical lesions.
^[95]($p = 0.02$; $p = 0.002$; Chi-squared test, Yates)—both EBV DNA and RNA in large versus small size periapical lesions.
^[96]($p = 0.03$; Fisher exact test)—HHV-6 DNA in apical periodontitis versus control group.
^[96]($p = 0.018$; Logistic regression analysis)—Correlation between HHV-6 DNA occurrence and lesion size.
^[96]($p = 0.008$; Logistic regression analysis)—HHV-6 DNA in symptomatic versus asymptomatic periapical lesions.
^[96]($p < 0.01$; Fisher exact test)—HHV-6B DNA versus HHV-6A DNA in symptomatic large-sized lesions.

^[97]($p = 0.048$; $p = 0.002$; Mann–Whitney U test)—dual HCMV/ EBV infection in symptomatic versus asymptomatic periapical lesion.

^[98]($p < 0.000001$; Chi-squared test, Yates)—EBV infection in apical periodontitis lesions versus control group.

^[98]($p < 0.05$; Chi-squared test, Yates)—EBV infection in symptomatic versus asymptomatic periapical lesions.

^[98]($p = 0.002$; Chi-squared test)—EBV infection more in large versus small size periapical lesions.

^[100]($p < 0.01$; Chi-squared test)—EBV copies more in symptomatic versus asymptomatic periapical lesions.

^[100]($p = 0.07$; Chi-squared test)—EBV infection more in symptomatic versus asymptomatic periapical lesions.

^[103]($p < 0.0001$; Mann–Whitney U test)—EBV DNA copies in apical periodontitis versus healthy gingival tissues.

^[104]($p < 0.001$; Chi-squared test)—HCMV infection in symptomatic versus asymptomatic periapical lesions.

^[104]($p < 0.001$; Chi-squared test)—EBV infection in symptomatic versus asymptomatic periapical lesions.

^[104]($p < 0.001$; Chi-squared test)—HCMV/EBV dual infection in symptomatic versus asymptomatic periapical lesions.

^[104]($p < 0.001$; Chi-squared test)—HCMV infection in large symptomatic versus small symptomatic periapical lesions.

^[104]($p < 0.001$; Chi-squared test)—HCMV infection in large asymptomatic versus small asymptomatic periapical lesions.

^[105]($p = 0.020$; Chi-squared test)—EBV infection in periapical lesions versus healthy pulp control.

^[105]($p = 0.001$; Chi-squared test)—EBV-1 versus EBV-2 infection in periapical lesions versus healthy pulp control.

^[105]($p = 0.020$; Chi-squared test)—HCMV infection in periapical lesions versus healthy pulp control.

^[105]($p = 0.036$; Chi-squared test)—HCMV gB 1 versus gB 2 infection in periapical lesions versus healthy pulp control.

^[105]($p = 0.038$; Chi-squared test)—HCMV/EBV dual infection in large-sized versus small-sized periapical lesions.

Table 5. The occurrence of herpesviruses among apical periodontitis lesions and control specimens.

Author, year [reference numbers]	Study group	Control group	Co-infection	Lesion size
Chen et al. 2009 [94]	n = 31	n = 19		≥5 mm
	HCMV+ (29%)	healthy pulp		HCMV+ (26.1%)
	EBV+ (6.5%)	HCMV+ (42.1%)		EBV+ (4.3%)
	HSV+ (3.2%)	EBV+ (0%)		HSV+ (4.3%)
	VZV+ (0%)	HSV+ (5.3%)		<5 mm
Ferreira et al. 2011a [79]	n = 23	n = 5	VZV+ (8.7%)	HCMV+ (37.5%)
	HCMV+ (0%)	healthy pulp	HSV+ (8.7%)	EBV+ (12.5%)
	EBV+ (0%)	HCMV+ (0%)	HHV 6+ (4.3%)	
	HSV+ (4%)	EBV+ (0%)	HHV 7+ (4.3%)	
	VZV+ (9%)	HSV+ (0%)	HHV 8 (21.7%)	
	HHV 6+ (9%)	VZV+ (0%)		
	HHV 7+ (4%)	HHV 6+ (0%)		
	HHV 8+ (48%)	HHV 7+ (20%)		
	HPV+ (13%)	HHV 8+ (40%)		
	HPV+ (0%)			
Ferreira et al. 2011b [80]	n = 33		HHV 8 (15.2%)	
	HCMV+ (0%)		VZV+ (6.1%)	
	EBV+ (6%)		HPV+ (6.1%)	
	VZV+ (6%)		HSV+ (3%)	
	HHV 6+ (6%)		EBV+ (3%)	
	HHV 7+ (3%)		HHV 6 + (3%)	
	HHV 8+ (54.5%)		HHV 7 + (3%)	
	HSV+ (3%)		HHV 8, HPV -bacterial co-infection	
	HPV+ (9%)			
Ozbek et al. 2015a [101]	n = 27	n = 6	Dual HCMV/EBV (4%)	
	HCMV+	healthy pulp		

Author, year [reference numbers]	Study group	Control group	Co-infection	Lesion size
Ozbek et al. 2015b [103]	(22.2%)EBV+	HCMV+ (0%)		
	(11.1%)	EBV+ (0%)		
	HPV+ (7.4%)	HPV+ (0%)		
	n = 21	n = 10	Dual HCMV/EBV (4.8%)	≥5 mm
	HCMV+ (19%)	healthy pulp	Dual HCMV/HHV 6 (4.8%)	HCMV+ (27%)
	EBV+ (14%)	HCMV+ (0%)		EBV+ (18%)
	HHV 6+ (5%)	EBV+ (0%)		HHV 6+ (9%)
HPV+ (5%)	HHV 6+ (0%)		HPV+ (9%)	
	HPV+ (0%)		<5 mm	
			HCMV+ (10%)	
			EBV+ (10%)	
			HHV 6+ (0%)	
			HPV+ (0%)	

HCMV, human cytomegalovirus; EBV, Epstein–Bar virus; HHV, human herpesvirus; HPV, human papillomavirus; VZV, Varicella-zoster virus; HSV, Herpes simplex virus.

Table 6. The occurrence of herpesviruses among acute apical abscess lesions and control specimens.

Fourteen studies compared the occurrence of herpesviruses between the symptomatic and asymptomatic periapical lesions [68, 69, 84, 85, 90, 91, 93, 95–100, 104, 105]. The most investigated herpesviruses were EBV and HCMV. An overall analysis of EBV and HCMV presence showed variability in their occurrence.

The results of analysed studies revealed that EBV was the most prevalent herpesvirus in samples of apical periodontitis lesions [91, 93, 95–98, 100, 105]. Six studies shown that EBV infection was found in an increased percentage among symptomatic periapical lesions. Among these studies, five of them reported that EBV occurrence was significantly more common in symptomatic compared to asymptomatic periapical lesions [91, 95, 98, 100, 104].

Additionally, HCMV infection was also found in large percentage among symptomatic periapical lesions [68, 69, 85, 90, 104]. Yazdi et al. [90] and Popovic et al. [104] reported significant difference in HCMV occurrence between symptomatic and asymptomatic periapical lesions ($P = 0.03$, $P < 0.001$, respectively).

All studies of apical abscesses analysed the occurrence of herpesviruses in patients with acute and developed form of disease [79, 80, 94, 101, 103] (Table 6). They were characterized by rapid onset, spontaneous pain, tenderness of the tooth to pressure, pus formation, and associated swelling. The results of analysed studies have shown that HHV-8 and HCMV were the most frequently detected herpesviruses in cases of acute apical abscess. Two studies of Ferreira et al. [79, 80] have reported remarkably high occurrence of HHV-8 compared to other analysed herpesviruses. Oppositely, Chen et al. [94] and Ozbek et al. [101, 103] have found that HCMV was the most prevalent herpesvirus in abscess samples. Although herpesviruses were more prevalent in abscess lesions, their occurrence was not significantly different compared to control pulp tissues [79, 80, 94, 101, 103].

3.3. Findings of herpesviral infections among large- and small-sized apical periodontitis lesions

Clinical investigations use different radiographic methods to confirm the presence of periapical pathoses and to determine their size. The size of the periapical lesions is important prognostic parameter because it indicates the level of periapical bone resorption. Numerous studies investigated the occurrence of herpesviruses in periapical lesions regarding their size, estimated by conventional radiography. The common approach was to compare the occurrence of herpesviruses in groups of large- ($\geq 5 \times 7$ mm) and small-sized ($< 5 \times 7$ mm) lesions based on its mesiodistal and craniocaudal diameter. The summarized results of relevant studies are given in **Table 5**.

Eight studies investigated the occurrence of herpesviruses among small- and large-sized periapical lesions [68, 69, 93, 95, 96, 98, 104, 105]. The most frequently analysed herpesviruses were EBV and HCMV. Similarly, an overall analysis of EBV and HCMV presence in apical periodontitis lesions with different size showed variability in their occurrence.

All eight studies reported that EBV infection was found in an increased percentage among large-sized periapical lesions [68, 69, 93, 95, 96, 98, 104, 105]. Two studies of Hernadi et al. [95, 98] have shown that EBV infection was significantly more frequent in large-sized compared to small-sized periapical lesions ($P = 0.02$, $P = 0.002$, respectively).

Moreover, five studies showed that HCMV infection was found in large percentage among large-sized periapical lesions [68, 69, 96, 104, 105]. Popovic et al. [104] reported that HCMV was detected significantly more often in large-sized compared to small-sized periapical lesions ($P < 0.001$). In opposite to these findings, several studies reported that EBV [95, 96, 98, 105] and HCMV [68, 69, 105] could be found in large percentage among small-sized periapical lesions.

Beside EBV and HCMV infection, Hernadi et al. [96] also found that HHV-6 significantly correlates with increasing periapical lesion size ($P = 0.018$).

Only two studies [94, 103] analysed the occurrence of herpesviruses among acute apical abscesses with different size. HCMV was the most frequently detected herpesvirus in both groups of lesions without significant difference in relation to their size (**Table 6**).

3.4. Findings of herpesviral infections in periapical granulomas and radicular cysts

Four studies analysed the presence of herpesviruses in apical periodontitis lesions in relation to their histopathological features [86, 88, 93, 105]. The common approach was to compare the occurrence of herpesviruses between periapical granulomas and radicular cysts.

In study of Kabak et al. [86], the immunohistochemistry analysis showed the presence of HSV in five radicular cysts, while none of the periapical granulomas were positive. Saboia-Dantas et al. [88] compared the presence of HCMV and EBV between 29 periapical granulomas and 6 radicular cysts. Statistical analysis did not reveal significant difference between HCMV and EBV presence in examined groups. Additionally, subsequent studies by Li et al. [93] and Jakovljevic et al. [105] did not report significant differences in the occurrence of herpesviruses between periapical granulomas and radicular cysts (**Table 5**).

3.5. Findings of multiple herpesviral infections and co-infection with bacteria in periapical pathoses

Fifteen included studies reported the presence of dual herpesviral infection in apical periodontitis samples [68, 69, 83–85, 87, 88, 90, 95–97, 99, 100, 104, 105].

Dual infection including HCMV and EBV was the most commonly investigated. Only one study reported dual infection of EBV and HHV-6 in 17,5% of investigated sample [95]. Majority of studies compared the presence of dual infection in relation to clinical and radiographic features of apical periodontitis. Three studies [68, 84, 105] showed that dual infection was detected significantly more often in large-sized compared to small-sized periapical lesions ($P = 0.03$, $P < 0.001$, $P = 0.038$, respectively). Moreover, the results of four other studies [83, 86, 97, 104] indicated that dual herpesviral infection was significantly more common in symptomatic in comparison with asymptomatic apical periodontitis ($P = 0.007$, $P < 0.001$, $P = 0.048$, $P < 0.0001$, respectively) (Table 5).

Two studies investigated the presence of herpesviral–bacterial co-infection in samples of apical periodontitis [84, 100]. Sabeti et al. [84] showed that *Fusobacterium* species, *Streptococcus* species, and *Parvimonas micra* were the most common bacterial species in co-infection with herpesviruses in these lesions. Additionally, Verdugo et al. [100] reported that *Tannerella forsythia*, *Porphyromonas gingivalis*, and *Prevotella nigrescens* were the most common bacterial species found in concomitant infection with EBV (Table 5).

Four studies investigated the presence of multiple herpesviral infections in samples of acute apical abscesses [79, 80, 101, 103]. Studies of Ferreira et al. [79, 80] reported multiple infections with several herpesviruses. The most prevalent herpesviruses in multiple infections of acute apical abscess were HHV-8, HSV, and VZV (Table 6). Additionally, Ozbek et al. [101, 103] showed the presence of dual infection between HCMV and EBV, and HCMV and HHV-6 in samples of large acute apical abscesses. Ferreira et al. [80] investigated the presence of herpesviral–bacterial co-infection in acute apical abscess. They have shown that the most prevalent bacterial species were *Tannerella forsythia* (70%), *Tannerella forsythia* (67%), *Porphyromonas endodontialis* (67%), *Dialister invisus* (61%), and *Dialister pneumosintes* (57, 5%). Their findings indicate that HHV-8 was positively associated with seven of the target bacterial species, but all these associations were weak (Table 6).

3.6. Findings of different herpesviral genotypes in periapical pathoses

Four studies investigated the presence of different genotypes of herpesviruses in periapical pathoses [93, 94, 96, 105].

Li et al. [93] analysed the presence of EBV BLRF2 gene product genotypes (type 1 and type 2) in apical periodontitis lesions. Although, 50.1% of samples were EBV positive, authors did not report the frequencies of investigated genotypes. They were not able to distinguish EBV strains because the sequences of the amplified region were too similar.

Hernadi et al. [96] reported the presence of different genotypes of HHV-6 in samples of apical periodontitis. They analysed the occurrence of two variants (type A and B) of the immediate

early fragment sequence of HHV-6. They did not find significant difference between HHV-6 type A and B in samples of apical periodontitis and control group. On the other side, HHH-6B was significantly associated with symptomatic and large-sized lesions ($P < 0.01$).

Jakovljevic et al. [105] analysed the occurrence of EBV EBNA-2 (type 1 and 2) and HCMV gB (types I–IV) genotypes in apical periodontitis samples. They have reported that EBV type 1 was more frequently detected compared to EBV type 2 in both periapical lesions and healthy pulp tissues (74 versus 6% and 24 versus 4%, $P = 0.001$). In addition, authors have reported that only two out of four HCMV gB genotypes (type I and II) were detected. HCMV gB-II was more frequently detected among periapical lesions and healthy pulp tissue compared to gB-1 (42 versus 12%, 28 versus 0%, $P = 0.036$) Significant differences were not observed in the distribution of HCMV and EBV genotypes regarding clinical and radiographic features of periapical lesions.

Analysing the samples of acute apical abscess, Chen et al. [94] showed the presence of EBV type 1 in two examined samples. These findings were not correlated with clinical and radiographic features of acute apical abscess.

3.7. Quantitative herpesviral analysis in apical periodontitis lesions

The quantification of herpesviruses in apical periodontitis samples has been reported in four studies [91, 97, 100, 102]. All studies reported the number of HCMV and/or EBV copies/mL in samples of apical periodontitis using the real-time PCR method.

Sunde et al. [91] analysed the number of HCMV and EBV copies in samples of apical periodontitis. EBV was detected in 50% of sample, while HCMV was not detectable. They reported low average levels of EBV copies in symptomatic and asymptomatic apical periodontitis (300 versus 970 copies/mL) without any significant difference between the analysed groups.

Sabeti et al. [97] analysed the number of HCMV and EBV copies in symptomatic and asymptomatic apical periodontitis. Four out of nine symptomatic lesions were positive for HCMV, and the average number of HCMV copies was 874.000/mL. Eight out of nine symptomatic lesions exhibited the presence of EBV. The average number of EBV copies in samples was 2.162.500/mL. In contrast, HCMV and EBV were not detected in asymptomatic lesions. They have reported significant difference in the occurrence of HCMV and EBV between symptomatic and asymptomatic periapical lesions ($P = 0.048$, $P = 0.002$, respectively).

Similarly, Verdugo et al. [100] demonstrated the presence of increased number of EBV copies in symptomatic in comparison with asymptomatic periapical lesions. They reported that the average number of EBV copies in symptomatic lesions (391.903/mL) was significantly higher than the average copy numbers of EBV in asymptomatic lesions (623/mL) ($P < .01$). Additionally, HCMV was detected in only 3 out of 20 symptomatic lesions (at average number of 124.076 copies/mL).

Makino et al. [102] reported the difference in EBV DNA copies between samples of periapical granulomas and healthy gingival tissue. They have shown that EBV was positive in 78.1% of

sample and the median EBV DNA copy number was 8.688/ μ g total DNA. In contrast, EBV was not detected in control group and that difference was statistically significant ($P = 0.0001$).

3.8. Levels of proinflammatory mediators in relation to herpesviral infection in apical periodontitis

The relationship between herpesviral infection and levels of proinflammatory mediators in apical periodontitis has been analysed in three studies [87, 97, 98].

Yildirim et al. [87] investigated a possible relationship between the presence of HCMV and EBV in apical periodontitis samples and increased levels of bone resorption-inducing cytokines. They analysed the presence of HCMV and EBV DNA and the expression of mRNA transcripts of receptor activator of nuclear factor (NF- κ B) ligand (RANKL), osteoprotegerin, core binding factor α -1, colony-stimulating factor-1, transforming growth factor (TGF)- β 3, and monocyte chemoattractant protein-1. Only, the RANKL expression revealed statistically significant difference between periapical lesions and healthy pulpal tissue ($P < 0.04$). No correlation was found between herpesvirus presence and cytokine expression in apical periodontitis sample.

Sabeti et al. [97] correlated the occurrence of HCMV and EBV infection in periapical tissues with the expression of mRNA transcripts of TNF- α , γ -interferon (IFN), IL-1 β , IL-6, IL-10, and IL-12. They found significant direct correlation between EBV, HCMV and TNF- α , γ -IFN, IL-1 β , and IL-12 in symptomatic periapical lesions.

Hernadi et al. [98] evaluated the association between TNF- α and TGF- β and the clinical, radiologic, and virologic characteristics of the lesions. They compared the levels of these cytokines in relation to EBV, HCMV, HHV-6, and HHV-8 infection in apical periodontitis. They showed that the levels of TNF- α were significantly higher in periapical lesions with EBV infection in comparison with lesions without EBV infection (1.1×10^{-2} versus 6.8×10^{-3} , $P = 0.032$). All other comparisons between levels of cytokines and features of periapical lesions were insignificant.

4. Discussion

The emerging role of herpesviruses in the development and progression of apical periodontitis changes previous concepts of etiopathogenesis of destructive periapical disease. The hallmark of herpesviral infection is impairment of immune system. Most herpesviruses are ubiquitous agents. They are often acquired early in life and capable of infecting individuals from diverse geographical and economic backgrounds [71]. The initial herpesviral infection is followed by a latent phase in host cells, which ensures the survival of the viral genome throughout the lifetime of the infected individual. The α herpesviruses establish latency in long-living non-dividing neuronal cells of sensory ganglia. The β herpesviruses establish latency in bone marrow-derived myeloid progenitor cells, while the γ herpesviruses are latent in B lymphocytes [72]. Herpesvirus reactivation may occur spontaneously or as a result of psychosocial

and physical stress, hormonal changes, infections, immunosuppressive medication, and other events impairing the host immune defence [73]. After activation, they can infect monocytes/macrophages, T and B lymphocytes, epithelial cells, endothelial cells, fibroblasts, and other mammalian cells [73].

Cell-mediated immune responses are the key defence mechanisms against herpesviral infection [71–73]. Cytotoxic T lymphocytes and natural killer cells are the most important effector cells responsible for suppression of viral replication and maintenance of herpesviruses in latent state. The T-lymphocyte response to herpesviruses changes over time from a predominantly CD4⁺ response early in infection, to a CD8⁺ response during latent phase [71–73].

In response to antiviral host defences, herpesviruses have developed a number of immunosubversive mechanisms to ensure persistent infections in the host [71–73]. Herpesviruses can affect toll-like receptors function thus interfering with antigen presentation process [111]. In addition, they have the ability to inhibit the expression of the major histocompatibility complex (MHC) class I and II on the surface of macrophages [112]. These actions allow them to evade cytotoxic T-cell recognition [113] and natural killer cell lysis [114]. Moreover, herpesviruses can inhibit migration of dendritic cells [115] and decrease chemotaxis of polymorphonuclear leukocytes [116]. Herpesviruses infection induces production of proinflammatory cytokines [117] but also impairs antiviral cytokine responses [113, 118]. Although IFN- γ , TNF- α , and IL-6 exert high antiviral activity, some herpesviruses encode unique homologs of IL-10 capable to inhibit production of these cytokines in macrophages and monocytes [119–121]. Additionally, some herpesviral genes protect cells from undergoing apoptosis in order to prolong the life of infected cells [113].

As already mentioned, tissues of periapical granuloma and radicular cysts are characterized by inflammatory cells infiltration [24–33]. However, these inflammatory cells are also the host cells for herpesviruses [72]. In proposed herpesviral–bacterial hypothesis, bacterial infection of the pulp causes herpesviral-infected inflammatory cells to enter pulpal tissue through the periapical region. Bacterial infection causes subsequent herpesviral reactivation. Reactivated herpesviruses in pulp and periapical tissues may induce development of periapical pathoses as a direct result of viral infection or as a result of virally induced damage to the host defence. Although primary bacterial infection in periapical region may induce herpesviral reactivation, herpesviral infection also possesses mechanisms to induce upgrowth of bacterial pathogens in the periodontium [75, 76]. Previous results suggest that herpesviral infection in apical periodontitis was associated with *Fusobacterium* species, *Tannerella forsythia*, *Porphyromonas gingivalis*, *Parvimonas micra*, and *Streptococcus* species [84, 100]. Additionally, Ferreira et al. [80] reported positive association between HHV-8 and several bacteria in acute apical abscess. Using the animal model, Stern et al. [122] have shown that co-infection of murine CMV and *Porphyromonas gingivalis* is characterized with decreased level of antiviral IFN- γ . Moreover, interaction between EBV and *Porphyromonas gingivalis* may also be bidirectional [123]. Herpesviral proteins on infected cells may serve as a new attachment sites for bacteria [124], while some bacterial products may facilitate herpesviral entry into cells and activate intracellular signalling pathways [125].

In contrast to proposed model of herpesviral–bacterial interaction, Ferreira et al. [79, 80] hypothesized that occurrence of herpesviruses might be just an epiphenomenon to bacterial infection that caused inflammation of periapical tissue and consequent influx of virus-infected inflammatory cells. Those authors believed that the presence of viral DNA in clinical samples does not necessarily imply a role in disease pathogenesis [79, 80]. Both theories suggest that virus-infected inflammatory cells, in which herpesviruses maintained their latency, could be attracted to periapical area. Histological analyses confirmed that these inflammatory cells constitute regular infiltrate of periapical granuloma and radicular cysts. Obviously, the essential difference between proposed hypotheses is whether herpesviruses may or may not be reactivated in periapical region and subsequently induce tissue breakdown.

Viral activation may be assessed by molecular techniques identifying transcription of genes associated with viral reactivation, immunologic methods to detect viral proteins, and by electron microscopy demonstrating the presence of intact virions inside the cells [126]. Li et al. [93] pointed out that the detection of herpesviral DNA *per se* is not sufficient to distinguish latent episomal viral DNA from genomic viral DNA contained in virus particles that would be indicative of an active infection. Herpesvirus virion genes are replicated in a specific order: immediate–early, early, and late genes [72]. Slots [71–73] proposed that the transcription of late genes can be used as an indicator of viral replication and active infection. Therefore, several studies have used detection of complementary DNA of genes transcribed late during the infectious cycle of herpesviruses [68, 69, 83–85, 90, 93, 95, 96]. The majority of those studies [68, 69, 83–85, 90] reported high occurrence of herpesviral infection in their samples. Moreover, the authors concluded that their findings suggest the presence of an active herpesviral infection at apical periodontitis sites. Although studies of Li et al. [93] and Hernadi et al. [95, 96] have employed the same reverse-transcription (RT) PCR technique for complementary DNA herpesviral detection, they failed to report such high percentage of periapical lesions exhibiting active replication of EBV and HCMV. Those findings could be explained by different prevalence of herpesviruses due to geographic, socio-economic, and racial/ethnic factors [71–76].

Quantification of herpesviruses by real-time PCR can also be used as a marker of active infection [126, 127]. Previously reported studies showed that increased viral load of herpesviruses correlates positively with progression of marginal periodontitis [126–128]. Based on these findings, Sunde et al. [91] suggested that increased number of viral copies of HCMV and EBV could possibly correlate with clinical features of apical periodontitis. However, their results did not reveal any significant differences between HCMV and EBV copies in symptomatic and asymptomatic periapical lesions. On the other hand, Sabeti et al. [97] and Verdugo et al. [100] have found significant differences in HCMV and EBV copy number between symptomatic and asymptomatic lesions. Makino et al. [102] have shown that the number of EBV copies was significantly increased in periapical lesions compared to healthy pulp controls. These results are in accordance with previous reports of Kubar et al. [126, 127], and their statement that increased herpes viral load may represent an important characteristic of active herpesvirus infection.

Statistical analysis of pooled data in our previous review [70] suggested that there is no significant correlation between the occurrence of HCMV and EBV and clinical features of apical

periodontitis. These results are based on analysis of studies which used RT-PCR technique for complementary DNA herpesviral detection [68, 69, 85, 90, 93, 95]. In addition, studies included in this review used immunohistochemical [81, 82, 86] or single-PCR [104, 105] method to identify herpesviruses in symptomatic and asymptomatic periapical lesions. One of the aims of this study was to analyse the occurrence of herpesviruses in relation to histopathological and radiographic features of periapical lesions. Only four studies [86, 88, 93, 105] have compared the presence of herpesviruses in periapical granulomas and radicular cysts and concluded that there were no significant differences between these two groups. Although radicular cysts are related to more intensive bone resorption in periapical area compared to periapical granulomas, the fact that both types of lesions are characterized by intensive inflammatory cells infiltrate might explain these results [129].

The analysis of correlation between herpesviral infection and size of apical periodontitis lesions gave inconclusive results. Only 8 out of 24 studies [68, 69, 93, 95, 96, 98, 104, 105] analysed the occurrence of herpesviruses in small- and large-sized periapical lesions. We did not conduct meta-analysis of these studies because they employed different techniques to identify herpesviral presence (**Table 4**). Only one study [104] reported significantly increased detection rates of HCMV in large-sized compared to small-sized periapical lesions. Also, Hernadi et al. [95, 98] showed that EBV infection was more frequent in large-sized compared with small-sized periapical lesions. Additionally, Hernadi et al. [96] reported positive correlation between the occurrence of HHV-6 and increased periapical lesion size.

During primary HCMV infection, the host responds by production of IL-1 β , IL-6, IL-12, TNF- α , IFN- γ , and prostaglandin E₂ (PGE₂) [117]. EBV infection stimulates the production of IL-1 β , IL-1 receptor agonist (IL-1Ra), IL-6, IL-8, IL-10, IL-12, TNF- α , IFN- γ , etc. [117]. In addition, increased production of proinflammatory cytokines induces bone resorption in periapical area [130–132]. Sabeti et al. [97] found significant correlation between EBV and HCMV infection and TNF- α , IFN- γ , IL-1 β , and IL-12 in symptomatic periapical lesions. Similar results were reported by Hernadi et al. [98]. They detected increased levels of TNF- α in apical periodontitis lesions infected with EBV in comparison with a lesion without EBV infection [98]. Although disturbed balance between RANKL and OPG has been correlated with increased periapical bone resorption [133], Yildirim et al. [87] did not find correlation between herpesviral presence and increased RANKL expression in apical periodontitis samples.

Growing knowledge about herpesviruses indicates that there is a great diversity of viral strains which might influence the course and severity of infection. Until now, researchers have identified more than 5000 different strains of herpesviruses. Different herpesviral genotypes possess specific pathogenic abilities due to differences in cell tropism and specific interactions with the host's immune system [71–73, 134].

Although, HCMV and EBV were the most investigated herpesviruses in periapical pathoses, only one study [105] analysed the occurrence of different HCMV gB and EBV EBNA-2 genotypes in apical periodontitis. Subtype classification of HCMV is mostly based on the gB gene which encodes a glycoprotein with high immune reactivity incorporated in the viral envelope. This glycoprotein is required for HCMV infectivity because it regulates viral penetration into cells, transmission of infection, and modulation of cellular transcription [135,

136]. Based on the nucleotide sequence of gB genes, all HCMV genotypes belong to one of four variants (gB I-gB IV) [137] with evidently different geographical distribution [138]. Depending on the sequence of EBV EBNA-2 gene, two types of EBV can be distinguished, EBV-1 and EBV-2. EBNA-2 acts as a transcription factor inducing the expression of viral latent membrane protein genes. EBNA-2 is also required for continued proliferation of lymphoblastoid cell lines in which the latent viral genome is maintained [139].

Our previous research [105] indicated that gB-II was more frequently detected than gB-I in both periapical lesions (42 versus 12%) and healthy control group (28 versus 0%) ($P = 0.036$). Additionally, EBV-1 was also more frequently detected compared to EBV-2 in both periapical lesions (74 versus 6%) and healthy control group (24 versus 4%) ($P = 0.001$). Our results were in accordance with previously reported occurrence of HCMV gB and EBV EBNA-2 genotypes in generalized chronic periodontitis and peri-implantitis tissues [140, 141]. On the other hand, our findings did not reveal significant differences between HCMV and EBV genotypes and clinical or histopathological features of apical periodontitis lesions. Also, Hernadi et al. [96] investigated the occurrence of HHV-6 subtypes (type A and B) in apical periodontitis. They have reported that subtype A was found in small-sized, asymptomatic lesions and in a control pulp sample, whereas subtype B was significantly associated with large sized symptomatic lesions.

The rates of herpesviral detection in acute apical abscess vary among analysed studies (Table 6). In studies of Chen et al. [94] and Ozbek et al. [101, 103], HCMV and EBV were the most frequently detected herpesviruses in acute apical abscesses. However, no significant differences were noted compared to healthy pulp controls and between small- and large-sized lesions [94, 101, 103] (Table 6). In contrast to these findings, Ferreira et al. [79, 80], reported very low occurrence of HCMV and EBV infection in acute apical abscesses among Brazilian population. Analysing the occurrence of all members of *Herpesviridae* family in acute apical abscess samples, they reported the increased detection rate of HHV-8 [79, 80].

HHV-8 was first described in Kaposi's sarcoma tissues from an HIV-positive individual [142]. Since then, epidemiological and molecular studies suggested that HHV-8 is the etiological agents of all subtypes of Kaposi's sarcoma and two B-cell lymphomas, i.e. primary effusion lymphoma and multicentric Castelman's disease [143–145]. HHV-8 DNA sequence have also been found in association with other diseases, such as pemphigus, various skin diseases, salivary gland tumours, multiple myeloma, and non-neoplastic lymphadenopathies of immunocompetent individuals, but the role of this virus in these diseases remains uncertain [146]. Until now, only these two studies [79, 80] investigated the occurrence of HHV-8 in periapical pathoses. Data from periodontal literature are also scarce and inconclusive, but it has been suggested that HHV-8 in immunocompetent patients may reduce the host defences and thereby contribute to destructive periodontal disease by mechanism similar to other herpesviruses [147, 148].

Assessing the studies included in this review, it is obvious that there is a wide variety in the detection rates of herpesviruses. Such discrepancies are mainly due to different methodological approaches for virus detection. In previous reports, Slots [76] claimed that observed variations in detection rates of herpesviruses can be caused by different inclusion criteria and

clinical status of study individuals, use of different diagnostic methods, or geographic differences in herpesvirus occurrence.

Replacing classical viral diagnostic techniques, the PCR method has become the standard methodology for the detection of herpesvirus nucleic acids [149]. Included studies used different variants of PCR method (**Table 4**). When discussing the results of the PCR analyses, several issues should be taken into consideration, including the selection of PCR method, the selection of primers, the high sensitivity of this technique, and the possible false-positive and false-negative results [70, 149].

Single stage or end-point PCR is a gel-based technique that identifies the target nucleic acid as either present or absent. Nested PCR, as one of the variants of classical PCR method, is used to increase the sensitivity and specificity of the PCR assay [149]. However, the results of this method should be taken with precaution because it may detect herpesviruses at copy counts too low to be of clinical significance. Additionally, it must be stressed that single stage and nested PCR cannot distinguish latent episomal viral DNA from genomic viral DNA. Oppositely to other variants of PCR methods, RT-PCR assay can detect and quantify RNA expression and may identify active herpesvirus infection [149]. That is the reason why RT-PCR method should be recommended as method of choice in herpesviruses detection. In addition, real-time PCR assay has been used to quantify herpesviruses at diseased periapical site. Increased viral load detected by real-time PCR can also be indicative of viral replication and active viral infection [127].

The sensitivity of PCR techniques is determined by the selection of primer pairs used in the PCR. Possible reason for different detection rates of herpesviruses among included studies may be due to the use of different primers [150]. The majority of studies [68, 69, 83–85, 90, 93, 95–97] tested the coding sequence of HCMV pp65 matrix protein which is transcribed late during the infectious cycle. On the other hand, two other studies [87, 89] reported different, immediate early gene primers for HCMV transcript detection. Similarly, identification of EBV products in analysed samples was not uniform. The PCRs in 10 studies [68, 69, 83–85, 87, 90, 97, 104, 105] were performed with amplification of genome encoding for the EBNA-2. Oppositely, studies by Li et al. [93] and Hernadi et al. [95, 96] reported different primers for the BLRF2 gene product and the Bam H1-W fragment of the EBV genome.

Such variations in use of different primers were not observed for HSV, HHV-6, and HHV-8 detection. Primers for glycoprotein D, as major component of the virion envelope and infected cell membranes, were used to analyse HSV infection in samples of periapical pathoses [68, 69, 83, 84]. HHV-6 was detected by amplification of the immediate early fragment that is conservative regulator region in its genome [96]. Additionally, Chen et al. [94] and Ferreira et al. [79, 80] reported the amplification of ORF26 gene of HHV-8 that represents a minor capsid protein.

In addition, it is important to be aware of possible false-negative and false-positive results using the PCR techniques. False-negative PCR results may be caused by inadequate sampling technique or by inhibitory effects of components of the amplification process. However, false-positive results may be caused by cross-contamination among samples or the contamination of samples by saliva.

Other related factors that influence the prevalence of herpesviruses are race/ethnicity and socio-economic status of individuals [151–153]. Epidemiological results show that as a country becomes more developed, the occurrence of herpesviruses may decrease. Herpesviruses seroprevalence tended to be the highest in South America, Africa, and Asia and the lowest in Western Europe and the United States [154–156]. Most of the studies analysed in this review were performed on North American [68, 69, 81, 83–85, 92–94, 97, 100] and European populations [86, 87, 89, 91, 95, 96, 99, 101, 103–105]. Results of these studies are in accordance with the herpesviruses seroprevalence in the United States [156] and Europe [157–162]. Moreover, data on herpesvirus seroprevalence among organ recipients in Iran [163], patients with HSV infection of the peripheral nervous system in Israel [164], patients with head and neck carcinomas in Japan [165], and patients with hematologic disorders in Brazil [166] are in line with results of herpesvirus detection rates in specimens of periapical pathoses.

All studies included in the final review were cross-sectional. A significant limitation of all the microbiological studies of endodontic infections is their cross-sectional nature. Given results of any cross-sectional study preclude any strong conclusions about involvement of certain identified microbiota in causation of disease. As a consequence, these results may only suggest possible association between certain microbial species and development of disease, and they cannot be used for determination of cause-and-effect relationship between them [40].

In conclusion, this study provides an updated review of the occurrence of herpesviruses in periapical pathoses with different clinical, histopathological, and radiographic features. HCMV and EBV were the most prevalent herpesviruses in apical periodontitis lesions, followed by HHV-8 in samples of acute apical abscesses. Several studies reported positive correlation between the occurrence of herpesviruses and clinical and histopathological features of apical periodontitis, but overall results are still controversial.

Presented results place periapical pathoses into a context of complex aetiology, with many aspects still remaining to be elucidated. It might be concluded that the etiopathogenesis of periapical pathoses involves specific bacteria and viruses, protective and destructive host immune responses, modifiable and non-modifiable environmental factors, and genetic and epigenetic factors.

It is well known that herpesviral infection can cause focal immunosuppression, but the specific molecular mechanisms by which herpesviruses may cause or exacerbate periapical pathoses still have to be identified. Further studies on experimental animal models or controlled longitudinal trials with potential antiviral therapy and quantification of viral copies as prognostic markers should provide more data on herpesviruses as a factor in the pathogenesis of the periapical inflammation.

Acknowledgements

Supported by Grants 175075 and 175073 from the Ministry of Education, Science and Technological Development of the Republic of Serbia.

Author details

Aleksandar Jakovljević^{1,4*}, Miroslav Andrić¹, Aleksandra Knežević², Katarina Beljić-Ivanović³, Maja Miletić⁴, Tanja Jovanović², Ljiljana Kesić⁵ and Jelena Milašin⁶

*Address all correspondence to: dr.sasuli@hotmail.com

1 Clinic of Oral surgery and Implantology, School of Dental Medicine, University of Belgrade, Belgrade, Serbia

2 Department of Virology, Institute of Microbiology and Immunology, Faculty of Medicine, University of Belgrade, Belgrade, Serbia

3 Clinic of Restorative Dentistry and Endodontics, School of Dental Medicine, University of Belgrade, Belgrade, Serbia

4 Department of Pathophysiology, School of Dental Medicine, University of Belgrade, Belgrade, Serbia

5 Department of Oral Medicine and Periodontology, Clinic of Dentistry, Medical Faculty, University of Nis, Nis, Serbia

6 Department of Human Genetics, School of Dental Medicine, University of Belgrade, Belgrade, Serbia

References

- [1] Nair PN. Pathogenesis of apical periodontitis and the causes of endodontic failure. *Crit Rev Oral Biol Med.* 2004;15:348–391. doi:10.1177/154411130401500604.
- [2] Figdor D. Apical periodontitis: a very prevalent problem. *Oral Surg Oral Med Oral Pathol Oral Radiol Endod.* 2002;94:651–652. doi:10.1067/moe.2002.130322.
- [3] Jiménez-Pinzón A, Segura-Egea JJ, Poyato-Ferrera M, Velasco-Ortega E, Ríos-Santos JV. Prevalence of apical periodontitis and frequency of root-filled teeth in an adult Spanish population. *Int Endod J.* 2004;37:167–173. doi:10.1111/j.0143-2885.2004.00759.x.
- [4] Eriksen HM. Epidemiology of apical periodontitis. In: Ørstavik D, Pitt Ford TR, editors. *Essential endodontology. Prevention and treatment of apical periodontitis.* 1st ed. London: Blackwell Science;1998. pp. 179–191.
- [5] Nair PN. Apical periodontitis: a dynamic encounter between root canal infection and host response. *Periodontol* 2000. 1997;13:121–148. doi:10.1111/j.1600-0757.1997.tb00098.x.

- [6] Siqueira JF Jr. Endodontic infections: concepts, paradigms, and perspectives. *Oral Surg Oral Med Oral Pathol Oral Radiol Endod.* 2002;94:281–293. doi:10.1067/moe.2002.126163.
- [7] Kakehashi S, Stanley HR, Fitzgerald RJ. The effects of surgical exposures of dental pulps in germ-free and conventional laboratory rats. *Oral Surg Oral Med Oral Pathol.* 1965;20:340–349. doi:10.1016/0030-4220(65)90166-0.
- [8] Sandquist G. Bacteriological studies of necrotic dental pulps [thesis]. Umea (Sweden): University of Umea; 1976.
- [9] Möller AJ, Fabricius L, Dahlén G, Ohman AE, Heyden G. Influence on periapical tissues of indigenous oral bacteria and necrotic pulp tissue in monkeys. *Scand J Dent Res.* 1981;89:475–484.
- [10] Stashenko P, Teles R, D'Souza R. Periapical inflammatory responses and their modulation. *Crit Rev Oral Biol Med.* 1998;9:498–521. doi:10.1177/10454411980090040701.
- [11] Siqueira JF Jr, Rocas IN, Ricucci D. Biofilms in endodontic infection. *Endod Topics.* 2012;22:33–49. doi:10.1111/j.1601-1546.2012.00279.x.
- [12] Paster BJ, Dewhirst FE. Molecular microbial diagnosis. *Periodontology* 2000. 2009;51:38–144.
- [13] Siqueira JF Jr, Rôças IN. Diversity of endodontic microbiota revisited. *J Dent Res.* 2009;88:969–81. doi:10.1177/0022034509346549.
- [14] Siqueira JF Jr, Alves FR, Rôças IN. Pyrosequencing analysis of the apical root canal microbiota. *J Endod.* 2011;37:1499–503. doi:10.1016/j.joen.2011.08.012.
- [15] Saito D, Leonardo Rde T, Rodrigues JL, Tsai SM, Höfling JF, Gonçalves RB. Identification of bacteria in endodontic infections by sequence analysis of 16S rDNA clone libraries. *J Med Microbiol.* 2006;55:101–7. doi:10.1099/jmm.0.46212-0.
- [16] Munson MA, Pitt-Ford T, Chong B, Weightman A, Wade WG. Molecular and cultural analysis of the microflora associated with endodontic infections. *J Dent Res.* 2002;81:761–6. doi:10.1177/154405910208101108.
- [17] Rôças IN, Siqueira JF Jr. Root canal microbiota of teeth with chronic apical periodontitis. *J Clin Microbiol.* 2008;46:3599–606. doi:10.1128/JCM.00431-08.
- [18] Nair PNR. Light and electron microscopic studies of root canal flora and periapical lesions. *J Endod.* 1987;13:29–39.
- [19] Ricucci D, Siqueira JF Jr. Biofilms and apical periodontitis: study of prevalence and association with clinical and histopathologic findings. *J Endod.* 2010;36:1277–88. doi:10.1016/j.joen.2010.04.007.

- [20] Metzger Z, Abramovitz I. Periapical lesions of endodontic origin. In: Ingle JI, Bakland LK, Baumgartner JC, editors. *Ingle's endodontics*. 6th ed. Hamilton: BC Decker Inc. 2008. p. 494.
- [21] Langeland K, Block RM, Grossman LI. A histopathologic and histobacteriologic study of 35 periapical endodontic surgical specimens. *J Endod*. 1977;3:8–23. doi:10.1016/S0099-2399(77)80217-3.
- [22] Nair PNR, Schmid-Meier E. An apical granuloma with epithelial integument. *Oral Surg Oral Med Oral Pathol*. 1986;62:698–703. doi:10.1016/0030-4220(86)90266-5.
- [23] Nair PNR, Pajarola G, Schroeder HE. Types and incidence of human periapical lesions obtained with extracted teeth. *Oral Surg Oral Med Oral Pathol Oral Radiol Endod*. 1996;81:93–102.
- [24] Cymerman JJ, Cymerman DH, Walters J, Nevins AJ. Human T lymphocyte subpopulations in chronic periapical lesions. *J Endod*. 1984;10:9–11. doi:10.1016/S0099-2399(84)80246-0.
- [25] Nilsen R, Johannessen AC, Skaug N, Matre R. In situ characterization of mononuclear cells in human dental periapical inflammatory lesions using monoclonal antibodies. *Oral Surg Oral Med Oral Pathol*. 1984;58:160–5. doi:10.1016/0030-4220(84)90131-2.
- [26] Torabinejad M, Kettering JD. Identification and relative concentration of B and T lymphocytes in human chronic periapical lesions. *J Endod*. 1985;11:122–5. doi:10.1016/S0099-2399(85)80230-2.
- [27] Yu SM, Stashenko P. Identification of inflammatory cells in developing rat periapical lesions. *J Endod*. 1987;13:535–40.
- [28] Gao Z, Mackenzie IC, Rittman BR, Korszun AK, Williams DM, Cruchley AT. Immunocytochemical examination of immune cells in periapical granulomata and odontogenic cysts. *J Oral Pathol*. 1988;17:84–90. doi:10.1111/j.1600-0714.1988.tb01512.x.
- [29] Barkhordar RA, Desouza YG. Human T-lymphocyte subpopulations in periapical lesions. *Oral Surg Oral Med Oral Pathol*. 1988;65:763–6.
- [30] Lukic A, Arsenijević N, Vujanić G, Ramić Z. Quantitative analysis of the immunocompetent cells in periapical granuloma: correlation with the histological characteristics of the lesions. *J Endod*. 1990;16:119–22.
- [31] Piattelli A, Artese L, Rosini S, Quaranta M, Musiani P. Immune cells in periapical granuloma: morphological and immunohistochemical characterization. *J Endod*. 1991;17:26–9. doi:10.1016/S0099-2399(07)80157-9.
- [32] Márton IJ, Kiss C. Characterization of inflammatory cell infiltrate in dental periapical lesions. *Int Endod J*. 1993;26:131–6. doi:10.1111/j.1365-2591.1993.tb00555.x.
- [33] Márton IJ, Kiss C. Overlapping protective and destructive regulatory pathways in apical periodontitis. *J Endod*. 2014;40:155–63.

- [34] Rodini CO, Lara VS. Study of the expression of CD68+ macrophages and CD8+ T cells in human granulomas and periapical cysts. *Oral Surg Oral Med Oral Pathol Oral Radiol Endod.* 2001;92:221–7.
- [35] Colić M, Gazivoda D, Vucević D, Vasilijić S, Rudolf R, Lukić A. Proinflammatory and immunoregulatory mechanisms in periapical lesions. *Mol Immunol.* 2009;47:101–13.
- [36] Nair PNR. Non-microbial endodontic disease. In: Ingle JI, Bakland LK, Baumgartner JC, editors. *Ingle's endodontics*. 6th ed. Hamilton: BC Decker Inc. 2008. p. 309.
- [37] Nair PN. New perspectives on radicular cysts: do they heal? *Int Endod J.* 1998;31:155–60. doi:10.1046/j.1365-2591.1998.00146.x.
- [38] Simon JH. Incidence of periapical cysts in relation to the root canal. *J Endod.* 1980;6:845–8. doi:10.1016/S0099-2399(80)80039-2.
- [39] Torabinejad M, Shabahang S. Pulp and periapical pathosis. In: Torabinejad M, Walton RE, editors. *Endodontics. Principles and practice*. 4th ed. St. Louise: Saunders/Elsevier; 2009. pp. 49–67.
- [40] Siqueira JF Jr, Rôças IN. Microbiology and treatment of acute apical abscesses. *Clin Microbiol Rev.* 2013;26:255–73. doi:10.1128/CMR.00082-12.
- [41] Williams BL, McCann GF, Schoenknecht FD. Bacteriology of dental abscesses of endodontic origin. *J Clin Microbiol.* 1983;18:770–4.
- [42] Brook I, Frazier EH, Gher ME. Aerobic and anaerobic microbiology of periapical abscess. *Oral Microbiol Immunol.* 1991;6:123–5. doi:10.1111/j.1399-302X.1991.tb00464.x.
- [43] Külekçi G, Inanç D, Koçak H, Kasapoglu C, Gümrü OZ. Bacteriology of dentoalveolar abscesses in patients who have received empirical antibiotic therapy. *Clin Infect Dis.* 1996;23 Suppl 1:S51–3. doi:10.1093/clinids/23.Supplement_1.S51.
- [44] Rôças IN, Siqueira JF Jr. Detection of novel oral species and phylotypes in symptomatic endodontic infections including abscesses. *FEMS Microbiol Lett.* 2005;250:279–85.
- [45] Larawin V, Naipao J, Dubey SP. Head and neck space infections. *Otolaryngol Head Neck Surg.* 2006;135:889–93. doi:10.1016/j.otohns.2006.07.007.
- [46] Moghimi M, Baart JA, Karagozoglu KH, Forouzanfar T. Spread of odontogenic infections: a retrospective analysis and review of the literature. *Quintessence Int.* 2013;44:351–61.
- [47] Daramola OO, Flanagan CE, Maisel RH, Odland RM. Diagnosis and treatment of deep neck space abscesses. *Otolaryngol Head Neck Surg.* 2009;141:123–30. doi:10.1016/j.otohns.2009.03.033.
- [48] Pappa H, Jones DC. Mediastinitis from odontogenic infection. A case report. *Br Dent J.* 2005;198:547–8.

- [49] Umeda M, Minamikawa T, Komatsubara H, Shibuya Y, Yokoo S, Komori T. Necrotizing fasciitis caused by dental infection: a retrospective analysis of 9 cases and a review of the literature. *Oral Surg Oral Med Oral Pathol Oral Radiol Endod.* 2003;95:283–90. doi:10.1067/moe.2003.85.
- [50] Kim IK, Kim JR, Jang KS, Moon YS, Park SW. Orbital abscess from an odontogenic infection. *Oral Surg Oral Med Oral Pathol Oral Radiol Endod.* 2007;103:e1–6. doi:10.1016/j.tripleo.2006.07.002.
- [51] Corson MA, Postlethwaite KP, Seymour RA. Are dental infections a cause of brain abscess? Case report and review of the literature. *Oral Dis.* 2001;7:61–5. doi:10.1034/j.1601-0825.2001.70112.x.
- [52] Pasqualini L, Mencacci A, Scarponi AM, et al. Cervical spondylodiscitis with spinal epidural abscess caused by *Aggregatibacter aphrophilus*. *J Med Microbiol.* 2008;57:652–5. doi:10.1099/jmm.0.47614-0.
- [53] Márton IJ. How does the periapical inflammatory process compromise general health? *Endodontic Topics.* 2004;8:3–14. doi:10.1111/j.1601-1546.2004.00095.x.
- [54] Segura-Egea JJ, Martín-González J, Castellanos-Cosano L. Endodontic medicine: connections between apical periodontitis and systemic diseases. *Int Endod J.* 2015;48:933–51. doi:10.1111/iej.12507.
- [55] Segura-Egea JJ, Jiménez-Pinzón A, Ríos-Santos JV, Velasco-Ortega E, Cisneros-Cabello R, Poyato-Ferrera M. High prevalence of apical periodontitis amongst type 2 diabetic patients. *Int Endod J.* 2005;38:564–9. doi:10.1111/j.1365-2591.2005.00996.x.
- [56] López-López J, Jané-Salas E, Estrugo-Devesa A, Velasco-Ortega E, Martín-González J, Segura-Egea JJ. Periapical and endodontic status of type 2 diabetic patients in Catalonia, Spain: a cross-sectional study. *J Endod.* 2011;37:598–601. doi:10.1016/j.joen.2011.01.002.
- [57] Marotta PS, Fontes TV, Armada L, Lima KC, Rôças IN, Siqueira JF Jr. Type 2 diabetes mellitus and the prevalence of apical periodontitis and endodontic treatment in an adult Brazilian population. *J Endod.* 2012;38:297–300. doi:10.1016/j.joen.2011.11.001.
- [58] Segura-Egea JJ, Castellanos-Cosano L, Machuca G, et al. Diabetes mellitus, periapical inflammation and endodontic treatment outcome. *Med Oral Patol Oral Cir Bucal.* 2012;17:e356–61. doi:10.4317/medoral.17452.
- [59] Morsani JM, Aminoshariae A, Han YW, Montagnese TA, Mickel A. Genetic predisposition to persistent apical periodontitis. *J Endod.* 2011;37:455–9. doi:10.1016/j.joen.2011.01.009.
- [60] Aminoshariae A, Kulild JC. Association of functional gene polymorphism with apical periodontitis. *J Endod.* 2015;41:999–1007.

- [61] de Sá AR, Moreira PR, Xavier GM, et al. Association of CD14, IL1B, IL6, IL10 and TNFA functional gene polymorphisms with symptomatic dental abscesses. *Int Endod J*. 2007;40:563–72.
- [62] Menezes-Silva R, Khaliq S, Deeley K, Letra A, Vieira AR. Genetic susceptibility to periapical disease: conditional contribution of MMP2 and MMP3 genes to the development of periapical lesions and healing response. *J Endod*. 2012;38:604–7. doi:10.1016/j.joen.2012.02.009.
- [63] Amaya MP, Criado L, Blanco B, et al. Polymorphisms of pro-inflammatory cytokine genes and the risk for acute suppurative or chronic nonsuppurative apical periodontitis in a Colombian population. *Int Endod J*. 2013;46:71–8. doi:10.1111/j.1365-2591.2012.02097.x.
- [64] Rauch B. Attempts to isolate a virus from infected root canals and periapical tissue using monkey kidney cells cultures. *J Can Dent A*. 1958;24:404–10.
- [65] Shindell E. Studies on the possible presence of a virus in subacute and chronic periapical granulomas. *Oral Surg Oral Med Oral Pathol*. 1962;15:1382–4. doi:10.1016/0030-4220(62)90359-6.
- [66] Parra B, Slots J. Detection of human viruses in periodontal pockets using polymerase chain reaction. *Oral Microbiol Immunol*. 1996;11:289–93. DOI:10.1111/j.1399-302X.1996.tb00183.x.
- [67] Contreras A, Slots J. Mammalian viruses in human periodontitis. *Oral Microbiol Immunol* 1996;11:381–6. doi:10.1111/j.1399-302X.1996.tb00199.x.
- [68] Sabeti M, Valles Y, Nowzari H, et al. Cytomegalovirus and Epstein–Barr virus DNA transcription in endodontic symptomatic lesions. *Oral Microbiol Immunol* 2003a; 18:104–8. doi:10.1034/j.1399-302X.2003.00055.x.
- [69] Sabeti M, Simon JH, Slots J. Cytomegalovirus and Epstein–Barr virus are associated with symptomatic periapical pathosis. *Oral Microbiol Immunol* 2003b;18:327–8. doi:10.1034/j.1399-302X.2003.00079.x.
- [70] Jakovljevic A, Andric M. Human cytomegalovirus and Epstein–Barr virus in etiopathogenesis of apical periodontitis: a systematic review. *J Endod* 2014;40:6–15. doi:10.1016/j.joen.2013.10.001.
- [71] Contreras A, Slots J. Herpesviruses in human periodontal disease. *J Periodontal Res*. 2000a;35:3–16. doi:10.1034/j.1600-0765.2000.035001003.x.
- [72] Slots J. Herpesviruses in periodontal diseases. *Periodontol* 2000. 2005;38:33–62. doi:10.1111/j.1600-0757.2005.00109.x.
- [73] Slots J. Human viruses in periodontitis. *Periodontol* 2000. 2010a;53:89–110. doi:10.1111/j.1600-0757.2009.00325.x.

- [74] Slots J, Sabeti M, Simon JH. Herpesviruses in periapical pathosis: an etiopathogenic relationship? *Oral Surg Oral Med Oral Pathol Oral Radiol Endod.* 2003;96:327–31. doi: 10.1016/S1079-2104(03)00352-4.
- [75] Slots J. Herpesviral-bacterial synergy in the pathogenesis of human periodontitis. *Curr Opin Infect Dis.* 2007;20:278–83. doi:10.1097/QCO.0b013e3280964da0.
- [76] Slots J. Herpesviral-bacterial interactions in periodontal diseases. *Periodontol* 2000. 2010b;52:117–40.
- [77] Ongrádi J, Sallay K, Kulcsár G. The decreased antibacterial activity of oral polymorphonuclear leukocytes coincides with the occurrence of virus-carrying oral lymphocytes and epithelial cells. *Folia Microbiol (Praha).* 1987;32:438–47.
- [78] Smith MacDonald E, Nowzari H, Contreras A, Flynn J, Morrison J, Slots J. Clinical and microbiological evaluation of a bioabsorbable and a nonresorbable barrier membrane in the treatment of periodontal intraosseous lesions. *J Periodontol.* 1998;69:445–53.
- [79] Ferreira DC, Rôças IN, Paiva SS, et al. Viral-bacterial associations in acute apical abscesses. *Oral Surg Oral Med Oral Pathol Oral Radiol Endod* 2011a;112:264–71. doi: 10.1016/j.tripleo.2011.01.029.
- [80] Ferreira DC, Paiva SSM, Carmo FL, et al. Identification of herpesviruses types 1 to 8 and human papillomavirus in acute apical abscesses. *J Endod* 2011b;37:10–6. doi: 10.1016/j.joen.2010.09.009.
- [81] Rider CA, Rupkalvis R, Miller AS, Chen SY. Search for evidence of three viral agents in radicular (periapical) cysts with immunohistochemistry. *Oral Surg Oral Med Oral Pathol Oral Radiol Endod.* 1995;80:87–91. doi:10.1016/S1079-2104(95)80022-0.
- [82] Heling I, Morag-Hezroni M, Marva E, Hochman N, Zakay-Rones Z, Morag A. Is herpes simplex virus associated with pulp/periapical inflammation? *Oral Surg Oral Med Oral Pathol Oral Radiol Endod.* 2001;91:359–61. doi:10.1067/moe.2001.113162.
- [83] Sabeti M, Simon JH, Nowzari H, et al. Cytomegalovirus and Epstein–Barr virus active infection in periapical lesions of teeth with intact crowns. *J Endod* 2003c;29:321–3. doi: 10.1097/00004770-200305000-00002.
- [84] Sabeti M, Slots J. Herpesviral-bacterial coinfection in periapical pathosis. *J Endod* 2004;30:69–72. doi:10.1097/00004770-200402000-00001.
- [85] Slots J, Nowzari H, Sabeti M. Cytomegalovirus infection in symptomatic periapical pathosis. *Int Endod J* 2004;37:519–24. doi:10.1111/j.1365-2591.2004.00816.x.
- [86] Kabak SL, Kabak YS, Anischenko SL. Light microscopic study of periapical lesions associated with asymptomatic apical periodontitis. *Ann Anat.* 2005;187:185–94. doi: 10.1016/j.aanat.2004.05.001.

- [87] Yildirim S, Yapar M, Kubar A, et al. Human cytomegalovirus, Epstein–Barr virus and bone resorption-inducing cytokines in periapical lesions of deciduous teeth. *Oral Microbiol Immunol* 2006;21:107–11. doi:10.1111/j.1399-302X.2006.00268.x.
- [88] Saboia-Dantas CJ, Coutrin de Toledo LF, Sampaio-Filho HR, et al. Herpesviruses in asymptomatic apical periodontitis lesions: an immunohistochemical approach. *Oral Microbiol Immunol* 2007;22:320–5. doi:10.1111/j.1399-302X.2007.00362.x.
- [89] Andric M, Milasin J, Jovanovic T, et al. Human cytomegalovirus is present in odontogenic cysts. *Oral Microbiol Immunol* 2007;22:347–51. doi:10.1111/j.1399-302X.2007.00369.x.
- [90] Yazdi KA, Sabeti M, Jabalameli F, et al. Relationship between human cytomegalovirus transcription and symptomatic apical periodontitis in Iran. *Oral Microbiol Immunol* 2008;23:510–4. doi:10.1111/j.1399-302X.2008.00471.x.
- [91] Sunde PT, Olsen I, Enersen M, et al. Human cytomegalovirus and Epstein–Barr virus in apical and marginal periodontitis: a role in pathology? *J Med Virol* 2008;80:1007–11. doi:10.1002/jmv.21180.
- [92] Sabeti M, Daneshmand A, Simon JH, et al. Cytomegalovirus-infected inflammatory cells in dental periapical lesions. *Oral Microbiol Immunol* 2009;24:434–6. doi:10.1111/j.1399-302X.2009.00540.x.
- [93] Li H, Chen V, Chen Y, et al. Herpesviruses in endodontic pathoses: association of Epstein–Barr virus with irreversible pulpitis and apical periodontitis. *J Endod* 2009;35:23–9. doi:10.1016/j.joen.2008.09.017.
- [94] Chen V, Chen Y, Li H, Kent K, Baumgartner JC, Machida CA. Herpesviruses in abscesses and cellulitis of endodontic origin. *J Endod*. 2009;35:182-8. DOI: 10.1016/j.joen.2008.11.018.
- [95] Hernádi K, Szalmás A, Mogyorósi R, et al. Prevalence and activity of Epstein–Barr virus and human cytomegalovirus in symptomatic and asymptomatic apical periodontitis lesions. *J Endod* 2010;36:1485–9. doi:10.1016/j.joen.2010.06.008.
- [96] Hernádi K, Csoma E, Adám B, et al. Association of human herpesvirus 6 subtypes with symptomatic apical periodontitis. *Oral Surg Oral Med Oral Pathol Oral Radiol Endod*. 2011;112:401–6. doi:10.1016/j.tripleo.2011.02.007.
- [97] Sabeti M, Kermani V, Sabeti S, et al. Significance of human cytomegalovirus and Epstein–Barr virus in inducing cytokine expression in periapical lesions. *J Endod* 2012;38:47–50.
- [98] Hernádi K, Gyöngyösi E, Mészáros B, et al. Elevated tumor necrosis factor-alpha expression in periapical lesions infected by Epstein–Barr virus. *J Endod* 2013;39:456–60. doi:10.1016/j.joen.2012.12.028.

- [99] Ozbek SM, Ozbek A , Yavuz MS. Detection of human cytomegalovirus and Epstein–Barr virus in symptomatic and asymptomatic apical periodontitis lesions by real-time PCR. *Med Oral Patol Oral Cir* 2013;18:811–6. doi:10.4317/medoral.18905.
- [100] Verdugo F, Castillo A, Simonian K, et al. Periodontopathogen and Epstein–Barr virus-associated periapical periodontitis may be the source of retrograde infectious peri-implantitis. *Clin Implant Dent Relat Res* 2015;17:199–207. doi:10.1111/cid.12083.
- [101] Ozbek A, Ozbek SM. Detection of herpesviruses and human papillomavirus in acute apical abscesses by real-time PCR. *Clin Oral Investig*. 2015a;19:343–7. doi:10.1007/s00784-014-1251-0.
- [102] Makino K, Takeichi O, Hatori K, Imai K, Ochiai K, Ogiso B. Epstein–Barr virus infection in chronically inflamed periapical granulomas. *PLoS One*. 2015;10:e0121548. doi:10.1371/journal.pone.0121548.
- [103] Ozbek SM, Ozbek A, Demiray T. Prevalence of several herpesviruses and human papillomavirus in acute apical abscesses. *Int Endod J*. 2015b. doi:10.1111/iej.12482.
- [104] Popovic J, Gasic J, Zivkovic S, et al. Prevalence of Human cytomegalovirus and Epstein–Barr virus in chronic periapical lesions. *Intervirology*. 2015;58:271–7. doi:10.1159/000441208.
- [105] Jakovljevic A, Andric M, Knezevic A, et al. Human cytomegalovirus and Epstein–Barr Virus genotypes in apical periodontitis lesions. *J Endod*. 2015;41:1847–51. doi:10.1016/j.joen.2015.08.027.
- [106] Gregory WB Jr, Brooks LE, Penick EC. Herpes zoster associated with pulpless teeth. *J Endod*. 1975;1:32–5. doi:10.1016/S0099-2399(75)80248-2.
- [107] Goon WW, Jacobsen PL. Prodromal odontalgia and multiple devitalized teeth caused by a herpes zoster infection of the trigeminal nerve: report of case. *J Am Dent Assoc*. 1988;116:500–4. doi:10.14219/jada.archive.1988.0301.
- [108] Wadden JV. Extensive endodontic involvement following herpes zoster attack to facial area: report of a case. *Northwest Dent*. 1991;70:31.
- [109] Ramchandani PL, Mellor TK. Herpes zoster associated with tooth resorption and periapical lesions. *Br J Oral Maxillofac Surg*. 2007;45:71–3. doi:10.1016/j.bjoms.2005.05.008.
- [110] Gupta S, Sreenivasan V, Patil PB. Dental complications of herpes zoster: Two case reports and review of literature. *Indian J Dent Res*. 2015;26:214–9. doi:10.4103/0970-9290.159175.
- [111] Cai MS, Li ML, Zheng CF. Herpesviral infection and Toll-like receptor 2. *Protein Cell*. 2012;3:590–601.
- [112] Wagner M, Gutermann A, Podlech J, Reddehase MJ, Koszinowski UH. Major histocompatibility complex class I allele-specific cooperative and competitive interactions

between immune evasion proteins of cytomegalovirus. *J Exp Med*. 2002;196:805–16. doi:10.1084/jem.20020811.

- [113] Tortorella D, Gewurz BE, Furman MH, Schust DJ, Ploegh HL. Viral subversion of the immune system. *Annu Rev Immunol*. 2000;18:861–926. doi:10.1146/annurev.immunol.18.1.861.
- [114] Rossini G, Cerboni C, Santoni A, et al. Interplay between human cytomegalovirus and intrinsic/innate host responses: a complex bidirectional relationship. *Mediators Inflamm*. 2012;2012:607276. doi:10.1155/2012/607276.
- [115] Varani S, Frascaroli G, Homman-Loudiyi M, Feld S, Landini MP, Söderberg-Nauclér C. Human cytomegalovirus inhibits the migration of immature dendritic cells by down-regulating cell-surface CCR1 and CCR5. *J Leukoc Biol*. 2005;77:219–28. doi:10.1189/jlb.0504301.
- [116] Bale JF Jr, Kern ER, Overall JC Jr, Baringer JR. Impaired migratory and chemotactic activity of neutrophils during murine cytomegalovirus infection. *J Infect Dis*. 1983;148:518–25.
- [117] Mogensen TH, Paludan SR. Molecular pathways in virus-induced cytokine production. *Microbiol Mol Biol Rev*. 2001;65:131–50. doi:10.1128/MMBR.65.1.131-150.2001.
- [118] Alcami A, Koszinowski UH. Viral mechanisms of immune evasion. *Trends Microbiol*. 2000; 8:410–8. doi:10.1016/S0966-842X(00)01830-8.
- [119] Thomassen MJ, Divis LT, Fisher CJ. Regulation of human alveolar macrophage inflammatory cytokine production by interleukin-10. *Clin Immunol Immunopathol*. 1996;80:321–4. doi:10.1006/clin.1996.0130.
- [120] Kotenko SV, Sacconi S, Izotova LS, Mirochnitchenko OV, Pestka S. Human cytomegalovirus harbors its own unique IL-10 homolog (cmvIL-10). *Proc Natl Acad Sci USA*. 2000;97:1695–700. doi:10.1073/pnas.97.4.1695.
- [121] Salek-Ardakani S, Arrand JR, Mackett M. Epstein–Barr virus encoded interleukin-10 inhibits HLA-class I, ICAM-1, and B7 expression on human monocytes: implications for immune evasion by EBV. *Virology*. 2002;304:342–51. doi:10.1006/viro.2002.1716.
- [122] Stern J, Shai E, Zaks B, et al. Reduced expression of gamma interferon in serum and marked lymphoid depletion induced by *Porphyromonas gingivalis* increase murine morbidity and mortality due to cytomegalovirus infection. *Infect Immun*. 2004;72:5791–8. doi:10.1128/IAI.72.10.5791-5798.2004.
- [123] Sugano N, Ikeda K, Oshikawa M, et al. Relationship between *Porphyromonas gingivalis*, Epstein–Barr virus infection and reactivation in periodontitis. *J Oral Sci*. 2004;46:203–6. doi:10.2334/josnusd.46.203.

- [124] Teughels W, Sliepen I, Quirynen M, et al. Human cytomegalovirus enhances *A. actinomycetemcomitans* adherence to cells. *J Dent Res*. 2007;86:175–80. doi:10.1177/154405910708600213.
- [125] Dai L, DeFee MR, Cao Y, et al. Lipoteichoic acid (LTA) and lipopolysaccharides (LPS) from periodontal pathogenic bacteria facilitate oncogenic herpesvirus infection within primary oral cells. *PLoS One*. 2014;9:e101326. doi:10.1371/journal.pone.0101326.
- [126] Kubar A, Saygun I, Yapar M, Ozdemir A, Slots J. Real-time PCR quantification of cytomegalovirus in aggressive periodontitis lesions using TaqMan technology. *J Periodontal Res*. 2004;39:81–6. doi:10.1111/j.1600-0765.2004.00707.x.
- [127] Kubar A, Saygun I, Ozdemir A, Yapar M, Slots J. Real-time polymerase chain reaction quantification of human cytomegalovirus and Epstein–Barr virus in periodontal pockets and the adjacent gingiva of periodontitis lesions. *J Periodontal Res*. 2005;40:97–104. doi:10.1111/j.1600-0765.2005.00770.x.
- [128] Konstantinidis A, Sakellari D, Papa A, Antoniadis A. Real-time polymerase chain reaction quantification of Epstein–Barr virus in chronic periodontitis patients. *J Periodontal Res*. 2005;40:294–8. doi:10.1111/j.1600-0765.2005.00796.x.
- [129] Radics T. The role of inflammatory and immunological processes in the development of chronic apical periodontitis [thesis]. Debrecen (Hungary): University of Debrecen; 2004.
- [130] Gazivoda D, Dzopalic T, Bozic B, Tatomirovic Z, Brkic Z, Colic M. Production of pro-inflammatory and immunoregulatory cytokines by inflammatory cells from periapical lesions in culture. *J Oral Pathol Med* 2009;38:605–11.
- [131] Teixeira-Salum TB, Rodrigues DB, Gervasio AM, Souza CJ, Rodrigues V Jr, Loyola AM. Distinct Th1, Th2 and Treg cytokines balance in chronic periapical granulomas and radicular cysts. *J Oral Pathol Med* 2010;39:250–6. doi:10.1111/j.1600-0714.2009.00863.x.
- [132] Jakovljevic A, Knezevic A, Karalic D, et al. Pro-inflammatory cytokine levels in human apical periodontitis: correlation with clinical and histological findings. *Aust Endod J*. 2015;41:72–7. doi:10.1111/aej.12072.
- [133] Belibasakis GN, Rechenberg DK, Zehnder M. The receptor activator of NF- κ B ligand-osteoprotegerin system in pulpal and periapical disease. *Int Endod J*. 2013;46:99–111. doi:10.1111/j.1365-2591.2012.02105.x.
- [134] Puchhammer-Stöckl E, Görzer I. Cytomegalovirus and Epstein–Barr virus subtypes—the search for clinical significance. *J Clin Virol*. 2006;36:239–48. doi:10.1016/j.jcv.2006.03.004.
- [135] Navarro D, Paz P, Tugizov S, et al. Glycoprotein B of human cytomegalovirus promotes virion penetration into cells, transmission of infection from cell to cell, and fusion of infected cells. *Virology* 1993;197:143–58. doi:10.1006/viro.1993.1575.

- [136] Simmen KA, Singh J, Luukkonen BG, et al. Global modulation of cellular transcription by human cytomegalovirus is initiated by viral glycoprotein B. *Proc Natl Acad Sci USA* 2001;98:7140–5. doi:10.1073/pnas.121177598.
- [137] Chou SW, Dennison KM. Analysis of interstrain variation in cytomegalovirus glycoprotein B sequences encoding neutralization-related epitopes. *J Infect Dis* 1991;163:1229–34. doi:10.1093/infdis/163.6.1229.
- [138] Zipeto D, Hong C, Gerna G, et al. Geographic and demographic differences in the frequency of human cytomegalovirus gB genotypes 1-4 in immunocompromised patients. *AIDS Res Hum Retroviruses* 1998;14:533–6. doi:10.1089/aid.1998.14.533.
- [139] Dambaugh T, Hennessy K, Chamnankit L, et al. U2 region of Epstein–Barr virus DNA may encode Epstein–Barr nuclear antigen 2. *Proc Natl Acad Sci USA* 1984;81:7632–6. doi: 10.1073/pnas.81.23.7632.
- [140] Wu YM, Yan J, Ojcius DM, et al. Correlation between infections with different genotypes of human cytomegalovirus and Epstein–Barr virus in subgingival samples and periodontal status of patients. *J Clin Microbiol* 2007;45:3665–70.
- [141] Jankovic S, Aleksic Z, Dimitrijevic B, et al. Correlation between different genotypes of human cytomegalovirus and Epstein–Barr virus and peri-implant tissue status. *Aust Dent J* 2011;56:382–8. doi:10.1111/j.1834-7819.2011.01360.x.
- [142] Chang Y, Cesarman E, Pessin M.S, et al. Identification of herpesvirus-like DNA sequences in AIDS-associated Kaposi’s sarcoma. *Science*. 1994;265:1865–1869.
- [143] Cesarman E, Chang Y, Moore PS, Said JW, Knowles DM. Kaposi’s sarcoma-associated herpesvirus-like DNA sequences in AIDS-related body-cavity-based lymphomas. *N Engl J Med*.1995;332:1186–1191.
- [144] Cesarman E, Knowles DM. The role of Kaposi’s sarcoma-associated herpesvirus (KSHV/HHV-8) in lymphoproliferative diseases. *Semin Cancer Biol*. 1999;9:165–74. doi: 10.1006/scbi.1998.0118.
- [145] Soulier J, Grollet L, Oksenhendler E, et al. Kaposi’s sarcoma-associated herpesvirus-like DNA sequences in multicentric Castlemán’s disease. *Blood*. 1995;86:1276–80.
- [146] Ablashi DV, Chatlynne LG, Whitman JE Jr, Cesarman E. Spectrum of Kaposi’s sarcoma-associated herpesvirus, or human herpesvirus 8, diseases. *Clin Microbiol Rev*. 2002;15:439–64. doi:10.1128/CMR.15.3.439-464.2002.
- [147] Mardirossian A, Contreras A, Navazesh M, Nowzari H, Slots J. Herpesviruses 6, 7 and 8 in HIV- and non-HIV-associated periodontitis. *J Periodontal Res*. 2000;35:278–84. doi: 10.1034/j.1600-0765.2000.035005278.x.
- [148] Contreras A, Nowzari H, Slots J. Herpesviruses in periodontal pocket and gingival tissue specimens. *Oral Microbiol Immunol*. 2000b;15:15–8. doi:10.1034/j.1399-302x.2000.150103.x.

- [149] Slots J. Periodontal herpesviruses: prevalence, pathogenicity, systemic risk. *Periodontol* 2000. 2015;69:28–45. doi:10.1111/prd.12085.
- [150] Haque T, Crawford DH. PCR amplification is more sensitive than tissue culture methods for Epstein–Barr virus detection in clinical material. *J Gen Virol*. 1997;78:3357–60. doi:10.1099/0022-1317-78-12-3357.
- [151] Stadler LP, Bernstein DI, Callahan ST, et al. Seroprevalence of cytomegalovirus (CMV) and risk factors for infection in adolescent males. *Clin Infect Dis*. 2010;51:e76–81. doi:10.1086/656918.
- [152] Stadler LP, Bernstein DI, Callahan ST, et al. Seroprevalence and risk factors for cytomegalovirus infections in adolescent females. *J Pediatric Infect Dis Soc*. 2013;2:7–14. doi:10.1093/jpids/pis076.
- [153] Stowe RP, Peek MK, Perez NA, Yetman DL, Cutchin MP, Goodwin JS. Herpesvirus reactivation and socioeconomic position: a community-based study. *J Epidemiol Community Health*. 2010;64:666–71. doi:10.1136/jech.2008.078808.
- [154] Looker KJ, Garnett GP. A systematic review of the epidemiology and interaction of herpes simplex virus types 1 and 2. *Sex Transm Infect*. 2005;81:103–7. doi:10.1136/sti.2004.012039.
- [155] Maeda A, Sato T, Wakiguchi H. Epidemiology of Epstein–Barr virus (EBV) infection and EBV-associated diseases. *Nihon Rinsho*. 2006;64:609–12.
- [156] Cannon MJ, Schmid DS, Hyde TB. Review of cytomegalovirus seroprevalence and demographic characteristics associated with infection. *Rev Med Virol*. 2010;20:202–13. doi:10.1002/rmv.655.
- [157] Varga M, Görög D, Kári D, et al. Cytomegalovirus seroprevalence among solid organ donors in Hungary: correlations with age, gender, and blood group. *Transplant Proc*. 2011;43:1233–5. doi:10.1016/j.transproceed.2011.03.067.
- [158] Mutlu B, Günlemez A, Türker G, Gökalp AS, Willke A. Is serologic screening necessary in the donor bloods for cytomegalovirus seronegative blood transfusion to risky patients? *Mikrobiyol Bul*. 2008;42:337–41.
- [159] Pejčić A, Kesic L, Milasin J. Association between periodontopathogens and CRP levels in patients with periodontitis in Serbia. *J Dent Res Dent Clin Dent Prospects*. 2011;5:10–6.
- [160] Petrović SM, Zelić K, Milasin J, Popović B, Pucar A, Zelić O. Detection of herpes simplex virus type 1 in gingival crevicular fluid of gingival sulcus/periodontal pocket using polymerase chain reaction. *Srp Arh Celok Lek*. 2014;142:296–300.
- [161] Djuric M, Jankovic L, Jovanovic T, et al. Prevalence of oral herpes simplex virus reactivation in cancer patients: a comparison of different techniques of viral detection. *J Oral Pathol Med*. 2009;38:167–73. doi:10.1111/j.1600-0714.2008.00684.x.

- [162] Banko A, Lazarevic I, Cupic M, Stevanovic G, Borcic I, Jovanovic T. Carboxy-terminal sequence variation of LMP1 gene in Epstein–Barr-virus-associated mononucleosis and tumors from Serbian patients. *J Med Virol.* 2012;84:632–42. doi:10.1002/jmv.23217.
- [163] Taherimahmoudi M, Ahmadi H, Baradaran N, et al. Cytomegalovirus infection and disease following renal transplantation: preliminary report of incidence and potential risk factors. *Transplant Proc.* 2009;41:2841–4. doi:10.1016/j.transproceed.2009.07.027.
- [164] Steiner I. Herpes virus infection of the peripheral nervous system. *Handb Clin Neurol.* 2013;115:543–58. doi:10.1016/B978-0-444-52902-2.00031-X.
- [165] Deng Z, Uehara T, Maeda H, et al. Epstein–Barr virus and human papillomavirus infections and genotype distribution in head and neck cancers. *PLoS One.* 2014;9:e113702. doi:10.1371/journal.pone.0113702.
- [166] de Matos SB, Meyer R, Lima FW. Seroprevalence and serum profile of cytomegalovirus infection among patients with hematologic disorders in Bahia State, Brazil. *J Med Virol.* 2011;83:298–304. doi:10.1002/jmv.21965.

