

# We are IntechOpen, the world's leading publisher of Open Access books Built by scientists, for scientists

## 4,800

Open access books available

## 122,000

International authors and editors

## 135M

Downloads

Our authors are among the

## 154

Countries delivered to

## TOP 1%

most cited scientists

## 12.2%

Contributors from top 500 universities

**WEB OF SCIENCE™**Selection of our books indexed in the Book Citation Index  
in Web of Science™ Core Collection (BKCI)

Interested in publishing with us?  
Contact [book.department@intechopen.com](mailto:book.department@intechopen.com)

Numbers displayed above are based on latest data collected.  
For more information visit [www.intechopen.com](http://www.intechopen.com)



---

# Advances in Management of Class II Malocclusions

---

Azita Tehranchi, Hossein Behnia,  
Farnaz Younessian and Sahar Hadadpour

Additional information is available at the end of the chapter

<http://dx.doi.org/10.5772/63348>

---

## Abstract

Although mandibular advancement by bilateral sagittal split osteotomy seems to be a good mandibular treatment option to treat skeletal class II malocclusion, it is less stable than setback; relapse depends on a wide range of patient-centered and surgeon-centered factors relating to the skill and experience of the surgeon, proper seating of the condyles, the exact amount of mandibular advancement, the tension of the muscles and soft tissues, the mandibular plane angle, and the patient's age. In fact, patients with low and high mandibular plane angles have increased vertical and horizontal relapses, respectively. Nonsurgical management of class II malocclusion may be an option by which to effectively manage such cases. The present chapter discusses different treatment modalities for clinical management of class II malocclusion in growing and non-growing patients.

**Keywords:** class II malocclusion, diagnosis, treatment, management, advances

---

## 1. Introduction

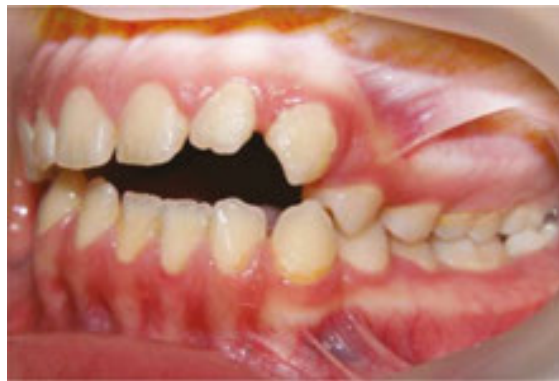Class II malocclusion is among the most common developmental anomalies with a prevalence ranging from 15 to 30% in most populations [1, 2]. This malocclusion is likely to produce significant negative esthetic, psychological, and social effects [3–6]. This dentofacial anomaly can be divided into two different categories based on the involved arch to maxillary excess or mandibular deficiency [7, 8]. The resulting anomaly may demonstrate various severities of class II malocclusion in different ages, which dictates the preferred approach to clinical management.

## 2. Etiology and pathogenesis of class II malocclusion

Like other types of malocclusions, the etiology of class II malocclusion has been linked to hereditary and environmental factors [9].

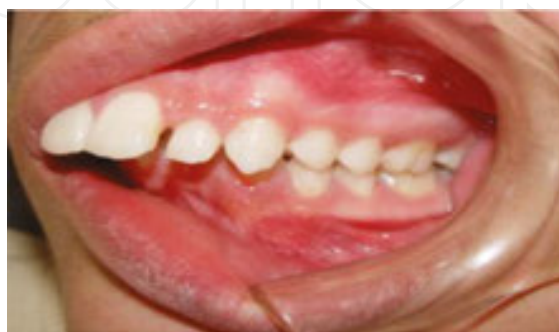### 2.1. Class II division 1

Proclination of upper incisors and/or retroinclination of the lower incisors by a habit or the soft tissues can result in an increased overjet in any type of skeletal pattern [10]. In class II division 1, the lips of the parents are usually incompetent and they try to compensate it via circumoral muscular activity, rolling the lower lip behind the upper incisors, or moving the tongue forward between the incisors, or a combination of all these items [11]. Finger-sucking or other oral habits may also lead to the development of this malocclusion, mostly following imbalances of the buccinator muscles and tongue force, and narrowing the maxillary arch. In addition, habits usually procline the upper incisors and retrocline the lower incisors (**Figure 1**).



**Figure 1.** Prolonged thumb-sucking habit creating asymmetric open bite and class II malocclusion.

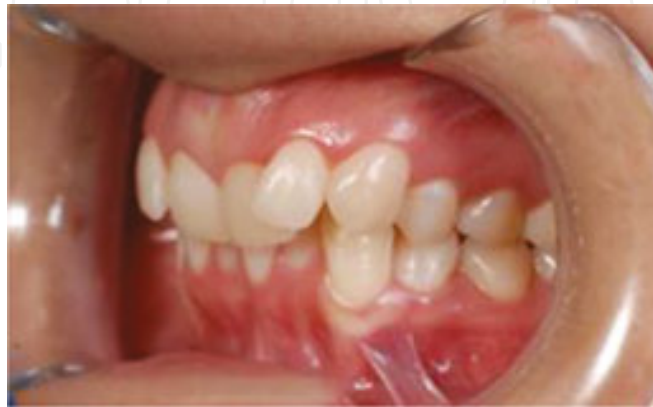Dental features such as tooth size arch length discrepancies could be involved in developing class II malocclusion, which might be the reason for the labial movement of the upper incisors resulting in exacerbation of the overjet (**Figure 2**).



**Figure 2.** Class II div 1 malocclusion with class II molar and canine relationship and increased overjet and overbite.

## 2.2. Class II division 2

Vertical dimension of class II division 2 patients is usually decreased in comparison to other types, which may result in the absence of an occlusal stop on lower incisors and consequently an increase in the overbite [11]. Dental crowding also, in contrast to the div 1 category, is exacerbated by retroinclination of the upper incisors [11, 12]. Active muscular lips are responsible for upper and lower retroinclination in this type (**Figure 3**).

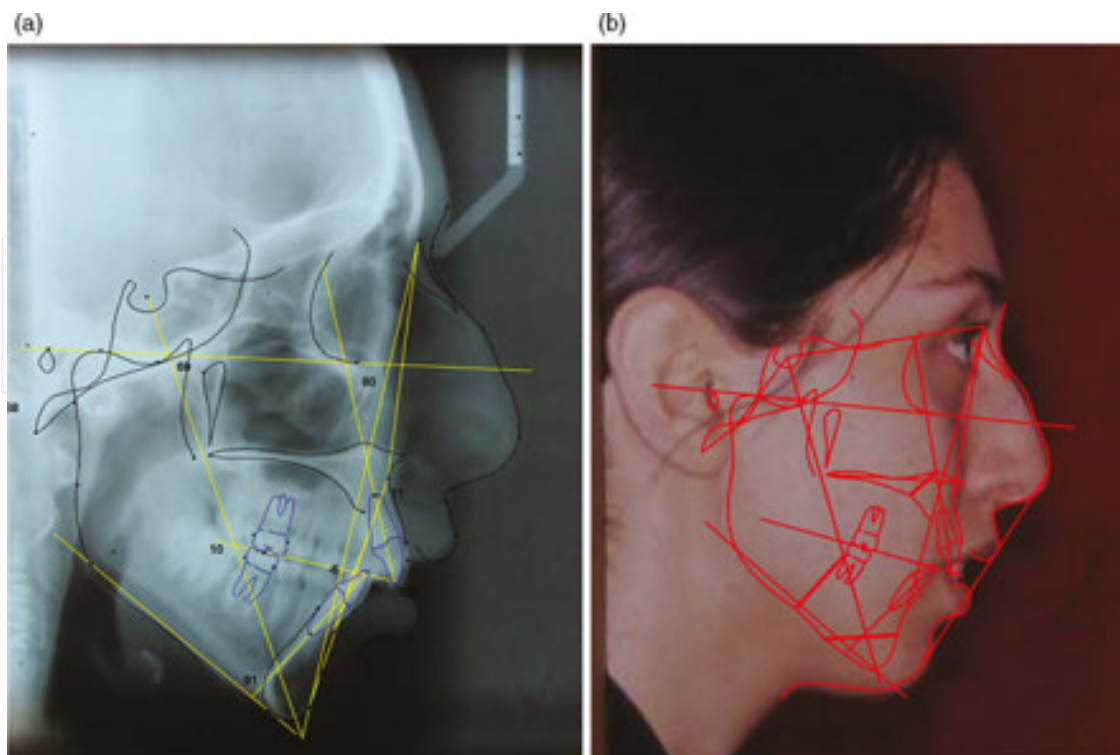


**Figure 3.** Retroclined upper central incisors, proclined laterals, and increased overbite in a class II div 2 case.

## 3. Diagnosis and clinical features of class II malocclusion

As in other types of malocclusions, class II malocclusion could be identified based on precise clinical evaluation (extra- and intra-oral features), diagnostic aids (history, photographic analysis, radiographic analysis, and cast analysis), and functional analysis (examination of postural rest position and maximum intercuspation, examination of the temporomandibular joint and orofacial dysfunction) of the patients [11–13]. The angle defined class II malocclusion as characterized by a distal relation of the lower to the upper permanent first molars to the extent of more than one-half the width of one cusp and the maxillary incisors being protrusive [14]. Class II division 1 patients demonstrate convex profile, dolichocephalic shape of the head, shallow/deep mentolabial sulcus, hyperactive mentalis, and upper lip. Class II division 2 patients present straight to convex profile, mesocephalic or dolichocephalic head shape, normal or hyperactive mentolabial sulcus, and normal or hyperactive upper lip [11, 12].

The presence of distal step molar relation, tooth size discrepancy, and/or excessive overjet may lead the clinicians to a false interpretation of skeletal class II malocclusion [9]. Skeletal class II malocclusion components may be classified by maxillomandibular relationship (mandibular retrognathism, midface protrusion or both), the cranial base length (increased length of the anterior cranial base: midface protrusion, while lengthening of the posterior cranial base: more retruded position of the temporomandibular articulation), vertical discrepancy (anterior upper face height often greater than normal), and steep occlusal plane (**Figure 4**) [9].



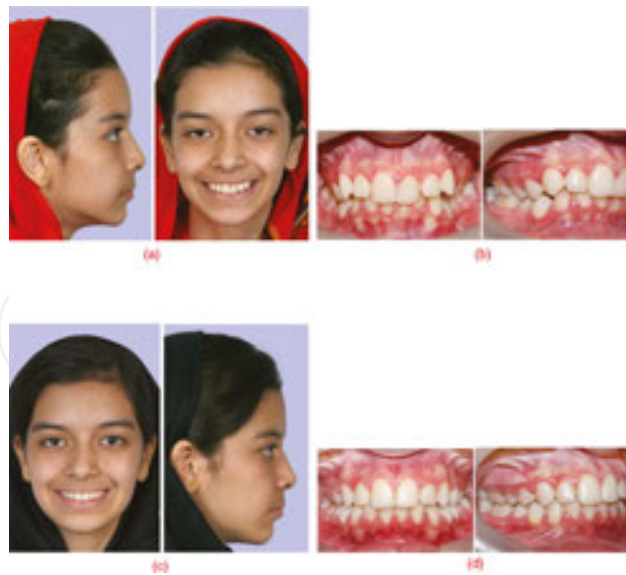**Figure 4.** (a) Lateral cephalometric analysis of a patient with class II malocclusion and vertical growth pattern. (b) Superimposition of lateral cephalometric analysis on the soft-tissue profile of the patient (overlay tracing).

## 4. Treatment of class II malocclusion

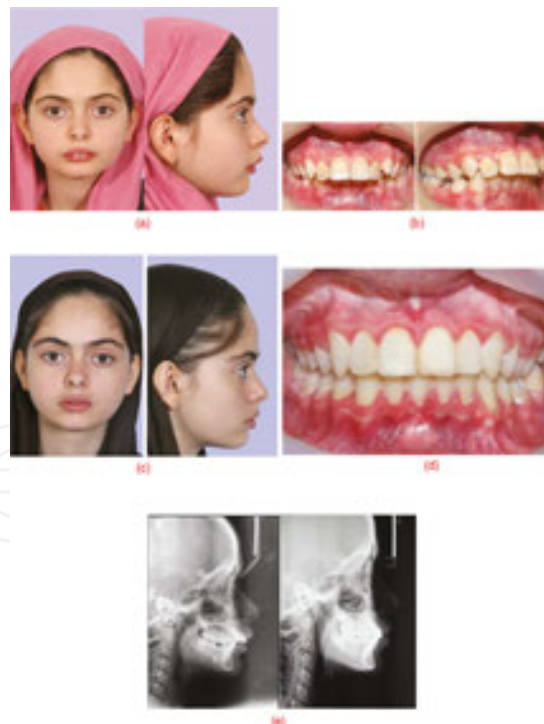Treatment strategies of class II malocclusion are categorized based on the growing and non-growing status of patients. Treatment timing of class II malocclusion has long been a topic of controversy for decades [15–17]. The literature is replete with research aimed at answering most clinical challenges of this type of malocclusion [18]. The existing evidence suggests that providing early orthodontic treatment for children with class II malocclusion and prominent upper front teeth is more effective in reducing the incidence of incisal trauma than providing one course of orthodontic treatment when the child is in early adolescence [19].

### 4.1. Early management in the mixed dentition

The best treatment modalities for class II malocclusion in growing patients include using functional appliances either removable (Activator, Bionator, Frankel, and Twin-block) or fixed appliances (MARA, cemented Twin-block, or Herbst appliance) that mostly enhance further mandibular growth via mandibular advancement and also headgear (Cervical, Highpull, and combination type), which provides extra oral force to restrict further maxillary growth [20–22] (Figures 5 and 6).



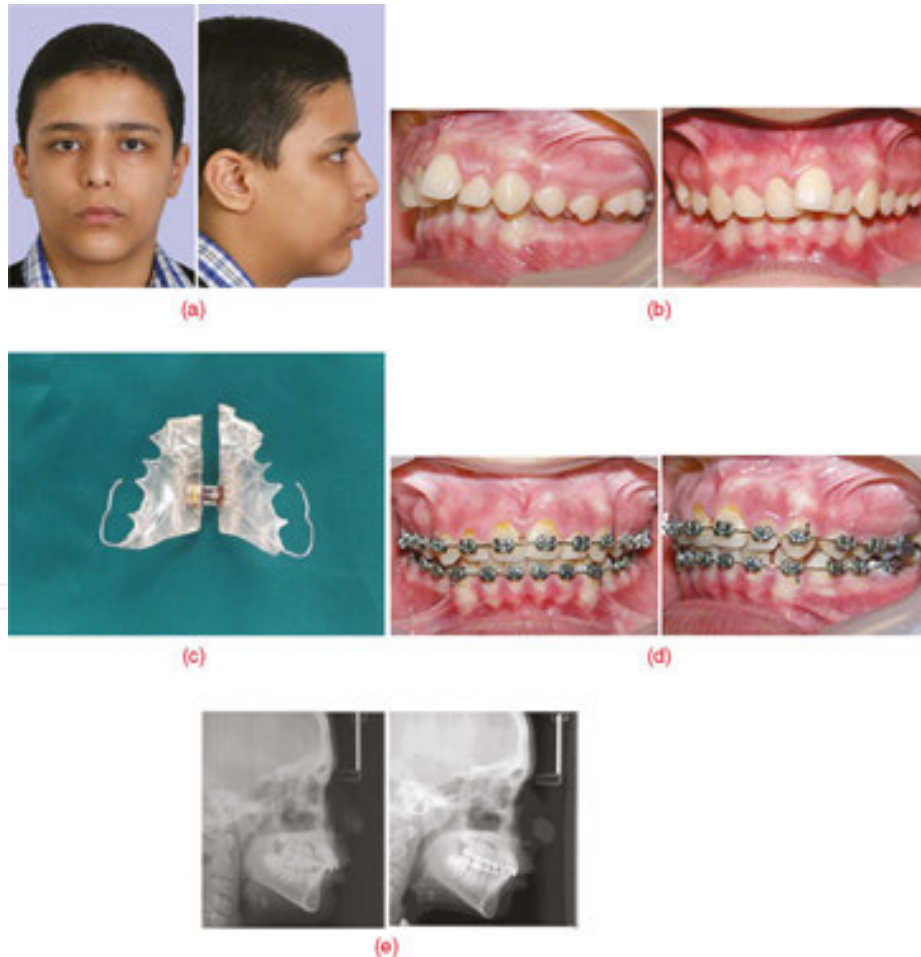
**Figure 5.** (a) Patient at age 11 years: frontal and profile photographs of the patient before treatment. (b) Intraoral photographs of the patient showing class II div 2 malocclusion. (c) Patient at age 13 years: photographs of the patient after treatment with cervical headgear and fixed orthodontic treatment. (d) Intraoral photographs of the patient after treatment.



**Figure 6.** (a) Frontal and profile photographs of the patient at age 12 years prior to treatment. (b) Intraoral photographs of the patient showing class II div 1 malocclusion with increased overjet and overbite before treatment. (c) Photographs of the patient at age 14 years after an 8-month treatment with Twin-block, followed by fixed orthodontic treatment. (d) Intraoral photograph of the patient after treatment. (e) Pretreatment and posttreatment lateral cephalograms.

Both removable functional appliances and headgear therapy depend on the cooperation of the patients. However, in contrast to the theory, there would not be a clear cut between clinical indications of these two broad clinical interventions of class II malocclusions [23]. Among the different removable appliances, Twin-block is used more often [18], which can efficiently promote mandibular growth, restrict further forward growth of the maxilla, and improve skeletal relationships in growing skeletal class II individuals with mandibular retrusion [24, 25].

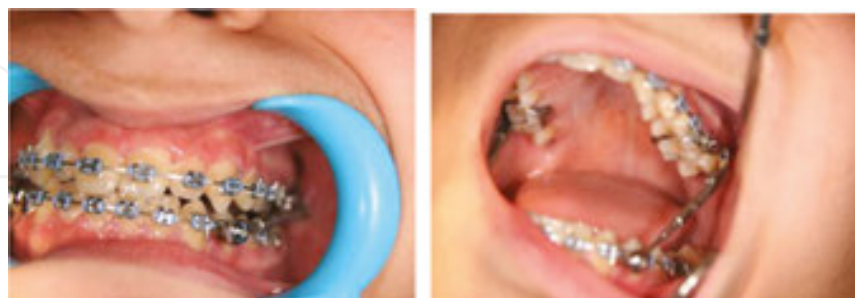**Figure 7** demonstrates a 14-year-old boy with class II malocclusion and bilateral buccal crossbite (Brodie syndrome). His mandible was totally locked and could not grow normally. Treatment began with a removable anterior bite plate, an open midpalatal screw in the acrylic portion for the upper arch in order to constrict the expanded ridge, and a Quad-helix appliance for the lower arch to expand the ridge. After 3 months, treatment was continued with a Twin-block appliance and an open screw in the maxilla. Fixed orthodontic treatment was performed for only 6 months.



**Figure 7.** (a) Frontal and profile photographs of the patient before treatment. (b) Intraoral photograph before treatment. (c) Anterior bite plate and open screw in midpalatal portion. (d) Intraoral photograph of the patient 6 months after beginning the treatment. (e) Pretreatment and posttreatment lateral cephalograms.

Several systematic review studies have investigated the present literature on the effect of treatment with functional appliances in comparison with untreated controls and demonstrated that skeletal changes were statistically significant, but unlikely to be clinically significant [26]. The limited quality and heterogeneity of the present studies in this field restrict the power of pure clinical judgment. However, in two recent systematic review articles, removable functional appliances were effective in improving class II malocclusion in short term, although their effects are mainly dentoalveolar, rather than skeletal [27]. On the other hand, more long-term skeletal effects following removable functional appliances were seen in patients during their pubertal growth phase, compared to prepubertal phase [18, 25]. However, their soft-tissue changes were minimal from the clinical standpoint [28].

Fixed functional appliances were introduced first by Emil Herbst to overcome the cooperation obstacle of removable appliances [29]. The key differences between removable and fixed appliances are different working hours (intermittent vs. continuous), and also optimal treatment timing (before puberty growth vs. at or after puberty spurt) and direction of further growth [30]. To date, there are a limited number of studies evaluating clinical effectiveness and patient's experience and perceptions of these fixed functional appliances [23]. As it is stated in the literature, fixed functional treatment is effective when performed during the pubertal growth phase, and very little data are available on postpubertal patients [31]. Various types of fixed functional appliances (rigid, semirigid, and flexible) have been developed and used in clinical settings [13] (**Figure 8**). However, dental changes including mesial movement of lower molars and proclination of lower incisors were proven more significant than skeletal changes following their implication, compared to removable appliances [18, 32], which can negatively affect the long-term stability of the results. Many treatment modalities have been introduced to minimize the aforementioned side effects of these appliances including the application of increased-dimension arch wire, negative torque arch wire, and the use of lower incisor brackets with increased lingual crown torque [33, 34].



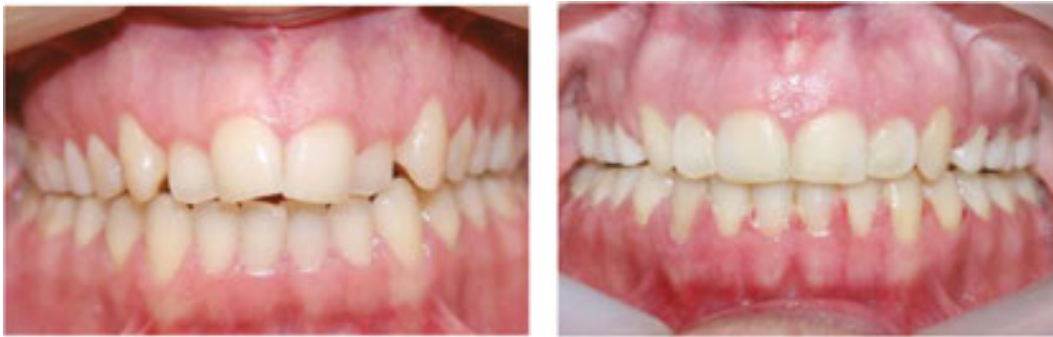**Figure 8.** Fixed functional appliance.

Recently, clinicians tried to control the dentoalveolar side effects of fixed functional appliances by means of bone anchorage such as miniscrews and miniplates [35–37]. The results of the studies investigating the efficacy of skeletal anchorage were controversial and need further investigation [1, 38–40].

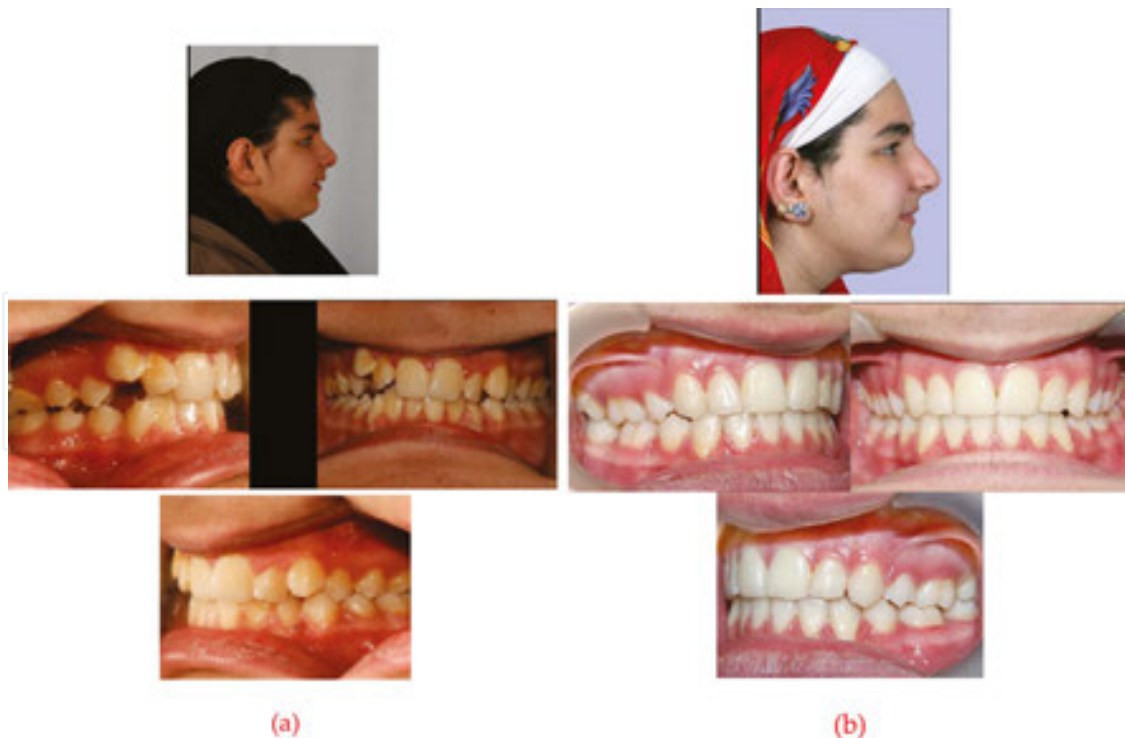

#### 4.2. Late management of class II malocclusion

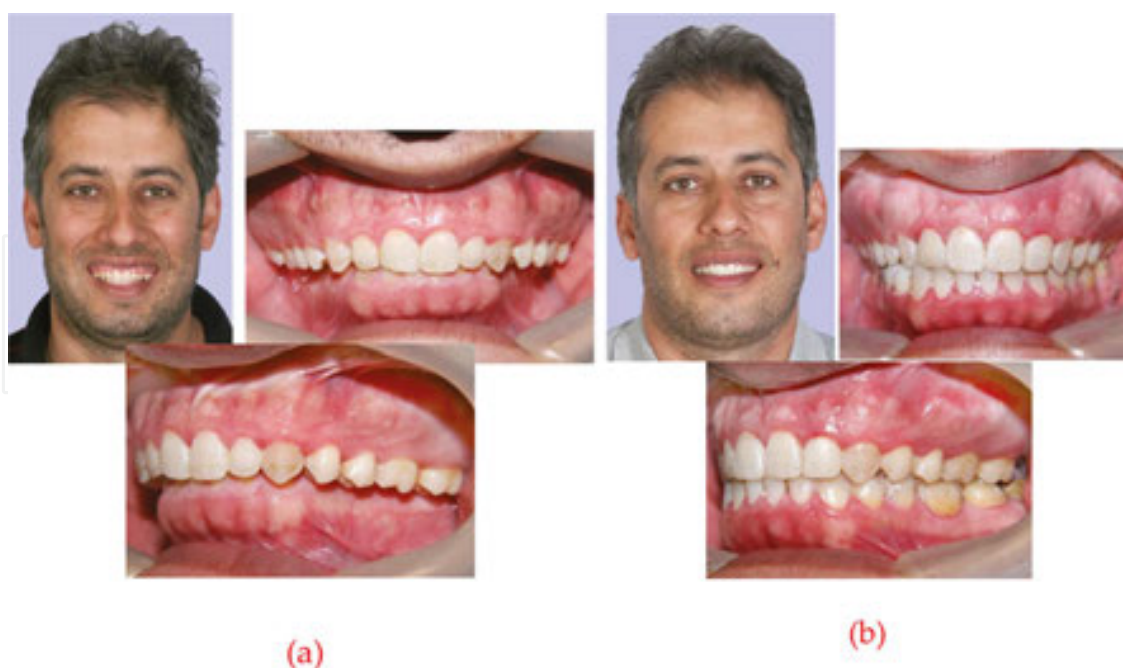
Currently, the number of adult patients seeking orthodontic treatment has gradually increased which focus mostly on camouflaging the malocclusion [41]. In contrast to growing patients, limited range of treatment modalities could be served for adult cases with class II skeletal and dental malocclusions. Depending on the severity of malocclusion, class II elastics, compensatory extraction (maxillary premolars and/or mandibular premolars) or even orthognathic surgical modalities may be used to alleviate the functional and esthetic problems associated with this type of malocclusion [42] (**Figures 9–11**).



**Figure 9.** Pre- and posttreatment intraoral photographs of a patient using cervical headgear non-extraction treatment.



**Figure 10.** (a) Profile and intraoral photographs of the patient at age 13 years. Treatment plan was to extract upper first premolars and lower second premolars. (b) Photographs of the patient after treatment at age 15 years.



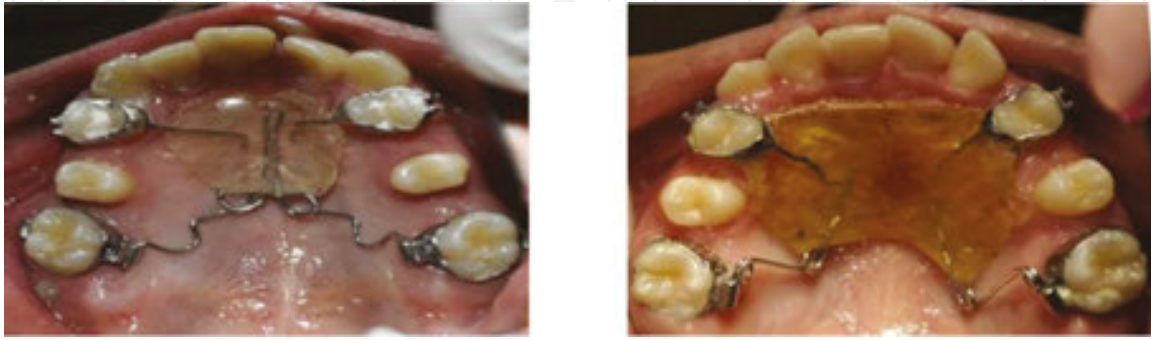**Figure 11.** (a) Frontal and intraoral photographs of the patient with bilateral buccal crossbite. (b) Profile and intraoral photographs of the patient at the end of treatment.

The patient presented in **Figure 11** is another case of Brodie syndrome but at the age of 34 years. Fixed orthodontic treatment in combination with upper removable constriction plate and Quad-helix appliance in the lower arch was performed for 12 months, and then the patient underwent Lefort I (two-piece constriction and impaction) and mandibular advancement surgery. Postsurgical orthodontic treatment was continued for 5 months. Prevention of such complex orthognathic bimaxillary surgery could have easily been achieved in growing patients (**Figure 7**).

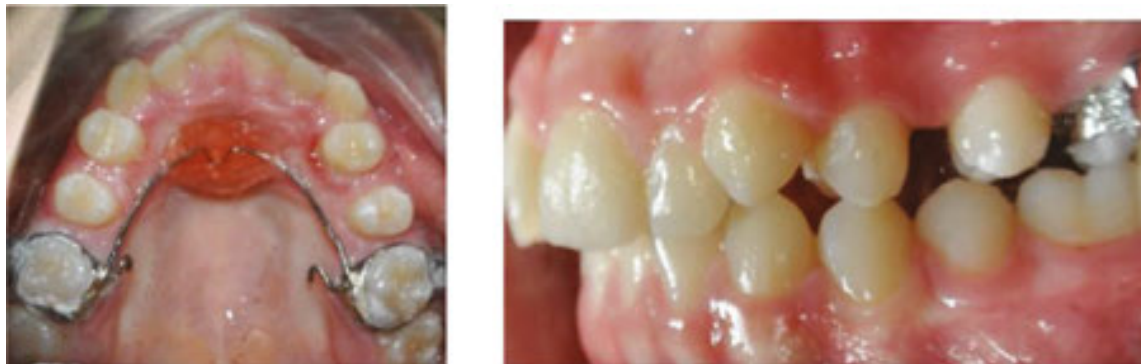Class II elastics with non-extraction treatment plan is a typical interarch approach for managing mild class II malocclusion [43]. The effects of class II elastics include mesial movements of the mandibular molars, tipping of the mandibular incisors, distal movements and tipping of the maxillary incisors, extrusion of the mandibular molars and maxillary incisors, and consequently clockwise rotation of the mandibular plane [44]. As success of treatments based on interarch elastics depends heavily on patient compliance for their effectiveness, poor cooperation can lead to poor treatment outcomes and increased treatment time [45].

In many non-extraction cases, the pendulum appliance is the most effective and commonly used device for distalizing maxillary molars. Its significant clinical advantages include minimal dependence on patient compliance, allows for correction of minor transverse and vertical molar positions by incorporation of u-loop in adjustment springs (which further enhance additional space achievement), and laboratory-friendly fabrication. Palatal coverage concomitant to pendulum appliance mediated to reduce the moderate anchorage loss effect causing upper incisor proclination [46]. The expected distal movement of the first molars appears to be more significant if it could be used before the eruption of the upper second

molars. To achieve proper distal movement of dentition after second molar eruption, clinicians may need to distalize the second molars first, followed by using a palatal arch bar (PAB) or Nance holding arch for retention. Then, the first molars are distalized. The extraction of erupted second molars can be done in case of great demand of distalizing first molars and the presence of erupting third molars, which may totally replace the second molar position [47] (Figures 12 and 13).



**Figure 12.** Distalizing maxillary molars by pendulum appliance, palatal coverage for anchorage control.



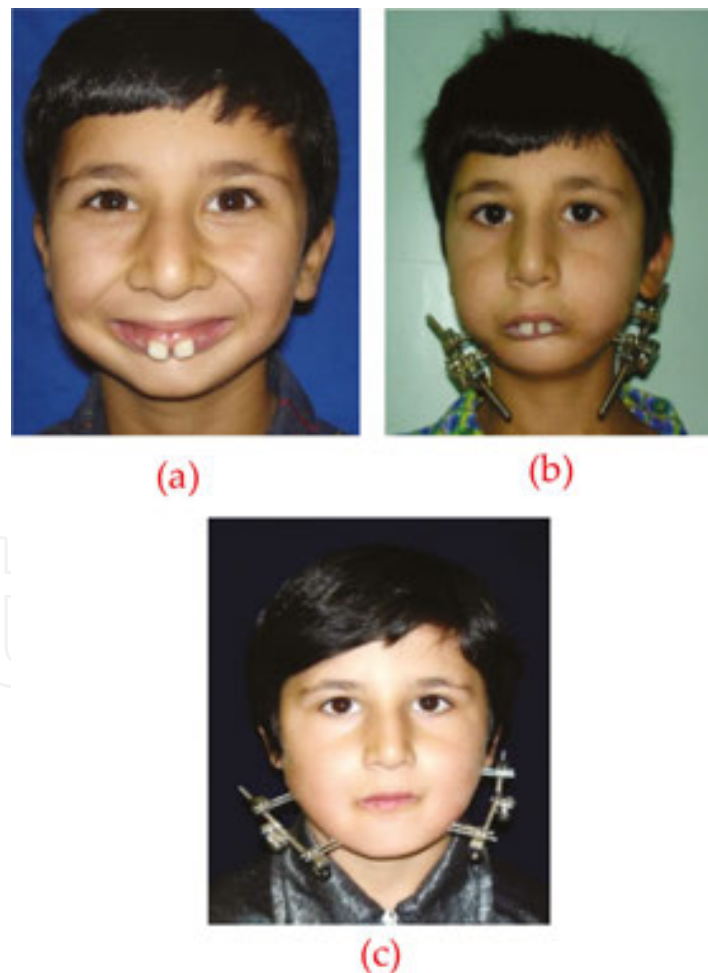
**Figure 13.** Nance holding arch for retention after achieving angle class I for the first permanent molars.

In a very recent study, both pendulum and distal screw seem to be equally effective in distalizing maxillary molars; however, greater distal molar tipping and premolar anchorage loss can be expected using the pendulum appliance [46].

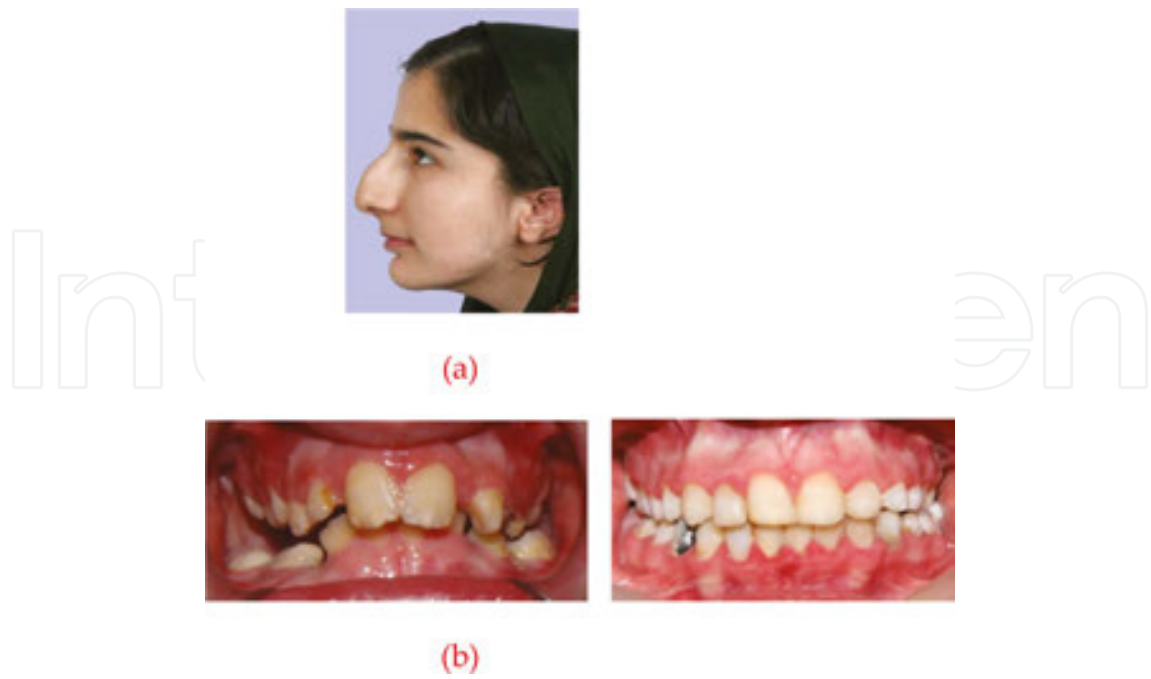
Extractions of only upper premolars are indicated for some special patients. According to a current soft-tissue paradigm, clinicians must pay attention to several factors such as soft-tissue thickness, amount of pretreatment crowding or cephalometric discrepancy, when deciding their extraction regimens for adult patients [48, 49]. As it is stated in a very recent systematic review, when class II division 1 malocclusion is treated with maxillary and mandibular premolar extractions, the nasolabial angle increases and the lips are retracted. However, there is less retraction of the lower lip in the only upper premolar extraction protocol [50]. A delicate adjustment and trade-off between the amount of anterior retraction and the mesial movement of the posterior segment following extraction regimens in each vulnerable adult class II patient

have to be considered to maintain the profile and the position of the upper lip at its most appropriate state. In order to reduce anchorage loss and space management obtained in extraction and non-extraction cases (distalizing appliances), temporary anchorage devices have been introduced in clinical orthodontic situations [51]. These devices serve considerable advantages including the ease of insertion and the removal in addition to the possibility of immediate loading [52, 53]. The only distinct factors predicting temporary anchorage device failures were soft-tissue inflammation surrounding a temporary anchorage device and early loading (within 3 weeks after insertion) [54].

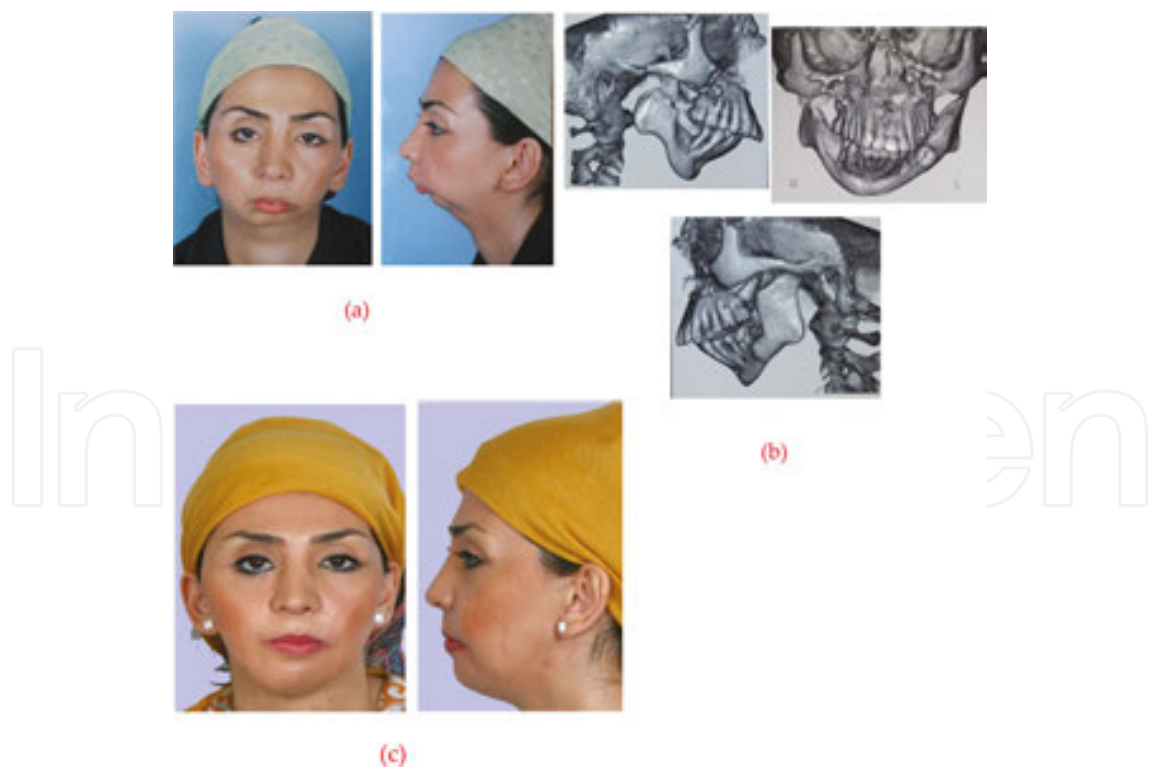
In rare and very severe cases, distraction osteogenesis (DO) with or without further orthognathic surgery can be done to promote the situation [55, 56]. This procedure can be applied for very severe class II malocclusions following mandibular deficiencies with wide age range such as infants with Pierre Robbins syndrome, growing children with severe class II malocclusion (Figures 14 and 15), or even adult patients with the history of bilateral condylar ankylosis (Figure 16).



**Figure 14.** (a) Frontal photograph of the patient before distraction. (b) Bilateral extraoral distractors in place. (c) Post-distraction photograph after 30-mm activation.

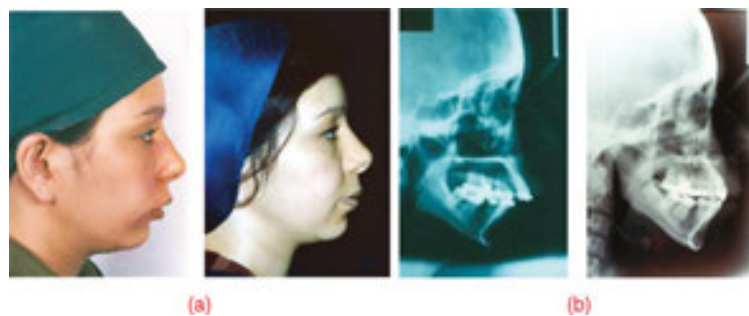


**Figure 15.** (a) Pre- and postdistraction photographs of patient's profile. (b) Intraoral photographs of the patient before and after bilateral DO.

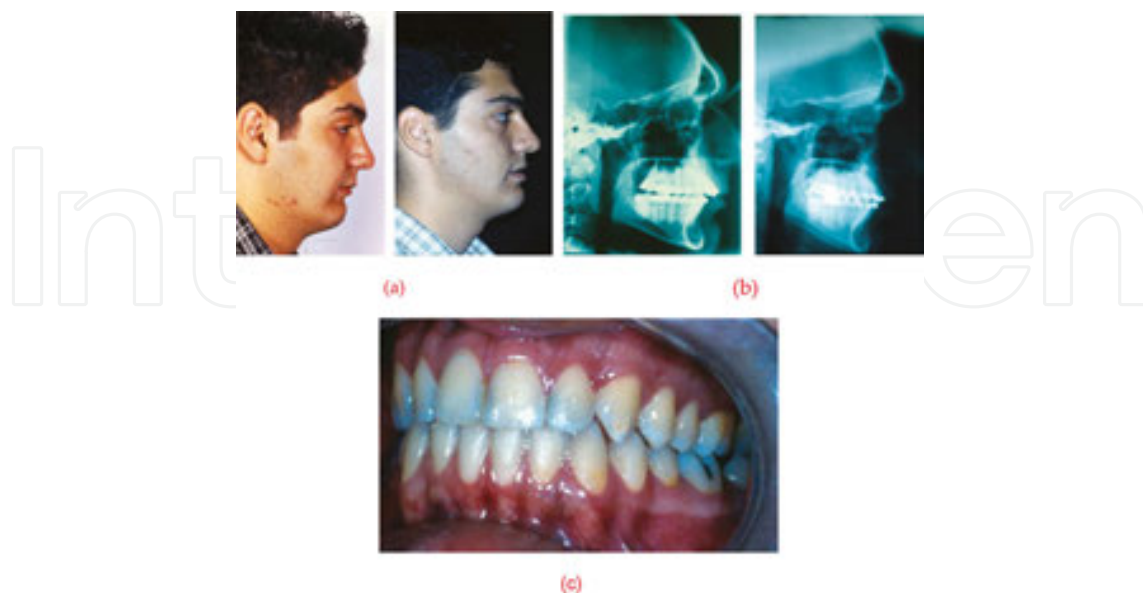


**Figure 16.** (a) A 29-year-old patient with bilateral condylar ankylosis. (b) CBCT scans of the patient. (c) At age 33 years after bilateral distraction osteogenesis, orthognathic surgery, and genioplasty.

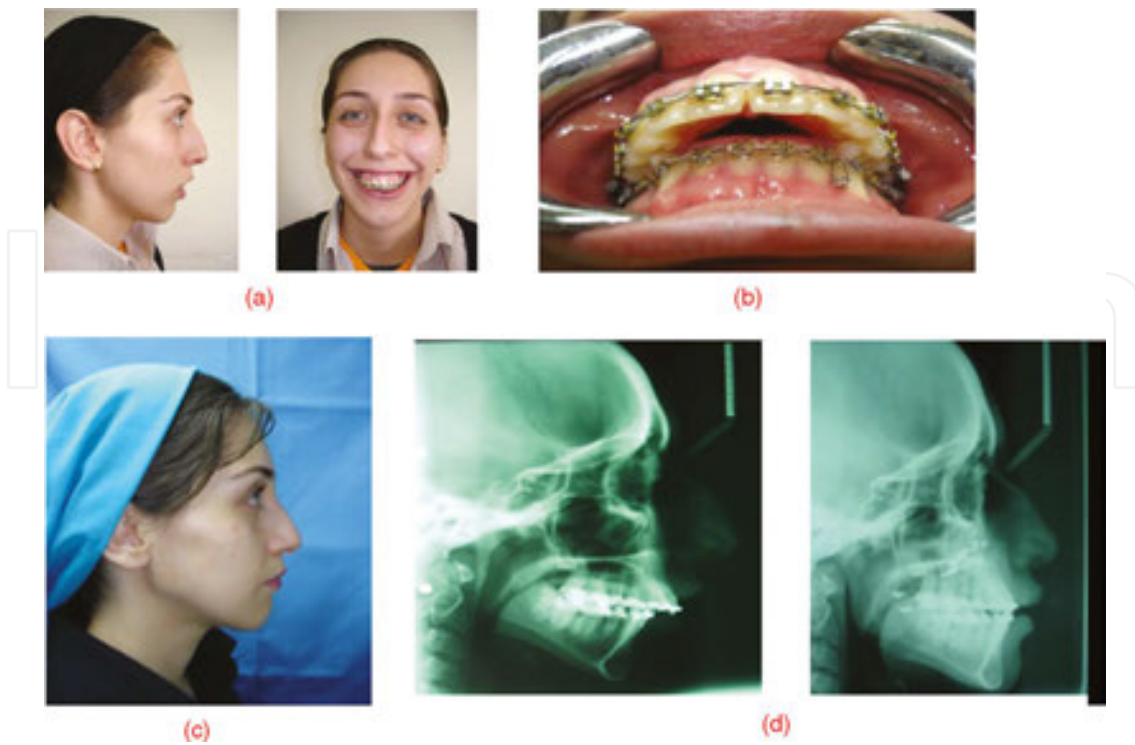
In severe class II malocclusion cases, orthognathic surgery (mandibular advancement with or without maxillary impaction) can be done to enhance soft-tissue esthetic [57, 58]. The proper presurgical orthodontic tooth movements and alignment of arches are essential to maximize the amount of discrepancy correction during surgery [59]. Many class II patients present with proper mandible size, which is located downward and backward secondary to vertical maxillary excess. Superior impaction of the maxilla with proper center of rotation allows the mandible to rotate upwards and forwards, which enhance the facial height and increase chin prominence [59]. Although orthognathic surgery could be an efficient treatment modality in severe class II patients, both the cost of the surgery and the fear of undergoing surgery normally prevent patients from choosing this treatment option [60]. Furthermore, most of the studies on surgery-first approach are done on class III malocclusion cases, which significantly reduced treatment time with equal dentoalveolar short- and long-term results [61] (Figures 17–20).



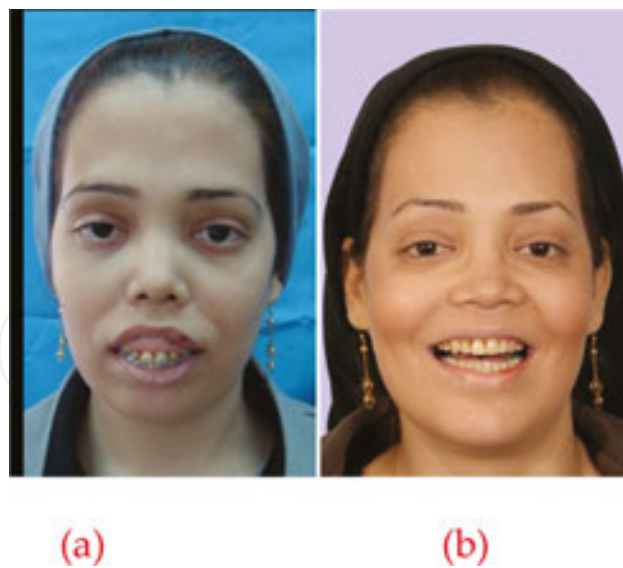**Figure 17.** (a) Pre- and postsurgical (maxillary narrowing and mandibular advancement) photographs of the patient. (b) Pre- and postsurgical lateral cephalograms.



**Figure 18.** (a) Pre- and postsurgical (mandibular advancement) photographs of the patient. (b) Pre- and postsurgical lateral cephalograms. (c) Posttreatment occlusion.



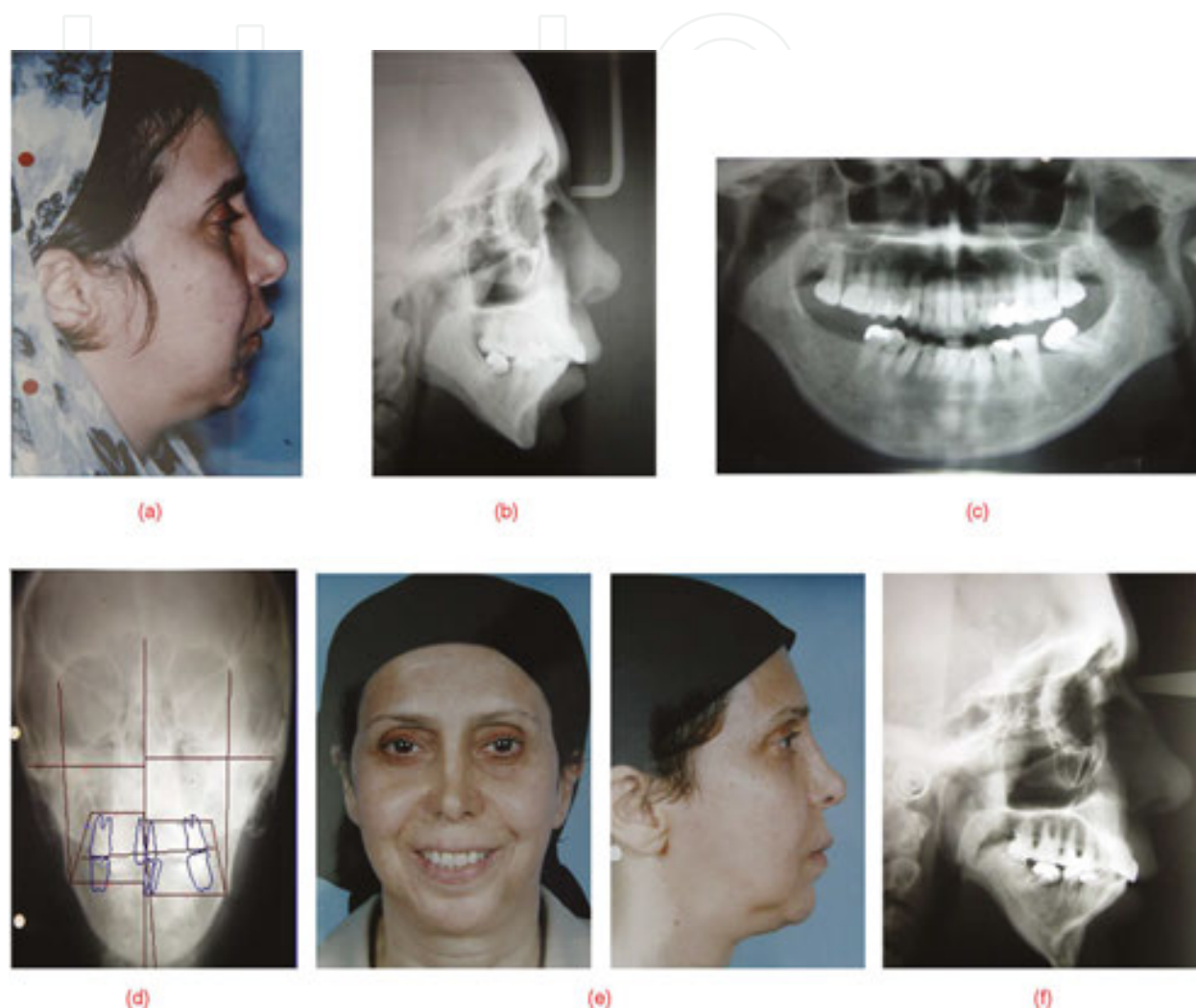**Figure 19.** (a) Profile and frontal photographs of the patient before surgery. (b) Intraoral view of the patient prior to surgery. (c) Profile photograph of the patient after maxillary impaction and mandibular advancement surgery. (d) Lateral cephalograms of the patient before and after surgery.



**Figure 20.** (a) Frontal photograph of an adult patient with major thalassemia, severe class II malocclusion 9-mm overjet, and 8-mm overbite before surgery. (b) Frontal photograph after 12-mm maxillary impaction and 8-mm setback plus genioplasty.

The clinical efficacy of orthognathic surgery on preexisting temporomandibular disorder (TMD) in class II patients is controversial [62, 63]. There are some reports of postsurgical

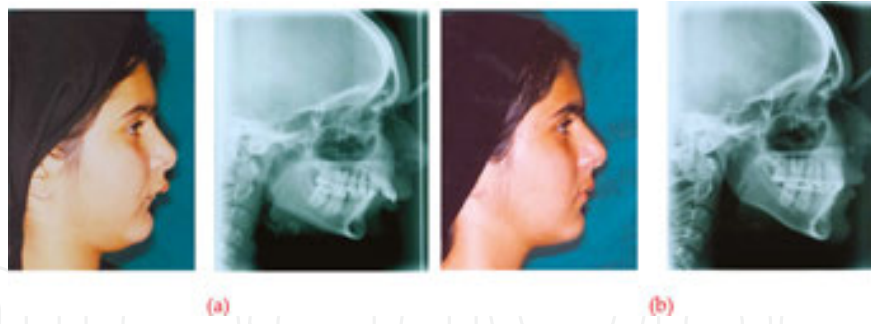condylar resorption in class II adult patients [64]. This could be the result of direct changes in the position of condyle, which may take place by inappropriate application of rigid fixation during surgery, worsening the TMD [65]. On the other hand, the improvement of clinical symptoms after orthognathic surgery can be explained by the better occlusal stability following surgery [66] (**Figure 21**).



**Figure 21.** (a) Profile photograph of a patient with class II malocclusion and TMD. (b) Lateral cephalogram of the patient before treatment. (c) Panoramic view of the patient before treatment. (d) PA cephalogram showing cant of the maxilla and deviation of the mandible. (e) Frontal and profile photographs of the patient after mandibular advancement (nonrigid fixation). (f) Lateral cephalogram of the patient after surgery.

Mandibular DO has been introduced to correct severe skeletal discrepancies in class II adult patients [67]. This technique was first developed by Ilizarov for the long bones in the 1950s [68] and was ultimately applied for the facial skeleton [55, 69, 70]. At first, clinicians thought this method might end up in less neurosensory disturbances and a more stable result compared to the routine bilateral sagittal split osteotomies. However, these findings were not verified later by more controlled studies as they reported no considerable differences regarding neurosensory disturbances and short- or long-term skeletal stability [71] (**Figure 22**).





**Figure 22.** (a) Predistraction profile photograph and lateral cephalogram of an adult patient. (b) Postdistraction profile photograph and lateral cephalogram. (Bilateral intraoral distractors were used.)

## 5. Relapse

Despite the correction of a class II malocclusion, a considerable number of class II patients experience some level of unpredictable relapses in following years after treatment [28]. Reported relapse rates following these treatments range from 20 to 52% [72]. The only available evidence on stability of treatment regards the Herbst appliance [72]. Several factors including gender, muscular functions and pretreatment habits, different treatment modalities, and posttreatment occlusion have been considered as potential factors affecting stability of the result. However, a very recent systematic review concluded that currently, there is very limited evidence to support the influence of predictive factors on relapse or stability of treatment outcomes [73].

Although mandibular advancement by bilateral sagittal split osteotomy seems to be a good treatment option for skeletal class II, it is less stable than setback in the short and long terms [74]. Miniplates demonstrated better long-term results than bicortical screws of titanium, stainless steel, or bioresorbable material. However, their short-term relapse rate was approximately comparable in class II malocclusion patients. This observed relapse depends on a wide range of patient-centered and surgeon-centered characteristics involving the skill and experience of the surgeon in the proper seating of the condyles, the exact amount of mandibular advancement, the tension of muscles and soft tissue, the mandibular plane angle, and the patient's age. Patients with low and high mandibular plane angles have increased vertical and horizontal relapses, respectively [74].

## 6. Diagram

### Class II Malocclusion Treatment

- Growing
  - Functional

- Removable
  - Activator
  - Bionator
  - Frankel
  - Twin-block
- Fixed
  - MARA
  - Cemented Twin-block
  - Herbst
- Headgear (skeletal effect)
  - Cervical
  - High pull
  - Combination
- Non-growing
  - Camouflage
    - Non-extraction regimen with class II elastics
    - Distal movement of upper teeth ± second molar extraction
      - Pendulum
      - Headgear (dental effect)
      - Miniscrew-assisted distalizations
    - Extraction of maxillary premolars
  - Orthognathic surgery
    - Mandibular advancement
    - Bimax surgery
  - DO
- Relapse

## Acknowledgements

The authors thank the staff of Orthodontic, Oral, and Maxillofacial Surgery departments for the general support of treatment procedures of the presented cases and specially wish to express their sincere gratitude to Prof. L Eslamian, Prof. M Nouri, and Prof. M Safavi.

## Author details

Azita Tehranchi<sup>1\*</sup>, Hossein Behnia<sup>2</sup>, Farnaz Younessian<sup>3</sup> and Sahar Hadadpour<sup>4</sup>

\*Address all correspondence to: azitatehranchi@yahoo.com

1 Preventive Dentistry Research Center, Research Institute of Dental Sciences, Department of Orthodontics, School of Dentistry, Shahid Beheshti University of Medical Sciences, Tehran, Iran

2 Dental Research Center, Research Institute of Dental Sciences, Department of Oral and Maxillofacial Surgery, School of Dentistry, Shahid Beheshti University of Medical Sciences, Tehran, Iran

3 Dentofacial Deformities Research Center, Research Institute of Dental Sciences, School of Dentistry, Shahid Beheshti University of Medical Sciences, Tehran, Iran

4 Department of Orthodontics, School of Dentistry, Shahid Beheshti University of Medical Sciences, Tehran, Iran

## References

- [1] Elkordy SA, Aboelnaga AA, Salah Fayed MM, AboulFotouh MH, Abouelezz AM. Can the use of skeletal anchors in conjunction with fixed functional appliances promote skeletal changes? A systematic review and meta-analysis. *European Journal of Orthodontics*. 2015.
- [2] Vasquez MJ, Baccetti T, Franchi L, McNamara JA, Jr. Dentofacial features of class II malocclusion associated with maxillary skeletal protrusion: a longitudinal study at the circumpubertal growth period. *American Journal of Orthodontics and Dentofacial Orthopedics: Official Publication of the American Association of Orthodontists, Its Constituent Societies, and the American Board of Orthodontics*. 2009;135(5):568.e1-7; discussion 9.

- [3] Kiekens RM, Maltha JC, Hof MAt, Kuijpers-Jagtman AM. Objective measures as indicators for facial esthetics in white adolescents. *The Angle Orthodontist*. 2006;76(4): 551–6.
- [4] Kalha AS. Early orthodontic treatment reduced incisal trauma in children with class II malocclusions. *Evidence-based Dentistry*. 2014;15(1):18–20.
- [5] Seehra J, Fleming PS, Newton T, DiBiase AT. Bullying in orthodontic patients and its relationship to malocclusion, self-esteem and oral health-related quality of life. *Journal of Orthodontics*. 2011;38(4):247–56; quiz 94.
- [6] Tehranchi A, Behnia H, Younessian F. Bipolar disorder: review of orthodontic and orthognathic surgical considerations. *Journal of Craniofacial Surgery*. 2015;26(4):1321–5.
- [7] Feres MF, Raza H, Alhadlaq A, El-Bialy T. Rapid maxillary expansion effects in class II malocclusion: a systematic review. *The Angle Orthodontist*. 2015;85(6):1070–9.
- [8] Perillo L, Padricelli G, Isola G, Femiano F, Chiadini P, Mataresei G. Class II malocclusion division 1: a new classification method by cephalometric analysis. *European Journal of Paediatric Dentistry*. 2012;13(3):192.
- [9] Shaughnessy T, Shire L. Etiology of class II malocclusions. *Pediatric Dentistry*. 1988;10(4):336–8.
- [10] Zaher AR, Kassem HE. Diagnostic considerations and conventional strategies for treatment of class II malocclusion. *Skeletal Anchorage in Orthodontic Treatment of Class II Malocclusion: Contemporary Applications of Orthodontic Implants, Miniscrew Implants and Mini Plates*. 2014:1.
- [11] Moyers RE, Riolo ML, Guire KE, Wainright RL, Bookstein FL. Differential diagnosis of class II malocclusions: Part 1. Facial types associated with class II malocclusions. *American Journal of Orthodontics*. 1980;78(5):477–94.
- [12] Baccetti T, Franchi L, McNamara JA, Tollaro I. Early dentofacial features of class II malocclusion: a longitudinal study from the deciduous through the mixed dentition. *American Journal of Orthodontics and Dentofacial Orthopedics*. 1997;111(5):502–9.
- [13] Pfeiffer J, Grob ty D. The class II malocclusion: differential diagnosis and clinical application of activators, extraoral traction, and fixed appliances. *American Journal of Orthodontics*. 1975;68(5):499–544.
- [14] Craig CE. The skeletal patterns characteristic of class I and class II, division I malocclusions in *Norma Lateralis 1*. *The Angle Orthodontist*. 1951;21(1):44–56.
- [15] Wheeler TT, McGorray SP, Dolce C, King GJ. The timing of class II treatment. *American Journal of Orthodontics and Dentofacial Orthopedics: Official Publication of the American Association of Orthodontists, Its Constituent Societies, and the American Board of Orthodontics*. 2006;129(4 Suppl):S66–70.

- [16] Dolce C, McGorray SP, Brazeau L, King GJ, Wheeler TT. Timing of class II treatment: skeletal changes comparing 1-phase and 2-phase treatment. *American Journal of Orthodontics and Dentofacial Orthopedics: Official Publication of the American Association of Orthodontists, Its Constituent Societies, and the American Board of Orthodontics*. 2007;132(4):481–9.
- [17] Burden D, Johnston C, Kennedy D, Harradine N, Stevenson M. A cephalometric study of class II malocclusions treated with mandibular surgery. *American Journal of Orthodontics and Dentofacial Orthopedics: Official Publication of the American Association of Orthodontists, Its Constituent Societies, and the American Board of Orthodontics*. 2007;131(1):7.e1–8.
- [18] Giuntini V, Vangelisti A, Masucci C, Defraia E, McNamara JA, Jr., Franchi L. Treatment effects produced by the twin-block appliance vs the forsus fatigue resistant device in growing class II patients. *The Angle Orthodontist*. 2015;85(5):784–9.
- [19] Thiruvengkatachari B, Harrison JE, Worthington HV, O'Brien KD. Orthodontic treatment for prominent upper front teeth (class II malocclusion) in children. *The Cochrane Database of Systematic Reviews*. 2013;11:Cd003452.
- [20] Firouz M, Zernik J, Nanda R. Dental and orthopedic effects of high-pull headgear in treatment of class II, division 1 malocclusion. *American Journal of Orthodontics and Dentofacial Orthopedics*. 1992;102(3):197–205.
- [21] Hubbard GW, Nanda RS, Currier GF. A cephalometric evaluation of nonextraction cervical headgear treatment in class II malocclusions. *The Angle Orthodontist*. 1994;64(5):359–70.
- [22] Behnia H, Motamedi MHK, Tehranchi A. Use of activator appliances in pediatric patients treated with costochondral grafts for temporomandibular joint ankylosis: analysis of 13 cases. *Journal of Oral and Maxillofacial Surgery*. 1997;55(12):1408–14.
- [23] Pacha MM, Fleming PS, Johal A. A comparison of the efficacy of fixed versus removable functional appliances in children with class II malocclusion: a systematic review. *European Journal of Orthodontics*. 2015.
- [24] Gong Y, Yu Q, Li PL, Wang HH, Wei B, Shen G. Efficacy evaluation of fixed Twin-block appliance and tooth extraction in skeletal class II malocclusion. *Shanghai Journal of Stomatology*. 2014;23(5):597–600.
- [25] Perinetti G, Primožic J, Franchi L, Contardo L. Treatment effects of removable functional appliances in pre-pubertal and pubertal class II patients: a systematic review and meta-analysis of controlled studies. *PloS One*. 2015;10(10):e0141198.
- [26] Marsico E, Gatto E, Burrascano M, Matarese G, Cordasco G. Effectiveness of orthodontic treatment with functional appliances on mandibular growth in the short term. *American Journal of Orthodontics and Dentofacial Orthopedics: Official Publication of*

the American Association of Orthodontists, Its Constituent Societies, and the American Board of Orthodontics. 2011;139(1):24–36.

- [27] Koretsi V, Zymperdikas VF, Papageorgiou SN, Papadopoulos MA. Treatment effects of removable functional appliances in patients with class II malocclusion: a systematic review and meta-analysis. *European Journal of Orthodontics*. 2015;37(4):418–34.
- [28] Flores-Mir C, Major PW. A systematic review of cephalometric facial soft tissue changes with the activator and bionator appliances in class II division 1 subjects. *European Journal of Orthodontics*. 2006;28(6):586–93.
- [29] Rondeau B. Herbst appliance fixed-functional appliance class II skeletal malocclusion. *Journal of General Orthodontics*. 2001;12(3):7–17.
- [30] Shen G, Hagg U, Darendeliler M. Skeletal effects of bite jumping therapy on the mandible – removable vs. fixed functional appliances. *Orthodontics and Craniofacial Research*. 2005;8(1):2–10.
- [31] Perinetti G, Primožic J, Furlani G, Franchi L, Contardo L. Treatment effects of fixed functional appliances alone or in combination with multibracket appliances: a systematic review and meta-analysis. *The Angle Orthodontist*. 2015;85(3):480–92.
- [32] Zymperdikas VF, Koretsi V, Papageorgiou SN, Papadopoulos MA. Treatment effects of fixed functional appliances in patients with class II malocclusion: a systematic review and meta-analysis. *European Journal of Orthodontics*. 2015.
- [33] Dowsing P, Murray A, Sandler J. Emergencies in orthodontics. Part 2: management of removable appliances, functional appliances and other adjuncts to orthodontic treatment. *Dental Update*. 2015;42(3):221–4, 7–8.
- [34] Gonner U, Ozkan V, Jahn E, Toll DE. Effect of the MARA appliance on the position of the lower anteriors in children, adolescents and adults with class II malocclusion. *Journal of Orofacial Orthopedics: Fortschritte der Kieferorthopädie : Organ/official journal Deutsche Gesellschaft für Kieferorthopädie*. 2007;68(5):397–412.
- [35] Markic G, Katsaros C, Pandis N, Eliades T. Temporary anchorage device usage: a survey among Swiss orthodontists. *Progress in Orthodontics*. 2014;15(1):29.
- [36] Jing Y, Han X, Guo Y, Li J, Bai D. Nonsurgical correction of a class III malocclusion in an adult by miniscrew-assisted mandibular dentition distalization. *American Journal of Orthodontics and Dentofacial Orthopedics*. 2013;143(6):877–87.
- [37] Leung MT-C, Lee TC-K, Rabie ABM, Wong RW-K. Use of miniscrews and miniplates in orthodontics. *Journal of Oral and Maxillofacial Surgery*. 2008;66(7):1461–6.
- [38] Cozzani M, Fontana M, Maino G, Maino G, Palpacelli L, Caprioglio A. Comparison between direct vs indirect anchorage in two miniscrew-supported distalizing devices. *The Angle Orthodontist*. 2015.

- [39] Munoz A, Maino G, Lemler J, Kornbluth D. Skeletal anchorage for class II correction in a growing patient. *Journal of Clinical Orthodontics*. 2009;43(5):325–31.
- [40] Pattabiraman V, Kumari S, Sood R. Mini-implant-supported sliding jig. *Orthodontics: The Art and Practice of Dentofacial Enhancement*. 2011;12(4):396–9.
- [41] Alvirde AE, Acevedo JA, González RMA. Treatment of a class II division 1 malocclusion in an adult patient. A case report. *Revista Mexicana de Ortodoncia*. 2015;3(1):39–46.
- [42] Cleall JF, Begole EA. Diagnosis and treatment of class II division 2 malocclusion. *The Angle Orthodontist*. 1982;52(1):38–60.
- [43] Jones G, Buschang PH, Kim KB, Oliver DR. Class II non-extraction patients treated with the forsus fatigue resistant device versus intermaxillary elastics. *The Angle Orthodontist*. 2008;78(2):332–8.
- [44] Pancherz H, Malmgren O, Hägg U, Ömblus J, Hansen K. Class II correction in Herbst and Bass therapy. *The European Journal of Orthodontics*. 1989;11(1):17–30.
- [45] Skidmore KJ, Brook KJ, Thomson WM, Harding WJ. Factors influencing treatment time in orthodontic patients. *American Journal of Orthodontics and Dentofacial Orthopedics*. 2006;129(2):230–8.
- [46] Caprioglio A, Cafagna A, Fontana M, Cozzani M. Comparative evaluation of molar distalization therapy using pendulum and distal screw appliances. *The Korean Journal of Orthodontics*. 2015;45(4):171–9.
- [47] Hilgers J. The pendulum appliance for class II non-compliance therapy. *Journal of Clinical Orthodontics*. 1992;26(11):706–14.
- [48] Kachiwala VA, Kalha AS, Machado G. Soft tissue changes associated with first premolar extractions in adult females. *Australian Orthodontic Journal*. 2009;25(1):24–9.
- [49] Erdinc AE, Nanda RS, Dandajena TC. Profile changes of patients treated with and without premolar extractions. *American Journal of Orthodontics and Dentofacial Orthopedics: Official Publication of the American Association of Orthodontists, Its Constituent Societies, and the American Board of Orthodontics*. 2007;132(3):324–31.
- [50] Janson G, Mendes LM, Junqueira CHZ, Garib DG. Soft-tissue changes in class II malocclusion patients treated with extractions: a systematic review. *The European Journal of Orthodontics*. 2015:cjv083.
- [51] Păun A, Stanciu R, Pătrașcu I. Skeletal anchorage in orthodontic treatment of a class II malocclusion. *Romanian Journal of Oral Rehabilitation*. 2015;7(1).
- [52] King KS, Lam EW, Faulkner MG, Heo G, Major PW. Vertical bone volume in the paramedian palate of adolescents: a computed tomography study. *American Journal of Orthodontics and Dentofacial Orthopedics: Official Publication of the American*

Association of Orthodontists, Its Constituent Societies, and the American Board of Orthodontics. 2007;132(6):783–8.

- [53] Tehranchi A, Behnia H, Younessian F, Ghochani MS. Rapid, conservative, multidisciplinary miniscrew-assisted approach for treatment of mandibular fractures following plane crash. *Dental Research Journal*. 2013;10(5):678.
- [54] Chen YJ, Chang HH, Lin HY, Lai EHH, Hung HC, Yao CCJ. Stability of miniplates and miniscrews used for orthodontic anchorage: experience with 492 temporary anchorage devices. *Clinical Oral Implants Research*. 2008;19(11):1188–96.
- [55] Behnia H, Tehranchi A, Morad G. *Distraction osteogenesis*. 2013.
- [56] Tehranchi A, Behnia H, Soheilifar S. Evaluation of skeletal, dental, soft tissue and airway cephalometric changes in severe class II malocclusions treated by bilateral mandibular distraction osteogenesis. *Iranian Journal of Orthodontics*. 2012;7(3).
- [57] Proffit WR, Phillips C, Tulloch JF, Medland PH. Surgical versus orthodontic correction of skeletal class II malocclusion in adolescents: effects and indications. *The International Journal of Adult Orthodontics and Orthognathic Surgery*. 1992;7(4):209–20.
- [58] Tehranchi A, Behnia H, Ghochani M, Younessian F. Oro-facial characteristics and the surgical correction of patients affected by beta-thalassaemia: a review of the literature and report of a case. *Australian Orthodontic Journal*. 2015;31(1):98–106.
- [59] Balachander R, Karthik K, Katta A, Rajasigamani K. Surgical correction of class II skeletal malocclusion in an adult patient. *Journal of Orofacial Sciences*. 2014;6(1):58.
- [60] Shetty A, Patil A, Ganeshkar S. Comparison of skeletal, dental and soft tissue changes in young adults with class II malocclusion, treated either by camouflage, fixed functional appliance or orthognathic surgery – a prospective study on Indian subjects. *Open Journal of Stomatology*. 2012;2(04):373.
- [61] Huang CS, Hsu S, Chen Y-R. Systematic review of the surgery-first approach in orthognathic surgery. *Biomedical Journal*. 2014;37(4):184.
- [62] Magnusson T, Ahlborg G, Svartz K. Function of the masticatory system in 20 patients with mandibular hypo- or hyperplasia after correction by a sagittal split osteotomy. *International Journal of Oral Maxillofacial Surgery*. 1990;19(5):289–93.
- [63] Sanders B, Kaminishi R, Buoncristiani R, Davis C. Arthroscopic surgery for treatment of temporomandibular joint hypomobility after mandibular sagittal osteotomy. *Oral Surgery, Oral Medicine, and Oral Pathology*. 1990;69(5):539–41.
- [64] Catherine Z, Breton P, Bouletreau P. Condylar resorption after orthognathic surgery: a systematic review. *Revue de stomatologie, de chirurgie maxillo-faciale et de chirurgie orale*. 2015.
- [65] Behnia H, Tehranchi A, Younessian F. *Comprehensive management of temporomandibular joint ankylosis—state of the art*. 2015.



- [66] Jang J-H, Choi S-K, Park S-H, Kim J-W, Kim S-J, Kim M-R. Clinical evaluation of temporomandibular joint disorder after orthognathic surgery in skeletal class II malocclusion patients. *Journal of the Korean Association of Oral and Maxillofacial Surgeons*. 2012;38(3):139–44.
- [67] Azumi Y, Sugawara J, Takahashi I, Mitani H, Nagasaka H, Kawamura H. Positional and morphologic changes of the mandibular condyle after mandibular distraction osteogenesis in skeletal class II patients. *World Journal of Orthodontics*. 2003;5(1):32–9.
- [68] Ilizarov GA. The principles of the Ilizarov method. *Bulletin of the Hospital for Joint Diseases Orthopaedic Institute*. 1987;48(1):1–11.
- [69] Tehranchi A, Behnia H. Treatment of mandibular asymmetry by distraction osteogenesis and orthodontics: a report of four cases. *The Angle Orthodontist*. 2000;70(2):165–74.
- [70] Tehranchi A, Behnia H. Facial symmetry after distraction osteogenesis and orthodontic therapy. *American Journal of Orthodontics and Dentofacial Orthopedics*. 2001;120(2):149–53.
- [71] Vos M, Baas E, de Lange J, Bierenbroodspot F. Stability of mandibular advancement procedures: Bilateral sagittal split osteotomy versus distraction osteogenesis. *International Journal of Oral and Maxillofacial Surgery*. 2009;38(1):7–12.
- [72] Bock NC, von Bremen J, Ruf S. Stability of class II fixed functional appliance therapy – a systematic review and meta-analysis. *The European Journal of Orthodontics*. 2015:cjv009.
- [73] Wins SM, Antonarakis GS, Kiliaridis S. Predictive factors of sagittal stability after treatment of class II malocclusions: a systematic review. *The Angle Orthodontist*. 2015.
- [74] Joss CU, Vassalli IM. Stability after bilateral sagittal split osteotomy advancement surgery with rigid internal fixation: a systematic review. *Journal of Oral and Maxillofacial Surgery*. 2009;67(2):301–13.