

We are IntechOpen, the world's leading publisher of Open Access books Built by scientists, for scientists

4,800

Open access books available

122,000

International authors and editors

135M

Downloads

Our authors are among the

154

Countries delivered to

TOP 1%

most cited scientists

12.2%

Contributors from top 500 universities



WEB OF SCIENCE™

Selection of our books indexed in the Book Citation Index
in Web of Science™ Core Collection (BKCI)

Interested in publishing with us?
Contact book.department@intechopen.com

Numbers displayed above are based on latest data collected.
For more information visit www.intechopen.com



Cardiac Catheterisation and Intervention on ECMO

Christopher Duke, Chris J. Harvey,
Vikram Kudumula, Elved B. Roberts and
Suhair O. Shebani

Additional information is available at the end of the chapter

<http://dx.doi.org/10.5772/63978>

Abstract

Cardiac catheterisation is an essential tool to evaluate patients who require ECMO support for severe haemodynamic impairment. In the first part of this chapter, we describe the equipment, teamwork, expertise, techniques and precautions that are necessary to carry out safe and effective cardiac catheterisation on ECMO. We have moved on from an early pioneering era to a stage where the multidisciplinary team approach has been worked out in detail, using operational procedures that deal with the technical challenges and minimise the risks of ECMO catheterisation and intervention. In the second part of the chapter, we explain in detail how cardiac catheterisation and intervention on ECMO contribute to the management of (1) post-operative congenital heart disease patients, (2) cardiac patients who suffer sudden haemodynamic deterioration, (3) patients with low cardiac output who require left heart decompression because of extracorporeal support, (4) patients with haemodynamically unstable arrhythmias and (5) haemodynamically unstable patients who require percutaneous coronary intervention. We also provide state-of-the-art information on the elective use of ECMO to support congenital and structural catheter interventions. Acute survival and long-term outcome are now related to the underlying conditions rather than complications of the catheterisation procedure itself.

Keywords: ECMO, cardiac catheterisation, catheter intervention, congenital heart disease, myocarditis, cardiomyopathy, balloon septostomy, atrial septal stent, arrhythmia, radiofrequency ablation, percutaneous coronary intervention, structural intervention

1. Introduction

Since cardiac catheterisation and transcatheter intervention in patients on ECMO was pioneered in the late 1980s, interventional cardiologists and ECMO teams have learned to work together to provide rapid accurate diagnosis and safe interventional solutions for patients with the most challenging anatomical problems and the most fragile physiologies. In the current era, experienced teams provide excellent results. The aim of this chapter was to describe state-of-the-art practice in this area.

Catheterisation is most commonly required in the setting of extracorporeal support in the following scenarios:

- a. Following surgery for congenital heart disease
- b. When acute haemodynamic collapse occurs in a cardiac patient unrelated to surgery
- c. To decompress the left heart in patients with poor left ventricular function
- d. Patients with haemodynamically unstable refractory arrhythmias
- e. Percutaneous coronary intervention in patients with severe haemodynamic instability
- f. Elective ECMO support for high-risk congenital and structural transcatheter interventional procedures

The first part of this chapter will address the practical issues related to carrying out cardiac catheterisation in patients on ECMO. The second part of the chapter will focus on up-to-date knowledge and practice in each of the clinical scenarios listed above.

2. Practical tips for ECMO catheterisation

2.1. Staffing

To maximise the safety of ECMO support, the entire team should be familiar with all local ECMO protocols and experienced in moving patients on ECMO. When out of the intensive care unit, the patient is accompanied by the bedside ECMO specialist, ECMO coordinator and a perfusionist. Surgical expertise is available in the event of a cannulation issue, and an anaesthetist or intensive care specialist always accompanies the patient. The circuit is maintained as if it were in the intensive care unit with the same routine circuit checks and monitoring of anticoagulation. The ECMO specialist needs to ensure that there is an adequate supply of syringes and ACT cartridges close by and that the ECMO emergency box containing spare connectors and pigtails accompanies the patient at all times. Each member of the team is tasked with surveillance of a different part of the circuit or patient during the transport.

2.2. Transport between intensive care and the catheter laboratory

The ECMO system should be mounted on a mobile cart. As most modern ECMO systems are capable of operating on battery power for extended periods, the patient and circuit can be

transferred in a slow and steady manner to the catheter suite. The patient must be fully monitored and sufficient gas supply must be carried to provide oxygen both to the ECMO circuit, as sweep gas, and to the ventilator. All drug infusions should be continued. The ECMO circuit often represents the safest and most reliable access point as pre-existing central lines may need to be rewired and upsized to permit the procedure. It is, however, recommended that at least one well-functioning peripheral cannula is available in case there is a circuit-related complication. As with most critical care transfers, the ECMO patient should be appropriately sedated or anaesthetised prior to leaving the unit. All studies that have assessed the process of patient transport have described excellent outcomes with no cannula displacement, morbidity or mortality [1–3].

2.3. Cannulation

The exact method of ECMO cannulation is largely dictated by patient factors, mainly the weight and age of the patient, but consideration needs to be given to any anatomical variation or loss of vessels either secondary to prolonged ITU stay, surgery or previous catheter interventions. In children below 10 kg in weight, the carotid artery and the jugular vein are the vessels of choice. For most patients, a right-sided cut-down centred on the medial border of the sternocleidomastoid muscle approximately 1.5–2 cm above the clavicle provides excellent access to both of these vessels. Cannulas between 8 and 14 Fr may be inserted depending on the size of the patient and vessels and the amount of support required. In children over 10 kg, cannulation of a femoral vein and artery are preferred. This approach avoids damage to the carotid artery and alterations to flow of blood to the brain. It must be remembered that the femoral artery is an end vessel and the distal perfusion of the leg needs careful consideration in order to prevent limb ischaemia. An additional small cannula either placed antegradely into the superficial femoral artery or retrogradely into the posterior tibial artery can be used satisfactorily to prevent critical limb ischaemia. Once inserted, the cannulas should be firmly secured with at least two sutures.

Occasionally, a patient who is cannulated centrally through an open chest may need treatment in the catheter laboratory. This is almost exclusively in the post-operative patient and although possible carries a significantly higher risk than the patient cannulated peripherally. Centrally placed cannulas are usually shorter and therefore much more prone to being dislodged on patient movement or during the procedure. For such patients, a surgeon capable of reinserting the cannula is essential and additional caution must be exercised by the entire team.

2.4. In the catheter laboratory

A briefing is essential so that the cardiologist understands the ECMO set-up but also so that the ECMO team may fully appreciate what the diagnostic or interventional procedure involves. It is relatively straight forward to position the ECMO circuit to the side of the patient if the catheter procedure can be achieved utilising simple antero-posterior imaging. However, for more complex procedures, requiring imaging through a wide range of planes, we have found it preferential to position both the ECMO pump and the oxygenator on the catheter table, away from the traditional ECMO cart (**Figure 1**). By securing the circuit on the table, the

cardiologist can move the patient and position the C-arm without fear of inadvertent decannulation or damage to the circuit components. It is essential to ensure that the circuit is connected to a main's power supply and that the ECMO heater unit is running to prevent unwanted cooling of the patient throughout the procedure. When possible, oxygen should be connected to the wall supply.

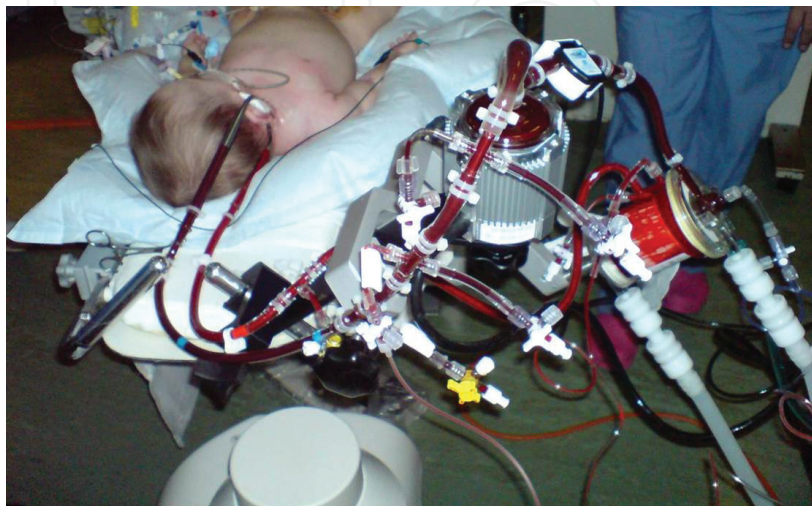


Figure 1. The ECMO circuit secured to the catheter table.

2.5. Vascular access

As the patient is heparinised, it is preferable to avoid new punctures. Existing central venous lines or arterial pressure monitoring lines are therefore exchanged over a wire for a sheath whenever possible. However, new punctures are required in the majority of procedures and complications are surprisingly rare [2, 4, 5]. Only one study described complications, in 13% patients, including venous thrombosis, lower extremity oedema without thrombosis, transient loss of peripheral pulses and lower extremity compartment syndrome requiring fasciotomy [3]. Patients often have a history of previous operations, interventions and prolonged intensive care. It is therefore important to check in advance whether any vessels are known to be occluded and to confirm vessel patency with vascular ultrasound before attempting new access. It is preferable to use vascular ultrasound during puncture attempts to minimise complications [2].

Draping the patient and maintaining sterility can be challenging, as old lines are being exchanged for sterile sheaths, requiring extra care to lift the line that is being removed away from the patient without contaminating the sterile field. Changing gloves after removing the old line and a second pair of hands to assist the exchange are advisable.

To avoid the morbidity of additional vascular access, angiography can be carried out by injecting contrast directly via the ECMO cannula, using a three-way adaptor in the connector [2]. This manoeuvre requires a coordinated sequence of transient flow cessation, contrast injection, saline flush, image acquisition and recommencement of flow [2]. With this technique,

it is possible to get good images of the aortic root and coronary arteries, particularly if the aorta distal to the cannula is transiently occluded in patients with an open chest [2]. It is also possible to cut a Y-connector into the arterial limb of the ECMO circuit, through which catheters can be inserted [6–9]. The blind end of the Y-connector is closed with a haemostatic valve (Check-Flo Performer accessory adapter, Cook Medical, USA). Although this allows direct access to the heart, without the need for further punctures, catheters are more difficult to manipulate and torque takes longer to transmit because of friction inside the cannula and Y-connector. This loss of feel may hamper the procedure. For this reason, we reserve this approach for simple diagnostic procedures and for cases where vessels are absent or thrombosed or attempts to gain alternative access have failed. When the catheter is completed, the Y-connector must be removed. One study describes similarly placing a Y-connector in the venous limb of the ECMO circuit to obviate the need for venous puncture [2]. We remain concerned that this approach has the potential to rapidly entrain air into the venous circulation because of the negative pressure generated by the centrifugal pump.

2.6. Angiography

The ECMO circuit will normally be positioned to the right of the patient's head with neck cannulation. This usually makes it impossible to bring in the lateral camera C-arm, so most ECMO catheters are carried out with single plane fluoroscopy and angiography. Before starting the case, the image intensifier should be moved through a full range of right and left

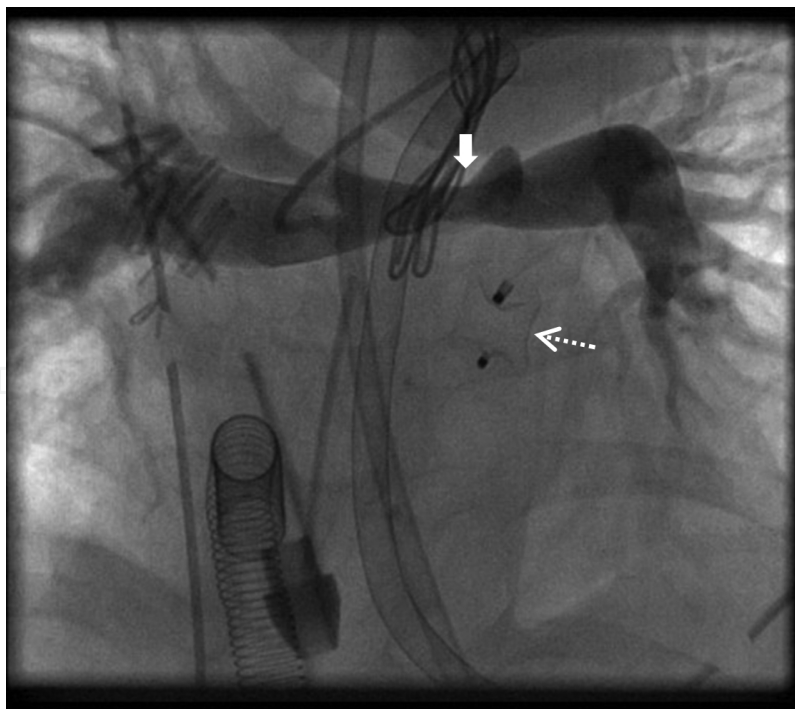


Figure 2. Clutter in the X-ray field. Legend—The image includes ECMO cannulas, chest drains, surgical clips, swabs, a nasogastric tube, a cardiac catheter and a vascular occlusion device (dashed arrow). There is a significant stenosis at the pulmonary artery bifurcation (solid arrow) following cardiac surgery (superior cavopulmonary shunt).

anterior oblique angles, to check whether any equipment is impeding the movement of the C-arm. The ECMO circuit and ancillary equipment should be positioned to maximise the range of camera angles. Test screening is carried out to check that equipment does not encroach on the field of view in the camera angles that are likely to be used during the case. ECG leads and electrodes that are not radiolucent may need to be removed, saturation probes repositioned, chest drain tubing moved and bundles of epicardial pacing wires taped over the abdomen rather than the chest. If it is anticipated that angles approaching the lateral plane may be required, the arms should be lifted up and supported either side of the head, taking care not to displace the ECMO cannulas. Sometimes items of equipment that cannot be moved, for example ECMO cannulas, chest drains, pacing leads, swabs with radio-opaque markers, chest spreaders and clamps, clutter the X-ray field and overlies the area of interest (**Figure 2**). Unusual camera angles may therefore be needed to properly visualise the area without hardware encroaching on the image. For angiography, 1 ml/kg contrast, or even lower volumes for low flow states, gives good image quality [2].

2.7. Catheter technique

Catheter manipulation is not usually any more difficult because of the extracorporeal support, though appreciation of catheter position is sometimes limited by single plane fluoroscopy. ECMO flow may need to be diminished or temporarily discontinued to document cardiac haemodynamics. ECMO can actually facilitate intervention, as it offers a stable haemodynamic platform to carry out interventions that might otherwise cause significant haemodynamic derangement. Furthermore, if the chest is open and a surgeon is close at hand, it is justifiable to accept a greater risk of vessel rupture during balloon angioplasty or stenting as the area is rapidly accessible for surgical repair. Complications during catheterisation are rare. One study reported myocardial perforation in 2 patients (3%), dealt with by inserting a pericardial drain without the need for surgery [5]. Another study reported retroperitoneal haematoma secondary to arterial trauma when removing an embolised coil [4]. Even in the earliest study, transeptal puncture was carried out in a fully anticoagulated state without complication [10]. The safety of transeptal puncture can now be enhanced by intraprocedural transoesophageal echocardiography, even in small children, using a micro-TOE probe.

2.8. Return to the intensive care unit

On completing the catheter, the circuit is resecured to the ECMO trolley if needed and the patient is returned to the intensive care unit. If additional vascular access was utilised for the procedure, this should be left in place until the patient returns to ICU. In this way, the clotting status of the patient can be assessed prior to line removal. Although some have recommended that sheaths should be left in place until the patient is weaned from ECMO, most sheaths can be safely removed and bleeding controlled by manual compression [2, 4]. The ongoing need for anticoagulation and inherent platelet dysfunction mean that pressure needs to be applied for longer than would be expected for non-ECMO patients. Alternatively, venous sheaths can be exchanged for a central line of equal outer diameter, venous puncture sites can be closed with a Z-suture or the vessels can be repaired surgically.

3. Clinical scenarios where catheterisation on ECMO is required

3.1. ECMO catheterisation following surgery for congenital heart disease

3.1.1. *Why is ECMO required following surgery?*

ECMO support may be required following surgery for congenital heart disease in the following circumstances: (a) failure to separate from cardiopulmonary bypass; (b) ventricular dysfunction with low cardiac output in the immediate post-operative period; (c) unexpected cardiac arrest requiring extracorporeal CPR; (d) lung disease; (e) pulmonary hypertension; and (f) refractory arrhythmias [11]. In such cases, it is important to quickly assess the integrity of the surgical repair and establish whether there are any residual anatomical problems that require correction, as studies have shown between 6% and 28% of post-operative patients requiring ECMO have residual lesions [11–14].

3.1.2. *Why is cardiac catheterisation required following surgery?*

In the majority of cases, echocardiography does not provide complete information because ventilation, dressings, pacing wires, chest drains, air in the anterior mediastinum and an open chest restrict the available echocardiographic windows. In one study, where ECMO was established using central cannulation with the chest open, only 17% of residual lesions were identified by echocardiography [11]. Other studies confirm that echocardiography has clear limitations in this context, with residual problems detected in at best 41% and at worst 19% of patients [1, 5]. Echocardiography is particularly poor at identifying problems with branch pulmonary arteries and systemic to pulmonary artery shunts. In contrast, in one of the largest studies on post-operative ECMO, cardiac catheterisation identified 78% of residual lesions. About 91% of cardiac catheterisation procedures yielded unexpected diagnostic information of clinical importance [11]. Both surgeon and cardiologist therefore need to remain open to the fact that something may have been missed. In 70–83% of cases, management is altered by the results of cardiac catheterisation [1, 2, 4, 5, 11]. The findings may result in redo surgery, cardiac intervention or elective withdrawal of ECMO in patients with severe neurological impairment or lack of myocardial recovery. Cardiac catheterisation is therefore mandated whenever there is any doubt about the cause of the patient's poor haemodynamic status.

3.1.3. *Survival after catheterisation on ECMO*

Table 1 shows how outcomes for patients who require cardiac catheterisation on ECMO have improved over time. The studies listed describe a mixed group of paediatric cardiac ECMO patients, not just patients who required ECMO in the post-operative period. Nevertheless, the trend towards improved survival is impressive.

Outcome	1990–1995 Desjardins et al. (1999) [4]	1984–2001 Booth et al. (2002) [5]	2009–2012 Panda et al. (2014) [2]	2004–2013 Callahan et al. (2015) [3]
Weaned from ECMO	53%	72%	82%	86%
Discharged from hospital	29%	48%	68%	72%
Survival on follow-up	14%	43%	64%	69%

Table 1. Outcomes in patients who have cardiac catheterisation on ECMO.

In a study that included only children on ECMO following paediatric cardiac surgery, children with residual lesions had 87% survival to decannulation when lesions were detected within 3 days of the operation, compared with 36% survival when the lesions were detected later. Most lesions were detected by cardiac catheterisation. Survival to discharge was 58% and 18%, respectively, in the two groups [11]. These findings reinforce the 2011 recommendations of the American Heart Association that cardiac catheterisation with potential for intervention is indicated early in the post-operative period in any patient who requires mechanical cardiopulmonary support without a clear cause [15].

3.1.4. *The timing of cardiac catheterisation*

Although there is a natural tendency to attribute the need for extracorporeal support to myocardial stun following cardiopulmonary bypass and cross-clamping, if patients fail to wean from ECMO within 3 days, cardiac catheterisation is strongly advised. Catheterisation should be carried out earlier if haemodynamic measurements made on PICU or echocardiography suggest a residual problem. In cases where the surgeon suspects a residual problem or coronary artery issues could result in permanent myocardial damage, it is preferable to proceed straight from theatre to the cardiac catheterisation laboratory. In our centre, it is routine to carry out a detailed assessment of every surgical repair in theatre either by TOE or by epicardial echocardiography. Intracardiac problems are therefore usually identified early and repaired immediately. In view of this, when a patient fails to wean from ECMO on PICU, it is likely that any residual lesion will be beyond the reach of echocardiographic imaging. Branch pulmonary artery problems, aortic problems and distortion, stenosis and thrombosis of cavopulmonary and aortopulmonary shunts remain a blind spot for the echocardiographer.

3.1.5. *Types of catheter procedures required in the post-operative period*

Indications for catheterisation include the evaluation of coronary arteries (**Figure 3**), pulmonary arteries (**Figure 4**), pulmonary venous obstruction, aortic obstruction, shunts and aortopulmonary collaterals. The surgeon who carried out the operation is usually present in the catheter laboratory at the time of the study. If a residual lesion is identified, our practice is to convene a short meeting in the catheter laboratory control room with surgeons, cardiologists and intensivists represented. An immediate decision is made whether the patient should return to the operating theatre or should proceed to have catheter intervention. About 20–50% of residual lesions can be dealt with in the catheter laboratory [2, 11, 16]. Interventions include

duct stenting (**Figure 5**), shunt angioplasty or stenting, branch pulmonary artery angioplasty or stenting, coronary stenting, stent fenestration of Fontan circulation, balloon atrial septostomy, ASD device closure, VSD device closure, coil occlusion of collaterals and catheter-directed thrombolysis [3, 5, 11, 17]. Complications are rare [2–5, 11, 16]. As the circulation is fully supported, hybrid procedures are possible, particularly when the chest is open. For example, branch pulmonary artery stenting can be carried out with a sheath introduced through the anterior wall of the main pulmonary artery or right ventricular outflow tract. A greater risk of vessel rupture during angioplasty or stenting can be accepted when the chest is open, the patient is draped for a surgical procedure and the whole theatre team are scrubbed and on standby in the catheter laboratory, as the surgeon can quickly control bleeding and repair even major damage to blood vessels (**Figure 4**).

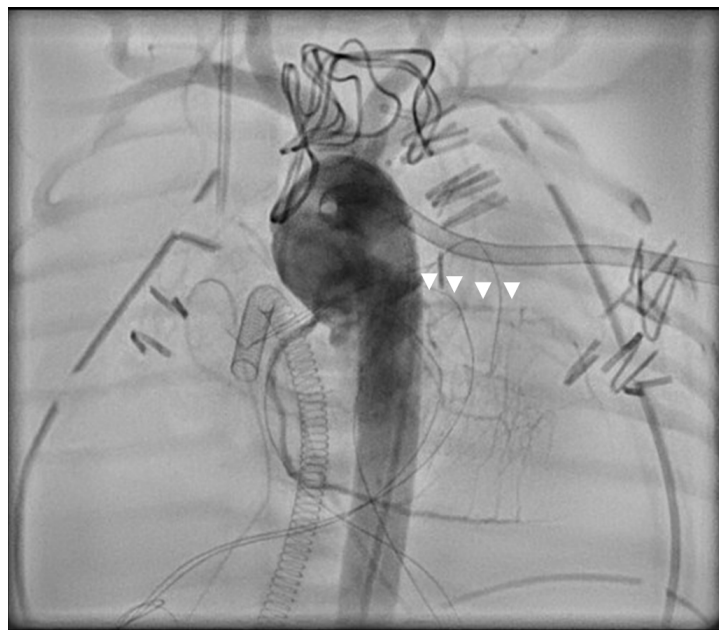


Figure 3. Partial occlusion of the left coronary artery post-repair of common arterial trunk. Legend—The arrowheads show weak opacification of the left coronary artery.

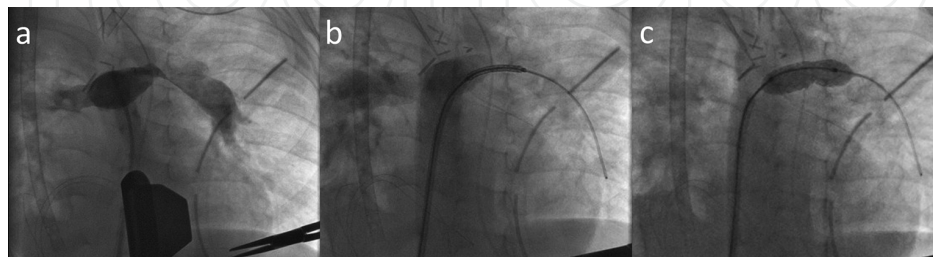


Figure 4. (a) Torsion of the left pulmonary artery following unifocalisation surgery for pulmonary atresia with VSD and MAPCAS (major aortopulmonary collateral arteries); (b) A pre-mounted stent is positioned across the site of stenosis; (c) The stent is deployed but has a residual waist. As the balloon is inflated to higher pressure, the pulmonary artery ruptures at the stenotic anastomotic site and has to be repaired immediately by the surgeon who is on standby.

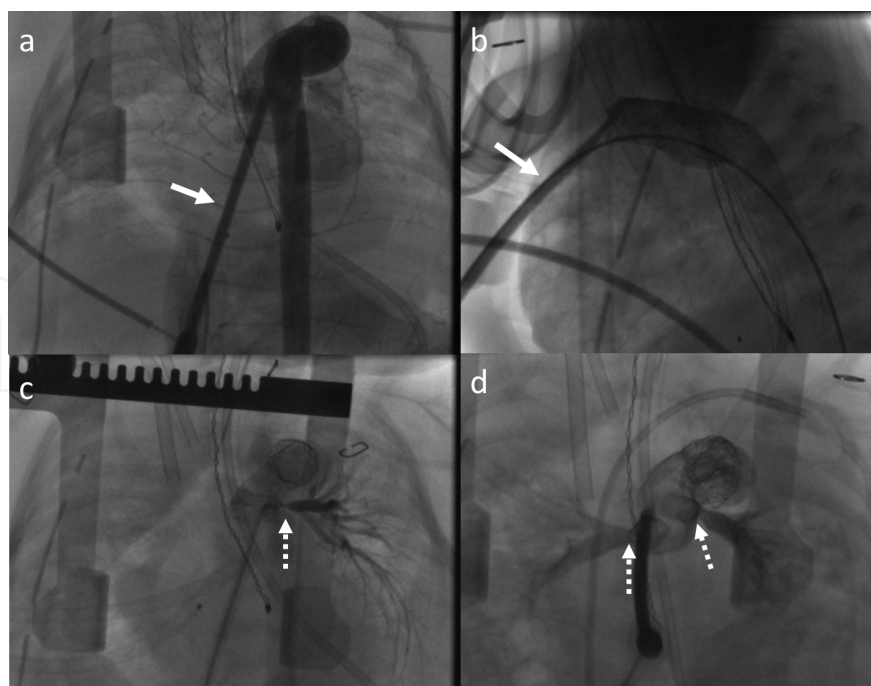


Figure 5. Stenting the arterial duct and altering pulmonary artery bands in a hybrid Norwood procedure. (a) Angiography is carried out via a sheath introduced through the anterior wall of the pulmonary artery (solid arrow). The pulmonary arteries are not opacified as the bands are too tight; (b) Lateral view showing flow into the aorta after stenting the arterial duct; (c) Very tight left pulmonary artery band (dashed arrow); (d) Good flow into the pulmonary arteries with mild proximal narrowing (dashed arrows) after loosening the pulmonary artery bands.

3.2. The cardiac patient with acute haemodynamic collapse unrelated to surgery

3.2.1. When is diagnostic catheterisation indicated?

Neonates who present moribund with shock or profound cyanosis may require urgent extracorporeal support before a full cardiac evaluation can be carried out. When congenital heart disease is present, a full diagnosis is usually then secured with transthoracic echocardiography alone. However, it may be difficult to diagnose obstructed total anomalous pulmonary venous drainage, as its clinical presentation mimics lung disease and pulmonary venous drainage can be hard to define once VA ECMO has been commenced, even when ECMO flows are reduced to encourage flow through the pulmonary circulation. In view of this, ECMO patients have sometimes required cardiac catheterisation to establish or exclude TAPVD [18, 19]. However, in the current era, every effort is made to establish pulmonary venous drainage echocardiographically before sick neonates are placed on ECMO. When this is not possible, contrast CT may offer a less invasive alternative.

3.2.2. Catheter intervention in children on ECMO

When ECMO is initiated to treat shock or cyanosis in cardiac patients, cardiac catheterisation is normally only necessary when intervention is planned. A wide array of interventions have

been described following emergency ECMO in paediatric patients, including balloon angioplasty of critical aortic stenosis [1, 20], balloon angioplasty of a restrictive cor triatriatum membrane [21], balloon atrial septostomy in the context of hypoplastic left heart syndrome with a restrictive atrial septum [4] and radiofrequency ablation of incessant tachycardia [22, 23].

3.2.3. ECMO salvage as an alternative to balloon atrial septostomy for moribund patients with transposition of the great arteries

Patients with transposition of the great arteries deserve special mention. When such patients present profoundly hypoxic and acidotic, the team is under great pressure to perform balloon atrial septostomy quickly. However, it may sometimes be difficult and time-consuming to gain vascular access. In such circumstances, it is occasionally easier and quicker to cannulate the neck vessels for ECMO. Once the patient is on ECMO, balloon atrial septostomy can be undertaken or the patient can proceed to theatre for an arterial switch procedure after a period of stabilisation [24].

3.2.4. Catheter intervention in adults on ECMO

Adult patients may also require emergency ECMO support followed by catheter intervention. Patients with massive pulmonary embolism may need to be resuscitated using extracorporeal support, following which catheter-directed thrombolytic therapy, catheter embolus fragmentation or percutaneous thrombectomy can be carried under stable conditions [25–27]. As structural intervention gains momentum, patients who need ECMO support because of shock or cardiac failure caused by severe valvar stenosis or regurgitation may increasingly be treated using transcatheter therapy on extracorporeal support. TAVI has already been carried out following emergency ECMO [28] and one patient with severe mitral regurgitation requiring ECMO has been successfully treated with a MitraClip [29]. However, results are likely to be better if ECMO is used to electively support interventional procedures in high-risk patients, before acute haemodynamic decompensation occurs [28].

3.3. Left heart decompression in patients with poor ventricular function

3.3.1. Why is left heart decompression necessary?

When VA ECMO is commenced to support patients with severe myocardial dysfunction, the heart may stop ejecting completely because of the increased afterload caused by the extracorporeal circulation. In these circumstances, left ventricular end-diastolic pressure rises sharply because of acute left heart distension, and the increased wall stress, reduced myocardial perfusion and subendocardial ischaemia that occur as a consequence compromise recovery of ventricular function. Left atrial pressure increases, causing pulmonary venous hypertension, pulmonary oedema and in severe cases pulmonary haemorrhage. Left heart decompression is necessary to decrease pulmonary oedema, avoid pulmonary haemorrhage and allow myocardial recovery [30–32].

3.3.2. *Making the decision to decompress the left heart*

Approximately 10–20% patients who require ECMO for poor left ventricular function will require left heart decompression [31–33]. The decision to decompress the left atrium is usually made within 24 h of commencing ECMO, on the basis of left heart dilation on echocardiography and pulmonary oedema on chest X-ray [32]. Direct surgical left atrial cannulation is possible in post-operative patients [31, 32]. However, a non-surgical approach is preferable in patients with myocarditis and post-operative patients where there is a plan to switch to neck cannulation in order to close the chest.

3.3.3. *Percutaneous decompression using drains incorporated into the ECMO circuit*

Percutaneous decompression may be achieved by introducing a transeptal left atrial drain from a femoral venous approach [32, 34–37] or passing a pigtail catheter into the left ventricle from a femoral artery approach [38, 39]. The return from these drains is incorporated into the venous limb of the ECMO circuit. However, there are concerns about systemic thromboembolism when hardware remains in the left heart for a prolonged period of time. Also, transeptal drains have become less popular in recent years because of problems with kinking, poor flow and drain movement with patient care [32].

3.3.4. *Percutaneous left atrial decompression by opening the atrial septum*

In the majority of patients, left atrial decompression is achieved by balloon atrial septostomy [30, 32, 40]. If prolonged extracorporeal support is anticipated or balloon septostomy fails to achieve an adequate interatrial communication, atrial septal stenting is carried out [32, 41]. Transeptal puncture is required as a first step in approximately 90% of patients, as only about 10% have a pre-existing interatrial communication [30, 32]. Most transeptal punctures are carried out using a Brockenbrough needle. Accidental left atrial perforation is a particular concern as the patient is fully anticoagulated. However, the largest series reported only one left atrial perforation, which closed without requiring pericardial drainage [32]. Needle position may be guided by transthoracic or transoesophageal echocardiography to minimise complications [40, 42]. Radiofrequency transeptal perforation is an alternative and may be preferable when the septum is very thick, but there is some concern that an accidental burn hole in the atrial wall may be less likely to close spontaneously. In young infants, it is possible to perform a Rashkind balloon atrial septostomy, rapidly jerking a septostomy balloon from the left to the right atrium in order to tear a hole in the atrial septum. Older patients require a static balloon septostomy, as the septum is too thick for the Rashkind technique to be effective.

3.3.5. *Static balloon septostomy*

To perform a static balloon septostomy, a long sheath is advanced over the transeptal needle into the left atrium. A catheter is then advanced through the transeptal sheath and directed into the left upper pulmonary vein. A wire is passed through the catheter into the pulmonary vein and the catheter and sheath are withdrawn. A balloon is advanced over the wire until it is centred across the atrial septum. Balloons are usually in the 12–18 mm range, but smaller

and larger diameters may be required, depending on patient size [32, 33]. The balloon is then inflated to tear a hole in the septum (**Figure 6**). Historically, blade atrial septostomy was carried out after transseptal puncture to ensure that a large hole could be created, but blade septostomy has now almost disappeared from practice. If the hole is not big enough to reduce left atrial pressure to less than about 20 mmHg, a larger balloon can be used, a second hole can be created by a separate transseptal puncture, a cutting balloon (Boston Scientific, Natick, USA) can be used to create blade cuts in the margins of the defect to allow more effective balloon dilation, or atrial septal stenting can be carried out.

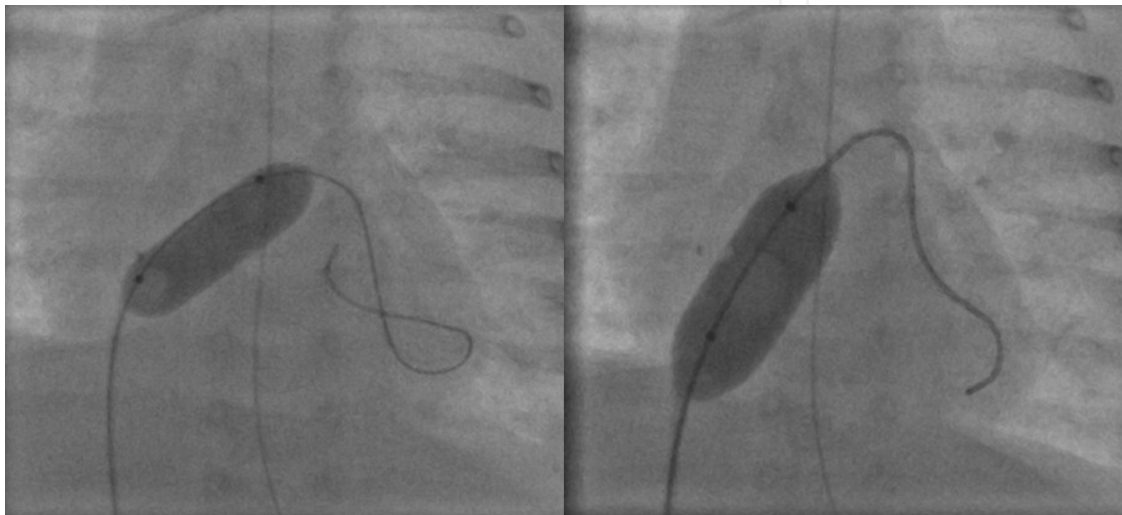


Figure 6. Static balloon dilation of the atrial septum with progressively larger balloons.

3.3.6. *Stenting the atrial septum*

Stenting can be carried out using the 'dog-bone' technique described by Stumper et al. (**Figure 7**) [43] or simply by implanting a straight stent across the septum (**Figure 8**) [42]. Echocardiography is used to measure the distance from the inferior vena cava to the atrial septum and from the septum to the pulmonary veins to guide what length of stent should be chosen. The stent should not project more than about halfway across the atrial cavity, to avoid the risk of puncturing the atrial wall, particularly when the heart size reduces as the patient recovers. Transoesophageal echocardiography can be used to check that the stent is accurately centred on the septum before the balloon is inflated. A hole with a diameter of about 4–5 mm is usually adequate [33]. To achieve this, when a straight stent is implanted, it is usually mounted on an 8- to 10-mm-diameter balloon, which is inflated at low pressure to leave a waist at the septum. In the current era, premounted stents are often used [42]. When the dog-bone technique is used, a 15-mm balloon should be used with a 4- to 5-mm constraining loop that prevents the centre of the balloon expanding. If a larger communication is required, the stent can be post-dilated. If the communication is too large, the centre of the stent can be constricted with a gooseneck snare [43].

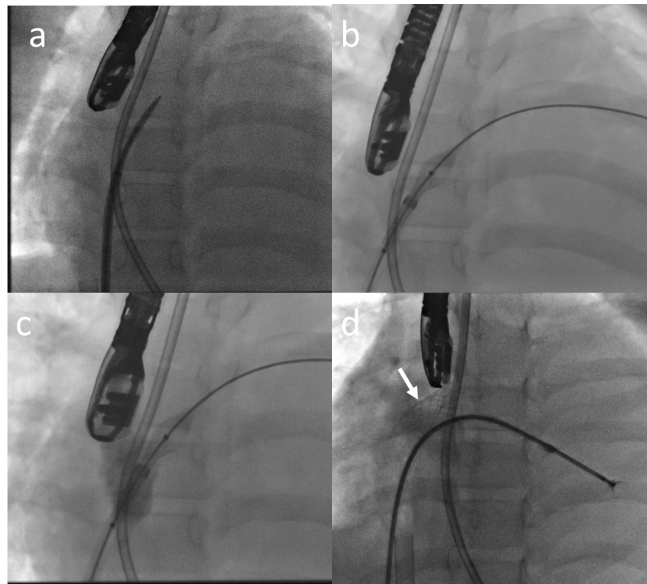


Figure 7. ‘Dog-bone’ stenting the atrial septum. (a) Brockenbrough needle transseptal puncture; (b) A wire is introduced into the left pulmonary vein, and a stent mounted on a balloon is advanced through a long sheath. The stent balloon assembly is half-unsheathed so that the distal half of the stent can be inflated and pulled back against the atrial septum; (c) As the sheath is pulled back to the right atrium to expose the whole stent, contrast injected through the side arm of the sheath defines the plane of the atrial septum and shows the stent is well centred; (d) The stent has been deployed across the atrial septum (arrow). There is a central waist which stabilises the stent on the septum. The waist was produced by tying a loop of prolene around the middle of the balloon before the stent was mounted. Myocardial biopsy is also shown.

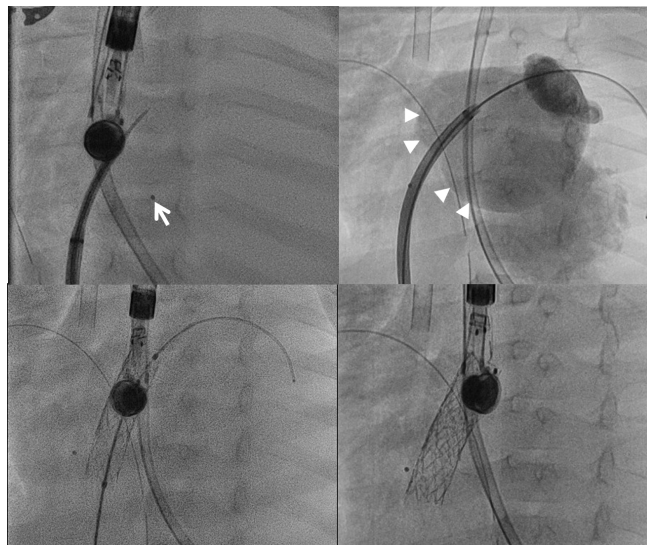


Figure 8. Implanting a straight stent across the atrial septum. (a) Brockenbrough needle transseptal puncture. The arrow highlights the small radio-opaque marker at the tip of the ECMO cannula. Most of the distal cannula is radiolucent; (b) The tip of the transseptal sheath is in the left atrium. Contrast injected into the left atrium defines the plane of the atrial septum (arrow heads); (c) A balloon mounted stent was deployed, but was not well centred on the septum. A second stent was therefore implanted overlapping the first stent to prevent embolisation; (d) The balloon and wire have been removed, leaving the 2 overlapping stents in a stable position.

3.3.7. *Does the atrial communication need to be closed after the patient recovers?*

Patients who survive ECMO after left atrial decompression should have routine follow-up echocardiography to check whether the atrial septal defect has closed. One study found that 80% of such patients had a residual defect and 44% required either transcatheter or surgical closure [33]. However, this may be an overestimate, as less than 20% of patients in another series had residual defects, and only one of those patients needed device closure [32].

3.4. Patients with haemodynamically unstable refractory arrhythmias

3.4.1. *Why is ECMO required in arrhythmia patients?*

Patients with haemodynamically unstable arrhythmias fall into two main categories:

(1) Adults with ventricular arrhythmias; (2) infants with tachycardia mediated cardiomyopathy secondary to incessant supraventricular tachycardia [44]. Such patients may require ECMO because (a) there is an abrupt haemodynamic deterioration; (b) there is no therapeutic window for drug treatment, because antiarrhythmic drugs have caused an unacceptable deterioration in the patient's haemodynamics; (c) catheter ablation is indicated but cannot proceed without extracorporeal support, either because the patient cannot maintain cardiac output in tachycardia or because the patient's haemodynamics are so precarious that there is a significant risk of cardiac arrest during the procedure.

3.4.2. *ECMO support of VT ablation in adult patients*

It is debatable whether adult patients with haemodynamically unstable VT benefit from ablation with ECMO support. ECMO certainly provides a stable platform to carry out activation mapping of VT where the arrhythmia is not haemodynamically tolerated [45]. However, VT ablation can now be carried out by substrate mapping, which does not require the patient to remain in the unstable tachycardia. The authors of a leading article in 2009 that advocated VT ablation with ECMO support have now retreated from that position [45]. They point out that greater experience with substrate mapping and the widespread availability of three-dimensional mapping systems have allowed the vast majority of haemodynamically unstable VTs to be successfully treated during sinus rhythm with very reasonable long-term success rates and very low morbidity. Their use of ECMO support for VT ablation therefore fell from 9% (2003–2007) to 0.5% (2007–2012) [46]. There will inevitably be cases where patients with VT require extracorporeal CPR or urgent ECMO for critically compromised haemodynamics. In such patients, who are small in number, it is sensible to proceed to ablate the VT whilst on mechanical support [47]. However, the era of elective ECMO support to allow activation mapping seems to have passed.

3.4.3. *When is radiofrequency ablation on ECMO necessary in infancy?*

In infants with tachycardia-related cardiomyopathy, ECMO is commenced when drug refractory incessant tachycardia causes progressive deterioration in haemodynamics or when antiarrhythmic drugs cause cardiovascular collapse requiring extracorporeal CPR [23, 48].

Once the patient is receiving extracorporeal support, approximately 2/3 should be treatable with antiarrhythmic drug therapy alone. However, catheter ablation may be required in about 1/3 patients [44]. Ablation may be necessary because the tachyarrhythmia is truly drug resistant. However, ablation is also reasonable when the tachycardia is very difficult to control on ECMO, requiring high-dose or multiple antiarrhythmic medications, as invasive treatment can shorten the duration of ECMO support and minimise the risk of tachycardia recurrence [23, 48]. It is important to avoid tachycardia recurrence following decannulation as it is may be very difficult to recannulate the neck vessels if the child becomes unstable again.

3.4.4. Elective use of ECMO to support paediatric ablation procedures

ECMO can be used to electively support paediatric ablation procedures when patients cannot maintain an adequate cardiac output in tachycardia, either because of congenital heart disease or poor ventricular function, and mapping in tachycardia is an essential part of the procedure [49]. In such procedures, the length of time the patient will need to spend in tachycardia, the degree of haemodynamic impairment this will cause, the size of the patient, the technical difficulty of the ablation and the possibility of extracorporeal CPR being required all factor into the decision to use ECMO pre-emptively.

3.4.5. Technical aspects

Very few publications focus on catheter ablation of arrhythmias in children on ECMO. Although some of the larger series dealing with paediatric cardiac catheterisation on ECMO include a few patients who had ablation, only basic information is provided [2, 5]. The sum total of published information consists of 13 patients described in a multicentre review [44] and 16 patients described in various case reports and case series [2, 5, 22, 23, 48–54], with possible overlap between these sources.

Atrial septostomy may be needed at the same time as ablation when left heart distension has developed on ECMO, as ventricular function and cardiac output may take several days to improve after the tachycardia is successfully ablated [22, 23, 44, 51]. Left atrial decompression may speed up resolution of pulmonary oedema, improve function and shorten the time to decannulation.

Most infant ablation procedures on ECMO are carried out with 2 vascular access points. A single diagnostic catheter and a 5 Fr 4-mm tip ablation catheter are usually used [44]. An oesophageal bipolar electrode can be added for atrial sensing and stimulation [48]. The largest study described an average of two ablation substrates per patient. Right-sided accessory pathways and left-sided ventricular tachycardia were the most common ablation targets. About 69% were successfully treated with radiofrequency ablation alone. In 29% cases, there were problems with convective cooling of the catheter tip, resulting in inadequate lesion formation. Energy delivery and thermodynamics were not improved by reducing ECMO flow to increase blood flow through the heart. After converting to cryoablation, the tachycardias were successfully ablated. Although this series described a procedural success rate of 100%, the complication rate was 15%, with one patient suffering transient heart block and one mitral

valve damage that ultimately required valve replacement [44]. The desire to produce effective lesions to avoid tachycardia recurrence must be tempered by caution. Lesion depth should be kept at a minimum to reduce the risk of perforation and damage to adjacent cardiac structures, such as valves or coronary arteries, which are particularly close to the endocardium of the atrioventricular junction in infants. There are no robust data to suggest how much energy should be delivered to achieve this balance. Although successful ablation has been described with energy as low as 5 W [23], we recommend initially setting up the ablator to deliver 20 s lesions at a power of 10 W with a temperature limit of 50° when treating infants. Where convective cooling does not allow delivery of an effective lesion, successful ablation can also be achieved with a cooled tip ablation catheter [23].

3.5. Percutaneous coronary intervention on ECMO in critically ill patients

3.5.1. Types of mechanical support available for percutaneous coronary intervention

There are occasions when percutaneous coronary intervention (PCI) cannot be carried out without additional haemodynamic support. The characteristic scenarios are cardiac arrest, cardiogenic shock and global critical coronary perfusion status. In these circumstances, various types of mechanical circulatory support are available, including VA ECMO, intra-aortic balloon pump, Impella (Abiomed, Danvers, MA) and Tandem Heart (Cardiac Assist, Inc., Pittsburgh, PA). Impella uses an axial flow pump to propel blood from the left ventricle to the aorta. Tandem Heart pumps blood extracorporeally from the left atrium to the femoral artery via a transeptally placed left atrial cannula. Current evidence on the utility of these devices is summarised in the 2015 SCAI/ACC/HFSA/STS consensus statement on mechanical circulatory support [55]. Choice between these various modalities is dictated by the patients' haemodynamic status, availability of equipment and local expertise. In our centre, where there is a large ECMO programme and considerable experience with emergent use of ECMO,

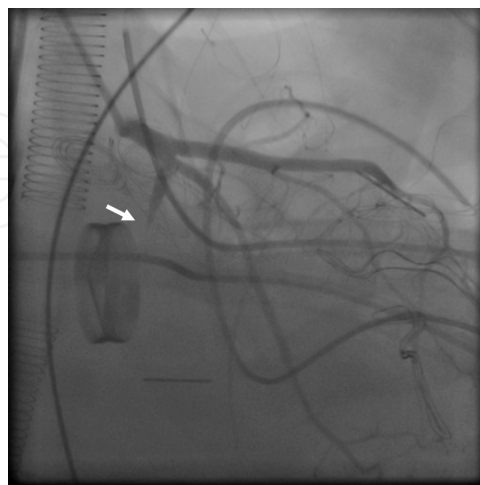


Figure 9. Circumflex occlusion (arrow) following mitral valve replacement. Stent implantation successfully opened the occluded segment.

patients are more likely to receive ECMO support when their haemodynamic status is critically compromised. ECMO should be chosen in preference to other ventricular assist devices when there is impaired oxygenation or right ventricular failure. Post-operative patients on ECMO may occasionally require PCI when there is an unexpected coronary lesion (**Figure 9**).

3.5.2. PCI on ECMO in patients who have a cardiac arrest

Patients who have cardiac arrest before or during PCI present the greatest challenge to the interventional team. To carry out PCI while there is no spontaneous cardiac output is extremely difficult. Manual CPR in this setting, even if performed to perfection, requires pauses for X-ray imaging and soon becomes ineffective in most cases. When extracorporeal CPR is instituted soon after cardiac arrest, it provides a haemodynamically stable platform for PCI that allows the operator to focus on the technique itself, rather than dealing with volatile haemodynamics and a jerky, mobile X-ray view of the target vessel. There are reports of excellent outcomes from PCI in patients on ECMO following cardiac arrest [56–61]. However, Kagawa et al. described only 29% 30-day survival in 61 patients with acute coronary syndrome who received emergency ECMO coupled with PCI to treat cardiac arrest unresponsive to manual CPR [62]. Arlt et al. described 40% survival to hospital discharge in a cohort of patients who received PCI coupled with extracorporeal CPR using a miniaturised ECMO system [63]. Better results were described in the CHEER trial, which included 26 patients with resistant cardiac arrest who were treated with emergency ECMO, combined with 30 ml/kg of intravenous ice-cold saline to induce therapeutic hypothermia. Eleven of these patients proceeded to have PCI on ECMO. Six patients survived with full neurological recovery [64]. A well-organised extracorporeal CPR service is important to achieve the best outcomes in this context. Patients should be established on ECMO quickly by an expert team, following high-quality CPR without severe metabolic disturbance or tissue hypoxia, to maximise their chance of survival with intact neurology.

3.5.3. PCI on ECMO in patients with profound cardiogenic shock

When patients who require PCI present with severe cardiogenic shock (usually defined as systolic blood pressure less than 75 mmHg on high-dose inotropic support), extracorporeal support can be used to offload the left ventricle and boost cardiac output during revascularisation. Recent studies have suggested that survival is improved when ECMO is used as an adjunct to PCI in this patient group. Esper et al. [65] showed an impressive 67% survival to discharge in patients with severe shock who received ECMO in the cardiac catheter laboratory. Good outcome has also been demonstrated following left main stem PCI in patients with cardiogenic shock supported by ECMO [66]. Data from true randomised comparison of outcomes with and without ECMO are absent. However, comparison between present and historic cohorts provides some insight. Sheu et al. [67] demonstrated a statistically significant reduction in 30-day mortality in PCI patients with profound shock, from 72% to 39%, following introduction of ECMO support in 2002. Tsao et al. [68] demonstrated a significant difference in 30-day (32% vs 67%) and 1-year (24% vs 64%) survival in PCI patients with severe shock when they compared cohorts treated without ECMO (2004–2006) and with ECMO (2007–2009),

respectively. Unai et al. [69] found similar results after introducing ECMO support for PCI patients with profound shock in 2010. Existing evidence therefore supports early ECMO intervention in this patient group, particularly to avoid the peak in mortality that normally occurs in the first few days after revascularisation [67]. A recent meta-analysis suggests that this positive effect on in-hospital mortality is found only in patients treated with ECMO and that treatment with percutaneous left ventricular assist devices, such as the Impella or Tandem Heart, does not confer a survival benefit [70].

3.5.4. Elective use of ECMO to support high-risk PCI

Percutaneous coronary intervention is regarded as high risk when there is moderate-to-severe left ventricular dysfunction, a large amount of myocardium is subtended by the stenosed vessels and, in addition, the procedure involves technical difficulties, such as the presence of bifurcation lesions, triple vessel disease, left main stenosis or chronic total occlusion. In such cases, where there is a significant risk that the intervention will precipitate haemodynamic decompensation, it is intuitive to suppose that elective extracorporeal support will reduce mortality. Yet, better outcomes have not been convincingly demonstrated in high-risk PCI procedures supported by intra-aortic balloon pump or Impella [71–73]. In contrast to this, a recent study using elective Tandem Heart support yielded promising results, with 30-day and 6-month survival rates of 90% and 87%, respectively [73]. From this study, it is tempting to extrapolate that elective ECMO may improve outcome in this patient group, where the safety margin is very small. Case reports have certainly described success in high-risk PCI using ECMO to produce a stable haemodynamic platform [74, 75]. One single-centre prospective study reported 100% PCI success with no in-hospital major adverse cardiac events in 12 consecutive patients who underwent high-risk PCI with ECMO support. At 6-month follow-up, neither death nor myocardial infarction were noted [76]. Notwithstanding this, there are at present no large volume conclusive multicentre trials of these techniques. It is possible that other means of haemodynamic support may be just as effective as ECMO in these situations. Technological advances in usability and further attempts at generating good scientific evidence for the role of ECMO in PCI will go hand in hand and hopefully provide strong evidence for guideline development in the longer term.

3.6. ECMO support for high-risk elective congenital and structural catheter intervention procedures

3.6.1. When has elective ECMO support been used for high-risk procedures?

Elective use of ECMO to support high-risk intervention is a new area of practice. There is little published information. The larger series that deal with paediatric catheterisation on ECMO do not include data on ECMO use in this context [2–5, 11]. One series dealing with extracorporeal CPR in the paediatric catheter laboratory included two patients with critically low cardiac output and one with severe hypoxaemia who had elective ECMO support before catheterisation [77]. The patients survived with no neurological damage. A handful of case reports have also shown that elective ECMO before catheterisation allows procedures to be

undertaken safely in patients with extremely fragile haemodynamics. Interventions included branch pulmonary artery stenting [78, 79], radiofrequency ablation of a Mahaim pathway [49], radiofrequency ablation of VT [52] and tricuspid valve implantation [80]. In adult patients, 100% procedural success and 0% mortality were described in a small very high-risk TAVI cohort where ECMO was instituted electively before the procedure. These results were clearly superior to those cases where high-risk TAVI patients were rescued by emergency ECMO during the procedure [28]. Such 'ECMO hybrid procedures' allow us to deal with increasingly complex interventional problems in sicker patients without increasing mortality.

3.6.2. The team approach to using ECMO in high-risk catheter procedures

In our catheter laboratory, the risks of procedures that could potentially have catastrophic complications are mitigated by collaboration with the ECMO team. Whenever there is a significant possibility of lethal complications, the case is discussed with the interventional team, the ECMO team, cardiac intensivists and cardiac surgeons. A joint plan is made in advance at a multidisciplinary team meeting. A detailed team briefing then takes place on the morning of the procedure, with all disciplines represented. Participants are encouraged to raise any potential issues in advance. It is important to plan as much as possible before the procedure, anticipating difficulties rather than reacting to them as they occur [81].

3.6.3. Our local 3 level strategy to support high-risk catheter procedures

Depending on the perceived level of risk, we have three different levels of ECMO support:

3.6.3.1. Level 1

The first level of support is used for cases where serious complications are possible but unlikely. We include duct stenting or right ventricular outflow tract stenting in this category, as it is possible that the patient's only source of pulmonary blood supply can be compromised by the intervention. In such cases, the ECMO team and surgical team are made aware that the procedure is taking place, but no special precautions are taken. Sharing information cuts down the response time, should extracorporeal CPR become necessary.

3.6.3.2. Level 2

The second level of support is used for cases where there is a significant possibility of a lethal complication. In this category, we include patients undergoing stenting and high-pressure balloon dilation of a calcific right ventricle to pulmonary artery conduit, particularly where aggressive dilation is planned at a site where rupture would be difficult to control with a covered stent, for example at the pulmonary artery bifurcation. If there is a massive rupture, the only possible rescue strategy may be to occlude the entire conduit with a balloon and place the patient on VA ECMO while preparations are made for cardiac surgery. In such cases, in addition to the vascular access that is required to perform the intervention, we place an extra sheath in the contralateral femoral artery and vein. These sheaths can be rewired and used for percutaneous ECMO cannulation in an emergency. An ECMO circuit is assembled and kept

in the catheter laboratory. Blood and products are prepared in advance as if the patient were going for cardiac surgery. The ECMO team, a cardiac surgeon and a theatre team remain in the catheter laboratory during the procedure, and a cardiac theatre is kept free. When the risk is particularly high and the response needs to be immediate, the ECMO circuit is primed with blood before the procedure starts. High-risk neonatal interventions in this category involve preparing the neck for cannulation rather than the groin. This may consist of prepping and draping the neck area and inserting a sheath that can be easily rewired into the jugular vein or may extend to cut down and exposure of the neck vessels for cannulation in very high-risk cases.

3.6.3.3. Level 3

The third level of support is reserved for patients with poor ventricular function and low cardiac output, where there is a high risk of cardiac arrest or acute haemodynamic decompensation during the catheter procedure (**Figure 10**). Also in this category are patients who have critically low oxygen saturation because of narrowed shunts or branch pulmonary arteries, where pulmonary blood flow will be further compromised during the intervention. In these patients, ECMO is electively instituted in advance of the case while the patient is on the intensive care unit. We have used this approach to carry out conduit stenting in an adult patient with gross right heart failure secondary to severe chronic right ventricle to pulmonary artery conduit stenosis. The patient, who had an excellent result, was decannulated on the

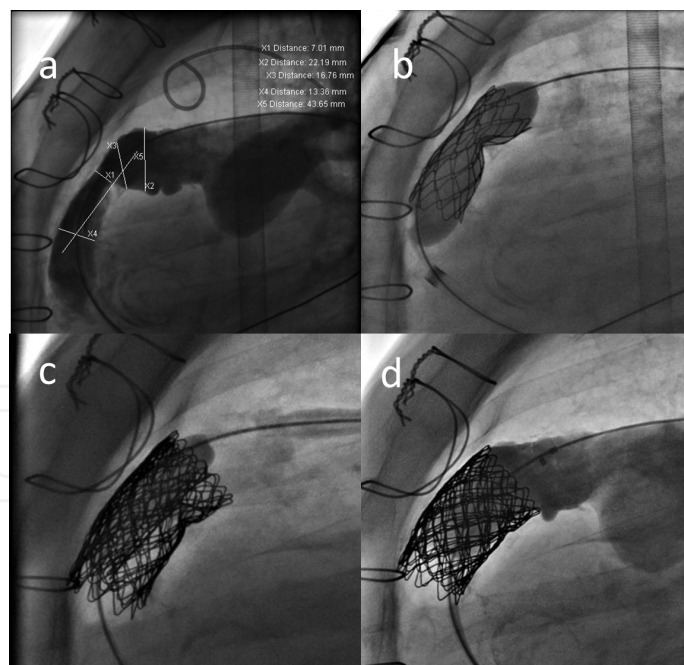


Figure 10. Elective ECMO support of right ventricle to pulmonary artery conduit stenting. (a) Angiography shows a tight stenosis in the right ventricle to pulmonary artery conduit; (b) A covered stent is implanted in the conduit. Further stents were subsequently implanted and dilated with a high-pressure balloon; (c) A Melody (Medtronic, Minneapolis, MN) percutaneous pulmonary valve is implanted in the prestented conduit at a second procedure 5 months later; (d) A well-expanded conduit with a competent pulmonary valve is ultimately achieved.

same day as the procedure and ultimately had successful percutaneous pulmonary valve implantation.

Author details

Christopher Duke^{1*}, Chris J. Harvey², Vikram Kudumula³, Elved B. Roberts⁴ and Suhair O. Shebani³

*Address all correspondence to: akd11@le.ac.uk

1 Department of Paediatric Cardiology, King Faisal Cardiac Centre, National Guard Health Affairs, Jeddah, Saudi Arabia and East Midlands Congenital Heart Disease Centre, Glenfield Hospital, Leicester, UK

2 Department of Cardiothoracic Surgery, Glenfield Hospital, Leicester, UK

3 East Midlands Congenital Heart Disease Centre, Glenfield Hospital, Leicester, UK

4 Department of Cardiology, Glenfield Hospital, Leicester, UK

References

- [1] Prodhan P, Fiser RT, Cenac S, Bhutta AT, Fontenot E, Moss M, et al. Intrahospital transport of children on extracorporeal membrane oxygenation: indications, process, interventions, and effectiveness. *Pediatr Crit Care Med*. 2010;11(2):227–33. doi:10.1097/PCC.0b013e3181b063b2
- [2] Panda BR, Alphonso N, Govindasamy M, Anderson B, Stocker C, Karl TR. Cardiac catheter procedures during extracorporeal life support: a risk-benefit analysis. *World J Pediatr Congenit Heart Surg*. 2014;5(1):31–7. doi:10.1177/2150135113505297
- [3] Callahan R, Trucco SM, Wearden PD, Beerman LB, Arora G, Kreutzer J. Outcomes of pediatric patients undergoing cardiac catheterization while on extracorporeal membrane oxygenation. *Pediatr Cardiol*. 2015;36(3):625–32. doi:10.1007/s00246-014-1057-5
- [4] desJardins SE, Crowley DC, Beekman RH, Lloyd TR. Utility of cardiac catheterization in pediatric cardiac patients on ECMO. *Catheter Cardiovasc Interv*. 1999;46(1):62–7. doi:10.1002/(SICI)1522-726X(199901)46:1<62::AID-CCD17>3.0.CO;2-9
- [5] Booth KL, Roth SJ, Perry SB, del Nido PJ, Wessel DL, Laussen PC. Cardiac catheterization of patients supported by extracorporeal membrane oxygenation. *J Am Coll Cardiol*. 2002;40(9):1681–6.

- [6] Endemann DH, Philipp A, Hengstenberg C, Luchner A, Puhler T, Hilker M, et al. A simple method of vascular access to perform emergency coronary angiography in patients with veno-arterial extracorporeal membrane oxygenation. *Intensive Care Med.* 2011;37(12):2046–9. doi:10.1007/s00134-011-2383-1
- [7] Ucer E, Fredersdorf S, Jungbauer C, Debl K, Philipp A, Amann M, et al. A unique access for the ablation catheter to treat electrical storm in a patient with extracorporeal life support. *Europace: European pacing, arrhythmias, and cardiac electrophysiology: journal of the working groups on cardiac pacing, arrhythmias, and cardiac cellular electrophysiology of the European Society of Cardiology.* 2014;16(2):299–302. doi:10.1093/europace/eut165
- [8] Kogon B, Villari C, Shah N, Kirshbom P, Kanter K, Kim D, et al. Occlusion of the modified Blalock-Taussig shunt: unique methods of treatment and review of catheter-based intervention. *Congenit Heart Dis.* 2007;2(3):185–90. doi:10.1111/j.1747-0803.2007.00095.x
- [9] Thuys C, MacLaren G, d’Udekem Y, Eastaugh L. Vascular access for pediatric coronary angiography on extracorporeal membrane oxygenation. *World J Pediatr Congenit Heart Surg.* 2015;6(1):126–9. doi:10.1177/2150135114554303
- [10] Ettetdgui JA FF, Park SC, Fischer DR, Siewers RD, del Nido, PJ. Cardiac catheterization in children on extracorporeal membrane oxygenation. *Cardiol Young.* 1996;6:59–61.
- [11] Agarwal HS, Hardison DC, Saville BR, Donahue BS, Lamb FS, Bichell DP, et al. Residual lesions in post-operative pediatric cardiac surgery patients receiving extracorporeal membrane oxygenation support. *J Thorac Cardiovasc Surg.* 2014;147(1):434–41. doi:10.1016/j.jtcvs.2013.03.021
- [12] Kulik TJ, Moler FW, Palmisano JM, Custer JR, Mosca RS, Bove EL, et al. Outcome-associated factors in pediatric patients treated with extracorporeal membrane oxygenator after cardiac surgery. *Circulation.* 1996;94(9 Suppl):II63-8.
- [13] Alsoufi B, Al-Radi OO, Gruenwald C, Lean L, Williams WG, McCrindle BW, et al. Extracorporeal life support following cardiac surgery in children: analysis of risk factors and survival in a single institution. *Eur J Cardiothorac Surg.* 2009;35(6):1004–11; discussion 11. doi:10.1016/j.ejcts.2009.02.015
- [14] Chaturvedi RR, Macrae D, Brown KL, Schindler M, Smith EC, Davis KB, et al. Cardiac ECMO for biventricular hearts after paediatric open heart surgery. *Heart.* 2004;90(5):545–51.
- [15] Feltes TF, Bacha E, Beekman RH, 3rd, Cheatham JP, Feinstein JA, Gomes AS, et al. Indications for cardiac catheterization and intervention in pediatric cardiac disease: a scientific statement from the American Heart Association. *Circulation.* 2011;123(22):2607–52. doi:10.1161/CIR.0b013e31821b1f10

- [16] Zahn EM, Dobrolet NC, Nykanen DG, Ojito J, Hannan RL, Burke RP. Interventional catheterization performed in the early post-operative period after congenital heart surgery in children. *J Am Coll Cardiol*. 2004;43(7):1264–9. doi:10.1016/j.jacc.2003.10.051
- [17] Anderson BW, Barron DJ, Jones TJ, Edwards L, Brawn W, Stumper O. Catheter takedown in the management of the acutely failing Fontan circulation. *Ann Thorac Surg*. 2011;92(1):346–8. doi:10.1016/j.athoracsur.2011.01.040
- [18] Zylberberg R, Cook L, Roberts J, Edmonds D, Reese A, Groff D. Total anomalous pulmonary venous return: report of a case diagnosed on ECMO. *J Perinatol*. 1987;7(3):185–8.
- [19] Faulkner SC, Chipman CW, Moss MM, Frazier EA, Love JC, Harrell JE, et al. Extracorporeal life support of neonates with congenital cardiac defects: techniques used during cardiac catheterization and surgery. *J Extra Corpor Technol*. 1994;26(1):28–33.
- [20] Butler TJ, Yoder BA, Seib P, Lally KP, Smith VC. ECMO for left ventricular assist in a newborn with critical aortic stenosis. *Pediatr Cardiol*. 1994;15(1):38–40. doi:10.1007/BF00797005
- [21] Schiller O, Burns KM, Sinha P, Cummings SD. Cor triatriatum with partial anomalous pulmonary venous return: a rare case of parallel obstruction and successful staged treatment. *Pediatr Cardiol*. 2012;33(2):363–5. doi:10.1007/s00246-011-0148-9
- [22] Khan M, Gauri A, Grifka R, Elmouchi D. Radiofrequency Ablation of a Left Atrial Appendage Tachycardia on ECMO Support. *Case Rep Pediatr*. 2013;2013:203241. doi:10.1155/2013/203241
- [23] Shebani SO, Ng GA, Stafford P, Duke C. Radiofrequency ablation on veno-arterial extracorporeal life support in treatment of very sick infants with incessant tachycardia. *Europace: European pacing, arrhythmias, and cardiac electrophysiology: journal of the working groups on cardiac pacing, arrhythmias, and cardiac cellular electrophysiology of the European Society of Cardiology*. 2015;17(4):622–7. doi:10.1093/europace/euu365
- [24] O'Connor TA, Downing GJ, Ewing LL, Gowdamarajan R. Echocardiographically guided balloon atrial septostomy during extracorporeal membrane oxygenation (ECMO). *Pediatr Cardiol*. 1993;14(3):167–8. doi:10.1007/BF00795647
- [25] Griffith KE, Jenkins E, Haft J. Treatment of massive pulmonary embolism utilizing a multidisciplinary approach: a case study. *Perfusion*. 2009;24(3):169–72. doi:10.1177/0267659109346663
- [26] Munakata R, Yamamoto T, Hosokawa Y, Tokita Y, Akutsu K, Sato N, et al. Massive pulmonary embolism requiring extracorporeal life support treated with catheter-based interventions. *Int Heart J*. 2012;53(6):370–4.

- [27] Nakamura M, Sunagawa O, Tsuchiya H, Miyara T, Taba Y, Touma T, et al. Rescue balloon pulmonary angioplasty under veno-arterial extracorporeal membrane oxygenation in a patient with acute exacerbation of chronic thromboembolic pulmonary hypertension. *Int Heart J*. 2015;56(1):116–20. doi:10.1536/ihj.14-257
- [28] Husser O, Holzamer A, Philipp A, Nunez J, Bodi V, Muller T, et al. Emergency and prophylactic use of miniaturized veno-arterial extracorporeal membrane oxygenation in transcatheter aortic valve implantation. *Catheter Cardiovasc Interv*. 2013;82(4):E542–51. doi:10.1002/ccd.24806
- [29] Staudacher DL, Bode C, Wengenmayer T. Severe mitral regurgitation requiring ECMO therapy treated by interventional valve reconstruction using the MitraClip. *Catheter Cardiovasc Interv*. 2015;85(1):170–5. doi:10.1002/ccd.25332
- [30] Seib PM, Faulkner SC, Erickson CC, Van Devanter SH, Harrell JE, Fasules JW, et al. Blade and balloon atrial septostomy for left heart decompression in patients with severe ventricular dysfunction on extracorporeal membrane oxygenation. *Catheter Cardiovasc Interv*. 1999;46(2):179–86. doi:10.1002/(SICI)1522-726X(199902)46:2<179::AID-CCD13>3.0.CO;2-W
- [31] Kotani Y, Chetan D, Rodrigues W, Sivarajan VB, Gruenwald C, Guerguerian AM, et al. Left atrial decompression during venoarterial extracorporeal membrane oxygenation for left ventricular failure in children: current strategy and clinical outcomes. *Artif Organs*. 2013;37(1):29–36. doi:10.1111/j.1525-1594.2012.01534.x
- [32] Eastaugh LJ, Thiagarajan RR, Darst JR, McElhinney DB, Lock JE, Marshall AC. Percutaneous left atrial decompression in patients supported with extracorporeal membrane oxygenation for cardiac disease. *Pediatr Crit Care Med*. 2015;16(1):59–65. doi:10.1097/PCC.0000000000000276
- [33] O'Byrne ML, Glatz AC, Rossano JW, Schiavo KL, Dori Y, Rome JJ, et al. Middle-term results of trans-catheter creation of atrial communication in patients receiving mechanical circulatory support. *Catheter Cardiovasc Interv*. 2015;85(7):1189–95. doi:10.1002/ccd.25824
- [34] Aiyagari RM, Rocchini AP, Remenapp RT, Graziano JN. Decompression of the left atrium during extracorporeal membrane oxygenation using a transseptal cannula incorporated into the circuit. *Crit Care Med*. 2006;34(10):2603–6. doi:10.1097/01.CCM.0000239113.02836.F1
- [35] Ward KE, Tuggle DW, Gessouroun MR, Overholt ED, Mantor PC. Transseptal decompression of the left heart during ECMO for severe myocarditis. *Ann Thorac Surg*. 1995;59(3):749–51. doi:10.1016/0003-4975(94)00579-6
- [36] Hlavacek AM, Atz AM, Bradley SM, Bandisode VM. Left atrial decompression by percutaneous cannula placement while on extracorporeal membrane oxygenation. *J Thorac Cardiovasc Surg*. 2005;130(2):595–6. doi:10.1016/j.jtcvs.2004.12.029

- [37] Swartz MF, Smith F, Byrum CJ, Alfieris GM. Transseptal catheter decompression of the left ventricle during extracorporeal membrane oxygenation. *Pediatr Cardiol.* 2012;33(1):185–7. doi:10.1007/s00246-011-0113-7
- [38] Fumagalli R, Bombino M, Borelli M, Rossi F, Colombo V, Osculati G, et al. Percutaneous bridge to heart transplantation by venoarterial ECMO and transaortic left ventricular venting. *Int J Artif Organs.* 2004;27(5):410–3.
- [39] Barbone A, Malvindi PG, Ferrara P, Tarelli G. Left ventricle unloading by percutaneous pigtail during extracorporeal membrane oxygenation. *Interact Cardiovasc Thorac Surg.* 2011;13(3):293–5. doi:10.1510/icvts.2011.269795
- [40] Johnston TA, Jagers J, McGovern JJ, O’Laughlin MP. Bedside transseptal balloon dilation atrial septostomy for decompression of the left heart during extracorporeal membrane oxygenation. *Catheter Cardiovasc Interv.* 1999;46(2):197–9. doi:10.1002/(SICI)1522-726X(199902)46:2<197::AID-CCD17>3.0.CO;2-G
- [41] Haynes S, Kerber RE, Johnson FL, Lynch WR, Divekar A. Left heart decompression by atrial stenting during extracorporeal membrane oxygenation. *Int J Artif Organs.* 2009;32(4):240–2.
- [42] Sivakumar K. Atrial septal stenting—How I do it? *Ann Pediatr Cardiol.* 2015;8(1):37–43. doi:10.4103/0974-2069.149516
- [43] Stumper O, Gewillig M, Vettukattil J, Budts W, Chessa M, Chaudhari M, et al. Modified technique of stent fenestration of the atrial septum. *Heart.* 2003;89(10):1227–30.
- [44] Silva JN, Erickson CC, Carter CD, Greene EA, Kantoch M, Collins KK, et al. Management of pediatric tachyarrhythmias on mechanical support. *Circulation Arrhythmia and electrophysiology.* 2014;7(4):658–63. doi:10.1161/CIRCEP.113.000973
- [45] Carbucicchio C, Della Bella P, Fassini G, Trevisi N, Riva S, Giraldo F, et al. Percutaneous cardiopulmonary support for catheter ablation of unstable ventricular arrhythmias in high-risk patients. *Herz.* 2009;34(7):545–52. doi:10.1007/s00059-009-3289-3
- [46] Bella PD, Maccabelli G. Temporary percutaneous left ventricular support for ablation of intolerated ventricular tachycardias: is it worth the trouble? *Circ Arrhythm Electrophysiol.* 2012;5(6):1056–8. doi:10.1161/CIRCEP.112.979013
- [47] Rizkallah J, Shen S, Tischenko A, Zieroth S, Freed DH, Khadem A. Successful ablation of idiopathic left ventricular tachycardia in an adult patient during extracorporeal membrane oxygenation treatment. *Can J Cardiol.* 2013;29(12):1741 e17-9. doi:10.1016/j.cjca.2013.08.015
- [48] Walker GM, McLeod K, Brown KL, Franklin O, Goldman AP, Davis C. Extracorporeal life support as a treatment of supraventricular tachycardia in infants. *Pediatr Crit Care Med.* 2003;4(1):52–4. doi:10.1097/01.PCC.0000043916.45503.34

- [49] Carmichael TB, Walsh EP, Roth SJ. Anticipatory use of venoarterial extracorporeal membrane oxygenation for a high-risk interventional cardiac procedure. *Respir Care*. 2002;47(9):1002-6.
- [50] Thomas V, Lawrence D, Kogon B, Frias P. Epicardial ablation of ventricular tachycardia in a child on venoarterial extracorporeal membrane oxygenation. *Pediatr Cardiol*. 2010;31(6):901-4. doi:10.1007/s00246-010-9734-5
- [51] Cisco MJ, Asija R, Dubin AM, Perry SB, Hanley FL, Roth SJ. Survival after extreme left atrial hypertension and pulmonary haemorrhage in an infant supported with extracorporeal membrane oxygenation for refractory atrial flutter. *Pediatr Crit Care Med*. 2011;12(3):e149-52. doi:10.1097/PCC.0b013e3181e8b3e5
- [52] Arya SO, Karpawich PP, Gupta P, Buddhe S, Singh HR, Hussein Y, et al. Primary endocardial fibroelastosis presenting in a young child as incessant ventricular tachycardia and dilated cardiomyopathy. *Tex Heart Inst J*. 2012;39(5):714-8.
- [53] Dyamenahalli U, Tuzcu V, Fontenot E, Papagiannis J, Jaquiss RD, Bhutta A, et al. Extracorporeal membrane oxygenation support for intractable primary arrhythmias and complete congenital heart block in newborns and infants: short-term and medium-term outcomes. *Pediatr Crit Care Med*. 2012;13(1):47-52. doi:10.1097/PCC.0b013e3182196cb1
- [54] Koutbi L, Chenu C, Mace L, Franceschi F. Ablation of idiopathic ventricular tachycardia arising from posterior mitral annulus in an 11-month-old infant by transapical left ventricular access via median sternotomy. *Heart Rhythm: The Official Journal of the Heart Rhythm Soc*. 2015;12(2):430-2. doi:10.1016/j.hrthm.2014.10.030
- [55] Rihal CS, Naidu SS, Givertz MM, Szeto WY, Burke JA, Kapur NK, et al. 2015 SCAI/ACC/HFSA/STS clinical expert consensus statement on the use of percutaneous mechanical circulatory support devices in cardiovascular care (Endorsed by the American heart association, the cardiological society of India, and sociedad latino Americana de cardiologia intervencion; Affirmation of value by the canadian association of interventional cardiology-association canadienne de cardiologie d'intervention). *Catheter Cardiovasc Interv*. 2015;85(7):E175-96. doi:10.1002/ccd.25720
- [56] Dahdouh Z, Roule V, Sabatier R, Lognone T, Labombarda F, Pellissier A, et al. Extracorporeal life support, transradial thrombus aspiration and stenting, percutaneous blade and balloon atrioseptostomy, all as a bridge to heart transplantation to save one life. *Cardiovasc Revasc Med*. 2012;13(4):241-5. doi:10.1016/j.carrev.2012.02.007
- [57] Galassi AR, Ganyukov V, Tomasello SD, Haes B, Leonid B. Successful antegrade revascularization by the innovation of composite core dual coil in a three-vessel total occlusive disease for cardiac arrest patient using extracorporeal membrane oxygenation. *Eur Heart J*. 2014;35(30):2009. doi:10.1093/eurheartj/ehu070
- [58] Lazzeri C, Sori A, Bernardo P, Picariello C, Gensini GF, Valente S. In-hospital refractory cardiac arrest treated with extracorporeal membrane oxygenation: a tertiary single

- center experience. *Acute Card Care*. 2013;15(3):47–51. doi:10.3109/17482941.2013.796385
- [59] Lee MS, Pessequeiro A, Tobis J. The role of extracorporeal membrane oxygenation in emergent percutaneous coronary intervention for myocardial infarction complicated by cardiogenic shock and cardiac arrest. *J Invasive Cardiol*. 2008;20(9):E269–72.
- [60] Magovern GJ Jr, Simpson KA. Extracorporeal membrane oxygenation for adult cardiac support: the Allegheny experience. *Ann Thorac Surg*. 1999;68(2):655–61.
- [61] Ricciardi MJ, Moscucci M, Knight BP, Zivin A, Bartlett RH, Bates ER. Emergency extracorporeal membrane oxygenation (ECMO)-supported percutaneous coronary interventions in the fibrillating heart. *Catheter Cardiovasc Interv*. 1999;48(4):402–5.
- [62] Kagawa E, Dote K, Kato M, Sasaki S, Nakano Y, Kajikawa M, et al. Should we emergently revascularize occluded coronaries for cardiac arrest?: rapid-response extracorporeal membrane oxygenation and intra-arrest percutaneous coronary intervention. *Circulation*. 2012;126(13):1605–13. doi:10.1161/CIRCULATIONAHA.111.067538
- [63] Arlt M, Philipp A, Voelkel S, Schopka S, Husser O, Hengstenberg C, et al. Early experiences with miniaturized extracorporeal life-support in the catheterization laboratory. *Eur J Cardiothorac Surg*. 2012;42(5):858–63. doi:10.1093/ejcts/ezs176
- [64] Stub D, Bernard S, Pellegrino V, Smith K, Walker T, Sheldrake J, et al. Refractory cardiac arrest treated with mechanical CPR, hypothermia, ECMO and early reperfusion (the CHEER trial). *Resuscitation*. 2015;86:88–94. doi:10.1016/j.resuscitation.2014.09.010
- [65] Esper SA, Bermudez C, Dueweke EJ, Kormos R, Subramaniam K, Mulukutla S, et al. Extracorporeal membrane oxygenation support in acute coronary syndromes complicated by cardiogenic shock. *Catheter Cardiovasc Interv*. 2015;86 Suppl 1:S45–50. doi:10.1002/ccd.25871
- [66] Lee WC, Tsai TH, Chen YL, Yang CH, Chen SM, Chen CJ, et al. Safety and feasibility of coronary stenting in unprotected left main coronary artery disease in the real world clinical practice—a single center experience. *PloS one*. 2014;9(10):e109281. doi:10.1371/journal.pone.0109281
- [67] Sheu JJ, Tsai TH, Lee FY, Fang HY, Sun CK, Leu S, et al. Early extracorporeal membrane oxygenator-assisted primary percutaneous coronary intervention improved 30-day clinical outcomes in patients with ST-segment elevation myocardial infarction complicated with profound cardiogenic shock. *Crit Care Med*. 2010;38(9):1810–7. doi:10.1097/CCM.0b013e3181e8acf7
- [68] Tsao NW, Shih CM, Yeh JS, Kao YT, Hsieh MH, Ou KL, et al. Extracorporeal membrane oxygenation-assisted primary percutaneous coronary intervention may improve survival of patients with acute myocardial infarction complicated by profound cardiogenic shock. *J Crit Care*. 2012;27(5):530 e1–11. doi:10.1016/j.jcrc.2012.02.012
- [69] Unai S, Tanaka D, Ruggiero N, Hirose H, Cavarocchi NC. Acute myocardial infarction complicated by cardiogenic shock: an algorithm-based extracorporeal membrane

oxygenation program can improve clinical outcomes. *artif organs*. 2015. doi:10.1111/aor.12538

- [70] Romeo F, Acconcia MC, Sergi D, Romeo A, Francioni S, Chiarotti F, et al. Percutaneous assist devices in acute myocardial infarction with cardiogenic shock: review, meta-analysis. *World J Cardiol*. 2016;8(1):98–111. doi:10.4330/wjc.v8.i1.98
- [71] Perera D, Stables R, Thomas M, Booth J, Pitt M, Blackman D, et al. Elective intra-aortic balloon counterpulsation during high-risk percutaneous coronary intervention: a randomized controlled trial. *JAMA*. 2010;304(8):867–74. doi:10.1001/jama.2010.1190
- [72] Romeo F, Acconcia MC, Sergi D, Romeo A, Gensini GF, Chiarotti F, et al. Lack of intra-aortic balloon pump effectiveness in high-risk percutaneous coronary interventions without cardiogenic shock: a comprehensive meta-analysis of randomised trials and observational studies. *Int J Cardiol*. 2013;167(5):1783–93. doi:10.1016/j.ijcard.2012.12.027
- [73] O'Neill WW, Kleiman NS, Moses J, Henriques JP, Dixon S, Massaro J, et al. A prospective, randomized clinical trial of haemodynamic support with Impella 2.5 versus intra-aortic balloon pump in patients undergoing high-risk percutaneous coronary intervention: the PROTECT II study. *Circulation*. 2012;126(14):1717–27. doi:10.1161/CIRCULATIONAHA.112.098194
- [74] Kass M, Moon M, Vo M, Singal R, Ravandi A. Awake extracorporeal membrane oxygenation for very high-risk coronary angioplasty. *Can J Cardiol*. 2015;31(2):227 e11–3. doi:10.1016/j.cjca.2014.11.004
- [75] Spina R, Forrest AP, Adams MR, Wilson MK, Ng MK, Vallely MP. Venous-arterial extracorporeal membrane oxygenation for high-risk cardiac catheterisation procedures. *Heart Lung Circ*. 2010;19(12):736–41. doi:10.1016/j.hlc.2010.08.015
- [76] Tomasello SD, Boukhris M, Ganyukov V, Galassi AR, Shukevich D, Haes B, et al. Outcome of extracorporeal membrane oxygenation support for complex high-risk elective percutaneous coronary interventions: a single-center experience. *Heart Lung*. 2015;44(4):309–13. doi:10.1016/j.hrtlng.2015.03.005
- [77] Allan CK, Thiagarajan RR, Armsby LR, del Nido PJ, Laussen PC. Emergent use of extracorporeal membrane oxygenation during pediatric cardiac catheterization. *Pediatr Crit Care Med*. 2006;7(3):212–9. doi:10.1097/01.PCC.0000200964.88206.B0
- [78] Zampi JD, Rocchini A, Hirsch-Romano JC. Elective ECMO support for pulmonary artery stent placement in a 4.9-kg shunt-dependent patient. *World J Pediatr Congenit Heart Surg*. 2015;6(1):101–4. doi:10.1177/2150135114549077
- [79] Ward CJ, Mullins CE, Barron LJ, Grifka RG, Gomez MR, Cuellar-Gomez MR. Use of extracorporeal membrane oxygenation to maintain oxygenation during pediatric interventional cardiac catheterization. *Am Heart J*. 1995;130(3 Pt 1):619–20. doi:

- [80] Kefer J, Sluysmans T, Vanoverschelde JL. Transcatheter Sapien valve implantation in a native tricuspid valve after failed surgical repair. *Catheter Cardiovasc Interv.* 2014;83(5):841–5. doi:10.1002/ccd.25330
- [81] Dalton HJ. Planning for the unexpected: extracorporeal membrane oxygenation in the catheterization laboratory and beyond. *Pediatr Crit Care Med.* 2006;7(3):279–81. doi:10.1097/01.PCC.0000216673.97153.D9

IntechOpen

IntechOpen