

We are IntechOpen, the world's leading publisher of Open Access books Built by scientists, for scientists

4,800

Open access books available

122,000

International authors and editors

135M

Downloads

Our authors are among the

154

Countries delivered to

TOP 1%

most cited scientists

12.2%

Contributors from top 500 universities



WEB OF SCIENCE™

Selection of our books indexed in the Book Citation Index
in Web of Science™ Core Collection (BKCI)

Interested in publishing with us?
Contact book.department@intechopen.com

Numbers displayed above are based on latest data collected.
For more information visit www.intechopen.com



A Perspective on the Current Medical Approach of Advanced Medullary Thyroid Carcinoma

Ana Valea and Carmen Emanuela Georgescu

Additional information is available at the end of the chapter

<http://dx.doi.org/10.5772/63650>

Abstract

Medullary thyroid carcinoma (MTC) is a neuroendocrine tumor (NET), which originates in neural crest-derived calcitonin-producing C-cells. It occurs either sporadically or as a result of a germline mutation in the RET proto-oncogene, as in multiple endocrine neoplasia (MEN) syndrome type 2A including its variant familial MTC (FMTC) and type 2B. Currently, the only curative treatment for MTC is surgery, accompanied by lymph node dissection. However, the outcome is largely dependent on disease staging, with lymph node and distant metastases often identified at diagnosis, particularly in sporadic forms. Furthermore, the presence of cervical lymph node invasion at surgery predicts residual disease. The development of new treatments is strongly motivated by: (a) the low surgical cure rate when cervical lymph node metastases are present at the time of initial surgery, with 90% of patients having residual disease, (b) the high prevalence of distant metastases at initial diagnosis (lungs, bones and liver) and (c) the poor outcome in patients receiving cytotoxic chemotherapeutic agents. Herein, we focus on current nonsurgical options and perspectives in the treatment of MTC with emphasis on last year's FDA-approved tyrosine kinase inhibitors (TKIs) and other systemic therapies that need to be considered in the setting of advanced disease.

Keywords: thyroid, medullary thyroid carcinoma, therapy, tyrosine kinase inhibitors, everolimus, somatostatin analogues

1. Introduction

Medullary thyroid carcinoma (MTC) accounts for 1–5% of all thyroid cancers worldwide, with an apparently descending slope in the prevalence of MTC, at least in the USA, which rather can

be explained by the marked increase in the relative incidence of papillary thyroid carcinoma over the past decades [1]. As many as 25–30% of cases harbor a germline mutation in the RET proto-oncogene and present as a hereditary syndrome, as in multiple endocrine neoplasia (MEN) syndrome types 2A and 2B [2]. MEN2A, which accounts for 95% of all MEN2 cases, presents with four variants: classical MEN2A, MEN2A with cutaneous lichen amyloidosis (CLA), MEN2A with Hirschsprung's disease (HD) and familial MTC (FMTC, i.e. individuals or families with RET germline mutations and MTC but without pheochromocytoma or primary hyperparathyroidism) [1]. Alternatively, MTC develops as a sporadic form, with a peak of incidence between the 4th and 6th decades of life [3].

A feature of medullary cancer is represented by a variety of hormones or biogenic amines as secretory products of MTC cells including calcitonin and carcinoembryonic antigen (CEA; **Figure 1**) in addition to chromogranin A (CgA), serotonin, neurotensin, adrenocorticotrophic hormone (ACTH), B-melanocyte stimulating hormone (MSHB) or somatostatin. Of note, specifically calcitonin and CEA (unspecific) are validated as sensitive tumor markers for the diagnosis and post-therapeutic follow-up of the disease, and their preoperative serum concentrations are directly related to the C-cell mass [4].

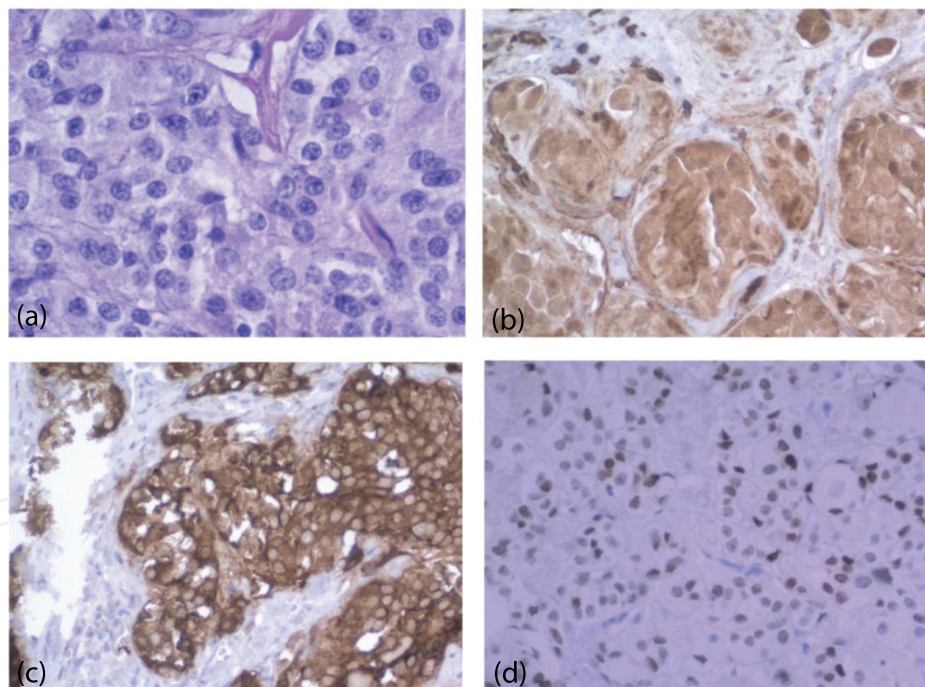


Figure 1. Microscopy of bifocal, bilobar MTC on a thyroidectomy piece in a c.1901G>T codon 634 mutation carrier. (a) H-E 40 \times ; (b) IHC anti-calcitonin 20 \times ; (c) IHC anti-CEA 20 \times ; and (d) IHC anti-TTF 20 \times . Adapted from Sovrea et al. [5], with permission from the publisher. H-E, haematoxylin-eosin; IHC, immunohistochemistry; CEA, carcinoembryonic antigen; TTF-1, thyroid transcription factor-1.

Early diagnosis of MTC still represents a challenge in clinical practice. About 70% of patients with medullary cancer who present with a palpable thyroid nodule have cervical metastases at initial evaluation; on top of that, 10% have distant metastases [6]. While sporadic forms more

often present as a solitary thyroid mass, hereditary syndromes are frequently multicentric and bilateral (**Figure 1**).

On neck ultrasonography, the tumor is typically located in the upper or central parts of the thyroid lobes in correlation with the distribution of C-cells (**Figure 2**). The exhibition of ultrasonographic features of malignancy including hypoechogenicity, irregular margins and intranodular calcifications correlates with tumor aggressiveness and a poor outcome. On the contrary, specific ultrasonographic appearance is lacking, and up to one-third of MTC may appear as non-suspicious on neck ultrasonography [7]. Overall, cost analysis suggests cost-effectiveness of calcitonin screening in patients with nodular goiter [8] and, subsequently, deepening investigations in patients with basal serum calcitonin levels at screening >20 pg/mL is recommended. Use of high-sensitivity immunoassays for measurements of calcitonin or, alternatively, a calcium-stimulation test, is indicated in patients with mildly elevated calcitonin levels.

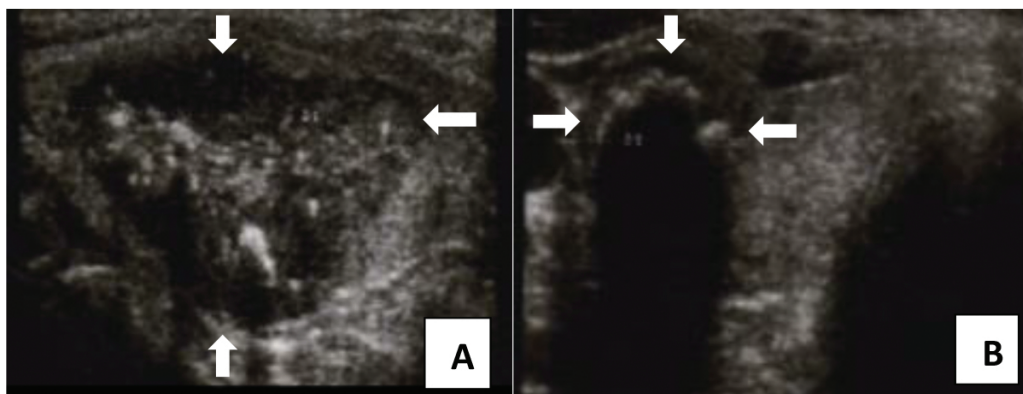


Figure 2. Grey-scale image of medullary thyroid carcinoma (MTC). (A) Cranio-caudal section and (B) transversal section.

Contrast-enhanced computer tomography (CT) scanning of the neck and chest (lymph nodes, lung metastases), contrast-enhanced CT or magnetic resonance imaging (MRI) of the liver, axial MRI and bone scintigraphy should be considered in patients with confirmed, extensive neck disease and signs of regional or distant metastases and in the presence of a serum calcitonin level above 400–500 pg/mL, as these patients almost always harbor systemic disease [9, 10]. Sensitivity of FDG-PET/CT or F-DOPA-PET/CT in detecting MTC metastases appears to be lower compared to other imaging investigations [1].

Recently revised American Thyroid Association (ATA) Guidelines for the management of medullary thyroid carcinoma suggest that fine needle aspiration biopsy (FNAB) should be performed in all thyroid nodules that are 1 cm or greater in size [1]. According to a meta-analysis, FNAB has been shown to have an accuracy of less than 50% in diagnosing MTC in affected subjects; however, diagnostic accuracy of FNAB analysis is significantly improved by measuring calcitonin levels in the FNA washout fluid [11]. In addition, immunohistochemistry analysis with positivity for calcitonin \pm CEA and CgA and absence of thyroglobulin (Tg) staining of the FNAB specimen is reassuring [1].

In advanced disease, markedly increased basal CEA in addition to discordantly lower calcitonin, or normal or low levels of both CEA and calcitonin (i.e. nonsecretory MTC) suggests poorly differentiated MTC. Screening for RET mutations is indicated as well, since it has been shown that up to 7% of patients with apparently sporadic MTC have hereditary disease [12].

There is evidence of central and lateral compartment lymph node metastases in 14 and 11% of patients with stage T₁ tumor, whereas an incidence of 86% and 93%, respectively, has been reported in stage T₄ [13]. Ten-year survival rates of 100% for stage I disease, 93% for stage II, 71% for stage III and 21% for stage IV MTC have been reported [14].

2. Conventional treatment strategies of medullary thyroid carcinoma

2.1. Surgery

Thyroidectomy is the only curative treatment for both sporadic and hereditary MTC, accompanied by dissection of cervical lymph node compartments. Patients who carry RET mutations should undergo prophylactic thyroidectomy upon genetic diagnosis, even during childhood but at different ages depending on the risk associated with the specific RET mutation. Radical surgery is rarely possible in advanced regional/distant disease and rather preservation of swallowing, speech and parathyroid function should be attempted [1].

The outcome of surgery is largely dependent on disease staging, with 10-year survival rate of 96% in localized disease but rapidly decreasing to a median survival rate of 3 years after evidence of distant metastases. Normalization of calcitonin (<10 pg/mL) and CEA is only seen in 40% of cases, and approximately 9% of patients who have achieved biochemical cure will later develop recurrent disease [14]. A primary tumor larger than 1 cm diameter in the presence of high preoperative basal calcitonin levels (>20 pg/mL) and CEA concentrations (>10 pg/mL) predicts lymph node metastases in both central and ipsilateral neck compartments [15].

Following surgery, patients undergo levothyroxine replacement therapy in order to maintain serum thyroid stimulating hormone (TSH) levels in the normal range. In patients with unilateral lobectomy in whom MTC was histologically confirmed, completion thyroidectomy is indicated in the presence of elevated postoperative calcitonin or imaging studies indicating residual disease, or patients in whom a positive RET germline mutation was confirmed. In residual MTC, the calcitonin doubling time bears significant prognostic value. Patients whose calcitonin doubling time is 1 year or less have 10-year survival rates of 18%, whereas those with calcitonin doubling time longer than 1 year have a 95% survival rate [16].

According to 2015 ATA guidelines, postoperative care is based upon the dynamics of tumor markers and ultrasonographic findings. Therefore, serum levels of calcitonin and CEA should be measured 3 months after surgery, and if undetectable or within the normal range, every 6–12 months, then yearly. If calcitonin levels are high, yet less than 150 pg/mL, and however, there is no evidence of loco-regional disease on ultrasonography, measurement of serum tumor markers and thyroid ultrasonography every 6 months are strongly recommended.

Should calcitonin levels exceed 150 pg/mL postoperatively, patients should undergo extensive imaging studies to detect persistent disease and/or metastases [1].

2.2. External beam radiation therapy

Adjunctive external beam radiation of the neck or mediastinum could be considered after surgery in MTC patients with high risk for local recurrence (i.e. residual tumor, extra-thyroidal extension, extensive lymph node metastases) or airway obstruction, when repeat surgery is not possible. External beam radiation therapy has been used as a therapeutic method to control local tumor growth in patients with advanced loco-regional disease and implies postoperative delivery of 60–66 Gy over 6 weeks to the thyroid bed, although higher doses may be needed in the presence of important residual disease [1]. Although external radiation therapy positively affects the quality of life [17, 18], it appears not to significantly alter the overall survival rate in patients with lymph node metastases as shown by Martinez et al. [19]. External radiation beam therapy adverse effects include skin erythema, laryngeal edema, mucositis and esophagitis in the early phase. Later on, osteonecrosis, arterial injury, brain or cranial nerve injury are encountered.

Additional indications of external beam radiation therapy are painful bone metastasis, for palliation, or for the prevention of other bone-related complications such as fractures or spinal cord compression. Bone metastases may also benefit from high-dose anti-resorptive therapy (intravenous bisphosphonates or RANK-ligand inhibitor human monoclonal antibody).

2.3. Radioactive iodine

Previous studies certified lack of significant effect of radioactive iodine treatment in patients with MTC, as C-cells do not concentrate iodine. It was hypothesized that radioiodine, concentrated by follicular cells, might induce C-cell apoptosis through a bystander effect, however, not confirmed. In 2013, a controlled multicentre study compared the outcome of 232 patients with local or loco-regional MTC treated only by surgery to 61 matched patients that were also treated with RAI and found no difference in terms of disease-free or disease-specific survival [20]. On the contrary, radioactive iodine therapy should be considered in patients with MTC if the primary tumors or metastases contain MTC mixed with papillary or follicular thyroid carcinoma [1].

2.4. Conventional chemotherapy

Indication of cytotoxic chemotherapy is limited to advanced MTC, when disease control cannot be achieved with other treatments, however, with limited efficacy. Single agent or combination chemotherapeutic regimens generally show low response rates (15–20%), and of short duration (a few months), whereas large clinical trials demonstrating survival benefits are lacking.

According to the National Comprehensive Cancer Network (NCCN), dacarbazine is the drug of choice in patients with disseminated, symptomatic disease [21], in combination to 5-fluorouracil (5FU). Apart from that, dacarbazine has been combined with other cytotoxic agents such as cyclophosphamide, vincristine, streptozotocin and epirubicin, with modest

results. Few studies and case reports have focused on the use of capecitabine, a 5FU pro-drug that preferentially accumulated in tumors rather than in plasma to inhibit tumor cell proliferation [22], with apparently encouraging effects in stabilizing MTC patients with advanced disease. In a small phase I study, the combination of imatinib with capecitabine and dacarbazine failed to induce an objective response in MTC but four of five patients subjected to the therapeutic regimen maintained stable disease [23]. A combination of capecitabine with temozolomide appears to improve metastatic MTC [24], but experience is limited to isolated case reports.

Alternatively, combination treatment regimens with doxorubicin and another agent (e.g. cisplatin) may be used [1].

3. Molecular targeted therapies in medullary thyroid carcinoma

Systemic therapy is solely reserved for metastatic, unresectable, unstable MTC (i.e. calcitonin doubling time below 2 years) [1] or symptomatic tumor progression that cannot be managed by localized organ therapy [21]. Severe diarrhea that does not respond to symptomatic medication might need systemic therapy.

In contrast to classic cytotoxic chemotherapeutic agents that show weak specificity in discriminating between normal and tumor cells, the use of targeted molecular therapies is advantageous by providing a more narrow and specific therapeutic window and less toxicity. The broader spectrum of targeted therapies in neoplastic disease includes: (a) tyrosine kinases inhibitors (TKIs), (b) anti-sense inhibitors of growth factor receptors and (c) monoclonal antibodies. Tyrosine kinases play key roles in the modulation of growth factors signaling. For instance, RAS activation depends on epidermal growth factor receptor (EGFR), and somatic RAS mutations have been described in patients with MTC in the absence of RET mutations [25]. Apart from the activation by growth factors, protein kinase activation by germline or somatic mutations is a mechanism commonly described in tumor genesis. In fact, about 50% of the patients with sporadic MTC have somatic mutations of RET proto-oncogene, besides patients with MEN2 syndrome, of whom 98% express germline RET mutations [26]. In addition, MTC cells often overexpress vascular endothelial growth factor receptors (VEGFRs). TKI intervenes by blocking the ATP site of the tyrosine kinase receptors to prevent tyrosine kinase activation. They inhibit thyroid tumor cell proliferation, migration and survival and angiogenesis.

3.1. Tyrosine kinase inhibitors

Of all TKIs, the Food and Drug Administration (FDA) recently approved vandetanib and cabozantinib as first-line agents for the treatment of symptomatic or progressive MTC in patients with unresectable or metastatic disease. Both American Thyroid Association (ATA) and National Comprehensive Cancer Network guidelines (NCCN) specifically address the two drugs to patients with advanced MTC [1, 21]. Vandetanib and cabozantinib are multi-kinase inhibitors, with vandetanib targeting several cell-signaling pathways involved in the

pathogenesis of MTC, including receptor tyrosine kinase RET, VEGFR-2 and -3 and EGFR and cabozantinib blocking RET, VEGFR-2 and c-MET [27], without simultaneously over-expressing any of the factors leading to the inhibition of angiogenesis. However, neither drug shows a clear correlation between RET mutational status and efficacy.

3.1.1. Vandetanib

In a trial with a phase II design on 30 adult patients with advanced MTC, of whom 70% had hereditary forms, objective partial response was obtained in 20% of patients while in 53% disease remained stable for 24 weeks during vandetanib 300 mg daily [28]. Vandetanib 100 mg/m²/d was confirmed as a relatively well-tolerated and effective treatment in children (5–18 years) positive for M918T *RET* germline mutations [29].

In a phase III, randomized, double-blind, placebo-controlled trial (ZETA trial) of 331 patients with unresectable locally advanced (5%) or metastatic (95%) MTC, vandetanib 300 mg once daily resulted in significant prolongation of median progression-free survival to a predicted 30.5 months in the vandetanib group in comparison to 19.3 months in the placebo group [30]. The overall response rate to vandetanib was 44% and was noticed in both patients positive for RET mutations and those without a RET mutation. At the end of the study, 35% of study subjects required dose reductions, and 12% discontinued therapy due to toxicity. A fatal adverse effect was reported in 2.5% of patients.

Tumor markers calcitonin and CEA may fluctuate in patients undergoing therapy with vandetanib, often with an initial drop of the marker levels. A rise in calcitonin levels $\geq 40\%$ between two follow-ups during the treatment for MTC appears to predict tumor progression early [31].

Vandetanib carries a black box warning for prolongation of the QT interval, *torsades de pointes* and sudden death. During treatment, medications that may prolong the QT interval must be avoided, and patients must undergo regular EKGs and serum electrolyte control. Patients with a history of long QT syndrome, baseline rate-corrected QT >450 ms, or uncorrectable electrolyte abnormalities should be excluded from treatment [32]. Other common adverse effects of vandetanib include diarrhea, nausea, fatigue and abdominal pain. In addition, hypertension, headache, acne and rash were reported. Hypocalcaemia, hepatocytolysis, hypoglycemia, hypertriglyceridemia [33], hypothyroidism and increased creatinine are common laboratory findings. In patients who cannot tolerate recommended dose, there is preliminary evidence that low-dose vandetanib is also efficient [34]; however, further studies are warranted.

Drug resistance to vandetanib has been described. Rare RET mutations V804M and V804L confer resistance to vandetanib as do RAS mutations, identified in 60–80% of RET-negative sporadic MTC cases. Sorafenib could be effective in these particular situations [26]. *In vitro* testing of tumor cell sensitivity to TKI, even in cell cultures prepared from fine needle aspiration specimens [35], has been shown to have a 60% positive predictive value of clinical response in the same patient and a 90% negative predictive value.

3.1.2. Cabozantinib

Cabozantinib approval was obtained following a phase III randomized, double-blind, placebo-controlled trial that enrolled 330 patients with progressive, metastatic or locally advanced MTC, in whom median progression-free survival increased significantly from 4.0 months in the placebo group to 11.2 months in the cabozantinib group [36]. The overall response rate was 28%. More than half of patients developed adverse effects such as diarrhea, stomatitis and palmo-plantar erythrodysesthesia. Other adverse effects were similar to those observed for vandetanib (nausea, abdominal pain, fatigue, hypertension). Hepatocytolysis, hyperbilirubinemia, neutropenia and thrombocytopenia were also encountered. Rare but severe adverse effects were gastrointestinal perforation and fistula and hemorrhage, also included on the black box warning. Thromboembolic events, osteonecrosis of the jaw and reversible posterior leukoencephalopathy syndrome were also mentioned. A total of 16% of patients discontinued treatment due to toxicity and 79% required dose reductions; 6% of patients experienced fatal adverse reactions. In view of major adverse effects, patients with a history of diverticulitis, chronic inflammatory gastrointestinal disease, active peptic ulcer, radiation to the neck or mediastinum as well as tumor invasion characteristics that may predispose to fistulas and hemorrhage need to be identified. A systematic review and meta-analysis on small-molecule TKI in patients with thyroid cancer published by Klein Hesselink et al. concluded that vandetanib and cabozantinib resulted in objective responses in 40% (95% CI 34–46%) and 27% (95% CI 22–32%) of patients with advanced MTC [37]. In clinical practice, response to cabozantinib was documented following a failed vandetanib treatment [38].

In conclusion, TKI vandetanib and cabozantinib have demonstrated important rates of disease control at the cost of significant drug toxicity. Still, TKIs are less toxic when compared to conventional cytotoxic agents. Further studies assessing the impact on overall survival for both agents are warranted, as previous studies failed to demonstrate prolonged survival. Head-to-head studies comparing the efficacy of the two drugs in patients with advanced MTC are lacking, therefore selection of one treatment over the other needs evaluation of potential risks and benefits for each patient. Factors that might influence the choice of TKI in patients with MTC are related to patient and drug characteristics, laboratory and cardiologic assessments, past medical history and concomitant medication. Cabozantinib is favored in patients with or at risk for long QT syndrome (baseline QTcF interval >450 ms), patients with uncorrected baseline dyselectrolytemia (hypocalcemia, hypomagnesemia or hypokalemia), patients unable or unwilling to protect from sun exposure or in the case of rapid disease progression. On the contrary, vandetanib should be firstly considered in patients with gastrointestinal comorbidities or tumors invading the trachea, esophagus, or major blood vessels because of the risk of perforation or fistula [39]. Concomitant use of a CYP3A4 inhibitor drug may increase the plasma concentration of cabozantinib, resulting in toxicity, whereas use of a CYP3A4 inducer may decrease the efficacy of vandetanib [32, 39]. Vandetanib may cause weight gain, whereas cabozantinib should be avoided in patients with low body mass index.

Several case reports indicated that both vandetanib and cabozantinib might successfully control ectopic Cushing's syndrome associated to MTC [40].

3.1.3. Sorafenib

Sorafenib, currently approved for the treatment of renal cell and hepatocellular carcinomas, constitutes first-line indication in advanced radioiodine-refractory differentiated thyroid carcinomas (DTCs). Reviewing retrospectively 13 patients with advanced MTC treated with sorafenib 400 mg twice daily, de Castroneves et al. observed stable disease in 10 (83.3%) patients [41]. A systematic review of sorafenib in metastatic thyroid cancer (both DTC and MTC) noticed an overall partial response rate of 22% for MTC patients, with only 6.5% having progressive disease, which suggests a reasonable clinical benefit [42]. However, treatment with sorafenib is associated with considerable toxicity, leading to highest rates of dose reduction or discontinuation [37].

3.1.4. Sunitinib

Sunitinib, available for gastrointestinal stromal tumors (GIST), renal cell carcinomas and pancreatic neuroendocrine tumors (pNET), was investigated in a small phase II study, and a response was objectivized in three of six (50%) patients with metastatic MTC and radiologically evaluable lesions, but more than 10% of treated patients experienced grade 3 or higher toxicities [43]. In a recent meta-analysis, encouraging results were obtained with sunitinib, with a clinical benefit in 43% of patients ($n = 36$) with advanced MTC [37].

3.1.5. Axitinib, motesanib, lenvatinib, ponatinib

Other kinase inhibitors have been investigated, with small trials showing variable results. *Axitinib* is an oral TKI that inhibits VEGFRs, c-KIT and PDGFR- β , approved for the treatment of renal carcinoma. A multicenter, open-label, phase II study examined the efficacy of axitinib in 60 patients with advanced or metastatic thyroid carcinoma of all histological subtypes [44]. Overall, 18% of patients with MTC presented partial response, with median progression-free survival of 18.1 months. Axitinib was relatively well tolerated, with the most common adverse event being hypertension. Another multicenter phase II study aimed at investigating the efficacy and tolerability of *motesanib* in 91 patients with locally advanced or metastatic, progressive or symptomatic MTC. Only two patients (2%) experienced a partial response, and stable disease was achieved in 74 patients (81%), lasting for 24 weeks or longer in 44 (48%) [45].

Ponatinib, a newer multi-kinase inhibitor used in the treatment of chronic myeloid leukemia and acute lymphoblastic leukemia, showed promising results in early trials, but it carries a black box warning due to a high rate of arterial thrombotic events.

A multi-kinase inhibitor targeting VEGFR-1-3, FGFR-1-4, RET, c-KIT and PDGFR- β is *lenvatinib*. Moreover, lenvatinib has been shown to be able to inhibit FGFR-1, thus targeting a pathway involved in resistance to VEGF-pathway inhibitors. In a phase II trial enrolling 59 patients with advanced MTC, an objective response rate was documented in 59%, stable disease was confirmed in 36% and a median progression-free survival of 13.3 months was reported [46].

Neither gefitinib nor imatinib induced objective responses in patients with advanced, progressive MTC [37].

The response of individual cases to TKI could be subjected to influence by the expression of RET or RAS mutations in the primary tumor, and Mancikova et al. found that in contrast to RET-positive tumors, RAS-positive tumors express neither PDGFR- β nor MET and poorly express VEGFR-3 [47], thus suggesting that intracellular targets of TKI are expressed according to the presence of RAS mutations, a potentially useful information in the selection of patients receiving treatment with TKI.

Summary

In summary, TKI, specifically vandetanib and cabozantinib, demonstrated a response rate of 27–44% in randomized trials and meta-analyses, to support first-line therapeutic indication in the management of symptomatic or progressive MTC in patients with non-resectable or metastatic disease. Nevertheless, dose-dependent toxicity of these drugs is considerable, including gastrointestinal perforations, fistulas and hemorrhage for cabozantinib and prolongation of the QT interval, *torsades de points* and sudden death for vandetanib. Liver failure, pulmonary arterial hypertension and development of secondary malignancies have been reported. Apparently, regression or stabilization of skeletal metastases related to advanced MTC is weakly influenced by TKI, although cabozantinib may exert some activity against certain types of bone lesions [43]. Overall, the quality of life is markedly affected by TKI with adverse effects reported by 30–60% of patients and serious adverse events occurring in 2% of cases [48]. The evidence for sorafenib and sunitinib in MTC is not as strong, but small studies have demonstrated their efficacy. Other kinase inhibitors have shown variable results.

3.2. Mammalian target of rapamycin (mTOR) inhibitors

There is solid evidence that the PI3K/Akt pathway is extensively involved in cell growth, proliferation and survival of all types of thyroid tumors. The mTOR kinase is a component of the PI3K signaling pathway, and AKT/mTOR activation is demonstrated in DTC and MTC with AKT/mTOR immunostaining present in more than 50% of medullary carcinoma cells [48]. *In vitro* experiments showed oncogenic RET may regulate mTOR activity in patients with MTC. Moreover, low-concentration RET and mTOR inhibitors administered as a combination, to concomitantly target RET and mTOR, acted cooperatively in cell culture experiments [49]. Prospective phase II trials with everolimus, an mTOR inhibitor, in patients with advanced MTC reported promising results. In one small-sized study, stable disease was obtained in five of seven (71%) patients [50]. The most frequent side effects in everolimus trials were fatigue, mucositis and hypertriglyceridemia, but overall the drug was well tolerated. Further investigations are warranted to evaluate the efficacy of everolimus as monotherapy or combined with other targeted agents in patients with advanced MTCs. **Table 1** depicts relevant randomized and non-randomized studies on treatment with TKI and mTOR inhibitors in patients with MTC.

Author	Study design	Drug regimen	Objective partial response (PR)%	Stable disease (SD)%	Common adverse effects
Wells et al., 2010 [28]	Open-label, phase II trial	Vandetanib 300 mg/day	20	53	Diarrhea, rash, fatigue, nausea
Robinson et al., 2010 [34]	Open-label, single-arm trial	Vandetanib 100 mg/day	16	53	Diarrhea, fatigue, rash, constipation, anorexia, back pain, nausea, photosensitivity
Wells et al., 2012 [30]	Randomized, double-blind, placebo-controlled phase III trial	Vandetanib 300 mg/day	45	87	Diarrhea, rash, nausea, hypertension, headache
Chougnnet et al., 2015 [51]	Retrospective cohort	Vandetanib 300 mg/day	20	55	Skin toxicity, diarrhea, asthenia
Kurzrock et al., 2011 [38]	Open-label, phase I dose-escalation study	Cabozantinib (maximum-tolerated dose = 175 mg/day)	29	41	Diarrhea, fatigue, decreased appetite, nausea, palmar-plantar erythrodysesthesia (PPE), rash, hepatocytolysis
Elisei et al., 2013 [36]	Randomized, double-blind, placebo-controlled phase III trial	Cabozantinib 140 mg/day	28	47.3 (progression-free at 1 year)	Diarrhea, decreased weight and appetite, PPE, nausea, fatigue
Capdevila et al., 2012 [52]	Retrospective longitudinal study	Sorafenib 2 × 400 mg/day	47	40	PPE, diarrhea, rash, asthenia, anorexia, stomatitis, hypertension, abdominal pain
de Castroneves et al., 2016 [41]	Retrospective, longitudinal study	Sorafenib 2 × 400 mg/day	0	83.3	PPE, weight loss, fatigue
De Souza et al., 2010 [53]	Nonrandomized, open-label, phase II study	Sunitinib 50 mg/day, 4/2 week schedule	35	57	Fatigue, lymphopenia, neutropenia, nausea, diarrhea, mucositis, PPE

Author	Study design	Drug regimen	Objective partial response (PR)%	Stable disease (SD)%	Common adverse effects
Carr et al., 2010 [19]	Non-randomized, open-label, phase II study	Sunitinib 37.5 mg/day	50	71	Fatigue, diarrhea, PPE, neutropenia
Lim et al., 2013 [54]	Non-randomized, open-label, single-arm phase II study	Everolimus 10 mg/day	0	100	Mucositis, anorexia, hepatocytolysis
Schneider et al., 2015 [50]	Non-randomized, open-label, single arm phase II study	Everolimus 10 mg/day	0	71	Mucositis, fatigue, hypertriglyceridemia

Table 1. Randomized and non-randomized studies on tyrosine kinase inhibitors (TKIs) and mammalian target of rapamycin (mTOR) inhibitors in advanced medullary thyroid carcinoma (MTC).

3.3. Somatostatin analogues (SSA)

Medullary thyroid cancers are neuroendocrine tumor (NET) that expresses cell surface somatostatin receptors (SSTRs) in less than 40% of cases; however, these cases may respond favorably to SSA treatment. *Octreotide* and *lanreotide*, the currently available SSA with high affinity for SSTR2 and SSTR5, may be helpful in controlling symptoms in advanced MTC, but they do not appear to significantly affect tumor burden or disease course. Indeed, SSA should be considered in case of flushing and diarrhea, if other drugs are ineffective [55].

3.4. Peptide receptor radiation therapy (PRRT)

There is limited experience with PRRT targeting SSTR2 and cholecystokinin (CCK) receptors A and B, which are expressed by medullary carcinomas, in patients with advanced, metastatic MTC [55]. A phase II trial evaluating systemic ^{90}Y -DOTATOC treatment in selected patients with stage IV MTC showed encouraging response and survival rates: 29% of the 31 study patients experienced reduction of serum calcitonin levels and had a significantly longer median survival from onset of treatment in comparison to non-responders (i.e. 74.5 months vs. 10.8 months); however, 13% of patients developed serious hematological toxicity, and 23% developed nephrotoxicity [56].

One study evaluated CCK-B/gastrin receptor-based PRRT and included eight patients with advanced MTC to whom the radioligand ^{90}Y -DTPT-D-Glu-minigastrin was administered. Of all, two patients developed partial remission and four had stable disease; severe adverse events were encountered, with one patient developing chronic myelogenous leukemia and another patient developing chronic renal failure [57]. Treatment with ^{177}Lu -DOTATATE reached

similar results with three of nine patients having partial response and other three presenting stable disease [58]. Current guidelines suggest that PRRT should be taken into account in well-selected cases [1].

3.5. Experimental therapies

A number of other treatments are in the early phases of development. *Pre-targeted radioimmunotherapy* with bi-specific monoclonal antibody (BsMAb) and ¹³¹I-labeled bivalent hapten has shown positive results in advanced, progressive MTC, but prospective, randomized trials comparing this therapy to other therapies or placebo are needed [1].

Vaccination with autologous dendritic cells pulsed with MTC-specific antigens (CEA or calcitonin) has been attempted, inducing specific immunoreactivity and leading to a clinical response in three of seven patients in one small study [59].

Combination therapy of a TKI (e.g. vandetanib) and a protease inhibitor (bortezomib) appears to induce synergistic effects in cell culture experiments [60], being under evaluation in human trials.

Treatment with *plitidepsin*, an antibiotic that can induce tumor apoptosis, has been used in 16 subjects with unresectable MTC in a phase II trial, with modest clinical benefits and manageable toxicity [61].

The HIV-protease inhibitor *nelfinavir* has been shown to decrease RET expression and induce apoptosis in medullary thyroid cancer cells, but clinical studies are needed to prove its efficacy in treating MTC [62].

Metformin is an anti-diabetic drug that seems to inhibit cancer cell viability through the inhibition of mTOR, an effect that was also observed in MTC cell lines [63]. Metformin is under testing in clinical trials in combination with other agents.

AZD 1480, a JAK 1,2 inhibitor, was shown to block proliferation and tumor growth of RET-activated thyroid cancer cells, supporting its use in advanced MTC; however, further research is needed [64].

Enzastaurin is a protein kinase C inhibitor that has been shown to produce tumor cell apoptosis and suppress tumor-induced angiogenesis. Its value in the treatment of advanced MTC is under investigation.

Epigenetic drugs, that target DNA methylation and acetylation, are regarded with increasing interest. Histone deacetylases regulate gene expression and cell cycle, proliferation and apoptosis. *Histone deacetylase inhibitors* have been shown to suppress proliferation of thyroid cancer cells, but evidence is based on small studies [48]. Combined targeted therapy is also currently under investigation.

3.6. Treatment of hormonally active metastases

Co-secretion of hormones other than calcitonin can often be observed in medullary carcinoma. The prevalence of diarrhea is related to tumor volume. From a pathogenic viewpoint,

diarrhea is due to either hypersecretory or increased gastrointestinal motility. Treatment includes anti-motility drugs (loperamide, diphenoxylate/atropine, codeine) and, in selected cases, SSA. When these therapies are insufficient, palliative surgery or chemoembolization may be helpful.

In cases of ectopic CRH or ACTH syndromes associated with unresectable MTC, steroidogenesis inhibitors and ultimately bilateral adrenalectomy should be considered.

4. Conclusions

The treatment of residual or recurrent medullary thyroid carcinoma (MTC) continues to be a challenge. Although surgery remains the mainstay of therapy, it can be curative only in the early stages of the disease. External beam radiotherapy and cytotoxic chemotherapy with dacarbazine and doxorubicin-based regimens may be useful in select patients, but with little or no impact on overall survival. In recent years, there has been significant progress in the treatment of advanced, metastatic MTC. The use of tyrosine kinase inhibitors (TKIs), cabozantinib and vandetanib, as first-line agents for symptomatic metastatic and progressive MTC has significantly improved progression-free survival, showing high rates of partial response and disease stabilization; however, prolonged survival has not been confirmed yet. The search continues for kinase inhibitors that can be used in patients who are unresponsive or develop resistance to existing drugs. Ongoing clinical trials evaluate additional agents that might significantly impact future management of the disease.

Acknowledgements

This work was supported by CNCSIS grant PN-II-ID-PCE-2011-3-0879 and Iuliu Hațieganu University of Medicine and Pharmacy internal grant 4944/20/08/03.2016.

Author details

Ana Valea and Carmen Emanuela Georgescu*

*Address all correspondence to: cgeorgescu@umfcluj.ro

Department of Endocrinology, Iuliu Hațieganu University of Medicine and Pharmacy
Cluj-Napoca, Cluj-Napoca, Romania

References

- [1] Wells SA Jr, Asa SL, Dralle H, Elisei R, Evans DB, Gagel RF, Lee N, Machens A, Moley JF, Pacini F, Raue F, Frank-Raue K, Robinson B, Rosenthal MS, Santoro M, Schlumberger M, Shah M, Waguespack SG. Revised American Thyroid Association guidelines for the management of medullary thyroid carcinoma. *Thyroid*. 2015;25(6):567–610. DOI: 10.1089/thy.2014.0335.
- [2] Moo-Young TA, Traugott AL, Moley JF. Sporadic and familial medullary thyroid carcinoma: state of the art. *Surg Clin North Am*. 2009;89(5):1193–204. DOI: 10.1016/j.suc.2009.06.021.
- [3] Leboulleux S, Baudin E, Travagli JP, Schlumberger M. Medullary thyroid carcinoma. *Clin Endocrinol*. 2004;61(3):299–310. DOI: 10.1111/j.1365-2265.2004.02037.
- [4] Costante G, Durante C, Francis Z, Schlumberger M, Filetti S. Determination of calcitonin levels in C-cell disease: clinical interest and potential pitfalls. *Nat Clin Pract Endocrinol Metab*. 2009;5(1):35–44. DOI: 10.1038/ncpendmet1023.
- [5] Sovrea AS, Dronca E, Galatâr M, Radian S, Vornicescu C, Georgescu C. Diagnostic correlation between RET proto-oncogene mutation, imaging techniques, biochemical markers and morphological examination in MEN2A syndrome: case report and literature review. *Rom J Morphol Embryol*. 2014;55(2):389–400.
- [6] Moley JF. Medullary thyroid carcinoma: management of lymph node metastases. *J Natl Compr Canc Netw*. 2010;8(5):549–556.
- [7] Trimboli P, Giovanella L, Valabrega S, Andrioli M, Baldelli R, Cremonini N, Rossi F, Guidobaldi L, Barnabei A, Rota F, Paoloni A, Rizza L, Fattorini G, Latini M, Ventura C, Falasca P, Orlandi F, Crescenzi A, D'Ambrosio F, Cantisani V, Romanelli F, Negro R, Saggiorato E, Appetecchia M. Ultrasound features of medullary thyroid carcinoma correlate with cancer aggressiveness: a retrospective multicenter study. *J Exp Clin Cancer Res*. 2014;33:87. DOI: 10.1186/s13046-014-0087-4.
- [8] Mayr B, Brabant G, von zur Mühlen A. Incidental detection of familial medullary thyroid carcinoma by calcitonin screening for nodular thyroid disease. *Eur J Endocrinol*. 1999;141(3):286–289. DOI: 10.1530/eje.0.1410286.
- [9] Machens A, Schneyer U, Holzhausen HJ, Dralle H. Prospects of remission in medullary thyroid carcinoma according to basal calcitonin levels. *J Clin Endocrinol Metab*. 2005;90(4):2029–2034. DOI: 10.1210/jc.2004-1836.
- [10] Machens A, Dralle H. Biomarker-based risk stratification for previously untreated medullary thyroid cancer. *J Clin Endocrinol Metab* 2010;95(6):2655–2663. DOI: 10.1210/jc.2009-2368.
- [11] Trimboli P, Cremonini N, Ceriani L, Saggiorato E, Guidobaldi L, Romanelli F, Ventura C, Laurenti O, Messuti I, Solaroli E, Madaio R, Bongiovanni M, Orlandi F, Crescenzi A,

- Valabrega S, Giovanella L. Calcitonin measurement in aspiration needle washout fluids has higher sensitivity than cytology in detecting medullary thyroid cancer: a retrospective multicentre study. *Clin Endocrinol*. 2014;80(1):135–140. DOI: 10.1111/cen.12234.
- [12] Elisei R, Romei C, Cosci B, Agate L, Bottici V, Molinaro E, Sculli M, Miccoli P, Basolo F, Grasso L, Pacini F, Pinchera A. RET genetic screening in patients with medullary thyroid cancer and their relatives: experience with 807 individuals at one center. *J Clin Endocrinol Metab*. 2007;92(12):4725–4729. DOI: 10.1210/jc.2007-1005.
- [13] Machens A, Hinze R, Thomusch O, Dralle H. Pattern of nodal metastasis for primary and reoperative thyroid cancer. *World J Surg*. 2002;26(1):22–28. DOI: 10.1007/s00268-001-0176-3.
- [14] Modigliani E, Cohen R, Campos JM, Conte-Devolx B, Maes B, Boneu A, Schlumberger M, Bigorgne JC, Dumontier P, Leclerc L, Corcuff B, Guilhem I. Prognostic factors for survival and for biochemical cure in medullary thyroid carcinoma: results in 899 patients. *Clin Endocrinol*. 1998;48(3):265–273. DOI: 10.1046/j.1365-2265.1998.00392.x.
- [15] Moley JF, DeBenedetti MK. Patterns of nodal metastases in palpable medullary thyroid carcinoma: recommendations for extent of node dissection. *Ann Surg*. 1999;229(6):880–887.
- [16] Meijer JA, le Cessie S, van den Hout WB, Kievit J, Schoones JW, Romijn JA, Smit JW. Calcitonin and carcinoembryonic antigen doubling times as prognostic factors in medullary thyroid carcinoma: a structured meta-analysis. *Clin Endocrinol*. 2010;72(4):534–542. DOI: 10.1111/j.1365-2265.2009.03666.x.
- [17] Brierley J, Tsang R, Simpson WJ, Gospodarowicz M, Sutcliffe S, Panzarella T. Medullary thyroid cancer: analyses of survival and prognostic factors and the role of radiation therapy in local control. *Thyroid*. 1996;6(4):305–310.
- [18] Schwartz DL, Rana V, Shaw S, Yazbeck C, Ang KK, Morrison WH, Rosenthal DI, Hoff A, Evans DB, Clayman GL, Garden AS, Sherman SI. Postoperative radiotherapy for advanced medullary thyroid cancer-local disease control in the modern era. *Head Neck*. 2008;30(7):883–888. DOI: 10.1002/hed.20791.
- [19] Martinez SR, Beal SH, Chen A, Chen SL, Schneider PD. Adjuvant external beam radiation for medullary thyroid carcinoma. *J Surg Oncol*. 2010;102(2):175–178. DOI: 10.1002/jso.21557.
- [20] Meijer JA, Bakker LE, Valk GD, de Herder WW, de Wilt JH, Netea-Maier RT, Schaper N, Fliers E, Lips P, Plukker JT, Links TP, Smit JA. Radioactive iodine in the treatment of medullary thyroid carcinoma: a controlled multicenter study. *Eur J Endocrinol*. 2013;168(5):779–786. DOI: 10.1002/jso.21557.
- [21] Tuttle RM, Haddad RI, Ball DW, Byrd D, Dickson P, Duh QY, Ehya H, Haymart M, Hoh C, Hunt JP, Iagaru A, Kandeel F, Kopp P, Lamonica DM, Lydiatt WM, McCaffrey J, Moley JF, Parks L, Raeburn CD, Ridge JA, Ringel MD, Scheri RP, Shah JP, Sherman

- SI, Sturgeon C, Waguespack SG, Wang TN, Wirth LJ, Hoffmann KG, Hughes M. Thyroid carcinoma, version 2.2014. *J Natl Compr Canc Netw*. 2014;12(12):1671–1680.
- [22] Nakayama Y, Inoue Y, Nagashima N, Katsuki T, Matsumoto K, Kadowaki K, Shibao K, Tsurudome Y, Hirata K, Sako T, Nagata N, Itoh H. Expression levels of thymidine phosphorylase (TP) and dihydropyrimidine dehydrogenase (DPD) in patients with gastrointestinal cancer. *Anticancer Res*. 2005;25(6A):3755–61.
- [23] Halperin DM, Phan AT, Hoff AO, Hoff AO, Aaron M, Yao JC, Hoff PM. A phase I study of imatinib, dacarbazine, and capecitabine in advanced endocrine cancers. *BMC Cancer*. 2014;14:561. DOI: 10.1186/1471-2407-14-561.
- [24] Lacin S, Esin E, Karakas Y, Yalcin S. Metastatic medullary thyroid cancer: a dramatic response to a systemic chemotherapy (temozolomide and capecitabine) regimen. *Onco Targets Ther*. 2015;8:1039–1042. DOI: 10.2147/OTT.S82906.
- [25] Agrawal N, Jiao Y, Sausen M, Leary R, Bettegowda C, Roberts NJ, Bhan S, Ho AS, Khan Z, Bishop J, Westra WH, Wood LD, Hruban RH, Tufano RP, Robinson B, Dralle H, Toledo SP, Toledo RA, Morris LG, Ghossein RA, Fagin JA, Chan TA, Velculescu VE, Vogelstein B, Kinzler KW, Papadopoulos N, Nelkin BD, Ball DW. Exomic sequencing of medullary thyroid cancer reveals dominant and mutually exclusive oncogenic mutations in RET and RAS. *J Clin Endocrinol Metab*. 2013;98(2):E364–E369. DOI: 10.1210/jc.2012-2703.
- [26] Fallahi P, Di Bari F, Ferrari SM, et al. Selective use of vandetanib in the treatment of thyroid cancer. *Drug Des Devel Ther*. 2015;9:3459–3470. DOI: 10.2147/DDDT.S72495.
- [27] Roy S, Narang BK, Rastogi SK, Rawal RK. A novel multiple tyrosine-kinase targeted agent to explore the future perspectives of anti-angiogenic therapy for the treatment of multiple solid tumors: cabozantinib. *Anticancer Agents Med Chem*. 2015;15(1):37–47. DOI: 10.2174/1871520614666140902153840.
- [28] Wells SA Jr, Gosnell JE, Gagel RF, et al. Vandetanib for the treatment of patients with locally advanced or metastatic hereditary medullary thyroid cancer. *J Clin Oncol*. 2010;28(5):767–772. DOI: 10.1200/JCO.2009.23.6604.
- [29] Fox E, Widemann BC, Chuk MK, et al. Vandetanib in children and adolescents with multiple endocrine neoplasia type 2B associated medullary thyroid carcinoma. *Clin Cancer Res*. 2013;19(15):4239–4248. DOI: 10.1158/1078-0432.CCR-13-0071.
- [30] Wells SA Jr, Robinson BG, Gagel RF, Dralle H, Fagin JA, Santoro M, Baudin E, Elisei R, Jarzab B, Vasselli JR, Read J, Langmuir P, Ryan AJ, Schlumberger MJ. Vandetanib in patients with locally advanced or metastatic medullary thyroid cancer: a randomized, double-blind phase II trial. *J Clin Oncol*. 2012;30(2):134–141. DOI: 10.1200/JCO.2011.35.5040.
- [31] Werner RA, Schmid JS, Muegge DO, Lücknerath K, Higuchi T, Hänscheid H, Grelle I, Reiners C, Herrmann K, Buck AK, Lapa C. Prognostic value of serum tumor markers

- in medullary thyroid cancer patients undergoing vandetanib treatment. *Medicine (Baltimore)*. 2015;94(45):e2016. DOI: 10.1097/MD.0000000000002016.
- [32] Cabanillas ME, Hu MI, Jimenez C. Medullary thyroid cancer in the era of tyrosine kinase inhibitors: to treat or not to treat-and with which drug-those are the questions. *J Clin Endocrinol Metab*. 2014;99(12):4390–4396. DOI: 10.1210/jc.2014-2811.
- [33] Chrisoulidou A, Mandanas S, Margaritidou E, Mathiopoulou L, Boudina M, Georgopoulos K, Pazaitou-Panayiotou K. Treatment compliance and severe adverse events limit the use of tyrosine kinase inhibitors in refractory thyroid cancer. *Onco Targets Ther*. 2015;8:2435–2442. DOI: 10.2147/OTT.S86322.
- [34] Robinson BG, Paz-Ares L, Krebs A, Vasselli J, Haddad R. Vandetanib (100 mg) in patients with locally advanced or metastatic hereditary medullary thyroid cancer. *J Clin Endocrinol Metab*. 2010;95(6):2664-2671. DOI: 10.1210/jc.2009-2461.
- [35] Antonelli A, Ferrari SM, Fallahi P, Berti P, Materazzi G, Marchetti I, Ugolini C, Basolo F, Miccoli P, Ferrannini E. Evaluation of the sensitivity to chemotherapeutics or thiazolidinediones of primary anaplastic thyroid cancer cells obtained by fine-needle aspiration. *Eur J Endocrinol*. 2008;159(3):283–291. DOI: 10.1530/EJE-08-0190.
- [36] Elisei R, Schlumberger MJ, Müller SP, Schöffski P, Brose MS, Shah MH, Licitra L, Jarzab B, Medvedev V, Kreissl MC, Niederle B, Cohen EE, Wirth LJ, Ali H, Hessel C, Yaron Y, Ball D, Nelkin B, Sherman SI. Cabozantinib in progressive medullary thyroid cancer. *J Clin Oncol*. 2013;31(29):3639–3646. DOI: 10.1200/JCO.2012.48.4659
- [37] Klein Hesselink EN, Steenvoorden D, Kapiteijn E, Corssmit EP, van der Horst-Schrivers AN, Lefrandt JD, Links TP, Dekkers OM. Therapy of endocrine disease: response and toxicity of small-molecule tyrosine kinase inhibitors in patients with thyroid carcinoma: a systematic review and meta-analysis. *Eur J Endocrinol*. 2015;172(5):R215–R225. DOI: 10.1530/EJE-14-0788.
- [38] Kurzrock R, Sherman SI, Ball DW, Forastiere AA, Cohen RB, Mehra R, Pfister DG, Cohen EE, Janisch L, Nauling F, Hong DS, Ng CS, Ye L, Gagel RF, Frye J, Müller T, Ratain MJ, Salgia R. Activity of XL184 (cabozantinib), an oral tyrosine kinase inhibitor, in patients with medullary thyroid cancer. *J Clin Oncol*. 2011;29(19):2660–2666. DOI: 10.1200/JCO.2010.32.4145.
- [39] Weitzman SP, Cabanillas ME. The treatment landscape in thyroid cancer: a focus on cabozantinib. *Cancer Manag Res*. 2015;7:265–278. DOI: 10.2147/CMAR.S68373.
- [40] Baudry C, Paepegaey AC, Groussin L. Reversal of Cushing's syndrome by vandetanib in medullary thyroid carcinoma. *N Engl J Med*. 2013;369(6):584–586. DOI: 10.1056/NEJMc1301428.
- [41] De Castroneves LA, Negrão MV, de Freitas RM, Papadia C, Lima JV Jr, Fukushima JT, Simão EF, Kulcsar MA, Tavares MR, Jorge AA, de Castro G Jr, Hoff PM, Hoff AO.

- Sorafenib for the treatment of progressive metastatic medullary thyroid cancer: efficacy and safety analysis. *Thyroid*. 2016;26(3):414–419. DOI: 10.1089/thy.2015.0334.
- [42] Thomas L, Lai SY, Dong W, Feng L, Dadu R, Regone RM, Cabanillas ME. Sorafenib in metastatic thyroid cancer: a systematic review. *Oncologist*. 2014;19(3):251–258. DOI: 10.1634/theoncologist.2013-0362.
- [43] Carr LL, Mankoff DA, Goulart BH, Eaton KD, Capell PT, Kell EM, Bauman JE, Martins RG. Phase II study of daily sunitinib in FDG-PET-positive, iodine-refractory differentiated thyroid cancer and metastatic medullary carcinoma of the thyroid with functional imaging correlation. *Clin Cancer Res*. 2010;16(21):5260–5268. DOI: 10.1158/1078-0432.CCR-10-0994.
- [44] Cohen EE, Rosen LS, Vokes EE, Kies MS, Forastiere AA, Worden FP, Kane MA, Sherman E, Kim S, Bycott P, Tortorici M, Shalinsky DR, Liau KF, Cohen RB. Axitinib is an active treatment for all histologic subtypes of advanced thyroid cancer: results from a phase II study. *J Clin Oncol*. 2008;26(29):4708–4713. DOI: 10.1200/JCO.2007.15.9566.
- [45] Schlumberger M, Elisei R, Bastholt L, Wirth LJ, Martins RG, Locati LD, Jarzab B, Pacini F, Daumerie C, Droz JP, Eschenberg MJ, Sun YN, Juan T, Stepan DE, Sherman SI. Phase II study of safety and efficacy of motesanib in patients with progressive or symptomatic, advanced or metastatic medullary thyroid cancer. *J Clin Oncol*. 2009;27(23):3794–3801. DOI: 10.1200/JCO.2008.18.7815.
- [46] Schlumberger M, Jarzab B, Cabanillas ME, Robinson B, Pacini F, Ball DW, McCaffrey J, Newbold K, Allison R, Martins RG, Licitra LF, Shah MH, Bodenner D, Elisei R, Burmeister L, Funahashi Y, Ren M, O'Brien JP, Sherman SI. A phase II trial of the multitargeted tyrosine kinase inhibitor Lenvatinib (E7080) in advanced medullary thyroid cancer. *Clin Cancer Res*. 2016;22(1):44–53. DOI: 10.1158/1078-0432.CCR-15-1127.
- [47] Mancikova V, Inglada-Pérez L, Curras-Freixes M, de Cubas AA, Gómez Á, Letón R, Kersten I, Leandro-García LJ, Comino-Méndez I, Apellaniz-Ruiz M, Sánchez L, Cascón A, Sastre-Marcos J, García JF, Rodríguez-Antona C, Robledo M. VEGF, VEGFR3, and PDGFRB protein expression is influenced by RAS mutations in medullary thyroid carcinoma. *Thyroid*. 2014;24(8):1251–1255. DOI: 10.1089/thy.2013.0579.
- [48] Links TP, Verbeek HH, Hofstra RM, Plukker JT. Progressive metastatic medullary thyroid carcinoma: first- and second-line strategies. *Eur J Endocrinol*. 2015;172(6):R241–R251. DOI: 10.1530/EJE-14-0726.
- [49] Gild ML, Landa I, Ryder M, Ghossein RA, Knauf JA, Fagin JA. Targeting mTOR in RET mutant medullary and differentiated thyroid cancer cells. *Endocr Relat Cancer*. 2013;20(5):659–667. DOI: 10.1530/ERC-13-0085.
- [50] Schneider TC, de Wit D, Links TP, van Erp NP, van der Hoeven JJ, Gelderblom H, van Wezel T, van Eijk R, Morreau H, Guchelaar HJ, Kapiteijn E. Beneficial effects of the

- mTOR inhibitor everolimus in patients with advanced medullary thyroid carcinoma: subgroup results of a phase II trial. *Int J Endocrinol*. 2015;2015:348124. DOI: 10.1155/2015/348124.
- [51] Chougnet CN, Borget I, Leboulleux S, de la Fouchardiere C, Bonichon F, Criniere L, Niccoli P, Bardet S, Schneegans O, Zanetta S, Schwartz C, Drui D, Chauffert B, Rohmer V, Schlumberger M. Vandetanib for the treatment of advanced medullary thyroid cancer outside a clinical trial: results from a French cohort. *Thyroid*. 2015;25(4):386–391. DOI: 10.1089/thy.2014.0361.
- [52] Capdevila J, Iglesias L, Halperin I, Segura A, Martínez-Trufero J, Vaz MÁ, Corral J, Obiols G, Grande E, Grau JJ, Tabernero J. Sorafenib in metastatic thyroid cancer. *Endocr Relat Cancer*. 2012;19(2):209–216. DOI: 10.1530/ERC-11-0351.
- [53] De Souza JA, Busaidy N, Zimrin A, Seiwert TY, Villaflor VM, Poluru KB, Reddy PL, Nam J, Vokes EE, Cohen EE. Phase II trial of sunitinib in medullary thyroid cancer (MTC). *J Clin Oncol (Meeting Abstracts)*. 2010;28:5504.
- [54] Lim SM, Chang H, Yoon MJ, Hong YK, Kim H, Chung WY, Park CS, Nam KH, Kang SW, Kim MK, Kim SB, Lee SH, Kim HG, Na II, Kim YS, Choi MY, Kim JG, Park KU, Yun HJ, Kim JH, Cho BC. A multicenter, phase II trial of everolimus in locally advanced or metastatic thyroid cancer of all histologic subtypes. *Ann Oncol*. 2013;24(12):3089–3094. DOI: 10.1093/annonc/mdt379.
- [55] Maxwell JE, Sherman SK, O'Dorisio TM, Howe JR. Medical management of metastatic medullary thyroid cancer. *Cancer*. 2014;120(21):3287–3301. DOI: 10.1002/cncr.28858.
- [56] Iten F, Müller B, Schindler C, Rochlitz C, Oertli D, Mäcke HR, Müller-Brand J, Walter MA. Response to [90yttrium-Dota]-Toc treatment is associated with long-term survival benefit in metastasized medullary thyroid cancer: a phase II clinical trial. *Clin Cancer Res*. 2007;13(22 Pt 1):6696–6702. DOI: 10.1158/1078-0432.CCR-07-0935.
- [57] Behe M, Behr TM. Cholecystokinin-B (Cck-B)/gastrin receptor targeting peptides for staging and therapy of medullary thyroid cancer and other Cck-B receptor expressing malignancies. *Semin Nucl Med*. 2002;66(6):399–418. DOI: 10.1053/snuc.2002.31028.
- [58] Vaisman F, de Castro PH, Lopes FP, Kendler DB, Pessoa CH, Bulzico DA, de Carvalho Leal D, Vilhena B, Vaisman M, Carneiro M, Corbo R. Is there a role for peptide receptor radionuclide therapy in medullary thyroid cancer? *Clin Nucl Med*. 2015;40(2):123–127. DOI: 10.1097/RLU.0000000000000628.
- [59] Schott M, Seissler J, Lettmann M, Fouxon V, Scherbaum WA, Feldkamp J. Immunotherapy for medullary thyroid carcinoma by dendritic cell vaccination. *J Clin Endocrinol Metab*. 2001;86(10):4965–4969.
- [60] Cascone T, Morelli MP, Morgillo F, Kim WY, Rodolico G, Pepe S, Tortora G, Berrino L, Lee HY, Heymach JV, Ciardiello F. Synergistic anti-proliferative and pro-apoptotic activity of combined therapy with bortezomib, a proteasome inhibitor, with anti-

epidermal growth factor receptor (EGFR) drugs in human cancer cells. *J Cell Physiol.* 2008;217(1):290. DOI: 10.1002/jcp.21444.

- [61] Baudin E, Droz JP, Paz-Ares L, van Oosterom AT, Cullell-Young M, Schlumberger M. Phase II study of plitidepsin 3-hour infusion every 2 weeks in patients with unresectable advanced medullary thyroid carcinoma. *Am J Clin Oncol.* 2010;33(1):83–88. DOI: 10.1097/COC.0b013e31819fdf5e.
- [62] Kushchayeva Y, Jensen K, Recupero A, Costello J, Patel A, Klubo-Gwiedzinska J, Boyle L, Burman K, Vasko V. The HIV protease inhibitor nelfinavir down-regulates RET signaling and induces apoptosis in medullary thyroid cancer cells. *J Clin Endocrinol Metab.* 2014;99(5):734–745. DOI: 10.1210/jc.2013-3369.
- [63] Klubo-Gwiedzinska J, Jensen K, Costello J, Costello J, Patel A, Hoperia V, Bauer A, Burman KD, Wartofsky L, Vasko V. Metformin inhibits growth and decreases resistance to anoikis in medullary thyroid cancer cells. *Endocr Relat Cancer.* 2012;19(3):447–456. DOI: 10.1530/ERC-12-0046.
- [64] Couto JP, Almeida A, Daly L, Sobrinho-Simões M, Bromberg JF, Soares P. AZD1480 blocks growth and tumorigenesis of RET-activated thyroid cancer cell lines. *PLoS One.* 2012;7:4686. DOI: 10.1371/journal.pone.0046869.

IntechOpen

