

# We are IntechOpen, the world's leading publisher of Open Access books Built by scientists, for scientists

## 4,800

Open access books available

## 122,000

International authors and editors

## 135M

Downloads

Our authors are among the

## 154

Countries delivered to

## TOP 1%

most cited scientists

## 12.2%

Contributors from top 500 universities

**WEB OF SCIENCE™**Selection of our books indexed in the Book Citation Index  
in Web of Science™ Core Collection (BKCI)

Interested in publishing with us?  
Contact [book.department@intechopen.com](mailto:book.department@intechopen.com)

Numbers displayed above are based on latest data collected.  
For more information visit [www.intechopen.com](http://www.intechopen.com)



---

# Respiratory Management of the Newborn with an Omphalocele

---

Joanne Baerg, Arul Thirumoorthi and  
Andrew Hopper

Additional information is available at the end of the chapter

<http://dx.doi.org/10.5772/63735>

---

## Abstract

Despite advances in neonatal care, infants with omphalocele have a mortality rate ranging between 5% and 25%. Respiratory insufficiency is a common clinical challenge and an independent predictor of mortality in these infants. The causes of respiratory failure are diverse and are not well understood. This chapter discusses the unique aspects of respiratory management in omphalocele infants. The authors have chosen references in this chapter with appropriate sample size, variable comparisons, regression analyses, and documented median follow-up times. Omphalocele is rare; therefore, the case reports of chapter references have important information.

Omphalocele infants are sometimes born with inadequate lung volume to support survival. Prenatal predictors of pulmonary hypoplasia are discussed in the context of fetal magnetic resonance imaging (MRI) and postnatal clinical-radiologic correlation studies. Two recent retrospective articles explain the unique aspects of pulmonary hypertension in omphalocele infants and distinguish it from pulmonary hypoplasia. The avoidance of abdominal compartment syndrome at the time of omphalocele closure is discussed. Clinical strategies that improve the respiratory care of these infants, based on specific definitions and diagnoses, may reduce the high mortality rate.

**Keywords:** respiratory insufficiency, pulmonary hypoplasia, pulmonary hypertension, abdominal compartment syndrome, extracorporeal membrane oxygenator, delayed repair

## 1. Introduction

Omphalocele is a congenital ventral defect of the umbilical ring with herniation of the abdominal viscera. The reported incidence is 1 in 6000 live births [1]. If omphalocele is diagnosed in the first trimester, over 30% of fetuses die in utero [2, 3]. Despite advances in neonatal care, for live-born infants, the mortality rate remains between 5% and 25% [4].

Postnatal management includes protection of the herniated viscera, prevention of hypothermia, gastric decompression, and maintenance of cardiopulmonary stability [5].

Respiratory insufficiency at birth is reported as an independent predictor of mortality for infants with omphalocele, but the causes are diverse [1]. Respiratory insufficiency in neonates is generally defined as hypoxemia in room air with progressive respiratory and metabolic acidosis and the need for mechanical ventilation within 24 hours of birth [1].

In this chapter, giant and nongiant omphaloceles are compared, as giant omphalocele infants have a more complex postnatal course and more respiratory difficulties.

Prenatal predictors of postnatal respiratory failure and unique clinical care strategies are discussed. Pulmonary hypoplasia is defined. Historically, fetuses and infants with omphalocele are reported to have markedly reduced chest capacities. Recently, fetal magnetic resonance imaging (MRI) has expanded the understanding of decreased congenital lung volume in infants with omphaloceles. Clinical-radiologic correlation studies support the use of prenatal MRI to predict the degree of respiratory insufficiency observed in the postnatal period.

The contribution of major anomalies to respiratory difficulties is discussed.

Infants with omphalocele may have increased pulmonary vascular reactivity and pulmonary hypertension that increases the postnatal mortality risk. In this chapter, pulmonary hypoplasia and pulmonary hypertension are defined as distinct entities. The chapter emphasizes that the two diagnoses must be distinguished from each other in the clinical setting. Each has different clinical implications and care strategies.

The implications of congenital heart defects in omphalocele infants are explained. The roles and goals of assisted ventilation for respiratory insufficiency in omphalocele infants are expanded.

Since 2011, a small number of infants with omphalocele and respiratory insufficiency have required the extra-corporeal membrane oxygenator (ECMO) for respiratory failure. This chapter provides the first review of the Extra-corporeal Life Support Organization (ELSO, Ann Arbor, MI, USA) database for the causes of respiratory failure and outcomes in omphalocele infants placed on ECMO.

The timing of surgical repair and postoperative complications, such as compartment syndrome, delayed surgical closure techniques, and the implications of a ruptured omphalocele, are explained.

Pulmonary function abnormalities, chronic lung disease, the role of tracheostomy, the influence of gastroesophageal reflux disease (GERD), prematurity, and strategies to improve outcomes, are discussed.

## 2. Giant omphalocele

Giant omphalocele represents an important subset of omphalocele infants. Giant omphalocele is defined as an omphalocele defect containing greater than 75% liver in the sac, and/or a diameter greater than 5 cm [4, 6]. A nongiant omphalocele is generally defined as a defect with diameter less than 5 cm. Previous definitions that measured the defect in centimeters do not account for the differences in size and gestational age of infants.

The definition that giant omphalocele is a defect that contains greater than 75% liver in the sac is preferable and uniform [4]. Giant omphalocele is associated with poor prognosis in many studies. Giant omphalocele is often associated with a greater incidence of respiratory insufficiency, longer ventilator requirements, and an increased incidence of pulmonary hypoplasia and pulmonary hypertension [6, 7].

Infants with giant omphaloceles have significantly more neonatal morbidity. When large and small omphaloceles are compared, the median length of stay (47 vs. 10 days), median age at full enteral feeds (23 vs. 5 days), median duration of mechanical ventilation (23 vs. 7 days), and requirement of supplemental oxygen at 30 days of life (88% vs. 27%) are significantly longer for infants with giant omphaloceles [7].

Respiratory failure is the major cause of mortality in infants with giant omphaloceles [8]. In the neonatal period, these infants have significantly more pulmonary hypoplasia and pulmonary hypertension and therefore, more respiratory difficulties [4, 7, 9]. Lung preservation ventilation strategies are emphasized in infants with giant omphaloceles. The overall in-hospital mortality for infants with giant omphaloceles approaches 20% [6].

After the neonatal period, giant omphalocele infants have more chronic lung disease and gastroesophageal reflux. In contrast, small omphaloceles generally have a good prognosis when they are not associated with lethal malformations or congenital syndromes [5].

Most minor defects are closed primarily. Because of the preponderance for respiratory insufficiency in infants with giant omphaloceles, however, there is more controversy regarding closure techniques.

Infants with giant omphaloceles have suboptimal neurodevelopmental outcomes. Their difficult early course frequently includes hypoxia, acidosis, hypotension during delivery, a long duration of mechanical ventilation, infection, and prolonged hospitalization. These factors all compound and play a role in determining neurologic outcomes.

Giant omphalocele survivors tend to have more significant neurodevelopmental delay than children with other congenital anomalies such as congenital diaphragmatic hernia or congenital heart defects. They appear similar in their neurocognitive outcomes to preterm newborns

that develop severe bronchopulmonary dysplasia. This further emphasizes the importance of optimal respiratory management and an understanding of the goals of assisted ventilation for infants with giant omphaloceles [6].

### 3. Pulmonary hypoplasia and the role of fetal magnetic resonance imaging

Lung hypoplasia is defined as insufficient development of pulmonary airways, alveoli, and vessels [10]. Historically, plain chest radiographs of omphalocele infants revealed a narrow thorax and curved ribs. Measures of chest width and lung area were significantly smaller in giant omphalocele infants. Such abnormalities of lung growth may be the result of a deformation sequence in utero. The liver is displaced in giant omphaloceles and so does not mold the thoracic cage [11–13].

Subsequently, prenatal ultrasound was used to calculate observed/expected lung volumes for fetuses. Two-dimensional ultrasound measured the lung-to-thorax ratio and predicted pulmonary hypoplasia. However, some report the assessment as inaccurate [14]. Three-dimensional ultrasound has improved sensitivity in normal amniotic fluid volume but not oligohydramnios [15, 16].

Presently, fetal magnetic resonance imaging studies have established a curve of normal fetal lung volume values plotted against gestational age [17]. The measured fetal lung volume is divided by the expected mean fetal lung volume for a given gestational age or fetal body volume to obtain the observed/expected total fetal lung volume (O/E-TFLV) ratio [17].

Accurate measurement of fetal lung volume has important clinical applications. Fetal magnetic resonance imaging has shown that lung volumes are only 50% of the predicted values in some prematurely born omphalocele infants with large defects. Such infants have lower Apgar scores and require prolonged ventilator support [18].

When infants with congenital lung malformations (CLMs), congenital diaphragmatic hernias (CDHs), or omphaloceles and an O/E-TFLV of 40% to 60% are compared, the need for ECMO, the use of supplemental oxygen at 30 days of life, and the 6-month mortality are similar among the three groups (**Table 1**) [19].

Variable	CDH <i>n</i> = 27	Omphalocele <i>n</i> = 13	CLM <i>n</i> = 16	<i>p</i> -value
Length of intubation, days median (IQR)	9.0 (7–17)	0 (0–6)*	0 (0–1.3)*	<0.001
Length of hospital stay, days median (IQR)	29.0 (22–55)	30.5 (15–47)	8.0 (3–20)*#	0.009

Variable	CDH <i>n</i> = 27	Omphalocele <i>n</i> = 13	CLM <i>n</i> = 16	<i>p</i> -value
Pulmonary HTN, <i>n</i> (%)	11/27 (40.7%)	0/13 (0%)*	0/16 (0%)*	0.001
Treatment of pulmonary HTN <i>n</i> (%)	7/27 (25.9%)	0/13 (0%)	0/16 (0%)*	0.014
iNO utilization <i>n</i> (%)	4/27 (14.8%)	0/13 (0%)	0/16 (0%)	0.099
ECMO <i>n</i> (%)	1/27 (3.7%)	0/13 (0%)	0/16 (0%)	0.579
Supplemental oxygen at 30 DOL <i>n</i> (%)	7/27 (25.9%)	3/13 (23.1%)	1/16 (6.3%)	0.274
Mortality at 6 months <i>n</i> (%)	0/27 (0%)	1/13 (7.7%)	0/16 (0%)	0.234

IQR: interquartile range; HTN: hypertension; iNO: inhaled nitric oxide; ECMO: extra-corporeal membrane oxygenation; supplemental O<sub>2</sub> at 30 DOL: supplemental oxygen at 30 days of life  
 \**p* < 0.05 vs. CDH.  
 †*p* < 0.05 vs. OM.

**Table 1.** Outcomes of congenital diaphragmatic hernia (CDH), omphalocele (OM), and congenital lung malformation (CLM) in infants with fetal lung volumes between 40% and 60% of predicted values [19].

In fetuses with CLM, an O/E-TFLV of less than 75% after 26 weeks predicts a difficult postnatal course that includes increased respiratory distress, a need for intubation, and lung mass excision [20].

Infants with CDH generally have O/E-TFLV measurements ranging from less than 25% to 45%. They require more pulmonary support than omphalocele and congenital lung malformation infants. Clinical-radiologic correlation studies support the use of prenatal MRI to predict the perinatal and postnatal courses in neonates with CDH. The measurements have also been used to guide the fetal therapy with improved postnatal results. Ratios less than 35% are associated with an increased use of ECMO and a higher mortality [21].

A series of infants with giant omphaloceles compare those with less than 50% to infants with greater than 50% O/E-TFLV at 26 to 31 weeks gestational age. Infants with less than 50% O/E-TFLV have significantly lower Apgar scores at birth, prolonged ventilation, and a longer hospitalization. MRI-based O/E-TFLV of less than 50% is considered predictive of increased postnatal morbidity in giant omphalocele infants [18].

A precise quantification of compromised fetal lung development in omphalocele infants may improve perinatal and postnatal management. Fetal magnetic resonance imaging after 26 weeks gestational age and calculation of the O/E-TFLV is recommended.

Similar to CDH and CLM, this calculation reflects pulmonary hypoplasia and allows clinicians to prepare for increased respiratory distress, a need for intubation after birth, and chronic ventilator support. Similar to CDH, further studies may prove that it prognosticates for ECMO use and for mortality. Detailed prenatal counseling and realistic expectations can be provided.

For infants that do not survive, lung-volume-to-body-weight ratios have been established for term and preterm infants [10]. Assessment of lung growth is a critical component of perinatal autopsy. One single series review reports lung biopsy or autopsy pathologic diagnosis of pulmonary hypoplasia or pulmonary hypertension in five omphalocele cases but does not expand on the precise histology details [7].

Fetal magnetic resonance lung volume curves and pathologic lung-volume-to-body-weight ratios for gestational age exist, but clinical-pathologic correlation studies are needed to further characterize pulmonary hypoplasia in infants with omphaloceles.

#### **4. The contribution of major anomalies**

Infants with major anomalies and omphaloceles have a longer duration of mechanical ventilation, hospital stay and a need for oxygen at 30 days of life. In a single-institution series of 82 live-born infants, 26% had chromosomal and 30% had major associated anomalies. None of the 19 live-born infants with an isolated defect died. Mortality, however, was 41% and 17% for those with major and minor anomalies, respectively [22].

The presence of associated anomalies is a strong predictor of morbidity and mortality, and anomalies are also linked to respiratory status [5, 16, 23].

Beckwith-Wiedemann syndrome is characterized by omphalocele, macroglossia, macrosomia, hypoglycemia, and embryonic tumors. It is a growth disorder due to dysregulation of the growth regulatory gene on chromosome 11p15 [23]. The presence of hypoglycemia in the perinatal period should alert the clinician to the possibility of Beckwith-Wiedemann syndrome.

The finding of omphalocele on a prenatal ultrasound should prompt a search for associated anomalies and possible further prenatal testing. In a large prenatal study of 445 fetuses with omphalocele, diagnosed in the first trimester, only 55 were live born. Over 85% died in utero due to the presence of fatal chromosomal anomalies [2, 3].

The presence of omphalocele indicates an increased risk of aneuploidy. In a recent first trimester study, fetuses with an omphalocele were found to carry a chromosomal abnormality in 55% of cases [16]. The most frequent abnormal karyotypes in omphalocele infants are Trisomy 18 and 13 [24]. Both have almost 100% incidence of congenital heart defects, including ventricular septal defect, atrial septal defect, and double outlet right ventricle. Infants with omphaloceles, in the setting of Trisomy 13 or 18 and a congenital heart defect, tend to have severe hemodynamic compromise.

In the setting of omphalocele and major anomalies, the cardiopulmonary support provided by the clinician is intensified [25].

Congenital diaphragmatic hernia is sporadically reported in conjunction with an omphalocele. Careful review of fetal MRI of the diaphragm may identify congenital diaphragmatic hernia. Conflicting reports exist, but generally pulmonary hypertension is profound and the outcome is poor [7, 26]. Elevated hemidiaphragms, diaphragmatic eventration, and congenital diaphragmatic hernia have been described in infants with giant omphaloceles, and could contribute to impaired lung development and postnatal distress [8, 11, 27].

## 5. Pulmonary hypertension

Previously, nonspecific respiratory insufficiency at birth was reported as an independent predictor of mortality for infants with omphaloceles. Older reports do not distinguish between pulmonary hypertension and pulmonary hypoplasia in their contribution to ventilation difficulties.

Pulmonary hypertension is now established as an independent predictor of mortality in infants with omphaloceles [28]. One recent series found that mortality was highest for live-born infants with omphaloceles diagnosed with pulmonary hypertension (45%), considerably higher than mortality in a cohort of infants with omphaloceles alone (18%) [29]. The contribution of pulmonary hypertension to respiratory insufficiency was previously unappreciated [28].

Pulmonary hypertension is diagnosed using echocardiography performed after the second day of life. Changes in the transitional circulation on the first day of life preclude evaluation for pulmonary hypertension by echocardiography. Directionality of flow through the ductus arteriosus is not considered in the diagnosis of pulmonary hypertension on the first day of life.

Pulmonary hypertension is defined on echocardiography as flattening of the interventricular septum during systole and/or a tricuspid regurgitant jet (TR) with an estimated right ventricular pressure greater than 40 mmHg when observed in the setting of hypoxemia [28, 30]. Qualitative measures of right-sided stress, as determined by the cardiologist interpreting the study, contribute to the assessment. These are right ventricular dilation, right atrial enlargement, right ventricular hypertrophy, septal flattening, and pulmonary artery dilation [28, 30, 31].

The incidence of pulmonary hypertension is reported in 37 to 55% of infants with giant omphaloceles. It is more prevalent in infants with additional anomalies [28, 31]. The explanation, whether structural, oxygen tension related, genetic, or some other cause, remains unknown.

Pulmonary hypertension correlates to endpoints of pulmonary insufficiency, including duration of mechanical ventilation, requirement for high-frequency oscillator ventilation, need for tracheostomy, and reliance on oxygen at the time of discharge from neonatal intensive care unit [31].



Conflicting reports exist regarding the prognosis of infants with giant omphaloceles. Some have mild respiratory distress, achieve early feeding and undergo delayed fascial closure with good results [28]. In contrast, others report a high mortality rate in giant omphalocele infants, relating to the predominance of respiratory insufficiency and pulmonary hypertension.

Several retrospective studies suggest that there may be a direct relationship between giant defects and abnormal pulmonary vascular tone. Clinicians should not focus on the defect diameter, but recognize that respiratory insufficiency and pulmonary hypertension are the prognosticators to identify [8, 18, 32].

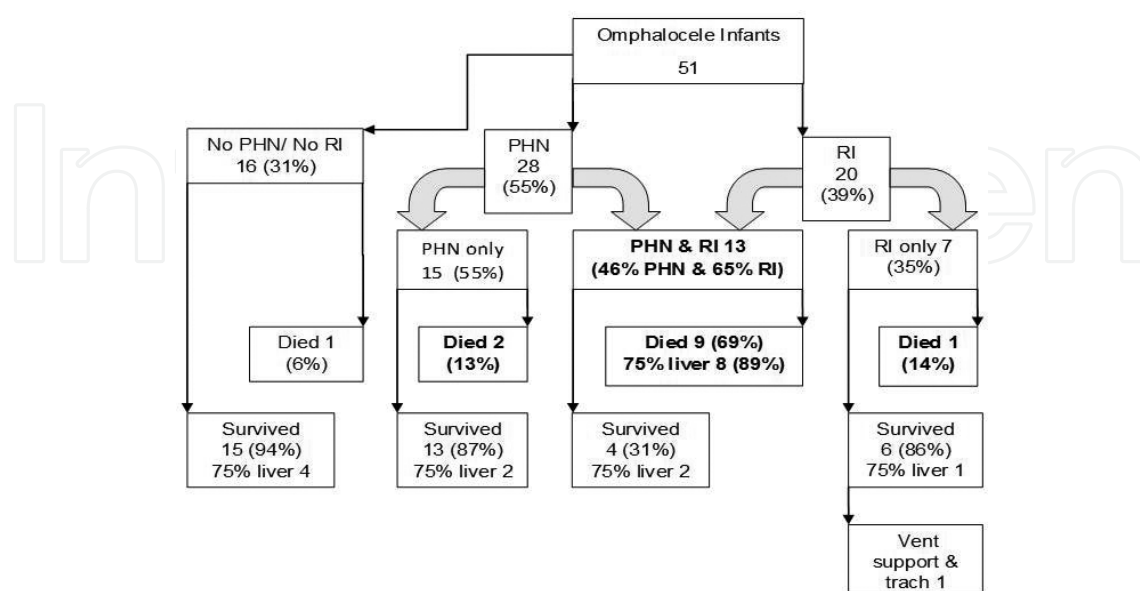
A recent multicenter retrospective review illustrates the distribution of respiratory insufficiency and pulmonary hypertension in 51 infants with omphalocele (**Figure 1**). All 51 had echocardiography performed between the day of life 2 and 7 [28].

Sixteen infants (31%) had no pulmonary hypertension and no respiratory insufficiency at birth. Of these, 15 survived (94%) and 1 died (6%).

Of the 51 infants (55%), 28 had pulmonary hypertension, and of these, 13 had respiratory insufficiency (46%) while 15 did not (54%).

Of the 51 (39%), 20 infants had respiratory insufficiency at birth without detectable pulmonary hypertension. Six of twenty (30%) were premature infants with a mean gestational age of 31.7 weeks.

Ninety-two percent of mortalities in the cohort were distributed among the infants with pulmonary hypertension, with or without respiratory failure, or respiratory failure without pulmonary hypertension. Of 38 survivors, one that initially presented with respiratory insufficiency, without pulmonary hypertension, progressed to chronic lung disease and required a tracheostomy and a long-term ventilator support. Of the 15 infants with isolated



**Figure 1.** The distribution of respiratory failure and pulmonary hypertension in 51 infants with omphaloceles.

pulmonary hypertension and no evidence of respiratory insufficiency, 13 survived (87%), and none required long-term ventilation (**Figure 1**).

Giant omphalocele defects containing 75% liver were closely associated with mortality. The distribution of 17 giant defects is illustrated among the cohort in **Figure 1**. Eight of seventeen (47%) died, and the eight deaths with giant defects were all distributed in the nine infant deaths that had a combination of pulmonary hypertension and respiratory failure at birth (89%). The distribution of the remaining giant defects is illustrated among the survivors (**Figure 1**) [28].

Logistic regression analysis further revealed that both respiratory insufficiency at birth (OR: 14.8; 95% CI: 2.5–85.0) and pulmonary hypertension diagnosed between days 2 and 7 of life (OR: 6.4; 95% CI: 1.1–39.0) were independently associated with mortality in infants with omphaloceles. This is a new and previously unappreciated finding.

A clinical care strategy that screens for pulmonary hypertension in omphalocele infants is recommended. Echocardiography is best performed between the second and seventh day of life to avoid examination during transitional circulation. Echocardiography should be performed at regular intervals until resolution or stabilization of pulmonary hypertension is demonstrated [28, 30].

The aims of pharmacotherapy for pulmonary hypertension are pulmonary vasodilation, restoration of normal endothelial function, and reversal of remodeling of the pulmonary vasculature. All of these therapies reduce right ventricular afterload and prevent right ventricular failure. Pulmonary vasodilation is needed acutely for pulmonary hypertension, but long-term therapy may focus on vascular remodeling. The main therapies for pulmonary hypertension emphasize the nitric oxide, prostacyclin, and endothelin pathways [33].

There are sporadic reports of the use of ventilator support with inhaled nitric oxide to treat omphalocele infants with pulmonary hypertension. However, detailed reports of lung function measurements before and after trials of inhaled nitric oxide that establish vascular reactivity are few [25]. The phosphodiesterase inhibitor and vasodilator, sildenafil, is administered with success in sporadic series.

After nitric oxide, sildenafil is considered the next-line therapy for pulmonary hypertension in infants, irrespective of etiology [31, 34]. Sildenafil generally improves the oxygenation index with minimal adverse effects in infants with pulmonary hypertension. Despite sildenafil, however, abnormal vascular tone does not necessarily resolve. One-quarter of giant omphalocele infants may require long-term vasodilator therapy with sildenafil [31].

We report one case of giant omphalocele treated with sildenafil and Bosentan. Echo performed at age 4 years shows that the pulmonary hypertension has completely resolved. Bosentan is an oral endothelin receptor antagonist that inhibits vascular remodeling and muscular thickening. Endothelin-1 is believed to play a role in the pathogenesis of neonatal pulmonary hypertension, and endothelin blockade augments pulmonary vasodilation in the perinatal lung. Several reports have shown that Bosentan provides benefit in the treatment of pulmonary hypertension in infants [33].

Selected fetuses may benefit from a maternal hyperoxia study prenatally to predict who will be at risk for elevated pulmonary vascular resistance and pulmonary hypertension, similar to prenatal evaluation in congenital diaphragmatic hernia [25, 35, 36].

The biology of neonatal pulmonary hypertension is linked to lung vascular growth modified by prenatal and early postnatal factors. The use of medical therapy to modify pulmonary hypertension in omphalocele infants is an important area of future study [37].

## 6. Congenital heart defects

The anterior abdominal wall develops between weeks 3 and 10 of fetal development. The process involves folding of the embryonic disk in cranio-caudal and lateral directions. By week 6 of fetal development, the elongated midgut herniates into the base of the umbilical cord due to lack of space in the abdominal cavity. By the tenth week, it rotates and returns to the abdomen. During this period, the cardiac tubes, which lie on the ventral surface of the embryo, are incorporated into the chest by the lateral folds. Errors in these critical steps of fetal development result in simultaneous anterior abdominal wall defects, such as omphalocele, and structural cardiac defects [25].

In general, a single- or multiinstitutional series of live-born infants with omphaloceles report a 30% incidence of structural congenital heart defects. Neonates with patent ductus arteriosus or patent foramen ovale are not considered to have a congenital heart defect.

A single-center retrospective series found that of 22 live-born omphalocele infants, 7 had evidence of a structural congenital heart defect, 4 of which developed pulmonary hypertension, and 1 of the 4 also had a dysplastic tricuspid valve. Only one infant required a surgical repair, and that infant presented with coarctation of the aorta [25]. The incidence of structural cardiac defects was lower than expected, and this was attributed to the low incidence of abnormal karyotypes.

Another recent multicenter series reports a congenital heart defect incidence in omphalocele infants of 30%, but all were nonductal-dependent lesions without hemodynamic compromise. None had cardiac failure [28].

Although structural cardiac defects should be specifically sought by echo in the first week of life, the influence of congenital heart defects on the outcome for omphalocele infants may be lower than expected, in particular if the cohort has normal karyotypes.

Although clinicians previously evaluated for congenital heart defects, they did not evaluate for pulmonary hypertension. Recent reports clarify that pulmonary hypertension likely has a greater influence on the outcome and mortality in omphalocele infants than congenital heart defects, unless Trisomy 13 or 18 is diagnosed.

In the setting of Trisomy 13 or 18, the incidence of congenital heart defects is over 90%. The most common defects are ventricular septal defect, atrial septal defect, and double outlet right ventricle.

The congenital heart defects of these chromosomal anomalies tend to present with hemodynamic compromise [25, 28, 38]. The establishment of regional and national databases for omphalocele would enhance the statistical understanding of the true incidence of congenital heart defects and hemodynamic compromise in omphalocele infants as few detailed reports with large sample size exist.

## 7. Respiratory insufficiency and assisted ventilation

Assisted ventilation may be necessary in neonates with omphalocele due to respiratory insufficiency from pulmonary hypoplasia, increased abdominal pressure following surgical repair, diaphragm dysfunction, and pulmonary hypertension [39]. The need for assisted ventilation may occur at delivery or may be confined to the immediate postoperative period related to increased intraabdominal pressure and upward displacement of the diaphragm following closure.

### 7.1. Goals of assisted ventilation

The goal of assisted ventilation in neonates with respiratory insufficiency due to omphalocele is to achieve adequate functional residual capacity to facilitate gas exchange. Assisted ventilation should be applied to maintain adequate lung volume with even distribution of tidal volume to avoid trauma from atelectasis and lung injury. If lungs with partial atelectasis are ventilated, the tidal volume entering only the open alveoli will lead to overexpansion of the relatively healthy portion of the lung with subsequent trauma due to overexpansion.

Additionally, atelectasis leads to vascular protein leak with increased surfactant inactivation and release of inflammatory mediators. Maintaining adequate lung volume is achieved by applying adequate positive end expiratory pressure (PEEP). There is no single optimal PEEP, and the level must be tailored to the degree of lung injury. For infants with healthy lungs and normal lung compliance, PEEP of 3–4 cm H<sub>2</sub>O may be appropriate. Excessive PEEP may lead to overexpansion of normal lungs with circulatory impairment and elevated cerebral venous pressure. However, poorly compliant lungs with atelectasis may transiently require higher PEEP, as high as 8–10 cm H<sub>2</sub>O or more, to achieve adequate alveolar recruitment and optimize ventilation/perfusion ratios [40].

For small omphaloceles, if primary abdominal closure has been accomplished, the majority of neonates will require mechanical ventilation for a few days postoperatively. During this time, the abdominal wall and bowel wall edema will improve, and the intraabdominal pressure will decrease.

The elective, routine use of mechanical ventilation to ensure primary closure in every instance is unwarranted. Short-term ventilator support, however, has been a welcomed adjunct to postoperative care and certainly has improved the outlook for these infants [41].

## 7.2. Noninvasive ventilation

Little information exists regarding the use of continuous positive airway pressure (CPAP) or positive end expiratory pressure (PEEP) in stabilizing the lungs of infants with omphaloceles. Positive end expiratory pressure has been used in premature infants to minimize the effect of excessively compliant chest wall and surfactant deficiency by stabilizing alveoli during the expiratory phase, and has been shown to help establish functional residual capacity.

Traditional management in neonates with omphalocele and respiratory insufficiency involves intubation and mechanical ventilation in the delivery room to presumably avoid further distention of bowel from air swallowing. However, nasal CPAP and/or nasal intermittent positive pressure ventilation may be a preferable approach to improve inadequate respiratory effort in these neonates, while avoiding the complications associated with endotracheal intubation [42].

The noninvasive approach offers the benefit of avoiding an endotracheal tube; therefore, reducing the incidence of ventilator-associated pneumonia and avoiding the contribution of postnatal inflammatory response to the development of bronchopulmonary dysplasia. Noninvasive ventilation reduces iatrogenic lung injury.

## 7.3. Conventional mechanical ventilation

Several modes of mechanical ventilation have been applied to neonates with omphalocele, but there is little evidence to guide clinicians in selecting the best method. Historically, pressure-controlled ventilation is the standard mode of ventilation in neonates with respiratory failure because of its wide availability, simplicity, ability to ventilate despite large endotracheal tube leak, and improved intrapulmonary gas distribution. However, pressure-controlled ventilation is limited, in that tidal volume varies with changes in lung compliance.

A rapid improvement in compliance may occur in the immediate postnatal period as a result of resorption of lung fluid, recruitment of optimal lung volume, and surfactant replacement therapy, leading to hyperventilation and trauma from excessive lung hyperexpansion [40].

Insufficient tidal volume may develop because of decreasing lung compliance, increasing airway resistance, airway obstruction, air trapping, and/or decreased spontaneous respiratory effort. Inadequate lung volume leads to hypercapnia, increased work of breathing and oxygen consumption, agitation, fatigue and atelectasis/atelectrauma. Low tidal volume leads to inefficient gas exchange due to increased dead space: tidal-volume ratio. Mechanical ventilation goals should include weaning toward extubation, as well as weaning supplemental  $\text{FiO}_2$ , in order to avoid oxygen toxicity that may contribute to chronic lung disease.

## 7.4. High-frequency ventilation

In selected infants with respiratory failure due to pulmonary hypoplasia and/or severe pulmonary hypertension, high-frequency ventilation may optimize lung inflation and improve gas exchange. High-frequency ventilation is beneficial as it reduces pressure and volume swings transmitted to the periphery of the lungs, and promotes gentle ventilation. For

optimal effectiveness, alveoli must be recruited and stabilized with the lowest possible mean airway pressure.

There is little information in the literature describing the effectiveness of high-frequency ventilation in neonates with omphalocele. In a large single-center series of giant omphalocele infants, mechanical ventilation maintains preductal oxygen saturation above 85% and high-frequency oscillatory ventilation is reserved for patients with refractory hypercapnia [41].

One report examines the use of high-frequency ventilation in 15 omphalocele infants after surgical closure. Of 15 infants, 11 had not required ventilation and were breathing room air prior to operation. High-frequency ventilation is reported as required in six infants (61%) within the first week in the intensive care unit after omphalocele closure. The remainder were managed with conventional ventilation. In half of the 15 infants, lung expansion on chest radiograph was reported at 50%.

The average mean airway pressure at days 5–7 for both the conventional ventilation group and the high-frequency group was 14 mmHg  $\pm$  3.0. Weaning from ventilation was achieved on day 7 in only five of the omphalocele infants. Six required ventilation until day 28. Four infants required tracheostomy and prolonged respiratory support between 330 and 1065 days [38]. Prolonged duration of mechanical ventilation and use of parenteral nutrition during this time period likely also contribute to an increased risk of infection.

Primary closure was the procedure of choice in this series. Despite the use of high-frequency ventilation, this series reports a slightly lower survival rate of 73%, compared to the studies with an emphasis on delayed closure that report survival rates of 80% or higher. They note that tension was described by the surgeon in three closures and may have contributed to postoperative difficulties. They note closure of the abdominal wall defect compromised pulmonary mechanics when increased intraabdominal pressure inhibited diaphragmatic movements as the viscera was reduced [38].

This study supports the existence of a degree of pulmonary hypoplasia and decreased pulmonary reserve in omphalocele infants that could only be overcome to a degree by high-frequency ventilation in some but not all of the infants that underwent early closure. It supports the use of delayed closure techniques and careful evaluation of abdominal-visceral disproportion and cardiopulmonary status prior to proceeding with operation [38].

## **8. Extra-corporeal membrane oxygenation (ECMO)**

Despite improvements in the management of respiratory insufficiency and pulmonary hypertension in infants, a number of infants with inadequate gas exchange are treated with extra-corporeal membrane oxygenation (ECMO). This includes infants with omphaloceles.

The authors retrospectively analyzed the Extra-corporeal Life Support Organization (ELSO, Ann Arbor, MI, USA) database between 1992 and 2015 for extra-corporeal membrane oxygenator (ECMO) use and omphalocele. ELSO membership consists of many major medical

centers worldwide, with the capability of placing infants on ECMO. This database would capture the majority of infants with omphaloceles, managed with ECMO, during the time period and provide the most of the information about the use of ECMO in these infants. The first infant with an omphalocele was placed on ECMO in 2011.

The specific diagnoses for respiratory insufficiency listed in the database are pulmonary hypertension, congenital heart defects, congenital diaphragmatic hernia, and sepsis. The recorded diagnoses for respiratory insufficiency in the 11 infants were isolated pulmonary hypertension in three; congenital heart defect and pulmonary hypertension in five (one of the five also had capillary alveolar dysplasia); congenital diaphragmatic hernia, congenital heart defect, sepsis, and pulmonary hypertension in one; and congenital diaphragmatic hernia and pulmonary hypertension in two infants.

The six congenital heart defects were double outlet right ventricle in two, Tetralogy of Fallot in one, ventricular septal defect in one, cor triatriatum in one, and aortic atresia/stenosis in one.

**Table 2** presents the demographic details and outcomes of 11 infants with omphaloceles placed on ECMO between 2011 and 2015.

	<b>Omphalocele</b> <b>N = 11</b>
First recorded ECMO run	2011
ECMO after day of life 3	8 (73%)
Gender (male)	7 (64%)
Weight at ECMO (kg) <sup>a</sup>	3.27 (2.5–10)
Age at ECMO (days) <sup>a</sup>	10 (0–351)
Run length (hours) <sup>a</sup>	193 (11–589)
A diagnosis of PHN	11 (100%)
Veno-arterial ECMO	10 (91%)
Discontinued from ECMO alive	7 (64%)
Discharged from hospital alive	2 (18%)

Data are expressed in number (%) except with (a) data are expressed in median (range).

**Table 2.** Omphalocele infants that underwent ECMO (2011–2015).

This is a small but significant series as it provides the only data available at present for omphalocele infants and the use of ECMO. The incidence of abnormal karyotypes is not reported with the database, so any association with Trisomy 13 or 18 is unknown.

For infants with omphaloceles that underwent ECMO, between 2011 and 2015 and reported in the ELSO database, the overall mortality was 80%. This high mortality rate contrasts to the reports from a large multicenter series of infants that underwent ECMO for pulmonary

hypertension and other conditions such as congenital diaphragmatic hernia between 2000 and 2010, where the mortality rate is 20% or better. These data support the need to better understand the underlying pathophysiology of pulmonary hypertension, so therapy can target its causes in omphalocele infants. There is overlap in the diagnoses of respiratory insufficiency in almost all cases of omphalocele placed on ECMO. Only a large study with multivariate analysis could determine the contribution of each diagnosis to respiratory failure and mortality in omphalocele infants.

One term infant with omphalocele, and respiratory insufficiency attributable to congenital heart defect and pulmonary hypertension, underwent lung biopsy after 10 days of ECMO support. The lung biopsy revealed capillary alveolar dysplasia. Extra-corporeal membrane oxygenation was withdrawn due to the fatal prognosis.

This solitary report raises questions about the etiology of persistent pulmonary hypertension in some omphalocele infants. More autopsy studies and published reports after examination of omphalocele infant lungs may expand the understanding of the contribution of this disorder to pulmonary hypertension and mortality.

Clinically, capillary alveolar dysplasia cannot be distinguished from other syndromes that cause pulmonary hypertension. Histologically, it is characterized by paucity of capillaries adjacent to alveolar epithelium, immature alveolar development, and muscularization of arterioles. The distribution can be diffuse or patchy. The etiology and incidence of capillary alveolar dysplasia are unknown [43].

## 9. Surgical considerations

The aim of surgical management in infants with omphaloceles is to avoid an abrupt increase in the abdominal pressure that may impair ventilation. An omphalocele which is less than 4 cm in size may be suitable for primary repair after cardiopulmonary stabilization and assessment of anomalies. In contrast, if a giant omphalocele is closed too early, the intraabdominal volume may be insufficient to contain the organs [4, 5].

Immediate postoperative complications are compromise of venous return from a sudden increase in intra-abdominal pressure and cardiopulmonary instability from decreased diaphragmatic excursion. The result is abdominal compartment syndrome (ACS) [38, 39].

Compartment syndrome due to increased intraabdominal pressure is a serious complication after a difficult omphalocele reduction. Early series report a 12% incidence of complications, including acute hepatic congestion, renal failure, and bowel infarction [5, 6].

Before the impact of viscerio-abdominal disproportion (VAD) and abdominal compartment syndrome was understood, surgeons placed emphasis on operative closure. Between 1980 and 1995, in a series of 30 operative closures, about half were small defects and were closed primarily without complications [44].

The remainder were giant omphaloceles. Three underwent skin closure due to viscerio-abdominal disproportion. Thirteen underwent silo placement and were closed between 11 and



Complication	N (%)
Wound dehiscence	7 (24%)
Gastroesophageal reflux	5 (17%)
Hepatic hematoma	3 (10%)
Hepatic congestion	2 (6%)
Enterocutaneous fistula	2 (6%)
Bowel infarction	1 (3%)
Renal failure	1 (3%)

**Table 3.** Operative complications [44].

137 days. There were 14 serious complications in 13 infants. All were due to initial tight closure, and all were opened postoperatively. There was one postoperative death (**Table 3**).

No randomized studies show that intraabdominal pressure monitoring is beneficial, and therefore it is not used to guide closure in the operating room, but may have a role in the postoperative period. Continuous bladder pressure monitoring in the postoperative period does not prevent necrotizing enterocolitis, but maintaining abdominal pressure below 20 mmHg prevents renal failure [45].

Various closure techniques for giant omphalocele exist, including alloderm patch, vacuum-assisted closure, tissue expanders, silos, and other types of mesh materials [46, 47]. If the sac is intact, application of topical agents and dressing changes for initial nonoperative management of a giant omphalocele is recommended. This technique transitions to delayed closure [26]. Tension and intraabdominal compression increase morbidity and must be avoided during closure. If tension exists, then a silo or mesh must be used for coverage [38].

In two recent series, infants with giant omphaloceles underwent treatment of the sac with topical agents and delayed closure. The median age of repair was 10 months (range: 3.4–23.6 months) in one series and 215 days in the other. No repairs were opened postoperatively [4, 22]. Six-month survival was 80% in both the series, despite the fact that half of the delayed closure infants in one series met the criteria for pulmonary hypoplasia on fetal magnetic resonance imaging [22].

A recent series of 16 infants with giant omphaloceles achieved discharge and returned for delayed closure during an elective admission at a median of 14 months (range: 2–28 months). The median length of hospital stay for this elective admission was 4 days (range: 2–21 days). One of sixteen (6%) required unexpected prolonged ventilation and stayed in hospital for 21 days. Four (25%) required mesh as visceros-abdominal disproportion had not resolved [26].

When compared to the reports obtained from previous decades, surgeons wait 7–24 months longer before attempting closure of a giant omphalocele. Although no comparative studies exist, the concept of giant omphalocele closure has evolved over the last two decades [38, 39].

Most surgeons promote application of topical agents to the sac, followed by delayed closure. This approach allows improved respiratory status, fewer complications, and better outcomes

[1, 4, 22, 26]. The emphasis on closure has been replaced by a better appreciation of visceroperitoneal disproportion, abdominal compartment syndrome, and the connection between stable cardiopulmonary status and survival.

Clinicians should be aware, however, that even if closure succeeds, a 40–50% reduction in respiratory system compliance on the first and second postoperative days after closure of abdominal wall defects has been demonstrated, as well as a 38% reduction in forced vital capacity.

Mechanical ventilation, including high-frequency ventilation, may be required after delayed omphalocele closure [9, 26, 27].

### **9.1. Technique of delayed repair**

After birth, the application of topical povidone-iodine, silver sulfadiazine or bacitracin ointment and xeroform gauze to the omphalocele sac allows epithelialization. Epithelialization often occurs within 10 weeks [16]. During this time, the infant can begin intestinal feeding.

As the giant omphalocele infant grows, the visceroperitoneal disproportion gradually resolves, but the infant must be clinically monitored. Giant omphalocele infants with respiratory distress, pulmonary hypoplasia, pulmonary hypertension, or sepsis will require specific care strategies, until they meet the criteria for extubation. Surgical closure of the abdominal fascia is not a priority during this time period.

The respiratory status of some giant omphalocele infants improves to the point that they can be discharged, followed as an outpatient, and can return for elective closure [26]. When the omphalocele contents reduce manually into the abdominal cavity with ease, the body cavity is considered large enough to proceed with operative closure.

If the contents fit, the impact on venous return, renal perfusion, and diaphragmatic excursion is decreased. After operative closure, the majority of infants are extubated postoperatively, and the average length of hospital stay is 4 days. A minority of infants may have a longer ventilator time after closure (up to 21 days), and this can be difficult to predict [4, 26]. Parents should be informed of this possibility.

### **9.2. Ruptured omphalocele**

A ruptured omphalocele is defined as any disruption of the omphalocele sac membrane [48]. Rupture of the omphalocele sac is frequently reported as a poor prognosticator associated with sepsis and mortality. The goal of the pediatric surgeon is to cover the eviscerated organs.

Although disrupted, if enough sac exists, it can be successfully sutured together with absorbable sutures.

Successful reduction and coverage of a giant ruptured omphalocele are reported after silo placement and coverage with an absorbable mesh, followed by split thickness skin grafting [49]. Despite coverage, many infants die of respiratory insufficiency and infection [28].

A ruptured sac requires urgent surgical intervention, but only sporadic case reports exist that pertain to specific surgical management of a ruptured omphalocele.

Hemodynamic instability dominates the clinical course in infants with ruptured omphalocele. The majority of infants with ruptured omphalocele require at least  $80 \text{ ml}^{-1} \text{ kg}^{-1}$  volume expansion in the first 7 days of life [38]. Intestinal exposure results in increased water and heat loss. Manipulation and closure can result in losses into a third space that exacerbates hypovolemia.

Volume expansion to achieve a mean arterial pressure of 45 mmHg increases blood pressure and urine output. The use of renal dose dopamine is controversial, and benefits have not been confirmed in recent meta-analyses. High-dose norepinephrine should be avoided as it can exacerbate bowel ischemia and necrosis [38].

An infant with ruptured omphalocele requires surgical consultation to obtain organ coverage, but intensive cardiopulmonary support with features of sepsis and a high mortality rate will dominate the clinical course. The association between ruptured omphalocele, sepsis, and mortality is not well understood.

## 10. Long-term respiratory support

There is a potential need for ongoing mechanical ventilatory support after the neonatal period in neonates born with a giant omphalocele. Partridge observed high rates of reactive airways disease in giant omphalocele survivors that was significantly associated with pulmonary hypertension [31]. Neonates with giant omphalocele and pulmonary hypertension required increased respiratory support based on the significant increases in the duration of mechanical ventilation, requirement for high-frequency oscillatory ventilation and tracheostomy, with dependence on home oxygen therapy following hospital discharge [31].

Whether reactive airways disease is an innate characteristic of the airways of infants with pulmonary hypoplasia associated with giant omphalocele versus increased respiratory support requirements and sequelae of mechanical ventilation remains unclear.

Pulmonary function abnormalities have been described in giant omphalocele survivors, and include reduced mean forced vital capacity and forced expiratory volume on pulmonary function testing with significant bronchodilator responsiveness in almost half of all patients studied [31]. Long-term respiratory issues in infants with giant omphaloceles include asthma, recurrent infections, chronic lung disease, and bronchomalacia.

Prolonged respiratory insufficiency is a frequent complication of giant omphalocele and the major prognostic factor for infants without life-threatening malformations. Infants with giant omphaloceles may require support for respiratory insufficiency into their second year of life. This possibility should be discussed with their families.

Of 22 long-term survivors with giant omphaloceles in a prospective follow-up series, chronic lung disease exists in 40%, and 16% have a tracheostomy for prolonged ventilation at a mean

day of life 154 (median: 156 days; range: 100–204 days) [6]. Of six long-term survivors in a single retrospective series at 33.2 months (range: 20–70 months), three have asthma requiring medical therapy, two have recurrent infections, and one requires overnight continuous positive airway pressure (CPAP) at 20 months for bronchomalacia [4].

Not much data are reported about the indications of tracheostomy in neonates with giant omphalocele, although most retrospective series report a subset that required prolonged ventilation and tracheostomy placement, in general, 5–10% of infants in a series. In general, tracheostomies are placed to secure a safe airway for infants with protracted mechanical ventilation. The optimal timing for tracheostomy placement in these babies is unknown; however, severity of lung disease and problems of airway that preclude extubation are the most common indications.

There is no good evidence for deferring tracheostomy because infants are receiving high ventilator pressures. While high ventilator settings may be a concern that discourages consideration of tracheostomy placement, appropriate developmental interventions are nearly impossible to implement without placement of a tracheostomy in infants with an unstable artificial airway [50].

## 11. Gastroesophageal reflux disease (GERD)

In infants with omphaloceles, the incidence of gastroesophageal reflux disease (GERD) with associated esophagitis approaches 45% [51]. Gastroesophageal reflux disease is diagnosed at a median age of 7 months and is more prevalent in infants with giant defects. Infants with omphalocele and a large defect have a high incidence of GERD complicated by esophagitis during the first few years of life [51].

Frequently, the retrospective series reports infants with omphaloceles and GERD that fail medical therapy and undergo Nissen fundoplication [6].

Pulmonary function studies were performed on follow-up of 30 giant omphalocele infants at a median of 19 months. The studies performed were spirometry, fractional lung volume measurements, assessment of bronchodilator responsiveness and passive respiratory mechanics, to evaluate the nature and degree of pulmonary dysfunction in these survivors. The series reports lung volume restriction without obstruction, an increased likelihood of airway hyperresponsiveness and reduced compliance in almost 50% of the infants studied [31, 52]. Early recognition of pulmonary functional impairment may help develop targeted treatment strategies for these infants, and this may include evaluation and treatment for GERD.

Partridge reports similar high rates of reactive airways disease in giant omphalocele survivors. Follow-up pulmonary function study results are similar to those obtained for infants with congenital diaphragmatic hernia and bronchopulmonary dysplasia. There may be a common etiology between pulmonary hypoplasia and reactive airways disease. The same series of omphalocele infants also reports a 10% rate of Nissen fundoplication for symptomatic GERD.

Targeted treatment strategies are not well established, but GERD will exacerbate hyperactive airways and asthma. Evidence for GERD should be sought by pH probe studies or endoscopy to diagnose esophagitis in infants with omphaloceles. Contrast radiographs may also add information regarding the esophageal-gastric anatomy and the presence of GERD. Any contribution of GERD to airway responsiveness should decrease with appropriate medical and/or surgical therapy.

## 12. Prematurity

In the majority of series that examine outcomes in omphalocele infants and factors associated with mortality, when factors such as respiratory insufficiency, pulmonary hypertension, and measures of pulmonary hypoplasia are examined, the influence of prematurity (defined as an infant born before 37 weeks gestation) is rarely as preponderant as other respiratory comorbidities. In the first series that reported respiratory insufficiency as an independent predictor of mortality in omphalocele infants, respiratory insufficiency at birth was found to be independent of gestational age [1].

In a recent multicenter series of 51 infants that found pulmonary hypertension and respiratory insufficiency at birth were associated with mortality in omphalocele infants, the median gestational age was 38.2 weeks (range: 28.0–40.0 weeks) for survivors and 34.6 weeks (range: 29.0–40.4 weeks) for mortalities [28]. There was no significant difference in gestational age between survivors and nonsurvivors. Respiratory insufficiency and pulmonary hypertension were associated with mortality, independent of gestational age. Of seven infants with respiratory insufficiency at birth, but without evidence of pulmonary hypertension, six survived. None of the remaining 44 infants in the series were premature. There was no significant association between prematurity, respiratory insufficiency, and mortality that could be identified in these infants with omphaloceles [28].

In contrast, in one study from Porter, preterm birth complicated more than a third of omphalocele cases, and the only neonatal deaths occurred because of complications of prematurity [53]. This is an isolated report.

Another series reports that the presence of major anomalies was the most significant factor associated with pulmonary morbidity, independent of gestational age [19].

For the majority of series that examine the influence of various factors on respiratory insufficiency, morbidity, and mortality in omphalocele infants, the influence of prematurity is not as predominant as other factors. This is likely because the median gestational age for most series is closer to term as modern prenatal care and monitoring of high-risk pregnancies may prevent preterm birth. For infants that are premature, if there is no pulmonary hypertension or pulmonary hypoplasia, the modern neonatal care of premature infant lungs is now sophisticated to the point that an influence on mortality cannot be consistently identified in the retrospective series.

### 13. Conclusions

Despite advances in neonatal care, mortality rates for infants with omphaloceles remain between 5% and 25% [4]. In this chapter, the unique aspects of respiratory management in omphalocele infants and care strategies are discussed. The chapter emphasizes pulmonary hypoplasia as distinct from pulmonary hypertension. Pulmonary hypoplasia is defined as insufficient development of pulmonary airways, alveoli, and vessels. Fetal MRI after 26 weeks gestational age with calculation of the O/E-TFLV is recommended. A prenatal O/E-TFLV of less than 50% predicts lower Apgar scores and a longer duration of mechanical ventilation. It may eventually prognosticate for mortality.

Pulmonary hypertension is an independent predictor of mortality in omphalocele infants [28]. A relationship may exist between giant defects and abnormal pulmonary vascular tone. Respiratory insufficiency and pulmonary hypertension, not the defect diameter, are the prognosticators to identify [8, 18, 32]. We recommend echocardiography between days 2 and 7 of life to evaluate for pulmonary hypertension. After diagnosis, echocardiography should be performed at regular intervals, until stabilization is demonstrated [28, 30].

Assisted-ventilation concepts in omphalocele infants are similar for all neonates with respiratory compromise. Gentle ventilation, adequate gas exchange, and early extubation minimize adverse outcomes. A longer duration of ventilation is associated with chronic lung disease, sepsis, and neurodevelopmental impairment [6]. Infants with giant omphaloceles represent a subgroup that benefit from these concepts. They frequently have several comorbidities and a longer period of respiratory insufficiency after birth.

Review of the ELSO database reveals that for infants with omphaloceles requiring ECMO, between 2011 and 2015, the mortality is estimated at 80%. Clinicians should consider these results before recommending ECMO. The surgical approach for infants with omphaloceles has evolved over the last two decades. The emphasis on primary closure is now replaced by an appreciation of viscerο-abdominal disproportion and abdominal compartment syndrome [1, 4, 22, 26].

Respiratory management for infants with omphaloceles may be arduous. Application of specific definitions allows targeting of therapy and clinical strategies. A multidisciplinary approach by perinatology, pediatric surgery, and neonatology may allow comprehensive evaluation of respiratory status. Analysis of prenatal information followed by postnatal clinical correlation may improve the outcomes for infants with omphaloceles.

### Acknowledgements

The authors thank Douglas Deming, MD, for reviewing the manuscript.

## Author details

Joanne Baerg\*, Arul Thirumoorthi and Andrew Hopper

\*Address all correspondence to: jbaerg@llu.edu

Loma Linda University Children's Hospital, Loma Linda, CA, USA

## References

- [1] Tsakayannis DE, Zurakowski D, Lillehei CW. Respiratory insufficiency at birth: A predictor of mortality for infants and omphalocele. *J Pediatr Surg* 1996;31:1088–91.
- [2] Tassin M, Descriaud C, Elie C, et al. Omphalocele in the first trimester: Prediction of perinatal outcome. *Prenat Diagn* 2013;33:497–501.
- [3] Brantberg A, Blaas HG, Haugen SE, Eik-Nes SH. Characteristics and outcome of 90 cases of fetal omphalocele. *Ultrasound Obstet Gynecol* 2005;26:527–37.
- [4] Biard JM, Douglas Wilson R, Johnson MP, et al. Prenatally diagnosed omphaloceles: Short and long-term outcomes. *Prenat Diagn* 2004;24:434–9.
- [5] Mcnair C, Hawes J, Urquhart H. Caring for the newborn with an omphalocele. *Neonatal Netw* 2006;25:319–27.
- [6] Danzer E, Gerdes M, D'Agostino JA, et al. Prospective interdisciplinary follow-up of children with prenatally diagnosed giant omphalocele: Short-term neurodevelopmental outcome. *J Pediatr Surg* 2010;45:718–23.
- [7] Vachharajani AJ, Rao R, Keswani S, Mathur AM. Outcomes in exomphalos: An institutional experience. *Pediatr Surg Int* 2009;25:139–44.
- [8] Edwards EA, Broome S, Green S, et al. Long-term respiratory support in children with giant omphalocele. *Anaesth Intensive Care* 2007;35:94–8.
- [9] Dimitriou G, Greenough A, Giffin F, et al. Temporary impairment of lung function in infants with anterior abdominal wall defects who have undergone surgery. *J Pediatr Surg* 1996;31:670–2.
- [10] De Paepe ME, Shapiro S, Hansen K, Gundogan F. Postmortem lung volume/body weight standards for term and preterm infants. *Pediatr Pulmonol* 2014;49:60–6.
- [11] Hershenson MB, Brouillette RT, Klemka I, et al. Respiratory insufficiency in newborns with abdominal wall defects. *J Pediatr Surg* 1985;20:348–53.
- [12] Griscom NT, Driscoll SG. Radiography of stillborn fetuses and infants dying at birth. *AJR Am J Roentgenol* 1980;134:485–9.

- [13] Argyle JC. Pulmonary hypoplasia in infants with giant abdominal wall defects. *Pediatr Pathol* 1989;9:43–55.
- [14] Kamata S, Usul N, Sawai T, Nose K, Fukuawa M. Prenatal detection of pulmonary hypoplasia in giant omphalocele. *Pediatr Surg Int* 2008;24:107–11.
- [15] Prendergast M, Rafferty GF, Davenport M, et al. Three-dimensional ultrasound fetal lung volumes and infant respiratory outcome: A prospective observational study. *BJOG* 2011;118:608–14.
- [16] Prefumo F, Izzi C. Fetal abdominal wall defects. *Best Pract Res Clin Obstet Gynaecol* 2014;28:391–402.
- [17] Rypens F, Metens T, Rocourt N, et al. Fetal lung volume: Estimation at MR imaging—initial results. *Radiology* 2001;219:236–41.
- [18] Danzer E, Victoria T, Bebbington MW, et al. Fetal MRI calculated total lung volumes in the prediction of short-term outcome in giant omphalocele: Preliminary findings. *Fetal Diagn Ther* 2012;31:248–53.
- [19] Akinkuotu AC, Sheikh F, Cass DL, et al. Are all pulmonary hypoplasias the same? A comparison of pulmonary outcomes in neonates with congenital diaphragmatic hernia, omphalocele and congenital lung malformation. *J Pediatr Surg* 2015;50:55–9.
- [20] Zamora I, Sheikh F, Cassady C. Fetal MRI lung volumes are predictive of perinatal outcomes in fetuses with congenital lung masses. *J Pediatr Surg*. 2014;49:853–8.
- [21] Akinkuotu A, Cruz S, Abbas P, et al. Risk stratification for infants with CDH: Prenatal vs. postnatal predictors of outcome. *J Pediatr Surg* 2016;51:44–8.
- [22] Akinkuotu A, Sheikh F, Olutuye O, et al. Giant omphaloceles: Surgical management and perinatal outcomes. *J Surg Res* 2015;198:388–92.
- [23] Chen CP. Syndromes and disorders associated with omphalocele. *Taiwan J Obstet Gynecol* 2007;46:96–102.
- [24] Khalil A, Arnaoutoglou C, Pacilli M, et al. Outcome of fetal exomphalos diagnosed at 11-14 weeks gestation. *Ultrasound Obstet Gynecol* 2012;39:401–6.
- [25] Gibbin C, Touch S, Groth R, Berghella V. Abdominal wall defects and congenital heart disease. *Ultrasound Obstet Gynecol* 2003;21:334–7.
- [26] Lee SL, Beyer TD, Kim SS, et al. Initial nonoperative management and delayed closure for treatment of infants with giant omphaloceles. *J Pediatr Surg* 2006;41:1846–9.
- [27] Nakayama DK, Mutich R, Motoyama EK. Pulmonary dysfunction after primary closure of an abdominal wall defect and its improvement with bronchodilators. *Pediatr Pulmonol* 1992;12:174–80.
- [28] Baerg JE, Thorpe DL, Sharp NE, et al. Pulmonary hypertension predicts mortality in infants with omphalocele. *J Neonatal Perinat Med* 2016;8:333–8.



- [29] Corey K, Hornik C, Laughon M, et al. Frequency of anomalies and hospital outcomes in infants with gastroschisis and omphalocele. *Early Hum Dev* 2014;90:421–4.
- [30] Mourani P, Sontag M, Younoszai A, et al. Clinical utility of echocardiography for the diagnosis and management of pulmonary vascular disease in young children with chronic lung disease. *Pediatrics* 2008;121:317–25.
- [31] Partridge EA, Hanna BD, Panitch HB, et al. Pulmonary hypertension in giant omphalocele infants. *J Pediatr Surg* 2014;49:1767–70.
- [32] van Eijck FC, Hoogeveen YL, van Weel C, et al. Minor and giant omphalocele: Long-term outcomes and quality of life. *J Pediatr Surg* 2009;44:1355–9.
- [33] Steinhorn, RH. Diagnosis and treatment of pulmonary hypertension in infancy. *Early Hum Dev* 2013;89:865–74.
- [34] Archer SL, Michelakis ED. An evidence-based approach to the management of pulmonary arteriole hypertension. *Curr Opin Cardiol* 2006;21:385–92.
- [35] Rasanen J, Wood DC, Debbs R, et al. Reactivity of the human fetal circulation to maternal hyperoxygenation increases in the second half of pregnancy, a randomized study. *Circulation* 1998;97:257–62.
- [36] Broth RE, Wood DC, Rasanen J, et al. Prenatal prediction of lethal pulmonary hypoplasia: The hyperoxygenation test for pulmonary artery reactivity. *Am J Obstet Gynecol* 2002;187:940–5.
- [37] Abman S, Baker C, Gien J, et al. The Robyn Barst memorial lecture: Differences between fetal, newborn, and adult pulmonary circulations: Relevance for age-specific therapies. *Pulm Circ* 2014;4:424–40.
- [38] Aizenfisz S, Dauger S, Gondon E, et al. Gastroschisis and omphalocele: Retrospective study of initial postoperative management in the ICU. *Eur J Pediatr Surg* 2006;16:84–9.
- [39] Panitch H. Pulmonary complications of abdominal wall defects. *Pediatr Res* 2015;16:11–7.
- [40] Kezler M, Gizzi SA. Mechanical ventilation and bronchopulmonary dysplasia. *Bronchopulmonary dysplasia: An update. Clin Perinatol* 2015;42:781–96.
- [41] Christison-Lagay ER, Kelleher CM, Langer JC. Neonatal abdominal wall defects. *Semin Fetal Neonatal Med* 2011;16:164–72.
- [42] Moretti C, Gizzi C, Papoff P et al. Comparing the effects of nasal synchronized intermittent positive pressure ventilation (nSIPPV) and nasal continuous positive airway pressure (nCPAP) after extubation in very low birth weight infants. *Early Hum Dev* 1999;56:167–77.

- [43] Gerrits LC, De Mol AC, Bulten J, Van der Staak FH, Van Heijst AF. Omphalocele and alveolar capillary dysplasia: A new association. *Pediatr Crit Care Med* 2010;11:36–7.
- [44] Dunn J, Fonkalsrud E. Improved survival in infants with omphalocele. *Am J Surg* 1997;173:284–7.
- [45] Engum SA, Kogon B, Jensen E, et al. Gastric tonometry and direct intraabdominal pressure measuring in abdominal compartment syndrome. *J Pediatr Surg*. 2002;37:214–8.
- [46] Binet A, Gelas T, Jochault-Ritz S, et al. VAC therapy a therapeutic alternative in giant omphalocele treatment: A multicenter study. *J Plast Reconstr Aesthet Surg* 2013;66:373–5.
- [47] Barkat A, Shetty A, McKee J. A novel approach for the closure of challenging giant omphalocele. *J Pediatr Surg Case Rep* 2015;3:485–8.
- [48] Ledbetter DJ. Congenital abdominal wall defects and reconstruction in pediatric surgery: Gastroschisis and omphalocele. *Surg Clin North Am* 2012;92(3):713–27.
- [49] Yamagishi J, Takayasu H, Otani Y, et al. Visceral coverage with absorbable mesh followed by split-thickness skin graft in the treatment of ruptured giant omphalocele. *Pediatr Surg Int* 2007;23:199–201.
- [50] Mandy G, Malkar M, Welty SE, et al. Tracheostomy placement in infants with bronchopulmonary dysplasia: Safety and outcomes *Pediatr Pulmonol* 2013;48:245–9.
- [51] Koivusalo A, Rintala R, Lindahl H. Gastroesophageal reflux in children with congenital abdominal wall defects. *J Pediatr Surg* 1999;34:1127–9.
- [52] Danzer E, Hedrick H, Rintoul N, et al. Assessment of early pulmonary function abnormalities in giant omphalocele survivors. *J Pediatr Surg* 2012;47:1811–20.
- [53] Porter A, Benson CB, Hawley P, et al. Outcome of fetuses with a prenatal ultrasound diagnosis of isolated omphalocele. *Prenat Diag* 2009;29:668–73.

