

# We are IntechOpen, the world's leading publisher of Open Access books Built by scientists, for scientists

**4,800**

Open access books available

**122,000**

International authors and editors

**135M**

Downloads

Our authors are among the

**154**

Countries delivered to

**TOP 1%**

most cited scientists

**12.2%**

Contributors from top 500 universities



**WEB OF SCIENCE™**

Selection of our books indexed in the Book Citation Index  
in Web of Science™ Core Collection (BKCI)

Interested in publishing with us?  
Contact [book.department@intechopen.com](mailto:book.department@intechopen.com)

Numbers displayed above are based on latest data collected.

For more information visit [www.intechopen.com](http://www.intechopen.com)



---

# Brain Network Metabolic Changes in Patients with Parkinsonian Tremors

---

Hideo Mure, David Eidelberg and Satoshi Goto

Additional information is available at the end of the chapter

<http://dx.doi.org/10.5772/63159>

---

## Abstract

Functional neuroimaging and modern multivariate analysis techniques have greatly contributed to research into the pathophysiology, diagnosis, and new treatments of neurodegenerative diseases, such as Parkinson's disease (PD). The pathogenesis of PD symptoms, especially akinesia and rigidity, is associated with abnormalities of cortico-striato-pallido-thalamocortical circuits. Although a resting tremor is one of the cardinal features of PD, the pathophysiology underlying this symptom is unclear and is thought to differ from those of akinesia and rigidity. The application of network analyses to metabolic positron emission tomography scans of patients with PD has provided valuable information concerning functional neural connectivity and identified the patterns of covariance that are specific to the motor manifestations and many nonmotor features of the disease, such as cognitive dysfunction. Functional imaging methods have revealed PD-specific brain activation patterns, including a parkinsonian tremor-related network. Network-based algorithms might aid in the clinical diagnosis of patients with PD from early symptoms and provide objective evidence of treatment responses.

**Keywords:** parkinson's disease, tremor, metabolic brain networks, positron emission tomography, deep brain stimulation

---

## 1. Introduction

A resting tremor, which results from a striatal dopamine (DA) deficiency, is one of the most common motor symptoms of Parkinson's disease (PD). A tremor-dominant type of PD is exhibited by 36 to 49% of patients with PD [1]. Clinical and pathophysiological studies have

revealed that the PD tremor has distinct characteristics compared with other major parkinsonian signs, such as akinesia (bradykinesia) and rigidity [2, 3]. Studies that used the Unified Parkinson's Disease Rating Scale (UPDRS) have shown that the severity of patients' akinesia and rigidity symptoms correlates with the severity of striatal DA loss and the clinical progression of the disease, while the severity of their tremor did not [4–7]. Although levodopa therapy is still the gold standard in the treatment of PD, it is more effective on akinesia and rigidity symptoms than it is on tremor. Furthermore, patients with the tremor-dominant type of PD have a better prognosis compared to those with the akinesia-rigid type [8]. The thalamic ventral intermediate (Vim) nucleus is considered the optimal target for stereotactic intervention treatments of PD tremor. Indeed, ablation or deep brain stimulation (DBS) of the Vim nucleus effectively reduces PD tremor while it does not improve akinesia or rigidity.

To date, metabolic changes in the brain networks of patients with PD have been analyzed with a variety of neuroimaging techniques, including positron emission tomography (PET), single-photon emission computed tomography (SPECT), and functional magnetic resonance imaging (fMRI). Eidelberg and colleagues have applied multivariate analyses to [<sup>18</sup>F]fluorodeoxyglucose (FDG)-PET scans in their studies of the brain networks of patients with PD, and they found a PD-related pattern (PDRP) of spatial covariance. They showed that patients with PD exhibit increased metabolism in the thalamus, globus pallidus, pons, and primary motor cortex and decreased metabolism in the lateral premotor cortex, supplementary motor area (SMA), and parietal association area. Interestingly, the scores for the PDRP expression of the individual patients with PD correlated with their UPDRS motor subscores for akinesia and rigidity, but not with their subscores for tremor. These findings suggested that PD tremors might be associated with different patterns of activation in these regions compared to those observed in the PDRP. Mure et al. (2011) identified a discrete PD-related tremor pattern (PDTP) in the FDG-PET scans of a cohort of patients with tremor-dominant PD who had undergone DBS in the thalamic Vim nucleus. They analyzed the scans that were obtained when the patients were on- and off-stimulation with an Ordinal Trends/Canonical Variates Analysis, which is a within-subject, network-mapping, and algorithm-guided principal component analysis (PCA) method. They found that the PDTP topography was characterized by increased metabolism in the cerebellar dentate nucleus and primary cortex and, to a lesser degree, in the putamen. In contrast to the PDRP, the scores for the PDTP expression correlated with the tremor amplitudes and UPDRS motor scores for tremor, but not with the UPDRS motor scores for akinesia and rigidity. In addition, the PDTP was modulated more by Vim-DBS than by subthalamic DBS. Thus, these findings suggested that PD tremors might be mediated by a distinct metabolic network that primarily involves cerebello-thalamo-cortical pathways.

In this chapter, we introduce the recent advancements that have been made in neuroimaging research for elucidating the pathogenesis of PD tremor and other PD symptoms. In addition, we emphasize the importance of quantitative analyses of the PDTP and PDRP in the development of objective methods for precisely diagnosing PD and evaluating the effects of treatments on PD tremor.

## 2. Functional neuroimaging techniques: a brief overview

Functional neuroimaging is used in studies with the goal of elucidating the pathophysiology of neurological disorders. Representative functional neuroimaging techniques are fMRI, SPECT, and PET. The fMRI technique, which is employed more because injections of radiotracers are not required, measures changes in the relative amounts of deoxyhemoglobin in different regions of the brain. The interactions of deoxyhemoglobin with the water molecules surrounding blood vessels result in proton signals that produce blood-oxygenation-level-dependent (BOLD) contrast in the scans. Increases in regional blood flow result in relative decreases in deoxyhemoglobin and an increase in the BOLD signals. When neurons are active, the supply of oxygenated blood to the active region increases [9]. Thus, increases in BOLD signals are associated with local neuronal activity [9]. However, in contrast to imaging with radiotracers, fMRI has a poor signal-to-noise ratio, and its signals are difficult to quantify.

Radiotracer imaging techniques, such as PET and SPECT, are used to investigate the patterns of cerebral glucose metabolism, cerebral blood flow, and specific neurochemical systems. In general, even though SPECT imaging is less expensive and more widely available compared with PET imaging, PET has better spatial resolution and sensitivity. The most widely used PET radiotracer is FDG. Because FDG uptake reflects cerebral glucose metabolism, it is thought to measure regional synaptic activity [10]. [<sup>15</sup>O]-labeled water (H<sub>2</sub><sup>15</sup>O) PET can be used to quantify regional cerebral blood flow (rCBF). As described above, increases in rCBF are thought to reflect neuronal activity increases [9]. DAergic function can be evaluated by measuring the storage capability of presynaptic DA with [<sup>18</sup>F]-fluorodopa or presynaptic DA transporter binding with [<sup>123</sup>I]-iodine-123-beta-carbomethoxy-3 beta-(4-iodophenyl)tropane (CIT) and [<sup>18</sup>F]-fluoropropyl CIT. Postsynaptic DA receptors can also be assessed with [<sup>11</sup>C]-raclopride [11]. Given the prominent role of nigrostriatal pathology in PD, radioligand imaging of the DA system has been widely used in investigations of PD. However, many other neurochemical systems, such as the serotonergic, adrenergic, and cholinergic systems, can be examined with PET and SPECT imaging [12]. Because rCBF and cerebral metabolisms are affected in many neurodegenerative disorders, PET and SPECT imaging techniques have greatly contributed to the understanding of the abnormal brain circuitry underlying the pathophysiology of PD.

## 3. Metabolic network mapping

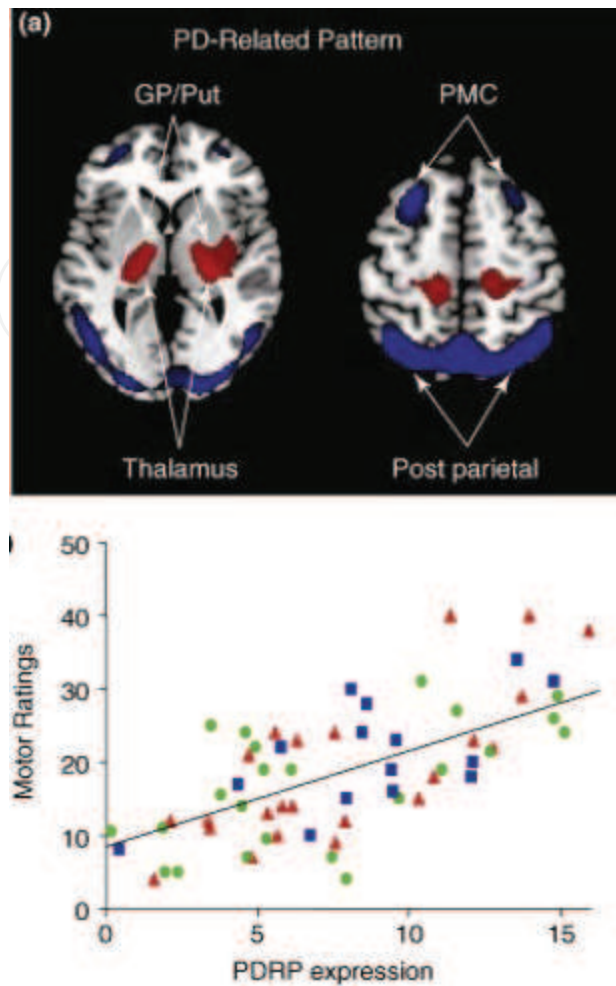
Network analyses of functional brain imaging data are an innovative approach for examining circuit abnormalities in neurodegenerative diseases. PD is related to the degeneration of nigral DAergic neurons, which also alters activity in the thalamus, pallidum, and cortex. These metabolic changes can be evaluated at the regional voxel level with standard univariate approaches, such as statistical parametric mapping [13]. Disease-related abnormalities in brain functional organization can also be assessed at the network level with multivariate analytical procedures. The Scaled Subprofile Model (SSM) is an innovative multivariate approach that is used to identify disease-specific brain networks [14]. SSM is a spatial covariance method that is based on a PCA and that is used to assess the subject-by-region effects in functional

brain images [15, 16]. The details of this method have been reviewed elsewhere [15–17]. Briefly, the SSM is applied to multivoxel metabolic imaging data in a combined sample of scans from healthy subjects and patients. Once a pattern is identified that distinguishes one group from the other, its expression can be prospectively quantified on an individual basis [18, 19], and the resulting subject scores can be correlated with clinical and physiological measures of interest. The SSM/PCA and related multivariate techniques are well suited to the study of circuit disorders, which are neurological diseases with stereotyped disturbances in brain network organization. Resting state measures of regional glucose utilization provide an index of local synaptic activity as well as of the biochemical maintenance processes that dominate this condition. The effects of pathology on these functions have a greater influence on regional cerebral metabolism and blood flow than physiological and/or hemodynamic factors do. It was recognized early in imaging research that neurodegenerative processes are associated with disease-specific alterations in functional connectivity across the whole brain. Therefore, network approaches have increasingly been used to analyze the metabolic imaging data from subjects with brain disorders, and these data have had a growing impact on imaging neuroscience.

## 4. Metabolic brain networks in PD

### 4.1. The PDRP

Presynaptic nigrostriatal DA loss is associated with abnormalities of the cortico-striato-pallido-thalamocortical (CSPTC) loops. Applications of the SSM/PCA method to resting-state FDG-PET scans of patients with PD have consistently revealed an abnormal disease-related spatial covariance pattern in the CSPTC loops and related pathways [15, 20, 21]. This PDRP is characterized by increased pallido-thalamic and pontine metabolism that is associated with relative reductions in the premotor cortex, SMA, and parietal association cortices (**Figure 1a**). The presence of the PDRP has been verified by its reproducibility in another independent PD cohort [22], and it has been associated with standardized motor ratings in multiple patient cohorts (**Figure 1b**) [23–25]. In general, PDRP expression has been found to correlate with clinical ratings of akinesia and rigidity, but not with tremor ratings. Interestingly, longitudinal increases in the pattern of expression correlate with progression in the motor disability ratings and concurrent PET measurements of presynaptic nigrostriatal DA function [26, 27]. In addition, the clinical outcomes of individual patients are associated with the degree of PDRP expression that is observed during subthalamic nucleus (STN)-targeted surgical interventions, including ablation therapy and DBS. Moreover, in patients with untreated PD, the PDRP expression scores that are determined with measures of cerebral perfusion in radiotracer imaging, such as  $H_2^{15}O$ -PET and  $99mTc$ -ethyl cysteinyl dimer SPECT, closely correlate with the corresponding network values that are computed from scans of cerebral glucose metabolism (i.e., FDG-PET) from the same cohort [22, 28]. Thus, PDRP expression can be measured in rCBF scans that are obtained by PET, SPECT, or perfusion-weighted MRI methods, such as the arterial spin labeling technique [29, 30].

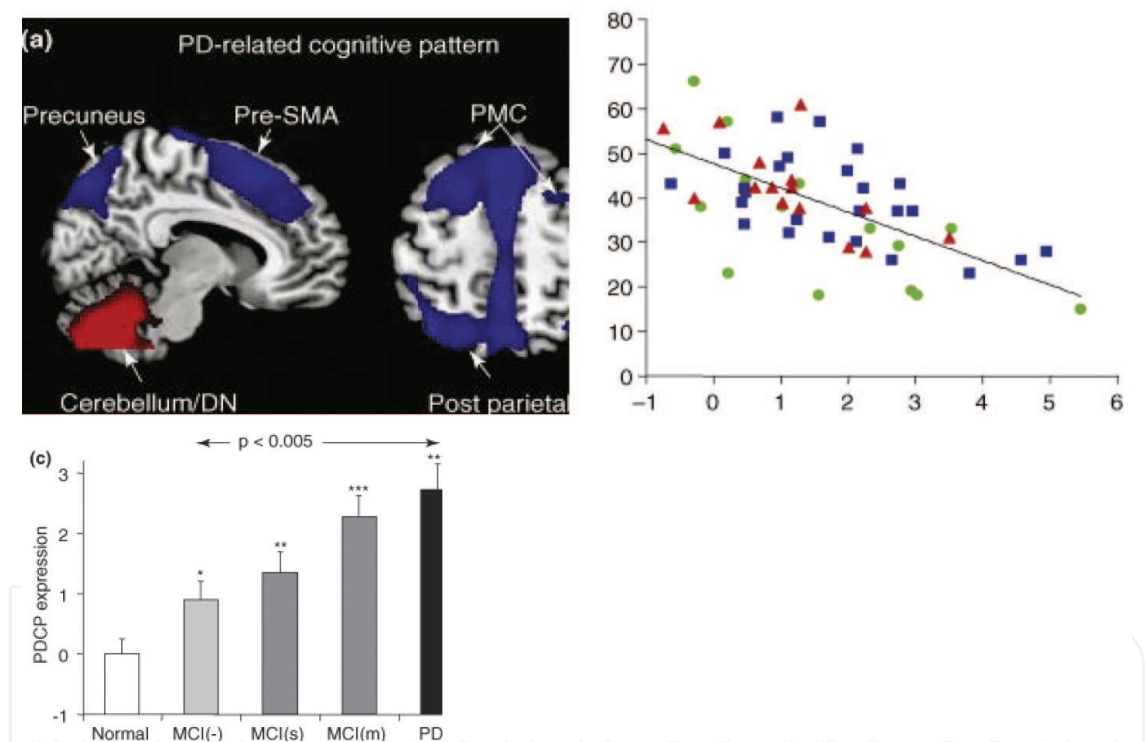


**Figure 1. Neuroimaging analysis on Parkinson's disease-related pattern.** (a) Parkinson's disease (PD)-related pattern (PDRP). This spatial covariance pattern of motor-related metabolism was identified by a multivariate analysis of [<sup>18</sup>F]fluorodeoxyglucose (FDG)-positron emission tomography (PET) scans from 33 patients with PD and 33 age-matched normal control subjects. This pattern is characterized by hypermetabolism (red) in the thalamus, globus pallidus (GP)/putamen (Put), pons, and primary motor cortex and relative metabolic reductions (blue) in the lateral premotor (PMC) and posterior parietal cortex. (b) The scores of the PDRP expression in the subjects correlated with the motor subscale scores on the Unified Parkinson's Disease Rating Scale (UPDRS) from a combination of patients with PD from three independent cohorts ( $n = 65$ ;  $r = 0.68$ ;  $p < 0.001$ ) [6, 23, 25]. (From Eidelberg D. Metabolic brain networks in neurodegenerative disorders: a functional imaging approach. *Trends Neurosci.* 2009;32:548-557, with permission from Elsevier).

#### 4.2. The PD-related cognitive pattern (PDCP)

Although PD is clinically defined by its motor features, nonmotor symptoms that involve cognitive dysfunction can appear, even in early clinical stages [31]. Mild cognitive impairment (MCI) in early PD typically involves visuomotor processing, working memory, and/or aspects of executive performance [32, 33]. A FDG-PET study revealed decreased glucose metabolism in the frontal and occipital cortices of patients with PD with and without apparent cognitive impairments [34]. After applying a SSM/PCA analysis to FDG-PET data from a

cohort of PD patients without dementia, Huang et al. identified a significant pattern of covariance that was related to cognitive performance [35]. This pattern, which was termed the PDCP, is characterized by metabolic decreases in the rostral SMA (pre-SMA), precuneus, and posterior parietal and prefrontal regions and increases in the dentate nucleus and cerebellar cortex (**Figure 2a**). The expression of PDCP in nondemented patients with PD correlates with the patients' ratings on neuropsychological tests of memory and executive functioning (**Figure 2b**). In addition, PDCP expression shows stepwise increases in accordance with worsening cognitive impairments (**Figure 2c**). In contrast to PDRP, the expression of PDCP is not modulated by antiparkinsonian motor symptom treatments, such as levodopa and DBS. Importantly, although both the PDRP and the PDCP increase in accordance with symptom duration, the rate of the increase in PDCP expression was slower than that of PDRP in the same subjects. These findings suggest that different neural systems underlie these two disease-related metabolic networks.



**Figure 2. Neuroimaging analysis on Parkinson's disease-related cognitive pattern.** (a) The PD-related cognitive pattern (PDCP). This spatial covariance pattern of cognition-related metabolism was identified by a network analysis of FDG-PET scans from 15 patients with nondemented PD [35]. This pattern is characterized by hypometabolism (blue) of the dorsolateral prefrontal cortex (PMC), rostral supplementary motor area (preSMA), precuneus, and posterior parietal regions and relative metabolic increases (red) in the dentate nucleus (DN) and cerebellar cortex. (b) The expression of PDCP correlates with the performances on neuropsychological tests of memory and executive functioning ( $r = -0.67$ ,  $p < 0.001$ ) of 56 patients with nondemented PD from two prospective validation groups and the original validation group [35]. (c) Bar graph of PDCP expression [mean  $\pm$  standard error of the mean (SE)] in patients with PD with dementia (PDD), multiple-domain mild cognitive impairment [MCI(m)], single-domain mild cognitive impairment [MCI(s)], patients with PD without mild cognitive impairment [MCI(-)], and normal subjects. PDCP expression differed significantly across the patient and control groups and among the PD groups. The asterisks indicate significant increases in PDCP expression compared to normal controls. (From Eidelberg D. Metabolic brain networks in neurode-

generative disorders: a functional imaging approach. *Trends Neurosci.* 2009;32:548-557, Copyright 2009, with permission from Elsevier).

## 5. Parkinsonian tremor and metabolic changes

### 5.1. Parkinsonian tremor

A resting tremor of 3–6 Hz is one of the cardinal features of PD that presents in 75 to 100% of patients during the course of the illness [36, 37]. The parkinsonian tremor is typically asymmetrical, at least initially, and it affects the upper limbs before involving the ipsilateral leg after about 2 years. Tremor of the lips, jaw, or tongue may also occur. Head or voice tremor is rare, which contrasts with observations of essential tremors. A postural tremor is also present in most cases, and it exhibits a wide range of severity [38]. However, kinetic tremor is uncommon [39]. An isolated lower-leg resting tremor is an uncommon symptom of neurological disease and an unusual presentation of PD, and such tremors are typically suspected to be caused by multiple system atrophy, psychogenic tremor, or drug-induced parkinsonism [40].

The pathophysiology of parkinsonian tremors is thought to be distinct from that of akinesia and rigidity [2, 3]. The clinical progression and mental status declines of patients with akinetic-rigidity-dominant PD are more rapid compared to patients with tremor-dominant PD [41]. Moreover, the loss of DAergic projections to the striatum correlates with the clinical ratings of bradykinesia and rigidity, but not with those of tremor [5, 42]. Indeed, DAergic therapy is less effective on parkinsonian tremor than it is on akinesia and rigidity.

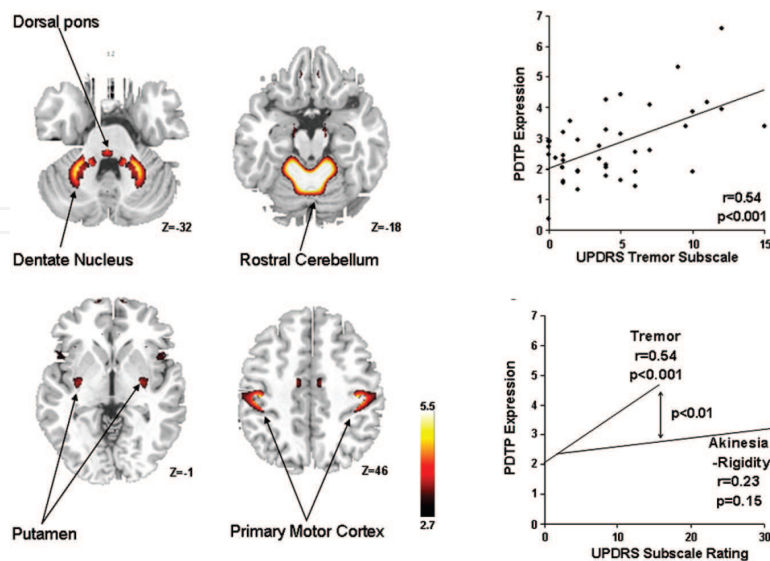
The Vim nucleus of the thalamus has commonly been recognized as the optimal surgical target for the treatment of tremors. Neurons in this region receive projections from the deep cerebellar nuclei and discharge in synchrony with parkinsonian tremors [43]. Given that PD tremors can be modulated by the lesioning of other brain regions, such as the pons and cerebellum, the Vim nucleus is considered one of a number of interconnected nodes in a spatially distributed tremor circuit. Nevertheless, the precise anatomical and functional network underlying tremors is still unclear, particularly with respect to the relative contributions of the basal ganglia and cerebellum to this pathway [3, 44–47].

### 5.2. The PDTP

In order to identify the PDTP, FDG-PET scans were acquired in patients with tremor-predominant PD who underwent Vim-DBS. The PDTP was identified with an ordinal trends/canonical variates analysis, which is a within-subject network-mapping algorithm that is based on PCA methods [48], by comparing scans that were conducted during Vim-DBS OFF (i.e., tremor present) and Vim-DBS ON (i.e., tremor suppressed) [7]. This pattern is characterized by increased activity in the cerebellum and dorsal pons, primary motor cortex, and caudate and putamen (**Figure 3a**). Unlike PDRP, prospectively computed PDTP correlates with accelerometer measurements of the tremors and UPDRS tremor subscale scores, but not with UPDRS bradykinesia-rigidity subscale ratings (**Figure 3b** and **3c**). Interestingly, Vim-DBS was

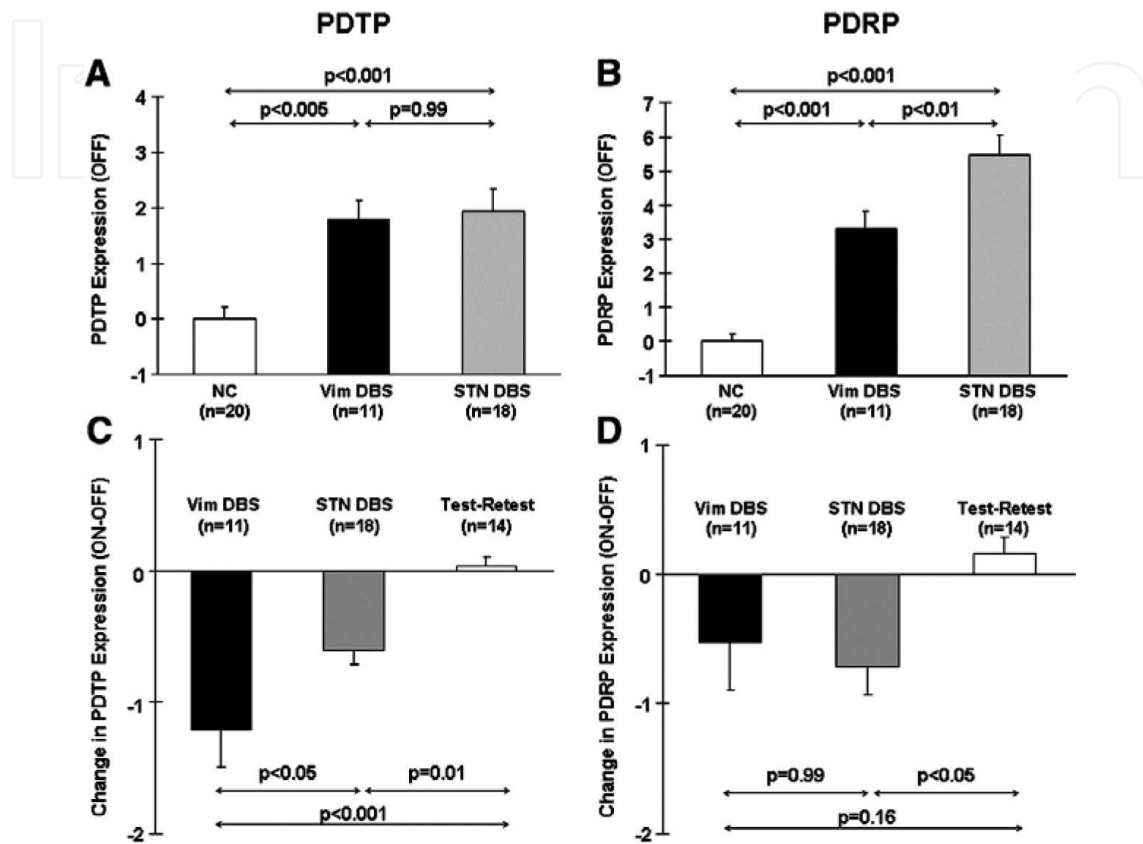


associated with changes in PDTP expression, but not PDRP expression. Although STN DBS decreased the activity in both networks, PDTP expression was reduced more by Vim than by STN stimulation (**Figure 4**). Moreover, while both the PDRP and the PDTP progressed over time, the rate of the PDTP increase was much slower than that of the PDRP. These findings suggest major differences between the tremor- and bradykinesia/rigidity-related brain networks in terms of their clinical correlates, treatment effects, and natural histories. The bradykinetic manifestations of PD have been associated with discrete functional abnormalities of the CSPTC pathways [49]. In contrast, tremor generation has been linked to abnormal activity in cerebello-thalamo-cortical pathways [44, 46, 47], and the role of the basal ganglia in the etiology of this symptom is still controversial [46, 50]. Indeed, prior  $H_2^{15}O$  PET imaging studies have shown that both the lesioning and the stimulation of the thalamic Vim nucleus results in localized reductions in neural activity in the primary motor cortex and anterior cerebellum [51, 52]. Moreover, a magnetoencephalography study revealed a tremor-coherent oscillatory network involving the primary motor cortex, thalamus, and cerebellum [47]. These findings give support to the suggestions that PDTP topography and the cerebello-thalamo-cortical circuit are associated with parkinsonian tremors. Interestingly, the PDTP topography includes a significant contribution from the striatum, although the contribution is less than those of the other nodes of this network. In the primate, the striatum receives cerebellar output through the ventrolateral and intralaminar thalamic nuclei [53]. In aggregate, the regional nodes of the PD tremor network may be defined by the abnormal synchronization of firing, which results in localized increases in synaptic activity and concomitant increases in glucose metabolism. While the tremor-related metabolic changes that are observed are most prominent in the primary motor cortex and thalamus, these PDTP regions interconnect through the thalamic Vim nucleus and putamen [7].



**Figure 3. Neuroimaging analysis on Parkinson's disease tremor-related pattern.** (a) PD tremor-related pattern (PDTP). This spatial covariance pattern was identified by an ordinal trends/canonical variate analysis of the FDG-PET data from nine patients with tremor-dominant PD who were scanned when they were on and off ventral intermediate nucleus (Vim) stimulation. The pattern is characterized by hypermetabolism in the primary motor cortex, anterior cer-

ebellum/dorsal pons, and putamen. (b) PDTP expression correlated with the UPDRS subscale ratings for tremor in 40 patients with PD ( $r = 0.54$ ,  $p < 0.001$ ). (c) The correlation of the PDTP scores with tremor was significantly greater in magnitude than that with the subscale ratings for akinesia-rigidity ( $p < 0.01$ ; multiple regression analysis). (From Mure H. et. al., Parkinson's disease tremor-related metabolic network: characterization, progression, and treatment effects. *Neuroimage*. 2011;54:1244-1253 Copyright 2011, with permission from Elsevier).



**Figure 4. Changed activity of the metabolic network as a result of deep brain stimulation (DBS) for parkinsonian tremor.** (a) Bar graphs showing the mean baseline PDTP expression ( $\pm$ SE) in patients who were treated with Vim-DBS (black), patients who were treated with subthalamic nucleus (STN) DBS (gray), and healthy control subjects (white). PDTP expression differed significantly across the three groups ( $p < 0.001$ ; one-way ANOVA), with comparable increases in the baseline expression in both the Vim-DBS ( $p < 0.005$ ) and STN DBS ( $p < 0.001$ ) groups relative to the controls. (b) The baseline PDRP expression also differed across the three groups ( $p < 0.001$ ), with higher expression in both treatment groups relative to the controls ( $p < 0.001$ ). Nonetheless, PDRP expression was higher in the STN DBS group than in the Vim-DBS group ( $p < 0.01$ ). (c) Treatment-mediated changes (ON-OFF) in PDTP expression ( $\pm$ SE) in the Vim-DBS patients (black), STN DBS patients (gray), and test-retest PD control subjects (white). The changes in PDTP expression differed across the three groups ( $p < 0.001$ ; one-way ANOVA), with stimulation-mediated declines in network activity in both DBS groups (Vim:  $p < 0.001$ ; STN:  $p = 0.01$ , relative to the test-retest control group). The PDTP changes were greater as a result of Vim stimulation compared with STN stimulation ( $p < 0.05$ ). (d) There was also a significant group difference in the treatment-mediated PDRP changes ( $p = 0.02$ ). The treatment-mediated reductions in PDRP expression were significant ( $p < 0.05$ ) after STN stimulation, but not after Vim stimulation ( $p = 0.16$ ). (From Mure H. et. al., Parkinson's disease tremor-related metabolic network: characterization, progression, and treatment effects. *Neuroimage*. 2011;54:1244-1253 Copyright 2011, with permission from Elsevier).

## 6. Concluding remarks

Neuroimaging study with the new multivariate network analysis is now used to elucidate the disease-related network abnormalities that involve the functional changes of certain brain regions in multiple neurodegenerative diseases. Particularly in PD, it has contributed to our understanding of the pathophysiology of the nigrostriatal dopaminergic system and of the non-dopaminergic system. Quantification of PD-related metabolic pattern could improve the accuracy and precision in diagnosing PD. Moreover, it also could provide an objective means of assessment of the PD therapies such as DBS.

## Acknowledgements

This work was supported in part by grants from the Ministry of Education, Culture, Sports, Science, and Technology of Japan (grants-in-aid for Scientific Research no. 24390223, 26461272, and 26430054).

## Author details

Hideo Mure<sup>1</sup>, David Eidelberg<sup>2</sup> and Satoshi Goto<sup>3\*</sup>

\*Address all correspondence to: sgoto@tokushima-u.ac.jp

1 Department of Neurosurgery, Institute of Biomedical Sciences, Graduate School of Medical Science, Tokushima University, Japan

2 Center for Neurosciences, Feinstein Institute for Medical Research, North Shore-LIJ Health System, USA

3 Department of Neurodegenerative Disorders Research, Institute of Biomedical Sciences, Graduate School of Medical Science, Tokushima University, Japan

## References

- [1] Stebbins GT, Goetz CG, Burn DJ, Jankovic J, Khoo TK, Tilley BC. How to identify tremor dominant and postural instability/gait difficulty groups with the movement disorder society unified Parkinson's disease rating scale: comparison with the unified Parkinson's disease rating scale. *Mov Disord.* 2013;28:668–670.
- [2] Fishman PS. Paradoxical aspects of parkinsonian tremor. *Mov Disord.* 2008;23:168–173.

- [3] Zaidel A, Arkadir D, Israel Z, Bergman H. Akineto-rigid vs. tremor syndromes in parkinsonism. *Curr Opin Neurol*. 2009;22:387–393.
- [4] Antonini A, Moeller JR, Nakamura T, Spetsieris P, Dhawan V, Eidelberg D. The metabolic anatomy of tremor in Parkinson's disease. *Neurology*. 1998;51:803–810.
- [5] Benamer HT, Oertel WH, Patterson J, Hadley DM, Pogarell O, Hoffken H, Gerstner A, Grosset DG. Prospective study of presynaptic dopaminergic imaging in patients with mild parkinsonism and tremor disorders: part 1. Baseline and 3-month observations. *Mov Disord*. 2003;18:977–984.
- [6] Eidelberg D, Moeller JR, Ishikawa T, Dhawan V, Spetsieris P, Chaly T, Robeson W, Dahl JR, Margouleff D. Assessment of disease severity in parkinsonism with fluorine-18-fluorodeoxyglucose and pet. *J Nucl Med*. 1995;36:378–383.
- [7] Mure H, Hirano S, Tang CC, Isaias IU, Antonini A, Ma Y, Dhawan V, Eidelberg D. Parkinson's disease tremor-related metabolic network: characterization, progression, and treatment effects. *Neuroimage*. 2011;54:1244–1253.
- [8] Jankovic J, McDermott M, Carter J, Gauthier S, Goetz C, Golbe L, Huber S, Koller W, Olanow C, Shoulson I, et al. Variable expression of parkinson's disease: a base-line analysis of the datatop cohort. The Parkinson study group. *Neurology*. 1990;40:1529–1534.
- [9] Raichle ME, Mintun MA. Brain work and brain imaging. *Annu Rev Neurosci*. 2006;29:449–476.
- [10] Eidelberg D, Moeller JR, Kazumata K, Antonini A, Sterio D, Dhawan V, Spetsieris P, Alterman R, Kelly PJ, Dogali M, Fazzini E, Beric A. Metabolic correlates of pallidal neuronal activity in parkinson's disease. *Brain*. 1997;120 (Pt 8):1315–1324.
- [11] Niccolini F, Su P, Politis M. Dopamine receptor mapping with pet imaging in Parkinson's disease. *J Neurol*. 2014;261:2251–2263.
- [12] Brooks DJ. Positron emission tomography and single-photon emission computed tomography in central nervous system drug development. *NeuroRx*. 2005;2:226–236.
- [13] Moeller JR, Habeck CG. Reciprocal benefits of mass-univariate and multivariate modeling in brain mapping: applications to event-related functional mri, h(2) (15)o-, and fdg-pet. *Int J Biomed Imaging*. 2006;2006:79862.
- [14] Moeller JR, Strother SC. A regional covariance approach to the analysis of functional patterns in positron emission tomographic data. *J Cereb Blood Flow Metab*. 1991;11:A121–135.
- [15] Eidelberg D. Metabolic brain networks in neurodegenerative disorders: a functional imaging approach. *Trends Neurosci*. 2009;32:548–557.
- [16] Spetsieris PG, Eidelberg D. Scaled subprofile modeling of resting state imaging data in Parkinson's disease: methodological issues. *Neuroimage*. 2011;54:2899–2914.

- [17] Habeck C, Stern Y. Multivariate data analysis for neuroimaging data: overview and application to Alzheimer's disease. *Cell Biochem Biophys*. 2010;58:53–67.
- [18] Ma Y, Eidelberg D. Functional imaging of cerebral blood flow and glucose metabolism in Parkinson's disease and Huntington's disease. *Mol Imaging Biol*. 2007;9:223–233.
- [19] Spetsieris PG, Ma Y, Eckert T, Dhawan V, Eidelberg D. New strategies for automated differential diagnosis of degenerative brain disorders. *Conf Proc IEEE Eng Med Biol Soc*. 2007;2007:3421–3425.
- [20] Eidelberg D, Moeller JR, Dhawan V, Spetsieris P, Takikawa S, Ishikawa T, Chaly T, Robeson W, Margouleff D, Przedborski S, et al. The metabolic topography of parkinsonism. *J Cereb Blood Flow Metab*. 1994;14:783–801.
- [21] Moeller JR, Nakamura T, Mentis MJ, Dhawan V, Spetsieris P, Antonini A, Missimer J, Leenders KL, Eidelberg D. Reproducibility of regional metabolic covariance patterns: comparison of four populations. *J Nucl Med*. 1999;40:1264–1269.
- [22] Ma Y, Tang C, Spetsieris PG, Dhawan V, Eidelberg D. Abnormal metabolic network activity in Parkinson's disease: test-retest reproducibility. *J Cereb Blood Flow Metab*. 2007;27:597–605.
- [23] Asanuma K, Tang C, Ma Y, Dhawan V, Mattis P, Edwards C, Kaplitt MG, Feigin A, Eidelberg D. Network modulation in the treatment of Parkinson's disease. *Brain*. 2006;129:2667–2678.
- [24] Feigin A, Antonini A, Fukuda M, De Notaris R, Benti R, Pezzoli G, Mentis MJ, Moeller JR, Eidelberg D. Tc-99m ethylene cysteinate dimer spect in the differential diagnosis of parkinsonism. *Mov Disord*. 2002;17:1265–1270.
- [25] Lozza C, Baron JC, Eidelberg D, Mentis MJ, Carbon M, Marie RM. Executive processes in Parkinson's disease: Fdg-pet and network analysis. *Hum Brain Mapp*. 2004;22:236–245.
- [26] Tang CC, Poston KL, Dhawan V, Eidelberg D. Abnormalities in metabolic network activity precede the onset of motor symptoms in Parkinson's disease. *J Neurosci*. 2010;30:1049–1056.
- [27] Huang C, Tang C, Feigin A, Lesser M, Ma Y, Pourfar M, Dhawan V, Eidelberg D. Changes in network activity with the progression of Parkinson's disease. *Brain*. 2007;130:1834–1846.
- [28] Hirano S, Asanuma K, Ma Y, Tang C, Feigin A, Dhawan V, Carbon M, Eidelberg D. Dissociation of metabolic and neurovascular responses to levodopa in the treatment of Parkinson's disease. *J Neurosci*. 2008;28:4201–4209.
- [29] Ma Y, Huang C, Dyke JP, Pan H, Alsop D, Feigin A, Eidelberg D. Parkinson's disease spatial covariance pattern: noninvasive quantification with perfusion mri. *J Cereb Blood Flow Metab*. 2010;30:505–509.

- [30] Melzer TR, Watts R, MacAskill MR, Pearson JF, Rueger S, Pitcher TL, Livingston L, Graham C, Keenan R, Shankaranarayanan A, Alsop DC, Dalrymple-Alford JC, Anderson TJ. Arterial spin labelling reveals an abnormal cerebral perfusion pattern in Parkinson's disease. *Brain*. 2011;134:845–855.
- [31] Caviness JN, Driver-Dunckley E, Connor DJ, Sabbagh MN, Hentz JG, Noble B, Evidente VG, Shill HA, Adler CH. Defining mild cognitive impairment in Parkinson's disease. *Mov Disord*. 2007;22:1272–1277.
- [32] Aarsland D, Bronnick K, Williams-Gray C, Weintraub D, Marder K, Kulisevsky J, Burn D, Barone P, Pagonabarraga J, Allcock L, Santangelo G, Foltynie T, Janvin C, Larsen JP, Barker RA, Emre M. Mild cognitive impairment in Parkinson disease: a multicenter pooled analysis. *Neurology*. 2010;75:1062–1069.
- [33] Mure H, Tang CC, Argyelan M, Ghilardi MF, Kaplitt MG, Dhawan V, Eidelberg D. Improved sequence learning with subthalamic nucleus deep brain stimulation: evidence for treatment-specific network modulation. *J Neurosci*. 2012;32:2804–2813.
- [34] Hosokai Y, Nishio Y, Hirayama K, Takeda A, Ishioka T, Sawada Y, Suzuki K, Itoyama Y, Takahashi S, Fukuda H, Mori E. Distinct patterns of regional cerebral glucose metabolism in Parkinson's disease with and without mild cognitive impairment. *Mov Disord*. 2009;24:854–862.
- [35] Huang C, Mattis P, Tang C, Perrine K, Carbon M, Eidelberg D. Metabolic brain networks associated with cognitive function in Parkinson's disease. *Neuroimage*. 2007;34:714–723.
- [36] Rajput AH, Rozdilsky B, Ang L. Occurrence of resting tremor in Parkinson's disease. *Neurology*. 1991;41:1298–1299.
- [37] Hughes AJ, Daniel SE, Blankson S, Lees AJ. A clinicopathologic study of 100 cases of Parkinson's disease. *Arch Neurol*. 1993;50:140–148.
- [38] Habibur R. Diagnosis and management of tremor. *Arch Intern Med*. 2000;160:2438–2444.
- [39] Kraus PH, Lemke MR, Reichmann H. Kinetic tremor in Parkinson's disease—an underrated symptom. *J Neural Transm (Vienna)*. 2006;113:845–853.
- [40] Hellmann MA, Melamed E, Steinmetz AP, Djaldetti R. Unilateral lower limb rest tremor is not necessarily a presenting symptom of Parkinson's disease. *Mov Disord*. 2010;25:924–927.
- [41] Hoon DS, Fujimoto A, Shu S, Taback B. Assessment of genetic heterogeneity in tumors using laser capture microdissection. *Methods Enzymol*. 2002;356:302–309.
- [42] Eidelberg D, Moeller JR, Ishikawa T, Dhawan V, Spetsieris P, Chaly T, Belakhlef A, Mandel F, Przedborski S, Fahn S. Early differential diagnosis of Parkinson's disease with 18f-fluorodeoxyglucose and positron emission tomography. *Neurology*. 1995;45:1995–2004.

- [43] Lenz FA, Kwan HC, Martin RL, Tasker RR, Dostrovsky JO, Lenz YE. Single unit analysis of the human ventral thalamic nuclear group. Tremor-related activity in functionally identified cells. *Brain*. 1994;117(Pt 3):531–543.
- [44] Volkmann J, Joliot M, Mogilner A, Ioannides AA, Lado F, Fazzini E, Ribary U, Llinas R. Central motor loop oscillations in parkinsonian resting tremor revealed by magnetoencephalography. *Neurology*. 1996;46:1359–1370.
- [45] Deuschl G, Raethjen J, Lindemann M, Krack P. The pathophysiology of tremor. *Muscle Nerve*. 2001;24:716–735.
- [46] Timmermann L, Florin E, Reck C. Pathological cerebral oscillatory activity in Parkinson's disease: a critical review on methods, data and hypotheses. *Expert Rev Med Devices*. 2007;4:651–661.
- [47] Timmermann L, Gross J, Dirks M, Volkmann J, Freund HJ, Schnitzler A. The cerebral oscillatory network of parkinsonian resting tremor. *Brain*. 2003;126:199–212.
- [48] Habeck C, Krakauer JW, Ghez C, Sackeim HA, Eidelberg D, Stern Y, Moeller JR. A new approach to spatial covariance modeling of functional brain imaging data: ordinal trend analysis. *Neural Comput*. 2005;17:1602–1645.
- [49] DeLong MR, Wichmann T. Circuits and circuit disorders of the basal ganglia. *Arch Neurol*. 2007;64:20–24.
- [50] Deuschl G, Raethjen J, Baron R, Lindemann M, Wilms H, Krack P. The pathophysiology of parkinsonian tremor: a review. *J Neurol*. 2000;247(Suppl. 5):V33–V48.
- [51] Deiber MP, Pollak P, Passingham R, Landais P, Gervason C, Cinotti L, Friston K, Frackowiak R, Mauguiere F, Benabid AL. Thalamic stimulation and suppression of parkinsonian tremor. Evidence of a cerebellar deactivation using positron emission tomography. *Brain*. 1993;116(Pt 1):267–279.
- [52] Fukuda M, Barnes A, Simon ES, Holmes A, Dhawan V, Giladi N, Fodstad H, Ma Y, Eidelberg D. Thalamic stimulation for parkinsonian tremor: correlation between regional cerebral blood flow and physiological tremor characteristics. *Neuroimage*. 2004;21:608–615.
- [53] Hoshi E, Tremblay L, Feger J, Carras PL, Strick PL. The cerebellum communicates with the basal ganglia. *Nat Neurosci*. 2005;8:1491–1493.