

We are IntechOpen, the world's leading publisher of Open Access books Built by scientists, for scientists

4,800

Open access books available

122,000

International authors and editors

135M

Downloads

Our authors are among the

154

Countries delivered to

TOP 1%

most cited scientists

12.2%

Contributors from top 500 universities



WEB OF SCIENCE™

Selection of our books indexed in the Book Citation Index
in Web of Science™ Core Collection (BKCI)

Interested in publishing with us?
Contact book.department@intechopen.com

Numbers displayed above are based on latest data collected.

For more information visit www.intechopen.com



Applications of the Buccal Fat Pad in Oral and Maxillofacial Surgery

Ali Hassani, Solaleh Shahmirzadi and Sarang Saadat

Additional information is available at the end of the chapter

<http://dx.doi.org/10.5772/63133>

Abstract

The buccal fat pad (BFP) has become more and more popular in oral and maxillofacial surgery. Originally, it was described as an anatomic structure without any obvious function; it was even considered to be a surgical nuisance. Nowadays, the most reported application of the BFP is the closure of oroantral communications. In this chapter, different aspects of the BFP such as its applications, anatomy, physiology, and complications are explained.

Keywords: buccal fat pad, oral reconstruction, oroantral communication, oroantral fistula, cleft palate, surgical defects

1. Introduction

Although descriptions of the buccal fat pad (BFP) are typically very brief and lacking in detail in anatomical textbooks, they have recently received increased attention in the clinical literature [1]. After the first clinical use of the BFP by Egyedi in 1977, its use has increased rapidly during these years. The BFP has become more and more popular for closing oronasal and oroantral communications (OACs) and as a versatile pedicle graft for closing postsurgical maxillary defects [2].

The BFP initially believed to be an anatomic structure without any noticeable function was even considered to be a surgical nuisance [3–5]. However, with time, the use of the BFP as a pedicle graft has become more common; the relatively easy use and [6–8] the location of the BFP are anatomically favorable and minimal dissection allows it to be harvested and mobilized; good rate of epithelialization and low rate of failure have made it the preferred option for oral and maxillofacial applications [7]. The repair of oroantral and oronasal defects, the repair of pathological or traumatic defects (especially in the posterior maxilla and palate), the repair of congenital cleft palate defects, use as a biologic membrane for covering bone grafts, and its application in temporomandibular joint surgery are some of its common applications that are addressed here in this chapter.

2. History

Heister et al. introduced the BFP for the first time in 1732. They believed that the newly introduced structure was glandular and named it “glandula molaris” [9, 10]. Bichat in 1802 described this anatomic mass and realized its true nature. Therefore, it is commonly referred to as the *boule de Bichat* or *bolle graisseuse* in French; it is called “*wangenfettpfropf*” or “*Wangenfettpolster*” (*Wangen* means cheek, *fett* means fat, and *polster* means pad) in German, and the sucking pad, sucking cushion, masticatory fat pad, or BFP in English [10]. Samman was the first to explain the anatomy of the BFP and Goughram completed his description [11]. BFP's clinical importance was not discovered for years and due to its sudden egression during the surgical operations, it was known more as a nuisance factor [3, 4]. Egyedi for the first time in 1977 reported the use of the BFP in the regeneration of oral defects [2]. Nader introduced the use of the BFP as a pedicle and free graft in two patients with trauma of facial structures, but there were no reports available on the vascularization and functional anatomy of the BFP [12]. Tiedman et al. presented a complete report on anatomy, vascular supply, and operation method of the BFP for the first time [13]. Rapidis et al., Dean et al., and Hao used pedicle BFP for the reconstruction of medium-sized postsurgical oral defects of malignant lesions [11, 14, 15].

3. Anatomy, physiology, and embryology

3.1. General structures

The BFP is a simple lobulated mass described as consisting of a central body and four extensions: buccal, pterygoid, pterygopalatine, and temporal. The body consists of three independent lobes: anterior, intermediate, and posterior. Each lobe is encapsulated by an independent membrane and separated by a natural space [16] (**Figures 1–3**).

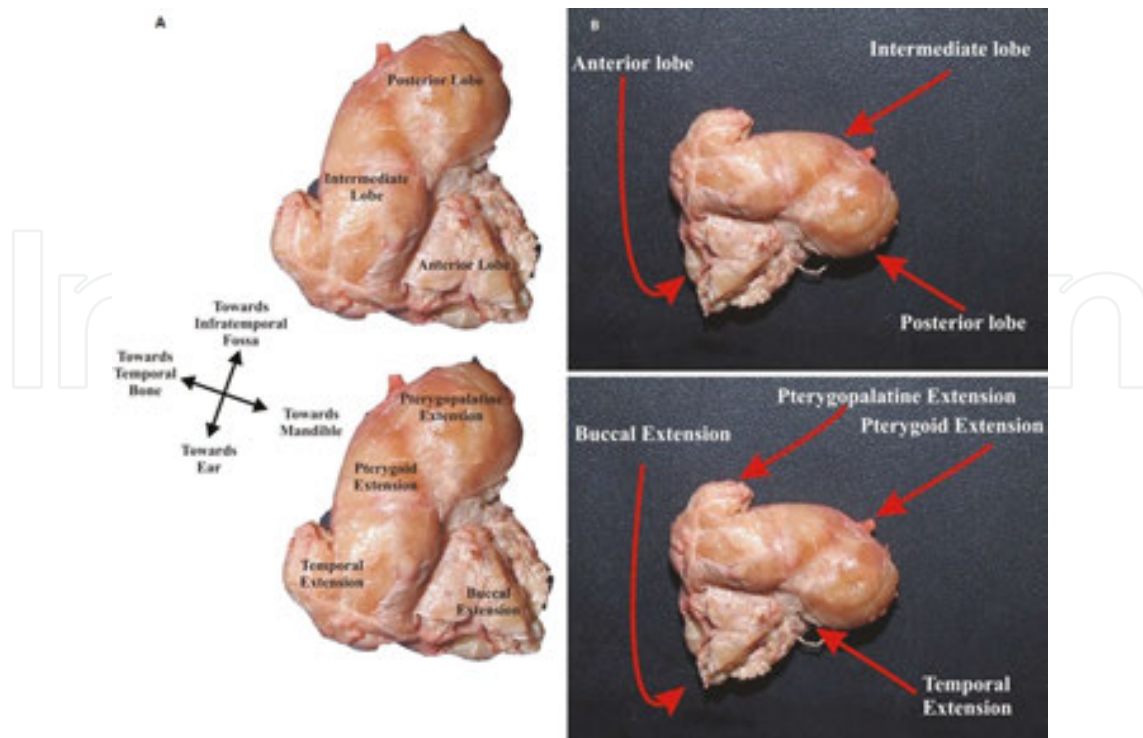


Figure 1. The BFP lobes and extensions (A, B) (Loukas M, et al. [1]).

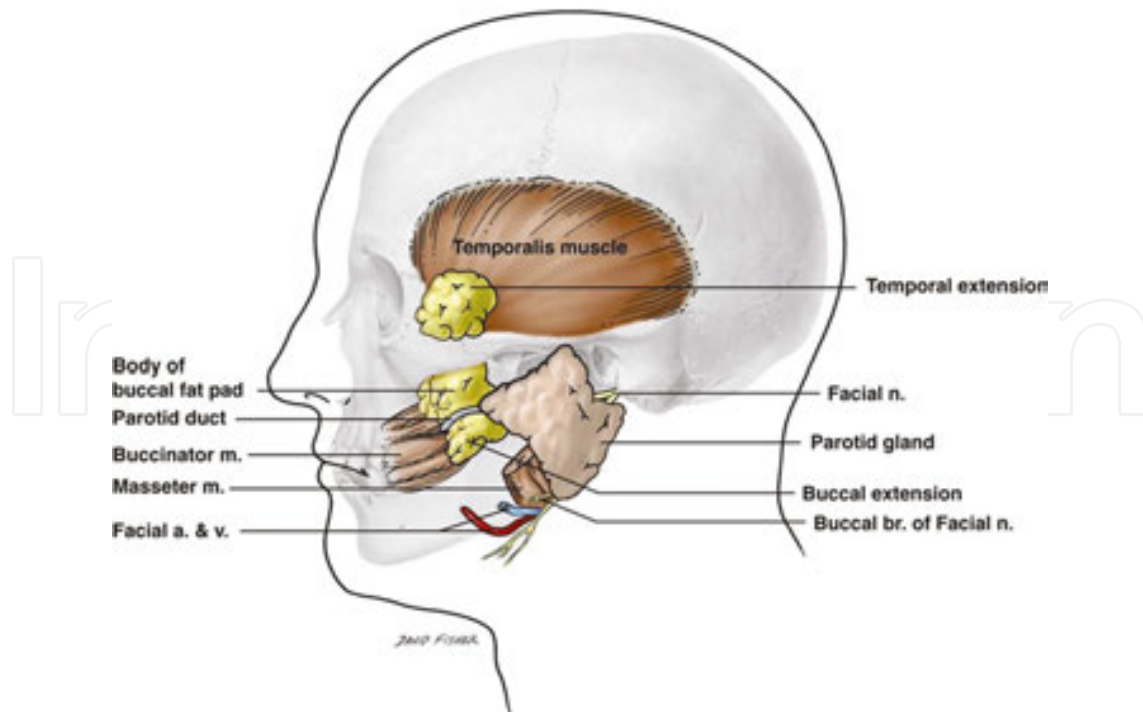


Figure 2. Anatomical relation of important adjacent structures (parotid duct, facial artery, parotid gland, and buccinator muscle) with the BFP, the temporal and buccal extensions of the BFP are present (Yousuf et al. [28]).

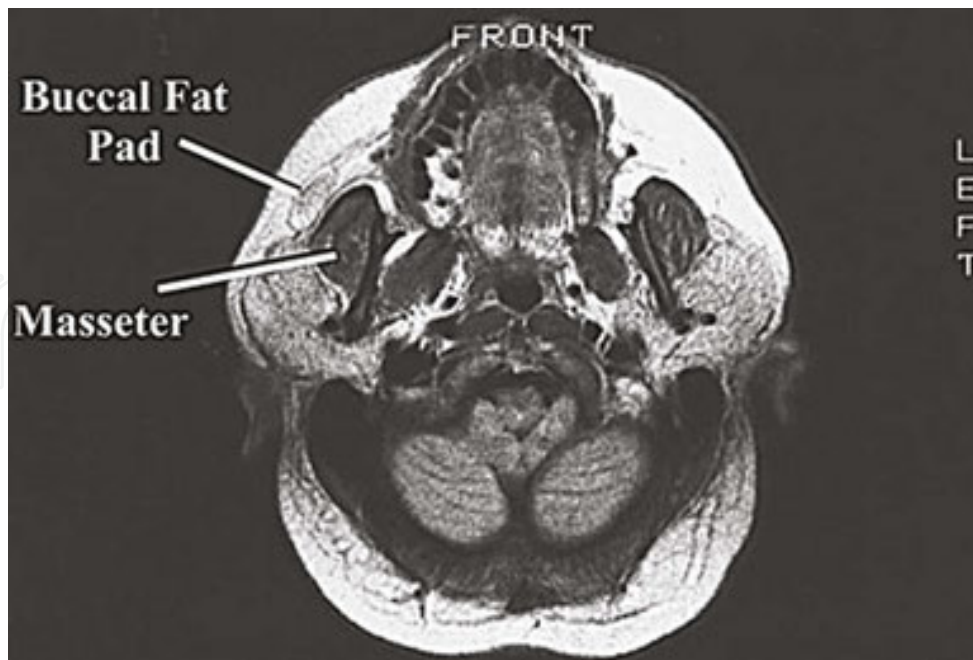


Figure 3. Cross-section of T1 MRI at the level of the oral cavity and the hard palate. The BFP is evident anteriorly to the masseter. Notice the volume of the BFP in relationship to the masseter (Yousuf et al. [28]).

The main body is situated deeply along the posterior maxilla and upper fibers of the buccinators, covered with a thin capsule.

The cheek contour is made generally by the buccal extension of the BFP, which is located superficially in the cheek. More than half of the total weight of the BFP mass is the body and the buccal extension together. Another extension of the BFP is pterygopalatine. It extends to the inferior orbital fissure and pterygopalatine fossa. The third extension is the pterygoid extension. It extends into the pterygomandibular space. The pterygoid extension packs the lingual nerve and mandibular neurovascular. The last extension of the BFP is the temporal extension. It has two parts, superficial and deep temporal extension. Actually, the superficial part is a distinct fat pad, its appearance is different, and has a different blood supply. Therefore, it is believed to be a distinct anatomical feature for the BFP.

A specific capsule covers each part of the BFP. Also, each part of the BFP is connected to the adjacent anatomical structures by ligaments. When the size of extensions is compared, the temporal, pterygopalatine, and pterygoid extensions are smaller and located deeper [1, 14, 16, 17].

3.2. Relation to the parotid duct and branches of the facial nerve

The parotid duct and zygomatic and buccal branches of the facial nerve cross the anterior and lateral surfaces of the BFP.

The parotid duct and zygomatic and buccal branches of the facial nerve cross the anterior and lateral surfaces of the BFP. The duct pierces the buccinators and presents in the oral cavity adjacent to the maxillary second molars [18]. It is established that the parotid duct either runs

along the lateral surface of BFP or perforates the body of the posterior lobe before it comes up to the surface of the buccinators [19]. With respect to the BFP, the parotid duct is seen in three different situations. In 42% of cases, it travels over the buccal process (type A), in 26% of the cases, through the buccal process (type B), and 32% of the cases superior to the buccal process of the BFP (type C) (Figure 4).

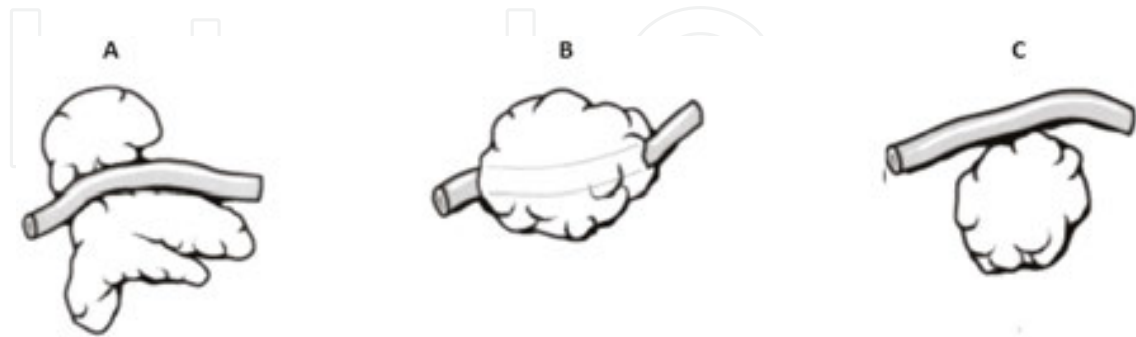


Figure 4. Relationship of the BFP with the parotid duct. (A) Type A: the parotid duct travels over the buccal extension. (B) Type B: the parotid duct travels through the buccal extension. (C) Type C: the parotid duct travels superior to the buccal extension of the BFP (Hwang et al. [18]).

The anterior surface of the BFP is covered by buccal branches of the facial nerve in 75% of cases, while the lateral border of the BFP is covered by the zygomatic branches in 90% of cases [1] (Figure 5).

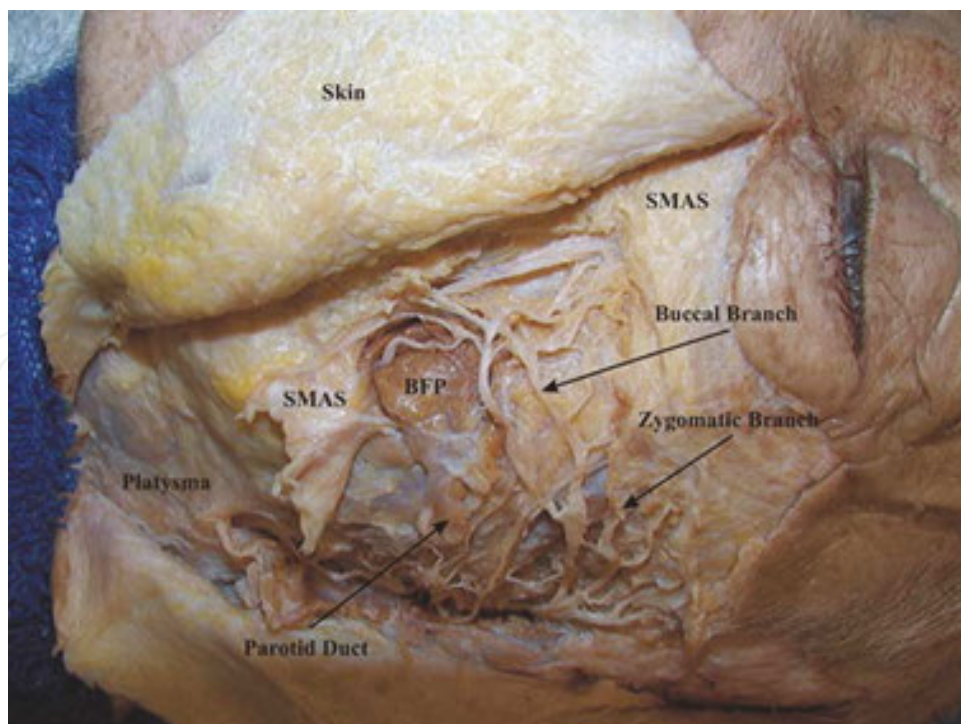


Figure 5. The relationship of the BFP with the branches of the facial nerve. Superficial musculoaponeurotic system (SMAS) (Loukas et al. [1]).

There are different types of the relations between the facial nerve and the BFP. Two different kinds of interrelations are present. First, in 73% of cases buccal branches of the facial nerve travel on the surface of the BFP (type one). Second, in 27% of cases the branches travel through into the buccal extension [18, 19].

3.3. Blood supply

There are three main sources of the BFP's blood supply. The maxillary artery (buccal and temporal branches), the superficial temporal artery (transverse facial branches), and the facial artery provide the blood supply for the BFP. These branches make a subcapsular plexus. Due to this rich blood supply, the BFP can be used as a pedicle graft. Also, it explains the great success rate of the BFP flap [17, 20–23]. The BFP has a very rich subcapsular capillary plexus. Arterioles go into the capsule, travel along the septa of the BFP, and finally make a capillary network among adipocytes. This circulation system is similar to the other white adipose tissues. However, the capillary plexus of the BFP is smaller and its capillaries are wider [19, 24]. The BFP venous system drains via the facial vein [23].

3.4. Volume and size

The mean volume of BFP is 10 cm³ (average 9.6 ml, range 8.33–11.9 ml); weight is 9.3 g; if flattened, it can cover the surface of 10 cm², preserving a thickness of 6 mm [1, 2, 19, 25]. The size of the BFP is fairly constant among different individuals regardless of overall body weight and fat distribution; even cachectic patients have BFPs that are of normal weight and volume [10]. Investigation of age-related changes in BFP volume reveals that the most important alterations are found between two age groups namely 0–10 years and 21–50 years. Moderate decrease in volume after the age of 50 years is noted [25].

3.5. Embryology and physiology

Poissonnet et al. [26] reported that fat tissue differentiation begins in the second trimester of gestation. The size of fat lobules increases until the 29th week of gestation. However, the number of them is approximately constant. Cheek fat is the first fat that develops [26]. Like adults, the BFP has an important role in the cheek prominence of newborns. Among fetal adipose tissue, the BFP is one of the initial adipose tissues that develop.

Some functions were introduced for the BFP in newborns. First, the BFP prevents the negative pressure while a newborn is sucking. Second, it separates the masticator muscles from one another and nearby bony structures. Third, it protects the neurovascular bundles. Finally, it enhances the intermuscular movement; this function is performed by a specialized type of fat which is called syssarcosis [16, 17, 20, 22].

Bagdade and Hirsch are the first who measured and tabulated the fatty acid composition of the BFP. They used gas-liquid and thin-layer chromatography for this purpose [27]. Ranke claims that the amount of lipolysis of the BFP is different from subcutaneous fat. Like the periorbital fat, the BFP is constant during emaciation while subcutaneous fat is lost [8, 15, 20, 29, 30].

One of the desirable features of the BFP as a flap is its quick epithelialization property [10, 31, 32].

4. Surgical approach

The most direct access to the BFP is found at the distobuccal depth of the maxillary tuberosity, and it may be dissected through a vestibular incision if it has not been encountered during the resection [33]. Under either local or general anesthesia, an upper mucosal incision posterior to the area of the zygomatic buttress is made, followed by a simple incision through the periosteum and fascial envelope of the BFP [8]. After a single sharp scissor stab through the periosteum and scant buccinator muscle, the BFP extrudes into the operative site [33] (**Figure 6**).

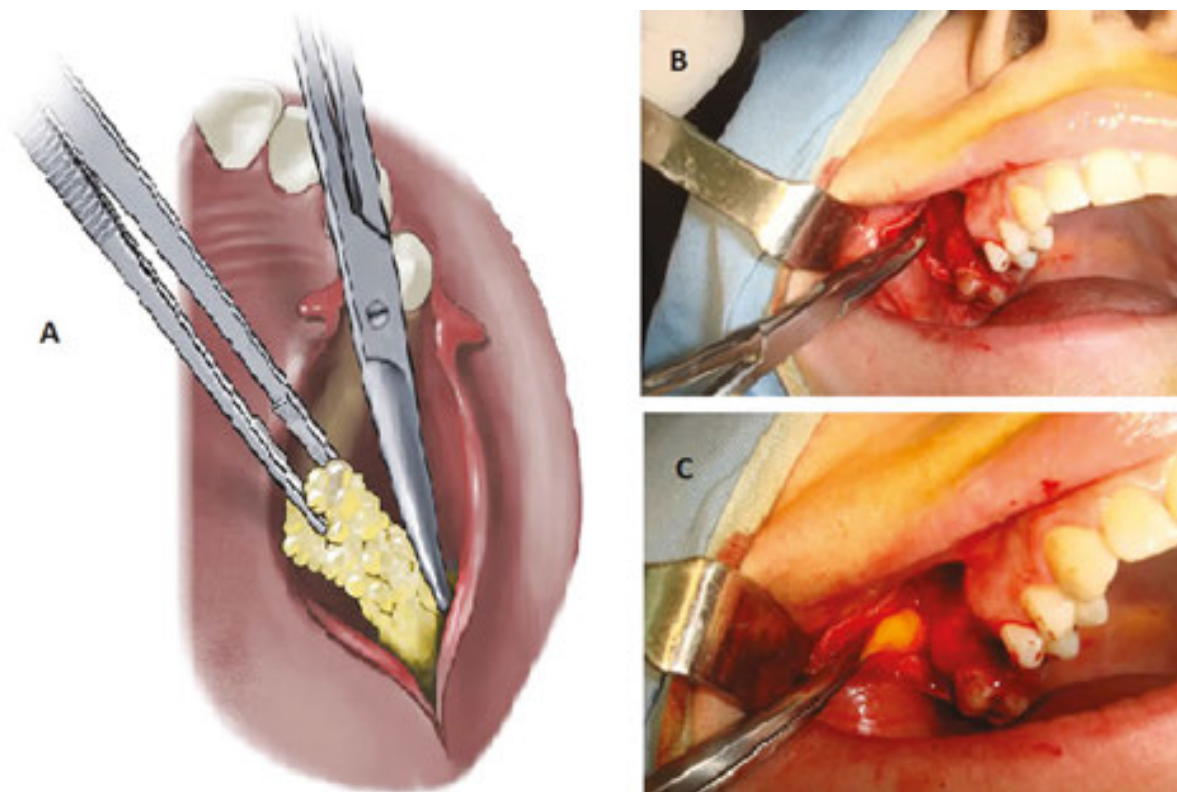


Figure 6. (A) Schematic view of the BFP intraoral approach (Arce [33]). Clinical view of intraoral approach. (B) The use of a hemostat to explore the site. (C) Pulling out the BFP very gently.

Mechanical suction must be avoided once the BFP is exposed. It easily herniates into the defect with a little teasing and is gently pulled out from its bed with a vascular clamp [8]. Since the main cause of sensory disturbances is the impairment of the metabolic supply due to the disturbed microvascular circulation of the nerve fibers by the mechanical trauma [34–36], surgeons should avoid the excessively and unnecessarily manipulating of the surgery site for finding the BFP. At this time, the external pressure helps the removal of the temporal extension

of the BFP. Surgeons should evaluate the amount of fat required, then based on their need manipulate the site and extract various processes of the BFP [8].

Clinically, the color of the oral aspect of the exposed BFP changes to yellowish-white within three days; then, it changes to red within the first week. It is a consequence of the formation of granulation tissue. In the second week, the granulation tissue becomes firmer and completely epithelialized [9, 37].

5. Applications of the BFP

The BFP has different applications in oral and maxillofacial reconstruction. It has some physiological functions, such as filling deep tissue space, has a role of gliding pad for facial and masticatory muscles during contraction, and has a role of cushion for some structures from outer force impulsion [21]. Besides its physiological functions, it serves as a versatile flap in reconstructive procedures [38].

Applications of the BFP in oral and maxillofacial surgeries have increased rapidly [7], and nowadays, the BFP is used in different kinds of surgeries. Particularly in recent years, scientists have been working on regenerative properties of the BFP, which rely on adipose-derived stem cells.

5.1. OAC and oroantral fistula

The BFP flap, preferably pedicle type, has been used most commonly for the closure of OACs and oroantral fistula (OAF) [2, 8, 39–43].

There is no doubt that some characteristics of the BFP such as favorable anatomical position, perfect epithelialization outcome, simple dissection for harvesting, and low rate of failure make it a desirable alternative [9]. Dolanmaz et al. claimed that using the BFP flap for the management of OAC is a reliable alternative, and this method probably is the best treatment choice for recurrent OAF [32].

The choice of the BFP versus a buccal advancement flap closure must weigh the advantages and disadvantages, and other available techniques, in regard to location, height of alveolus, sinus membrane status, and obliteration of the vestibule. Using the BFP eliminates the needs for removal of additional alveolar bone and mobilizes a buccal advancement flap, which may obliterate the buccal vestibule. It is also helpful when traumatized surrounding attached gingiva or mucosa precludes the use of a buccal advancement flap for primary closure [33]. It has a favorable healing course after the operation, and the wounds become successfully epithelialized in 3–4 weeks after surgery [7].

There is the minimal obliteration of the vestibule in the closure of OAF with the BFP as compared to closure with buccal advancement flap. There are no differences in the level or color of the mucosa [37]. The majority of reports point out a perfect success rate of the BFP in the treatment of OAC or fistula. Most studies state a high success rate of BFP in the closure of

OAC/OAF [7]. Nevertheless, 7.5% complications were reported, for example, the elimination of vestibule and recurrence of OAF. The vestibular depth became normal in the due course of time resulting in no postoperative prosthodontics complications [8] (**Figure 7**).

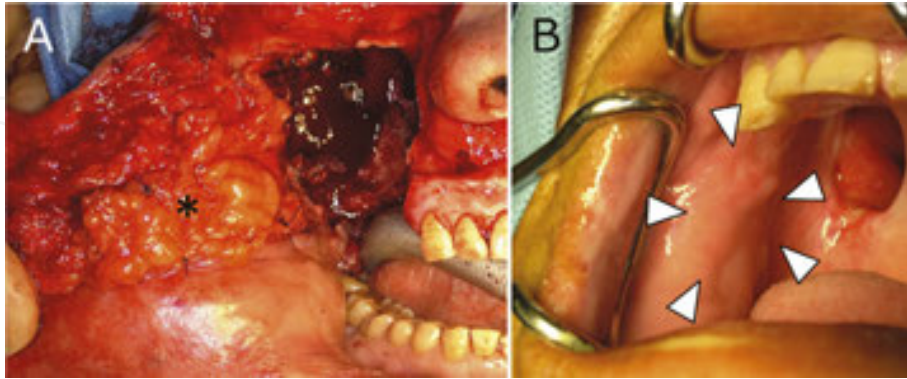


Figure 7. Reconstruction of the inner surface of a facial flap in a patient following resection of an ameloblastoma of the right upper gingiva. (A) BFP covers the inner surface of the facial flap (*). (B) At 1 year and 7 months postoperatively, cicatricial contracture is slight (arrowheads) (Toshihiro et al. [57]).

5.2. Regional defects

The other major use of the BFP is the closure of post-excision defects [9–11, 14, 29, 31, 39, 41, 44–48].

Different kinds of pathologies can cause a defect in the maxilla when resected. The applications of the BFP have been reported with a noted range of usage from the angle of the mouth to the retromolar trigone and palate [49]. The most used is for the reconstruction of the hard palate [44]. The most important consideration of using the BFP for reconstruction is the size of the defect. Most of the studies show a desirable result for closing defects up to $6 \times 5 \times 3$ cm [8]. The authors have had successful experience in the treatment of nine patients with large hard palate defects as large as 7×5 cm.

The use of BFP in the reconstruction of defects is highly successful; however, some complications have been reported [7, 8, 29, 41, 44–48].

The application of the BFP for covering mucosal defects following ablation of the buccal cancer has been reported [50]. The result of epithelialization is acceptable after 4–6 weeks. The capability of the BFP in the treatment of mucosal defects is compared with radial free forearm flap and free split-thickness graft. Although the BFP epithelializes easily, due to the lack of lamina propria and submucosa in the dense fibrous connective tissue, the BFP restricts mouth opening [46].

Mehrotra et al. [51] performed a retrospective study of 100 patients and compared the BFP with nasolabial flap, tongue flap, and split-skin graft for the coverage of post-fibrotic band incision in oral submucous fibrosis with 25 patients in each group. They claimed that the BFP serves as the best substitute, providing excellent function without deteriorating esthetics. It offered the ease of surgery, little postoperative morbidity, and good patient acceptance [51].

5.3. Cleft palate

The use of BFP to repair primary cleft palate was first described by Zhao et al. [52] in 1998. Most researchers agree that the ease of harvesting and mobilization of the graft, an excellent blood supply, and minimal donor-site complications make the pedicle BFP graft a convenient and reliable method in cleft palate surgery [53] (**Figure 8**).

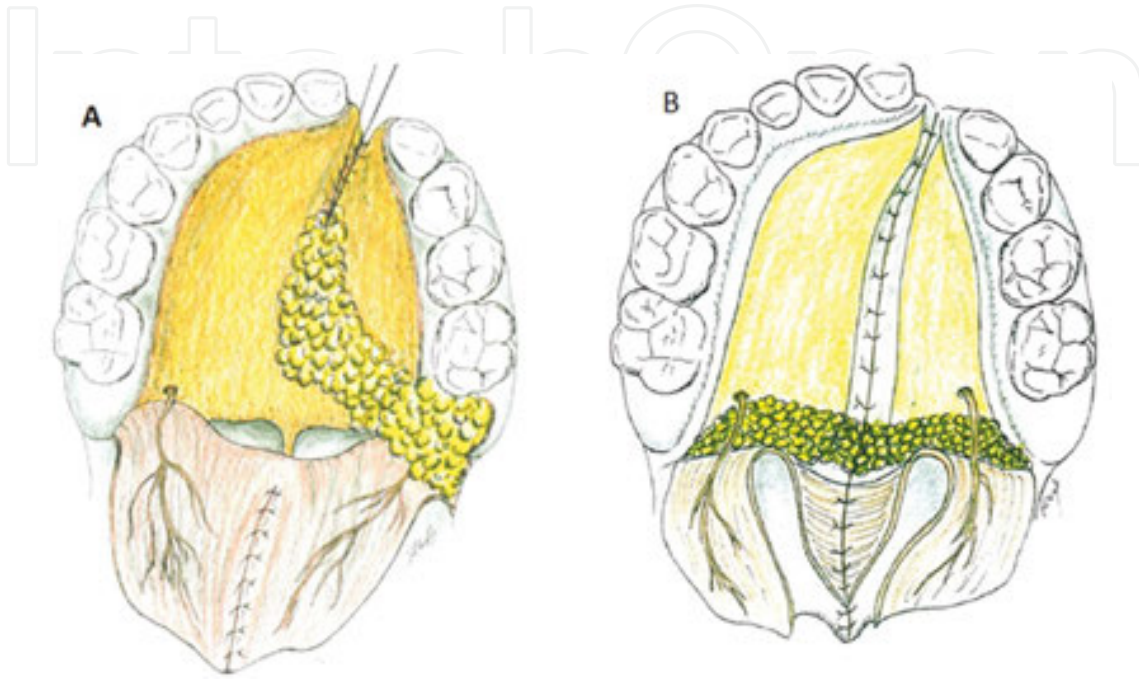


Figure 8. (A) The use of BFP for the closure of palatal fistulas. (B) The use of BFP to prevent type III fistulas between the hard and soft palate, minimizing scarring tension and obstructing the space of Ernst (Gröbe et al. [53]).

The transferred BFP was fully epithelialized with healthy-looking oral mucosa within 4 weeks, regardless of graft coverage with palatal mucosa or not. There is no significant impairment of palatal movement or any prevention of growth disturbances [54]. Levi et al. [54] suggests that the scar contraction and subsequent transverse maxillary growth restriction induced by the lateral hard palatal tissue defect decrease in this technique. Also, they believe that the hollowness of the child's cheek is unaffected.

Large, unlined, denuded palatal shelves serve as a key nidus of scar contraction as the palatal tissues attempt to fill the dead space [54]. Levi et al. state that adding the BFP to fill this open space causes an increase of vascularity in this area. Also, they believe that adding a layer of the BFP over the buccal mucosal flap decreases the time of surgery and needs less donor-site dissection [54, 55].

The combination of these two techniques, the BFP with pedicle mucosal flap, has some advantages: (1) the length of the soft palate increases without causing tension from the nasal side; (2) if the oral layer has failed and a perforation occurs, the graft serves as a bed for secondary granulation; (3) the flap also fills the secondary lateral defect; and (4) unlike buccal myomucosal flap, which is generated from another site, the BFP is easily accessible from the lateral incision [56].

5.4. Temporomandibular joint

Rattan used the BFP as a useful adjunct to autogenous or alloplastic temporomandibular joint (TMJ) reconstruction after TMJ ankylosis release. He claimed that the BFP can be used for TMJ reconstruction because of its local availability [16]. Toshihiro et al. used BFP graft in the TMJ region to repair the postoperative defect left by a synovial chondromatosis resected from the left condylar head in a 58-year-old female. The size of the defect was 20×25 mm and the size of the BFP was 30×30 mm. Although the tumor was resected via an extraoral approach, BFP grafting was prepared intraorally and tunneled to the TMJ region (**Figure 9**). There was no contraction of soft tissues or functional disorder of the TMJ during follow-up [57].

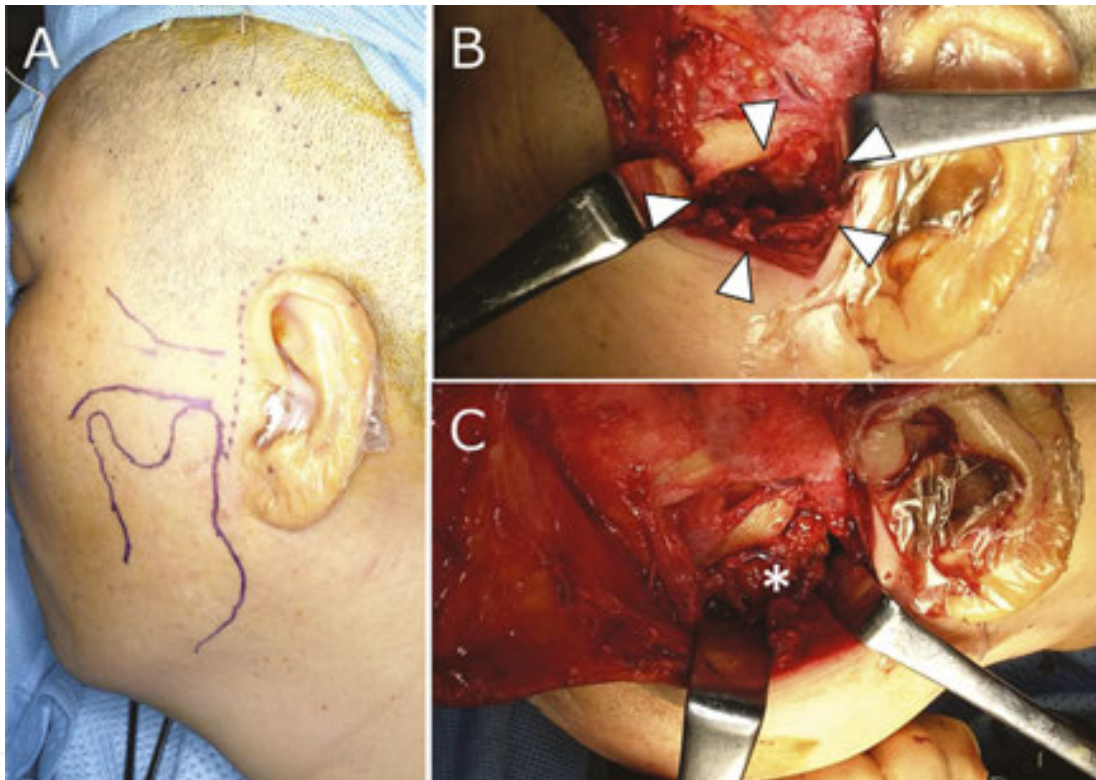


Figure 9. Reconstruction of a defect in the temporomandibular joint (TMJ) region in a patient following resection of a synovial chondromatosis of the left TMJ. (A) Preoperative view. (B) Resection of the mandibular condyle with the tumor (arrowheads). (C) Extension of the BFP to the surgical defect (*) (Toshihiro et al. [57]).

Singh et al. evaluated the feasibility and usefulness of BFP as an interposition graft in the treatment of TMJ ankylosis. Their findings showed the successful management of TMJ ankylosis using the BFP as an interposition graft. They assert that the mean of the maximum interincisal opening is 35.1 mm. Furthermore, the mean deviation to the affected side during opening the mouth is 1.6 mm. They claim that chewing function after this surgery satisfies the patients. Also, they believe that no major occlusal changes occur after this surgery and the intra-articular space is maintained well. Finally, they showed that using the BFP as an interposition graft is a desirable alternative to manage TMJ ankylosis, particularly in the short term [58].

Elimination of dead space is the main goal of using the BFP around the TMJ; the BFP prevents the hematoma around the joint. Also, due to the isolation of the joint by the BFP, the chance of the formation of fibrosis and bone decreases in the area [7].

5.5. Miscellaneous uses

Hassani et al. [59] reported the use of the BFP with a mixture of autogenous bone graft in sinus lifting procedure and covering the lateral wall of sinus for the first time. They believed that the BFP serves as both a physical barrier and a high vascularized bed for the bone graft. Tamura et al. used the BFP for augmentation of the vocal cord [60].

Khouw et al. reported the use of the BFP for palatal reconstruction when it is combined with a superiorly based pharyngeal flap. They used this technique to lengthen the soft palate in patients with extensive necrotizing defects [61].

El Haddad et al. reported the use of the pedicled BFP for covering of class IV Miller gingival defects. The BFP provides a significant amount of keratinized tissue for the gingival recession of the maxillary molars [62].

Also, some experts believe that the BFP can be used as a biologic membrane to cover bone grafts and in maxillary sinus lifting for implant placement. As mentioned before, the BFP can serve as a physical barrier. Also, it is well vascularized and contains adipose stem cells (ASCs), which have great potential to help bone regeneration in operation sites [59, 63, 64]. For these reasons and because the BFP is a source of stem cells, the BFP can be a great biologic membrane for covering the bone grafts.

Recently, researchers increased their focus of interest on adipose tissue-derived stem cells, and the BFP was introduced as a source of stem cells. Farré-Guasch et al. had claimed that the BFP is a source of stem cells. ASCs present in adipose tissue are able to differentiate into several lineages and express multiple growth factors, which makes them suitable for clinical application. The BFP represents an easy access source for dentists and oral surgeons. The stromal vascular fraction obtained from fresh BFP-derived adipose tissue and passaged ASCs were analyzed to detect and quantify the percentage of ASCs in this tissue. The BFP contains a huge amount of stem cells that has the capability to differentiate into the chondrogenic, adipogenic, and osteogenic lineages [65, 66].

6. BFP pathological conditions and complications

6.1. Pathological conditions

Kahn et al. explained that the continuity of fat tissue within the deep face makes it prone to pathological conditions such as cellulitis and abscess. The anaerobic organisms within the fat pad are responsible for it [67].

Although hemangioma in BFP is rare, some studies have reported the incidence of hemangioma with/without phleboliths inside the BFP mass [68] (**Figure 10**).

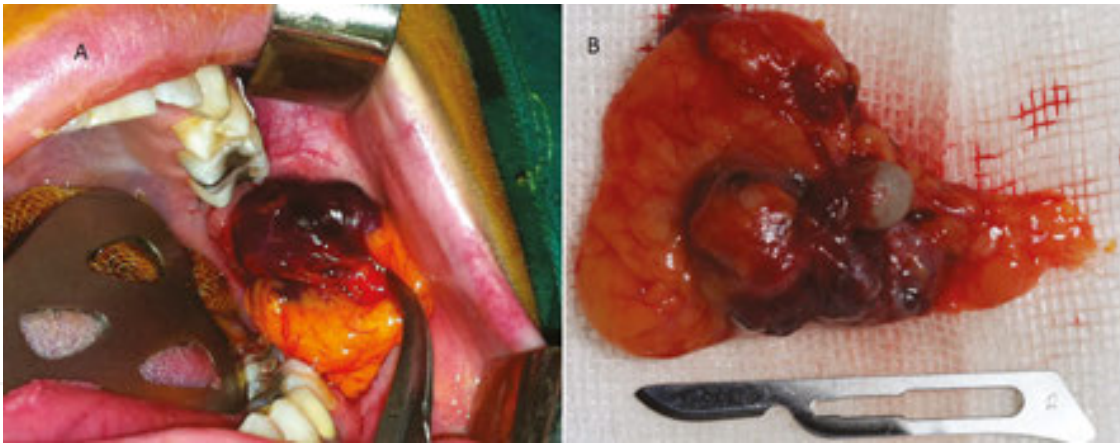


Figure 10. Hemangioma of the BFP. (A) Intraoperative view of the lesion. (B) View of the totally excised lesion showing hemangioma with phleboliths (Hassani et al. [68]).

BFP herniation is a common occurrence, particularly in infants and children. The BFP can pierce the oral mucosa and buccinators to the oral cavity [12]. Also, it may enter into the maxillary sinus after herniation [10].

A review of the literature shows that most cases of the BFP herniation involve children less than 5 years of age [28]. This fact can be due to some reasons. First, the BFP prominence is more in children. Second, because children put foreign objects into their mouth, they are more prone to the BFP herniation via rupturing the oral mucosa. Third, neonates and infant have a suckling activity which makes them prone to the BFP herniation [69].

6.2. Complications

Complications due to the mobilization of BFP are rare, and the BFP in the reconstruction of defects is highly successful [7, 19].

Partial necrosis accounted for the majority of failures involving the use of the BFP. A small dehiscence can be treated conservatively to see if spontaneous closure occurs. Reattempts at closure involve contralateral buccal fat flaps, palatal flaps, or buccal flaps. Rarely can the same flap be mobilized again, unless the defect was small and the reason for failure is easily identified. Trismus from scarring has been reported mainly when the BFP is used for the reconstruction of retromolar trigone or buccal mucosa defects. The range of motion should be noted in the few weeks after the use of the flap so that physical therapy, if necessary, is activated as soon as possible. A rarely visible change in facial contour has been reported in patients only when the BFP is used for the reconstruction of large defects. A surgeon might consider a contralateral buccal lipectomy to correct this alteration. The low morbidity and failure rate associated with the use of the BFP in maxillary reconstruction allows this simple reconstructive option to be used in carefully selected defects [33].

Different complications following application of the BFP have been reported. Although the complications are usually rare, it is a fact that it could be partial or complete loss of flap, limitation in mouth opening [44], hematoma, hemorrhage [45], postoperative infection [29,

47], and depressed cheek [8, 29, 46]. If a clinician harvests a large amount of the BFP for reconstruction purpose, the cheek may be depressed.

7. Summary

Generally, extraction of the BFP from the deep facial region is a safe procedure with minimal risk of unharzardous complications [19].

Due to the unique features of the BFP, such as its location, easy accessibility, rich blood supply, a rich source of ASCs, and high rate of epithelialization, using the term “versatile flap” is truly fitting. The BFP can be used in different directions. It can displace anteriorly up to the canine region, not beyond the midline, posteriorly in the hard palate tuberosity region, retromolar region, the soft palate, and to the anterior tonsillar pillar (**Figure 11**) [45].

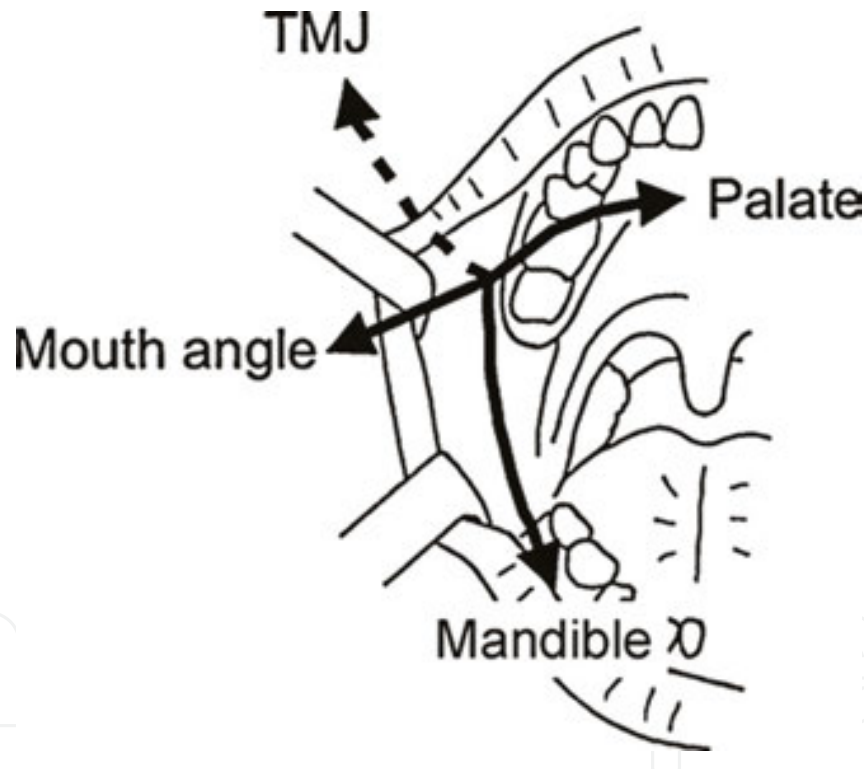


Figure 11. Applicability of the BFP. The graft could be extended in four directions to the palate via the maxilla, mandible, mouth angle, and TMJ region (Toshihiro et al. [57]).

The BFP has a variety of applications in oral and maxillofacial surgery. Among different applications, using it for the closure of OAC is the most common application reported. Although most of the time the BFP flap is used solely, it can be used in conjunction with other flaps, such as the pedicle temporalis muscle myocutaneous flap [31]. The success of the BFP has been attributed to its rich vascular supply, less donor-site morbidity, ease of harvest, and a lower rate of complications [39].

Author details

Ali Hassani^{1*}, Solaleh Shahmirzadi² and Sarang Saadat²

*Address all correspondence to: drhassani.omfs@gmail.com

1 Department of Oral and Maxillofacial Surgery, Implant Department, Dental Implant Research Center, Tehran Dental Branch, Islamic Azad University, Tehran, Iran

2 Dental Implant Research Center, Tehran Dental Branch, Islamic Azad University, Tehran, Iran

References

- [1] Loukas M, Kapos T, Louis RG Jr, Wartman C, Jones A, Hallner B. Gross anatomical, CT and MRI analyses of the buccal fat pad with special emphasis on volumetric variations. *Surg Radiol Anat.* 2006;28(3):254–60.
- [2] Egyedi P. Utilization of the buccal fat pad for closure of oro-antral and/or oro-nasal communications. *J Maxillofac Surg.* 1977;5(4):241–4.
- [3] Messenger K, Cloyd W. Traumatic herniation of the buccal fat pad: Report of a case. *Oral Surg Oral Med Oral Pathol.* 1977;43(1):41–3.
- [4] Wolford DG, Stapleford RG, Forte RA, Heath M. Traumatic herniation of the buccal fat pad: Report of case. *J Am Dent Assoc.* 1981;103(4):593–4.
- [5] Scott P, Fabbroni G, Mitchell D. The buccal fat pad in the closure of oro-antral communications: An illustrated guide. *Dent Update.* 2004;31(6):363–4, 366.
- [6] Allais M, Maurette PE, Cortez AL, Laureano Filho JR, Mazzonetto R. The buccal fat pad graft in the closure of oroantral communications. *Braz J Otorhinolaryngol.* 2008;74(5):799.
- [7] Singh J, Prasad K, Lalitha RM, Ranganath K. Buccal pad of fat and its applications in oral and maxillofacial surgery: A review of published literature (February) 2004 to (July) 2009. *Oral Surg Oral Med Oral Pathol Oral Radiol Endod.* 2010;110(6):698–705.
- [8] Poeschl PW, Baumann A, Russmueller G, Poeschl E, Klug C, Ewers R. Closure of oroantral communications with Bichat's buccal fat pad. *J Oral Maxillofac Surg.* 2009;67(7):1460–6.
- [9] Marzano UG. Lorenz Heister's "molar gland". *Plast Reconstr Surg.* 2005;115(5):1389–93.

- [10] Baumann A, Ewers R. Application of the buccal fat pad in oral reconstruction. *J Oral Maxillofac Surg.* 2000;58(4):389–92; discussion 392–3.
- [11] Rapidis AD, Alexandridis CA, Eleftheriadis E, Angelopoulos AP. The use of the buccal fat pad for reconstruction of oral defects: Review of the literature and report of 15 cases. *J Oral Maxillofac Surg.* 2000;58(2):158–63.
- [12] Neder A. Use of buccal fat pad for grafts. *Oral Surg Oral Med Oral Pathol.* 1983;55(4):349–50.
- [13] Tideman H, Bosanquet A, Scott J. Use of the buccal fat pad as a pedicled graft.
- [14] Dean A, Alamillos F, García-López A. The buccal fat pad flap in oral reconstruction. *Head Neck.* 2001;23(5):383–8.
- [15] Hao SP. Reconstruction of oral defects with the pedicle buccal fat pad flap. *Otolaryngol Head Neck Surg.* 2000;122(6):863–7.
- [16] Rattan V. A simple technique for use of buccal pad of fat in temporomandibular joint reconstruction. *J Oral Maxillofac Surg.* 2006;64(9):1447–51.
- [17] Matarasso A. Buccal fat pad excision: aesthetic improvement of the midface. *Ann Plast Surg.* 1991;26(5):413–8.
- [18] Hwang K, Cho H, Battuvshin D. Interrelated buccal fat pad with facial buccal branches and parotid duct. *J Craniofac Surg.* 2005;16(4):658–60.
- [19] Cherekaev V, Golbin D, Belov A. Translocated pedicle buccal fat pad: closure of anterior and middle skull base defects after tumor resection. *J Craniofac Surg.* 2012;23(1):98–104.
- [20] Dubin B, Jackson I, Halim A, Triplett WW, Ferreira M. Anatomy of the buccal fat pad and its clinical significance *Plast Reconstr Surg.* 1989;83(2):257–64.
- [21] Zhang HM, Yan YP, Qi KM, Wang JQ, Liu ZF. Anatomical structure of the buccal fat pad and its clinical adaptations. *Plast Reconstr Surg.* 2002;109(7):2509–18; discussion 2519–20.
- [22] Jackson I. Anatomy of the buccal fat pad and its clinical significance. *Plast Reconstr Surg.* 1999;103(7):2059–60; discussion 2061–3.
- [23] Tostevin P, Ellis H. The buccal pad of fat: A review. *Clin Anat.* 1995;8(6):403–6.
- [24] Kahn JL, Sick H, Laude M, Koritke JG. Vascularization of the adipose body of the cheek. *Arch Anat Histol Embryol.* 1990;73:3–20.
- [25] Xiao H, Bayramicli M, Jackson IT. Volumetric analysis of the buccal fat pad. *Eur J Plast Surg.* 1999;22(4):177–80.
- [26] Poissonnet C, Burdi A, Bookstein F. Growth and development of human adipose tissue during early gestation. *Early Hum Dev.* 1983;8(1):1–11.

- [27] Bagdade J, Hirsch J. Gestational and dietary influences on the lipid content of the infant buccal fat pad. *Proc Soc Exp Biol Med*. 1966;122(2):616–9.
- [28] Yousuf S, Tubbs RS, Wartmann CT, Kapos T, Cohen-Gadol AA, Loukas M. A review of the gross anatomy, functions, pathology, and clinical uses of the buccal fat pad. *Surg Radiol Anat*. 2010;32(5):427–36.
- [29] Amin M, Bailey B, Swinson B, Witherow H. Use of the buccal fat pad in the reconstruction and prosthetic rehabilitation of oncological maxillary defects. *Br J Oral Maxillofac Surg*. 2005;43(2):148–54.
- [30] Stuzin JM, Wagstrom L, Kawamoto HK, Baker TJ, Wolfe SA. The anatomy and clinical applications of the buccal fat pad. *Plast Reconstr Surg*. 1990;85(1):29–37.
- [31] Samman N, Cheung L, Tideman H. The buccal fat pad in oral reconstruction. *Int J Oral Maxillofac Surg*. 1993;22(1):2–6.
- [32] Dolanmaz D, Tuz H, Bayraktar S, Metin M, Erdem E, Baykul T. Use of pedicle buccal fat pad in the closure of oroantral communication: Analysis of 75 cases. *Quintessence Int*. 2004;35(3):241–6.
- [33] Arce K. Buccal fat pad in maxillary reconstruction. *Atlas Oral Maxillofac Surg Clin North Am*. 2007;15(1):23–32.
- [34] Hassani A, Saadat S, Moshiri R, Shahmirzad S, Hassani A. Nerve retraction during inferior alveolar nerve repositioning procedure: A new simple method and review of the literature. *J Oral Implantol*. 2015;41 Spec No: 391–4. doi: 10.1563/AAID-JOI-D-13-00108. Epub 2013 Dec 17.
- [35] Hassani A, Saadat S. Nerve repositioning injuries of the trigeminal nerve. In: Miloro M, editor. *Trigeminal Nerve Injuries*. 1st ed. Berlin: Springer; 2013. p. 109–135. DOI: 10.1007/978-3-642-35539-4_7
- [36] Hassani A, Motamedi MH, Saadat S. Inferior alveolar nerve transpositioning for implant placement. In: Motamedi MH, editor. *A Textbook of Advanced Oral and Maxillofacial Surgery*. 1st ed. Rijeka: InTech; 2013. p. 659–93). DOI: 10.5772/52317
- [37] Haraji A, Zare RE. The use of buccal fat pad for oro-antral communication closure. *J Mashhad Dent Sch Mashhad Univ Med Sci*. 2007;31:9–11.
- [38] Yousif NJ, Gosain A, Sanger JR, Larson DL, Matloub HS. The nasolabial fold: A photogrammetric analysis. *Plast Reconstr Surg*. 1994;93(1):70–7.
- [39] Adeyemo WL, Ogunlewe MO, Ladeinde AL, James O. Closure of oro-antral fistula with pedicle buccal fat pad. A case report and review of literature. *African Journal of Oral Health*. 2004;1(1):42–6.
- [40] Dolanmaz D, Tuz H, Bayraktar S, Metin M, Erdem E, Baykul T. Use of pedicle buccal fat pad in the closure of oroantral communication: analysis of 75 cases. *Quintessence Int*. 2004;35(3):241–46.

- [41] Hassani A, Motamedi M, Saadat S, Moshiri R, Shahmirzadi S. Novel technique to repair maxillary sinus membrane perforations during sinus lifting. *J Oral Maxillofac Surg.* 2012;70(11):e592–7. doi: 10.1016/j.joms.2012.06.191.
- [42] Kim Y, Hwang J, Yun P. Closure of large perforation of sinus membrane using pedicle buccal fat pad graft: A case report. *Int J Oral Maxillofac Implants.* 2008;23(6):1139–42.
- [43] Hanazawa Y, Itoh K, Mabashi T, Sato K. Closure of oroantral communications using a pedicle buccal fat pad graft. *J Oral Maxillofac Surg.* 1995;53(7):771–5.
- [44] Colella G, Tartaro G, Giudice A. The buccal fat pad in oral reconstruction. *Br J Plast Surg.* 2004;57(4):326–9.
- [45] Chakrabarti J, Tekriwal R, Ganguli A, Ghosh S, Mishra PK. Pedicled buccal fat pad flap for intraoral malignant defects: A series of 29 cases. *Indian J Plast Surg.* 2009;42(1):36–42.
- [46] Chien CY, Hwang CF, Chuang HC, Jeng SF, Su CY. Comparison of radial forearm free flap, pedicle buccal fat pad flap and split-thickness skin graft in reconstruction of buccal mucosal defect. *Oral Oncol.* 2005;41(7):694–7.
- [47] Liu YM, Chen GF, Yan JL, Zhao SF, Zhang WM, Zhao S, Chen L. Functional reconstruction of maxilla with pedicle buccal fat pad flap, prefabricated titanium mesh and autologous bone grafts *Int J Oral Maxillofac Surg.* 2006;35(12):1108–13.
- [48] Zhong LP, Chen GF, Fan LJ, Zhao SF. Immediate reconstruction of maxilla with bone grafts supported by pedicle buccal fat pad graft. *Oral Surg Oral Med Oral Pathol Oral Radiol Endod.* 2004;97(2):147–54.
- [49] Alkan A, Dolanmaz D, Uzun E, Erdem E. The reconstruction of oral defects with buccal fat pad. *Swiss Med Wkly.* 2003;133(33/34):465–70.
- [50] Ferrari S, Ferri A, Bianchi B, Copelli C, Magri AS, Sesenna E. A novel technique for cheek mucosa defect reconstruction using a pedicle buccal fat pad and buccinator myomucosal island flap. *Oral Oncol.* 2009;45(1):59–62.
- [51] Mehrotra D, Pradhan R, Gupta S. Retrospective comparison of surgical treatment modalities in 100 patients with oral submucous fibrosis. *Oral Surg Oral Med Oral Pathol Oral Radiol Endod.* 2009;107(3):e1–10.
- [52] Zhao Z, Li S, Li Y. The application of the pedicle buccal fat pad graft in cleft palate repair. *Zhonghua Zheng Xing Shao Shang Wai Ke Za Zhi.* 1998;14(3):182–5.
- [53] Gröbe A, Eichhorn W, Hanken H, Precht C, Schmelzle R, Heiland M, et al. The use of buccal fat pad (BFP) as a pedicle graft in cleft palate surgery. *Int J Oral Maxillofac Surg.* 2011;40(7):685–9.
- [54] Levi B, Kasten SJ, Buchman SR. Utilization of the buccal fat pad flap for congenital cleft palate repair. *Plast Reconstr Surg.* 2009;123(3):1018–21.

- [55] Cole P, Horn T, Thaller S. The use of decellularized dermal grafting (AlloDerm) in persistent oro-nasal fistulas after tertiary cleft palate repair. *J Craniofac Surg*. 2006;17(4):636–41.
- [56] Pappachan B, Vasant R. Application of bilateral pedicle buccal fat pad in wide primary cleft palate. *Br J Oral Maxillofac Surg*. 2008;46(4):310–2.
- [57] Toshihiro Y, Nariai Y, Takamura Y, Yoshimura H, Tobita T, Yoshino A, et al. Applicability of buccal fat pad grafting for oral reconstruction. *Int J Oral Maxillofac Surg*. 2013;42(5):604–10.
- [58] Singh V, Dhingra R, Sharma B, Bhagol A, Kumar P. Retrospective analysis of use of buccal fat pad as an interpositional graft in temporomandibular joint ankylosis: Preliminary study. *J Oral Maxillofac Surg*. 2011;69(10):2530–6.
- [59] Hassani A, Khojasteh A, Alikhasi M, Vaziri H. Measurement of volume changes of sinus floor augmentation covered with buccal fat pad: A case series study. *Oral Surg Oral Med Oral Pathol Oral Radiol Endod*. 2009;107(3):369–74.
- [60] Tamura E, Fukuda H, Tabata Y, Nishimura M. Use of the buccal fat pad for vocal cord augmentation. *Acta Otolaryngol*. 2008;128(2):219–24.
- [61] Khouw YL, van der Wal KG, Bartels F, van der Biezen JJ. Bilateral palatal reconstruction using 2 pedicle buccal fat pads in rhinolalea aperta after extensive necrotizing tonsillitis: A case report. *J Oral Maxillofac Surg*. 2004;62(6):749–51.
- [62] El Haddad SA, Abd El Razzak MY, El Shall M. Use of pedicle buccal fat pad in root coverage of severe gingival recession defect. *J Periodontol*. 2008;79(7):1271–9.
- [63] Hudson JW, Anderson JG, Russell RM Jr, Anderson N, Chambers K. Use of pedicle fat pad graft as an adjunct in the reconstruction of palatal cleft defects. *Oral Surg Oral Med Oral Pathol Oral Radiol Endod*. 1995;80(1):24–7.
- [64] Khojasteh A, Hassani A, Motamedian SR, Saadat S, Alikhasi M. Cortical bone augmentation versus nerve lateralization for treatment of atrophic posterior mandible: A retrospective study and review of literature. *Clin Implant Dent Relat Res*. 2016;18(2):342–59. DOI: 10.1111/cid.12317
- [65] Farré-Guasch E, Martí-Pagè C, Hernández-Alfaro F, Klein-Nulend J, Casals N. Buccal fat pad, an oral access source of human adipose stem cells with potential for osteochondral tissue engineering: An in vitro study *Tissue Eng Part C Methods*. 2010;16(5):1083–94.
- [66] Broccaioli E Niada S, Rasperini G, Ferreira LM, Arrigoni E, Yenagi V, et al. Mesenchymal stem cells from Bichat's fat pad: In vitro comparison with adipose-derived stem cells from subcutaneous tissue. *Biores Open Access*. 2013;2(2):107–17.
- [67] Kahn JL, Wolfram-Gabel R, Bourjat P. Anatomy and imaging of the deep fat of the face. *Clin Anat*. 2000;13(5):373–82.

- [68] Hassani A, Saadat S, Moshiri R, Shahmirzadi S. Hemangioma of the buccal fat pad. *Contemp Clin Dent*. 2014;5(2):243–6. doi: 10.4103/0976-237X.132368.
- [69] Matarasso A. Pseudoherniation of the buccal fat pad: A new clinical syndrome. *Plast Reconstr Surg*. 1997;100(3):723–30.

IntechOpen

IntechOpen