

We are IntechOpen, the world's leading publisher of Open Access books Built by scientists, for scientists

4,800

Open access books available

122,000

International authors and editors

135M

Downloads

Our authors are among the

154

Countries delivered to

TOP 1%

most cited scientists

12.2%

Contributors from top 500 universities



WEB OF SCIENCE™

Selection of our books indexed in the Book Citation Index
in Web of Science™ Core Collection (BKCI)

Interested in publishing with us?
Contact book.department@intechopen.com

Numbers displayed above are based on latest data collected.
For more information visit www.intechopen.com



Neuro-Ophthalmologic Evaluation as a Biomarker for Diagnosis and Progression in Parkinson Disease

María Satue, Vicente Polo, Sofía Otin,
Jose M. Larrosa, Javier Obis and Elena Garcia-Martin

Additional information is available at the end of the chapter

<http://dx.doi.org/10.5772/62877>

Abstract

Objectives: The purpose of current neuro-ophthalmologic research is to evaluate visual dysfunction and its correlation with structural changes in the retina of patients with Parkinson's disease and to examine whether there is an association between retinal thinning and disease progression.

Methods: Patients with Parkinson's disease and controls were included in a series of observational cross-sectional studies and underwent visual function evaluation. Structural measurements of different layers of the retina were obtained using spectral domain optical coherence tomography (SD-OCT). Disease severity was assessed using the Schwab–England Activities of Daily Living scale, the Unified Parkinson Disease Rating Scale, and the Hoehn and Yahr (HY) scale. Comparison of obtained data and correlation analysis between functional and structural results and disease severity was performed. The diagnostic ability of SD-OCT for the detection of Parkinson disease was also tested by the development of two linear discriminant functions (LDFs).

Results: Patients with Parkinson's disease had altered visual function and presented retinal thinning in different sectors. Disease progression correlated with retinal parameters and measurements of retinal thickness was differentiated between healthy subjects and those with advanced Parkinson's disease.

Keywords: Parkinson's disease, optical coherence tomography, retinal nerve fiber layer, retinal ganglion cells, macular thickness

1. Introduction

Parkinson's disease (PD) is well known for its motor symptoms, such as bradykinesia, rigidity, resting tremor, and postural instability. However, the loss of dopaminergic neurons also leads to non-motor alterations, such as depression, dementia, and autonomic dysfunction [1].

Vision is one of the non-motor systems altered in PD. Patients suffering from Parkinson's are reported to have decreased visual acuity (VA), contrast sensitivity, and color vision [2–8]. Recent research demonstrated that retinal thinning in PD patients and axonal damage can be detected and quantified using ocular imaging technologies, such as optical coherence tomography (OCT). The retina is part of the central nervous system and is easily accessible to clinical examination. The retinal nerve fiber layer (RNFL) comprises mainly non-myelinated axons of retinal ganglion cells (RGCs), so RNFL thickness measurements provide a relatively direct assessment of the axons and axonal damage.

OCT provides cross-sectional images of the retina and optic disc based on interference patterns produced by low coherence light reflected from retinal tissues. This technology includes the development of parameters to provide quantitative, objective, and reproducible measurements of the different retinal layers. Recent research on segmentation and analysis of different retinal layers has shown that measures of specific layers, such as the RGC layer provide more accurate information about axonal loss in neurodegenerative diseases [9].

Dopamine in the human retina is released by a set of amacrine cells. These dopaminergic cells are located in the proximal inner nuclear layer of the retina and send long processes to other retinal layers. Dopamine in the mammalian retina modulates color vision and contrast sensitivity through dopaminergic receptors (D1 and D2), which are differentially located in the retinal layers. A complete lack of D1 and D2 receptor activation leads to signal dispersion and alterations in color vision and contrast sensitivity.

The diagnosis of idiopathic PD is based on medical history and neurologic examination, and it sometimes takes several years to obtain a definitive diagnosis. Thus, new technologies and accurate tests are needed to improve and accelerate the diagnostic procedure in early stages of PD.

Recent research using OCT technology has demonstrated that parameters provided by OCT are accurate to detect various inner retinal or optic nerve pathologies, such as multiple sclerosis, PD, or Alzheimer disease [10–15]. At present, no clear guidelines are available on whether one, several, or all of the retinal parameters provided by OCT can be used in the diagnosis of PD.

Current research in the field of neuro-ophthalmology focuses on the evaluation of visual dysfunction in PD and its correlation with retinal alterations in these patients. Recent studies in PD have evaluated the association between macular, ganglion cell layer, and RNFL defects and PD severity, as well as the possible diagnostic ability of OCT technology [9, 15, 16].

The main objective of this study was to provide a better understanding of the role of retinal layers in PD and a diagnostic tool for the early detection of this neurodegenerative pathology.

2. Neuro-ophthalmologic evaluation of PD patients

2.1. Visual dysfunction in PD

Vision comprises many simultaneous functions that are important for daily life activities, such as mobility, reading, driving, and facial recognition [17–20]. Thus, it is important to assess the functional capability of the visual pathways by measuring VA, color vision, visual fixation, objects visual tracking, and contrast sensitivity and to evaluate the impact of vision loss on a person's ability to perform everyday visual tasks.

PD patients are reported to have decreased contrast sensitivity and color vision [2–8]. Previous studies have indicated that PD patients lose foveal contrast sensitivity to patterns to which normal observers are most sensitive (that is, requiring the least contrast for detection of letters, shapes, and figures) [3, 4]. In the retina, ganglion cells adapt to visual contrast and pool the visual information of their receptive fields through a network of parallel bipolar cells with smaller receptive fields [21]. Additionally, contrast sensitivity and color vision are modulated through dopaminergic receptors, which are located in the inner retinal layers. A complete lack of activation of these receptors leads to signal dispersion and alterations in color vision and contrast sensitivity [22].

In our hospital, we evaluated a cohort of 37 patients with PD and analyzed possible alterations in their visual function. We assessed VA, contrast sensitivity vision (CSV), and color vision in these patients and compared the results with healthy controls.

The diagnosis of PD was based on standard clinical and neuroimaging criteria [23]. Patients with significant refractive errors (>5 diopters of spherical equivalent refraction or 3 diopters of astigmatism), intraocular pressure ≥ 21 mm Hg, media opacifications, concomitant ocular diseases including history of glaucoma or retinal pathology, and systemic conditions that could affect the visual system were excluded from the study. The healthy controls had no history and no evidence of ocular or neurologic disease of any nature, and their best-corrected visual acuity (BCVA) was >20/30 based on the Snellen scale, to ensure all of them could complete the visual function evaluation tests. All subjects underwent a complete neuro-ophthalmic evaluation that included pupillary, anterior segment, and funduscopic examination. All procedures adhered to the tenets of the Declaration of Helsinki, and all participants provided informed consent to participate in the study.

Visual function was assessed by evaluating different functional parameters: BCVA using an ETDRS chart; CSV using the CVS-1000E test and Pelli–Robson chart; and color vision using the Farnsworth D15 and L'Anthony D15 tests.

VA is a measure of the spatial resolution of the visual processing system and is dependent on optical and neural factors, that is, the sharpness of the retinal focus within the eye, the health and functioning of the retina, and the sensitivity of the interpretative faculty of the brain. Thus, the VA in a patient with PD and a healthy eye will depend solely on their neurologic condition. VA can be evaluated using different optotypes (with letters or numbers). For clinical research, the ETDRS chart is considered the gold standard and consists of a set of 10 letters from the Roman alphabet, each of them equally visible (**Figure 1**).




Figure 1. ETDRS charts for evaluation of high and low contrast visual acuity. (A): 100% contrast ETDRS chart. (B): 2.50% contrast ETDRS chart.

The letters are arranged in 14 rows, with 5 letters each, and decrease in size progressively. Results can be expressed as 6/6, 10/10, decimal value or logarithmic scale (LogMar). In the expression 6/6, at 6 m, a human eye with a VA of 6/6 is able to separate contours that are approximately 1.75 mm apart; 6/12 means that a person with 6/6 vision would discern the same optotype from 12 m away (i.e., at twice the distance). The equivalent to 6/6 in decimal digits would be 1.0 and 0.0 in logarithmic scale (LogMar). In our patients, LogMAR VA was evaluated at three different contrast levels: 100, 2.50, and 1.25% (using Low-Contrast Sloan Letter Charts), the percentage indicating the level of contrast, that is, 100% representing black letters over white background and 1.25% light grey letters over white background (**Figure 1**).

CSV provides more complete information about visual function than VA tests. CSV was evaluated in our patients using the Pelli–Robson chart and the CSV-1000E test. The Pelli–Robson is a commonly used test for the evaluation of contrast sensitivity, assessing CSV at one spatial frequency (1 cycle/degree [cpd]). This chart comprises horizontal lines of capital letters organized into groups of three (triplets) with two triplets per line. Within each triplet, all letters have the same contrast. The contrast decreases from one triplet to the next, even within each line. All patients were evaluated at a distance of 1 m from the chart and under controlled photopic conditions (85 cd/m²). The score corresponding to the last triplet of letters seen by the patient was recorded. The CSV-1000E instrument is used worldwide for standardized CSV and glare testing and evaluates CSV at 4 different spatial frequencies (3, 6, 12, and 18 cpd). The chart comprises four rows with 17 circular patches each. The patches present a grating that decreases in contrast moving from left to right across the row (**Figure 2**). Each contrast value for each spatial frequency was transformed into a logarithmic scale according to standardized values.

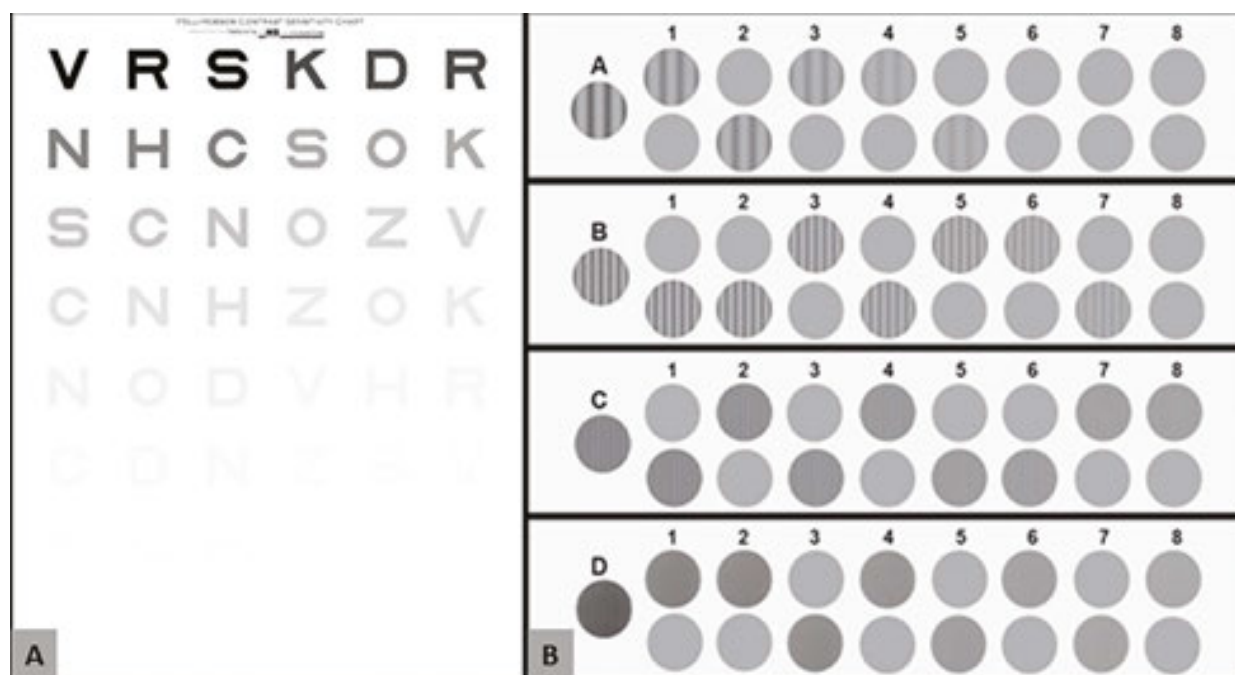


Figure 2. Contrast sensitivity vision tests. (A) Pelli–Robson chart explores contrast sensitivity in one spatial frequency (1 cycle per degree). (B) CSV 1000E test evaluates contrast sensitivity at four different spatial frequencies (3, 6, 12, and 18 cycles per degree).

Color vision was evaluated using the Color Vision Recorder (CVR) program. CVR software is designed for the Windows operating system and analyzes chromatic discrimination by classification of colors (color arrangement using colored caps). CVR includes several classic color tests. All patients in the study were evaluated using the Farnsworth D15 and L'Anthony D15 tests. These tests are often used to differentiate between subjects with severe loss of color vision and those with milder color defects or normal color vision. Different output parameters, such as the age-corrected color confusion index (AC CCI, which represents the ratio between the radius or distance between caps), the Confusion angle (Conf angle, which represents the axis of color deficiency), and the Scatter index (S-index, which represents the parallelism of confusion vectors to the personal confusion angle) were recorded [24, 25]. All these parameters evaluate the severity of dyschromatopsia. For example, an AC CCI score higher than 1, indicates altered color vision perception; the higher the score in the AC CCI and the S-index, the worse the color deficiency.

We found that our patients with PD had a lower BCVA at all three contrast levels of the ETDRS chart compared to the controls (0.18 ± 0.26 in patients vs. -0.065 ± 0.9 in controls at 100%, $p = 0.001$; 0.59 ± 0.21 vs. 0.44 ± 0.13 at 2.50%, $p = 0.01$; and 0.61 ± 0.23 vs. 0.58 ± 0.16 at 1.25%, $p = 0.009$). The Pelli–Robson results revealed a significant reduction in CSV in PD patients ($p = 0.02$). CSV was also affected in patients at all four spatial frequencies of the CSV 1000E chart (3, 6, 12, and 18 cpd; $p = 0.001$, <0.001 , <0.001 , and 0.004 respectively). Color vision was also affected in PD: In our patients, only the L'Anthony test results were significantly altered. L'Anthony test is less saturated than the Farnsworth color test; thus, it is designed to detect very subtle color deficiencies. Our patients performed worse than con-

trols in both tests (higher C-index and S-index, reaching ranges similar to protanomalies), although only the differences in L'Anthony S-index were statistically significant, indicating that our patients had a (subtle) protanomaly (**Table 1**).

	Healthy controls		Parkinson's disease		P
	Mean	SD	Mean	SD	
VA ETDRS 100	-0.06	0.096	0.18	0.26	0.001
VA ETDRS 2.5	0.44	0.13	0.59	0.22	0.010
VA ETDRS 1.25	0.58	0.16	0.62	0.23	0.009
Pelli-Robson	1.89	0.11	1.71	0.17	0.002
CSV 1000 3 cpd	1.72	0.16	1.49	0.35	0.001
CSV 1000 6 cpd	1.94	0.13	1.62	0.34	0.000
CSV 1000 12 cpd	1.62	0.17	1.26	0.41	0.000
CSV 1000 18 cpd	1.11	0.22	0.73	0.34	0.004
Farnsworth AC CCI	1.11	0.22	0.73	0.34	0.851
Farnsworth Conf Angle	63.90	11.15	65.84	7.49	0.392
Farnsworth S-index	1.56	0.22	1.64	0.39	0.278
Farnsworth time	78.67	28.96	82.91	33.10	0.616
L'Anthony AC CCI	1.05	0.19	1.02	0.18	0.489
L'Anthony Conf Angle	62.31	14.74	71.91	9.25	0.002
L'Anthony S-index	1.69	0.43	1.95	0.48	0.020
L'Anthony time	77.14	25.99	84.09	39.31	0.431

Results in bold letters indicate statistical significance ($p < 0.05$).

AC CCI, age-corrected color confusion index; Conf Angle, confusion angle; cpd, cycles per degree; ETDRS, early treatment diabetic retinopathy study; PD, Parkinson disease; S-index, scatter index; VA, visual acuity.

Table 1. Mean and standard deviation (SD) of visual functional parameters in healthy controls and subjects with Parkinson's disease. Results in bold letters indicate statistical significance ($p < 0.05$).

Ganglion cells in the retina show adaptation to visual contrast. The parvo- and magnocellular ganglion cells are located in the RGC layer and take two different pathways for the identification of color and contrast at different frequencies [26]. RGC loss was recently identified as the cause of visual impairment in patients suffering from another neurodegenerative process (multiple sclerosis) [27]. Thus, a similar process could be the cause of the contrast and color deficiencies in PD.

The results found in this study highlight the importance of visual function tests in the evaluation of PD patients and may have important implications for clinical diagnosis of functional deficits in these patients.

2.2. Retinal changes in PD

Parkinson's disease has been associated with alterations in foveal vision. This visual alteration seems to be caused by a dysfunction of the intraretinal dopaminergic circuitry and final retinal output to the brain [2].

Thanks to the new digital imaging technologies applied in the field of ophthalmology, an objective assessment of the retinal layers is now possible. OCT provides a rapid, objective, non-invasive, and reproducible method for the assessment of eye structures thicknesses and volumes.

OCT is an established medical imaging technique that uses light to capture micrometer-resolution, three-dimensional images from within optical scattering media. OCT is based on low-coherence interferometry, usually employing near-infrared light. The use of relatively long wavelength light allows it to penetrate into the scattering medium. The interference of light (caused by the different tissues) occurs at a distance of micrometers. Light with broad bandwidths can be generated using superluminescent diodes or lasers with extremely short pulses.

The OCT device combines the reflected light from two arms (one arm containing the object of study, and a second arm containing usually a mirror) to rise an interference pattern. A reflectivity profile of the sample is obtained by scanning the mirror in the reference arm [28]. Parts of the sample that reflect a lot of light will create greater interference than areas that do not. These higher interference areas will be seen as bright patterns and will correlate with fibrosis or dense retinal layers, whereas low interference areas will be seen as dark patterns and will correlate with fluid. Any light that is outside the short coherence length will not interfere.

There are many studies on neurodegenerative diseases using OCT to detect changes in the RNFL thickness and macular morphology. Regarding PD and the alteration of macular thickness, recent studies have shown a significant thinning in the retinal inner layers of the macular area in patients with PD. Alterations of the retinal layers in PD patients were first demonstrated in 2004 [29]. Since then, various studies have reported different results [29–33].

For the past 5 years, the neuro-ophthalmology research team of Miguel Servet University Hospital has studied retinal structural alterations in PD patients using different OCT devices. Various software applications were used in the evaluation of these patients.

A first cohort of 153 subjects with PD underwent OCT examinations using the Cirrus high-definition (HD) OCT device and the Spectralis OCT device. Two different applications were used for Spectralis OCT, for the analysis of the optic nerve: the *Glaucoma* application (which scans the optic nerve head starting and finishing in the temporal quadrant), and the *Axonal Analytics* application for neurodegenerative diseases (which scans the optic nerve from and to the temporal quadrant) (**Figure 3**).

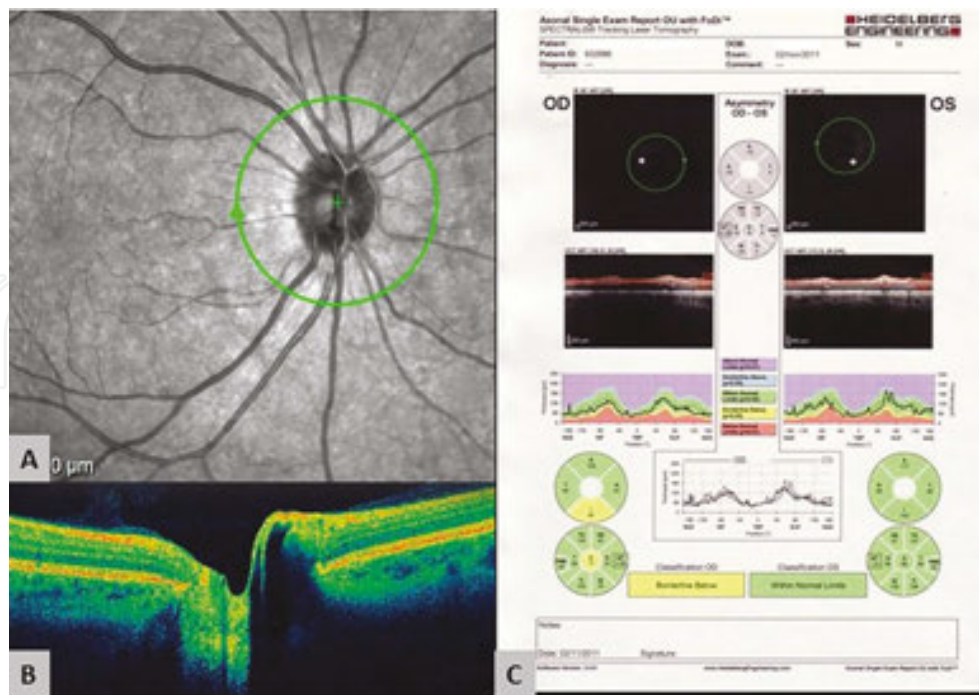


Figure 3 Evaluation of the retinal nerve fiber layer using Axonal Analytics application for Spectralis OCT. (A) Arrow marks the direction of the scan in the optic nerve head. (B) Cross-sectional image of the peripapillary retinal thickness. The retinal layers can be observed in different colors, depending on their interference pattern. (C) OCT report with measurements of the retinal nerve fiber layer in μm .

The difference between both applications resides in the sector with the most accurate measurements: With Glaucoma application, the most accurate sector is nasal, and with Axonal Analytics application is the temporal sector, which is precisely the sector with earlier affectation in neurodegenerative diseases. Macular and peripapillary RNFL thicknesses were evaluated and compared with thicknesses of a group of 242 healthy individuals [9].

The Spectralis OCT measurements revealed significant differences in most of the RNFL sectors using the traditional *Glaucoma* application, and in the mean thickness, the inferior quadrant, the inferonasal, and the inferotemporal RNFL sectors using the *Axonal Analytics* application. The Cirrus OCT measurements revealed significant RNFL differences in mean thickness, and thickness of superior, inferior, and temporal quadrants. Macular thickness was also reduced in patients with PD for all measurements of the inner and outer macular sectors using the Spectralis OCT device; and for the central sector (fovea thickness) and the nasal outer and inferior outer sectors with the Cirrus OCT. Results from this study were published in the *British journal of Ophthalmology* in 2014.

A different cohort of patients underwent retinal evaluation with a new prototype technique for retinal segmentation using the Spectralis OCT [16]. This new software is designed to identify each retinal layer and to measure its thickness. Segmentation of the retinal layers in single horizontal foveal scans was performed automatically by the segmentation application into 10 different layers [16] (**Figure 4**).

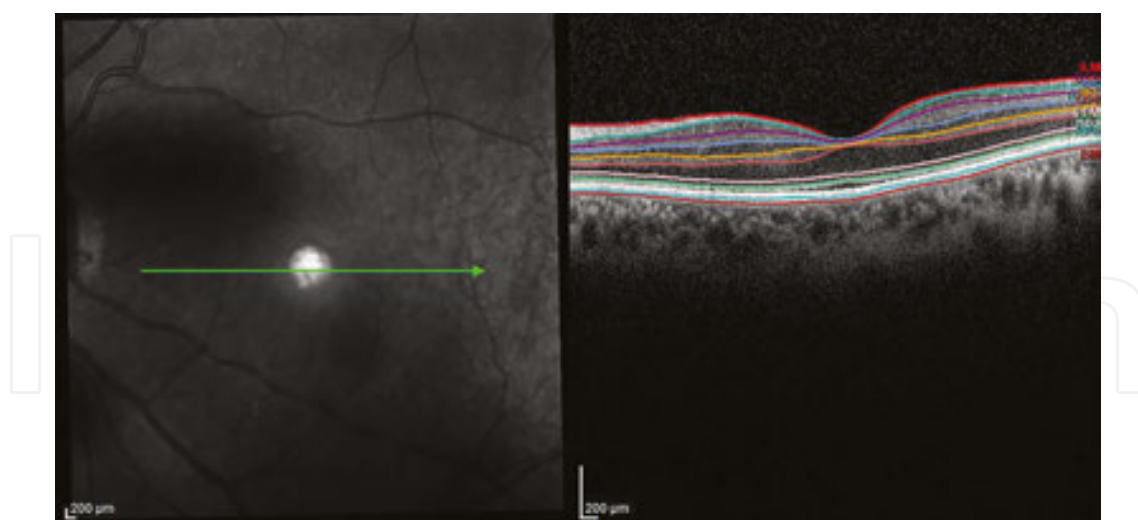


Figure 4 Macular cross-sectional image of a patient with Parkinson's disease, as provided by the segmentation application of Spectralis OCT. The different retinal layers can be observed marked in different colored lines.

All measurements of the macular and peripapillary thickness of the 10 layers were registered in a database for all eyes, and mean thickness of each retinal layer was calculated. A total of 129 eyes from 129 PD patients and 129 eyes of 129 healthy subjects were included in the study.

The segmentation application revealed a significant reduction of the RNFL, ganglion cell layer, the inner plexiform, and outer plexiform layer thickness in PD patients compared with controls. Surprisingly, the inner nuclear layer was significantly thicker in PD patients compared with healthy subjects (**Table 2**). These results were published in 2013 in the *American Journal of Ophthalmology*.

LAYER	Parkinson's disease (n = 129)	Healthy subjects (n = 129)	P*
Inner glial limiting membrane	5.69 ± 2.01	5.68 ± 1.72	0.563
Retinal nerve fiber layer	6.06 ± 1.90	6.26 ± 1.80	0.036
Ganglion cell layer	6.30 ± 1.89	6.49 ± 1.86	0.011
Inner plexiform layer	6.64 ± 1.95	6.77 ± 1.92	0.016
Inner nuclear layer	7.39 ± 1.94	7.14 ± 1.90	0.033
Outer plexiform layer	7.17 ± 1.93	7.31 ± 1.91	0.028
Outer nuclear layer	7.89 ± 1.91	7.95 ± 1.92	0.085
Outer glial limiting membrane	8.20 ± 1.90	8.25 ± 1.96	0.220
Photoreceptors	8.26 ± 1.98	8.29 ± 1.95	0.139
Retinal pigment epithelium	8.58 ± 1.88	8.63 ± 1.89	0.397

Table 2. Mean and standard deviation of retinal thickness in the 10 different retinal layers automatically provided by the segmentation application of the Spectralis optical coherence tomography and comparison between patients with Parkinson's disease and healthy subjects.

The correlation between retinal changes and visual dysfunction in patients suffering from PD was also investigated. A small cohort of 37 patients with PD (37 eyes) underwent visual function tests (see previous section *Visual dysfunction in Parkinson's disease*) and structural analysis of macular thickness, ganglion cell layer (GCL) and RNFL thickness, and linear correlations between functional and structural results were calculated using Pearson's correlation coefficient.

Results demonstrated that CSV was the functional parameter most frequently associated with structural measurements in PD. The Pelli–Robson CSV results correlated with GCL thickness in all sectors, although the association was not strong ($r < 0.5$, $p < 0.05$). The Pelli–Robson measurements also correlated with the thicknesses in different sectors of the peripapillary RNFL (average, superior, and inferior sectors). The CSV-1000E measurements at different spatial frequencies correlated significantly with most GCL measurements: The spatial frequency of 6 cpd correlated with the superonasal thickness ($r = 0.40$, $p = 0.013$), with the superotemporal thickness ($r = 0.44$, $p = 0.006$), with the average GCL + IPL thickness ($r = 0.40$, $p = 0.012$), and with the minimum GCL + IPL ($r = 0.40$, $p = 0.011$). The spatial frequency of 18 cpd correlated with the superotemporal thickness ($r = 0.41$, $p = 0.01$) and the minimum GCL + IPL thickness ($r = 0.43$, $p = 0.006$), showing here the strongest correlations with GCL thickness. Spatial frequencies of 6 and 18 cpd were strongly correlated with average macular thickness ($r = 0.79$, $p = 0.012$; $r = 0.77$, $p = 0.016$, respectively) and macular volume ($r = 0.78$, $p = 0.013$; $r = 0.78$, $p = 0.014$, respectively). Color vision was also associated with the structural parameters, but only those measurements (the C-index and CCI) assessed by the L'Anthony test were significantly correlated with all outer macular parameters and most of the GCL measurements. A significant association between color vision and the RNFL parameters was only found in isolated sectors.

The VA ETDRS results (high and low contrast) correlated strongly with average macular thickness and macular volume (**Table 3**). This was particularly interesting, since this is the first time such a strong correlation between macular thickness, macular volume, and functional parameters (VA and CSV) is reported ($r > 0.70$).

	Macular thickness (correlation coefficient)	P value	Macular volume (correlation coefficient)	P value
VA ETDRS 100	-0.765	0.006	-0.761	0.007
VA ETDRS 1.25	-0.718	0.013	-0.715	0.013
VA ETDRS 2.50	-0.738	0.010	-0.729	0.011

Correlation data in bold type are statistically significant (p value < 0.05).
ETDRS, early treatment diabetic retinopathy study; VA, visual acuity.

Table 3. Correlation between visual acuity measured with ETDRS chart at different levels of contrast (in %) and macular structural measurements (thickness and volume) in patients with Parkinson disease. Results in bold letters indicate statistical significance ($p < 0.05$).

The study on the association between structural and functional parameters is currently pending acceptance for its publication in a peer-reviewed journal.

2.3. Correlation between structural changes and disease severity

The stage and severity of PD were determined in all our patients based on three different rating scales: the Hoehn and Yahr (HY), the Schwab–England activities of daily living (ADL), and the Unified Parkinson’s disease rating score (UPDRS). Patients were tested by a trained neurologist who was blind to the ophthalmology results. Disease duration was also recorded, setting the appearance of the first symptoms as the onset time of the disease.

A correlation analysis between disease severity and structural changes as measured by OCT was performed in the first cohort of patients (153 patients with PD). Correlations between structural data (measured with Cirrus OCT and Spectralis OCT) and the different rating scales were examined by Pearson’s test. The results of this study were published in the *British Journal of Ophthalmology*, in 2014 [9].

The correlation analysis revealed an inverse correlation between most macular thickness measurements assessed by Spectralis OCT and the scores on the HY scale. This means that increased neurological effects and severity of PD progression are linked to thinning of macular tissue. There was a significant correlation between the Schwab–England ADL scores and the outer temporal macular thickness measured with the Cirrus OCT device ($r = 0.284$, $p = 0.010$); and between the Schwab–England ADL scores and the inner inferior macular thickness measured with the Spectralis OCT device ($r = 0.217$, $p = 0.039$). The UPDRS scores were significantly correlated with the inner inferior macular thickness and measured using the Cirrus OCT device ($r = -0.331$, $p = 0.032$). Disease duration was correlated with RNFL thickness measured by the Spectralis OCT device (nasal quadrant using glaucoma application, $p = 0.036$; nasal quadrant and mean thickness using axonal application, $p = 0.016$ and $p = 0.038$, respectively). No correlation between disease duration and Cirrus OCT values was found.

In the second cohort (129 patients and 129 healthy controls), PD patients were divided into two groups depending on disease duration: <10 years (67% of the patients) or at least 10 years (33%). The thickness of the different retinal layers was compared between both patient’s groups using Student’s t-test. Linear agreement between the mean thickness of each retinal layer and three neurologic parameters (duration of disease, HY, and UPDRS scores) was obtained using the Pearson correlation coefficient. A logistical regression analysis was performed to identify which retinal layer thicknesses predicted axonal damage in PD patients.

When analyzing the results, the inner retinal layer thicknesses (RNFL, ganglion cell, and inner plexiform layers) were more affected in PD patients with disease duration of at least 10 years (**Table 4**). GCL thickness correlated inversely with PD duration ($r = -0.221$, $p = 0.046$) and the HY scale ($r = -0.311$, $p = 0.041$), but not the UPDRS scale.

Layer	Parkinson's disease patients with disease duration < 10 years (n:86)	Parkinson's disease patients with disease duration ≥ 10 years (n:43)	P*
Inner glial limiting membrane	5.70 ± 1.95	5.68 ± 1.96	0.211
Retinal nerve fiber layer	6.06 ± 1.87	5.89 ± 1.91	0.028
Ganglion cell layer	6.40 ± 1.92	5.96 ± 1.85	0.031
Inner plexiform layer	6.47 ± 1.91	6.11 ± 1.89	0.009
Inner nuclear layer	7.37 ± 1.91	7.41 ± 1.75	0.111
Outer plexiform layer	7.19 ± 1.91	7.08 ± 1.99	0.136
Outer nuclear layer	7.89 ± 1.98	7.82 ± 1.93	0.356
Outer glial limiting membrane	8.21 ± 1.79	8.20 ± 1.95	0.457
Photoreceptors	8.27 ± 1.90	8.24 ± 1.89	0.665
Retinal pigment epithelium	8.60 ± 1.85	8.57 ± 1.93	0.763

Table 4. Mean and standard deviation of thicknesses in the 10 retinal layers automatically provided by the new segmentation application of the Spectralis optical coherence tomography and comparison between Parkinson disease patients with disease duration of <10 years or at least 10 years.

The regression analysis showed that only the GCL thickness could predict axonal atrophy in PD. Based on the OCT measurements, PD patients with thinner GCL thickness showed a greater decrease in average RNFL thickness. However, thickness of the other retinal layers was not predictive of axonal damage. These results were published in the *American Journal of Ophthalmology*, in 2013 [16].

Our data clearly revealed that disease duration has an impact on the thickness of the RNFL, the GCL, and the inner plexiform layer. The negative correlation between macular thickness, the thickness of the RNFL, and the Hoehn and Yahr score indicates that patients with greater axonal damage tend to have more severe PD symptoms. Our results also indicated that GCL thickness could predict axonal damage in PD patients. GCL atrophy is thought to be a component of RNFL loss, which is suggested to produce consecutive degeneration of the RGC layer and its axons as disease progresses [34, 35].

2.4. The role of OCT in the diagnosis of Parkinson's disease

Because of the difficulty in diagnosing PD, medical organizations have created diagnostic criteria to standardize and simplify the diagnostic process. Diffusion magnetic resonance imaging is a specific technique that may help discriminate between typical and atypical parkinsonism, but its exact diagnostic value is still under investigation.

A definitive diagnosis for PD may take years. Thus, new technologies and accurate tests are needed to improve and accelerate the diagnostic procedure in early stages of the disease. Currently, there are no clear guidelines available on which retinal or RNFL parameters provided by OCT can be used in the diagnosis of PD. Previous research demonstrated that

overall RNFL mean thickness provided by OCT is a good parameter to detect various inner retinal or optic nerve pathologies, such as glaucoma [11], and neurodegenerative disease [10]. Optimal neurodegenerative disease detection, however, is liable to depend on a combination of several parameters. In 2013, our research team published a study in the journal *Retina* that evaluated whether a selective combination of RNFL and retinal OCT parameters could further optimize PD diagnosis. The purpose of this study was to evaluate the diagnostic ability of a linear discriminant function (LDF) for PD, based exclusively on ophthalmologic parameters.

Two independent samples of 100 consecutive healthy subjects and 60 idiopathic patients with PD were recruited from two clinics in the hospital area. The diagnosis of PD was based on the United Kingdom’s BrainBank criteria and the United States National Institute of Neurological Disorders and Stroke criteria [36].

All subjects underwent OCT evaluation to obtain measurements of the peripapillary RNFL and retinal thickness using the Spectralis OCT device. Regression analysis was used, when the dependent variable (to have PD) was dichotomous (yes/no) and the independent variables (all OCT measurements) were of any kind. For logistic regression analysis, the probability that a subject has PD was set as the predicted-dependent variable. The relative importance of each independent variable was evaluated using the forward Wald method, which tests the unique contribution of each predictor in the context of the other predictors. The LDF was calculated by taking the weighted sum of the predictor variables. The significant OCT parameters were combined to generate a new variable (LDF) in such a way that the measurable differences between healthy eyes and eyes with PD were maximized. One hundred and eleven eyes from 60 patients with PD were evaluated. All RNFL scans and retinal measurements provided by the Spectralis OCT were analyzed to calculate three LDFs: the Retinal LDF using the 9 retinal measurements (macular area), the RNFL LDF with 768 RNFL measurements, and the definitive LDF (which combined all OCT measurements). The statistical analysis showed that the Retinal LDF was the best formula. Retinal LDF was defined as follows: $31.173 + \text{temporal outer thickness} \times 0.026 - \text{superior outer thickness} \times 0.267 + \text{nasal outer thickness} \times 0.159 - \text{inferior outer thickness} \times 0.197 - \text{superior inner thickness} \times 0.060 + \text{foveal thickness} \times 0.049$ [36].

For the Retinal LDF, the area under the ROC curves was 0.900 (Table 5).

OCT parameters	AUC	95% CI	AUC P-value	Cut-off point	Sens (%)	Spec (%)
Retinal LDF	0.900	0.862–0.933	<0.001	>–58.4	89.5	80.5
Foveal thickness	0.467	0.409–0.525	0.345	>305	22.4	96.5
Temporal inner thickness	0.737	0.684–0.787	<0.001	≤327	66.3	75.5
Temporal outer thickness	0.680	0.624–0.733	<0.001	≤277	47.2	83.5
RNFL LDF	0.824	0.777–0.865	<0.001	>–0.84	85.6	63.5
RNFL average thickness	0.535	0.478–0.592	0.185	<86	17.1	96.5
RNFL temporal thickness	0.574	0.517–0.630	0.083	>77	32.4	86.5

OCT parameters	AUC	95% CI	AUC P-value	Cut-off point	Sens (%)	Spec (%)
RNFL PMB sector	0.567	0.510–0.623	0.037	>52	65.7	50.0
RNFL N/T index	0.586	0.529–0.641	0.016	≤1.16	65.7	52.5

AUC, area under the receiver operating characteristic curve; CI, confidence interval; LDF, linear discriminant function; OCT, optical coherence tomography; RNFL, retinal nerve fiber layer; Sens, Sensitivity; Spec, Specificity.

Table 5. In the validating set, areas under the receiver operating characteristic curves, best sensitivity-specificity balance, and likelihood ratios of retinal nerve fiber layer parameters of the Nsite Axonal Analytics software of Spectralis optical coherence tomography (OCT) to discriminate between normal subjects and patients with Parkinson's disease.

The largest areas under the ROC curves were those for the Temporal Inner and Outer retinal thickness [36].

3. Discussion

Parkinson's disease patients present decreased high and low contrast VA and CSV, and mild anomalies in color perception. Visual dysfunction in PD is frequently underdiagnosed, since tests designed to detect abnormalities in visual function are not routinely performed in eye examination, and symptoms often go unnoticed by patients.

Neurodegeneration caused by PD can be detected using OCT. Our studies, along with previous research, revealed a reduction in retinal thickness (specifically in the macular area), RNFL and RGC thicknesses in patients suffering from PD. The loss of RGCs has been linked to visual dysfunction and may also be responsible for visual function anomalies in PD patients.

The loss of RGCs leads to a corresponding decrease in retinal and RNFL thicknesses that can be detected using OCT [37, 38]. In PD patients, this loss could be due to primary neurodegeneration of the RGCs and their axons or to retrograde degeneration of the RGC layer plus its axons produced by PD lesions of the posterior visual pathways [39]. Retrograde RGC degeneration produced by retrogeniculate lesions was previously reported in patients with homonymous hemianopia [40], which suggests that OCT measurements reveal combined anterior and posterior visual pathway disease [40, 41].

Our results revealed macular thinning of all areas in patients with PD compared with controls, an inverse correlation with HY and UPDRS severity, and a positive correlation with the Schwab–England ADL scale. Therefore, increased neurologic alterations and severity of PD progression are linked to thinning of macular tissue. The degree of correlation, although significant, was low moderate. These results, however, are consistent with findings in other neurodegenerative diseases [42].

Our segmentation analysis revealed that the GCL thickness was inversely correlated with disease duration and PD severity and was predictive of axonal damage in PD patients. We believe that further research with segmentation application is needed to establish the extent

to which each retinal layer can predict PD in particular circumstances (e.g., recognizing PD when in an early stage), or to evaluate the effectiveness of different treatments.

The retinal measurements provided by Fourier domain OCT technology are tools that can be used in combination with other parameters and clinical explorations. LDF calculated upon OCT parameters may be more sensitive and specific than the methods currently used for diagnosis. Our Retinal LDF yielded higher sensitivity (at a high specificity) than any single parameter determined using OCT. The high sensibility and specificity demonstrated by OCT may be better than some of the accepted neuroimaging criteria in the current PD diagnosis procedure.

The LDFs presented in our study, however, demonstrate better accuracy for PD diagnosis in patients with advanced disease. Clinical application of our findings may help diagnosis in patients who suffer from movement alterations, and PD is suspected. Our results indicate that retinal thinning may be useful for detecting patients with PD. However, larger studies using OCT technology are needed to evaluate the sensitivity, specificity, and the ability of retinal thickness measurements to detect PD. Longitudinal prospective studies should be carried out in the future, to assess disease progression and treatment effectiveness.

Author details

María Satue*, Vicente Polo, Sofía Otin, Jose M. Larrosa, Javier Obis and Elena Garcia-Martin

*Address all correspondence to: mariasatue@gmail.com

IIS Aragon, Ophthalmology Department, Institute for Health Sciences of Aragon (IACS), Miguel Servet University Hospital, Zaragoza, Spain

References

- [1] Park A, Stacy M. Non-motor symptoms in Parkinson's disease. *J Neurol* 2009; 256(Suppl 3): 293–298.
- [2] Bodis-Wollner I. Retinopathy in Parkinson disease. *J Neural Transm* 2009;116:1493–501.
- [3] Bodis-Wollner I. Visual acuity and contrast sensitivity in patients with cerebral lesions. *Science* 1972;178:769–71.
- [4] Bodis-Wollner I, Diamond S. The measurement of spatial contrast sensitivity in cases of blurred vision associated with cerebral lesions. *Brain* 1976;99:695–710.
- [5] Price MJ, Feldman RG, Adelberg D, Kayne H. Abnormalities in color vision and contrast sensitivity in Parkinson's disease. *Neurology* 1992;42:887–90.

- [6] Oh YS, Kim JS, Chung SW, Song IU, Kim YD, Kim YI, Lee KS. Color vision in Parkinson's disease and essential tremor. *Eur J Neurol* 2011;18: 577–83.
- [7] Hipp G, Diederichs NJ, Pieria V, Vaillant M. Primary vision and facial emotion recognition in early Parkinson's disease. *J Neurol Sci* 2014;338: 178–82.
- [8] Archibald NK, Clarke MP, Mosimann UP, Burn DJ. Retinal thickness in Parkinson's disease. *Parkinsonism Relat Disord* 2011; 17(6):431–6.
- [9] Satue M, Seral M, Otin S, Alarcia R, Herrero R, Bambo MP, Fuertes MI, Pablo LE, Garcia-Martin E. Retinal thinning and correlation with functional disability in patients with Parkinson's disease. *Br J Ophthalmol* 2014;98(3):350–5.
- [10] Garcia-Martin E, Pueyo V, Ara JR, Almarcegui C, Martin J, Pablo L, Dolz I, Sancho E, Fernandez FJ. Effect of optic neuritis on progressive axonal damage in multiple sclerosis patients. *Mult Scler* 2011;17:830–837.
- [11] Burgansky-Eliash Z, Wollstein G, Chu T, Glymour C, Noecker RJ, Ishikawa H, Schuman JS. Optical coherence tomography machine learning classifiers for glaucoma detection: a preliminary study. *Investig Ophthalmol Vis Sci* 2005;46:4147–4152.
- [12] Garcia-Martin E, Pueyo V, Martin J, Almarcegui C, Ara JR, Dolz I, Honrubia FM, Fernandez FJ. Progressive changes in the retinal nerve fiber layer in patients with multiple sclerosis. *Eur J Ophthalmol* 2010;20:167–173.
- [13] Garcia-Martin E, Pablo LE, Herrero R, Satue M, Polo V, Larrosa JM, Martin J, Fernandez J. Diagnostic ability of a linear discriminant function for Spectral domain optical coherence tomography in multiple sclerosis patients. *Ophthalmology* 2012;119(8): 1705–11.
- [14] Larrosa JM, Garcia-Martin E, Bambo MP, Pinilla J, Polo V, Otin S, Satue M, Herrero R, Pablo LE. Potential new diagnostic tool for Alzheimer's disease using a linear discriminant function for Fourier domain optical coherence tomography. *Investig Ophthalmol Vis Sci* 2014;55(5):3043–51.
- [15] Garcia-Martin E, Satue M, Otin S, Fuertes I, Alarcia R, Larrosa JM, Polo V, Pablo LE. Retina measurements for diagnosis of Parkinson disease. *Retina* 2014;34(5):971–80.
- [16] Garcia-Martin E, Larrosa JM, Polo V, Satue M, Marques ML, Alarcia R, Seral M, Fuertes I, Otin S, Pablo LE. Distribution of retinal layer atrophy in patients with Parkinson disease and association with disease severity and duration. *Am J Ophthalmol* 2014;157(2):470–478.
- [17] Turano KA, Broman AT, Bandeen-Roche K, Munoz B, Rubin GS, West SK. Association of visual field loss and mobility performance in older adults: salisbury eye evaluation study. *Optom Visi Sci* 2004;81(5):298–307.
- [18] Leat SJ, Woo GC. The validity of current clinical tests of contrast sensitivity and their ability to predict reading speed in low vision. *Eye* 1997;11(6):893–9.

- [19] Wood JM. Age and visual impairment decrease driving performance as measured on a closed-road circuit. *Hum Factors* 2002;44(3):482–94.
- [20] West SK, Rubin GS, Broman AT, Muñoz B, Bandeen-Roche K, Turano K. How does visual impairment affect performance on tasks of everyday life? The SEE project. *Arch Ophthalmol* 2002;120(6):774–80.
- [21] Kim, KJ, Rieke, F. Temporal contrast adaptation in the input and output signals of salamander retinal ganglion cells. *J. Neurosci* 2001;21:287–99.
- [22] Hajee ME, March WF, Lazzaro DR, Wolintz AH, Shrier EM, Glazman S, Bodis-Wollner IG. Inner retinal layer thinning in Parkinson's disease. *Arch Ophthalmol* 2009;127:737–41.
- [23] Gelb DJ, Oliver E, Gilman S. Diagnostic criteria for Parkinson disease. *Arch Neurol* 1999;56:33–9.
- [24] Vingrys AJ, King-Smith PE. A quantitative scoring technique for panel tests of color vision. *Investig Ophthalmol Vis Sci* 1988;29(1):50–63.
- [25] Bowman AJ. A method for quantitative scoring of the Farnsworth panel D15. *Acta Ophthalmol* 1982;60:907–16.
- [26] Laycock R, Crewther SG, Crewther DP. A role for the 'magnocellular advantage' in visual impairments in neurodevelopmental and psychiatric disorders. *Neurosci Biobehav Rev* 2007;31:363–76.
- [27] Lampert EJ, Andorra M, Torres-Torres R, Ortiz-Pérez S, Llufríu S, Sepúlveda M, Sola N, Saiz A, Sánchez-Dalmau B, Villoslada P, Martínez-Lapiscina EH. Color vision impairment in multiple sclerosis points to retinal ganglion cell damage. *J Neurol* 2015;262(11):2491–7.
- [28] Besharse J, Dana J, editors. *Corneal Imaging: Clinical*. Encyclopedia of the Eye, 1st ed. Academic Press Inc; Elsevier 2010. 9780123741981.
- [29] Inzelberg R, Ramirez JA, Nisipeanu P, Ophir A. Retinal nerve fiber layer thinning in Parkinson's disease. *Vis Res* 2004;44:2793–7.
- [30] Cubo E, Tedejo RP, Rodríguez Mendez V. Retina thickness in Parkinson's disease and essential tremor. *Mov Disord* 2010;25:2461–77.
- [31] Satue M, Garcia-Martin E, Fuertes I, Otin S, Alarcia R, Herrero R, Bambo MP, Pablo LE, Fernandez FJ. Use of Fourier-domain OCT to detect retinal nerve fiber layer degeneration in Parkinson's disease patients. *Eye (Lond)* 2013;27:507–14.
- [32] Garcia-Martin E, Satue M, Fuertes, Otin S, Alarcia R, Herrero R, Bambo MP, Fernandez J, Pablo LE. Ability and reproducibility of Fourier domain optical coherence tomography to detect retinal nerve fiber layer atrophy in Parkinson's disease. *Ophthalmology* 2012;119:2161–7.

- [33] Altıntaş O, Işeri P, Ozkan B, Çağlar Y. Correlation between retinal morphological and functional findings and clinical severity in Parkinson's disease. *Doc Ophthalmol* 2008;116:137–46.
- [34] Almarcegui C, Dolz I, Pueyo V, Garcia E, Fernandez FJ, Martin J, Ara JR, Honrubia F. Correlation between functional and structural assessments of the optic nerve and retina in multiple sclerosis patients. *Neurophysiol Clin* 2010;40(3):129–135.
- [35] Davies EC, Galetta KM, Sackel DJ, Talman LS, Frohman EM, Calabresi PA, Galetta SL, Balcer LJ. Retinal ganglion cell layer volumetric assessment by spectral-domain optical coherence tomography in multiple sclerosis: Application of a high precision manual estimation technique. *J Neuroophthalmol* 2011;31(3):260–264.
- [36] Garcia-Martin E, Satue M, Otin S, Fuertes I, Alarcia R, Larrosa JM, Polo V, Pablo LE. Retina measurements for diagnosis of Parkinson disease. *Retina* 2014;34(5):971–80.
- [37] Maresca A, la Morgia C, Caporali L, Valentino ML, Carelli V. The optic nerve: a “mito-window” on mitochondrial neurodegeneration. *Mol Cell Neurosci* 2013;55:62–76.
- [38] La Morgia C, Barboni P, Rizzo G, Carbonelli M, Savini G, Scaglione C, Capellari S, Bonazza S, Giannoccaro MP, Calandra-Buonaura G, Liguori R, Cortelli P, Martinelli P, Baruzzi A, Carelli V. Loss of temporal retinal nerve fibers in Parkinson disease: a mitochondrial pattern? *Eur J Neurol* 2013;20:198–201.
- [39] Albrecht P, Ringelstein M, Müller AK, Keser N, Dietlein T, Lappas A, Foerster A, Hartung HP, Aktas O, Methner A. Degeneration of retinal layers in multiple sclerosis subtypes quantified by optical coherence tomography. *Mult Scler* 2012;18(10):1422–1429.
- [40] Jindahra P, Petrie A, Plant GT. Retrograde trans-synaptic retinal ganglion cell loss identified by optical coherence tomography. *Brain* 2009;132(Pt3):628–634.
- [41] Reich DS, Smith SA, Gordon-Lipkin EM, Ozturk A, Caffo BS, Balcer LJ, Calabresi PA. Damage to the optic radiation in multiple sclerosis is associated with retinal injury and visual disability. *Arch Neurol* 2009;66(8):998–1006.
- [42] Garcia-Martin E, Rodriguez-Mena D, Herrero R, Almarcegui C, Dolz I, Martin J, Ara JR, Larrosa JM, Polo V, Fernández J, Pablo LE. Neuro-ophthalmologic evaluation, quality of life and functional disability in MS patients. *Neurology* 2013;81:1–8.