

We are IntechOpen, the world's leading publisher of Open Access books Built by scientists, for scientists

4,800

Open access books available

122,000

International authors and editors

135M

Downloads

Our authors are among the

154

Countries delivered to

TOP 1%

most cited scientists

12.2%

Contributors from top 500 universities



WEB OF SCIENCE™

Selection of our books indexed in the Book Citation Index
in Web of Science™ Core Collection (BKCI)

Interested in publishing with us?
Contact book.department@intechopen.com

Numbers displayed above are based on latest data collected.
For more information visit www.intechopen.com



Laser Ablation in Neuro-oncology

Mayur Sharma, Danilo Silva,
Suresh Balasubramanian, Gene H. Barnett and
Alireza M. Mohammadi

Additional information is available at the end of the chapter

<http://dx.doi.org/10.5772/62771>

Abstract

Laser interstitial thermal therapy (LITT) has emerged as a potential tool in the armamentarium of neurosurgeons managing patients with deep-seated and difficult-to-access brain tumors. Advances in stereotactic neurosurgery coupled with neuroimaging tools have led to the resurgence of interest in laser therapy for a variety of neurosurgical indications. Stereotactic placement of laser probe using minimally invasive techniques and the ability to monitor the tissue ablation in real time using MR thermometry are two distinct advantages of LITT. Patients with recurrent glioblastoma multiforme (GBM) or newly diagnosed gliomas with significant medical comorbidities, radiation necrosis, radiosurgery-resistant brain metastasis and cancer-related pain pose significant challenges in the field of neuro-oncology. LITT offers an opportunity to obtain stereotactic biopsy and cytoreduction in a minimally invasive nature. In this chapter, we have described the current applications of LITT in neuro-oncology, including malignant gliomas, brain metastatic disease, radiation necrosis and other indications such as cancer-related pain and epilepsy. We have also described the principles, technical nuances and LITT systems currently available in the clinical practice. With growing interest and acceptance of LITT in neuro-oncology, we are likely to obtain high-quality evidence supporting the utility of this modality in patients with a variety of neuro-oncological conditions in the near future.

Keywords: laser therapy, thermal therapy, gliomas, radiation necrosis, brain metastasis, epilepsy, cancer pain

1. Introduction

Laser interstitial thermal therapy (LITT) has established itself as a new treatment modality in neurosurgery due to its minimally invasiveness nature, safety and efficacy. Nowadays, LITT has become a reality in the world of neuro-oncology [1–4], epilepsy surgery [5–7], and is also emerging as an attractive option in the fields of spine surgery [8–10] and chronic pain syndromes [10–12]. In neuro-oncology, LITT has emerged as an option for malignant gliomas, refractory brain metastatic disease and radiation necrosis. LITT is best suited, but not limited, for patients with tumors located in deep-seated, difficult-to-access areas that could develop significant postoperative neurological deficits and poor performance status with traditional microsurgical resection. It is a FDA-approved treatment option for intracranial lesions including recurrent glioblastomas [4]. Concerning brain metastatic disease, although stereotactic radiosurgery (SRS) has become the standard of care for most patients, the failure rate associated with SRS is up to 23% [13–15]. Additionally, the potential risk of developing radiation necrosis following SRS can vary from 1.4 to 24% [16–18], and this complication can be refractory to standard therapeutic options like steroids and Bevacizumab. LITT has been effective in managing both radiosurgery-resistant brain metastasis [2, 3, 19–22] and radiation necrosis [3, 21–24].

The surgical applications of lasers are represented by three distinct functionalities of this technology: photocoagulation, photovaporization and photosensitization [25]. LITT is referred to the first one, photocoagulation, which implies tissue damage by thermal energy provided by a source of constant and continuous laser delivery to a planned target volume. It was first introduced in 1983 by Bown and colleagues [26], who used a neodymium-doped yttrium aluminum garnet (Nd:YAG) laser and achieved focal tissue coagulation in an experimental brain tumor model without tissue vaporization. Research using experimental animal models demonstrated the brain tissue changes in response to hyperthermia and confirmed that coagulation necrosis could result from the application of thermal energy to brain tissue [27–30]. However, the inability to monitor and control the laser-induced thermal effects limited the widespread application of this technology. Recent advances in magnetic resonance (MR) thermography [31] allowed real-time image feedback of laser thermal energy delivery, making it possible to predict the thermal damage of a planned target in the brain.

In the present chapter, the authors describe the current applications of LITT in neuro-oncology, including malignant gliomas, brain metastatic disease and radiation necrosis together with the basic principles and technical nuances related to the surgical procedure and the current LITT systems available in clinical practice. We also touched upon other applications of LITT such as cancer-related refractory pain and epilepsy. Future directions are also discussed in this chapter.

2. Laser interstitial thermal therapy: principles and rationale

Treating cancers with heat energy dates back to 1960s when Rosomoff et al. [32] first reported the application of ruby pulsed laser beam in two patients with GBM and in experimental

animals. They reported that in normal brains of experimental animals, laser application was associated with total cellular destruction with vacuolization secondary to vaporization and hemorrhage. The sensitivity to laser can be increased by Cardio-green and Evans blue injections. Whereas on brain tumors in patients with GBM, laser therapy induced cellular necrosis without hemorrhage and inflammation. Laser bursts were given at 2 min interval at estimated 3 cm depth from the cortical surface, followed by progressive 1 cm depth till approximately 9 cm depth from the surface was reached. Differential susceptibility of normal and tumor to laser application was noted in this study. However, given that the precise application and delivery of laser energy were not feasible at that time, this therapy has fallen out of favor and did not get acceptance in routine clinical practice. In 1985, Winter et al. [33] used microwave hyperthermia for treating brain tumors. Later, brain tumors were treated with focused ultrasound by Britt and coworkers [34]. Following these reports, another study [35] investigated the use of interstitial hyperthermia and iridium brachytherapy in malignant gliomas.

Without the availability of technology to safely monitor the extent of hyperthermia, these techniques remained largely experimental and were unable to be integrated in mainstream clinical practice. When the technological advancements overcome these limitations, thermal ablation using LITT was considered as a more viable, practical and cost-effective approach in treating brain tumors in selected patients. Using LITT, otherwise surgically inaccessible tumors were made amenable to surgical ablation with good outcomes [36, 37]. Though earlier generation probes like Nd-YAG lasers had limitations such as charring of adjacent tissue, thus limiting energy penetration and uncertainties in the extent of tissue ablation [37, 38], new-generation probes have protective mechanisms to prevent charring and also use real-time MR imaging (MR thermometry) to monitor the extent of ablation for minimizing thermal damage to normal surrounding brain parenchyma.

3. Histopathological and biological effects of LITT

Delivering thermal injury with LITT causes some major biological changes in the tissues [39]. Laser photons in the near-infrared range, when directed to the target tissue, get absorbed and converted to heat energy. Aided by abundant blood flow, conduction, convection and refraction all play a significant role in distributing the heat energy around the target tissue [39]. The inherent biology of the surrounding structures and the physical properties of the laser determine the uniformity in the distribution of the heat applied. Ablation of the entire target lesion is the primary aim of using LITT [40].

Cellular homeostasis is usually not disturbed with mild elevation in temperature to approximately 40°C. However, when the temperature is increased in the range of 42 to 45°C (hyperthermia), there is a substantial increase in susceptibility to cellular damage [40, 41]. When the temperature is increased from 46 to 60°C, marked cytotoxicity and cell death ensue with considerably decreased time needed to kill the cells [42, 43]. Above 60°C, there is substantial damage to the mitochondrial enzymes, cytosol and the nucleic acid proteins that culminate to coagulation necrosis [44]. Super boiling temperatures like 105°C results in charring, tissue

boiling, vaporization, and carbonization which if not released immediately might culminate in increased intracranial pressure. Apart from the true values of the temperature used, the time of exposure to such temperatures is also important. For example, 43°C for 2 min causes reversible damage to the tissue, while the same temperature for 10 min causes permanent tissue damage and for 60 min causes coagulative necrosis [22, 45]. Based upon the Arrhenius equation, only shorter intervals are needed when using high temperatures to get the same results [46].

The target lesion usually undergoes central coagulation necrosis following LITT therapy, surrounded by a zone of edema next to the undamaged tissue [36]. By the end of 1st week, granulation tissue gradually replaces the zone of necrosis. The targeted lesion then develops into a cystic lesion with remnant necrotic debris surrounded by reactive gliosis with mesenchymal deposits [47, 48].

Three distinct zones can be identified on MRI following LITT. The first central zone represents the zone of coagulation necrosis and if the temperature inadvertently exceeds 100°C, then there is a chance of charring and vaporization followed by a pseudo cavity formation. Just outside the core area lays a non-viable part with increased interstitial fluid called the intermediate zone. The outermost marginal zone is viable consisting of edematous viable surrounding brain parenchyma following thermal exposure and sharply delineates itself from the inner two zones. The ultra-structure of the inner two zones of thermal injury show disrupted organelles and evidence of apoptosis, whereas the outer zone shows only axonal swelling, neuronal shrinkage and hypertrophied endothelial cells with no evidence of vessel thrombosis [4, 49–51]. Following LITT therapy, the target lesions might exhibit an increase in size due to necrosis and perilesional edema, but eventually will shrink and form a rim of granulation tissue.

4. Technical aspects and commercially available components of LITT

4.1. MR thermometry

After numerous attempts of measuring the thermal energy delivery to the target tissue during LITT, including the use of skin thermometers, subcutaneous and interstitial probes, infrared detectors and thermographic cameras [28, 29, 52–56], it was the addition of MR thermometer that played the most significant role in allowing real-time monitoring and quantification of thermal energy delivery leading to thermal ablation [27]. MR thermography based on the temperature-dependent water proton resonance frequency (PRF) is capable of providing visual imaging together with a quantification model of thermal deposition with accurate temporal and spatial resolution. The theory behind PRF is based on the fact that as temperature increases during LITT, the number of free H₂O molecules also increases due to breakage of hydrogen bonds between H₂O molecules. The hydrogen nuclei (proton) are mobilized more efficiently within the gradient field when in the free H₂O molecule state, producing real-time imaging that can be interpreted and visualized using the proper computer software in the treatment workstation [57, 58].

4.2. Lasers and probes used for LITT

The two most common types of lasers used for LITT are the continuous-wave neodymium-doped yttrium aluminum garnet (Nd:YAG), with a wavelength of 1064 nm, and diode lasers with wavelengths between 800–980 nm, which operate at a wide range of powers [1, 59, 60]. Nd:YAG lasers are capable to achieve deeper tissue penetration compared to diode lasers, especially in soft tissues with high blood perfusion at wavelengths between 1000–1100 nm [59, 61]. Diode lasers have the advantage of producing lesions faster, but typically with less penetration [2].

LITT probes have three main components: an optical fiber with a 600 μm diameter, a heat-resistant terminal tip made of sapphire or quartz, measuring around 10 mm [59] and a cooling system, which is required to avoid overheating, tissue carbonization and optical fiber damage [61]. The current cooling mechanisms use either a cooled gas system (CO_2) or a constant stream of fluid (water or saline) delivered to the tip of the probe through a sheath associated to the optic fiber [60, 62]. The thermal energy delivery at the probe tip has been classically described as a symmetrical ellipsoid shape centered along the axis of the probe. Recent advances in probe design, most specifically by the NeuroBlate[®] System (Monteris Medical Corporation, Plymouth, MN, USA), also led to the development of side firing laser probes, which allows the surgeon to control the laser ablation of complex shaped tumors in a real-time fashion.

4.3. Commercially available LITT systems used in neurosurgery

Currently, there are two commercially available FDA-cleared LITT systems for neurosurgery in the United States: the NeuroBlate[®] System (Monteris Medical Corporation, Plymouth, MN, USA) and the Visualase Thermal Therapy System (Medtronic Inc., Minneapolis, MN, USA).

The Visualase Thermal Therapy System uses a 15 W 980 nm diode laser generator that supplies energy to a disposable 1.65-mm diameter outer cooling catheter, which contains a 1cm-long fiber optic with a light diffusing, tip [2, 63]. The cooling mechanism is provided by circulating sterile saline [2] and limits the duration of laser application to several minutes. Thermal energy is delivered in an ellipsoid-cylindrical fashion. The system is a MRI-guided laser ablation system, which is connected to a computer workstation capable of displaying real-time thermography data at the target location. Thermal information produces color-coded “thermal” and “damage” images [3, 27]. Limit temperatures can be designated as safety points on the pre-treatment MRI such that if during treatment an increase in temperature beyond the designated limit is detected at those points, the laser is automatically deactivated.

The NeuroBlate[®] system consists of a solid-state Dornier diode laser operating at the Nd:YAG wavelength (1064 nm) with a laser output of 30 W. The probes are available at diameters of 3.2 and 2.2 mm. The cooling mechanism is provided by a CO_2 gas-cooled system [22, 45]. One unique feature of this system is that both side-firing and diffuse-tip probes are available. The NeuroBlate[®] directional side-firing laser probe is aimed for contoured ablation of complex shaped targets while the diffusing-tip laser probe is designed to provide fast volumetric

ablation in a concentric fashion. The probes are inserted using frameless stereotactic guidance. The Monteris® Mini-Bolt provides rigid skull fixation and allows a direct interface to the NeuroBlate laser probe. The system is a MRI-guided laser ablation system, which is connected to a computer workstation capable of displaying real-time thermography data at the target location. The NeuroBlate software displays the extent of thermal energy delivered as thermal-damage-threshold (TDT) lines. The yellow line surrounds the target volume that has received the thermal energy equivalent of 43°C for at least 2 min; the blue line surrounds the target volume that has been exposed to 43°C for at least 10 min; finally, the white line corresponds to tissue exposed to 43°C for 60 min. Tissues located outside the yellow TDT line are expected to have no permanent damage, while tissue volume inside the blue line undergoes severe thermal damage and tissue volume within the white line experiences coagulation necrosis [22, 45] (**Figure 1**).

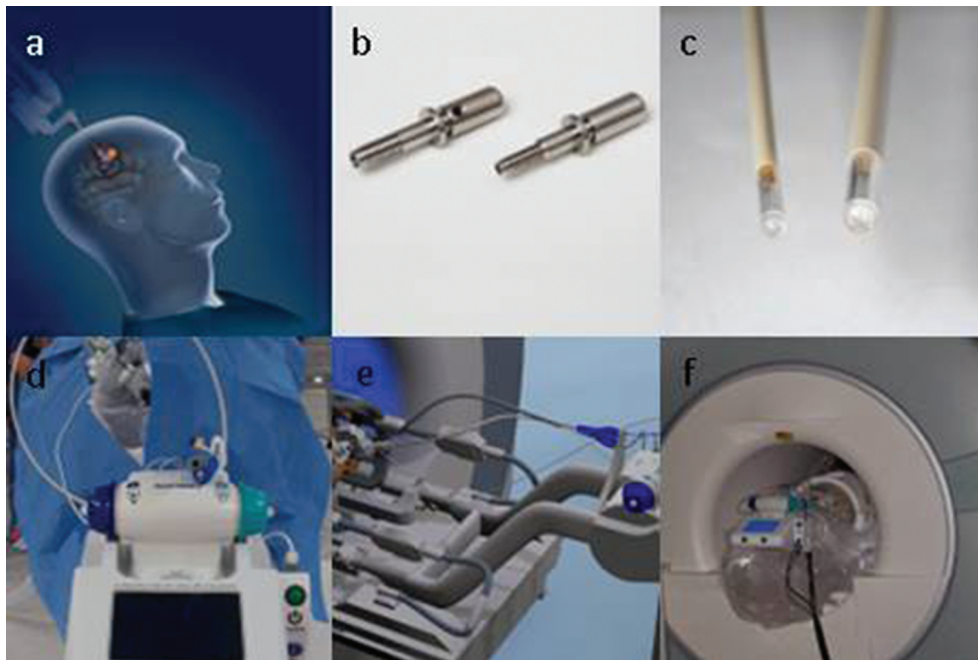


Figure 1. (a–d) show the individual components of NeuroBlate® System including the bolts (b), laser probes (c) and robotic motor drive (d). Figures 1e–f depict the integration of robotic motor drive with the MRI scanner. (Images used by permission from Monteris Medical Corporation, Plymouth, MN, USA. The use of any Monteris Medical photo or image does not imply Monteris' review or endorsement of any article or publication).

Disclosures: Drs. Gene Barnett and Alireza Mohammadi are consultants of Monteris Medical Company (NeuroBlate System). Figure 1 is provided by Monteris Medical Company and is the only contribution of this company in this chapter.

5. Animal models and preclinical studies

Various canine [32, 64, 65] and murine [48, 66–68] animal models of brain tumors have been used to investigate the efficacy of laser thermal therapy on tumors and surrounding brain

tissue, as well as to evaluate the thermal dose models. First, animal experiments evaluating the impact of laser energy on normal murine brains can be dated back to 1960s. Fine et al. [68] used ruby pulsed laser delivering 100 J of energy to the forehead of mice, which resulted in a mortality rate of 75% within a day of exposure. Later, Earle et al. [67] showed that 20–40 J of energy delivered using ruby laser was not lethal and resulted in sub-arachnoid and intracerebral hemorrhage with minimal neurological effects. Later, Rosomoff et al. [32] reported similar findings using 8 J ruby laser in a rat and dog experiment models. They also reported that the sensitivity to laser could be increased by Cardio-green and Evans blue injections. Kangasniemi et al. [64] reported the feasibility and utility of MR-guided laser (980 nm diode) ablation of tumors (transmissible venereal tumors) in seven canines. Utility of LITT was studied in Lewis mice implanted with glioma cells [48] and neoplastic lesion was monitored using MRI. In addition, proliferation of implanted tumor cells, gliosis and apoptosis was monitored using immunohistological techniques. LITT caused necrosis of neoplastic cells; however, apoptosis of residual tumor cells at the margin (more vascularized compared to pre-treatment) was noted following LITT [48]. Canine models have also been used to establish various thermal dose models, so as to reliably predict post-LITT tissue damage as well as to monitor tissue ablation in real time [65]. Localized interstitial thermal therapy using magnetic nanoparticles (dextran- or aminosilane-coated iron-oxide nanoparticles) have been described in a rat model of GBM [69]. Interestingly, rats treated with aminosilane-coated nanoparticles showed improvement in survival (4.5 times prolongation), whereas those treated with dextran-coated particles did not show any difference in survival compared to controls. These animal experiments paved a way to the development of LITT and future therapeutic options for gliomas.

6. Use of LITT in gliomas

High-grade glioma or glioblastoma multiforme (GBM, WHO grade IV), in particular, is a significant clinical challenge in the field of neuro-oncology with a high rate of morbidity and mortality. GBM constitutes approximately 45% of all malignant primary glial neoplasms [70]. Gross total surgical resection with concurrent chemo-radiotherapy is the mainstay treatment modality for this aggressive tumor [71]. However, even with the best available treatment options, 5-year overall survival (OS), progression-free survival (PFS) and median survival have been reported to be 9.9%, 6.9 months and 14.6 months, respectively [59, 71, 72]. The median survival decreases to 12.1 months with post-resection radiotherapy alone instead of concurrent chemo-radiotherapy and to 6.2 months in patients with progressive disease following standard treatment regimen [71, 72]. There is controversial data regarding optimal management (surgical vs. medical) in patients with recurrent GBM. Extent of resection greater than 80% has been shown to have improved overall survival in carefully selected patients with recurrent GBM [73–75]. Young patients with good performance status have been shown to have improved overall survival following surgical resection for recurrent GBM [76, 77]; however, after adjusting for age, no significant benefit was achieved following repeat surgery [77]. In addition, redo craniotomy for progressive GBM is associated with increased risk of per-operative complications including neurological deficits (18–22%) [78, 79]. Also,

there is a cumulative risk of these complications following each craniotomy with maximum risk between first and second procedures [80]. There is insufficient evidence supporting the role of radiosurgery, stereotactic fractionated radiation therapy or interstitial brachytherapy in patients with recurrent GBM [81, 82]. Of note, radiosurgery has also been shown to be associated with increased toxicity in patients with recurrent disease [81]. Survival benefit of 9.3 months have been reported in patients (good performance status) receiving interstitial brachytherapy for recurrent GBM [82]. Given a high incidence of this primary brain tumor with lack of effective therapies and dismal outcome, significant research is directed toward developing effective medical and surgical treatment modalities to improve overall and progression free survival. Laser interstitial thermal therapy (LITT) is one of the advancements in the surgical management of these tumors. LITT is a minimally invasive procedure, which involves stereotactic-guided placement of laser probe and utilizes thermal energy to cause protein coagulation and cell death [83, 84]. Advances in neuroimaging coupled with stereotactic techniques have led to the resurgence of interest in the utility of laser thermocoagulation in patients with brain tumors. In addition, integration of MR thermography to LITT made it possible to deliver thermal energy under real-time monitoring, thus avoiding injury to surrounding normal brain tissue [85]. Given these advantages of LITT, this technique has been utilized for a variety of neurosurgical indications such as deep-seated gliomas [1, 4, 86, 87], epilepsy [20, 88], brain metastasis with radiation necrosis [19, 23, 24, 49] and cingulotomy for intractable pain [12, 89].

First report of utilization of Nd-YAG laser thermal therapy in five patients with deep-seated brain tumors was published in 1990 [90]. Later, several studies with a smaller ($n < 8$) sample size reported the utility of this modality in patients with grade II/III gliomas [36, 87, 91–93]. In 2001, Leonardi et al. [94] reported the utility of stereotactic-guided laser-induced interstitial thermotherapy (SLITT) in 24 patients with residual/recurrent brain tumors [94]. Twenty-four patients with primary glial tumors (17 high grade and 7 low grade gliomas) underwent 30 Nd-YAG laser (1064 nm) procedures under local anesthesia using 0.2T MRI guidance [94]. Interestingly, the tumor ablation was monitored using 3D turbo-FLASH T-1W MRI while laser was applied in steps. Two different lesion architectures at 1108, 1393 J and tissue necrosis at 2979 J were observed on MR imaging during laser ablation. No correlation between the tissue response to thermal treatment and the grade of the tumor was observed in this study [94]. Of note, tumor response rate and clinical outcomes were not reported in this study [94]. Complications such as neurological deficits ($n = 4$), seizures ($n = 2$) and superficial wound infection ($n = 1$) were reported following LITT in this study. A year later, same investigators reported an overall survival of 34, 30 and 9 months in patients with low-grade astrocytoma, anaplastic gliomas and GBM, respectively, following LITT in 24 patients with brain tumors. Similarly, mean time to progression (PFS) for low-grade astrocytoma, anaplastic gliomas and GBM was reported to be 16, 10 and 4 months, respectively, in this study [86]. In 2005, Schwarzmaier et al. [95] reported MR-guided (0.5T) partial ablation using LITT in two patients with recurrent GBM. One of these patients had multifocal GBM, which was found during follow up of primary tumor and underwent LITT for the second focus, whereas second patient had GBM recurrence after standard treatment. Survival of 16 and 20 months following GBM recurrence was reported in this study, thus implicating the role of LITT in achieving im-

proved tumor control and overall survival [95]. A year later, same investigators reported the results of MRgLITT in 16 patients with recurrent GBM with a mean follow up of 9.1 ± 6.3 months [1]. The mean tumor volume treated was 21.6 ± 18.6 cm³, six patients had two procedures and three patients had three LITT procedures. Of these 16 patients, 15 had surgery, 16 had radiotherapy and 6 had chemotherapy prior to LITT and all patients received chemotherapy following LITT. Authors have reported median survival of 5.2 and 11.2 months after recurrence in first the 10 and later 6 patients, respectively, with an overall median survival of 9.4 months after recurrence and 6.9 months after LITT. Authors have attributed this difference in median survival between the first ($n = 10$) and the later cohort ($n = 6$) of patients to the “learning curve” in terms of delay between the tumor recurrence and LITT (2 months vs. 0.3 months in first and later group) [1]. Neurological complications including transient weakness in right upper limb in one patient and non-neurological complications such as neutropenia ($n = 3$), thrombocytopenia ($n = 1$) and deranged liver function tests ($n = 1$) following LITT was reported in this study [1]. Of note, the length of hospital stay was 12.0 ± 4.2 days with no ICU stay and 12 out of 16 patients were dead at the end of the study (7 deaths were due to tumor progression and 5 deaths were due to pulmonary embolism, septic mycosis, gastrointestinal bleeding, sigmoid perforation with peritonitis). Carpentier et al. [96] reported utility of MRgLITT (1.5 T) as a salvage therapy in four patients with recurrent GBM following standard treatment regimen. Five recurrent tumors in four patients (two temporal, one corpus callosum, one centrum semiovale and one temporal) with mean diameter of 16.4 mm under total ablation using Visualase system in this study. All patients except one underwent complete resection prior to salvage LITT. Recurrence was noted following a mean progression-free survival of 37 days and mean overall survival of 10.5 months following LITT, which is longer than the overall survival in patients with recurrent GBM (approximately 4–6 months) [71, 72]. Of note, local recurrence was noted in two patients (45, 30 and 19 days) and another two patients (30 and 60 days) had distant recurrences following LITT. The procedure was well tolerated in all patients with transient adverse effects such as single episode of seizure ($n = 1$), supplementary motor syndrome ($n = 1$) and CSF leak ($n = 1$) [96]. In 2013, the first human phase I study investigating the safety and efficacy of escalating dose of thermal energy using LITT in patients with recurrent GBM was published [4]. This was a multicenter study and enrolled 11 patients at two centers (Cleveland Clinic and UH-case Western Medical Center) from September 2008 to October 2009. Inclusion criterion used in this study was: adult patients with recurrent GBM following standard treatment regimen, KPS ≥ 60 , tumor size 15–40 mm cross-sectional dimension, supratentorial location of the tumor, stable medical comorbidities and no concurrent adjunct therapies. Of note, the primary end point of the study was the safety and feasibility of the NeuroBlate® system whereas the overall survival, progression-free survival, improvement in KP score and change in tumor volumes were the secondary end points [4]. Three thermal dose threshold lines [TDT, yellow (43°C for 2 min), blue (43°C for 10 min) and white lines (43°C for 60 min)] were chosen for the study based on previous animal studies. Ten patients underwent LITT procedure and were followed up for a minimum of 6 months or until death, whichever was earlier. All patients died secondary to disease progression following LITT therapy with a median follow up of 8 months. Three patients were initially enrolled for yellow thermal dose threshold line (43°C for 2 min) to the tumor margin. These three pa-

tients were followed for 14 days and assessed for any toxicity (defined as decrease of 20 or more points on KPS score). If an independent committee in two out of three patients noted toxicity, the thermal dose was either modified or the trial was halted. If there were no consequences during the follow up of 14 days, another three patients were enrolled for blue and white thermal dose threshold lines subsequently using the same protocol [4]. Mean total and treated tumor volume in all treated patients were $6.8 \pm 5 \text{ cm}^3$ and $5 \pm 3.2 \text{ cm}^3$ (78% of total tumor volume), respectively, in this study [4]. The procedure took approximately 2–8 mins/slice and was well tolerated in all the patients with a median hospital stay of 3 days. One entry site infection at 147 days following LITT was reported with no other significant procedure-related complications. Adverse events such as dysphasia with upper limb weakness ($n = 1$), homonymous hemianopia with contralateral weakness ($n = 1$), intracerebral hemorrhage due to rupture of pseudo aneurysm ($n = 1$, 6 weeks after LITT and was managed by endovascular coil placement), white matter injury with hemiparesis ($n = 1$), deep vein thrombosis ($n = 3$), pulmonary embolism ($n = 1$) and grade 3 neutropenia ($n = 1$) were reported following LITT in this study. Post-LITT edema was noted at 48 h MRI and was managed with steroids. Interestingly, one patient with gliosarcoma developed tumor seeding along the biopsy tract involving the skull and epicranial tissue 9 months after the LITT procedure [4]. The median progression-free survival at 6 months and median overall survival were reported to be $\geq 30\%$ (compared to 15% reported in the literature) and 316 days, respectively, following LITT in this study. Two deaths were reported during the follow up and the authors concluded LITT to be safe and effective (especially with blue and white TDT ablated zones) in carefully selected patients with recurrent deep-seated GBMs. DTI tractography and angiography might improve the safety profile of LITT, by delineating the critical neural and vascular structures along the tract of laser probe [4]. Mohammadi et al. [97] investigated the efficacy of LITT in 34 patients with high-grade gliomas HGG (GBM, $n = 24$ and anaplastic astrocytoma/oligodendroglioma, $n = 10$) in difficult-to-access (DTA) areas in a multicenter retrospective study. Of these 34 patients, 16 patients (16 procedures) underwent LITT as an upfront therapy and 18 patients (19 procedures) underwent LITT for recurrent disease. Median time from initial diagnosis of HGG was 29 months for LITT therapy in patients with recurrent disease with a median follow up of 7.2 months following LITT. Following LITT, all patients had standard adjunct treatment and were monitored with serial follow-up MRIs every 3 months. Progression-free survival was the primary end point, whereas overall survival and complications were considered as secondary end points in this study. Frontal lobe was the most common location ($n = 15$), followed by thalamus ($n = 7$), parietal and temporal ($n = 5$ each) and corpus callosum in a single patient. The median tumor volume that was treated using LITT was 10.13 cm^3 and 3 cm was the maximum tumor diameter in this study [97]. And, 98% of tumor volume was covered with yellow TDT lines and 91% with blue TDT lines, with median hospital stay of 3 days. Progression-free survival during the median follow up of 7.2 months was 5.1 months and 71% of treated patients had progressive disease. Majority (52%) of tumor progression following LITT was noted at the periphery of tumor, followed by at the center of the ablated zone (22%), outside the treatment field (22%) and in the contralateral hemisphere (4%). One year estimated survival was $68 \pm 9\%$ and 12 patients (35%) expired due to disease progression during the follow up. Based on the volume of tumor covered by yellow and blue TDT

lines, patients were stratified as favorable ($<0.05 \text{ cm}^3$ tumor volume missed by yellow TDT lines and $<1.5 \text{ cm}^3$ of tumor volume between yellow and blue TDT lines) and unfavorable groups ($\geq 0.05 \text{ cm}^3$ tumor volume missed by yellow TDT lines and $\geq 1.5 \text{ cm}^3$ of tumor volume between yellow and blue TDT lines) [97]. The median PFS in favorable group was 9.7 months, whereas it was 4.6 months in unfavorable group. Interestingly, when controlled for tumor volume of $>10 \text{ cc}$, the effect of TDT line coverage on PFS did not reach significance in this study. In terms of adverse events, 13 adverse events (37%) were noted in this study. Transient ($n = 5$) and permanent ($n = 2$) worsening of preoperative neurological deficits, superficial infection ($n = 1$), deep vein thrombosis ($n = 1$), ventriculitis ($n = 1$), seizure ($n = 1$), hyponatremia ($n = 1$), hydrocephalus ($n = 1$), intracerebral hematoma ($n = 3$) and mortality due to intracerebral hematoma ($n = 1$) were the complications following LITT noted in this study [97]. This study showed LITT to be an efficacious therapy in patients with primary or recurrent high-grade gliomas in difficult to access areas. However, major limitations of this study were its retrospective nature and small sample size. A recent single center retrospective study reported the utility of LITT in patients with a variety of intracranial pathologies including gliomas ($n = 34$) [98]. Total operative time and ablation time were 2.9 ± 0.6 hrs and 9.3 ± 6.5 mins, respectively. Median ICU and hospital stay was 1.0 day each and average hospital stay was 3.6 ± 5.4 days following LITT in this study. There was an overall increase in size of lesion immediately following LITT, followed by a gradual reduction in size 24 h after the procedure which was similar to that at first follow up [98]. Postoperative complications such as neurological worsening ($n = 7$), hemorrhage ($n = 2$), edema ($n = 4$), infection ($n = 1$), inaccurate catheter placement ($n = 2$) and deaths ($n = 2$) were reported [98]. Mortality occurred in two patients with glioblastoma multiforme (midbrain/pons in one patient) who developed malignant cerebral edema following LITT. One patient underwent hemicraniectomy with no successful outcome and died in the same admission. The 30-day readmission rate was 5.6% in this study. Of note, outcome measures such as overall survival, progression-free survival or recurrence were not reported in this study [98].

Although there is no Class 1 evidence supporting the efficacy of LITT in patients with high-grade gliomas, there is also paucity of high-quality data supporting the role of craniotomy and surgical resection in such patients [99]. Given the minimally invasive nature of LITT coupled with advances in neuroimaging stereotactic techniques and thermography, LITT can be a useful treatment modality in patients with poor performance status or medical comorbidities and high-grade glioma. The advantages of LITT have led to the exploration of this technique for a variety of intracranial tumors. LITT has been investigated in various prospective case-controlled studies and there is a likelihood to have Class 2 evidence data in the next couple of years.

7. Use of LITT in brain metastasis and radiation necrosis

Brain metastasis is a common and challenging clinical scenario affecting up to 40% of patients with systemic malignancies [100–102]. Lung carcinoma (16–19%) is the leading systemic cause of brain metastasis followed by renal (6–9%), melanoma (7–7.4%), breast (5%) and colorectal

cancers (1.2–1.8%) [103, 104]. Prognosis in patients with brain metastasis is often dismal, due to limited therapeutic options. Majority of chemotherapeutic agents and targeted immunotherapies do not cross the blood brain barrier, hence limited applicability of these agents in management of patients with brain metastasis. Stereotactic radiosurgery (SRS) has emerged as a primary therapeutic modality in patients with single or multiple brain metastases with an improvement in overall survival and quality of life [13, 14, 105, 106]. However, there is a subset of patients (up to 23%) who fail SRS with progression of metastatic disease and subsequent mortality [13, 15]. Brain metastasis from radio-resistant systemic tumors such as renal cell carcinoma, sarcoma, melanoma and triple negative breast carcinoma carries a worse prognosis, despite better control rates with SRS as compared to conventional radiotherapy [107]. Stereotactic radiosurgery is also associated with adverse radiation effects (AREs) with a 1-year cumulative incidence of 13–14%, which increases with size and volume of the tumor [108–111]. Of these adverse radiation effects, radiation necrosis (RN) is the most challenging in terms of diagnosis and management with a reported incidence ranging between 1.4% and 25% [16–18, 112]. Imaging modalities such as MR perfusion, MR spectroscopy, 6-[(18)F]-fluoro-L-3,4-dihydroxyphenylalanine (F-DOPA)/FDG PET, l-methyl-(11)C-methionine ((11)C-MET) and SPECT scan have been shown to be useful in differentiating radiation necrosis from recurrent metastasis or tumor [113–116]. The sensitivity, specificity, accuracy of perfusion MRI and F-DOPA PET have been reported to be 86.7, 68.2, 75.6 and 90, 92.3, 91.3%, respectively [114]. SPECT scan has been shown to have the highest specificity of 97.8% (sensitivity 87.6%) for differentiating tumor progression and radiation necrosis and may be preferred over other imaging modalities [116]. Medical therapeutic options for RN include corticosteroids, Bevacizumab, hyperbaric oxygen therapy, anticoagulation (heparin or warfarin) or vitamin E [117–125]. Surgical resection of RN can be considered in symptomatic patients with mass effect in accessible areas [125]. Therefore, there is always a scope for newer treatment strategies in the management of patients with brain metastasis to improve the clinical outcomes. LITT is a minimally invasive technique that offers an alternative therapeutic option in patients with either SRS-failed or radio-resistant brain metastasis. LITT also offers an opportunity to have a histological diagnosis before laser ablation in cases of suspicion between recurrence of metastasis and radiation-related changes. The minimally invasive nature of this technology permits its utility in patients with multiple medical comorbidities with poor Karnofsky performance status (KPS) and tumors in difficult-to-access locations.

First use of laser therapy for brain metastasis was reported in 1986, with successful-laser assisted ablation of a midbrain metastasis from primary lung adenocarcinoma [126]. In 1990, Sugiyama et al. [90] reported the utility of laser in patients with deep-seated tumors including metastasis. Later, Schulze et al. [36] studied the histological effects of laser thermotherapy in seven patients with brain metastasis and eight patients with glial tumors. In this study, authors reported that laser therapy created a unique pattern of architectural changes at the histological level with central zone of necrosis surrounded by edematous tissue. This surrounding edematous tissue tends to undergo cystic changes following regenerative and resorptive changes [36]. In addition to thermal coagulation, laser-induced tumor damage is caused by disruption of cellular membranes and organelles. Authors advocated this technique in older patients with significant medical comorbidities and brain tumors. First pilot

clinical trial investigating the safety and feasibility of LITT in patients with resistant focal metastatic brain tumors was reported in 2008 [2]. Four patients with six metastatic brain tumors (temporal lobe, $n = 2$; parietal lobe, $n = 2$; frontal lobe, $n = 1$; and occipital lobe, $n = 1$) were enrolled in this trial. Follow-up MRI scans were performed at 7, 15, 30 and 90 days after the procedure to monitor the zone of thermal necrosis. LITT was well tolerated and all patients were discharged within 14 h after the procedure in this study [2]. There was an acute increase in the tumor volume immediately after the procedure followed by a gradual reduction in the volume during the follow-up imaging. No adverse events, complications or tumor recurrence within the ablated zones were noted during the follow up [2]. Results of this trial were published in 2011, which showed no tumor recurrence in ablated zones in all 7 patients (15 metastatic tumors) at a follow up of 30 months [19]. Mean age of patients enrolled in this study was 54 years, with breast or pulmonary adenocarcinoma and average number of metastasis per patient was 3.3. Total coverage of the tumor under TDT lines was achieved in nine patients and partial coverage in six patients. Single applicator for laser delivery was used in majority of patients ($n = 13$) and two applicators in another two due to complex tumor shape. Majority of tumors were less than 2 cm in size ($n = 10$) and another five were 2–3 cm in size. Mean duration of the procedure and hospital stay was 135 mins and 26 h, respectively, and all patients were discharged within 24 h of procedure [19]. Complications such as blood suffusion, probe misplacement, transient aphasia and cerebellar syndrome were reported following LITT therapy. Of note, there was a mean increase of 26% (range 0–124%) in tumor volume at a mean interval of 4.7 days (range 0–15 days) after the procedure, which returned to baseline volume within 20 days (range 0–75 days). Following LITT, contrast-enhancing rim of the metastasis disappeared in a mean interval of 12.2 months. Mean overall survival and progression-free survival following LITT were 17.4 ± 3.5 months and 3.8 ± 1.0 months, respectively [19].

Another study reported progression-free and overall median survival of 5.8 months each following LITT in five patients with metastasis (non-small cell lung carcinoma, $n = 2$; colon adenocarcinoma, $n = 1$, melanoma, $n = 1$, fallopian tube carcinoma, $n = 1$) [20]. Frontal lobe was involved in two patients, fronto-parietal in one, insula in one and parietal in one patient. Four patients had one trajectory and another two patients had double trajectories for laser therapy. Of note, mean hospital and ICU stay following LITT were 4.4 days and 1 day, respectively, in patients with metastasis [20]. This duration of hospital stay following LITT was significantly higher as compared to previous study by Carpentier et al. [19, 20]. Complications such as transient aphasia (insula) and hemiparesis (frontal) were noted following LITT, which improved gradually with steroids. Patient with melanoma metastasis showed stable tumor size with edema and decrease in size of lesion at 1 and 3 months, respectively, following LITT on follow-up MRI [20]. Two patients had systemic progression; other two had CNS progression and none of the patients required additional treatment in this study.

Torres-Reveron et al. [3] reported the utility of LITT in six patients with progressive brain metastatic tumors (non-small cell lung cancer, $n = 2$; melanoma, $n = 2$; small cell lung cancer, $n = 1$; ovarian cancer, $n = 1$) following SRS. Tumor recurrence was diagnosed using PET and SPECT imaging in two patients, each using these imaging modalities; however interestingly, stereotactic biopsy prior to ablation therapy was negative in all the patients [3]. There was an

increase in length (63%) and width (64%) of the tumor on post-operative MRI at 2 weeks after LITT compared to preoperative size similar to previous studies [19, 20, 24]. However, in concordance with previous studies, tumor size returned to baseline within 4.5 to 6 months following the procedure in all the patients [3]. Interestingly, initial increase in size of lesion was not associated with increase in concurrent FLAIR signal changes on post-operative MRI at 2 weeks after the procedure. These radiological changes were also associated with improvement in clinical symptoms and thus the ability to wean off the patient from steroids. Satisfactory tumor control was achieved in four out of six patients; one patient had progression of systemic disease and died within 1 month of procedure. Another patient had progressive increase in tumor size 3 months after the procedure following initial response, and surgical resection of the tumor showed tumor progression. No significant complications were reported in this study. Similarly, another study investigated the efficacy of LITT in recurrent lesions following stereotactic radiosurgery for brain metastasis [21]. Of note, biopsy and histological diagnosis was not routinely performed in this study and authors advocated LITT irrespective of clinical diagnosis (tumor recurrence vs. radiation necrosis). Seventeen LITT procedures were performed in 16 patients and 14 patients (15 procedures) were available for follow up in this study. Non-small cell lung carcinoma ($n = 12$) was the most common systemic malignancy metastasizing to the brain, followed by breast and colon adenocarcinoma. Average time interval between SRS and LITT was 64.3 weeks [21]. Greater than 25% increase in tumor volume as compared to the immediate post-operative scan (after 24 h) was defined as local treatment failure or recurrence. Mean tumor size that was treated using LITT was 3.66 cm³ and 3.3 lesions were treated per treatment [21]. Mean procedure time, mean duration of ablation and in-patient hospital stay were 136.0, 7.43 and 1.2 days, respectively, in this study. Interestingly, postoperative MRI (within 24 h) revealed an average increase of 278% in tumor volume size following LITT in 12/14 patients and the other two patients showed 74 and 91% decrease in preoperative tumor volume. Subsequently, greater than 10% reduction in tumor volume was observed in seven patients at a median interval of 24 weeks, achieving a local control rate of 75.8% (13 of 15 lesions). Two patients experienced recurrence at 4 and 18 weeks following LITT within the treated zone and underwent surgical resection of the recurrent tumor. The median progression-free survival and overall survival at 39 weeks follow up were 37 weeks and 57%, respectively. Mortality was related to extra cranial disease in five patients and intracranial disease distant from the treated site in one patient. Two complications including non-operative hemorrhage ($n = 1$) and new onset hemiparesis ($n = 1$) was noted following LITT; former patient expired secondary to extra cranial progression and the other patient improved with steroids [21].

A recent study reported delayed failure in two patients who underwent LITT following tumor progression and refractory cerebral edema after SRS [23, 49]. LITT was performed 7 months (breast adenocarcinoma) and 14 weeks (lung adenocarcinoma) after stereotactic radiosurgery. Patient with lung adenocarcinoma metastasis to the external capsule had significant perilesional edema following radiosurgery and also experienced severe side effects secondary to steroid therapy (refractory hyperglycemia, weight gain and bilateral proximal muscle weakness), therefore LITT was considered 14 weeks after SRS [23]. This patient had significant clinical improvement and steroid was weaned off in 2 weeks following ablation therapy.

However, first patient with parietal metastasis and second patient with external capsule metastasis demonstrated tumor recurrence at 6 and 11 months, respectively, which was histologically confirmed following surgical resection [49]. A recent review based on pooled 25 patients with brain metastasis who were treated with LITT reported a median overall survival (OS) of 12.6 months (range 9.0–19.8 months) and progression-free survival (PFS) to vary between 3.8–8.5 months [127]. Severe complication rate was reported to be 8% and included events such as perioperative hemorrhage (non-surgical) and blood suffusion. Intracranial progression of disease (excluding local progression, 8%) and extra cranial progression as the etiology of mortality was reported in 36 and 55% of patients respectively following LITT for brain metastasis. Median survival time (9.0–19.8 months) and severe complication rate of 8% following LITT are similar to 1.4–16.1 months and 6–19%, respectively, following surgical management of brain metastasis [128]. Given these comparable outcomes, LITT is an effective therapeutic option for patients with resistant brain metastasis in difficult-to-access areas. There is a paucity of literature on the utility of LITT in patients with radiation necrosis (RN). It is often difficult to distinguish patients with radiation necrosis and those with tumor recurrence following stereotactic radiosurgery. Therefore, the majority of reported cases could represent a mixture of these clinical conditions, even following stereotactic biopsy. In an anecdotal report, LITT was used for diagnosed RN following stereotactic biopsy (may represent a mixed lesion), as patient was refractory and not able to tolerate standard medical management (steroids and bevacizumab) for suspected RN [24]. Patient developed several steroid-related complications along with several medical comorbidities. In light of these facts and the presence of a lesion in a difficult-to-access area (left centrum semiovale), LITT was considered in this patient with RN following SRS for brain metastasis (non-small cell lung carcinoma). As demonstrated in earlier reports, there was a significant improvement in clinical symptoms following LITT and patient was weaned off the steroid in 2 weeks after the procedure. However, there was a mild increase in size of lesion with no significant FLAIR signal changes at 7 weeks postoperative MRI, which was consistent with the literature.

Patel et al. [98] reported the utility of LITT in patients with a variety of intracranial pathologies including patients with recurrent metastasis or radiation necrosis ($n = 37$) [98]. Total operative time and ablation time were 2.8 ± 0.6 h and 8.7 ± 8.1 mins, respectively. Postoperative complications such as neurological worsening ($n = 7$), hemorrhage ($n = 1$), edema ($n = 1$), infection ($n = 1$) and thermal injury to pituitary leading to secondary complications ($n = 1$) were reported [98]. Overall survival and progression-free survival or recurrence was not reported in this study [98].

LITT has shown initial promising results in patients with recurrent brain metastasis and RN (to some extent) following SRS. However, long-term prospective randomized controlled studies are warranted and required to validate the efficacy of LITT for these clinical indications.

8. Use of LITT in other intracranial tumors

Jethwa et al. [63] reported the application of Visualase laser system in 20 patients (33 procedures) with a variety of intracranial tumors over a period of 1 year. GBM was the most common pathology treated ($n = 6$), followed by metastasis ($n = 4$), ependymoma ($n = 3$), meningioma ($n = 2$), hemangioblastoma ($n = 2$), anaplastic astrocytoma ($n = 1$), chordoma ($n = 1$) and supratentorial primitive neuroectodermal tumor ($n = 1$) in this study. LITT was considered primarily in patients with failed prior treatment (10 out of 20), in surgically inaccessible areas ($n = 3$), patient preference ($n = 3$) or in those in who conventional surgery was considered high risk ($n = 4$) [63]. Majority of patients were treated with single laser application; however, two patients with GBM, one each with metastasis, meningioma, ependymoma underwent two applications and one patient with GBM required three laser applications to cover the tumor volume. One patient each with ependymoma and GBM underwent staged LITT procedure 2 months apart and one with supratentorial primitive neuroectodermal tumor underwent repeat procedure due to tumor recurrence. The average tumor volume and average tumor diameter treated was $7.0 \pm 9.0 \text{ cm}^3$ and $2.4 \pm 0.85 \text{ cm}$. The average ablation time was $13.9 \pm 10.7 \text{ min}$ and median hospital stay of 24 h (average stay of 2.27 days) in this study [63]. It was noted in the study that LITT was well tolerated in the majority of patients with four procedure-related complications. Inaccurate placement of laser probe (patient with cerebellum hemangioblastoma), placement-related hemorrhage (near right sylvian fissure meningioma), pituitary thermal injury (pediatric patient with third ventricle recurrent ependymoma) and significant periprocedural edema (patient with GBM) were reported following 33 LITT procedures in 20 patients. All these complications except pituitary thermal injury required open surgical procedure. Tumor control rates and follow-up imaging were not reported in this study. Another group reported the use of LITT in six patients with intracranial tumors (metastasis, $n = 4$; pituitary prolactinoma, $n = 1$; medullary ependymoma) and one patient with conus ependymoma [129]. Complete ablation was achieved in six out of seven patients and no procedure-related adverse effects were noted in these patients [129]. No long-term outcomes and follow-up results were reported following LITT for these tumors. Recently, Patel et al. [98] reported the utility of LITT using Visualase system in patients with a variety of intracranial tumors such as meningioma ($n = 2$), ependymoma ($n = 3$), hemangioblastoma ($n = 2$), primitive neuroectodermal tumor ($n = 3$), cavernoma ($n = 2$), chordoma ($n = 1$), teratoma ($n = 1$), CNS lymphoma ($n = 1$) and pineal tumor ($n = 1$) [98]. Total operative time and ablation time were $2.8 \pm 0.6 \text{ hrs}$ and $8.7 \pm 8.1 \text{ mins}$, respectively, in all patients with intracranial tumors including glial tumors (GBM, ganglioglioma, pilocytic astrocytoma). Postoperative complications such as neurological worsening ($n = 7$), hemorrhage ($n = 2$), edema ($n = 4$), infection ($n = 1$), inaccurate catheter placement ($n = 2$) and two deaths following LITT were reported [98]. A major limitation of this study was that outcomes including tumor control rates and recurrence were not reported in this study [98]. The procedure was not completed in two patients, one with recurrent meningioma due to hemorrhage during probe insertion which required emergent evacuation and the second patient with hemangioblastoma had inaccurate placement of laser probe which led to abortion of the procedure.

9. Use of LITT in cancer-related pain

Cancer-related pain is a significant clinical problem affecting up to 60–90% of patients with cancer in terminal stages [130]. The first line of management in such patients is pharmacological including opioids; however, 10–20% of such patients are refractory to medical line of management and thus requires intervention for pain management [131–133]. Various neuromodulation and ablative procedures such as intrathecal morphine, myelotomy, cordotomy, DREZotomy, sympathetic blocks, paravertebral blocks and cingulotomy have been described for pharmacological-resistant, cancer-related and various refractory pain syndromes [131–137]. Ablative cingulotomy using radiofrequency [136] and neuromodulation using DBS [138] has been described in patients with various refractory pain syndromes. With the advances in neuroimaging and stereotactic techniques and introduction of LITT, this technique has been explored in patients with pharmacoresistant cancer-related pain [12, 98]. Patel et al. [12] describe the feasibility of MRgLITT in three patients (four procedures) with cancer-related pain. Ablation coordinates used in patients who underwent first-time ablation includes $x = 7.9$ mm (6.9–8.6mm range); $y = 20.5$ mm (20–22 mm range); $Z = 6.9$ mm (2.9–7.0 mm) above the lateral ventricles. Second ablation 1–2 cm above the first ablation was performed in patients with first-time ablation procedures. One patient who underwent ablation for recurrence had three ablations. Median ablation time and volume ablated were 257 seconds and 1.5 cm³, respectively. Median pain severity score (PSS) decreased from 7.7 in preoperative period to 1.6 following the LITT procedure. Similarly, pain interference score (PIS) decreased from 9.9 to 2.0 following the procedure [12]. Median pain reduction was maintained for 5 weeks (2–16 weeks) following LITT and all patients had significant reduction in medication requirements during the period. No significant adverse effects related to the procedure were noted in this study. The advantage of LITT is that the ablation can be monitored in real-time using MR thermography, which was not feasible in earlier ablative techniques.

Another recent study reported the utility of LITT in five patients with chronic pain syndrome [98]. Total operative time and ablation time were 2.9±0.3 h and 4.3±0.6 mins, respectively. No postoperative complications were noted following LITT in patients with chronic pain [98]. Outcomes in terms of pain control was not reported in this study [98].

10. Use of LITT in epilepsy

Pharmacoresistant or drug-resistant epilepsy (DRE) is a significant clinical challenge with prevalence of approximately 28 to 40% in patients with epilepsy [139, 140]. In addition, approximately 10% of pediatric patients with epilepsy meet the criterion of DRE within 18 months of diagnosis [140]. Epilepsy surgery has been shown to have beneficial long-term effects in terms of seizure control (seizure free outcome rate of 67 and 26% at 5 and 15 years follow-up, respectively) and psychosocial outcomes in patients with DRE [141–143]. Based on a recent meta-analysis, the incidence of neurological deficits, permanent neurological deficits,

wound infection/meningitis following temporal lobectomy with/without amygdalohippocampectomy and extratemporal lobar/multilobar resections have been reported to be 5.2, 0.8, 1.1 and 19.5, 3.2, 1.9%, respectively [144]. The complication rates have been shown to increase from 10% during first resective surgery in pediatric patients with complex refractory epilepsy to 50% during second respective surgery [145]. Given this success of epilepsy surgery in controlling seizures with associated morbidity in patients with DRE, there is always a need to improvise on surgical techniques so as to reduce the morbidity while improving the outcomes. Introduction of MRI-guided LITT in neurosurgery over the past decades have paved a way to exploration of this technique in patients with DRE. MRgLITT is a minimally invasive stereotactic technique that can be used to ablate the epileptogenic zone and associate fibers so as to simulate the resection and disconnection procedures, respectively. FDA approved Auto LITT in 2009, following a successful Phase 1 multicenter trial investigating the safety of this system in patients with recurrent GBM. In 2012, Curry et al. [146] first reported the use of MRI-guided (1.5T) LITT (Visualase thermal system) in five patients with DRE. In this study, they ablated six epileptic zones (cingulate tuber $n = 1$, mesial temporal sclerosis $n = 1$, hypothalamic hamartoma $n = 2$ and frontal cortical dysplasia $n = 2$) in five patients with DRE and all patients were reported to be seizure-free at 2–13 months of follow up [146]. No complications were reported in this study. Another study reported the use of this modality in a 3-year-old with a diagnosis of precocious puberty and pharmacoresistant gelastic seizures and MRI showed type III hypothalamic hamartoma (both pedunculated and sessile component) [88]. Patient underwent MRgLITT using Visualase system without perioperative complications. There was significant improvement in behavior and seizures at 2 weeks after the procedure. At 6 months follow up, patient remained seizure-free with improvement in behavior and self-indulging learning patterns such as playing and entertainment [88]. A year later, Wellmer et al. [147] reported the successful use of 3T MR-guided stereotactic radiofrequency thermal coagulation in two patients with DRE due to type IIB frontal focal cortical dysplasia. These focal cortical dysplasias were identified as epileptogenic zones prior to LITT and one of these lesions was in close proximity to the cortico-spinal tract as elicited by the motor-evoked potentials using in-depth electrodes. Both patients were seizure-free at 12 and 5 months with no persistent postoperative complications (one patient had transient mouth paresis) following thermal coagulation [147]. Authors emphasized the importance of precise placement of radiofrequency probe and destruction of epileptogenic zone, taking into account the surrounding eloquent area. Gonzalez-Martinez et al. [148] reported robot (ROSA, Medtech Surgical, Inc.) assisted placement of laser probe (Visualase Inc.) under intraoperative MRI guidance to ablate a periventricular heterotopic lesion in a 19-year-old female with DRE of 10-years duration. Authors reported that combination of robot, LITT and intraoperative MRI is a safe, accurate, efficacious and time-efficient minimally invasive technique that can be used for placement and ablation of epileptogenic zone in patients with DRE [148]. Esquenazi and colleagues [149] reported the utility and feasibility of stereotactic MRgLITT (3T) in two patients with DRE and periventricular nodular heterotopia. One patient underwent temporal lobectomy in addition to LITT and was seizure-free during the follow up and another patient had significant seizure control leading to adjustment in medications following the procedure [149]. Former patient with two procedures had transient visual deficit and no complications in

another patient were reported during the follow up. Stereotactic placement of multiple trajectories to achieve conformity of complex tumor shapes at deeper locations was also described in this report. Recently, Lewis and colleagues [150] described the feasibility and efficacy of MRgLITT in 17 pediatric patients with DRE using Visualase system. In this retrospective study, 17 patients with DRE underwent 19 MRgLITT procedures with a mean follow up of 16.1 months. Focal cortical dysplasia ($n = 12$) was the most common pathology followed by tuberous sclerosis complex ($n = 5$), hypothalamic hamartoma ($n = 1$), mesial temporal sclerosis ($n = 1$), Rasmussen encephalitis ($n = 1$) and tumor ($n = 1$) [150]. One LITT procedure was aborted and one was partially completed leading to completion of LITT in 17 procedures. Nine patients had prior surgeries including two patients had three, one had two and the rest had one procedure each prior to LITT. Engel class I, class II, class III and class IV outcome were achieved in 41, 6, 18 and 35%, respectively, following LITT with an average postprocedure hospital stay of 1.56 days. 38% of patients with Engel class I/II outcomes and 56% of patients with Engel class III/IV outcomes had at least one resective surgery prior to LITT [150]. Inaccurate fiber placement, device malfunction, inaccurate fiber placement with IVH (aseptic meningitis and ventriculostomy) and post-ablation edema/drug-induced gastritis were noted in one patient each leading to eight individual complications in four patients [150]. Patients with lesions <2 cm in size, well-circumscribed solitary lesions and concordant EEG and presurgical data were considered optimal candidates for LITT ablation in this study [150]. Recently, Patel et al. [98] reported the utility of LITT in 10 patients with pharmacoresistant epilepsy [98]. Total operative time and ablation time were 2.6 ± 0.4 h and 7.6 ± 2.3 mins, respectively. No procedure-related complications were noted in this study. However outcome in terms of seizures control was not reported in this study [98]. Based on these studies, LITT has shown promising results in patients with DRE, especially those who require repeat resection surgery with favorable outcome while minimizing morbidity. However, long-term prospective randomized controlled studies are warranted to validate the efficacy of LITT in patients with DRE and to establish appropriate selection and inclusion criterion to achieve favorable outcomes.

11. Future trends

FDA approved AutoLITT in 2009, following a multicenter trial investigating the efficacy of this modality in patients with recurrent GBM. Laser ablation has currently been investigated as a potential treatment modality in patients with failed stereotactic radiosurgery for brain metastasis (NCT01651078, Laser Ablation after Stereotactic Radiosurgery, LAASR study). Following these results, LITT is likely to be explored in other areas of neuro-oncology.

12. Our experience

At Cleveland clinic we have an experience of about 150 patients, who underwent LITT for a variety of indications since 2011. At our center, we use NeuroBlate[®] System (Monteris Medical

Corporation, Plymouth, MN, USA) with a side firing probes (Figure 1). Regarding intra-axial tumors, we have used LITT in 30 patients with de novo GBM, 24 patients with recurrent GBM (following standard treatment), 22 patients with recurrent anaplastic tumors, upfront in 10 patients with anaplastic tumors, 24 patients with low-grade gliomas (7 upfront and 17 recurrent). We have also used this modality in 17 patients with radiation necrosis and 15 patients with metastasis. We are also participating in a multi-institutional study investigating the role of this modality in patients with failed SRS (LAASR study). We have also utilized this therapy in patients with recurrent meningioma ($n = 4$) and schwannoma ($n = 1$, upfront) as well as epilepsy surgery (more than five cases).

13. Conclusion

LITT is a stereotactic minimally invasive technique that involves ablation of pathological tissue using laser energy. This technique has shown promising results in a variety of neuro-oncological conditions such as recurrent GBM, upfront deep-seated GBM, recurrent metastasis following SRS, radiation necrosis and cancer-related pain. LITT was approved by FDA in 2009 for unlimited intracranial usage. Minimally invasive nature of the therapy coupled with real-time monitoring of thermal ablation are distinct advantages of LITT over traditional surgical approaches, especially for deep-seated tumors in patients with significant co-morbidities. Currently, there is Level III /Level IV evidence in the literature supporting the role of LITT in patients with recurrent GBM/high-grade gliomas, metastasis and radiation necrosis. There is a paucity of data regarding other indications of LITT. However, trials are underway and are likely to provide significant level of evidence supporting the efficacy of LITT in a variety of the above-mentioned indications in coming years.

Author details

Mayur Sharma, Danilo Silva, Suresh Balasubramanian, Gene H. Barnett and Alireza M. Mohammadi*

*Address all correspondence to: MOHAMMA3@ccf.org

The Rose Ella Burkhardt Brain Tumor Neuro-Oncology Center, Neurological Institute, Cleveland Clinic, Cleveland, Ohio

References

- [1] Schwarzmaier HJ, Eickmeyer F, von Tempelhoff W, Fiedler VU, Niehoff H, Ulrich SD, Yang Q, Ulrich F. MR-guided laser-induced interstitial thermotherapy of recurrent

- glioblastoma multiforme: preliminary results in 16 patients. *European journal of radiology* 2006;59(2):208–15.
- [2] Carpentier A, McNichols RJ, Stafford RJ, Itzcovitz J, Guichard JP, Reizine D, Delalogue S, Vicaut E, Payen D, Gowda A, George B. Real-time magnetic resonance-guided laser thermal therapy for focal metastatic brain tumors. *Neurosurgery* 2008;63(1 Suppl 1):ONS21-8; discussion ONS8-9.
- [3] Torres-Reveron J, Tomasiewicz HC, Shetty A, Amankulor NM, Chiang VL. Stereotactic laser induced thermotherapy (LITT): a novel treatment for brain lesions regrowing after radiosurgery. *Journal of neuro-oncology* 2013;113(3):495–503.
- [4] Sloan AE, Ahluwalia MS, Valerio-Pascua J, Manjila S, Torchia MG, Jones SE, Sunshine JL, Phillips M, Griswold MA, Clampitt M, Brewer C, Jochum J, McGraw MV, Diorio D, Ditz G, Barnett GH. Results of the neuroblate system first-in-humans phase I clinical trial for recurrent glioblastoma: clinical article. *Journal of neurosurgery* 2013;118(6):1202–19.
- [5] Kang JY, Wu C, Tracy J, Lorenzo M, Evans J, Nei M, Skidmore C, Mintzer S, Sharan AD, Sperling MR. Laser interstitial thermal therapy for medically intractable mesial temporal lobe epilepsy. *Epilepsia* 2016;57(2):325–34.
- [6] Buckley R, Estronza-Ojeda S, Ojemann JG. Laser ablation in pediatric epilepsy. *Neurosurgery clinics of North America* 2016;27(1):69–78.
- [7] Gross RE, Willie JT, Drane DL. The role of stereotactic laser amygdalohippocampotomy in mesial temporal lobe epilepsy. *Neurosurgery clinics of North America* 2016;27(1):37–50.
- [8] Tatsui CE, Stafford RJ, Li J, Sellin JN, Amini B, Rao G, Suki D, Ghia AJ, Brown P, Lee SH, Cowles CE, Weinberg JS, Rhines LD. Utilization of laser interstitial thermotherapy guided by real-time thermal MRI as an alternative to separation surgery in the management of spinal metastasis. *Journal of neurosurgery. Spine* 2015;23(4):400–11.
- [9] Brouwer PA, Brand R, van den Akker-van Marle ME, Jacobs WC, Schenk B, van den Berg-Huijsmans AA, Koes BW, van Buchem MA, Arts MP, Peul WC. Percutaneous laser disc decompression versus conventional microdiscectomy in sciatica: a randomized controlled trial. *The spine journal: official journal of the North American Spine Society* 2015;15(5):857–65.
- [10] Lee GW, Jang SJ, Kim JD. The efficacy of epiduroscopic neural decompression with Ho:YAG laser ablation in lumbar spinal stenosis. *European journal of orthopaedic surgery & traumatology: orthopedie traumatologie* 2014;24(Suppl 1):S231–7.
- [11] Ammar TA. Monochromatic infrared photo energy versus low level laser therapy in chronic low back pain. *Journal of lasers in medical sciences* 2015;6(4):157–61.
- [12] Patel NV, Agarwal N, Mammis A, Danish SF. Frameless stereotactic magnetic resonance imaging-guided laser interstitial thermal therapy to perform bilateral

anterior cingulotomy for intractable pain: feasibility, technical aspects, and initial experience in 3 patients. *Neurosurgery* 2015;11(Suppl 2):17–25; discussion.

- [13] Flickinger JC, Kondziolka D, Lunsford LD, Coffey RJ, Goodman ML, Shaw EG, Hudgins WR, Weiner R, Harsh GR, Sneed PK, et al. A multi-institutional experience with stereotactic radiosurgery for solitary brain metastasis. *International journal of radiation oncology, biology, physics* 1994;28(4):797–802.
- [14] Kondziolka D, Patel A, Lunsford LD, Kassam A, Flickinger JC. Stereotactic radiosurgery plus whole brain radiotherapy versus radiotherapy alone for patients with multiple brain metastases. *International journal of radiation oncology, biology, physics* 1999;45(2):427–34.
- [15] Petrovich Z, Yu C, Giannotta SL, O'Day S, Apuzzo ML. Survival and pattern of failure in brain metastasis treated with stereotactic gamma knife radiosurgery. *Journal of neurosurgery* 2002;97(5 Suppl):499–506.
- [16] Minniti G, Clarke E, Lanzetta G, Osti MF, Trasimeni G, Bozzao A, Romano A, Enrici RM. Stereotactic radiosurgery for brain metastases: analysis of outcome and risk of brain radionecrosis. *Radiation oncology (London, England)* 2011;6:48.
- [17] Jagannathan J, Petit JH, Balsara K, Hudes R, Chin LS. Long-term survival after gamma knife radiosurgery for primary and metastatic brain tumors. *American journal of clinical oncology* 2004;27(5):441–4.
- [18] Kano H, Shuto T, Iwai Y, Sheehan J, Yamamoto M, McBride HL, Sato M, Serizawa T, Yomo S, Moriki A, Kohda Y, Young B, Suzuki S, Kenai H, Duma C, Kikuchi Y, Mathieu D, Akabane A, Nagano O, Kondziolka D, Lunsford LD. Stereotactic radiosurgery for intracranial hemangioblastomas: a retrospective international outcome study. *Journal of neurosurgery* 2015;122(6):1469–78.
- [19] Carpentier A, McNichols RJ, Stafford RJ, Guichard JP, Reizine D, Delalogue S, Vicaut E, Payen D, Gowda A, George B. Laser thermal therapy: real-time MRI-guided and computer-controlled procedures for metastatic brain tumors. *Lasers in surgery and medicine* 2011;43(10):943–50.
- [20] Hawasli AH, Bagade S, Shimony JS, Miller-Thomas M, Leuthardt EC. Magnetic resonance imaging-guided focused laser interstitial thermal therapy for intracranial lesions: single-institution series. *Neurosurgery* 2013;73(6):1007–17.
- [21] Rao MS, Hargreaves EL, Khan AJ, Haffty BG, Danish SF. Magnetic resonance-guided laser ablation improves local control for postradiosurgery recurrence and/or radiation necrosis. *Neurosurgery* 2014;74(6):658–67; discussion 67.
- [22] Sharma M, Balasubramanian S, Silva D, Barnett GH, Mohammadi AM. Laser interstitial thermal therapy in the management of brain metastasis and radiation necrosis after radiosurgery: An overview. *Expert review of neurotherapeutics*. 2016;16(2):223–232.

- [23] Fabiano AJ, Alberico RA. Laser-interstitial thermal therapy for refractory cerebral edema from post-radiosurgery metastasis. *World neurosurgery* 2014;81(3–4):652.e1–4.
- [24] Rahmathulla G, Recinos PF, Valerio JE, Chao S, Barnett GH. Laser interstitial thermal therapy for focal cerebral radiation necrosis: a case report and literature review. *Stereotactic and functional neurosurgery* 2012;90(3):192–200.
- [25] Ryan RW, Spetzler RF, Preul MC. Aura of technology and the cutting edge: a history of lasers in neurosurgery. *Neurosurgical focus* 2009;27(3):E6.
- [26] Bown SG. Phototherapy in tumors. *World journal of surgery* 1983;7(6):700–9.
- [27] Chen L, Wansapura JP, Heit G, Butts K. Study of laser ablation in the in vivo rabbit brain with MR thermometry. *Journal of magnetic resonance imaging: JMRI* 2002;16(2):147–52.
- [28] Cheng MK, McKean J, Boisvert D, Tulip J, Mielke BW. Effects of photoradiation therapy on normal rat brain. *Neurosurgery* 1984;15(6):804–10.
- [29] Elias Z, Powers SK, Atstupenas E, Brown JT. Hyperthermia from interstitial laser irradiation in normal rat brain. *Lasers in surgery and medicine* 1987;7(4):370–5.
- [30] Tracz RA, Wyman DR, Little PB, Towner RA, Stewart WA, Schatz SW, Wilson BC, Pennock PW, Janzen EG. Comparison of magnetic resonance images and the histopathological findings of lesions induced by interstitial laser photocoagulation in the brain. *Lasers in surgery and medicine* 1993;13(1):45–54.
- [31] De Poorter J. Noninvasive MRI thermometry with the proton resonance frequency method: study of susceptibility effects. *Magnetic resonance in medicine* 1995;34(3):359–67.
- [32] Rosomoff HL, Carroll F. Reaction of neoplasm and brain to laser. *Archives of neurology* 1966;14(2):143–8.
- [33] Winter A, Laing J, Paglione R, Sterzer F. Microwave hyperthermia for brain tumors. *Neurosurgery* 1985;17(3):387–99.
- [34] Britt RH, Pounds DW, Lyons BE. Feasibility of treating malignant brain tumors with focused ultrasound. *Progress in experimental tumor research* 1984;28:232–45.
- [35] Roberts DW, Coughlin CT, Wong TZ, Fratkin JD, Douple EB, Strohbehn JW. Interstitial hyperthermia and iridium brachytherapy in treatment of malignant glioma. A phase I clinical trial. *Journal of neurosurgery* 1986;64(4):581–7.
- [36] Schulze PC, Vitzthum HE, Goldammer A, Schneider JP, Schober R. Laser-induced thermotherapy of neoplastic lesions in the brain—underlying tissue alterations, MRI-monitoring and clinical applicability. *Acta neurochirurgica* 2004;146(8):803–12.
- [37] Svaasand LO, Ellingsen R. Optical properties of human brain. *Photochemistry and photobiology* 1983;38(3):293–9.

- [38] Takizawa T. The carbon dioxide laser surgical unit as an instrument for surgery of brain tumours—its advantages and disadvantages. *Neurosurgical review* 1984;7(2–3):135–44.
- [39] Jaunich M, Raje S, Kim K, Mitra K, Guo Z. Bio-heat transfer analysis during short pulse laser irradiation of tissues. *International Journal of Heat and Mass Transfer* 2008;51(23–24):5511–21.
- [40] Goldberg SN, Gazelle GS, Mueller PR. Thermal ablation therapy for focal malignancy: a unified approach to underlying principles, techniques, and diagnostic imaging guidance. *AJR. American journal of roentgenology* 2000;174(2):323–31.
- [41] Seegenschmiedt MH, Brady LW, Sauer R. Interstitial thermoradiotherapy: review on technical and clinical aspects. *American journal of clinical oncology* 1990;13(4):352–63.
- [42] Goldberg SN, Gazelle GS, Halpern EF, Rittman WJ, Mueller PR, Rosenthal DI. Radiofrequency tissue ablation: importance of local temperature along the electrode tip exposure in determining lesion shape and size. *Academic radiology* 1996;3(3):212–8.
- [43] Larson TR, Bostwick DG, Corica A. Temperature-correlated histopathologic changes following microwave thermoablation of obstructive tissue in patients with benign prostatic hyperplasia. *Urology* 1996;47(4):463–9.
- [44] Thomsen S. Pathologic analysis of photothermal and photomechanical effects of laser-tissue interactions. *Photochemistry and photobiology* 1991;53(6):825–35.
- [45] Mohammadi AM, Schroeder JL. Laser interstitial thermal therapy in treatment of brain tumors—the NeuroBlate System. *Expert review of medical devices* 2014;11(2):109–19.
- [46] Laidler KJ. The development of the Arrhenius equation. *Journal of chemical education* 1984;61(6):494.
- [47] Schober R, Bettag M, Sabel M, Ulrich F, Hessel S. Fine structure of zonal changes in experimental Nd:YAG laser-induced interstitial hyperthermia. *Lasers in surgery and medicine* 1993;13(2):234–41.
- [48] Schulze PC, Adams V, Busert C, Bettag M, Kahn T, Schober R. Effects of laser-induced thermotherapy (LITT) on proliferation and apoptosis of glioma cells in rat brain transplantation tumors. *Lasers in surgery and medicine* 2002;30(3):227–32.
- [49] Fabiano AJ, Qiu J. Delayed failure of laser-induced interstitial thermotherapy for postradiosurgery brain metastases. *World neurosurgery* 2014;82(3–4):e559–63.
- [50] Hawasli AH, Ray WZ, Murphy RK, Dacey RG, Jr., Leuthardt EC. Magnetic resonance imaging-guided focused laser interstitial thermal therapy for subinsular metastatic adenocarcinoma: technical case report. *Neurosurgery* 2012;70(2 Suppl Operative):332–7; discussion 8.

- [51] Murovic JA, Chang SD. The pathophysiology of cerebral radiation necrosis and the role of laser interstitial thermal therapy. *World neurosurgery* 2015;83(1):23–6.
- [52] Berns MW, Coffey J, Wile AG. Laser photoradiation therapy of cancer: possible role of hyperthermia. *Lasers in surgery and medicine* 1984;4(1):87–92.
- [53] Dougherty TJ, Grindey GB, Fiel R, Weishaupt KR, Boyle DG. Photoradiation therapy. II. Cure of animal tumors with hematoporphyrin and light. *Journal of the national cancer institute* 1975;55(1):115–21.
- [54] Henderson BW, Waldow SM, Mang TS, Potter WR, Malone PB, Dougherty TJ. Tumor destruction and kinetics of tumor cell death in two experimental mouse tumors following photodynamic therapy. *Cancer research* 1985;45(2):572–6.
- [55] Gomer CJ, Rucker N, Razum NJ, Murphree AL. In vitro and in vivo light dose rate effects related to hematoporphyrin derivative photodynamic therapy. *Cancer research* 1985;45(5):1973–7.
- [56] Marchesini R, Andreola S, Emanuelli H, Melloni E, Schirotti A, Spinelli P, Fava G. Temperature rise in biological tissue during Nd:YAG laser irradiation. *Lasers in surgery and medicine* 1985;5(2):75–82.
- [57] Rieke V, Butts Pauly K. MR thermometry. *Journal of magnetic resonance imaging. JMRI* 2008;27(2):376–90.
- [58] McNichols RJ, Gowda A, Kangasniemi M, Bankson JA, Price RE, Hazle JD. MR thermometry-based feedback control of laser interstitial thermal therapy at 980 nm. *Lasers in surgery and medicine* 2004;34(1):48–55.
- [59] Norred SE, Johnson JA. Magnetic resonance-guided laser induced thermal therapy for glioblastoma multiforme: a review. *BioMed research international* 2014;2014:761312.
- [60] Rahmathulla G, Recinos PF, Kamian K, Mohammadi AM, Ahluwalia MS, Barnett GH. MRI-guided laser interstitial thermal therapy in neuro-oncology: a review of its current clinical applications. *Oncology* 2014;87(2):67–82.
- [61] Stafford RJ, Fuentes D, Elliott AA, Weinberg JS, Ahrar K. Laser-induced thermal therapy for tumor ablation. *Critical reviews in biomedical engineering* 2010;38(1):79–100.
- [62] Anvari B, Tanenbaum BS, Hoffman W, Said S, Milner TE, Liaw LH, Nelson JS. Nd:YAG laser irradiation in conjunction with cryogen spray cooling induces deep and spatially selective photocoagulation in animal models. *Physics in medicine and biology* 1997;42(2):265–82.
- [63] Jethwa PR, Barrese JC, Gowda A, Shetty A, Danish SF. Magnetic resonance thermometry-guided laser-induced thermal therapy for intracranial neoplasms: initial experience. *Neurosurgery* 2012;71(1 Suppl Operative):133–44; 44–5.

- [64] Kangasniemi M, McNichols RJ, Bankson JA, Gowda A, Price RE, Hazle JD. Thermal therapy of canine cerebral tumors using a 980 nm diode laser with MR temperature-sensitive imaging feedback. *Lasers in surgery and medicine* 2004;35(1):41–50.
- [65] Yung JP, Shetty A, Elliott A, Weinberg JS, McNichols RJ, Gowda A, Hazle JD, Stafford RJ. Quantitative comparison of thermal dose models in normal canine brain. *Medical physics* 2010;37(10):5313–21.
- [66] Day ES, Thompson PA, Zhang L, Lewinski NA, Ahmed N, Drezek RA, Blaney SM, West JL. Nanoshell-mediated photothermal therapy improves survival in a murine glioma model. *Journal of neuro-oncology* 2011;104(1):55–63.
- [67] Earle KM, Carpenter S, Roessmann U, Ross MA, Hayes JR, Zeitler E. Central nervous system effects of laser radiation. *Federation proceedings* 1965;24(Suppl 14):129.
- [68] Fine S, Klein E, Nowak W, Scott RE, Laor Y, Simpson L, Crissey J, Donoghue J, Derr VE. Interaction of laser radiation with biologic systems. I. Studies on interaction with tissues. *Federation proceedings* 1965;24(Suppl 14):35–47.
- [69] Jordan A, Scholz R, Maier-Hauff K, van Landeghem FK, Waldoefner N, Teichgraeber U, Pinkernelle J, Bruhn H, Neumann F, Thiesen B, von Deimling A, Felix R. The effect of thermotherapy using magnetic nanoparticles on rat malignant glioma. *Journal of neuro-oncology* 2006;78(1):7–14.
- [70] Ostrom QT, Bauchet L, Davis FG, Deltour I, Fisher JL, Langer CE, Pekmezci M, Schwartzbaum JA, Turner MC, Walsh KM, Wrensch MR, Barnholtz-Sloan JS. The epidemiology of glioma in adults: a “state of the science” review. *Neuro-oncology* 2014;16(7):896–913.
- [71] Stupp R, Hegi ME, Mason WP, van den Bent MJ, Taphoorn MJ, Janzer RC, Ludwin SK, Allgeier A, Fisher B, Belanger K, Hau P, Brandes AA, Gijtenbeek J, Marosi C, Vecht CJ, Mokhtari K, Wesseling P, Villa S, Eisenhauer E, Gorlia T, Weller M, Lacombe D, Cairncross JG, Mirimanoff RO. Effects of radiotherapy with concomitant and adjuvant temozolomide versus radiotherapy alone on survival in glioblastoma in a randomised phase III study: 5-year analysis of the EORTC-NCIC trial. *The Lancet. Oncology* 2009;10(5):459–66.
- [72] Stupp R, Mason WP, van den Bent MJ, Weller M, Fisher B, Taphoorn MJ, Belanger K, Brandes AA, Marosi C, Bogdahn U, Curschmann J, Janzer RC, Ludwin SK, Gorlia T, Allgeier A, Lacombe D, Cairncross JG, Eisenhauer E, Mirimanoff RO. Radiotherapy plus concomitant and adjuvant temozolomide for glioblastoma. *The New England journal of medicine* 2005;352(10):987–96.
- [73] Oppenlander ME, Wolf AB, Snyder LA, Bina R, Wilson JR, Coons SW, Ashby LS, Brachman D, Nakaji P, Porter RW, Smith KA, Spetzler RF, Sanai N. An extent of resection threshold for recurrent glioblastoma and its risk for neurological morbidity. *Journal of neurosurgery* 2014;120(4):846–53.

- [74] Hervey-Jumper SL, Berger MS. Reoperation for recurrent high-grade glioma: a current perspective of the literature. *Neurosurgery* 2014;75(5):491–9; discussion 8–9.
- [75] Chaichana KL, Zadnik P, Weingart JD, Olivi A, Gallia GL, Blakeley J, Lim M, Brem H, Quinones-Hinojosa A. Multiple resections for patients with glioblastoma: prolonging survival. *Journal of neurosurgery* 2013;118(4):812–20.
- [76] Barbagallo GM, Jenkinson MD, Brodbelt AR. 'Recurrent' glioblastoma multiforme, when should we reoperate? *British journal of neurosurgery* 2008;22(3):452–5.
- [77] Ortega A, Sarmiento JM, Ly D, Nuno M, Mukherjee D, Black KL, Patil CG. Multiple resections and survival of recurrent glioblastoma patients in the temozolomide era. *Journal of clinical neuroscience: official journal of the Neurosurgical Society of Australasia* 2016;24:105–11.
- [78] Chang SM, Parney IF, McDermott M, Barker FG, 2nd, Schmidt MH, Huang W, Laws ER, Jr., Lillehei KO, Bernstein M, Brem H, Sloan AE, Berger M. Perioperative complications and neurological outcomes of first and second craniotomies among patients enrolled in the Glioma Outcome Project. *Journal of neurosurgery* 2003;98(6):1175–81.
- [79] Moiyadi AV, Shetty PM. Surgery for recurrent malignant gliomas: feasibility and perioperative outcomes. *Neurology India* 2012;60(2):185–90.
- [80] Hoover JM, Nwojo M, Puffer R, Mandrekar J, Meyer FB, Parney IF. Surgical outcomes in recurrent glioma: clinical article. *Journal of neurosurgery* 2013;118(6):1224–31.
- [81] Tsao MN, Mehta MP, Whelan TJ, Morris DE, Hayman JA, Flickinger JC, Mills M, Rogers CL, Souhami L. The American Society for Therapeutic Radiology and Oncology (ASTRO) evidence-based review of the role of radiosurgery for malignant glioma. *International journal of radiation oncology, biology, physics* 2005;63(1):47–55.
- [82] Chan TA, Weingart JD, Parisi M, Hughes MA, Olivi A, Borzillary S, Alahakone D, Detorie NA, Wharam MD, Kleinberg L. Treatment of recurrent glioblastoma multiforme with GliSite brachytherapy. *International journal of radiation oncology, biology, physics* 2005;62(4):1133–9.
- [83] Anzai Y, Lufkin R, DeSalles A, Hamilton DR, Farahani K, Black KL. Preliminary experience with MR-guided thermal ablation of brain tumors. *AJNR. American journal of neuroradiology* 1995;16(1):39–48; discussion 9–52.
- [84] Sakai T, Fujishima I, Sugiyama K, Ryu H, Uemura K. Interstitial laserthermia in neurosurgery. *Journal of clinical laser medicine & surgery* 1992;10(1):37–40.
- [85] McDannold N. Quantitative MRI-based temperature mapping based on the proton resonant frequency shift: review of validation studies. *International journal of hyperthermia: the official journal of European Society for Hyperthermic Oncology, North American Hyperthermia Group* 2005;21(6):533–46.

- [86] Leonardi MA, Lumenta CB. Stereotactic guided laser-induced interstitial thermotherapy (SLITT) in gliomas with intraoperative morphologic monitoring in an open MR: clinical experience. *Minimally invasive neurosurgery: MIN* 2002;45(4):201–7.
- [87] Kahn T, Bettag M, Ulrich F, Schwarzmaier HJ, Schober R, Furst G, Modder U. MRI-guided laser-induced interstitial thermotherapy of cerebral neoplasms. *Journal of computer assisted tomography* 1994;18(4):519–32.
- [88] Tovar-Spinoza Z, Carter D, Ferrone D, Eksioglu Y, Huckins S. The use of MRI-guided laser-induced thermal ablation for epilepsy. *Child's nervous system: ChNS: official journal of the International Society for Pediatric Neurosurgery* 2013;29(11):2089–94.
- [89] Sundararajan SH, Belani P, Danish S, Keller I. Early MRI characteristics after MRI-guided laser-assisted cingulotomy for intractable pain control. *AJNR. American journal of neuroradiology* 2015;36(7):1283–7.
- [90] Sugiyama K, Sakai T, Fujishima I, Ryu H, Uemura K, Yokoyama T. Stereotactic interstitial laser-hyperthermia using Nd-YAG laser. *Stereotactic and functional neurosurgery* 1990;54–55:501–5.
- [91] Roux FX, Merienne L, Fallet-Bianco C, Beuvon F, Devaux B, Leriche B, Cioloca C. Stereotaxic laser interstitial thermotherapy. A new alternative in the therapeutic management of some brain tumors. *Neuro-Chirurgie* 1992;38(4):238–44.
- [92] Ascher PW, Justich E, Schrottner O. A new surgical but less invasive treatment of central brain tumours Preliminary report. *Acta neurochirurgica. Supplementum* 1991;52:78–80.
- [93] Bettag M, Ulrich F, Schober R, Furst G, Langen KJ, Sabel M, Kiwit JC. Stereotactic laser therapy in cerebral gliomas. *Acta neurochirurgica. Supplementum* 1991;52:81–3.
- [94] Leonardi MA, Lumenta CB, Gumprecht HK, von Einsiedel GH, Wilhelm T. Stereotactic guided laser-induced interstitial thermotherapy (SLITT) in gliomas with intraoperative morphologic monitoring in an open MR-unit. *Minimally invasive neurosurgery: MIN* 2001;44(1):37–42.
- [95] Schwarzmaier HJ, Eickmeyer F, von Tempelhoff W, Fiedler VU, Niehoff H, Ulrich SD, Ulrich F. MR-guided laser irradiation of recurrent glioblastomas. *Journal of magnetic resonance imaging: JMRI* 2005;22(6):799–803.
- [96] Carpentier A, Chauvet D, Reina V, Beccaria K, Leclercq D, McNichols RJ, Gowda A, Cornu P, Delattre JY. MR-guided laser-induced thermal therapy (LITT) for recurrent glioblastomas. *Lasers in surgery and medicine* 2012;44(5):361–8.
- [97] Mohammadi AM, Hawasli AH, Rodriguez A, Schroeder JL, Laxton AW, Elson P, Tatter SB, Barnett GH, Leuthardt EC. The role of laser interstitial thermal therapy in enhancing progression-free survival of difficult-to-access high-grade gliomas: a multicenter study. *Cancer medicine* 2014;3(4):971–9.

- [98] Patel P, Patel NV, Danish SF. Intracranial MR-guided laser-induced thermal therapy: single-center experience with the Visualase thermal therapy system. *Journal of neurosurgery* 2016;1–8.
- [99] Metcalfe SE, Grant R. Biopsy versus resection for malignant glioma. *The Cochrane database of systematic reviews* 2001(3):Cd002034.
- [100] Mintz A, Perry J, Spithoff K, Chambers A, Laperriere N. Management of single brain metastasis: a practice guideline. *Current oncology (Toronto, Ont.)* 2007;14(4):131–43.
- [101] Colaco R, Martin P, Chiang V. Evolution of multidisciplinary brain metastasis management: case study and literature review. *The Yale journal of biology and medicine* 2015;88(2):157–65.
- [102] Nayak L, Lee EQ, Wen PY. Epidemiology of brain metastases. *Current oncology reports* 2012;14(1):48–54.
- [103] Barnholtz-Sloan JS, Sloan AE, Davis FG, Vigneau FD, Lai P, Sawaya RE. Incidence proportions of brain metastases in patients diagnosed (1973 to 2001) in the Metropolitan Detroit Cancer Surveillance System. *Journal of clinical oncology: official journal of the American Society of Clinical Oncology* 2004;22(14):2865–72.
- [104] Schouten LJ, Rutten J, Huveneers HA, Twijnstra A. Incidence of brain metastases in a cohort of patients with carcinoma of the breast, colon, kidney, and lung and melanoma. *Cancer* 2002;94(10):2698–705.
- [105] Soon YY, Tham IW, Lim KH, Koh WY, Lu JJ. Surgery or radiosurgery plus whole brain radiotherapy versus surgery or radiosurgery alone for brain metastases. *The Cochrane database of systematic reviews* 2014;3:Cd009454.
- [106] Greto D, Scoccianti S, Compagnucci A, Arilli C, Casati M, Francolini G, Cecchini S, Loi M, Desideri I, Bordi L, Bono P, Bonomo P, Meattini I, Detti B, Livi L. Gamma Knife radiosurgery in the management of single and multiple brain metastases. *Clinical neurology and neurosurgery* 2015;141:43–7.
- [107] Powell JW, Chung CT, Shah HR, Canute GW, Hodge CJ, Bassano DA, Liu L, Mitchell L, Hahn SS. Gamma Knife surgery in the management of radioresistant brain metastases in high-risk patients with melanoma, renal cell carcinoma, and sarcoma. *Journal of neurosurgery* 2008;109(Suppl):122–8.
- [108] Yamamoto M, Hara M, Ide M, Ono Y, Jimbo M, Saito I. Radiation-related adverse effects observed on neuro-imaging several years after radiosurgery for cerebral arteriovenous malformations. *Surgical neurology* 1998;49(4):385–97; discussion 97–8.
- [109] Chin LS, Ma L, DiBiase S. Radiation necrosis following gamma knife surgery: a case-controlled comparison of treatment parameters and long-term clinical follow up. *Journal of neurosurgery* 2001;94(6):899–904.

- [110] Ganz JC, Reda WA, Abdelkarim K. Adverse radiation effects after Gamma Knife Surgery in relation to dose and volume. *Acta neurochirurgica* 2009;151(1):9–19.
- [111] Sneed PK, Mendez J, Vemer-van den Hoek JG, Seymour ZA, Ma L, Molinaro AM, Fogh SE, Nakamura JL, McDermott MW. Adverse radiation effect after stereotactic radiosurgery for brain metastases: incidence, time course, and risk factors. *Journal of neurosurgery* 2015;123(2):373–86.
- [112] Kohutek ZA, Yamada Y, Chan TA, Brennan CW, Tabar V, Gutin PH, Yang TJ, Rosenblum MK, Ballangrud A, Young RJ, Zhang Z, Beal K. Long-term risk of radionecrosis and imaging changes after stereotactic radiosurgery for brain metastases. *Journal of neuro-oncology* 2015;125(1):149–56.
- [113] Chuang MT, Liu YS, Tsai YS, Chen YC, Wang CK. Differentiating radiation-induced necrosis from recurrent brain tumor using MR perfusion and spectroscopy: a meta-analysis. *PloS one* 2016;11(1):e0141438.
- [114] Cicone F, Minniti G, Romano A, Papa A, Scaringi C, Tavanti F, Bozzao A, Maurizi Enrici R, Scopinaro F. Accuracy of F-DOPA PET and perfusion-MRI for differentiating radionecrotic from progressive brain metastases after radiosurgery. *European journal of nuclear medicine and molecular imaging* 2015;42(1):103–11.
- [115] Terakawa Y, Tsuyuguchi N, Iwai Y, Yamanaka K, Higashiyama S, Takami T, Ohata K. Diagnostic accuracy of ¹¹C-methionine PET for differentiation of recurrent brain tumors from radiation necrosis after radiotherapy. *Journal of nuclear medicine: official publication, Society of Nuclear Medicine* 2008;49(5):694–9.
- [116] Shah AH, Snelling B, Bregy A, Patel PR, Tememe D, Bhatia R, Sklar E, Komotar RJ. Discriminating radiation necrosis from tumor progression in gliomas: a systematic review what is the best imaging modality? *Journal of neuro-oncology* 2013;112(2):141–52.
- [117] Shaw PJ, Bates D. Conservative treatment of delayed cerebral radiation necrosis. *Journal of neurology, neurosurgery, and psychiatry* 1984;47(12):1338–41.
- [118] Kohshi K, Imada H, Nomoto S, Yamaguchi R, Abe H, Yamamoto H. Successful treatment of radiation-induced brain necrosis by hyperbaric oxygen therapy. *Journal of the neurological sciences* 2003;209(1–2):115–7.
- [119] Levin VA, Bidaut L, Hou P, Kumar AJ, Wefel JS, Bekele BN, Grewal J, Prabhu S, Loghin M, Gilbert MR, Jackson EF. Randomized double-blind placebo-controlled trial of bevacizumab therapy for radiation necrosis of the central nervous system. *International journal of radiation oncology, biology, physics* 2011;79(5):1487–95.
- [120] Wong ET, Huberman M, Lu XQ, Mahadevan A. Bevacizumab reverses cerebral radiation necrosis. *Journal of clinical oncology: official journal of the American Society of Clinical Oncology* 2008;26(34):5649–50.

- [121] Gonzalez J, Kumar AJ, Conrad CA, Levin VA. Effect of bevacizumab on radiation necrosis of the brain. *International journal of radiation oncology, biology, physics* 2007;67(2):323–6.
- [122] Liu AK, Macy ME, Foreman NK. Bevacizumab as therapy for radiation necrosis in four children with pontine gliomas. *International journal of radiation oncology, biology, physics* 2009;75(4):1148–54.
- [123] Matuschek C, Bolke E, Nawatny J, Hoffmann TK, Peiper M, Orth K, Gerber PA, Rusnak E, Lammering G, Budach W. Bevacizumab as a treatment option for radiation-induced cerebral necrosis. *Strahlentherapie und Onkologie: Organ der Deutschen Röntgengesellschaft ... [et al]* 2011;187(2):135–9.
- [124] Glantz MJ, Burger PC, Friedman AH, Radtke RA, Massey EW, Schold SC, Jr. Treatment of radiation-induced nervous system injury with heparin and warfarin. *Neurology* 1994;44(11):2020–7.
- [125] Parvez K, Parvez A, Zadeh G. The diagnosis and treatment of pseudoprogression, radiation necrosis and brain tumor recurrence. *International journal of molecular sciences* 2014;15(7):11832–46.
- [126] Tobler WD, Sawaya R, Tew JM, Jr. Successful laser-assisted excision of a metastatic midbrain tumor. *Neurosurgery* 1986;18(6):795–7.
- [127] Banerjee C, Snelling B, Berger MH, Shah A, Ivan ME, Komotar RJ. The role of magnetic resonance-guided laser ablation in neurooncology. *British journal of neurosurgery* 2015;29(2):192–6.
- [128] Paek SH, Audu PB, Sperling MR, Cho J, Andrews DW. Reevaluation of surgery for the treatment of brain metastases: review of 208 patients with single or multiple brain metastases treated at one institution with modern neurosurgical techniques. *Neurosurgery* 2005;56(5):1021–34; discussion 34.
- [129] Vadivelu S, Schulder M. MRI-guided interstitial laser therapy of brain tumours. In: Jolesz FA, ed. *Intraoperative imaging and image-guided therapy*. New York, NY, 2014.
- [130] Daut RL, Cleeland CS. The prevalence and severity of pain in cancer. *Cancer* 1982;50(9):1913–8.
- [131] Bentley JN, Viswanathan A, Rosenberg WS, Patil PG. Treatment of medically refractory cancer pain with a combination of intrathecal neuromodulation and neurosurgical ablation: case series and literature review. *Pain medicine (Malden, Mass.)* 2014;15(9):1488–95.
- [132] Naja Z, Al-Tannir M, Ziade F, Daher M. Management of cancer pain: different intervention techniques. *Le Journal medical libanais. The Lebanese medical journal* 2008;56(2):100–4.

- [133] Harsh V, Viswanathan A. Surgical/radiological interventions for cancer pain. *Current pain and headache reports* 2013;17(5):331.
- [134] Christo PJ, Mazloomdoost D. Interventional pain treatments for cancer pain. *Annals of the New York Academy of Sciences* 2008;1138:299–328.
- [135] Sloan PA. Neuraxial pain relief for intractable cancer pain. *Current pain and headache reports* 2007;11(4):283–9.
- [136] Viswanathan A, Harsh V, Pereira EA, Aziz TZ. Cingulotomy for medically refractory cancer pain. *Neurosurgical focus* 2013;35(3):E1.
- [137] Sharma M, Shaw A, Deogaonkar M. Surgical options for complex craniofacial pain. *Neurosurgery clinics of North America* 2014;25(4):763–75.
- [138] Rasche D, Rinaldi PC, Young RF, Tronnier VM. Deep brain stimulation for the treatment of various chronic pain syndromes. *Neurosurgical focus* 2006;21(6):E8.
- [139] Jobst BC. Consensus over individualism: validation of the ILAE definition for drug resistant epilepsy. *Epilepsy currents/American Epilepsy Society* 2015;15(4):172–3.
- [140] Berg AT, Shinnar S, Levy SR, Testa FM, Smith-Rapaport S, Beckerman B. Early development of intractable epilepsy in children: a prospective study. *Neurology* 2001;56(11):1445–52.
- [141] Wasade VS, Elisevich K, Tahir R, Smith B, Schultz L, Schwalb J, Spanaki-Varelas M. Long-term seizure and psychosocial outcomes after resective surgery for intractable epilepsy. *Epilepsy & behavior E&B* 2015;43:122–7.
- [142] Tellez-Zenteno JF, Dhar R, Wiebe S. Long-term seizure outcomes following epilepsy surgery: a systematic review and meta-analysis. *Brain: a journal of neurology* 2005;128(Pt 5):1188–98.
- [143] Spencer S, Huh L. Outcomes of epilepsy surgery in adults and children. *The Lancet. Neurology* 2008;7(6):525–37.
- [144] Tebo CC, Evins AI, Christos PJ, Kwon J, Schwartz TH. Evolution of cranial epilepsy surgery complication rates: a 32-year systematic review and meta-analysis. *Journal of neurosurgery* 2014;120(6):1415–27.
- [145] Bower RS, Wirrell EC, Eckel LJ, Wong-Kisiel LC, Nickels KC, Wetjen NM. Repeat resective surgery in complex pediatric refractory epilepsy: lessons learned. *Journal of neurosurgery. Pediatrics* 2015;16(1):94–100.
- [146] Curry DJ, Gowda A, McNichols RJ, Wilfong AA. MR-guided stereotactic laser ablation of epileptogenic foci in children. *Epilepsy & behavior: E&B* 2012;24(4):408–14.
- [147] Wellmer J, Kopitzki K, Voges J. Lesion focused stereotactic thermo-coagulation of focal cortical dysplasia IIB: a new approach to epilepsy surgery? *Seizure* 2014;23(6):475–8.
- [148] Gonzalez-Martinez J, Vadera S, Mullin J, Enatsu R, Alexopoulos AV, Patwardhan R, Bingaman W, Najm I. Robot-assisted stereotactic laser ablation in medically intracta-

ble epilepsy: operative technique. *Neurosurgery* 2014;10(Suppl 2):167–72; discussion 72–3.

- [149] Esquenazi Y, Kalamangalam GP, Slater JD, Knowlton RC, Friedman E, Morris SA, Shetty A, Gowda A, Tandon N. Stereotactic laser ablation of epileptogenic periventricular nodular heterotopia. *Epilepsy research* 2014;108(3):547–54.
- [150] Lewis EC, Weil AG, Duchowny M, Bhatia S, Ragheb J, Miller I. MR-guided laser interstitial thermal therapy for pediatric drug-resistant lesional epilepsy. *Epilepsia* 2015;56(10):1590–8.

IntechOpen

