

We are IntechOpen, the world's leading publisher of Open Access books Built by scientists, for scientists

4,800

Open access books available

122,000

International authors and editors

135M

Downloads

Our authors are among the

154

Countries delivered to

TOP 1%

most cited scientists

12.2%

Contributors from top 500 universities



WEB OF SCIENCE™

Selection of our books indexed in the Book Citation Index
in Web of Science™ Core Collection (BKCI)

Interested in publishing with us?
Contact book.department@intechopen.com

Numbers displayed above are based on latest data collected.
For more information visit www.intechopen.com



A Strategy of Bone Regeneration for the Treatment of Idiopathic Femoral Head Necrosis

Tomoki Aoyama

Additional information is available at the end of the chapter

<http://dx.doi.org/10.5772/62478>

Abstract

Femoral head necrosis (FHN) is a difficult disease to treat. FHN results from an obstruction in the blood supply to the femoral head, which causes death of the bone-forming cells. For effective treatment of FHN, an osteogenic cell supply, revascularization, and provision of initial strength to resist collapse are needed. Evidence of favorable outcomes of cell transplantation therapy for the treatment of FHN is emerging. However, outcomes of treatment are influenced by the underlying FHN etiology and clinical stage. Therefore, understanding the epidemiology, clinical stage, and disease status of FHN is essential to inform treatment planning based on evidence. The aim of the chapter is to present and critically discuss the role of cell replacement therapy for the treatment of FHN based on clinical status.

Keywords: Femoral head necrosis, cell-based therapy, radiogenic stage, bone marrow, mesenchymal stromal cell

1. Epidemiology of osteonecrosis of the femoral head

Femoral head necrosis (FHN) is a painful disorder of the hip joint [1, 2]. Without treatment, more than 70% of clinically diagnosed cases of FHN proceed to collapse of the femoral head, requiring prosthetic joint replacement within 3–4 years after diagnosis [3, 4]. FHN typically occurs in adults, 30–40 years old, and is more prevalent in males than females, with evidence of bilateral involvement identified in 75% of cases [2]. The exact pathomechanism of FHN is not well understood. However, obstruction of blood supply caused by steroid use, alcoholism, sickle cell anemia, and femoral neck fracture are predisposing factors due to loss of osteogenic cells in the greater trochanteric region [1, 2].

In the natural history of FHN, 59% of cases progress to symptomatic disease and collapse of the femoral head [5]. The prognosis is different depending on the etiology. FHN resulting from sickle cell disease has the highest risk for progressing to collapse (73%), while 47% of cases due to excessive alcohol consumption are at risk of collapse and 46% of cases resulting from renal failure. The risk for collapse associated with corticosteroid use (26%) and for idiopathic FHN (38%) is comparable to the overall prevalence of collapse (38%). Cases of FHN associated with human immunodeficiency virus infection (15%) or systemic lupus erythematosus (7%) have a relatively lower risk for collapse, compared to the overall prevalence [5]. Therefore, understanding the etiologic factor of FHN is important for treatment planning.

Nonoperative treatment of FHN has been shown to have limited success in preventing disease progression [2]. Consequently, the use of joint preserving procedures has decreased in the United States, from being the treatment of choice in 25% of cases of FHN in 1992 compared to 12% of cases in 2008. Over the same period, total hip replacement for the management of FHN has increased from 75% in 1992 to 88% in 2008 [6].

2. Clinical stage assessed by radiographic image and prognosis

The clinical stages of FHN progression are classified based on radiographic examination, with magnetic resonance imaging (MRI) and bone scintigraphy used in the early stages. Although different radiographic classifications of clinical stage have been proposed, the underlying concept and indices of change are comparable between each classification [7–9]. The stage and classification, evaluated from plane, anterior–posterior, radiography images, are useful to understand the prognosis of FHN and to plan for treatment (**Table 1**). The classification of the Association Research Circulation Osseous (ARCO) Committee is the most widely used clinical grading classification for osteonecrosis of the femoral head (ONHF). The stages of FHN are defined as follows. Stage 1 is the identification of an osteonecrosis lesion by MRI and bone scintigraphy, with a marginal reaction emerging as a band of low signal intensity on T1-weighted images and a band of high signal intensity on T2-weighted images. Stage 2 is defined by radiographic appearance of demarcated regions of sclerosis and lucency. Blood vessels enter the necrotic zone as part of a repair process of bone resorption and formation, while toward the margin of the reactive interface, dead cancellous bone is invested by fibrous and lamellar tissues. In stage 3, resorption of bone causes fractures within the subchondral bone, with resulting segmental fractures identified on the radiographs by the ‘crescent sign.’ Stage 3 is subdivided into stage 3A, collapse of the femoral head <3 mm, and stage 3B, collapse of the femoral head ≥3 mm. In stage 4, osteoarthritic joint space narrowing, with osteophyte formation, is identified. According to Steinberg’s classification, after stage 5, osteoarthritic changes are advanced.

The radiographic classification of the Specific Disease Investigation Committee (SDIC), under the auspices of the Japanese Ministry of Health, Labour and Welfare, defines the progression of FHN based on the extent of involvement of the weight-bearing surface of the femoral head (**Figure 1**) [9]. Plane, anterior–posterior radiographs are used to evaluate the necrotic area, and

the three types of lesions are defined as follows. The type A lesion occupies the medial one-third or less of the weight-bearing surface of the femoral head, while the type B lesion occupies the medial two-thirds or less of the weight-bearing surface. The type C lesion occupies more than two-thirds of the weight-bearing surface and is subdivided into C1 and C2 types: the C2 lesion extends laterally to the edge of the acetabulum, whereas the C1 lesion does not. Mont et al. [5] reported a risk for progression to collapse of 9% for type A lesions, 19% for type B lesions, and 59% for type C lesions. Nishii et al. [10] calculated an odds ratio (OR) for the incidence of collapse of the femoral head with type C lesions of 10.8 (95% confidence interval, 2.4–48.0), and an OR for progressive collapse of 26.0 (95% confidence interval, 1.9–358.5).

	Ficat	Steinberg	ARCO
Stage 1	Normal radiographs	Normal radiographs; abnormal bone scan and MRI	Normal radiographs; however, specific findings are observed on MRI, bone scintigraphy, or histology
Stage 2	Subchondral cyst formation and sclerosis	“Cystic” and sclerotic changes in femoral head	Demarcating sclerosis without collapse of the femoral head
Stage 3	Femoral head flattening, subchondral collapse, “crescent sign”	Subchondral collapse without femoral head flattening	Femoral head collapse, “crescent sign,” no joint space narrowing
3A			Collapse <3 mm
3B			Collapse >3 mm
Stage 4	Osteoarthritic joint space narrowing, degenerative changes	Subchondral collapse, femoral head flattening, normal joint space	Osteoarthritic degenerative changes
Stage 5		Flattening, with joint space narrowing, acetabular changes, or both	
Stage 6		Advanced degenerative changes, secondary osteoarthritis	

Notes: ARCO, Association Research Circulation Osseous; MRI, magnetic resonance imaging.

Table 1. Clinical staging of osteonecrosis.

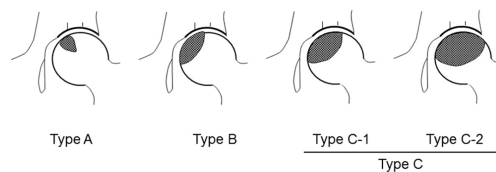


Figure 1 Radiographic classification of the Specific Disease Investigation Committee, under the auspices of the Japanese Ministry of Health, Labour and Welfare.

3. The treatment of FHN without cell-based therapy

Nonoperative treatment, which aims to offload forces exerted on the femoral head through limited weight bearing, activity modification, and physical therapy, has been shown to have limited success in preventing disease progression [2].

In the early stage of FHN (i.e., ARCO stage 1), intramedullary pressure is elevated and core decompression surgery is performed by drilling through the necrotic region, with a 6 or 8 mm short trephine drill, to reduce the pressure [7]. Core decompression treatment is more effective than conservative treatment [11], with clinically satisfactory results of core decompression obtained in 63.5% of cases of early FHN, compared to 22.7% with conservative treatment [12]. The clinical benefits of core decompression, however, have been questioned [13, 14]. Foremost, core decompression is not indicated for advanced stages of FHN. Mont et al. [15] reported satisfactory outcomes of core decompression of only 29% in patients with Steinberg stage 3 FHN, with 41% of patients in stage 3 and 92% in stage 4 requiring arthroplasty. In advanced stages of FHN, bone fragility is a more important consideration than elevated intrafemoral pressure.

Multiple microfractures of the subchondral bone are often present in advanced stages of FHN [16] and, therefore, reinforcing initial bone strength to prevent collapse of the femoral head is an important component of treatment at this stage. Vascularized bone grafts can offer reflux of blood flow and initial strength. Vascularized bone grafting is indicated for advanced stages of FHN [2, 17–19]. However, a radiographic study of outcomes after vascularized bone grafting by Ishizaka et al. [17] indicated continued progression of collapse in 50% of cases classified as Ficat stage 2 hips, and in 46% of cases classified as Ficat stage 3 hips. Therefore, vascularized bone grafting is not sufficient to prevent the collapse in cases of advanced FHN.

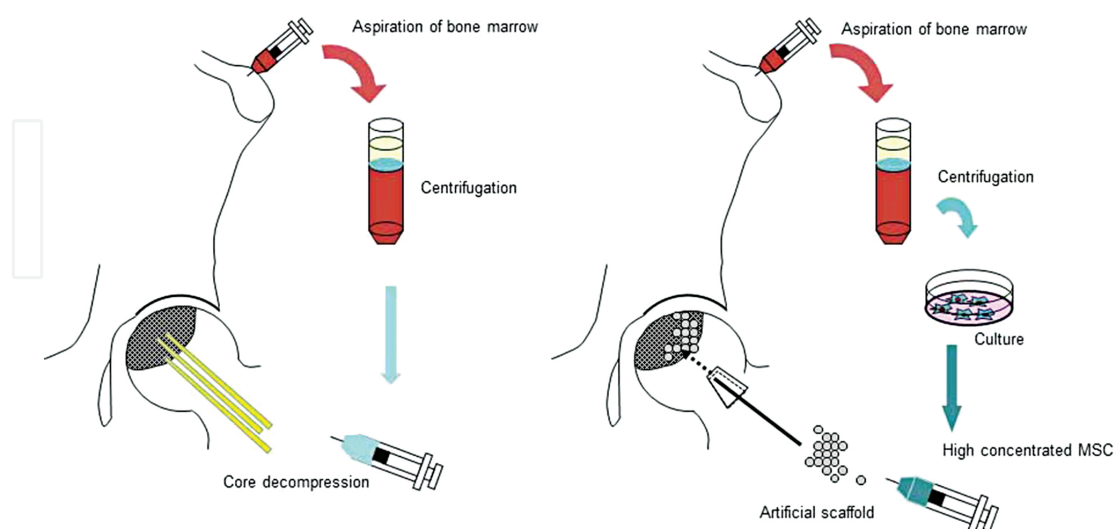


Figure 2 Cell-based therapy for osteonecrosis of the femoral head, combining concentrated bone marrow transplantation with core decompression is shown in the left panel. The right panel shows cultured mesenchymal stromal cell transplantation, combined with biomaterials, after removal of necrotic bone.

4. Concentrated bone marrow transplantation for the treatment of FHN

Core decompression offers not only a decrease in intramedullary pressure, but also a flow of living cells from regions surrounding the necrotic lesion. However, as FHN is not an isolated lesion of the femoral head, but rather involves the greater trochanteric area, the number of osteogenic cells throughout the trochanteric area is reduced [20, 21]. Hernigou et al. [22] and Gangji et al. [23] combined transplantation of concentrated autologous bone marrow from the iliac crest with core decompression with the aim of supplying osteoblastic cells. Gangji et al. [23] reported collapse of the femoral head to be significantly delayed with the use of concentrated bone marrow transplantation, compared with sole core decompression, when performed in the early stage of FHN (i.e., ARCO stage 1 or 2), with a collapse rate of 63% for the sole core decompression group, compared to 10% for the concentrated bone marrow transplantation group. Since the initial work of Hernigou et al. [22] and Gangji et al. [23], a number of studies have reported their outcomes of using concentrated autologous bone marrow transplantation in combination with core decompression [24–28], with relevant information from these studies reported in **Figure 2** and **Table 2**. Although clinically acceptable results for the combination of cell transplantation and core decompression were reported for patients classified in the early stages of FHN progression [23, 24], for patients with advanced stages of FHN, this combined treatment is not sufficient to prevent collapse of the femoral head [23–28]. The association between clinical stage of FHN and outcomes of the combined treatment was reported by Hernigou et al. [22], with 77% prevention of collapse for patients in stage 1 and 74% in stage 2, compared to 0% in stage 3 and 50% in stage 4. Therefore, additional treatment may be needed to enhance the positive effects of bone marrow transplantation. Martin et al. [29] used a combination of platelet rich plasma and bone marrow cells for transplantation after core decompression, with significant pain relief achieved in 86% of their cases, and with 79% of cases not progressing to collapse. Kang et al. [30] used a cancellous bone graft in combination with bone marrow transplantation after core decompression for both early and advanced stages of FHN, obtaining clinically successful outcomes in 80% of cases in stage 1, 65.7% in stage 2, 38.9% in stage 3, and 33.3% in stage 4.

Based on this evidence, it seems reasonable to suggest that for patients with the advanced stage of FHN (i.e., ARCO stage 3 or 4), providing initial strength to the femoral head is required to prevent further fracture and collapse. Bioactive scaffolding can provide the initial strength required. Yamasaki et al. [31] used interconnected porous calcium hydroxyapatite, in combination with concentrated bone marrow transplantation for patients with stages 1 and 2 FHN and advanced stage 3A. They reported no progression of the collapse in 56.7% of their case series, mild collapse of <2 mm in 33.3% and >2 mm of collapse in 10%. Liu et al. [32] used porous hydroxyapatite, with and without bone marrow transplantation, to treat patients in the precollapse stage of FHN progression (i.e., stage 2). They reported that 78.6% of their cases treated with the combination of porous hydroxyapatite and bone marrow transplantation did not progress to collapse, compared to 41.7% for patients treated only with bone marrow transplantation. A histological study by Arlot et al. [33], however, reported osteomalacia and osteoporosis to persist despite clinical improvement after treatment for FHN. Therefore, remodeling of the necrotic bone is difficult to achieve [34, 35]. To address this issue, Wang et

al. [36] performed curettage of the necrotic bone, instead of core decompression, packing the free bone graft with concentrated bone marrow cells. Progression to collapse was prevented in 75% of their patients in stage 2 and 100% in stage 3.

Cell source	Combined surgical technique	Radiographic stages (ARCO)			
		Stage 1	Stage 2	Stage 3 3A	Stage 4 3B
Bone marrow cells	Core decompression	Gangji V (2004)			
		Wang BL (2010)			
		Chotivichit A (2012)			
		Mao Q (2013)			
		Ma Y (2014)			
		Tabatabaee RM (2015)			
		Hernigou P (2002)			
	Core decompression + bioderived material	Martin JR (2013)			
		Kang JS (2013)			
	Core decompression + bioactive scaffold	Yamasaki T (2010)			
		Liu Y (2013)			
	Curretage + bone graft		Wang T (2014)		
MSCs	Core decompression	Zhao D (2012)			
		Rastogi S (2013)			
		Persiani P (2015)			
	Curretage + bone graft + bioactive scaffold			Aoyama T (2014)	Kawate K (2006)

MSC, mesenchymal stem cell.

Table 2. Cell therapy according to the grade of osteonecrosis of the femoral head.

5. Mesenchymal stromal cell transplantation for the treatment of FHN

Reports of poor results using concentrated bone marrow transplantation combined with core decompression may reflect the low population of osteogenic cells in bone marrow of patients with FHN. Hernigou et al. [22] reported the osteogenic cell number to be low in patients with a history of steroid and alcohol use, as well as in patients who had undergone organ transplantation. Mesenchymal stromal cells (MSCs) may provide a solution to the problem of low osteogenic cell number.

MSCs hold promise for their use in regeneration of tissues of the musculoskeletal system [37]. MSCs are plastic dish-adherent cells that differentiate into osteogenic, chondrogenic, and adipogenic cell lineages, *in vitro* [38, 39]. The adherent cells can be easily proliferated, yielding a large number of cells [38]. The high proliferation nature of these cells in *in vitro* cultures could provide an effective compensation for low cell numbers [39]. MSCs can also differentiate into

vascular endothelial cells [40]. This property to differentiate into vascular tissue would be useful to treat the avascular component of FHN. MSCs can be isolated from many tissues, including bone marrow, fat, and synovium [41]. The ideal source for MSC differentiation and proliferation remains controversial, with isolation of MSCs from bone marrow having been shown to be stable [42]. The technique to aspirate bone marrow is also well established [43] and relatively safe.

Zhao et al. [44] conducted a clinical trial on the use of MSCs for the treatment of FHN, with salient finding summarized in **Figure 2** and **Table 2**. Zhao et al. compared outcomes of transplanting cultured MSCs and bone marrow cells, in combination with core decompression, in patients with the early stage of FHN (i.e., ARCO stage 1 or 2). After 60-month follow-up, 4% of hip treated with MSCs progressed to collapse, compared to 23% of cases in the bone marrow treatment group. Rastogi et al. [45] also conducted a comparison of outcomes for treatment using cultured MSCs and bone marrow for transplantation in patients with the early (stages 1 and 2) and advanced (stage 3) stages of FHN. In contrast to Zhao et al., Rastogi et al. did not identify a significant difference in the rate of collapse between the two treatment groups, with a rate of collapse of 0% for both groups for stage 1 hips and 18% for stage 2 hips, and a rate of 20% for stage 3 hips for the MSC group, compared to 25% for the bone marrow group. Persiani et al. [46] reported that core decompression with MSCs transplantation was not a sufficient treatment for patients with advanced stages of FHN. Aoyama et al. [47] and Kawate et al. [48] performed curettage of the necrotic bone and packed beta-tricalcium phosphate with MSCs and a vascularized bone graft to treat patients with advanced stages of FHN. Aoyama et al. reported no progression to collapse for hips in stage 3A, while 50% of the hips in stage 3B progressed to collapse. In their 12-week follow-up, Kawate et al. did not report any progression to collapse of hips in stage 3 or 4 FHN.

6. The cell type used for the treatment of FHN

It is clear that transplantation of cells that can be differentiated to osteogenic cells is effective for the treatment of FHN. Preparation of concentrated bone marrow cells is easy, of low risk and of low cost. However, when the necrotic lesion is broad, preparation of a large number of cells is needed [49]. The condition of the host tissue influences the number and quality of osteogenic cells harvested [49]. Therefore, it is a great benefit that MSCs can be differentiated into both osteogenic and vascular endothelial cells [40]. The cytokine and paracrine effect of MSCs is important in yielding a large number of differentiated MSC cell lineages *in vitro* [50, 51]. However, the differentiation property of MSCs is highly influenced by the conditions of the host, such as age, disease, medication, etc. [52]. Peripheral CD34-positive MSCs may be another source for the treatment of FHN. They have the potential to differentiate into osteogenic and vascular endothelial cells and are easily prepared by *in vivo* induction of granulocyte colony-stimulating factors [53]. Despite the different possible sources of MSCs, remodeling of the osteonecrotic bone is an issue that remains to be solved. In healthy bone tissue, the balance between bone formation and bone resorption is under precise regulation [54]. In contrast, in pathological conditions, such as osteoporosis, prolonged fracture repair, and osteonecrosis,

there is a dysregulation of the balance between osteoclast and osteoblast activity [35, 54]. In FHN, both living osteoclast and osteoblast cells are reduced in number. Therefore, pathogenic tissue, such as necrotic bone, should be removed as a component of treatment to facilitate bone remodeling. MSCs have the ability not only to differentiate into osteogenic cells, but they can also stimulate the osteoclastogenesis [55–57]. Therefore, the cytokine effect of MSCs induces a healthy remodeling regulation.

7. Biomaterials

Implantation of biomaterial is useful to provide initial strength to avoid collapse of the femoral head. Recent development of biomaterials aims to implement osteoinduction and osteoconduction ability in biomaterials themselves [58, 59]. Tantalum rods have high volumetric porosity, providing excellent osteoconductive properties, while their elastic modulus is similar to that of bone, providing exceptional biocompatibility [60]. In their case series of 50 hips treated with tantalum rods, Veillette et al. [61] reported a conversion rate to total hip arthroplasty in only 15.5% of their cases. Miao et al. [62] compared tantalum rod implantation to core decompression in patients with the early stage FHN (i.e., Steinberg stage 1 or 2) hips. After treatment, clinical score on radiographic assessment was improved in both the treatment groups. Pakos et al. [63] used tantalum rods with bone marrow and autologous bone grafting to treat patients with Steinberg stage 2 or stage 3 FHN. Five years after treatment, only 3% of hips in stage 2 and 15% in stage 3 were converted to total hip replacement.

Other biodegradable materials have also been used. Nano-hydroxyapatite/polyamide (n-HA/PA) 66 rods were used for the treatment of FHN [61, 64]. In their case series of 84 FHN cases, Yang et al. [64] allocated patients to two treatment groups, the first combining core decompression in combination with insertion of a n-HA/PA 66 rod and the second combining core decompression with an autologous cancellous bone graft. In the n-HA/PA 66 rod group, 21.1% of hips progressed to collapse of the femoral head, compared to 45.7% in the bone grafting group. A distinct advantage of biomaterials is their ability to change their form to easily fill cavities of different shapes. The clinical benefits of different biomaterials in the treatment of hips with FHN have been reported: Yamasaki et al. [31] used rod type porous hydroxyapatite; Liu et al. [32] used composite filler; and Aoyama et al. [47] and Kawate et al. [48] used porous beta-tricalcium phosphate granules in combination with cultured MSCs. Although there is evidence of satisfactory clinical outcomes using biomaterials, when these materials are used in combination with cell transplantation, the balance between the timing of degradation and osteogenesis is an important factor influencing outcome. Specifically, the activity of osteoclasts has been shown to be influenced by the type of biomaterial [65]. In the presence of biomaterials that facilitate early resorption of bone, compared to bone formation, the biomaterial does not have sufficient strength to protect against collapse. Therefore, the combination between biomaterial and cell type needs to be carefully examined.

8. Growth factors

Growth factors, such as transforming growth factor- β 1, platelet-derived growth factor, vascular endothelial growth factors, fibroblast growth factor-2 (FGF-2), and bone morphogenetic protein (BMP) treatment, aim to promote revascularization and bone formation in hips with FHN [66]. Samara et al. [67] reported a lower expression of BMP-2 and BMP-6 in the femoral head of patients with FHN, compared to healthy controls. Therefore, supplying the lacking growth factor may be a reasonable adjunct treatment option. Lieberman et al. [68] used BMP-2 replacement in combination with allogenic fibula transplantation, reporting a radiographic progression of FHN in 17.6% of hips in Ficat stages 2 and 3. Sun et al. [69] compared the outcomes of recombinant BMP-2 treatment in combination with artificial bone implantation to implantation of artificial bone alone. The radiographic survival rate of the femoral head for hips in the BMP-2 treatment group was 100.0% for ARCO stage 2b hips, 84.2% for ARCO stage 2C hips, and 30.0% for ARCO stage 3 hips. By comparison, in the control group treated by implantation alone, the survival rate was 100.0% for ARCO stage 2b, 76.5% for ARCO stage 2C, and 37.5% for ARCO stage 3. Sun et al. concluded that BMP-2 was effective for selected patients. Papanagiotou et al. [70] used BMP-7 in combination with autologous, nonvascularized fibular grafting for hips in Steinberg stage 2 or stage 3. Over a 4-year follow-up, 29% of hips progressed to collapse and required total hip replacement. Papanagiotou et al. did report that BMP-7 in combination with autologous, nonvascularized, fibular grafting, is effective for shortening operative time and the postoperative rehabilitation period. Kuroda et al. [71] used recombinant FGF-2 impregnated with gelatin hydrogel for minimally invasive surgical treatment of patients in early stages of FHN. In their case series, 10% of hips progressed to collapse 1-year posttreatment, with improvement in radiographic clinical score in all other cases. Results of these preliminary studies provide evidence of the safety and feasibility of treatment using growth factors. Abe et al. [72] also reported elevation in levels of interleukin-6 and tumor necrosis factor- α in the joint fluid of hip in advanced stages of FHN. Therefore, modulation of cytokine activity, in combination with growth factors, may be an effective treatment strategy. Therefore, although there is currently no clinical report combining cell-based therapy and growth factor treatment, this combination holds promise for treatment of FHN and should be evaluated in future studies.

9. Conclusion

For an effective treatment of FHN, an osteogenic cell supply, revascularization, and providing initial strength to resist collapse are needed. The combination of cell-based therapy, growth factor, and biomaterial may effectively meet these requirements [73]. The development of new procedures is required, with treatment being according to the pathology and clinical status being extremely important considerations.

Acknowledgements

This work was supported by JSPS KAKENHI Grant Number 26282154.

Author details

Tomoki Aoyama

Address all correspondence to: blue@hs.med.kyoto-u.ac.jp

Human Health Sciences, Graduate School of Medicine, Kyoto University, Kyoto, Japan

References

- [1] Mankin HJ. Nontraumatic necrosis of bone (osteonecrosis). *N Engl J Med.* 1992;326(22): 1473–1479. DOI: 10.1056/NEJM199205283262206.
- [2] Kaushik AP, Das A, Cui Q. Osteonecrosis of the femoral head: an update in year 2012. *World J Orthop.* 2012;3(5):49–57. DOI: 10.5312/wjo.v3.i5.49.
- [3] Steinberg ME. Osteonecrosis of the hip: summary and conclusions. *Semin Arthroplasty.* 1991;2(3):241–249. DOI: 10.1097/B TO.0b013e31816b476e.
- [4] Steinberg ME, Steinberg DR. Classification systems for osteonecrosis: an overview. *Orthop Clin North Am.* 2004;35(3):273–283. DOI: <http://dx.doi.org/10.1016/j.ocl.2004.02.005>.
- [5] Mont MA, Zywił MG, Marker DR, McGrath MS, Delanois RE. The natural history of untreated asymptomatic osteonecrosis of the femoral head: a systematic literature review. *J Bone Joint Surg Am.* 2010;92(12):2165–2170. DOI: 10.2106/JBJS.I.00575.
- [6] Johnson AJ, Mont MA, Tsao AK, Jones LC. Treatment of femoral head osteonecrosis in the United States: 16-year analysis of the Nationwide Inpatient Sample. *Clin Orthop Relat Res.* 2014;472(2):617–623. DOI: 10.1007/s11999-013-3220-3.
- [7] Ficat RP. Idiopathic bone necrosis of the femoral head. Early diagnosis and treatment. *J Bone Joint Surg Br.* 1985;67(1):3–9.
- [8] Steinberg ME. Classification of avascular necrosis: a comparative study. *Acta Orthop Belg.* 1999;65(Suppl 1):45–46.
- [9] Sugano N, Atsumi T, Ohzono K, Kubo T, Hotokebuchi T, Takaoka K. The 2001 revised criteria for diagnosis, classification, and staging of idiopathic osteonecrosis of the femoral head. *J Orthop Sci.* 2002;7(5):601–605. DOI: 10.1007/s007760200108.

- [10] Nishii T, Sugano N, Ohzono K, Sakai T, Haraguchi K, Yoshikawa H. Progression and cessation of collapse in osteonecrosis of the femoral head. *Clin Orthop Relat Res* 2002;400:149–157. DOI: 10.1097/00003086-200207000-00019.
- [11] Stulberg BN, Davis AW, Bauer TW, Levine M, Easley K. Osteonecrosis of the femoral head. A prospective randomized treatment protocol. *Clin Orthop Relat Res*. 1991;268:140–151. DOI:10.1016/j.injury.2013.09.014.
- [12] Mont MA, Carbone JJ, Fairbank AC. Core decompression versus nonoperative management for osteonecrosis of the hip. *Clin Orthop Relat Res* 1996;324:169–178. DOI: 10.1097/00003086-199603000-00020.
- [13] Rajagopal M, Balch Samora J, Ellis TJ. Efficacy of core decompression as treatment for osteonecrosis of the hip: a systematic review. *Hip Int*. 2012;22(5):489–493. DOI: 10.5301/HIP.2012.9748.
- [14] Neumayr LD, Aguilar C, Earles AN, Jergesen HE, Haberkern CM, Kammen BF, Nancarrow PA, Padua E, Milet M, Stulberg BN, Williams RA, Orringer EP, Graber N, Robertson SM, VichinskyEP; National Osteonecrosis Trial in Sickle Cell Anemia Study Group. Physical therapy alone compared with core decompression and physical therapy for femoral head osteonecrosis in sickle cell disease. Results of a multicenter study at a mean of three years after treatment. *J Bone Joint Surg Am*. 2006;88(12):2573–2582. DOI: <http://dx.doi.org/10.2106/JBJS.E.01454>.
- [15] Mont MA, Jones LC, Pacheco I, Hungerford DS. Radiographic predictors of outcome of core decompression for hips with osteonecrosis stage III. *Clin Orthop Relat Res* 1998;354:159–168. DOI: 10.1097/00003086-199809000-00019.
- [16] Meier R, Kraus TM, Schaeffeler C, Torcka S, Schlitter AM, Specht K, Haller B, Waldt S, Rechl H, Rummeny EJ, Woertler K. Bone marrow oedema on MR imaging indicates ARCO stage 3 disease in patients with AVN of the femoral head. *Eur Radiol*. 2014;24(9):2271–2278. DOI: 10.1007/s00330-014-3216-8.
- [17] Ishizaka M, Sofue M, Dohmae Y, Endo N, Takahashi HE. Vascularized iliac bone graft for avascular necrosis of the femoral head. *Clin Orthop Relat Res* 1997;337:140–148.
- [18] AldridgeJM3rd, Urbaniak JR. Vascularized fibular grafting for osteonecrosis of the femoral head with unusual indications. *Clin Orthop Relat Res*. 2008;466(5):1117–1124. DOI: 10.1007/s11999-008-0201-z.
- [19] Korompilias AV, Lykissas MG, Beris AE, Urbaniak JR, Soucacos PN. Vascularised fibular graft in the management of femoral head osteonecrosis: twenty years later. *J Bone Joint Surg Br*. 2009;91(3):287–293. DOI: 10.1302/0301-620X.91B3.21846.
- [20] Gangji V, Hauzeur JP, Schoutens A, Hinsenkamp M, Appelboom T, Egrise D. Abnormalities in the replicative capacity of osteoblastic cells in the proximal femur of patients with osteonecrosis of the femoral head. *J Rheumatol*. 2003;30(2):348–351. DOI: 10.1016/j.bone.2014.04.034.

- [21] Hernigou P, Beaujean F, Lambotte JC. Decrease in the mesenchymal stem-cell pool in the proximal femur in corticosteroid-induced osteonecrosis. *J Bone Joint Surg Br.* 1999;81(2):349–355. DOI: 10.1302/0301-620X.81B2.8818.
- [22] Hernigou P, Beaujean F. Treatment of osteonecrosis with autologous bone marrow grafting. *Clin Orthop Relat Res* 2002;405:14–23. DOI: 10.4103/0019-5413.45322.
- [23] Gangji V, Hauzeur JP, Matos C, De Maertelaer V, Toungouz M, Lambermont M. Treatment of osteonecrosis of the femoral head with implantation of autologous bone-marrow cells. A pilot study. *J Bone Joint Surg Am.* 2004;86-A(6):1153–1160.
- [24] Wang BL, Sun W, Shi ZC, Zhang NF, Yue DB, Guo WS, Xu SQ, Lou JN, Li ZR. Treatment of nontraumatic osteonecrosis of the femoral head with the implantation of core decompression and concentrated autologous bone marrow containing mononuclear cells. *Arch Orthop Trauma Surg.* 2010;130(7):859–865. DOI: 10.1016/j.bone.2011.07.032.
- [25] Chotivichit A, Korwutthikulrangsri E, Pornrattanamaneewong C, Achawakulthep C. Core decompression with bone marrow injection for the treatment of femoral head osteonecrosis. *J Med Assoc Thai.* 2014;97(Suppl 9):S139-S143.
- [26] Mao Q, Jin H, Liao F, Xiao L, Chen D, Tong P. The efficacy of targeted intraarterial delivery of concentrated autologous bone marrow containing mononuclear cells in the treatment of osteonecrosis of the femoral head: a five year follow-up study. *Bone.* 2013;57(2):509–516. DOI: 10.1016/j.bone.2013.08.022.
- [27] Ma Y, Wang T, Liao J, Gu H, Lin X, Jiang Q, Bulsara MK, Zheng M, Zheng Q. Efficacy of autologous bone marrow buffy coat grafting combined with core decompression in patients with avascular necrosis of femoral head: a prospective, double-blinded, randomized, controlled study. *Stem Cell Res Ther.* 2014;5(5):115. DOI: 10.1186/scrt505.
- [28] Tabatabaee RM, Saberi S, Parvizi J, Mortazavi SM, Farzan M. Combining concentrated autologous bone marrow stem cells injection with core decompression improves outcome for patients with early-stage osteonecrosis of the femoral head: a comparative study. *J Arthroplasty.* 2015;30(9 Suppl):11–15. DOI: 10.1016/j.arth.2015.06.022.
- [29] Martin JR, Houdek MT, Sierra RJ. Use of concentrated bone marrow aspirate and platelet rich plasma during minimally invasive decompression of the femoral head in the treatment of osteonecrosis. *Croat Med J.* 2013;54(3):219–224. DOI: 10.3325/cmj.2013.54.219.
- [30] Kang JS, Moon KH, Kim BS, Kwon DG, Shin SH, Shin BK, Ryu DJ. Clinical results of auto-iliac cancellous bone grafts combined with implantation of autologous bone marrow cells for osteonecrosis of the femoral head: a minimum 5-year follow-up. *Yonsei Med J.* 2013;54(2):510–515. DOI: 10.3349/ymj.2013.54.2.510.
- [31] Yamasaki T, Yasunaga Y, Ishikawa M, Hamaki T, Ochi M. Bone-marrow-derived mononuclear cells with a porous hydroxyapatite scaffold for the treatment of osteo-

- necrosis of the femoral head: a preliminary study. *J Bone Joint Surg Br.* 2010;92(3):337–341. DOI: 10.1302/0301-620X.92B3.22483.
- [32] Liu Y, Liu S, Su X. Core decompression and implantation of bone marrow mononuclear cells with porous hydroxylapatite composite filler for the treatment of osteonecrosis of the femoral head. *Arch Orthop Trauma Surg.* 2013;133(1):125–133. DOI: 10.1007/s00402-012-1623-3.
- [33] Arlot ME, Bonjean M, Chavassieux PM, Meunier PJ. Bone histology in adults with aseptic necrosis. Histomorphometric evaluation of iliac biopsies in seventy-seven patients. *J Bone Joint Surg Am.* 1983;65(9):1319–1327.
- [34] Gangji V, Hauzeur JP. Cellular-based therapy for osteonecrosis. *Orthop Clin North Am.* 2009;40(2):213–221.
- [35] Chim SM, Tickner J, Chow ST, Kuek V, Guo B, Zhang G, Rosen V, Erber W, Xu J. Angiogenic factors in bone local environment. *Cytokine Growth Factor Rev.* 2013;24(3):297–310. DOI: 10.1016/j.cytogfr.2013.03.008.
- [36] Wang T, Wang W, Yin ZS. Treatment of osteonecrosis of the femoral head with thorough debridement, bone grafting and bone-marrow mononuclear cells implantation. *Eur J Orthop Surg Traumatol.* 2014;24(2):197–202. DOI: 10.1007/s00590-012-1161-2.
- [37] Steinert AF, Rackwitz L, Gilbert F, Nöth U, Tuan RS. Concise review: the clinical application of mesenchymal stem cells for musculoskeletal regeneration: current status and perspectives. *Stem Cells Transl Med.* 2012;1(3):237–247. DOI: 10.5966/sctm.2011-0036.
- [38] Pittenger MF, Mackay AM, Beck SC, Jaiswal RK, Douglas R, Mosca JD, Moorman MA, Simonetti DW, Craig S, Marshak DR. Multilineage potential of adult human mesenchymal stem cells. *Science.* 1999;284(5411):143–147. DOI: 10.1126/science.284.5411.143.
- [39] Dominici M, Le Blanc K, Mueller I, Slaper-Cortenbach I, Marini F, Krause D, Deans R, Keating A, Prockop Dj, Horwitz E. Minimal criteria for defining multipotent mesenchymal stromal cells. The International Society for Cellular Therapy position statement. *Cytotherapy.* 2006;8(4):315–317. DOI: 10.1080/14653240600855905.
- [40] Aoyama T, Toguchida J. Isolation of bone marrow stromal cells from bone marrow by using a filtering device (Method). *Stem Cells and Cancer Stem Cells.* Vol. 2; Netherlands: Springer; 2012. p.3-12. DOI: 10.1007/978-94-007-2016-9_1.
- [41] Sun Q, Zhang Z, Sun Z. The potential and challenges of using stem cells for cardiovascular repair and regeneration. *Genes Dis.* 2014;1(1):113–119. DOI: 10.1016/j.gendis.2014.07.003.
- [42] Mohal JS, Tailor HD, Khan WS. Sources of adult mesenchymal stem cells and their applicability for musculoskeletal applications. *Curr Stem Cell Res Ther.* 2012;7(2):103–109. DOI: 10.2174/157488812799219027.

- [43] Hernigou J, Alves A, Homma Y, Guissou I, Hernigou P. Anatomy of the ilium for bone marrow aspiration: map of sectors and implication for safe trocar placement. *Int Orthop*. 2014;38(12):2585–2590. DOI: 10.1007/s00264-014-2353-7.
- [44] Zhao D, Cui D, Wang B, Tian F, Guo L, Yang L, Liu B, Yu X. Treatment of early stage osteonecrosis of the femoral head with autologous implantation of bone marrow-derived and cultured mesenchymal stem cells. *Bone*. 2012;50(1):325–330. DOI: 10.1016/j.bone.2011.11.002.
- [45] Rastogi S, Sankineani SR, Nag HL, Mohanty S, Shivanand G, Marimuthu K, Kumar R, Rijal L. Intralesional autologous mesenchymal stem cells in management of osteonecrosis of femur: a preliminary study. *Musculoskelet Surg*. 2013;97(3):223–228. DOI: 10.1007/s12306-013-0273-0.
- [46] Persiani P, De Cristo C, Graci J, Noia G, Gurzi M, Villani C. Stage-related results in treatment of hip osteonecrosis with core-decompression and autologous mesenchymal stem cells. *Acta Orthop Belg*. 2015;81(3):406–412.
- [47] Aoyama T, Goto K, Kakinoki R, Ikeguchi R, Ueda M, Kasai Y, Maekawa T, Tada H, Teramukai S, Nakamura T, Toguchida J. An exploratory clinical trial for idiopathic osteonecrosis of femoral head by cultured autologous multipotent mesenchymal stromal cells augmented with vascularized bone grafts. *Tissue Eng Part B Rev*. 2014;20(4):233–242. DOI: 10.1089/ten.teb.2014.0090.
- [48] Kawate K, Yajima H, Ohgushi H, Kotobuki N, Sugimoto K, Ohmura T, Kobata Y, Shigematsu K, Kawamura K, Tamai K, Takakura Y. Tissue-engineered approach for the treatment of steroid-induced osteonecrosis of the femoral head: transplantation of autologous mesenchymal stem cells cultured with beta-tricalcium phosphate ceramics and free vascularized fibula. *Artif Organs*. 2006;30(12):960–962. DOI: 10.1111/j.1525-1594.2006.00333.x.
- [49] Hernigou P, Poignard A, Zilber S, Rouard H. Cell therapy of hip osteonecrosis with autologous bone marrow grafting. *Indian J Orthop*. 2009;43(1):40–45. DOI: 10.4103/0019-5413.45322.
- [50] Salem HK, Thiemermann C. Mesenchymal stromal cells: current understanding and clinical status. *Stem Cells*. 2010;28(3):585–596. DOI: 10.1002/stem.269.
- [51] Liang X, Ding Y, Zhang Y, Tse HF, Lian Q. Paracrine mechanisms of mesenchymal stem cell-based therapy: current status and perspectives. *Cell Transplant*. 2014;23(9):1045–1059. DOI: 10.3727/096368913X667709.
- [52] Schimke MM, Marozin S, Lepperdinger G. Patient-specific age: the other side of the coin in advanced mesenchymal stem cell therapy. *Front Physiol*. 2015;6:362. DOI: 10.3389/fphys.2015.00362.

- [53] Kuroda R, Matsumoto T, Kawakami Y, Fukui T, Mifune Y, Kurosaka M. Clinical impact of circulating CD34-positive cells on bone regeneration and healing. *Tissue Eng Part B Rev.* 2014;20(3):190–199. DOI: 10.1089/ten.
- [54] Xiao W, Li S, Pacios S, Wang Y, Graves DT. Bone remodeling under pathological conditions. *Front Oral Biol.* 2015;18:17–27. DOI: 10.1159/000351896.
- [55] Ikeguchi R, Kakinoki R, Aoyama T, Shibata KR, Otsuka S, Fukiage K, Nishijo K, Ishibe T, Shima Y, Otsuki B, Azuma T, Tsutsumi S, Nakayama T, Otsuka T, Nakamura T, Toguchida J. Regeneration of osteonecrosis of canine scapho-lunate using bone marrow stromal cells: possible therapeutic approach for Kienböck disease. *Cell Transplant.* 2006;15(5):411–422. DOI: 10.3727/000000007783465190.
- [56] Bielby R, Jones E, McGonagle D. The role of mesenchymal stem cells in maintenance and repair of bone. *Injury.* 2007;38(Suppl 1):S26–S32. DOI: 10.1016/j.injury.2007.02.007.
- [57] Crane JL, Cao X. Bone marrow mesenchymal stem cells and TGF- β signaling in bone remodeling. *J Clin Invest.* 2014;124(2):466–472. DOI: 10.1172/JCI70050.
- [58] Kokubo T, Yamaguchi S. Growth of novel ceramic layers on metals via chemical and heat treatments for inducing various biological functions. *Front Bioeng Biotechnol.* 2015;3:176. DOI: 10.3389/fbioe.2015.00176.
- [59] García-Gareta E, Coathup MJ, Blunn GW. Osteoinduction of bone grafting materials for bone repair and regeneration. *Bone.* 2015;81:112–121. DOI: 10.1016/j.bone.2015.07.007.
- [60] Bobyn JD, Poggie RA, Krygier JJ, Lewallen DG, Hanssen AD, Lewis RJ, Unger AS, O'Keefe TJ, Christie MJ, Nasser S, Wood JE, Stulberg SD, Tanzer M. Clinical validation of a structural porous tantalum biomaterial for adult reconstruction. *J Bone Joint Surg Am.* 2004;86-A(Suppl 2):123–129. DOI: 10.1038/srep02243.
- [61] Veillette CJ, Mehdian H, Schemitsch EH, McKee MD. Survivorship analysis and radiographic outcome following tantalum rod insertion for osteonecrosis of the femoral head. *J Bone Joint Surg Am.* 2006;88(Suppl 3):48–55. DOI: 10.1016/j.injury.2014.11.016.
- [62] Miao H, Ye D, Liang W, Yao Y. Effect of osteonecrosis intervention rod versus core decompression using multiple small drill holes on early stages of necrosis of the femoral head: a prospective study on a series of 60 patients with a minimum 1-year-follow-up. *Open Orthop J.* 2015;9:179–184. DOI: 10.2174/1874325001509010179.
- [63] Pakos EE, Megas P, Paschos NK, Syggelos SA, Kouzelis A, Georgiadis G, Xenakis TA. Modified porous tantalum rod technique for the treatment of femoral head osteonecrosis. *World J Orthop.* 2015;6(10):829–837. DOI: 10.5312/wjo.v6.i10.829.
- [64] Yang P, Bian C, Huang X, Shi A, Wang C, Wang K. Core decompression in combination with nano-hydroxyapatite/polyamide 66 rod for the treatment of osteonecrosis of the femoral head. *Arch Orthop Trauma Surg.* 2014;134(1):103–112. DOI: 10.1007/s00402-013-1885-4.

- [65] Detsch R, Boccaccini AR. The role of osteoclasts in bone tissue engineering. *J Tissue Eng Regen Med.* 2015;9(10):1133–1149. DOI: 10.1002/term.1851.
- [66] Rackwitz L, Eden L, Reppenhagen S, Reichert JC, Jakob F, Walles H, Pullig O, Tuan RS, Rudert M, Nöth U. Stem cell- and growth factor-based regenerative therapies for avascular necrosis of the femoral head. *Stem Cell Res Ther.* 2012;3(1):7. DOI: 10.1186/scrt98.
- [67] Samara S, Dailiana Z, Varitimidis S, Chassanidis C, Koromila T, Malizos KN, Kollia P. Bone morphogenetic proteins (BMPs) expression in the femoral heads of patients with avascular necrosis. *Mol Biol Rep.* 2013;40(7):4465–4472. DOI: 10.1007/s11033-013-2538-y.
- [68] Lieberman JR, Conduah A, Urist MR. Treatment of osteonecrosis of the femoral head with core decompression and human bone morphogenetic protein. *Clin Orthop Relat Res.* 2004;429:139–145. DOI: 10.1097/01.blo.0000150312.53937.6f.
- [69] Sun W, Li Z, Gao F, Shi Z, Zhang Q, Guo W. Recombinant human bone morphogenetic protein-2 in debridement and impacted bone graft for the treatment of femoral head osteonecrosis. *PLoS One.* 2014;9(6):e100424. DOI: 10.1371/journal.pone.0100424. eCollection 2014.
- [70] Papanagiotou M, Malizos KN, Vlychou M, Dailiana ZH. Autologous (non-vascularised) fibular grafting with recombinant bone morphogenetic protein-7 for the treatment of femoral head osteonecrosis: preliminary report. *Bone Joint J.* 2014;96-B(1):31–35. DOI: 10.1302/0301-620X.96B1.32773.
- [71] Kuroda Y, Asada R, So K, Yonezawa A, Nankaku M, Mukai K, Ito-Ihara T, Tada H, Yamamoto M, Murayama T, Morita S, Tabata Y, Yokode M, Shimizu A, Matsuda S, Akiyama H. A pilot study of regenerative therapy using controlled release of recombinant human fibroblast growth factor for patients with pre-collapse osteonecrosis of the femoral head. *Int Orthop.* Dec 29, 2015. [Epub ahead of print]. DOI: 10.1007/s00264-015-3083-1.
- [72] Abe H, Sakai T, Ando W, Takao M, Nishii T, Nakamura N, Hamasaki T, Yoshikawa H, Sugano N. Synovial joint fluid cytokine levels in hip disease. *Rheumatology (Oxford).* 2014;53(1):165–172. DOI: 10.1093/rheumatology/ket334.
- [73] Sun H, Yang HL. Calcium phosphate scaffolds combined with bone morphogenetic proteins or mesenchymal stem cells in bone tissue engineering. *Chin Med J (Engl).* 2015;128(8):1121–1127. DOI: 10.4103/0366-6999.155121.