

We are IntechOpen, the world's leading publisher of Open Access books Built by scientists, for scientists

4,800

Open access books available

122,000

International authors and editors

135M

Downloads

Our authors are among the

154

Countries delivered to

TOP 1%

most cited scientists

12.2%

Contributors from top 500 universities



WEB OF SCIENCE™

Selection of our books indexed in the Book Citation Index
in Web of Science™ Core Collection (BKCI)

Interested in publishing with us?
Contact book.department@intechopen.com

Numbers displayed above are based on latest data collected.

For more information visit www.intechopen.com



Robot-Assisted Colonic Resections for Cancer

Monica Ortenzi, Giovanni Lezoche,
Roberto Ghiselli and Mario Guerrieri

Additional information is available at the end of the chapter

<http://dx.doi.org/10.5772/62416>

Abstract

Minimally invasive surgery for colon cancer, if compared with open surgery, has shown similar oncologic outcomes, and it has become the standard management for malignant colonic disease. Its benefits appear yet in early post-operative period such as less postoperative pain, earlier recovery of gastrointestinal functions and shorter hospital stay. Robotic surgery was born in the attempt to overcome the intrinsic limitations of laparoscopic technique. It offers the possibility to have a tridimensional magnified view of surgical field and to use wristed instrument to perform an accurate dissection and lymphadenectomy. It provides the possibility to rotate at 360 degrees the instruments, facilitating considerably the performance of intracorporeal ileo-colic anastomosis in right colectomy. We want to illustrate the feasibility and technique to carry out right and left colectomy in a robotic-assisted way and its advantages with respect to laparoscopic surgery.

Keywords: robot-assisted, surgery, laparoscopy, colon, cancer

1. Introduction

Colon cancer has always been a hot topic, and a revolution has come about in its surgical management in the past 20 years with the introduction of laparoscopic surgery. This progress has culminated with the advent of robotic surgery.

Robotic surgery came about in an attempt to overcome the limitations of laparoscopy mainly because of long rigid instruments, poor ergonomics, and two-dimensional visualization [1–3].

Robotic system was introduced in the surgical field more than 25 years ago [4].

Laparoscopic and robotic surgeries have walked along a parallel path. When Semm reported the first laparoscopic appendectomy in 1983, the “Arthrobot” was first applied in orthopedic operations, which marked the beginning of robotic surgery [5].

Robotic technology applied to surgical procedures has had a rapid growth since then. PUMA (Programmable Universal Machine for Assembly), SARP (Surgeon-Assistant Robot for Prostatectomy) systems, PROBOT (Prostate robot), VRobot (Urology robot), and SPUD (Surgeon Programmable Urological Device) have been introduced and applied in urologic surgery [6–9].

The first robotic device approved by the US Food and Drug Administration (FDA) in 1994 was the AESOP (Automated Endoscopic System for Optimal Positioning) system followed by the ZEUS system (Computer Motion Inc.) in 1998 [10].

The ZEUS robotic system consisted of two separate components: a surgeon control center and three robotic arms attached to the operating table that provided four degrees of freedom and were able to hold various instruments, telemanipulated with joysticks at distance from the surgical console [11].

In 1998, this system was the one used for the first abdominal robotic procedure for fallopian tube anastomosis at Cleveland Clinic [12].

In 2001, Jacques Marescaux used the ZEUS system to perform the transatlantic robot-assisted cholecystectomy known as “Operation Lindbergh”, between New York and Strasburg giving a great demonstration of telepresence surgery [13].

In 2001, 10 years after the first laparoscopic colectomy, Weber described the first robot-assisted colectomy [14].

The first fully robotic system that was approved by FDA in 2000 for its application in laparoscopic surgery was the da Vinci™ Surgical System.

It derives its name from military medical research and was initially developed in a project funded by the Pentagon’s Defense Advanced Research Projects Agency with the aim of allowing remote operations on wounded soldiers [15].

This system was developed by Intuitive Surgical (Mountain View, CA). Later, Intuitive Surgical introduced the da Vinci S system, the da Vinci Si system, and the da Vinci Xi system in 2006, 2009, and 2014, respectively [16].

The da Vinci Si system consists of a remote surgeon’s console, a patient cart, and a vision cart.

The console is composed of a stereo viewer, which provides a three-dimensional visualization of the operative field with 10× magnification, a touchpad, which allows for arms and control selection, and joysticks to control the instrument arms remotely. The footswitch panel is located at the base of the console and is composed of two groups of footswitches. The three switches on the left control the functions of the system such as camera control, master clutch, and arm swap. The four pedals on the right side of the footswitch panel are used for power supply.

The four arms of the column hold the robotic instruments.

They are wrapped in sterile drapes for operations and have clutch buttons used to vary arm joint angulation to adjust the instrument arms even during the procedure.

EndoWrist instruments are installed onto the instrument arms after the system is docked to ports that are inserted into the patient's abdominal wall. Most instruments offer seven degrees of freedom and 90° of articulation in the wrist.

The system provides for tremor filtration and scaled motion, translating larger movements of the surgeon's hands into finer motions of the instruments.

The vision cart includes a 24-inch touch screen monitor and provides shelves for optional surgical equipment such as insufflators and electrosurgical generators [16–18].

2. Right colectomy

This procedure is carried out in a three-arm technique.

The patient is placed in the supine position under general anesthesia with the arms alongside the body and in a mild reverse Trendelenburg position with a left tilt. This position allows the surgeon to expose the patient's right and transverse colon by moving the small bowel aside under gravity. Final positioning is adjusted according to the operative field exposure before robot docking.

Pneumoperitoneum is induced with a supraumbilical incision and the pressure is maintained between 12 and 15 mmHg.

A 12-mm port for the air sealer is positioned on the left midclavicular line, on transverse umbilical line. A 30° laparoscope is used in this procedure.

Once the 12-mm port for the laparoscope and the camera is inserted in the supraumbilical incision, the other port is placed under vision.

A total of four ports (three robotic ports and one assistant port) are set.

We usually place an 8-mm port for instrument arm 1 on the axillary line, 2 cm below the left costal margin, and another suprapubic 8 mm port for instrument arm 2. An assistant 10–12 mm port is placed on the left of the camera port.

The surgical cart is positioned cranial to the patient's head.

The bipolar vessel sealer, used to coagulate and dissect tissues, and the fenestrated grasper are mounted on arms 1 and 2.

The bed-assistant surgeon introduces a laparoscopic grasper used to give tension and facilitate the dissection.

The ileocolic vessels are identified, and the peritoneum is opened just below their prominence. Ileocolic vessels are divided, and the dissection is continued in an avascular plane under the

right colon flexure to expose the duodenum between Gerota's fascia posteriorly and Toldt's fascia anteriorly.

Right colic vessels (if present), right colic veins, and the right branch of the middle colic artery are dissected with a bipolar vessel sealer. Parietal peritoneum is incised, and the dissection is carried out in a craniocaudal way till the cecum is reached. Once the specimen is totally mobilized, the transverse colon is resected with a mechanical stapler. In the case of intracorporeal anastomosis, the ileum is approximated to the transverse colon, and one sero-serosal stitch of suspension is positioned between the ileal loop and the transverse colon where the isoperistaltic side-to-side anastomosis is confectioned (**Figure 1**).

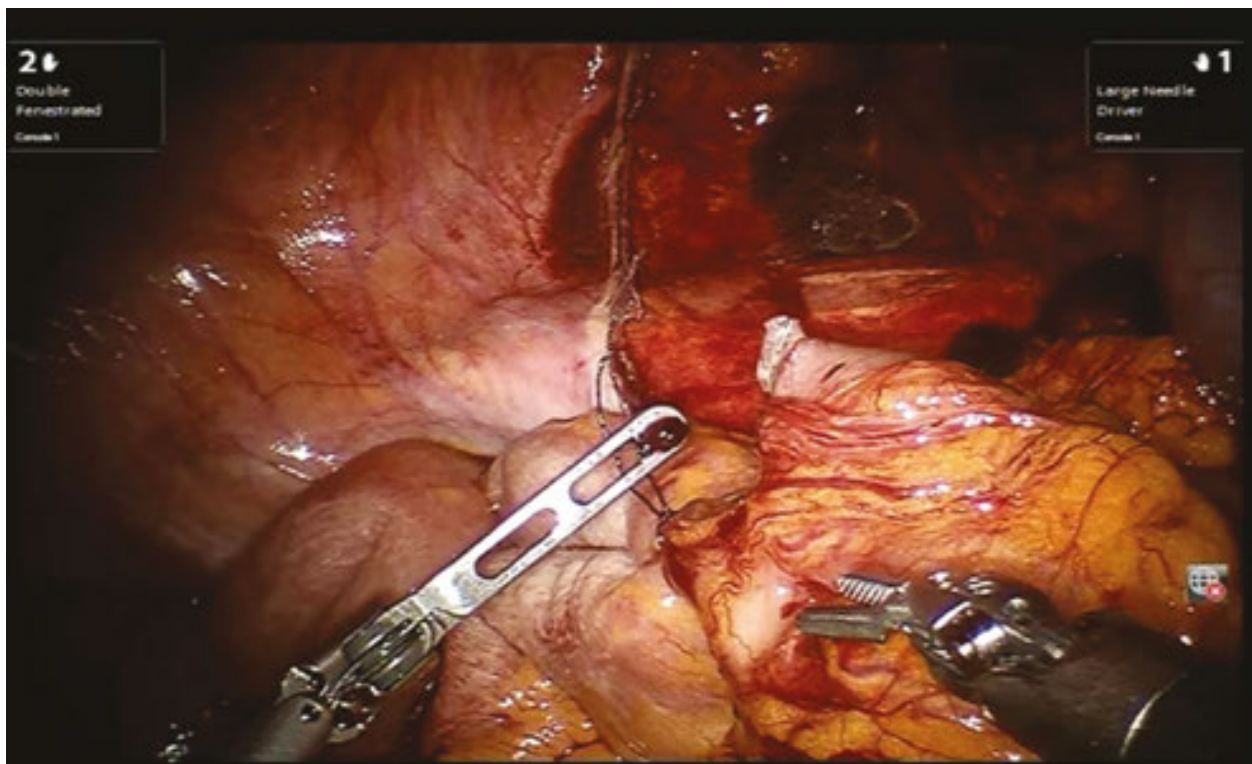


Figure 1. Suspension stitch between the ileal loop and the transverse colon.

Monopolar scissors are mounted on arm 1 and used to create enterotomies.

The surgeon-assistant introduces the larger part of the cartridge inside the colostomy and then the smaller part into the ileum (**Figure 2**). Intracorporeal latero-lateral isoperistaltic anastomosis is done. The enterotomies are then closed with a two-layer suture: the first layer of continuous suture and a second layer of interrupted sero-serosal suture with Vicryl 3/0 (**Figure 3**). A surgical specimen is extracted through the McBurney incision in the right iliac fossa.

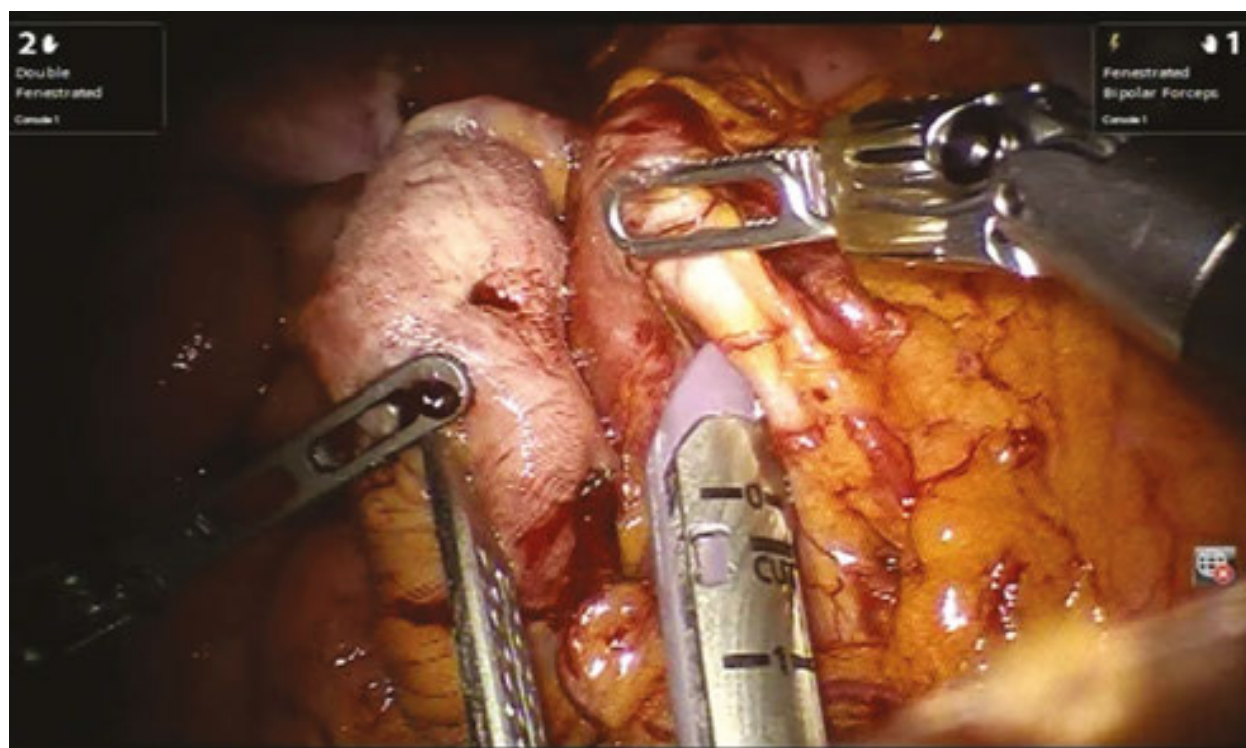


Figure 2. Insertion of the mechanical cartridge into the enterotomies.

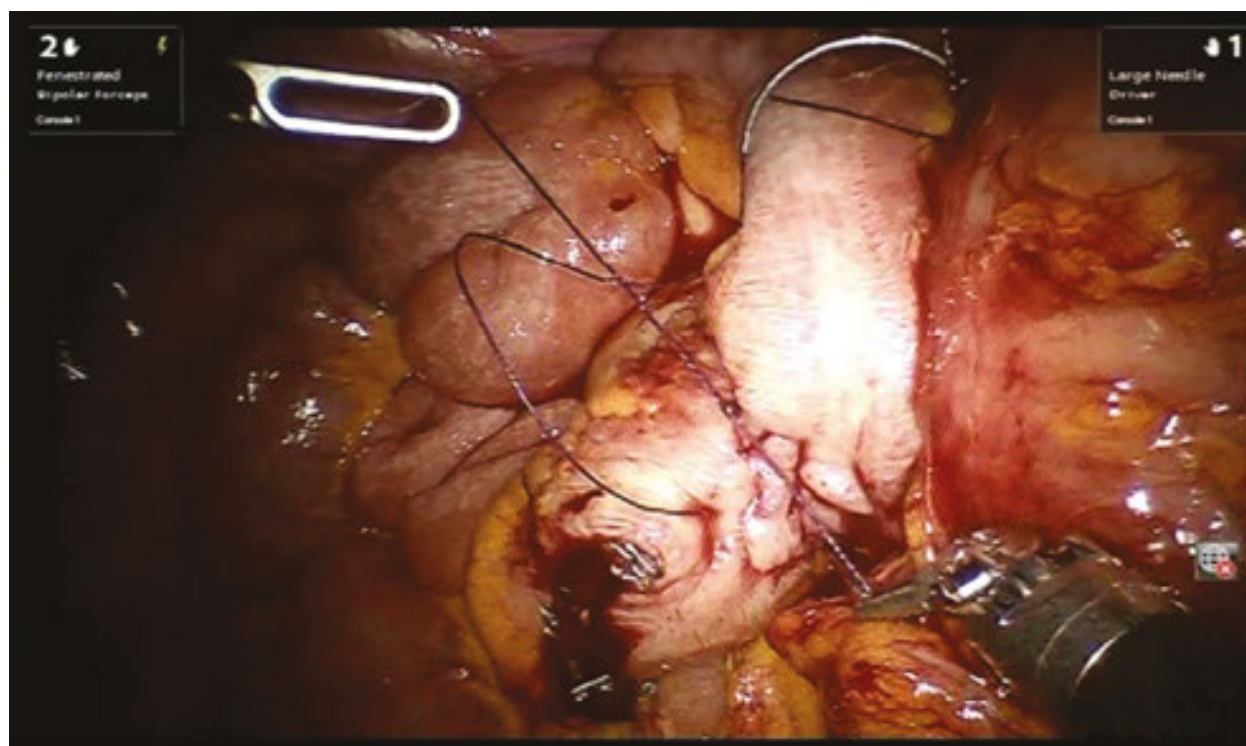


Figure 3. Closure of the enterotomies with a double layer manual suture with Vicryl 3/0.

3. Left colectomy

The patient is placed in a lithomy position with the left arm adducted.

A mild Trendelenburg position and a right tilt are set to expose the operative field. A 12-mmHg pneumoperitoneum is induced through a supraumbilical incision, and the 12-mm port for the camera is placed.

The other three 8-mm robotic ports are positioned under the vision, one on the right midclavicular line 2 cm below the right costal margin and the other in the midline under the xiphoid process. Two 10 mm trocars for the bed-assistant surgeon are added. A total of five ports are positioned. The robotic cart is on the patient's left side. The bipolar vessel sealer is mounted on arm 1. Arm 2 hosts the double fenestrated forceps. The dissection begins from the inferior mesenteric vein that is dissected by a bipolar vessel sealer once it is identified at the level of the inferior border of the pancreas.

The gastrocolic, splenocolic, and coloepiploic ligaments are dissected (**Figure 4**).

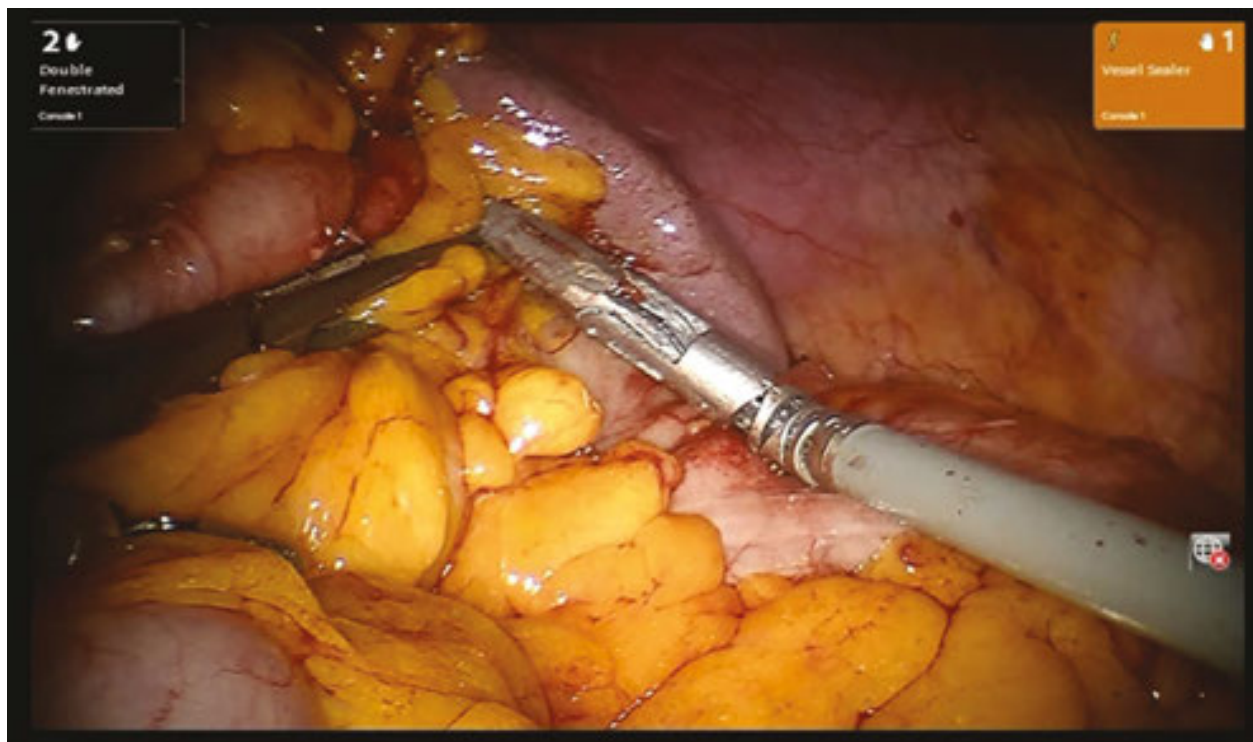

Figure 4. Division of the splenocolic ligament with electrothermal bipolar vessel sealer.

The root of the transverse mesocolon is exposed by the assistant and dissected by bipolar electrocautery to expose the pancreas and allow for a full mobilization of the splenic flexure.

Then, the parietal peritoneum is incised, and the dissection is made on the avascular plane between the two folds of Toldt's fascia.

The assistant pulls up the dissected inferior mesenteric vein with a grasper, and the arch of the inferior mesenteric artery is lifted up.

Once the artery is identified, it is divided between the clips placed by the assistant.

A careful locoregional lymphadenectomy is carried out by preserving the paraaortic nerves and the superior hypogastric plexus.

The colon is resected at the level of the promontory with a mechanical stapler (**Figure 5**).

The anastomosis is fashioned according to the Knight & Griffen technique.

During this step, the robot is usually undocked.

The surgical specimen is extracted through a minilaparotomy in the left iliac fossa. The descending colon is extracted through the protected incision and transected proximally. The anvil of a circular stapler is inserted into the colon stump and fixed by a manual purse-string suture. The colon is then reintroduced into the abdomen and the minilaparotomy is closed. A laparoscopy is carried out to perform the transanal end-to-end mechanical colorectal anastomosis.

Sometimes, we did not undock the robot, and once the colon is reintroduced into the abdomen, robotic instruments are used to perform the end-to-end anastomosis (**Figure 6**).

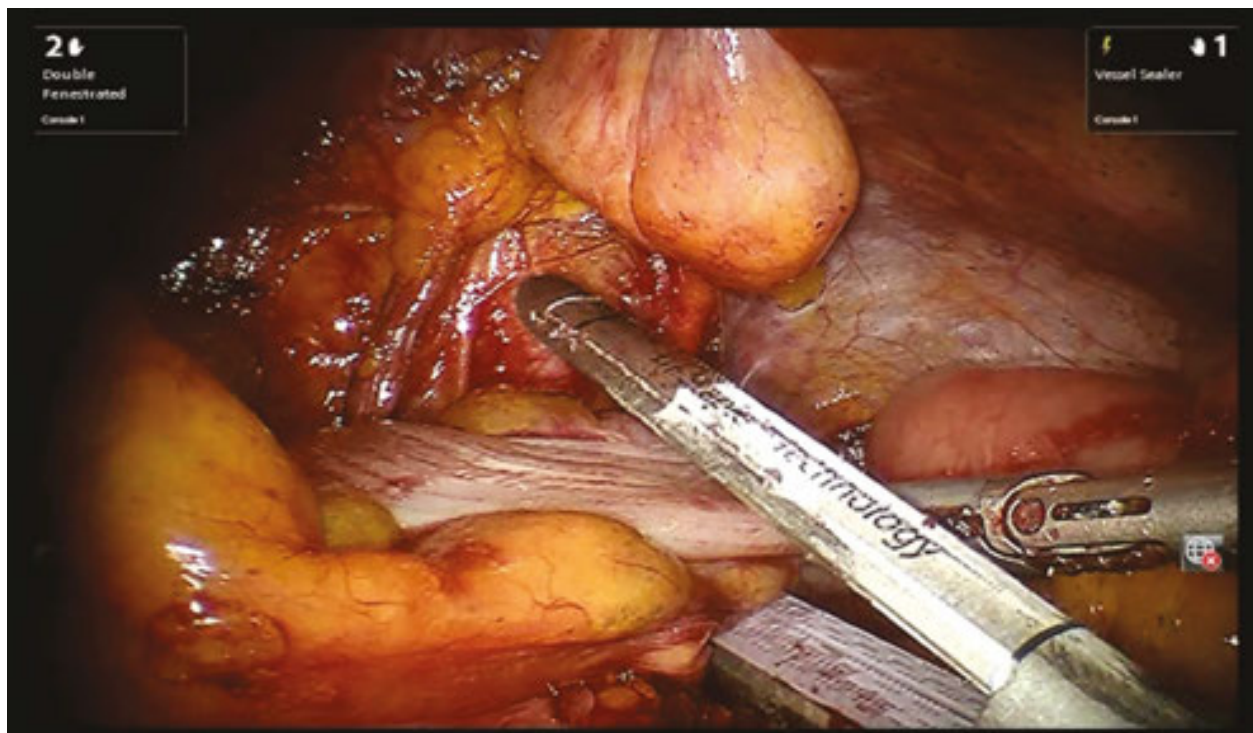


Figure 5. Section of the sigmoid colon at the level of the promontory with the mechanical cartridge.

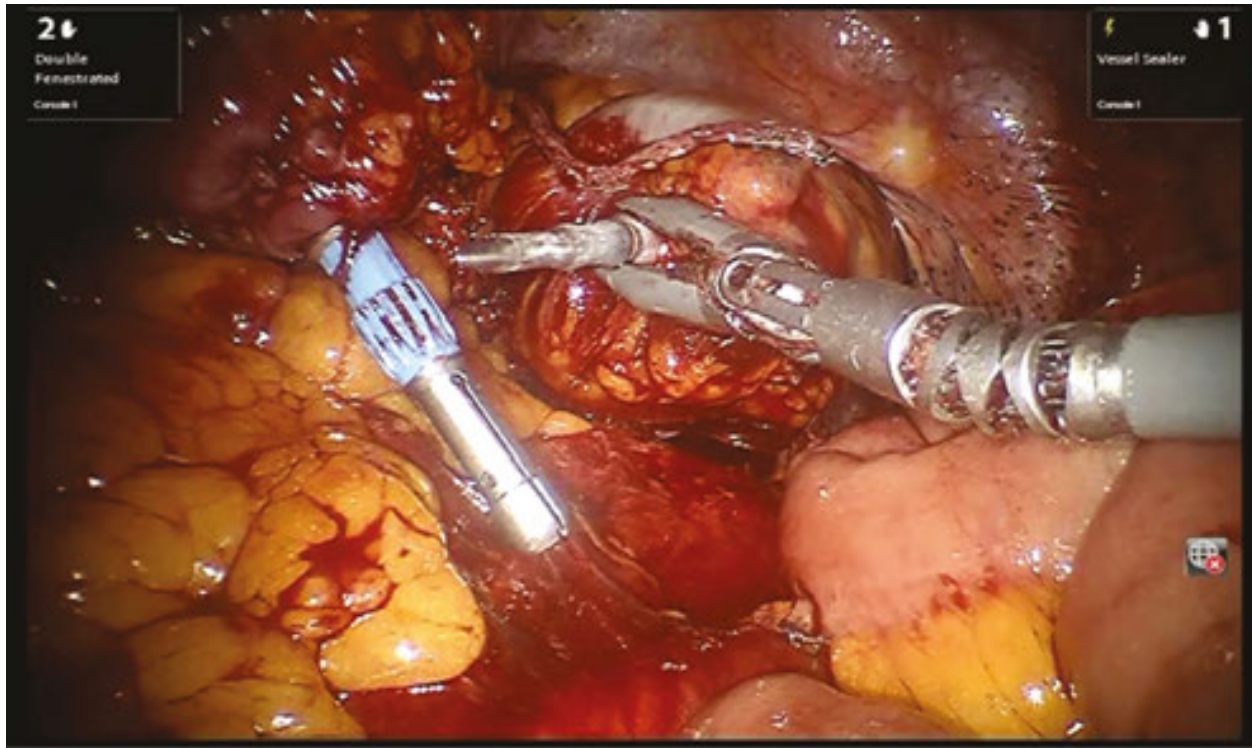


Figure 6. Confection of the end-to-end anastomosis without undocking the robotic system.

4. Advantages

Findings from the literature show how robot-assisted right and left hemicolectomies are comparable to conventional laparoscopic procedures in terms of short-term post-operative outcomes [18].

Patients undergoing robotic procedures typically return to normal activity faster and experience very low mortality and morbidity events [19–25].

The indications for robotic colectomy are well described and include benign conditions, such as inflammatory bowel disease, volvulus, diverticular disease, arteriovenous malformations, ischemic colitis, and polyps not amenable to endoscopic removal [26]. There are also emergent indications such as nearly obstructing lesions, ischemic colitis, and hemorrhage [27, 28].

Patients with contraindications for pneumoperitoneum, with an advanced disease invading adjacent organ and tumor greater than 8 cm in diameter, are contraindicated for robotic colectomy [26].

Colorectal robotic surgery also seems to be feasible for malignant disease comparable results in terms of oncologic radicality and surgical accuracy and in terms of short-term outcomes with respect to standard laparoscopy [18].

In a study of 50 consecutive right colectomies for cancer, D'Annibale et al. did not notice any statistically significant difference between laparoscopic and robotic groups in pathologic parameters and lymph node harvest. They concluded that robotic right colectomy was safe and provided adequate oncologic resection with acceptable short-term results [29].

However, if laparoscopic and robotic colectomies could be compared in terms of post-operative course and oncological outcomes, the robotic system offers several undoubtable technical advantages in performing colon surgery.

Robotic surgery allows an enhanced stabilized three-dimensional stereoscopic vision of the operative field and depth perception beyond the standard two-dimensional laparoscopic monitor [29, 30].

The da Vinci Si system provides hand stabilization, eliminating surgeon tremor and allowing for the refinement of scaled movements [29, 30]. This gives the surgeon the possibility to obtain greater precision in the surgical field.

In addition, the surgeon can work in a more ergonomic position compared with laparoscopic procedures that sometimes require maintaining a difficult posture even in long-lasting procedures [3, 20].

This improved surgical dexterity makes the switch to an intracorporeal anastomosis easier, which may lead to a higher adoption rate for intracorporeal anastomosis for right colectomies.

The potential benefits of intracorporeal anastomosis have been described in several studies and were known from laparoscopy.

Hanna et al. [31] recently concluded that intracorporeal anastomosis in laparoscopic right hemicolectomy is associated with similar post-operative and non-inferior oncologic outcomes compared with extracorporeal anastomosis, but it offers several advantages including freedom of specimen extraction sites, smaller incisions, and a lower risk of conversion to open resection especially in morbidly obese patients.

Hellan et al. [32] have found similar outcomes with intracorporeal and extracorporeal anastomosis but shorter incisions with intracorporeal anastomosis. Grams et al. [33] have reported an earlier return of bowel function, shorter length of hospital stay, and fewer complications.

Better outcomes are achieved when an intracorporeal anastomosis is performed. This is probably because of less traction and tension applied to the colon and the mesentery during an intracorporeal anastomosis as well as because of less trauma to the incision, which may result in less post-operative ileus and fewer complications [31, 34].

Another advantage in performing an intracorporeal anastomosis is the possibility to choose where to make the incision for extraction. In fact, keeping the extraction site far from the midline results in decreased risk of incisional hernia [35, 36].

The three-dimensional vision also provides advantages in mobilizing the left colic flexure with an accurate identification of the flexure borders and its relation to the spleen, while a gentle traction on the spleen is granted by the robotic arm, avoiding the risk of splenic rupture or laceration [14, 27, 36–38, 42].

Authors (years)	Patients (n)	OT (min)	HLN (n)	IC (%)	CR (%)	HS (days)	PC (%)	MR (%)
Rawling et al. [23]	LRC: 15	169.2			13.3	5.5	13.3	
	RRC: 17	189.9			0	5.2	11.7	
Park et al. [19]	LRC: 35	130	30.8	0	0	8.3	17.1	0
	RRC: 35	195	29.9	0	0	7.9	20	0
Deutsch et al. [20]	LRC: 47	214.4	18.7		0	6.3	42.55	2.12
	RRC: 18	219.2	21.1		11.1	4.3	33.33	0
Halabi et al. [21]	LRC: 53413					6	0.04	0.51
	RRC: 670					6	0	0
Casillas et al. [22]	LRC: 110	79	24	0	9.90	29	35	1
	RRC: 52	143	28	0	4.17	19	17	0

LRC, laparoscopic right colectomy; RRC, robotic right colectomy; OT, operative time; IC, intraoperative complications; HLN, harvested lymph node; CR, conversion rate; HS, hospital stay; PC, post-operative complications; MR, mortality rate.

Table 1. Robotic right colectomy data review.

Authors (years)	Patients (n)	OT (min)	HLN(n)	IC (%)	CR (%)	HS (days)	PC (%)	MR (%)
Rawling et al. [23]	LLC: 27	199.4		0	0	6.6	15.38	
	RLC: 30	225.2		7.7	15.38	6	23.07	
Deutsch et al. [20]	LLC: 45	254.7	30		0	4.2	17.7	0
	RLC: 61	289.7	10		3.33	4.1	18.03	0
Casillas et al. [22]	LLC: 68	188	14	0	5.88	32	12	0
	RLC: 82		14	0	5.88	32	12	0
Halabi et al. [21]	LLC: 62235					6	0.04	0.51
	RLC: 1473					6	0	0
Lim et al. [24]	LLC: 34	217.6	16.5			6.2	10.3	0
	RLC: 146	252.5	12			5.5	5.9	0

LLC, laparoscopic left colectomy; RLC, robotic left colectomy; OT, operative time; IC, intraoperative complications; HLN, harvested lymph node; CR, conversion rate; HS, hospital stay; PC, post-operative complications; MR, mortality rate.

Table 2. Robotic left colectomy review data.

The improved dexterity of the instruments favors precise tissue dissection and facilitates lymph node dissection.

Some authors have also reported lower conversion rates for laparoscopic colonic resections [16, 35, 36, 43], ranging from 0 to 4%, compared with 16.7–25%.

In our experience of 42 robotic colectomies, conversion was needed in three patients (7.1%). Two patients, who underwent right colectomy, required conversion to open surgery, one for excessive visceral obesity and the other for adhesions because of previous abdominal surgery. The mean number of lymph nodes in right colectomies (34 cases) and left colectomies (8 cases) was 17.7 and 13.9, respectively. Leak rate and 30-day mortality were 0%.

We recently conducted a retrospective analysis to compare operative measures and post-operative outcomes between laparoscopic 3D and robotic colectomy for cancer.

There were no differences between robotic colonic resections and 3D laparoscopic ones in terms of the number of lymph nodes removed and post-operative outcomes, but we found intracorporeal anastomosis easier to perform in robotic right colectomies than in the laparoscopic ones. In left colectomies, we observed that the robotic technique provided better outcomes, with earlier solid food intake registered in patients [39] (**Tables 1 and 2**).

5. Limitations

The high cost of robotic surgery because of the purchase and maintenance of the equipment is the main limitation to the widespread diffusion of this technology [39]. We estimated a cost of €4,950 for robotic procedures versus €1,950 needed for laparoscopic ones [36]. The cost factor can be prohibitive to the availability of robotic technology restricting it only to bigger centers.

Moreover, a higher number of complications have been observed in the low volume centers when compared with medium- and high-volume centers and surgeons [40].

Furthermore, robotic procedures are associated with a significantly longer operating time. Most of the authors have reported that the docking time was the main cause of longer operating time [3, 18, 41, 44].

There are also some practical and technical disadvantages. The major technical drawback of robotic surgery is the lower tensile feedback. The surgeon must rely on visual clues through the monitor to guide the instrumentation and ensure that appropriate and safe manipulation is preserved by trying to estimate the tension placed on tissues by da Vinci's powerful robotic arms [3, 38]. Performing robotic surgery requires two equally experienced surgeons, one working from the console and the other one staying at the operating table. The risk of system malfunction, inability to reposition the patient once the robot is docked, external and internal collision of the bulky robotic arms, and limited access to the patient by the anesthesia team when the tower is placed have also been observed [3, 20].

6. Conclusions

As was the case with laparoscopy, robotic technology will certainly undergo substantial development in the near future. It has proven to be safe and feasible also in the case of cancer and comparable to laparoscopy, but it still presents some drawbacks.

However, the real benefit to the patient must be carefully proven before this technology can become widely accepted in clinical practice.

Author details

Monica Ortenzi*, Giovanni Lezoche, Roberto Ghiselli and Mario Guerrieri

*Address all correspondence to: monica.ortenzi@gmail.com

Polytechnic University of Marche, Surgical Clinic, United Hospitals, Ancona, Italy

References

- [1] Ballantyne GH. (2002). Robotic surgery, telerobotic surgery, telepresence, and tele-mentoring: review of early clinical results. *Surg Endosc.* 10: 1389–1402.
- [2] Yohannes P, Rotariu P, Pinto P, Smith AD, Lee BR. (2002). Comparison of robotic versus laparoscopic skills: is there a difference in the learning curve? *Urology.* 1: 39–45.
- [3] Corcione F, Esposito C, Cuccurullo D, Settembre A, Miranda N, Amato F, Pirozzi F, Caiazzo P. (2005). Advantages and limits of robot-assisted laparoscopic surgery: preliminary experience. *Surg Endosc.* 19(1): 117–119.
- [4] Kwoh YS, Hou J, Jonckheere EA, Hayati S. (1988). A robot with improved absolute positioning accuracy for CT guided stereotactic brain surgery. *IEEE Trans Biomed Eng.* 35(2): 153–160.
- [5] Semm K. (1983). Endoscopic appendectomy. *Endoscopy.* 15: 59–64.
- [6] Davies BL, Hibberd RD, Coptcoat MJ, Wickham JE. (1989). A surgeon robot prostatectomy—a laboratory evaluation. *I Med Eng Tech.* 13: 273–277.
- [7] Harris SJ, Arambula-Cosio F, Mei Q, Hibberd RD, Davies BL, Wickham JEA, Nathan MS, Kundu B. (1997). The Probot—an active robot for procedures. *Proc Inst Mech Eng H.* 211: 317–325.
- [8] Ho G, Ng WS, Teo MY. (2001). Experimental study of transurethral robotic laser resection of the prostate using the laser Trode lightguide. *J Biomed Opt.* 6: 244–251.
- [9] Ho G, Ng WS, Teo MY, Cheng WS. (2001). Computer-assisted transurethral laser resection of the prostate (CALRP): theoretical and experimental motion plan. *IEEE Trans Biomed Eng.* 48: 1125–1133.
- [10] Unger SW, Unger HM, Bass RT. (1994). AESOP robotic arm. *Surg Endosc.* 8: 1131.

- [11] Kalan S, Chauhan S, Coelho RF, et al. (2010). History of robotic surgery. *JRS*. 4(3): 141–147.
- [12] Falcone T, Goldberg J, Garcia-Ruiz A, Margossian H, Stevens L. (1999). Full robotic for laparoscopic tubal anastomosis: a case report. *J Laparoendosc Adv Surg Tech A*. 9: 107–113.
- [13] Marescaux J, Leroy J, Rubino F, et al. (2002). Transcontinental robot-assisted remote telesurgery: feasibility and potential applications. *Ann Surg*. 235(4): 487–492.
- [14] Weber P, Merola S, Wasielewski A, Ballantyne GH. (2002). Telerobotic-assisted laparoscopic right and sigmoid colectomies for benign disease. *Dis Colon Rectum*. 45(12): 1689–1696.
- [15] Ballantyne GH, Moll F. (2003). The da Vinci telerobotic surgical system: the virtual operative field and telepresence surgery. *Surg Clin North Am*. 6: 1293–1304.
- [16] Spinoglio G, Marano A, Priora F, Melandro F, Formisano G. (2015). History of robotic surgery. In: Spinoglio G. Editor. *Robotic Surgery: Current Applications and New Trends*. Springer-Verlag Italia, 2–12.
- [17] Hagen ME, Curet MJ. (2014). The da Vinci Surgical® Systems. In: Watanabe G. *Robotic Surgery*. Springer Edition, 9–19.
- [18] Spinoglio G, Summa M, Priora F, Quarati R, Testa S. (2008). Robotic colorectal surgery: first 50 cases experience. *Dis Colon Rectum*. 51(11): 1627–1632.
- [19] Park JS, Choi GS, Park SY, Kim HJ, Ryuk JP. (2012). Randomized clinical trial of robot assisted *versus* standard laparoscopic right colectomy. *Br J Surg*. 99: 1219–1226.
- [20] Deutsch GB, Sathyanarayana SA, Gunabushanam V, Mishra N, Rubach E, Zemon H, Klein JD, Denoto G, 3rd. (2012). Robotic vs. laparoscopic colorectal surgery: an institutional experience. *Surg Endosc*. 26(4): 956–963.
- [21] Halabi WJ, Kang CY, Jafari MD, Nguyen VQ, Carmichael JC, Mills S, Stamos MJ, Pigazzi A. (2013). Robotic-assisted colorectal surgery in the United States: a nationwide analysis of trends and outcomes. *World J Surg*. 37(12): 2782–2790.
- [22] Casillas MA, Jr., Leichtle SW, Wahl WL, Lampman RM, Welch KB, Wellock T, Madden EB, Cleary RK. (2014). Improved perioperative outcomes of robotic versus conventional laparoscopic colorectal operations. *Am J Surg*. 208(1): 33–40.
- [23] Rawlings AL, Woodland JH, Vegunta RK, Crawford DL. (2007). Robotic versus laparoscopic colectomy. *Surg Endosc*. 21(10): 1701–1708.
- [24] Lim DR, Min BS, Kim MS, Alasari S, Kim G, Hur H, Baik SH, Lee KJ, Kim NK. (2013). Robotic versus laparoscopic anterior resection of sigmoid colon cancer: comparative study of long-term oncologic outcomes. *Surg Endosc*. 27(4): 1379–1385.

- [25] Delaney CP, et al. (2003). Comparison of robotically performed and traditional laparoscopic colorectal surgery. *Dis Colon Rectum*. 46:1633–1639.
- [26] NCCN Clinical Practice Guidelines in Oncology: Colon Cancer. (2013). The National Comprehensive Cancer Network. <http://www.nccn.org>. Accessed 10 December 2012.
- [27] Mutch M, Cellini C. (2011). Surgical management of colon cancer. In: Beck DE, Roberts PL, Saclarides TJ, Senagore AJ, Stamos MJ, Wexner SD. Editors. *The ASCRS Textbook of Colon and Rectal Surgery*. Second Edition, New York, NY: Springer Science + Business Media, LLC. 711–720.
- [28] Lujan HJ, Plasencia G. (2014). Robotic right colectomy: three-arm technique. In: Kim KC. Editor, Springer Edition.
- [29] D'Annibale A, Pernazza G, Morpurgo E, Monsellato I, Pende V, Lucandri G, Termini B, Orsini C, Sovernigo G. (2010). Robotic right colon resection: evaluation of first 50 consecutive cases for malignant disease. *Ann Surg Oncol*. 17: 2856–2862.
- [30] D'Annibale A, A, Morpurgo E, Fiscon V, Trevisan P, Sovernigo G, Orsini C, Guidolin D. (2004). Robotic and laparoscopic surgery for treatment of colorectal diseases. *Dis Colon Rectum*. 47(12): 2162–8.
- [31] Hanna MH, Hwang GS, Phelan MJ, Bui TL, Carmichael JC, Mills SD, Stamos MJ, Pigazzi A. (2015). Laparoscopic right hemicolectomy: short- and long-term outcomes of intracorporeal versus extracorporeal anastomosis. *Surg Endosc*. Dec 29
- [32] Hellan M, Stein H, Pigazzi A. (2009). Totally robotic low anterior resection with total mesorectal excision and splenic flexure mobilization. *Surg Endosc*. 23: 447–451.
- [33] Grams J, Tong W, Greenstein AJ, Salky B. (2010) Comparison of intracorporeal versus extracorporeal anastomosis in laparoscopic-assisted hemicolectomy. *Surg Endosc*. 24(8): 1886–1891.
- [34] Scatizzi M, Kroning KC, Borrelli A, Andan G, Lenzi E, Feroci F. (2010). Extracorporeal versus intracorporeal anastomosis after laparoscopic right colectomy for cancer: a case controlled study. *World J Surg*. 34: 2902–2908.
- [35] Samia H, Lawrence J, Nobel T, Stein S, Champagne BJ, Delaney CP. (2013). Extraction site location and incisional hernias after laparoscopic colorectal surgery: should we be avoiding the midline? *Am J Surg*. 205: 264–226.
- [36] Campagnacci R, Baldoni A, Ghiselli R, Cappelletti-Trombettoni MM, Guerrieri M. (2015). Prevention of hernia incision in laparoscopic left colon resection. *Minerva Chir*. 70(3): 155–160.
- [37] Anvari M, Birch DW, Bamehriz F, Gryfe R, Chapman T. (2004). Robotic-assisted laparoscopic colorectal surgery. *Surg Laparosc Endosc Percutan Tech*. 14: 311–315.
- [38] Rawlings AL, Woodland JH, Crawford DL. (2006). Telerobotic surgery for right and sigmoid colectomies: 30 consecutive cases. *Surg Endosc*. 20: 1713–1718.

- [39] Guerrieri M, Campagnacci R, Sperti P, Belfiori G, Gesuita R, Ghiselli R. (2015). Totally robotic vs 3D laparoscopic colectomy: a single centers preliminary experience. *World J Gastroenterol.* 21(46): 13152–13159.
- [40] Keller DS, Hashemi L, Lu M, Delaney CP. (2013). Short-term outcomes for robotic colorectal surgery by provider volume. *J Am Coll Surg.* 217: 1063–1069.
- [41] Cirocchi R, Cochetti G, Randolph J et al. (2014). Laparoscopic treatment of colovesical fistulas due to complicated colonic diverticular disease: a systematic review. *Tech Coloproctol.* doi:10.1007/s10151-014-1157-5
- [42] DeSouza AL, Prasad LM, Park JJ, Marecik SJ, Blumetti J, Abcarian H. (2010). Robotic assistance in right hemicolectomy: is there a role? *Dis Colon Rectum.* 53: 1000–1006.
- [43] Jayne DG, Thorpe HC, Copeland J, Quirke P, Brown JM, Guillou PJ. (2010). Five-year follow-up of the Medical Research Council CLASICC trial of laparoscopically assisted versus open surgery for colorectal cancer. *Br J Surg.* 97: 1638–1645.
- [44] Zimmern A, Prasad L, Desouza A. (2010). Robotic colon and rectal surgery: a series of 131 cases. *World J Surg.* 34: 1954–1958.

