

We are IntechOpen, the world's leading publisher of Open Access books Built by scientists, for scientists

4,800

Open access books available

122,000

International authors and editors

135M

Downloads

Our authors are among the

154

Countries delivered to

TOP 1%

most cited scientists

12.2%

Contributors from top 500 universities



WEB OF SCIENCE™

Selection of our books indexed in the Book Citation Index
in Web of Science™ Core Collection (BKCI)

Interested in publishing with us?
Contact book.department@intechopen.com

Numbers displayed above are based on latest data collected.

For more information visit www.intechopen.com



Botulinum Toxin in the Nasal Area

Diego Schavelzon, Guillermo Blugerman, Gabriel Wexler and Lorena Martinez

Additional information is available at the end of the chapter

<http://dx.doi.org/10.5772/62070>

Abstract

Introduction: Botulinum toxin type A for aesthetic purposes has been used since 1987, proving to be one of the most popular procedures in aesthetics due to its effectiveness in softening dynamic wrinkles.

Nasoglabellar lines or bunny lines: They are the result of the contraction of the nasal transversus. They can be primary or secondary, the latter as a result of muscle blockade in glabellar region, generating a compensatory contraction.

Specific application

Nasal tip ptosis: As people age the nasal tip tends to fall due to gravity forces and due to the kinetic action of the depressor of the septum muscle. The application of Botox in this area will only have positive results if the ptosis is of muscular cause.

Nasal flutter: Physical or emotional stress causes the involuntary contraction of the anterior and posterior dilator naris. Also the injection in these muscles produces the stretching of nostrils of very wide noses, when these muscles are active (they can move the ala).

Hyperhidrosis of nasal dorsum: The precise diagnosis of the areas is done through the Minor test (iodinated alcohol and starch). The injection is done in the dermis until the skin turns white, 1–2 UI per injection, separating them by 1cm.

Multiple eccrine hidrocystomas: This papula-cystic lesion, described by Andrew Ross Robinson, has a transparent dome through which a blue color is seen, usually confused with blackhead. They originate in sweat ducts and come out associated with hyperhidrosis.

Keywords: BOTOX nasal applications, Botulinum toxin, bunny lines, dynamic wrinkles, gingival smile, nasal anatomy, nasal cosmetic procedures, nasal dermatology, nasal dynamics, nasal flutter, nasal hyperhidrosis, nasal muscles, nasal proportions, nasal tip ptosis, nose aesthetics, multiple eccrine hidrocystomas, minimal invasive procedures, muscle blockade, wide nose

1. Introduction

Since 1987, Botulinum toxin type A has been used to enhance the aesthetic appearance of the upper third of the face (Fig. 1). The main effect is softening of dynamic wrinkles by diminishing mimic muscles contraction. Nowadays, the cosmetic use of Botulinum toxin is no longer limited to this area and has extended to the inferior third of face, neck, and the medial facial area and to the nose, which is the main subject of this book.

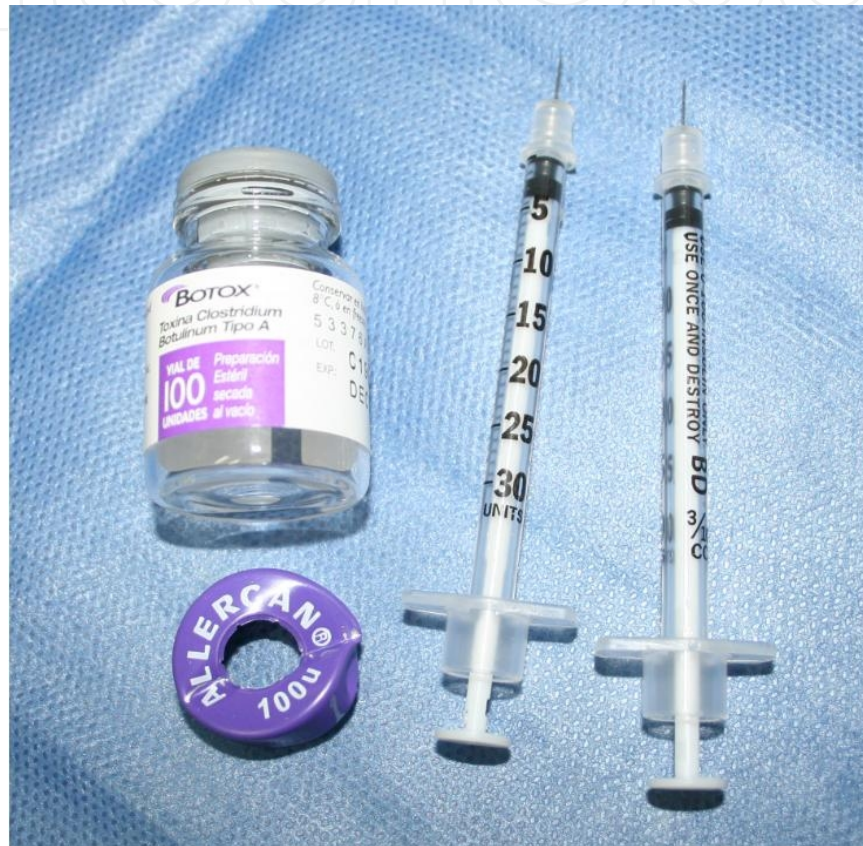

Figure 1. Commercial presentation of Botox®. Syringes used for application.

Botulinum toxin type A's popularity has increased in the past years, proving to be the most popular aesthetic procedure in the world, according to international scientific societies, mainly due to its safety and predictable results. We have large experience in the use of Botulinum toxin in the nose and other facial areas. In this chapter, we will share our experience with Botulinum toxin type A in nasal muscles.

1.1. Nasal muscles

According to Latourneau and Daniel [1], the superficial musculoaponeurotic system (SMAS) that covers the nasal dorsum and ala is composed by eight muscles that share common fascias with neighboring areas such as lids, cheeks, lips, and forehead.

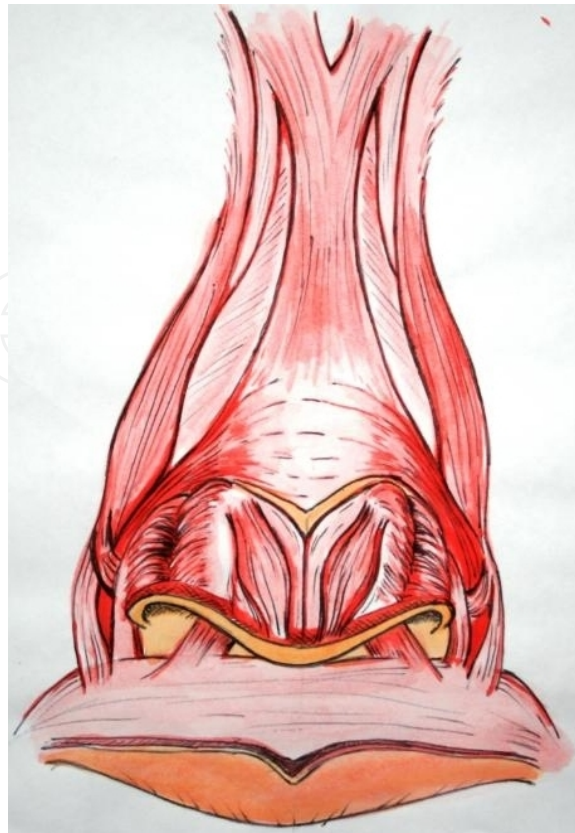


Figure 2. Nasal muscles. Front view.

Different authors have classified these muscles based on various criteria (Figs. 2 and 3). Aiach and Levignac [2] classify them according to the level of insertion in relation to the nostrils: above or below. Griesman [3] uses a physiological criterion, dividing them in elevators, depressors, dilators, and constrictors:

- Elevators that shorten the nose and open the nostrils:
 - *Procerus*
 - *Levator labii superioris alaeque nasi*
 - *Anomalus nasi*
- Depressors that enlarge the nose and open nostrils:
 - *Alar nasalis (dilator naris posterior)*
 - *Depressor septi nasi*
- Compressors that enlarge the nose and stretch nostrils:
 - *Transverse nasalis*
 - *Compressor narium minor*
- Dilators:

- *Dilator naris anterior*

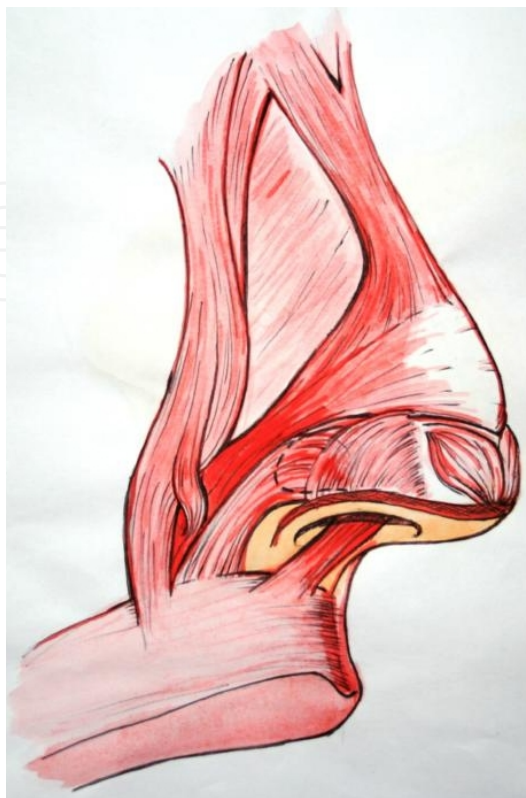


Figure 3. Nasal muscles. Lateral view.

The *procerus* originates in the *transverse nasalis* aponeurosis, nasal bones periosteum, and nasal lateral cartilage perichondrium, and ends in glabellar skin. As an elevator it antagonizes the *transverse nasalis* depressor action.

The *levator labii superioris alaeque nasi* originates in the medial portion of the *orbicularis oculi* and the frontal process of the maxilla, inserting down in the nasolabial fold, nasal ala, and skin and muscles of the upper lip. It has a nasal fascicle that covers the origin of the *transverse nasalis*. The main function is to elevate the nasal ala and open the nostrils.

The *anomalus* originates in the frontal process of the maxilla inserting in nasal bones, nasal lateral cartilage, the *procerus*, and the *transverse nasalis*. It is present in 50% of the population.

The *alar nasalis*, also known as *dilator naris posterior*, originates in the maxilla over the lateral incisor and inserts in the nasal ala. This muscle opens the nostrils.

The *depressor septi nasi* originates in the nasal spine of the maxilla inserting in the membranous septum and medial crus of alar cartilages. The contraction of this muscle turns downward the nasal tip. According to Zide [4], there are some superficial fibers that originate in the *orbicularis oris*, and insert in the columella, which are responsible for the elevation of the lip as the nasal tip turns down.

The *transverse nasalis* originates in the maxilla above the incisor fossa, sharing some fibers with the *levator labii superioris alaeque nasi*, then it inserts in an aponeurosis over the nasal dorsum, joining with the contralateral muscle. The contraction of this muscle stretches the nasal vestibule by descending the lateral crus of the alar cartilage.

The *compressor narium minor* is a small muscle that descends from the nasal lateral cartilage to the skin over the nostrils. It is present in 57% of the population. Superficial to this muscle is the *dilator naris anterior*, whose main function is to open the nostrils. This is a fan-shaped muscle that originates in the nasal lateral cartilage and the *transverse nasalis* and inserts in the caudal border of the lateral crus of the alar cartilage and in nostrils skin. The contraction of this muscle can be felt by compressing the nasal ala between two fingers.

2. Botulinum toxin properties

Clostridium Botulinum are bacteria that produce different types of toxins. Seven types have been identified, known as A, B, C, D, E, F, and G. They all produce denervation and atrophy of muscles. The most powerful is toxin A, being the elective treatment of many dystonias. Type B is also available for medical use; it has a faster but shorter effect (Myobloc®).

We refer to our experience with toxin A commercialized by Allergan with the name BOTOX® (other products differ in pharmacodynamics and pharmacokinetics).

3. Toxin handling

Botulinum toxin is commercialized as crystallized powder that contains 100 UI per vial. Reconstitution should be done with sterile, preservative-free saline solution. The product final concentration depends on the volume used for reconstitution. For cosmetic use in the nasal area, reconstitution of the toxin is recommended to be done with 1 ml of saline solution per vial. This avoids diffusion to neighboring muscles, preventing undesired effects.

The manufacturer recommends the use within 4 HS after reconstitution, but experience has demonstrated that the reconstituted solution does not lose effectiveness if conserved in a refrigerator at 4°C.

We like to use 0.3 ml syringes with 30 G needle (Ultrafine II. Becton Dickinson-BD) for precise application. These syringes do not have dead space so no solution is lost and allows a better dosage, a fundamental aspect in the nasal area.

Botulinum toxin can be injected intramuscular, subcutaneous, or intracuticular. Anesthetic cream can be applied locally if the patient is oversensitive. Other way to reduce pain is using cold packs.

4. Side effects and precautions

In patients with neuromuscular diseases such as myasthenia gravis or amyotrophic lateral sclerosis, it is relatively contraindicated. Application should be avoided during pregnancy and lactation. Drug interaction is limited to aminoglycosides, with which a lower dose is recommended. Most secondary effects are due to toxin diffusion to neighboring muscles. This is preventable using correct doses and injection planes. There are no long-term effects described with the toxin. With repeated application the effect can diminish, probably due to antitoxin antibodies.

5. Dosage and frequency

The clinical effect of the toxin starts between the second and the fourth day, and regularly lasts for four or five months. Generally, patients that are happy with the result come back to repeat the application when the effect starts to diminish. Stronger muscles require higher doses. When working in small areas, to prevent diffusion to neighboring muscles, reconstitution with lower volumes of saline solution is recommended. As a general rule, the limit per application per session is 400 UI, doses that are only used for spastic paralysis. In the nasal region, doses never exceed 20 UI.

6. Nasal application

6.1. Nasoglabellar wrinkles and bunny lines

Over the lateral wall of the nasal bridge an important percentage of the population have diagonal lines that go toward the nasal ala. This has been the first indication of BOTOX® in the nasal area suggested by Carruthers [5].

These wrinkles or bunny lines can be primary or secondary. The secondary ones, also known as BOTOX® effect, appear after the treatment with toxin in the glabellar muscles. That is why when treating frown wrinkles it is important to advert to patients the possibility of developing compensatory nasoglabellar wrinkles. This compensatory effect develops mostly in women that already have an insinuation of these wrinkles and have an outdoor life, which generates muscle contraction by sun exposure. By blocking frown muscles some people start contracting involuntarily the *nasalis transverse*. Primary wrinkles are frequent in people that gesticulate a lot, users of heavy glasses, chronic rhinitis, and those with clear eyes that try to close the lids in response to sun or light. These muscles get hypertrophied and hyperfunctional by forced and constant contraction, provoking wrinkles in the thin skin that covers them. They are more frequent in Caucasian people, and they get accentuated when they smile, talk, or get angry. Men have a thicker skin, thus having fewer wrinkles.

In patients with previous rhinoplasty, Botulinum toxin clinical effect is less evident, probably due to anatomic changes and muscular scar provoked by surgery.

It is important to differentiate wrinkles provoked by the *transverse nasalis* (described above) from wrinkles provoked by the *procerus*. The latter are horizontal lines that appear in the nasal root when the glabellar skin is pulled down by the contraction of the *procerus*. By eliminating both these wrinkles, a juvenile and relaxed appearance is obtained in the mid face. When we do not treat simultaneously the nasoglabellar and the glabellar wrinkles, the untreated ones develop compensatory contraction, producing a strange effect on nasal image.

Tamura [6] pointed out that in 40% of patients, the nasoglabellar wrinkles can be treated with 3 UI injected in each nasal wall in the muscular body. The other 60% of the patients present different patterns of muscular contraction, needing additional 2 UI in neighboring areas. He identifies three patterns of wrinkles that appear within the first 4 weeks of application: nasoalar, nasoorbicular, and nasociliar. The nasoalar lines are produced by the contraction of the alar fibers of the *levator labii superioris* and must be treated just over the nasal ala. The nasoorbicular and the nasociliar are produced by the contraction of the *orbicularis oculi*.

We inject 2–4 UI of Botulinum toxin in the *transverse nasalis* belly where it goes over the nasal bone. Then we observe the evolution, and if necessary perform the corrections following Tamura's recommendation.

6.1.1. Precaution

It is important to inject above the nasofacial groove to prevent diffusion of toxin to the *levator labii superioris*, causing lip ptosis and lip asymmetry. This can cause incompetence of the labial sphincter, creating problems to eat and talk.

Less frequent, but not less important complication is toxin diffusion to the *orbicularis oculi*, diminishing the pump effect over the lacrimal sac causing tearing. Diffusion to the *medial rectus* of the eye has been described, causing blurred vision.

It is important to avoid injecting the product in the angular artery, which can cause thrombosis and blindness.

To prevent these complications that are mainly caused by diffusion to neighboring muscles, and for which there is no antidote, it is preferable to avoid any kind of massage in the area after applying the toxin.

6.2. Nasal tip ptosis

As people age, the nasal tip tends to turn downward partially by the gravity forces and partially caused by the hyperkinetic action of the *depressor septi nasi* muscle over the caudal portion of the nasal septum. When this occurs, appearance turns senile, evil, and witch-like.

The importance of the *depressor septi nasi* in rhinoplasty has been remarked upon many years ago. Wright [7] in 1976 noted that a hyperactive muscle contributed to the tip ptosis, and that this phenomenon could be diagnosed by the "smile test." In 1983, Ham [8] reported that the

depressor septi nasi was responsible for the tension in nasal tip and dorsum, and he recommended this muscle transection to solve the problem. Cachay-Velazquez [9, 10] described in 1992 the “rhino-gingivo-labial syndrome of the smile.” He points out the importance of dynamic examining of face, which can reveal aesthetic imperfections, not so evident at rest. The rhino-gingivo-labial syndrome of the smile includes:

- Nasal tip ptosis
- Elevation and shortening of the superior lip
- Increased exposure oral mucosa

The author attributes this syndrome to the *depressor septi nasi* hypertrophy. For the correction he proposes excision of the *depressor septi nasi*, and a partial excision of *orbicularis oris* and *nasalis* muscles through a stab incision. There are no cases of nasal obstruction in the clinical experience of the author, contrary to what Converse [11] revealed about the importance of conserving this muscle.

De Souza Pinto [12] reported his technique called “dynamic rhinoplasty.” He uses a Z-plasty based on the labial bridle and combines relaxation of the medial fascicle of the *depressor septi nasi*, with horizontal or vertical plication of the intermediate fascicle, depending on the length of the superior lip.

The nasal tip ptosis generally coincides with a short superior lip, entity described by Rohrich [13] as the functional unity of the inferior third of the nose. The *depressor septi nasi* and the *levator labii superioris alaeque nasi* are responsible for the muscular forces affecting this area in the dynamic and static models. The *depressor septi nasi* is sometimes considered as part of the *dilator naris*, muscle that originates in the incisor fossa of the maxilla, just below the *orbicularis oris*, and in the mucosa of the superior lip. The *depressor septi nasi* pulls down the nasal septum and ala stretching the nostrils. The interdigitation of this muscle with *dilator naris* is present in a small percentage of the population. In these cases, a paradoxical opening of the nostrils is provoked when these muscles contract together.

Due to anatomical variations described above and the multifactorial etiology of the nasal tip ptosis, BOTOX® application will have positive results only when the main cause of the defect is the muscular action. To evaluate the muscular strength it is important to observe the functional unity of the inferior third of the nose during forced smile. With this observation, we can predict which patients will have a good result with toxin. To perform the procedure we have to pull down the patient’s upper lip over the teeth in order to open the nasolabial angle. In this way we elongate the muscle, making easier the identification of the muscle insertion in the base of the columella, where the needle should be introduced to inject 2–4 UI in the subcutaneous to avoid diffusion to the *orbicularis oris* (Fig. 4). If we are in the presence of a strong muscle, additional 2 UI can be used in the mid columella. In patients with interdigitation of the *depressor septi nasi* and the *dilator naris*, additional 4–5 UI are recommended in the nasal ala dorsum, inside the *dilator naris*, in order to obtain a better tip projection.

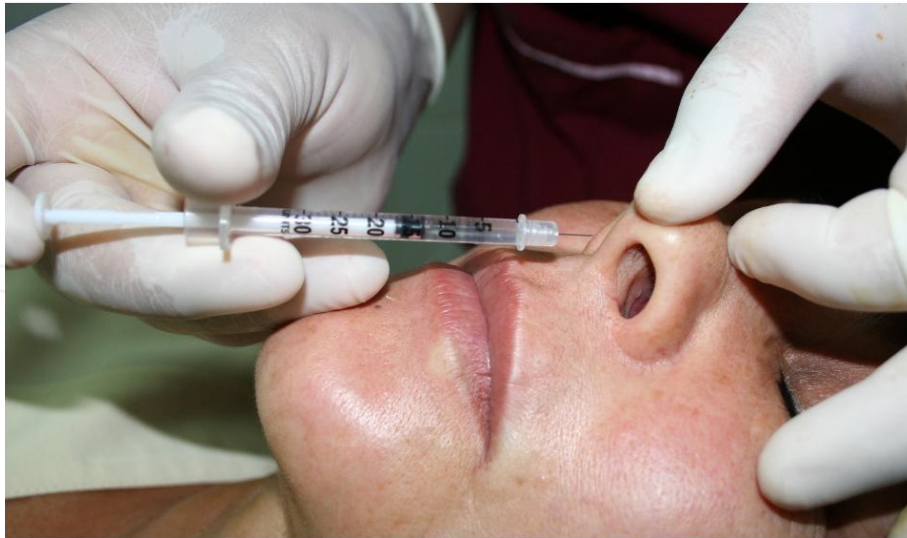

Figure 4. Application in the depressor septi nasi.

Peres Atamoros [14] created a therapeutic protocol that allows measuring of the tip elevation when using BOTOX®. He establishes that for a soft elevation, 2 UI must be injected in each *dilator naris* and 2 UI in the *depressor septi nasi* (total of 6 UI). For a medium elevation, 4 UI should be injected in each point (total of 12 UI). Finally, for a strong elevation 6 UI should be injected in each point (total of 18 UI).

In some patients, the use of BOTOX® increases the distance between the columellar base and the vermilion border, creating the appearance of a fuller and voluminous lip. It can also correct the gingival smile. If the toxin diffuses laterally in the base of the columella, it can affect the *levator labii superioris* and the *orbicularis oris*, provoking an unaesthetic elongation of the superior lip, filtrum flattening, and labial sphincter incompetence when talking and drinking.

The use of high doses in the nasal tip can produce an exaggerated opening of the nostrils and a strong elevation of the tip, leaving an unattractive appearance in the frontal view. The clinical effect in this area usually lasts for a shorter time than other parts of the face. The first days after the injection, the patient can experience pain in the nasal tip.

In order to obtain satisfactory results in nasal tip ptosis correction, it is important to understand the mechanism of the downward rotation of the tip when smiling. This mechanism depends on a functional unity with three components:

1. Cartilage frame (alar and accessory cartilages acting as a unique structure)
2. Muscle engine (*depressor septi nasi* and *levator labii superioris alaeque nasi*)
3. Neighboring structures (piriform fossa, valvular mechanism between the lateral and alar cartilages, areolar tissue of nasal dorsum and membranous septum)

BOTOX® application does not replace surgery in patients with static nasal tip ptosis, but it is useful in dynamic ptosis and in other defects caused by a hypertrophic or hyperactive *depressor septi nasi*, and with patients that do not desire a rhinoplasty. Besides, BOTOX® can be used

temporarily in patients that are evaluating a surgical procedure. The application of toxin is a great combination with other minimal invasive procedures as bioplasty, fillers, and nasal rein. It is possible to obtain a reduction of the dynamic nasal tip ptosis, a correction on the shortening of the superior lip, and apparent absence of philtrum by using BOTOX® (Allergan Inc. Irvine, California).

When the *depressor septi nasi* contracts the nasal tip descends, making more evident the nasal tip ptosis. According with the interdigitation of this muscle with the *orbicularis oris*, it is classified in three subtypes:

1. Type I: totally inserted in the *orbicularis oris* (62%)
2. Type II: inserted in the periosteum and partially in the *orbicularis oris* (22%)
3. Type III: rudimentary muscle or absent

The *levator labii superioris alaeque nasi* originates in the frontal process of the maxilla and inserts down in skin of the nasal ala and superior lip. Its action is to elevate the superior lip and nasal ala. When contracting, together with the *depressor septi nasi* they descend the nasal tip while ascending the nasal ala and superior lip, thus opening the nostrils. Their contraction also produces a horizontal wrinkle, which divides the philtrum, and oral mucosa exposure. Until the discovery of the Botulinum toxin, acting over these muscles was only possible through surgical procedures. Now we can, applying 5 UI in the *depressor septi nasi* and 3 UI in each *levator labii superioris alaeque nasi*, attenuate this muscle's action, diminishing tip ptosis during smile, leaving the alar insertion in a neutral position. Also, the nasal angle opens to 110–115°. Satisfaction index in patients is very high and we have not observed serious secondary effects as labial sphincter incompetence or problems with talking.

With Botulinum toxin we can:

1. Correct the balance between the tip and the lip
2. Elongate the superior lip
3. Create the appearance of superior lip fullness
4. Keep the rotation:projection proportion during movement
5. Preserve the motor and sensitive innervation of the superior lip

In patients where the nasal tip ptosis is mainly due to aging, the result of BOTOX® is not as good as in young people where the muscular hypertrophy plays a major role. Precaution should be taken with patients with long lips and little vermilion, since there is significant risk of lip ptosis after the procedure.

6.3. Nasal flutter

Some people, naturally or under stress (emotional or physical), present wide movements of nasal flutter that enlarge the nostrils. This nasal flutter can be very embarrassing. Generally, people with short and flat nasal bridge with wide nasal ala present more active nasal muscles,

which allow them to voluntarily move the nasal ala. The widened nostrils can take different forms expressing in the face moods such as anger, fear, worry, fatigue, reprobation, or stress.

The nasal flutter is the result of involuntary and repeated contraction of the inferior portion of the *alar nasalis* muscle, also known as *dilator naris posterior*. This muscle originates in the maxilla over the lateral incisive, is medial to the *transverse nasalis* in the nasolabial sulcus, travels through the nasal ala, and inserts in the caudal portion of the alar cartilage and skin of the nostrils. The medial fibers can join the *depressor septi nasi*. Its main action is to move the nasal ala laterally and downward, opening the nostrils and preventing the ala collapse during inspiration.

The side of the columella and the septum turns visible when the nostrils open exaggeratedly. This unaesthetic appearance gets accentuated with the contraction of the *depressor septi nasi*. In people with wide nasal base and ability to move the nasal ala, a stretching effect is seen in nostrils after applying BOTOX® in the *dilator naris posterior*. The injection of 5–10 UI, bilaterally, in the area of greater contraction of the *dilator naris posterior* (over the nasal ala), has diminished the nasal flutter for 3–4 months (Fig. 5). We have not experienced secondary effects after the use of toxin in this area.

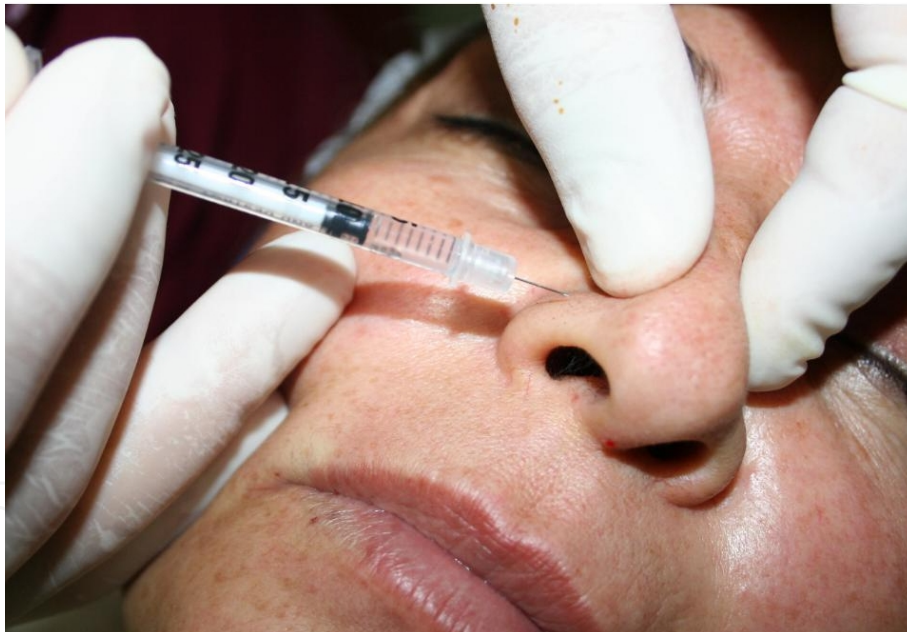

Figure 5. Application in the levator labii superioris alaeque nasi.

6.4. Botox® in nasal dorsum hyperhidrosis

Excessive sweating of the face generally affects areas as forehead, cheeks, scalp, lips, nasal dorsum, and ala. This is less frequent than axillary or hands and feet sweating but is highly detrimental for social and occupational life because it is extremely exposed to sight. Botulinum toxin blocks the liberation of acetylcholine in synapses that regulate the production of eccrine

glands. The incidence of this disorder in the population is not known, but statistically it is more frequent in man and tends to worsen with aging. The permanent sweat impedes the correct application of creams, makeup, and sun block. And sometimes it makes glasses slide over the wet surface producing local irritation.

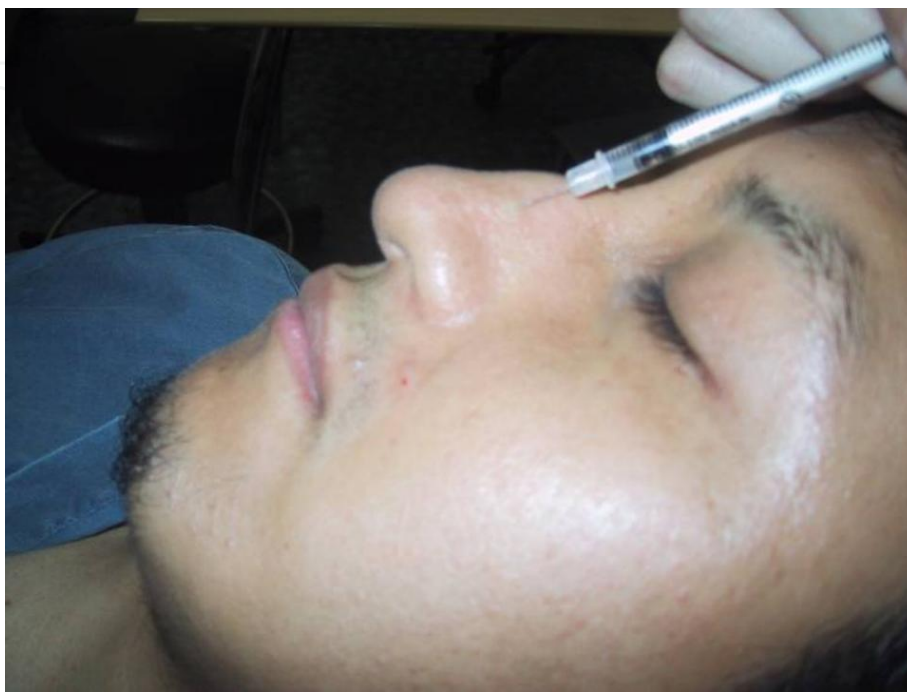

Figure 6. Application in nasal dorsum for hyperhidrosis

In some women, local sweating can appear in the premenopause together with the heat waves that characterize this period. Usually, these symptoms disappear spontaneously. Other stimuli for facial sweating are: caffeine, physical activity, stress, seasoned food, and heat.

A precise diagnosis of the area of sweating can be made through the test of Minor (iodinated alcohol and starch).

To treat this disorder, injections must be intracuticular, producing skin whitening and papules, in order to act over glands and not over muscles. This is a painful procedure, so we recommend the use of anesthetic cream, or if the patient is oversensitive, a local nerve blocking for the nasal area. The dose is 1–2 UI per injection, with 1 cm space between them, until covering the whole area of hyperhidrosis (Figs. 6 and 7). It is important to conserve symmetry while working, in order to avoid asymmetry that can affect the muscles. The patient is called back at day 10 after injection to evaluate the results, and if any area is still sweating, it is corrected. The effects in general last for seven months.

6.5. Botox® in the treatment of multiple eccrine hidrocystoma

Eccrine hidrocystomas is a cystic lesion of sweat gland ducts described by Andrew Ross Robinson in 1983. Incidence is higher in women. Multiple eccrine hidrocystoma are papule-

cystic lesions of elevated surface with a blue coloration that is seen through a transparent dome, easily confused with blackheads. It is common to find them in the facial area surrounding the eyes, forehead, nose, and superior lip. The etiology is a defect in transpiration or insensible perspiration. If ruptured or spontaneously broken, a clear and transparent liquid drains. It is presented in literature as an infrequent disease, but we think that is because of ignorance and misdiagnose with blackhead. This condition worsens with transpiration and environmental humidity, thus enlarging in summer and reducing in winter.

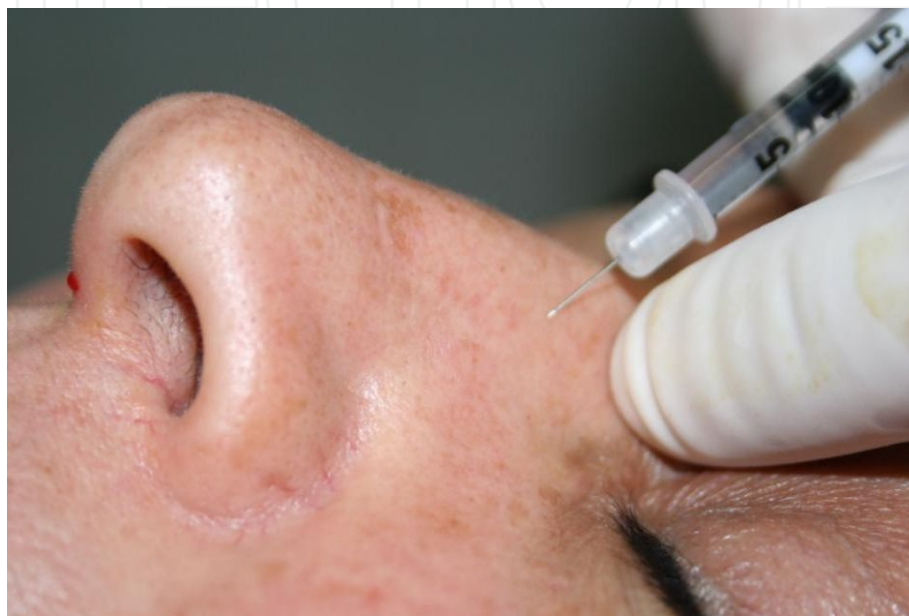

Figure 7. Application in nasal dorsum for hyperhidrosis pseudo-blackhead.

Based on our experience with botulinum toxin type A for the use of focal hyperhidrosis and the amount of bibliography about the effect of Botulinum toxin in parasympathetic fibers, we started using it in this disorder as well [15]. The application is similar to what is described above for hyperhidrosis. Results are excellent with complete reconstitution of the areas treated.

Author details

Diego Schavelzon^{1*}, Guillermo Blugerman¹, Gabriel Wexler² and Lorena Martinez¹

*Address all correspondence to: drschavelzon@centrosbys.com

1 Plastic Surgery Department of Centros B&S, Buenos Aires, Argentina

2 Universidad Nacional del Nordeste, Argentina

Conflict of interest

The authors declare no conflict of interest.

Informed consent was obtained from the patients included in the chapter.

References

- [1] Letourneau, A., and Daniel, R. K. The superficial musculoaponeurotic system of the nose. *Plast. Reconstr. Surg.* 1988 ;82(1):48-57.
- [2] Aiach, G., and Levignac, J. *La Rhinoplastie Esthetique*. Paris: Masson edit. 1986;13-14.
- [3] Griesman, B. Muscles and cartilages of the nose from the standpoint of a typical rhinoplasty. *Arch. Otolaryngol.* 1944: 39:334.
- [4] Zide B.M. Nasal Anatomy: The muscles and tip sensation. *Aesthetic. Plast. Surg.* 1985; 9(3):193-196.
- [5] Carruthers J., and Carruthers A. Practical cosmetic BOTOX techniques. *J. Cutan. Med Surg.* 1999 Dec; 3 Suppl 4:S49-S52.
- [6] Tamura B.M., Odo M.Y., Chang B., *et al.* Treatment of nasal wrinkles with botulinum toxin. *Dermatol Surg.* 2005;31(3):271-275.
- [7] Wright, W.K. Symposium: The supra-tip in rhinoplasty – A dilemma: II. Influence of surrounding structure and prevention. *Laryngoscope.* 1976;86(1):50-52.
- [8] Ham, K.S., Chung, S.C., and Lee, S.H. Complications of oriental augmentation rhinoplasty. *Ann. Acad. Med. Singapore.* 1983;12(2 Suppl):460-462.
- [9] Cachay-Velasquez, H., and Laguinge, R. Aesthetic treatment of the columella. *Ann. Plast. Surg.* 1989;22(5):370-379.
- [10] Cachay-Velasquez, H. Rhinoplasty and facial expression. *Ann. Plast. Surg.* 1992 ;28(5): 427-433.
- [11] Converse, J. M. (Ed.). *Plastic and Reconstructive Surgery*. Philadelphia: Saunders, 1964. pp. 702-703.
- [12] De Souza Pinto, E.B., Da Rocha, R. P., Filho, W. Q., *et al.* Anatomy of the median part of the septum depressor muscle in aesthetic surgery. *Aesthetic Plast. Surg.* 1998;22(2): 111-115.
- [13] Rohrich, Rod J. Importance of the depressor septi nasi muscle in rhinoplasty: Anatomic study and clinical application. *Plast. Reconstruct. Surg.* 2000;105(1):376-383; discussion 384-388.
- [14] Benedetto, Anthony V. Botulinum toxin in clinical medicine. *Clin. Dermatol.* 2003;21(6):465-468.
- [15] Blugerman G, and Schavelzon D. Multiple Eccrine Hidrocystomas: a new therapeutic option with Botulinum Toxin, *Dermatol. Surg.* 2003; 29(5):557-558.