

We are IntechOpen, the world's leading publisher of Open Access books Built by scientists, for scientists

4,800

Open access books available

122,000

International authors and editors

135M

Downloads

Our authors are among the

154

Countries delivered to

TOP 1%

most cited scientists

12.2%

Contributors from top 500 universities



WEB OF SCIENCE™

Selection of our books indexed in the Book Citation Index
in Web of Science™ Core Collection (BKCI)

Interested in publishing with us?
Contact book.department@intechopen.com

Numbers displayed above are based on latest data collected.
For more information visit www.intechopen.com



Principles of Strabismus Surgery for Common Horizontal and Vertical Strabismus Types

Helena Buch Hesgaard and Kenneth W. Wright

Additional information is available at the end of the chapter

<http://dx.doi.org/10.5772/61849>

Abstract

Strabismus can be distressing to our patients, yet often challenging to treat even in experienced hands. The goal of this chapter is to clearly and concisely share with the reader strategies and strabismus surgical techniques in common horizontal and vertical strabismus, that will improve the care of our patients. We describe indications for strabismus surgery, how to plan for successful surgery results and do's and don'ts regarding effective surgical procedures. This includes incision techniques, muscle tightening and weakening procedures and transposition surgery, for rectus as well as oblique muscles. Advice on how to avoid complications of strabismus surgery is also provided. The chapter is based on evidence-based medicine where available and consensus and/or common sense advice is provided where evidence-based medicine is not available. It is the intent of this chapter to be a practical, usable guide helpful for surgeons of diverse experience, from resident ophthalmologists to the expert strabismologist.

Keywords: Strabismus surgery, horizontal strabismus surgery, vertical strabismus surgery, esotropia, exotropia, inferior oblique overaction, superior oblique palsy, Harada-Ito

1. Introduction

Teaching strabismus surgical technique in the most common strabismus types is the goal of this chapter. However, it is almost impossible to do on only one book chapter. Thus, this chapter is simply an appetizer for further reading in well-known textbooks written by experienced great strabismus surgeons who are mentioned here. This chapter aims to describe indications for strabismus surgery, planning for a successful surgery result, and do's and don'ts for effective surgical procedures for horizontal and vertical strabismus, including incision techniques, muscle tightening, weakening procedures, and transposition surgery. In addition,

complications are concerns of the chapter. Our hope is that this book chapter will help surgeons of diverse experience and improve the care of strabismus patients.

2. The actions of the extraocular muscles

The actions of the extraocular muscles and the relative contributions of each muscle to the various ocular positions are important to understand for planning surgery. The muscles act together in order to produce smooth eye movements.

The horizontal recti have only one primary action, while the vertical and obliques each have three actions, which vary depending on the horizontal position of the eye. The relative strengths of these actions depend upon the direction of gaze. In abduction, the vertical muscles have a vertical action only, but in adduction, they become torsors of the eye.

The superior rectus acts as an intortor in extreme adduction, but in abduction, intorsion is lost and exchanged by its elevating primary function. The inferior rectus acts as an extortor when the eye is in adduction; when the eye is abducted, it acts as a pure depressor.

The superior oblique acts as an intortor, depressor, and abductor. It is the principal intortor of the eye produced by the anterior fibers of the tendon. The posterior fibers mediate depression. In adduction, it becomes a pure depressor; in abduction, it is a pure intortor. The inferior oblique acts as extortor, elevator, and abductor. It is the principal extortor of the eye. In extreme adduction, it becomes a pure elevator; in abduction, it is a pure extortor.

These muscles act in concert with cooperation between ipsilateral and contralateral groups of muscles, abiding Sherrington's and Hering's laws. Sherrington's law of reciprocal innervation describes that contraction of a muscle is accompanied by relaxation of its ipsilateral antagonist muscle ensuring smooth movements of the eye. Hering's law of equal innervation regards binocular movements and explains that equal contractions occur in the muscles that are contralateral synergists and ensures that equal movements of the two eyes occur, if both muscles are normal.

3. Surgical indication and planning for success

The indications for strabismus surgery fall into two categories: binocular function and cosmetic appearance with psychosocial impact. The indication and surgical goal should be based on the patients need prior to surgery and direct the surgical plan in order to achieve a successful result. Therefore, prior to surgery, the strabismus surgeon needs to establish the treatment goals by asking "Why are we operating"? Is it to establish binocular fusion, eliminate diplopia, expand the field of binocular vision, correct a compensatory head position, or improve cosmetic appearance?

Signs of binocular fusion potential include intermittent strabismus, acquired strabismus, binocular fusion after neutralizing the deviation with prisms, child <2 years old, equal vision,

and incomitant strabismus with compensatory face turn. Patients with fusion potential generally require large amounts of surgery, larger than standard surgical numbers to avoid undercorrection. However, in patients without binocular fusion, it is better to do less surgery, as a small residual esotropia is more stable and cosmetic acceptable than a consecutive exotropia.

Furthermore, defining the wished function outcome influences the selection of type of surgery. Monocular recession–resection surgery results in incomitance, which is not preferable in a fusing patient, as incomitance can cause diplopia in eccentric positions of gaze. Monocular surgery, however, is the procedure of choice for sensory strabismus to protect the seeing eye.

A specific strabismus diagnosis should be established preoperatively, and the exact etiology of the strabismus should be determined, if impossible, by an MRI of the head and orbit may be indicated. If the cause is unknown after a complete work up, then it is appropriate to operate for the strabismus taking into account the ductions, versions, and presence of incomitance.

Each patient requires an individual surgical approach to the management of their strabismus, but the following information and measurements may be of assistance as a guide for how much muscle surgery is required for concomitant deviations without previous surgery or underlying muscle or neurological pathology, particularly for those beginning strabismus surgery.

4. Horizontal concomitant deviations

Concomitant eso- and exodeviations are deviations with full ductions and the same deviation in all fields of gaze. Many horizontal deviations have an accommodative element.

Different horizontal concomitant strabismus types require different considerations when planning for successful strabismus surgery outcome and are therefore important to diagnose exactly. A table guide in planning strabismus surgery is given in Table 1. The numbers have been derived from Parks, with professor Dr. Kenneth Wright’s personal modifications according to the professors own surgical experience [11, 13]. The measurement recommended is only for concomitant deviations and should be altered based on the surgeon’s personal results.

Binocular surgery		
<i>Esotropia</i>		
	MR OU Recession	LR OU resection^a
15 ^A	3.0 mm	3.5 mm
20 ^A	3.5 mm	4.5 mm
25 ^A	4.0 mm	4.0 mm
30 ^A	4.5 mm	6.0 mm
35 ^A	5.0 mm	6.5 mm

Binocular surgery		
<i>Esotropia</i>		
	MR OU Recession	LR OU resection^a
40 ^A	5.5 mm	7.0 mm
50 ^A	6.0 mm	8.0 mm
<i>Exotropia</i>		
	LR OU recession^b	MR OU resection
15 ^A	4.0 mm	3.0 mm
20 ^A	5.0 mm	4.0 mm
25 ^A	6.0 mm	5.0 mm
30 ^A	7.0 mm	5.5 mm
35 ^A	7.5 mm	6.0 mm
40 ^A	8.0 mm	6.5 mm
50 ^A	9.0 mm	7.0 mm
Monocular surgery		
<i>Esotropia</i>		
	MR recession	LR resection^b
15 ^A	3.0 mm	3.5 mm
20 ^A	3.5 mm	4.0 mm
25 ^A	4.0 mm	5.0 mm
30 ^A	4.5 mm	5.5 mm
35 ^A	5.0 mm	6.0 mm
40 ^A	5.5 mm	6.5 mm
50 ^A	6.0 mm	7.0 mm
<i>Exotropia</i>		
	LR recession^b	MR resection
15 ^A	4.0 mm	3.0 mm
20 ^A	5.0 mm	4.0 mm
25 ^A	6.0 mm	4.5 mm
30 ^A	6.5 mm	5.0 mm
35 ^A	7.0 mm	5.5 mm
40 ^A	7.5 mm	6.0 mm
50 ^A	8.5 mm	6.5 mm

^aWhen a lateral rectus resection is done for residual esotropia after a large medial rectus recession (6 mm or larger), these numbers should be lowered.

^bAvoid large LR recessions if lateral incomitance is present.

^cIf the horizontal angle is greater for near deviation than distance deviation, relatively more should be done to the medial rectus than the lateral rectus and vice versa.

Table 1. Surgical numbers

For angles >50 , diopters perform bilateral surgery to more than 2 horizontal recti. This three muscle surgeries may be planned for the primary operation. The amount of surgery may be judged from the above tables. In adults, adjustable suture technique is recommended, placed on the eye where two muscles are being operated.

Strabismus can be congenital or develop later in life giving rise to different consideration for correct surgical strategy to choose. In the following, we will describe how to handle the most common strabismus types of early and later onset strabismus.

4.1. Infantile esotropia (congenital esotropia)

Infantile esotropia is an esotropia present during the first 6 months of life. This includes several types, with the most common being: small angle neonatal esotropia, accommodative infantile esotropia, Ciancia's syndrome, and congenital esotropia. The latter is described below.

The etiology of congenital esotropia is unknown, but genetic aspects are suspected. Congenital esotropia (CE) is characterized by a large angle constant esotropia of 40 PD or more (Figure 1) and later developing motor dysfunctions, including inferior oblique overaction (IOOA) (60%), dissociated vertical deviation (DVD) (40%), and latent nystagmus (40%). Low hypermetropia is often present in an extent not giving indication for glasses. Amblyopia is present in 50% of patients with CE, however vision screening in childhood may lower this occurrence as described by Høeg et al. [17]. Smooth pursuit asymmetry is also often present as described by Wright [14]. Spontaneous resolution is rare ($<4\%$), as shown by the Congenital Esotropia Observational Study (CEOS) if the angle is stable or increasing [6], which makes congenital esotropia a surgical disease requiring strabismus surgery.

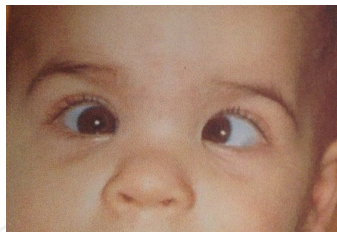

Figure 1. Infantile esotropia

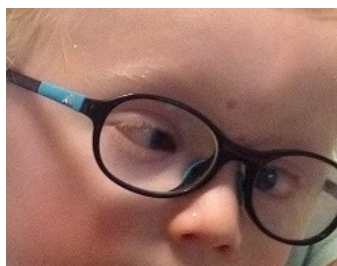

Figure 2. Ciancia's syndrome

4.1.1. *The management and preoperative evaluation*

The management and preoperative evaluation includes examination of the following:

1. Ductions, which often has a mild limitation of abduction (-1), with intact abduction saccades shown by doll head maneuver or vestibular stimulation. If limited abduction and abduction saccadic movement, consider following differential diagnosis listed by decreasing incidence: Ciancia's syndrome with abduction deficiency and compensatory head turn (Figure 2), Duane's syndrome, congenital fibrosis syndrome, congenital VI nerve palsy, and infantile myasthenia gravis.
2. Versions, to evaluate the presence of IOOA and V patterns
3. Amblyopia, which is revealed by strong fixation preference for one eye. Treat amblyopia before surgery by patching the dominant eye 4 h per day and follow-up every 1 to 2 weeks for small kids under 1 year (longer interval for older kids typically in Europe), until the patient holds fixation with the nondominant eye. The patients' cross-fixates usually indicate the absence of amblyopia, unless strong fixation preference is present.
4. Deviation size by prism alternate cover test at near and distance deviations if possible, verified by Krimsky testing. The near deviation measure is most reliable and therefore used as the surgical measure.
5. Cycloplegic refraction using cyclopentolate 1% one or two doses, 5 min apart, followed by refraction 30 min after last dose. If the cycloplegic refraction shows $>+3.00$ sphere, then prescribe the full hypermetropic correction. Repeat the cycloplegia if fluctuating readings is found on retinoscopy. After wearing the full correction constantly for 1 month, evaluate the patient for fixation preference. If an esodeviation of >10 PD persists after prescribing the full hypermetropic correction, surgery is indicated.

The timing of surgery for congenital esotropia is controversial, as no randomized clinical controlled trials have never been conducted due to ethical aspects and low incidence. Therefore, different approaches are used in different continents. In the United States, early surgery (before 2 years of age) is performed routinely when the CEOS [6,7] parameters are present (i.e., angle ≥ 40 PD esotropia, constant, or increasing) supported by Wiesel and Hubel's [10] famous study regarding binocular interaction in the striate cortex of kittens reared with artificial squint that showed loss of binocular cells. In addition, most references recommend that surgery should be performed between 6 months and 1 year of age in order to achieve peripheral fusion and low-grade stereo acuity. Furthermore, one of the authors reported results from very early surgery showing high-grade stereo acuity after surgical correction between 3 and 4 months of age [15].

The surgical procedure of choice depends on age, fusion potential, and visual acuity. Bilateral medial rectus (MR) muscle recession using the near deviation as the target angle is the preferred strategy in infants without amblyopia. Patients with irreversible dense amblyopia should have monocular surgery on the amblyopic eye (recession-tightening procedure) to avoid surgical risk to the sound eye.

The goal of surgery is to align the eyes early to within 8 to 10 PD to stimulate the development of binocular fusion, as described by Dr. Marshall Parks. Larger esotropia will not allow binocular fusion. Therefore, a residual esotropia of 10 PD or larger should be considered for further treatment. The standard surgical chart (Appendix I) numbers are designed to give infants with possible fusion potential a slight immediate overcorrection (5–10 PD exotropia). This is desired as fusional convergence will pull the eyes together to become straight, fusing the small exotropia. However, patients with poor prognosis for binocular fusion (e.g., older patients >2 years old, and patients with dense irreversible amblyopia 20/50 or worse) due to long-standing congenital esotropia should be considered for surgery based on cosmetic indications. In these older patients with poor fusion potential, the surgeon should aim to slightly undercorrect and leave an esotropia of 6 to 8 PD. Using the chart numbers will correctly result in a desired slight undercorrection in older patients with poor fusion potential that predisposes to drift outward to exotropia with time. Therefore, the surgical chart numbers can be used for all patients as they self-adjust for age and fusion potential. In general, patients older than 2 years with uncorrected infantile esotropia have a poorer prognosis for binocular fusion. Even older patients, however, will occasionally show an outcome of good binocular function and some degree of stereo acuity; this could be caused by an inaccurate anamnesis.

Residual esotropia of at least 10 PD first repeat the cycloplegic refraction and prescribe the full hypermetropic correction if 1.5 sphere or more to correct ET to within 10 PD. If there persists a residual ET of 15 PD or more after prescribing glasses, then consider further surgery. If the primary surgery was bilateral MR recession of 5 mm or less, both medial rectus muscles can be further recessed. However, if the primary bilateral MR recessions were >5 mm, both lateral recti would be resect with reduced standard numbers of 1.5 mm to avoid consecutive exotropia, which is a common occurrence after LR resections for residual esotropia.

Consecutive exotropia of ≥ 15 PD that does not improve over 2–3 months may be surgically corrected. If there is full ductions, slipped medial rectus muscle is ruled out and bilateral medial rectus recession should be performed. If there is limited adduction, slipped muscle or stretch scar of the medial rectus muscles is suspected and should be addressed by exploring the medial muscle and advancing the muscle if it is found to be slipped using nonabsorbable suture to avoid re-slippage [4].

Inferior oblique overaction (IOOA) is often bilateral and associated with IE, developing after 1.5 years of age. If significant IOOA ($\geq +2$) is present, a weakening inferior-graded anteriorization of the IO is indicated concurrent with the horizontal surgery, performed as a one stage surgery without modifying the amount of horizontal surgery. This IO weakening procedure reduces the V pattern, eliminates the IOOA, and reduces the dissociated vertical deviation (DVD), which will be described later in this chapter.

Prognosis for motor alignment and binocularity is good for surgical cases in hands of trained surgeons. Alignment to within 10 PD of orthotropia can be achieved in 80%. If this is achieved before 2 years of age, about 70% achieve some degree of peripheral fusion and gross stereopsis (monofixation syndrome). Very early surgery (3–4 months of age) increases the chance of binocular fusion and high-grade stereo acuity. Late surgery (after 2 years of age) minimizes the chance of obtaining binocular fusion.

4.2. Acquired esotropia (accommodative esotropia)

Acquired esotropia is a subacute emergency that requires urgent consult for two reasons: (1) fusion potential diminishes in proportion to the duration of ET while early intervention is important to restore high-grade binocular fusion. Prompt dispensing of hypermetropic spectacle correction is therefore important to correct the esotropia totally or partially and reduce the occurrence of amblyopia. (2) Acquired esotropia can be the presenting sign of intracranial (brain tumor, Arnold–Chiari malformation) or neurological disease (myasthenia gravis or chronic progressive external ophthalmoplegia) causing a sixth nerve paresis, which can be concomitant in the beginning as described by Buch Hesgaard and Vinding [1].

The most common types of acquired esotropia are the accommodative, the nonaccommodative, the cyclic, and the sensory esotropia. These often have an intermittent beginning. More seldom acute acquired concomitant esotropia develops [1]. Only the most frequent type, i.e., accommodative esotropia, will be described. Accommodative esotropia can have an infantile onset at 2 months to 1 year of age but typically develop between 1 and 3 years of age. It is characterized by initially intermittent with progression to constant moderate to large angle of deviation (20–50 PD) associated with hypermetropia (+2.00 to +6.00 sphere). The deviation is often initially intermittent and becomes constant.

The etiology is related to hypermetropia that necessitates increased accommodation for the child to achieve a clear image. This overaccommodation results in overconvergence and esotropia, depending on the AC/A ratio and divergence amplitudes.

The goal is to establish straight eyes within 8 to 10 PD of orthotropia to stimulate binocular fusion. This can be achieved in some patients with optical correction alone, and surgery is not indicated then. The patients that do not get straight eyes wearing full hypermetropic correction, as the child in Figure 3, needs urgent surgery. Therefore, these patients should be aggressively treated with early optical correction and surgery if indicated to avoid or treat amblyopia and stimulate binocular function in the small kids (2 months to 2 years), restore binocularity in older children (2 years to 6 years), and eliminate diplopia and regain stereo acuity in the children over 6 years of age. The younger the children the more vulnerable is the binocularity, and visibility could be lost if treatment is delayed. These authors agree with the late Dr. Marshall Parks that recent onset accommodative esotropia is an ophthalmic emergency, and the patient should be seen at an urgent appointment.

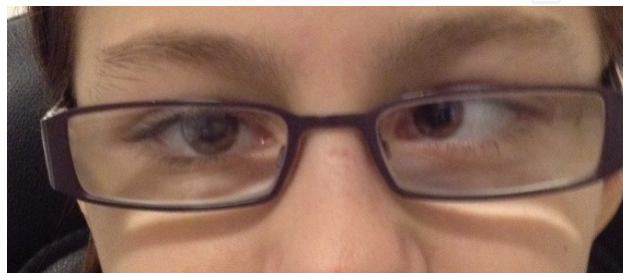


Figure 3. Partially accommodative esotropia

4.2.1. The management and preoperative evaluation

The management and preoperative evaluation includes the same examination procedures as patients with infantile esotropia, including the examination of ductions, versions, and evaluation for and treatment of amblyopia after full hypermetropic correcting spectacles is prescribed, following the same method as described previously. Then if residual esotropia persists (>10 PD), surgery is indicated. However, important additional preoperative orthoptic considerations and examinations are necessary:

1. Urgent performance of cycloplegic refraction and prescription of the full hypermetropic correction, even at babies only 2 months of age, is necessary in order to avoid development of amblyopia and loss of binocularity that is lost proportionally with the time after onset. There are 3 common responses to prescribing full hypermetropic spectacles for acquired accommodative esotropia: (a) correction results in orthotropia (<8 PD) for distance and near deviations. Single vision glasses are to be continued, and surgery is not indicated. This is termed accommodative esotropia. (b) Correction results in correction for distance, but there is a residual esotropia >10 PD for near deviation. Measure the AC/A ratio, and if the AC/A ratio is high in accommodative esotropia, prescribe bifocal spectacles and surgery can be indicated if the angle is only partially corrected with bifocal spectacles as described below. (c) Correction results in a residual esotropia >10 PD for both distance and near deviations, i.e., partially accommodative esotropia, and requires single vision glasses to be continued and surgery is indicated as described below.
2. Measure the AC/A ratio. It is vital to know the AC/A ratio in those with convergence excess esotropia and those with distance exotropia in making the definitive diagnosis and management plan. The gradient method of measuring AC/A ratio is the most accurate method to use, measuring the angle at near deviation with full hypermetropic correction, without (-L) and with (+L) +3 diopter (D) sphere lens: $-L - (+L) / 3D$. Specifically for esodeviations, if the AC/A ratio is high ($\geq 5:1$) in a child with accommodative esotropia, bifocals should be prescribed (not in infantile accommodative esotropia because of the age). This is the case if the full hypermetropic correction corrects the distance deviation resulting in fusion (i.e., ET <10 PD), but a residual esotropia persists at near deviation that cannot be fused (i.e., ET 10 PD), then prescribe a bifocal add. Prescribe the least amount of near deviation add to obtain fusion at near deviation, i.e., +2.50 to +3 sphere add – a flat top bifocal that splits the pupil.

Lens gradient formula:

- *Dev w lens* = deviation in prism diopters measured with the inducing lenses
- *Dev org* = original deviation in prism diopters without the lens
- *Lens power* (denominator) = inducing lens power in diopters

$$AC/A = \frac{Dev\ org. - Dev\ w\ lens}{Lens\ power}$$

For AC/A formulas, exodeviations are minus and esodeviations are plus:

Normal AC/A ratio = 4 to 5 PD/D

Example: The patient, in Figure 4, has a deviation of ET 20 with full hypermetropic correction but without extra lenses. When +3.00 lenses are placed over both eyes, as illustrated in Figure 5, the patient does not have to accommodate 3 diopter-inducing divergence so the deviation now measures ET 5. The AC/A ratio is calculated below and is 5 PD/D:

$$\begin{aligned} \text{AC/A} &= +20 \text{ PD} - (+5 \text{ PD}) / +3\text{D} \\ &= +20 \text{ PD} - 5 / +3\text{D} \\ &= +15 \text{ PD} / +3\text{D} = 5 \text{ PD/D} \end{aligned}$$

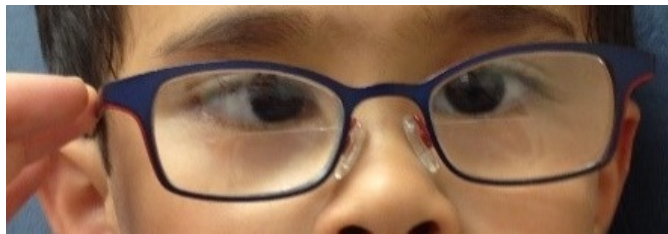


Figure 4. ET without extra lenses.

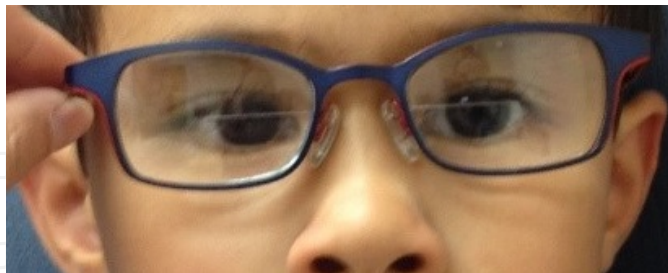

Figure 5. Less ET with +3.00 lenses placed over the eyes.

3. Test for binocularity and stereo acuity using Bagolini-striated test, Titmus, Lang, or TNO test with correcting prism bar, depending on the age of the child and level of stereo acuity present. The surgeon should aim to slightly overcorrect those patients with binocular potential but undercorrect those patients with no binocular function, e.g., long-standing acquired esotropia, which is often seen in Europe. Since accommodative esotropia is acquired, and the eyes are aligned during the early period of visual development, most patients have good binocular potential at the onset of the esotropia.

The goal is to achieve orthotropia within 10 PD of esotropia to establish high-grade stereo acuity. The surgical goal for *partially accommodative esotropia* is not to operate patients out of glasses but to achieve alignment and fusion with full hypermetropic correction. Patients having cycloplegic refraction of +2.5 sphere or more will require their hypermetropic spectacles after surgery to maintain a stable angle. Surgery is indicated if residual esotropia of >10 PD persists with full hypermetropic correction worn for 2 months. Surgery is urgent as the longer the esotropia persists, the worse the prognosis for establishing binocular fusion. For infants, distance measurements are difficult to obtain; try to get this measurement but base the surgery on the near deviation. Therefore, surgery for *infantile partially accommodative esotropia* requires bilateral medial rectus recessions augmented surgery (Wright and Bruce-Lyle 1998) using the augmented formula, i.e., for a target angle between the deviation with and without hypermetropic correction. Average the near deviation with correction and the near deviation without correction or bilateral MR recessions 5.5 mm (see Appendix I on surgical numbers). Bilateral medial rectus recessions are also the treatment of choice for partially accommodative esotropia in older children. It is recommended to use the “augmented surgery formula” developed by Professor Wright to achieve alignment. This formula have improved outcome by increasing the alignment success rate from 70% to 90% by increasing the amount of surgery [16].

Surgery is indicated in *high AC/A ratio accommodative esotropia* if there is a significant esotropia in the distance that disrupts fusion, even if a bifocal add results in fusion at near deviation. A relatively small distance deviation and large near measurement is more difficult to manage as the near distance discrepancy tends to persists postoperatively. It is recommended to perform bilateral medial recessions using a target angle based on the augmented formula with slight reduction in the numbers to prevent consecutive exotropia at distance. The patients should be informed that bifocal spectacles may be required after surgery.

There are 3 methods for determining the target angle for partially accommodative ET. These are described in the following examples:

Nsc ET 60 Ncc ET 40
Dsc ET 50 Dcc ET 30

1. Standard surgery formula uses the residual distance deviation with full hypermetropic correction as the target angle. It gives the highest rate of undercorrection (25%–30%), for example, Dcc ET 30 PD; target angle: 30 PD; surgery: BMR recessions 4.50 mm.
2. Augmented surgery formula uses the target angle, which is the average between near deviation without correction (largest) and distance deviation with correction (smallest). This improves successful results to >90% [16], for example, average Nsc ET 60 PD and Dcc ET 30 PD; target angle: 45 PD; surgery: BMR recessions 5.75 mm.
3. Prism adaptation determines the target angle by placing a base out press-on prism for the full deviation on the patient’s glasses. Then have the patient wear the glasses for 1 week. The deviation is then remeasured, and if it increases, additional base out prism is applied. This process is repeated until the deviation is stabilized. Prescribe 30 PD base out press-

on prisms over full hypermetropic correction and return in 1 week. At follow-up visit, there is no change in the deviation, after placing the 30 PD base put prism; target angle: 30 PD; surgery: BMR recessions 4.50 mm.

4.2.2. Postoperative management of partially accommodative esotropia

A residual esotropia larger than 10 PD will not allow binocular fusion and should be considered for further treatment as described above, by repeating cycloplegic refraction, prescribe full hypermetropic correction, and if there persists a residual esotropia at distance and near deviations of >10 PD, then consider further surgery if the patient has fusion potential.

Patients with preoperative high AC/A ratio will often have a residual esotropia at near deviation after surgery. To establish fusion at near deviation, bifocal add (+2.00 to +3.00 sphere) is required if the residual esotropia at near deviation is >10 PD, but the eyes are aligned at distance.

On the other hand, if a small consecutive exotropia of >10 PD results from surgery, try reducing the hypermetropic correction but not more than +2D as this leads to alignment instability. If the exotropic angle persists more than 3 months, reoperation should be considered. If the exotropia is large and associated with even mild adduction deficit, stretched scar or slipped muscle should be suspected, and the medial muscle should be explored and advanced if there is an insertion dehiscence. Surgery plan is the same as for consecutive exotropia as described above in congenital esotropia.

4.3. Exotropia (intermittent exotropia)

The normal eye position of rest is divergent due to the divergent positioning of the orbits. Therefore, small exophorias <10 PD are considered normal and the innate fusional convergence is strong (25 PD), facilitating fusion of small exodeviations.

Intermittent exotropia is a large exophoria (usually between 20 and 40 PD) that is difficult to fuse and intermittently breaks down and manifests especially when fatigued, daydreaming, or takes sedatives or drinking alcohol. Patients with intermittent exotropia have perfect stereoacuity when aligned (phoria phase), but no stereoacuity when tropic because the patient suppress the image from the deviated eye (tropia phase). Rarely patients will see double or have ARC when tropic. This is the case in patients with late onset exotropia during late childhood or adulthood. Patients with intermittent exotropia do not get strabismic amblyopia because they have intermittent binocular fusion with high-grade stereoacuity that provides binocular visual stimulation. Patients with intermittent exotropia can have anisometropic amblyopia with the same incidence as the general population. Approximately 80% of intermittent exotropia patients will show progressive loss of fusion control and increase in the exotropia with time.

Figures 6 and 7 show a child with intermittent exotropia and straight eyes when the deviation is fused (phoria phase), and moments later, where the patient lost concentration, fusion broke and exodeviation became manifest (tropia phase).

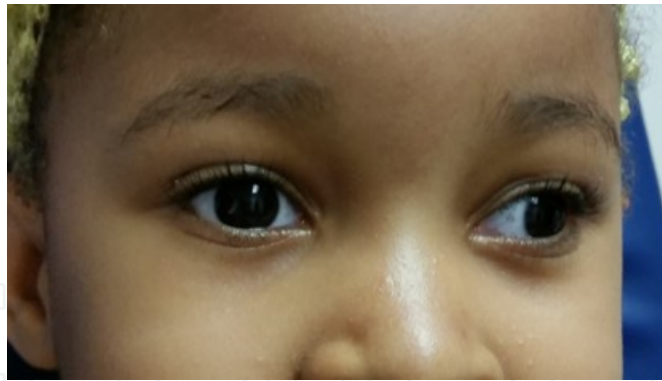

Figure 6. Intermittent exotropia, tropia phase.

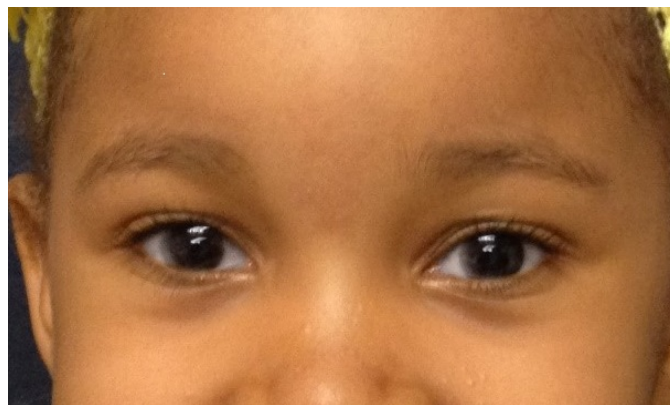

Figure 7. Intermittent exotropia, phoria phase.

4.3.1. The management and preoperative evaluation

For the most part, the treatment of intermittent exotropia is surgical. The indication for surgery is poor fusion control. Large deviations over 20 PD will eventually need surgery as they are difficult to fuse and will increase over time.

Small to moderate exodeviations (<20 PD) are usually well controlled and do not need treatment but can temporally be treated nonsurgically, but this is rarely effective in the long term. Nonsurgical options is not effective except for convergence exercises for convergence insufficiency, which is the preferred management in that disorder. Convergence exercises consist of pencil push-ups, which improve fusional convergence for near deviation, useful for convergence insufficiency, but will not reduce the distance exodeviation. Other nonsurgical treatment options is over minus glasses and monocular occlusion. Over minus glasses reduce the exotropia by stimulating accommodative convergence, which is not well tolerated because it requires the patient to constantly overaccommodate. It can be used for small angle exotropia (<15 PD) associated with concurrent myopia. Increase myopic correction by -2.5 sphere over existing correction. Monocular occlusion by patching the dominant eye for 2 to 4 h a day has been described, but recent prospective study shows no significant effect [8].

A surgical indication is poor fusion control. If the deviation is difficult to control and becomes manifest more than 50% of waking hours, then surgery is indicated. In general, it is preferable to operate after 4 years of age. This is because a small consecutive esotropia can occur after surgery, and as young children have the ability to suppress and develop amblyopia, they can lose stereoacuity after surgery. Older children with deviations greater than 20 PD are difficult to fuse and can cause eye strain, so these patients should be considered for surgery.

4.3.2. *Surgical plan*

The procedure of choice for intermittent exotropia is bilateral rectus recessions. Monocular recess/resect procedures induce incomitance and cause diplopia in side gaze. A small consecutive esotropia (4–8 PD) immediately after surgery is desirable as the late recurrence of the exotropia is common. This consecutive exotropia will cause diplopia but usually resolve in a few days. The standard surgical number chart (Appendix I) have this small overcorrection built in.

The pattern of the deviation is important for determining the surgical plan. Exopatterns are classified based on difference of deviation, distance deviation versus near deviation: (1) basic, (2) convergence insufficiency, and (3) divergence excess divided into pseudo and true divergence excess.

1. The basic type of intermittent exotropia is responsible for 60% and have a similar deviation distance and near deviations, e.g., Dsc X (T) 30 and Nsc X(T): 35; target angle = XT 35 bilateral LR recessions.
2. Convergence insufficiency intermittent exotropia type includes patients with weak convergence with a greater esotropia for near deviation. If the eyes are straight for distance, it is best to avoid surgery and treat with convergence exercises. Convergence insufficiency is the one strabismus that can be helped by exercises, e.g., Dsc Ortho. Nsc X(T) 30; plan: convergence exercises—no surgery.
3. Note: If there is a significant X(T) >15 PD in the distance, then consider bilateral lateral rectus recessions for 5 PD more than the distance angle. Patients will require convergence exercises after surgery for an X(T) at near deviation.
4. Divergence excess X(T) intermittent is when the exotropia is larger for distance than near, by at least 10 PD, e.g., N X(T) 15. D X(T) 30. There are 2 types of divergence excess:
 - a. Pseudo (90%) – tenacious fusional convergence
 - b. True (10%) – high AC/A ratio

Tenacious fusional convergence is near convergence that persists for several minutes after monocular occlusion. Patients with pseudo divergence pattern intermittent exotropia have strong tenacious fusional convergence that “falsely” diminishes the near deviation. Patching one eye for 45 min breaks tenacious fusional convergence. If the near exodeviation increases to be similar to the distance angle, e.g., 30 PD X(T) after the patch test, this indicates pseudo divergence excess, and bilateral LR recessions with a target angle of 30 PD is indicated. If the

near exodeviation does not increase with the patch test, this indicates true divergence excess and is associated with a high AC/A ratio. Bilateral LR recessions with target angle somewhere between distance and near deviations; see example below:

Dsc X(T) 30, Nsc X(T) 15 → patch test → Nsc X(T) 15. Target angle = 20–25 PD.

Patients with true divergence excess have a high AC/A ratio, and there is a high incidence of persistent esotropia and diplopia at near after surgery. Therefore, bifocals and more than one surgery are likely, and patients should be told this preoperatively.

4.3.3. Postoperative management

The immediate postoperative goal of surgery for intermittent exotropia is to achieve a small consecutive esodeviation of about 5 PD esotropia; in the long term, it is common for exotropia to recur. Larger consecutive esodeviations will often require further surgery. Children under 4 years of age with a small consecutive esotropia can rapidly develop amblyopia. That is why Dr. Wright suggests to postpone surgery to after 4 years of age if possible. However, if absolutely indicated because of loss of stereoacuity, part-time (2–3 h a day) alternate eye occlusion therapy may prevent amblyopia until the esotropia resolves. In older patients, the initial consecutive esotropia causes diplopia, and therefore it is important to inform the patients that diplopia may be present for some weeks to achieve a better long-term result. Hardesty et al. [2] has suggested prescribing prism glasses in the early postoperative period to neutralize the esodeviation and leave a small esophoria to stimulate divergence. For a persistent esotropia, after a week in a patient of any age, consider prescribing base out prism glasses to eliminate the diplopia and preserve binocular fusion. Give just enough prism to allow fusion while leaving a small esophoria to build divergence. If after 4 to 6 weeks the esotropia persists, then additional strabismus surgery should be considered. Either advance the lateral rectus muscle or recess the medial rectus muscles. Consider the possibility of a slipped lateral rectus muscle if abduction is limited and the esotropia is greater for distance. If the lateral has slipped, resect the stretched scar and replace at the intended recession point.

5. Vertical concomitant deviations

Vertical deviations can be caused in 3 different ways, which will be described as follows: (1) overaction of the rectus muscles, i.e., superior rectus muscles, ipsilateral dissociated vertical deviations (DVD); (2) dysfunction of the horizontal rectus muscles, i.e., pattern deviations (A and V patterns); and (3) overaction of the superior and inferior oblique muscles, i.e., primary or secondary to ipsilateral IV nerve palsy or contralateral superior rectus palsy.

All the preoperative examinations and considerations previously mentioned should be performed, but additionally two important orthoptic tests are necessary to find the correct diagnosis and plan the surgery for successful results. These tests that assist the surgeon in the diagnosis of vertical muscle weakness in patients with vertical strabismus are (1) the three-step test and (2) the Bielchowsky head tilt test.

1. Dr. Parks described the classical three-step test for diagnosing a cyclovertical muscle palsy. It helps to differentiate SOP from contralateral superior rectus palsy and to detect bilateral SOP and includes the following:

Step 1.cover test identifies which eye is hypertropic. The elevators of the low eye (IO or SR) or the depressors of the high eye (SO or IR) are affected.

Step 2.Side gaze to the right and left changes the degree of height. If the height increases when the eyes move away from the high eye, the possible weak muscle is either SO of the adducted eye or the contralateral SR (elevates the eye in abduction). Conversely, if the height increases when the eye move in the direction of the higher eye, it suggests either weak IR of the abducted eye (depresses the eye in abduction) or weak IO of the contralateral adducted eye.

Step 3.determine the hypertropia in up- and downgaze by cover test. This identifies which of the contralateral muscles is responsible for the vertical deviation. A modification to make this easier is "Wright's rule" described by Dr. Wright, which is a 2-step process: (1) Do the head tilt test first. If the hypertropia increases on head tilt to the side of the hypertropia, this indicates an oblique muscle palsy, and if the hypertropia increases opposite to the hypertropia, it is a rectus muscle palsy. (2) Test horizontal gaze to see where the hypertropia is greatest and match to the field of action of the cyclovertical muscle in question from step 1.

2. The Bielchowsky head tilt test helps to further identify a superior oblique weakness. When the head is tilted to the right, the right eye intorts by action of the intorters (SO and SR) of the eye, and their vertical pulls cancel each other if both are healthy. However, if the SO is weak, the moderately unopposed SR causes a hypertropia to develop in the intorting eye, as illustrated in Figure 8.

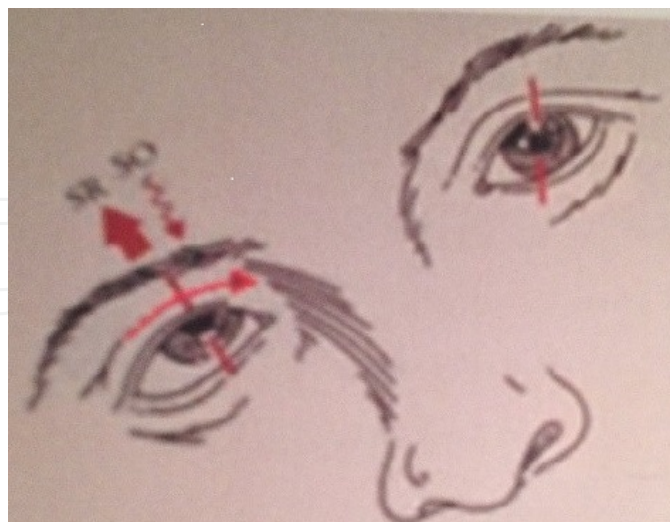


Figure 8. Explanation of the Bielchowsky head tilt test.

When the correct diagnosis and the weak muscle have been found, a plan for successful strabismus surgery outcome can be made by using the following five-step guideline:

1. Choose the right muscle to work on. In concomitant deviations, the balance between the vertical rectus muscles (which elevate and depress the eye in abduction) and the obliques (which elevate and depress in adduction) must be maintained. Therefore, always work on ipsilateral antagonists and contralateral synergists.
2. Choose the right amount of muscle surgery. However, it is more difficult to provide guidance tables for vertical deviations as they are less likely than horizontal deviations to be concomitant. A rule of thumb for vertical surgery is 3 prism diopters of vertical correction for every millimeter of recession of height in the primary position.
3. Aim to correct a vertical deviation in primary position and downgaze principally; upgaze is much less important.
4. Inferior rectus recessions can result in late overcorrection [3]. Therefore, great care must be taken with this muscle and aim to be conservative, and do not recess the inferior rectus muscle more than 5 mm to 6 mm. Superior rectus recessions for dissociated vertical deviation (DVD) must be large, on the other hand.
5. Long-standing vertical deviations, especially due to thyroid eye disease and congenital IV nerve palsies, should be slightly undercorrected due to large vertical fusional reserves.

5.1. Dissociated vertical deviation

Dissociated vertical deviation (DVD) occurs in patients with infantile esotropia and can occur with any disorder that disrupts normal binocular visual development. DVD is commonly associated with CE in Europe, where late surgery is the timing of choice. However, the incidence of surgery demanding severe DVD has dropped in the United States, probably due to early surgery with better sensory outcome. DVD is typically latent. However, when one eye is occluded (Figure 9), or when the patient is fatigued or daydreaming, it manifests, having three components: elevation, abduction, and extorsion. The vertical component is predominant. DVD is characterized by slow drift of one eye up and out with extorsion. It is usually bilateral and asymmetric and can be distinguished from a true hypertropia by the lack of a corresponding hypotropia in the contralateral eye, when the hypertropic eye returns to primary position. The indication for surgery for DVD is primarily based on the patients psychosocial requirements.

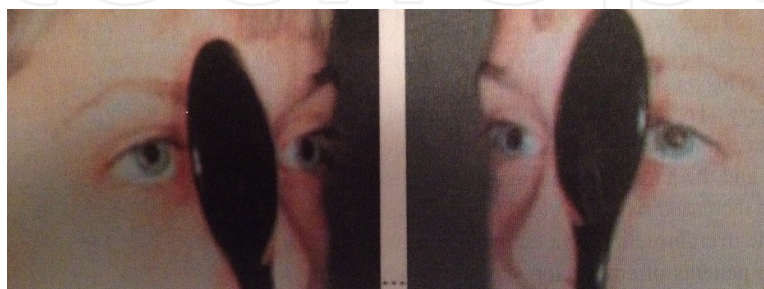


Figure 9. Bilateral DVD with a right hypertropia with the right eye covered and left hypertropia with the left eye covered.

Surgery is indicated if the deviation is larger than 10 PD, increases in frequency, and becomes obvious or symptomatic. Surgery for DVD is ipsilateral large superior rectus recession often between 5 mm to a maximum of 9 mm (fixed suture technique) as suggested by professor Dr. K. Wright.

Most cases require bilateral surgery. If the DVD is asymmetric, perform asymmetric superior rectus recessions. Unilateral surgery is indicated in patients with amblyopia >2 lines, which will not fixate with the amblyopic eye, where ipsilateral superior rectus recession is indicated. If DVD and inferior oblique overaction coexist, an inferior oblique anteriorization procedure is indicated and sufficient in most cases. Only in severe cases combined surgery of inferior oblique anteriorization and superior rectus recession is necessary. In this case, the superior rectus recession should be minimized to avoid limitation of up gaze.

5.2. Pattern (A and V) deviations

These are patterns of strabismus in which the horizontal deviation alters on upgaze and downgaze so that the pattern resembles the letter A or V and is considered significant if the horizontal angle varies by more than 10 PD (A pattern) or 15 PD (V pattern) diopters between up- and downgaze. An example of a V pattern esotropia is shown in Figure 10. The underlying cause may be as follows: (1) horizontal muscle dysfunction caused by abnormal insertion or action of the medial/lateral recti (spontaneously or secondary to surgery); (2) vertical rectus dysfunction (tight superior rectus/inferior rectus muscle weakness for A pattern and vice versa for V pattern), or (3) oblique muscles dysfunction (inferior oblique under action/superior oblique overaction for A patterns and vice versa for V patterns).

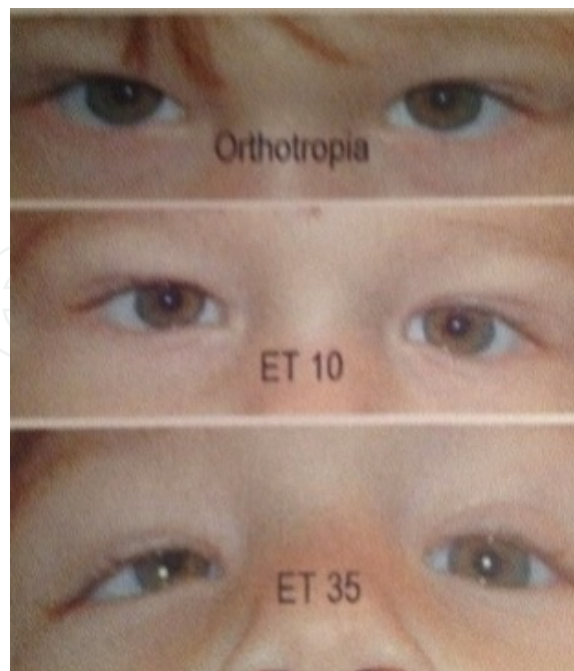


Figure 10. An example of a V pattern esotropia with arrow pattern.

5.3. Treatment of A and V patterns

If the pattern is small, not affecting fusion and not causing a compensatory head position, then it can be observed. If the pattern is significant and symptom producing, the treatment of choice is either by inducing an abnormal head posture to maintain binocular vision or by interfering with maintenance of binocular function binocular surgery. The surgical procedure depends on underlying muscle dysfunction. If the pattern is due to horizontal rectus muscle dysfunction without oblique and vertical rectus muscle dysfunction, surgery should be carried out to the horizontal rectus muscles and should be combined with recession \pm resection of these muscles to treat any associated eso- or exotropia in primary position. In bilateral surgery, the surgeon needs to elevate or depress the positions of medial or lateral rectus insertions. This is done by symmetrical full tendon vertical transposition surgery to contralateral MRs or LRs. The surgeon needs to move MRs toward the apex of the pattern (upward in A pattern and downward for V pattern, i.e., in the direction of the greatest esodeviation) or LRs away from the apex of the pattern (downward for A pattern and upward for V pattern, in the direction of the greatest exodeviation), as illustrated in Figure 11. The pattern breaking effect can be increased by recessing the upper or lower margin of the appropriate transposed horizontal muscle insertion 2 mm more in the direction where more weakening is required.

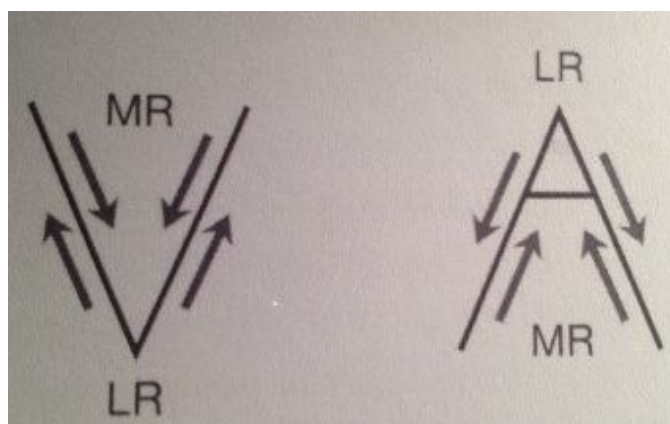


Figure 11. Move MRs toward the apex of the pattern or LR away from the apex of the pattern.

When unilateral recess/resect surgery is indicated, i.e., cases with unilateral amblyopia, or strabismus with equal near and distance angles, the horizontal rectus muscles are transposed elevating RL and depressing MR in V pattern and vice versa for A pattern. To increase the effect, the rectus muscles can be resutured to the globe with the upper and lower parts of the insertion placed at different distances from the limbus, e.g., place the lower margin of the medial rectus in a preferentially weaker position than upper margin, and vice versa for lateral rectus muscles in V patterns. Some authors [5] even prefer this repositioning to elevating or depressing the insertions as it reduces the risk of inducing unwanted torsion effects.

Each horizontal muscle is resected or recessed as specified by the magnitude of the horizontal deviation. Half width elevation or depression collapses pattern by 10 to 15 PD diopters. Full-width elevation or depression collapses pattern by up to 25 diopters. The latter is used for

patterns exceeding 25 PD. Expect relatively more effect for the surgical amounts for larger pattern deviations.

If oblique overaction is present, appropriate oblique muscle surgery should be performed.

5.4. Inferior oblique overaction and superior oblique palsy

Inferior oblique overaction (IOOA) is a common form of strabismus. It can be primary (idiopathic) or secondary caused by a superior oblique palsy (SOP). The clinician can give the right diagnose by performing the head tilt test. With primary IOOA, head tilt test is negative, and with SOP, head tilt is positive.

Figure 12 shows a +3 left IOOA with left upshoot on right gaze. Right eye is fixing, allowing the left adducting eye to elevate. Bilateral IOOA is associated with a V pattern because the inferior oblique muscles are abductors in the field of action in upgaze.

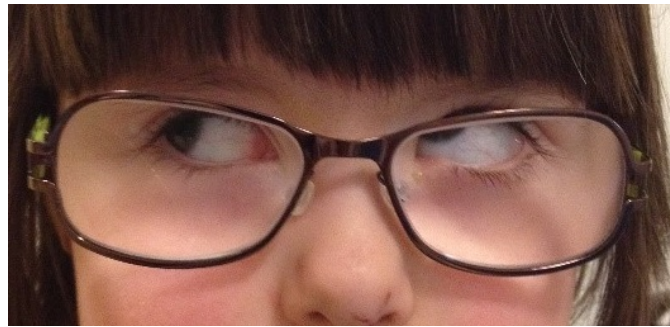


Figure 12. IOOA left eye.

5.4.1. Primary IOOA

Primary IOOA is usually bilateral and asymmetrical. It is often associated with horizontal strabismus, typically infantile esotropia (60%), but it can occur isolated. Signs of IOOA are upshoot in adduction, V pattern, and extorsion on fundus examination. The V pattern associated with primary IOOA is a Y with little or no change in the horizontal deviation from primary to downgaze. This patient had an upgaze preference and adopted chin down posturing to obtain binocular fusion (Figure 13).

5.4.2. Secondary IOOA (superior oblique palsy)

Secondary IOOA is most commonly due to a unilateral congenital SOP and less commonly bilateral acquired SOP. Differences and characteristics of unilateral and bilateral SOP are summarized in Table 2. Since the SO muscle is a depressor, a weak SO muscle can cause an ipsilateral IOOP and hypertropia in primary. A bilateral SOP will have cancelling hypertropia, so typically there is a small or no hypertropia in primary position. The key sign of SOP is hypertropia with the hypertropia increasing on tilt to the same side as the hypertropia and hypertropia increasing on horizontal gaze opposite to the hypertropia, as shown on photos

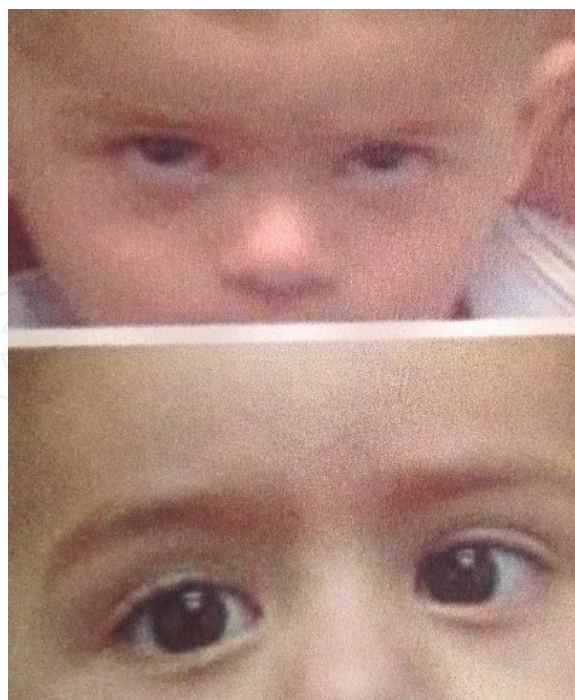


Figure 13. V pattern esotropia with compensatory chin down head posture.

below. In addition, patients with unilateral SOP will adopt a compensatory head tilt opposite to the side of the SOP to facilitate binocular fusion (R-SOP compensates with tilt left). In primary IOOA, the head tilt is negative, but the extorsion can be seen on fundus exam. Patients with congenital SOP do not have subjective extorsion. However, patients with acquired SOP will experience torsional diplopia that can be measured on Maddox rod testing.

Clinical sign	Unilateral	Bilateral
Hyper in primary	Large >5 PD	Small <5 PD
“V” pattern	Small <10 PD	Large >10 PD
Maddox rod	Extorsion <10°	Extorsion >10°
Head tilt test	Hyper increases on tilt to the side of the palsy	RH tilt R and LH tilt L

Table 2. Unilateral versus bilateral superior oblique paresis

5.4.3. Congenital SO palsy

Congenital SO palsy is usually unilateral with a relatively large hypertropia (10–30 PD), which is intermittently binocular fused so the eyes appear well aligned, facilitated by a compensatory head tilt and face turn away from the hypertropia. Therefore, facial asymmetry is common with the smaller side opposite to the SO palsy, as shown in Figure 14.

Patients with congenital SO palsy usually have excellent stereoacuity and have exaggerated vertical fusion amplitudes, and they can fuse large hyperdeviations up to 25 to 30 PD, whereas




Figure 14. Congenital SOP, compensatory head tilt, and face turn away from the hypertropia.

normal vertical fusion amplitudes are at 2–3 PD. The hypertropia will manifest when the patient is fatigued, much like patients with intermittent exotropia. When tropic, patients usually suppress diplopia, but some will note double vision. There is usually a significant IOOA with minimal under action of the SO. The etiology of congenital SO palsy is unknown, but some cases have been associated with a lax or absent SO tendon (rare).

Patients typically have control over the deviation in younger age, but as fusional control weakens over time, they may present late even as senior adults with intermittent vertical strabismus and manifest the hyperdeviation when they are fatigued. Typically, patients with decompensated congenital SO palsy present with large HT in primary with the HT increasing on head tilt to the affected side and in gaze to the contralateral side (Figures 15–19). Patients with intermittent vertical strabismus, facial asymmetry, and long-standing head tilt, which can be documented on early childhood family photos, have congenital SOP until proven otherwise. Unfortunately, patients with congenital SO palsy are misdiagnosed and receive multiple consultations, CT, MRI scans, and even surgery for the torticollis. Avoid this by knowing the 7 key findings of congenital SOP, which are as follows: (1) large vertical fusion amplitudes, (2) ipsilateral IO overaction, (3) positive head tilt (>hyper on tilt to the hyper), (4) torticollis (compensatory head tilt opposite to SOP), (5) minimal or no vertical diplopia before it decompensates, (6) no torsion on Maddox rod, and (7) facial asymmetry.

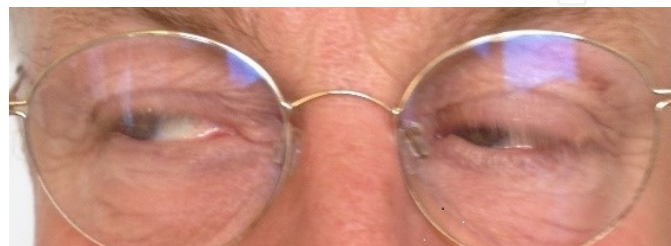

Figure 15. Congenital SO palsy with large RHT in primary with the RHT increasing on head tilt right and in left gaze (R-IOOA).

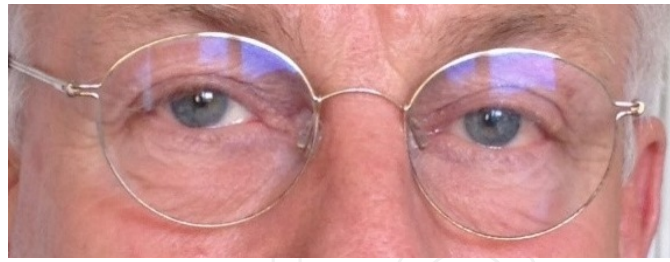

Figure 16. Congenital SO palsy with large RHT in primary with the RHT increasing on head tilt right and in left gaze (R-IOOA).

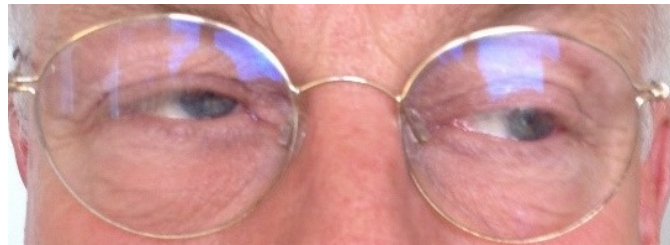

Figure 17. Congenital SO palsy with large RHT in primary with the RHT increasing on head tilt right and in left gaze (R-IOOA).



Figure 18. Congenital SO palsy with large RHT in primary with the RHT increasing on head tilt right and in left gaze (R-IOOA).

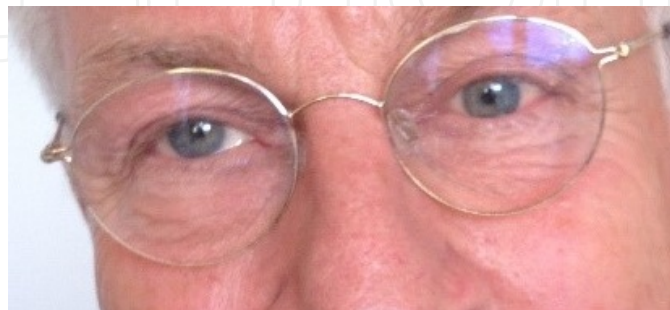

Figure 19. Congenital SO palsy with large RHT in primary with the RHT increasing on head tilt right and in left gaze (R-IOOA).

Masked bilateral SOP can look like a unilateral SOP as only one eye will show significant IOOA. The presence of a V-pattern and bilateral extorsion on fundus examination also suggests bilateral involvement in patients with a presumed unilateral SOP. In these cases of masked bilateral SOP, if surgery is performed on one eye, the contralateral SOP will become evident postoperatively

5.4.4. Traumatic SO palsy

Traumatic SO palsy is caused by closed head trauma. It is almost always bilateral as the 4th nerves exit the brain close together, so both nerves get traumatized with a traumatic shift of the tentorium. Since the strabismus is acquired, patients complain of torsional, vertical, and horizontal diplopia, worse in downgaze (SO field of action). Because both SO muscles are weak, the verticals cancel each other so there is minimal to no hypertropia in primary position. These patients have significant torsional diplopia because there is bilateral extorsion, which can be seen on fundus exam and on double Maddox rod testing. The fundus photos will show bilateral extorsion with the foveae below the lower pole of the optic disc. The pattern of strabismus for bilateral SO palsy is reversing hypertropia: (1) RHT on tilt right and LHT on tilt left and (2) RHT in left gaze and LHT on right gaze and a V pattern with esotropia in downgaze (Table 3).

Tilt R–RH 12		Tilt L–LH 10	
R-gaze	Ortho	L-gaze	
LH 8	RH 4	RH 10	
	ET 10		

Table 3. Example of measurements of bilateral SOP.

Bilateral SOP has a characteristic V pattern that is an arrow subtype. Since the SO muscles are abductors in downgaze, bilateral SOP causes lack of abduction in down gaze, thus causing an esotropia in downgaze. This causes a V-arrow pattern because most of the eso-shift occurs from primary position to downgaze. The big eso-shift from primary position to downgaze typical of an arrow pattern, which is virtually pathognomonic for bilateral SOP, as shown in Figure 10.

5.4.5. The management of inferior oblique muscle dysfunction

Selection of the appropriate surgical procedure is based on the amount of inferior oblique dysfunction. Inferior oblique overaction is clinically estimated on a scale of +1 through +4. Quantify the upshoot by bringing the fixing eye straight across to the lateral canthus and observe the adducting eye for upshoot (Figure 20).

Quantification of upshot in inferior oblique overaction: the abducting eye is fixating. The adducting eye is free to manifest the overaction. (A) Minimal upshoot (+1). (B) Upshoot (+2) of the adducting eye is obvious when the abducting eye looks straight across the lateral

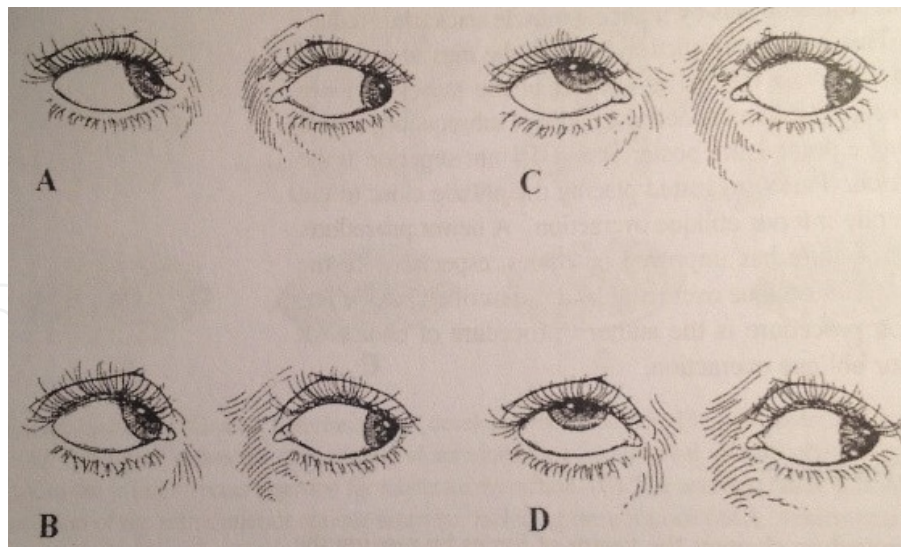


Figure 20. Quantifying the IOOA on a scale of +1 through +4.

canthus. (C) Severe upshoot (+3) of adducting eye. (D) Very severe upshoot (+4) of adducting eye.

The basic rule of thumb is that patients with +2 or more IOOA are candidates for an inferior oblique surgery, and those with +1 or less can be followed except those with significant V pattern (>15 PD). These should be considered for IO weakening procedure even with only +1 IOOA. In cases of asymmetric overaction, bilateral surgery should be done, even when one eye only displays +1 overaction, to avoid unmasking the minimal overaction. If amblyopia is present (greater than 2 Snellen lines), it is safer to restrict surgery to the amblyopic eye. Monocular surgery is sufficient in these amblyopic cases as the sound eye is always fixing and will not manifest an upshoot.

Weakening procedure of the IO muscle is the treatment for IO overaction, that is, IO recession (Figure 21), myectomy (Figure 22), or anteriorization (Figure 23). Inferior oblique overaction can be reduced by surgically moving the insertion anterior toward the equator and nasally so it is closer to the inferior rectus muscle (see the red arrow in the drawing below). Moving IO insertion nasally toward the inferior rectus slackens the IO, thus weakening its function and is called an IO recession. Myectomy weakens the inferior oblique, as removing a portion of muscle reduces the chance of local reattachment. Moving the IO insertion anterior to the equator changes the IO from an elevator to more of a depressor, and this is called IO anterior transposition. The graded anteriorization procedure is the authors' procedure of choice for mild to severe inferior oblique overaction. The basis of the graded anteriorization procedure is that the more anterior the inferior oblique insertion, the greater the weakening effect, tailoring the amount of IOOA to the amount of anteriorization. The IO muscle is placed 4 mm posterior to the inferior rectus insertion for +1 IOOA, and 3 to 4 mm to IR for +2 IOOA, 1 to 2 mm to IR for +3 IOOA, and at IR insertion for +4 IOOA. Severe bilateral DVD and IOOA needs the "J" deformity full anteriorization of the entire IO insertion, including the posterior fibers. The "J" deformity limits elevation of the eye.

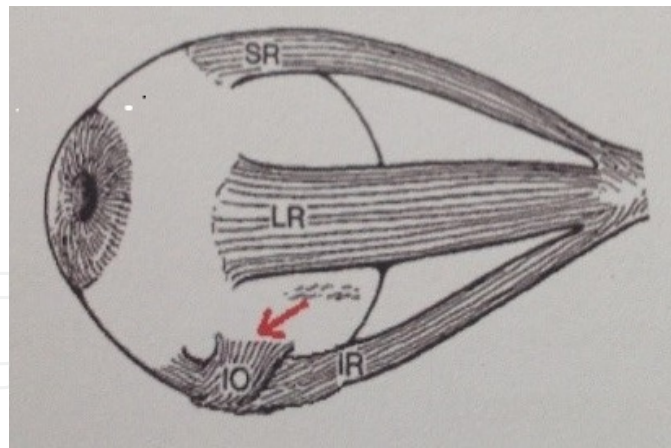


Figure 21. Recession.

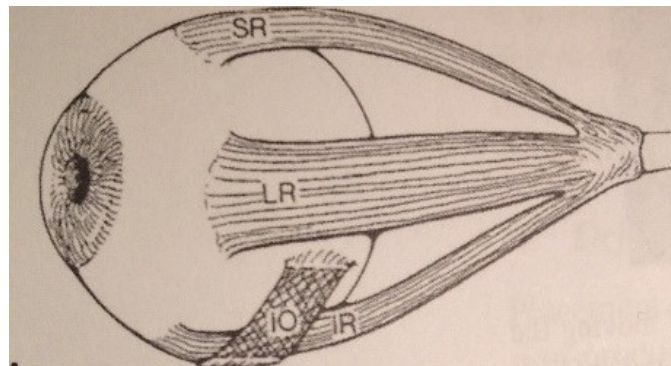


Figure 22. Myectomy.




Figure 23. Anteriorization.

In general, avoid antielevation by keeping the IO muscle 2 mm posterior to the IR insertion and avoid "J" deformity by keeping the IO posterior fibers posterior, as described in detail at the end of this chapter.

The final surgical decision must be based on a combination of factors, including the amount of V pattern and the presence of a vertical deviation in primary position. If no vertical deviation is present in primary position, then consider symmetrical surgery. Asymmetric-graded anteriorization is indicated if a hypertropia is present, and more anteriorization of the IO should be done on the side of the hypertropia. A full anteriorization (at the IR insertion, without "J" deformity) corrects about 6 PD hypertropia. An anteriorization with "J" deformity can correct up to 18 PD of hypertropia.

5.4.6. The management of congenital superior palsy

Surgery is indicated for a significant head tilt, a hypertropia causing asthenopia, and symptomatic diplopia. The surgery timing is controversial. In the United States, early surgery is suggested to prevent secondary facial asymmetry, while others advocate waiting until 2 to 3 years of age. Late surgery is advocated in Europe as strabismus measures are more reliable and binocular function more mature and stable. There is no evidence to clearly choose, as no controlled clinical randomized trials have ever been conducted. The authors' advice is to wait until 2 years of age as long as the head tilt is mild, or if binocular fusion is compromised, early surgery is indicated.

Prisms are usually of limited value because of the incomitance, but in some older adults, prisms can be used to help control the deviation. If prisms are used, undercorrect the deviation to stimulate vertical fusion amplitudes.

The surgical plan depends on the pattern of the strabismus, depending on unilateral or bilateral location. In general, the treatment strategy is based on where the deviation is greatest and designing a surgical plan to correct the deviation in the primary position while reducing the incomitance.

Unilateral SOP with hypertropia <18 PD can be treated with graded anteriorization ipsilateral IO muscle. Unilateral hypertropia >18 PD can be treated by graded anteriorization, ipsilateral IO muscle, and contralateral IR recession (if there is significant hyper in down gaze). Bilateral SOP with hypertropia <8 PD can be treated by bilateral IO-graded anteriorization with greater anteriorization on the hypertropic side. A masked bilateral can be treated by ipsilateral IO anteriorization and contralateral IR recession plus contralateral IO recession. If there is residual head tilt after IO weakening procedure, perform the Harada-Ito procedure on the opposite side to the head tilt. SO tendon tuck is reserved for extreme lax SO tendon.

5.4.7. The management of traumatic superior oblique paresis

Observe conservatively for at least 6 months, taking serial measurements of the deviation. If, after 6 months of observation, the SOP persists with diplopia, surgery should be considered. Prism glasses are usually not useful because of the torsion and incomitance of the deviation.

Surgical plan for most traumatic bilateral SOP with extorsion, esotropia ≥ 10 PD in down gaze but no significant hypertropia in the primary position, is the bilateral Harada-Ito procedure and bilateral MR recessions (small) with infraplacement one-half tendon width.

6. Strabismus surgical techniques: Do's and don'ts to avoid complications

6.1. Surgery to the horizontal rectus muscles

Muscle surgery to the horizontal rectus muscles, in the form of recessing and resecting, is commonly performed for esotropia and exotropia. These muscles can also be moved away from their original line of action to treat vertical deviations, pattern strabismus (A and V), and nerve palsies. Surgery to the vertical rectus muscles is fundamentally similar to horizontal rectus muscles surgery but is less commonly performed. Each patient requires an individual surgical approach to the management of their strabismus, but the tables provided in Appendix I may be of assistance as a guide in deciding on measurements.

6.1.1. General considerations

Before surgery, make sure that the patient's head position is optimal avoiding flex of the neck. Have the patient's neck extended so that the patient is looking at the surgeon sitting at the head of the surgical table. A towel roll placed under the patient's shoulders may be helpful to get the chin up (Figure 24).

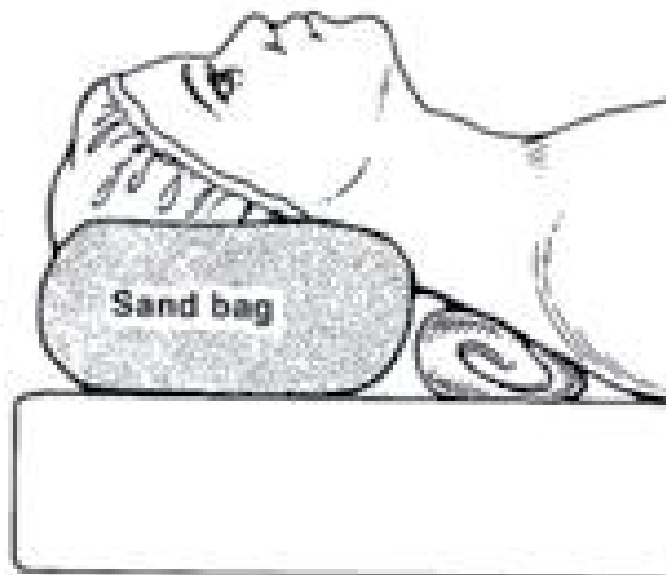


Figure 24. Correct head position.

6.1.2. *Limbal vs. fornix approach*

It is important to choose a proper conjunctival incision, as this can have an impact on your strabismus surgery as emphasized as one of the 10 commandments for strabismus surgery by Dr. Wright [12]. The limbal incision is made at the limbus (Figure 25) and is suitable for older patients over 40 years, as the conjunctiva is friable. For patients under 40 years, both limbal and fornix incisions are usable for rectus surgery. The fornix incision is 8 mm posterior to the limbus in the inferior fornix (Figure 26) and should therefore always be preferred for inferior and superior oblique surgery. Fornix incision is preferred to a Swan incision, which is over the muscle insertion, as Swan can leave a conjunctival scar making future surgery difficult, and careful closure is therefore required.

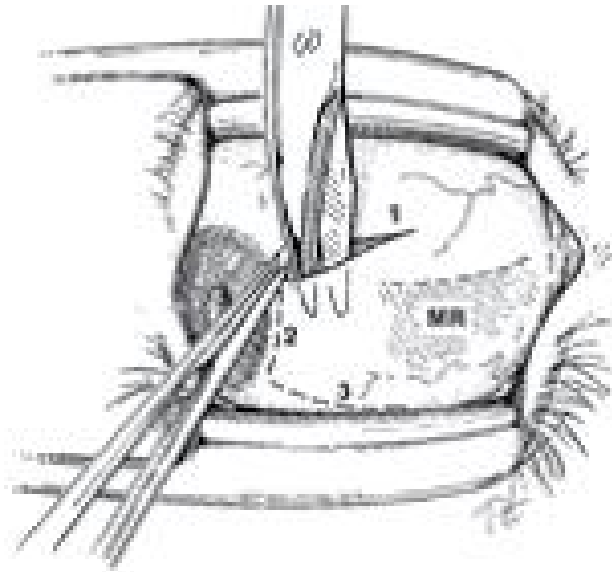


Figure 25. The limbal incision.

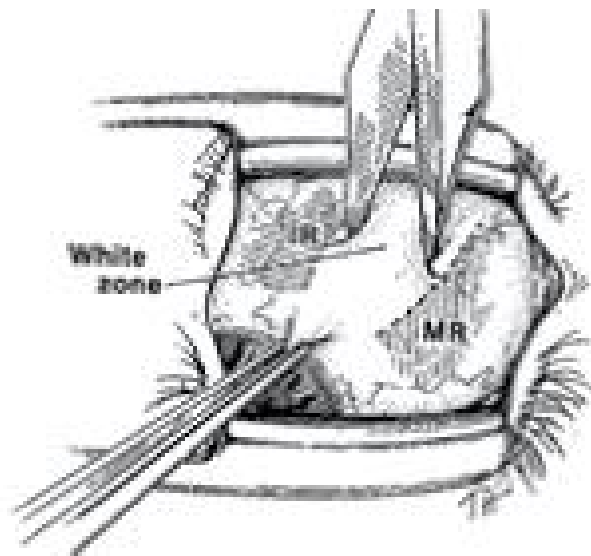


Figure 26. The fornix incision.

6.1.3. *Avoid fat adherence syndrome*

Posterior Tenon’s capsule separates orbital fat from the extraocular muscles and sclera (Figure 27). If during periocular surgery one ruptures posterior Tenon’s capsule, fat will prolapse and scar attaches to the extraocular muscle and/or the sclera (Figure 28). The scar is an adhesion that contracts causing restriction of ocular rotations (restrictive strabismus), called fat adherence, first described by Marshall M. Parks MD.

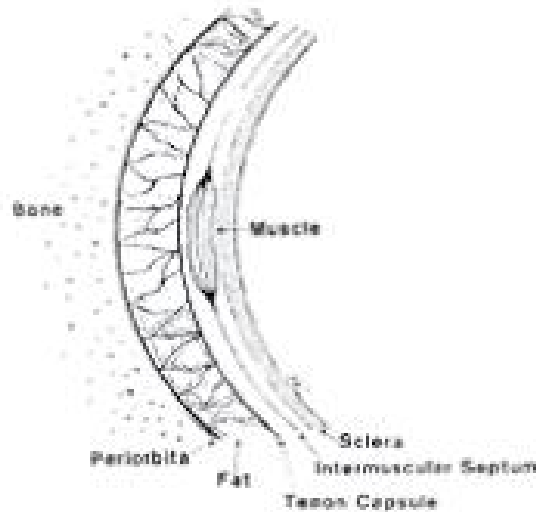


Figure 27. Anatomy of the posterior Tenon’s capsule.

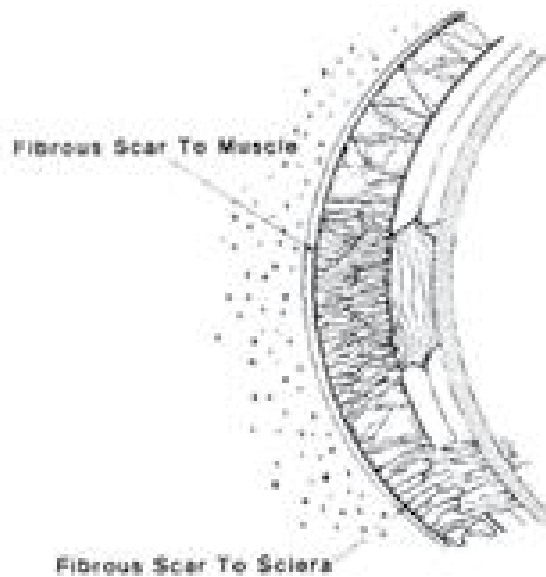


Figure 28. Anatomy of the posterior Tenon’s capsule.

6.1.4. Scleral thickness, avoid perforation

The scleral thickness behind the rectus muscle insertion is extremely thin, measuring only 0.3 mm. Because of the thin sclera, perforation into the globe is a significant risk during the scleral needle pass when suturing the muscle to sclera. Therefore, proper needle selection is important to reduce the risk of perforation. The preferred *side cutting or spatulated needle* has a flat top and bottom (Figure 29). The flat bottom reduces the chance of inadvertent perforation deep into the globe and the flat top prevents cutting into the roof of the scleral tunnel above. Furthermore, to avoid inadvertent perforation of the globe, it is critical that the scleral needle pass is shallow and controlled keeping the tip up and passing the needle horizontally during the scleral needle pass in a flat and straight manner.

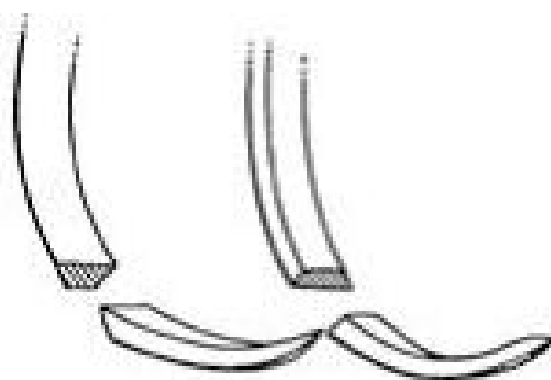


Figure 29. Side cutting or spatulated needle is preferred.

6.1.5. Avoid partially slipped muscle

To hook a rectus muscle successfully, keep a small hook perpendicularly and firmly to the sclera. Then pass the hook under the rectus insertion, keeping the perpendicular orientation until the hook is under the muscle (Figure 30). This will prevent splitting of the rectus muscle as the tip of the hook stays on the sclera. After hooking the muscle, replace the small hook with the large hook as a Jameson or Helveston hook.

The pole test should then be performed to ensure the entire rectus muscle is hooked. A small hook is placed at the tip of the larger hook holding the muscle. The small hook is then pulled supero anteriorly with the tip perpendicular to the sclera (Figure 30). If the muscle is split (Figure 31), the residual fibers will restrict the small hook from moving anteriorly.

After hooking the entire rectus muscle, avoiding rupture of the posterior Tenon's capsule as previously described, it is important to secure the muscle by full-thickness locking bites, centrally and then at each edge of the muscle for three point fixation (Figure 32). Full-thickness pass at the edges is very important, as a partial thickness pass will result in a partially slipped muscle occurring at the edge that was not secured with full-thickness bite (Figure 33).

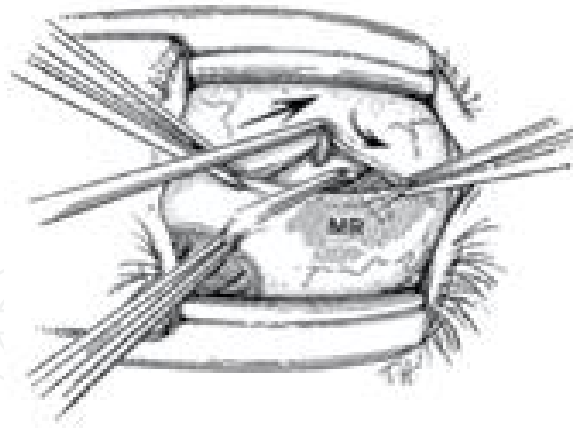


Figure 30. When hooking the muscle, remember perpendicular orientation of the hook.

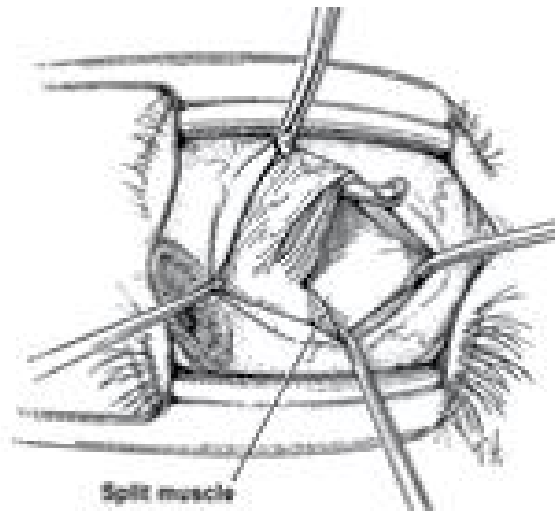


Figure 31. The pole test, disclose a split muscle.

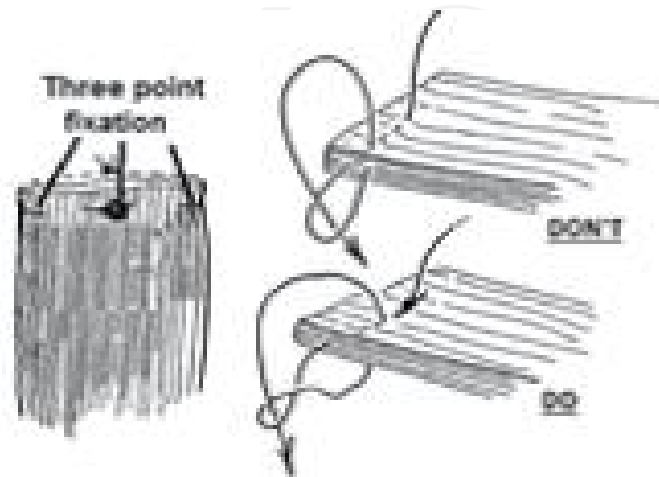


Figure 32. Secure the muscle by full-thickness locking bites.

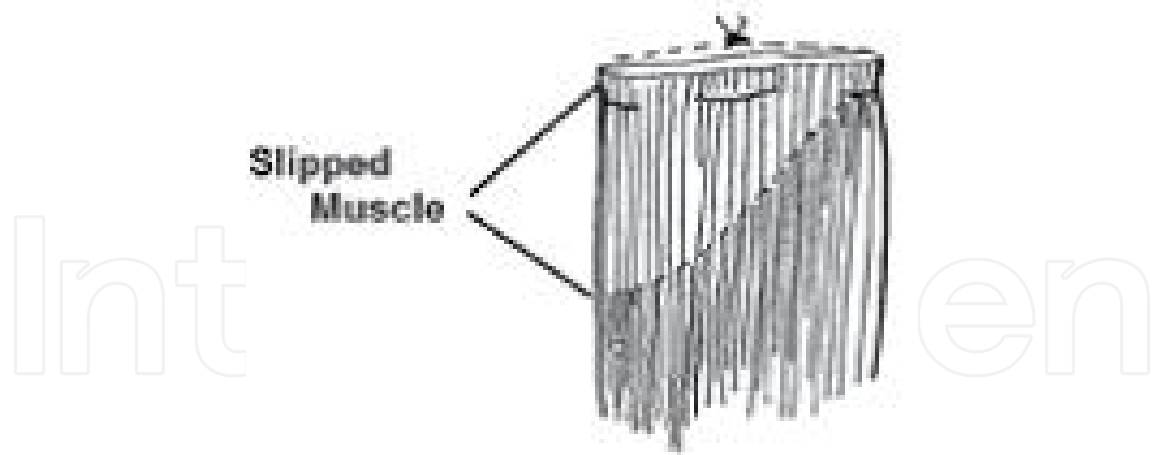


Figure 33. Partial thickness pass will result in a partially slipped muscle.

6.1.6. Weakening and tightening procedures

Rectus muscle recession is a weakening procedure, where the rectus muscle is detached from the globe and replaced further from the limbus. The muscle is detached from its insertion and recessed some specific mm and sutured to sclera. This shortens the distance between the origin and the insertion of the muscle and therefore has a weakening effect (Figure 34).

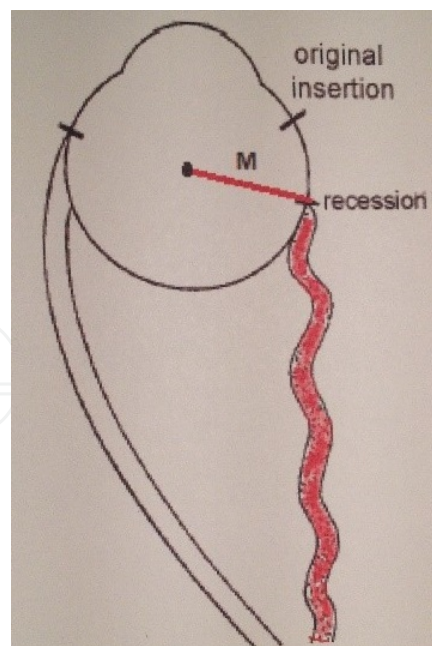


Figure 34. Recession.

If a rectus muscle is not widely splayed, there will be redundant muscle and central sag causing a larger recession than intended. Prevent central sag by adequately separating the muscle poles

and by securing the center of the muscle with a central security knot. Central sag can be corrected with the same suture that holds the muscle (Figure 35)

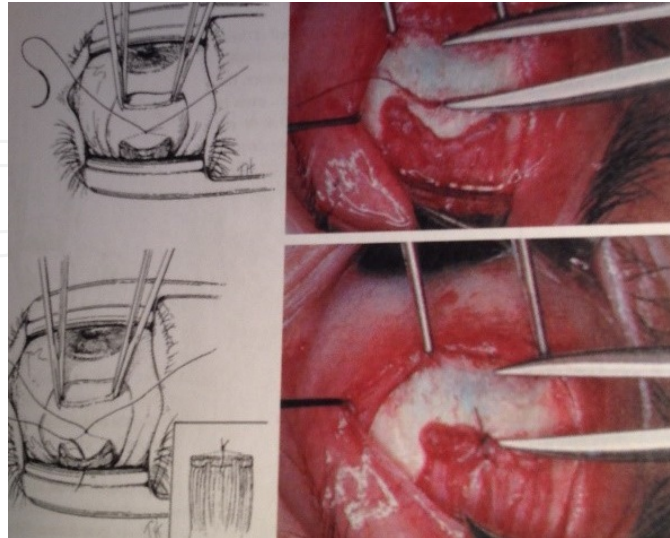


Figure 35. The center of the muscle is secured with a central security knot.

Rectus muscle resection tightens the muscle by removing a segment of the muscle then advancing the muscle to the original insertion (Figure 36). Tightening effect increases when the eye rotates away from the resected muscle because the muscle gets tighter.

Rectus muscle plication has the same effect as resection as it tightens the muscle. Sutures are attached to the muscle posterior to the insertion then passes thorough sclera anterior to the insertion (Figure 37, top). The sutures are pulled up to fold the muscle (Figure 37, bottom). Plication tightens the muscle without the need for muscle disinsertion; thus, it is safer than resection. Plication spares the anterior ciliary vessels, thus reducing the risk of anterior segment ischemia. The rectus plication was invented by professor and coauthor Dr. Kenneth Wright during his fellowship and published in 1991 (Figure 37).

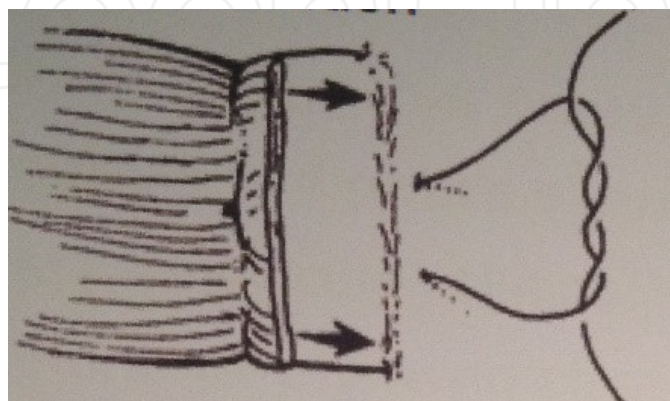


Figure 36. Resection.

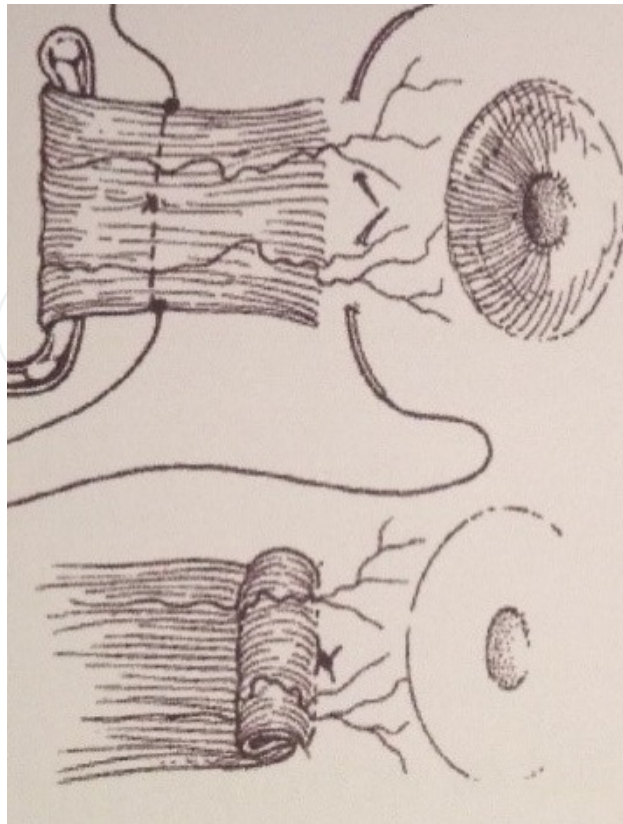


Figure 37. Plication.

To perform rectus muscle recessions, resections, and plications, replace the standard hook (Jameson or Helveston hook) with the titanium *Wright grooved hook* (Figure 38). This hook allows for suturing the muscle insertion over the groove (Figure 39), thus preventing inadvertent scleral perforation and making it easy to get full-thickness locking bites and keep suture placement precise and consistent: not too posterior—not too anterior. Especially when suturing tight muscles, the Wright hook helps pulling the muscle to the surgical field and provides space to suture the muscle (Figure 40). Dr. Wright holds a U.S. patent on the hook design.



Figure 38. Wright groove hook.

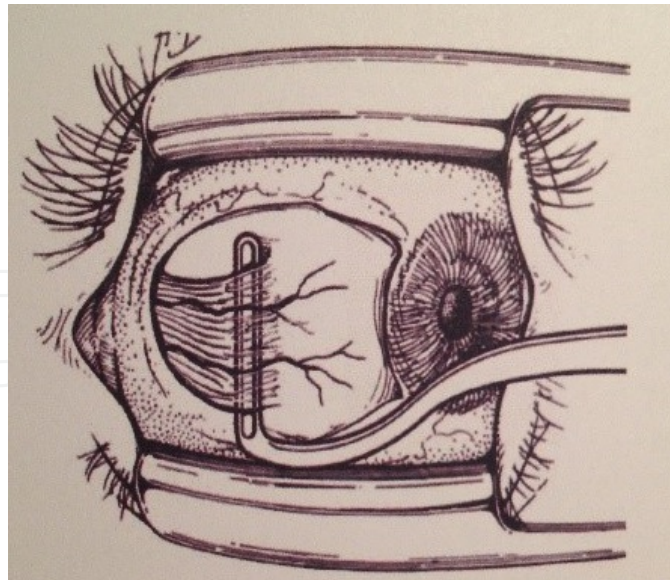


Figure 39. Suturing rectus muscle insertion over groove hook.

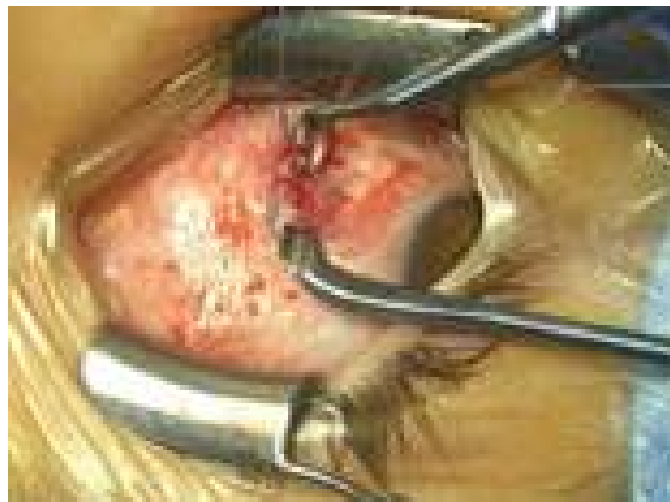

Figure 40. Suturing rectus muscle insertion over groove hook.

6.1.7. *Avoid anterior segment ischemia*

The two long posterior ciliary arteries and the anterior ciliary arteries supply circulation to the anterior segment. Each group contributes about 50% of the anterior segment blood flow. The anterior ciliary arteries course with the rectus muscles (Figure 41). The MR, SR, and IR muscles having 2 arteries and are major suppliers, while the RL has one artery and contributes little to anterior segment circulation. Removing a rectus muscle will permanently disrupt the blood flow from the corresponding anterior ciliary arteries, and the arteries do not recanalize. In children, the long posterior ciliary arteries can maintain enough flow, so even if all the rectus muscles were removed, the child will not get anterior segment ischemia. In senior adults,

however, the posterior ciliary supply can be compromised from small vessel disease, and removing the 3 major supplier rectus muscles (i.e., MR, SR, and IR) can result in anterior segment ischemia. Anterior segment ischemia can cause uveitis, hypotonia, and corneal edema. Anterior ischemia is usually transient, lasting a few weeks to a couple of months; however, severe cases can result in vision loss. Treatment is low dose topical corticosteroid drops. Anterior segment ischemia has been reported to occur 10 to 20 years after strabismus surgery. The iris angiogram (Figure 42) shows hypoperfusion of the superior iris, indicating the superior rectus muscle has been removed and its ciliary vessels gone. Once a rectus muscle is removed, its ciliary vessels are permanently destroyed. Over 3 months, the collateral circulation improves especially in young persons, and the iris angiogram can revert to normal. There is no formula for the number of rectus muscles that can be safely detached. As a general rule, do not detach more than two rectus muscles at one time, unless absolutely necessary. As the two vertical and the medial rectus muscles provide the major anterior ciliary blood supply to the anterior segment, try to preserve at least one of these muscles.

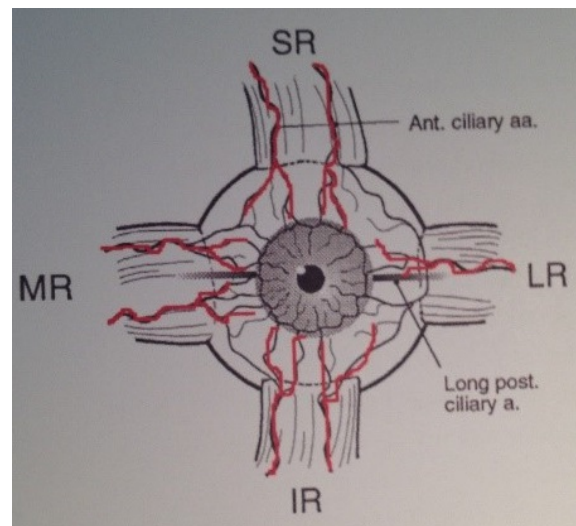


Figure 41. The anterior ciliary arteries course with the rectus muscles.

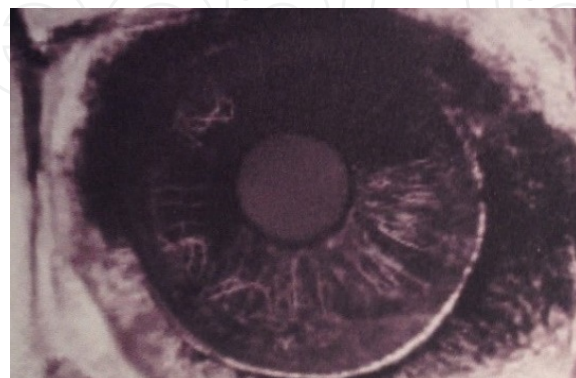


Figure 42. The iris angiogram shows hypoperfusion localized to the superior iris due to resection of the superior rectus muscle.

6.2. Surgery for oblique muscle dysfunction

6.2.1. Inferior oblique weakening

Inferior oblique overaction, both primary and secondary, can be treated by weakening the IO muscle. The three most frequently performed procedures to weaken the inferior oblique muscle is illustrated in Figure 43 and include inferior oblique (A) myectomy—remove a segment of muscle, (B) recession—move insertion toward the origin to slacken the muscle, and (C) anteriorization—move insertion anterior to equator to change the vector of forces so the IO is no longer an elevator; it is more or less vertically neutral. If the IO is placed anterior to the inferior rectus, then the IO will pull the front of the eye down and cause limited elevation, e.g., “antielelevation.” It is a complication of placing the inferior oblique too anterior but can be used to treat DVD. Avoid IO myotomy, as it is not effective, because the cut ends of the muscle inevitably reunite or scar to sclera, causing residual IOOA.

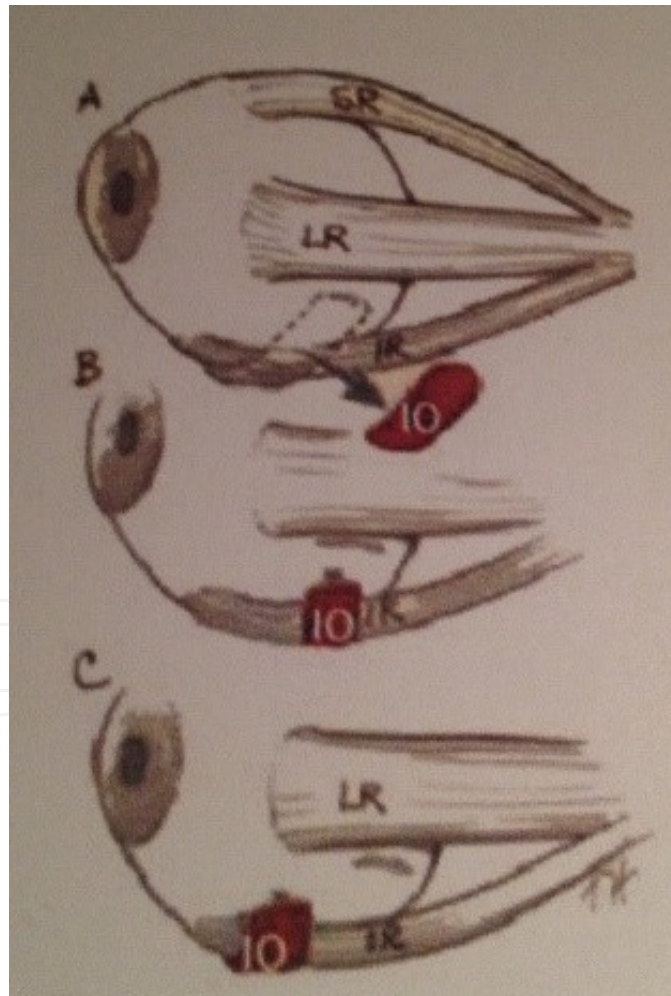


Figure 43. The three most frequently performed procedures to weaken the inferior oblique muscle: (A) myectomy, (B) recession, and (C) anteriorization.

The ciliary nerve courses with the IO nerve, so trauma during IO surgery to the nerve can rarely cause the complication of pupil dilatation and reduced accommodation. Avoid this by using direct visualization of the posterior border of the IO muscle during hooking off the muscle. Avoid “deep blind” posterior passes to hook the muscle and use the Wright grooved hook for suturing the inferior oblique muscle insertion while protecting the sclera in the area of the macular (Figure 44).

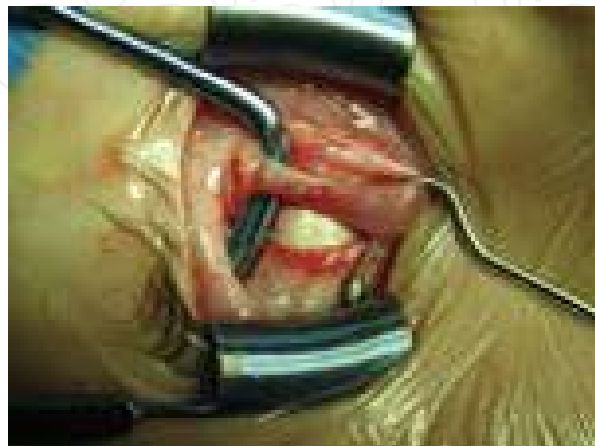

Figure 44. The Wright grooved hook used in IO recession protects the sclera in the area of the macular.

A neurovascular bundle attaches to the posterior aspect of the IO muscle. If the posterior fibers of the IO muscle are anteriorized to the level of the inferior rectus insertion, this will stretch the neurovascular bundle and cause a “J” deformity of the IO muscle (Figure 45). The tight neurovascular bundle attached to the IO muscle will pull the eye down and limit elevation (antielelevation). A better surgical technique is to keep the posterior muscle fibers posterior to avoid antielevation, unless some limitation of elevation is desired such as the case of treating DVD.

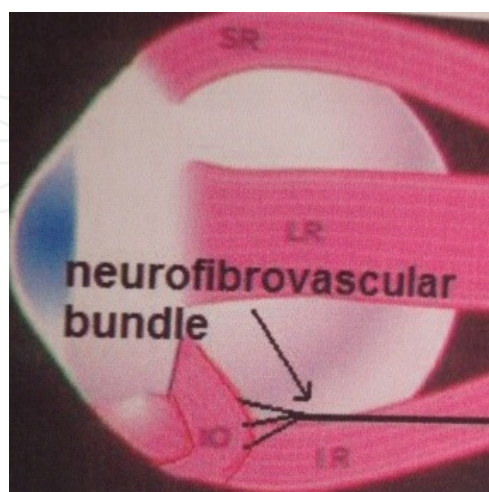


Figure 45. The posterior fibers of the IO muscle are anteriorized to the level of the inferior rectus insertion, stretching the neurovascular bundle and causing a “J” deformity of the IO muscle.

6.2.2. Superior oblique tightening

Two procedures that tighten the SO tendon include the full tendon tuck and the Harada–Ito procedure, which is a tightening of the anterior tendon fibers by a partial tuck or advancement of the anterior tendon fibers.

6.2.2.1. Superior oblique tuck

Extorsion associated with acquired SO palsy can be treated by tightening the anterior SO tendon fibers. The anterior SO tendon fibers are responsible for intorsion, while the posterior fibers cause depression and abduction. The SO full tendon tuck (Figure 46) tightens the tendon by pinching and folding the entire tendon. This results in intorsion, depression, and abduction. It can be used in cases of lax SO tendon causing an SOP and is therefore useful for correcting extorsion, hyperdeviation, and convergence in down gaze. If the full tendon tuck is made too tight, it will cause limited elevation worse in adduction due to tightening of the posterior tendon fibers, termed iatrogenic Brown's syndrome. Care must be taken to balance the superior oblique tightening against an induced Brown's syndrome by performing intraoperative forceductions of the superior oblique tendon after tucking.

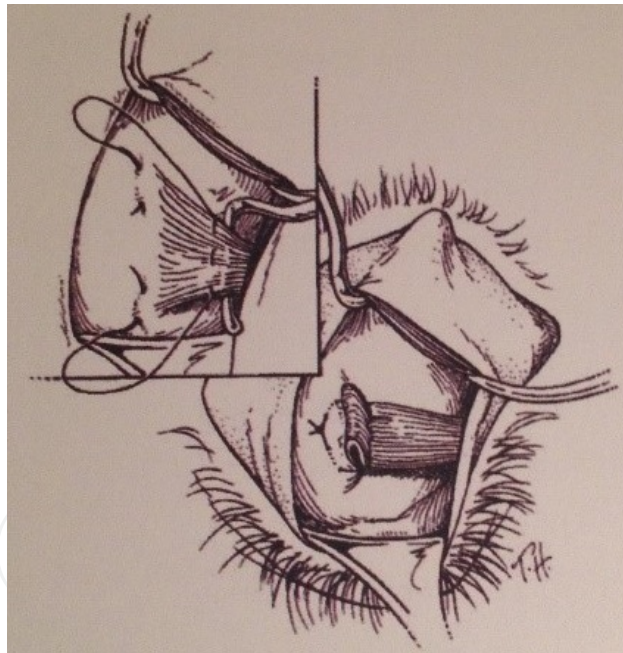


Figure 46. The SO full tendon tuck.

6.2.2.2. Harada–Ito procedure

There are clinical situations that require selective correction of extorsion without a significant change in vertical or horizontal alignment. A full tendon tuck in this situation is not appropriate as it would induce a hypotropia and iatrogenic Brown's syndrome. The Harada–Ito procedure is designed to selectively correct extorsion, as it tightens the anterior tendon thus intorting the

eye. Specifically, the procedure corrects extorsion, usually caused by an SOP, as only the anterior tendon fibers of the SO are tightened so there is little depressor or abduction effect. Iatrogenic Brown's syndrome is uncommon. Harada-Ito is the procedure of choice to correct extorsion without significant vertical strabismus. Figure 47 shows the Harada-Ito as the anterior fibers in red are pulled temporally toward the lateral rectus muscle to intort the eye as shown by the red arrow.

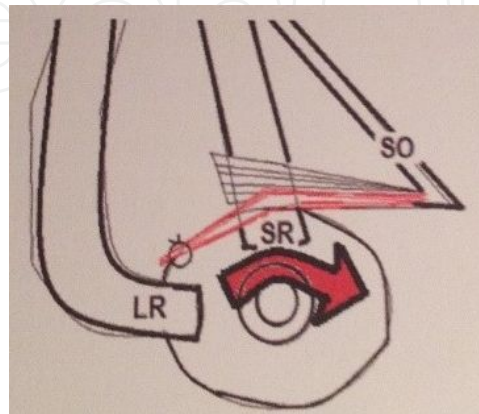


Figure 47. Harada-Ito procedure includes anterior fibers of SO pulled temporally toward the LR.

There are two ways to perform the Harada-Ito as illustrated in Figure 48: (A) remove the anterior 1/3 of the fiber and advance temporally toward the lateral rectus; (B) the classic Harada-Ito procedure—leave the tendon insertion intact but split the anterior fibers and pull them temporally toward the lateral rectus muscle (plication).

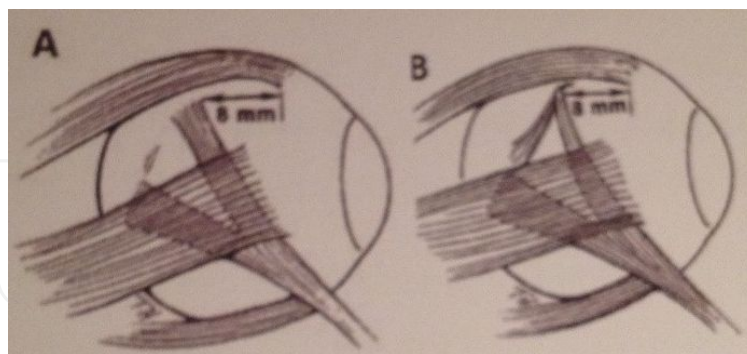


Figure 48. Two ways to perform the Harada-Ito procedure.

The anterior SO tendon fibers are looped with a suture and displaced laterally without disinsertion (Figure 49, left drawing). The anterior fibers are sutured to sclera 8 mm posterior to the superior border of the lateral rectus muscle (Figure 33, right photo). This procedure has the advantage of being easy reversible. To undo the classic Harada-Ito, simply cut the suture and the tendon will be back to normal. This must be done within 24 to 48 h after surgery, or the tendon will scar in place.

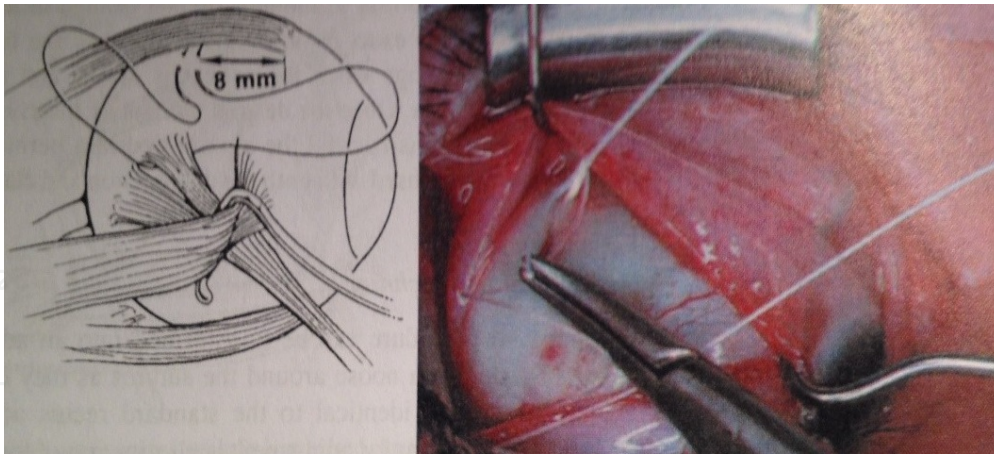


Figure 49. The classic Harada–Ito (plication) method where the anterior fibers are looped with a suture and sutured to sclera laterally.

6.2.2.3. Anesthesia

General anesthesia is used most frequently in strabismus surgery. All strabismus surgery on children requires general anesthesia. Patient anxiety, reoperations, and SO surgery are also indications for general anesthesia. An experienced anesthesiologist, familiar with pediatric anesthesia and potential life-threatening complications like malignant hyperthermia, is an essential member of the surgical team.

Local anesthesia can be used in cooperative adults for unilateral surgery. A retrobulbar injection of 4 ml of lidocaine is given. If the patient experiences intraoperative pain, it can be treated with an additional local injection of lidocaine near the muscle being careful not to inject directly into the muscle. Topical anesthesia and sub-Tenon anesthesia is a good option for adult patients requiring a unilateral or bilateral recession or even resection procedures. With gentle manipulation, avoiding pulling on the muscle, topical anesthesia strabismus surgery can be done with minimal pain, without bearing the risk of general anesthesia.

6.2.2.4. Sutures

A 5-0 vicryl suture with S-24 double-arm spatula needles, or a 6-0 vicryl suture with S-29 spatula needles, are the usual sutures of choice for strabismus surgery. A 5-0 mersilene suture (nonabsorbable) is indicated for muscles that may develop a postoperative stretched scar, advancement of a slipped muscle, the Harada–Ito procedure, and Wright’s silicone tendon expander procedure.

6.2.2.5. Magnification and light source

Magnification of 2 times is helpful or use the lowest magnification of a surgery microscope. High magnification should be avoided as it significantly limits depth of focus and field size. A head lamp is advised if a surgery microscope is not used.

6.2.2.6. Postoperative care

Immediate recovery: NPO is necessary for 2 h after surgery, depending on the age of the patient. Restricting all oral intake helps reduce nausea and vomiting postoperatively. Do not use eye patches unless an adjustable suture was used or it was a multiple reoperation.

6.2.2.7. Outpatient follow-up

Prescribe antibiotic-steroid ointment, b.i.d. × 10 days. No swimming for 2 weeks, and schedule a follow-up postoperative visit in the first week, then a second postoperative visit usually in 6 weeks, depending on the patient's condition and age. Young patients with intended overcorrection of intermittent exotropia need to be followed more frequent. Patients should be warned of the possibility of periocular infection and to return immediately if redness or swelling persists.

If you want to dig even deeper into strabismus surgery, we suggest you to read the books and papers mentioned below.

7. Conclusion

The most important rule for the strabismus surgeon is to continue learning from experience. Surgery should be done carefully and should preoperatively be planned and thought out logically. Unexpected results should be questioned. Procedures that do not measure up to the surgeon's expectations should be altered. The surgeon should work on improving his or hers skills and develop his or hers own set of guidelines. However, it is apparent that not all surgeons will have the opportunity to operate on a sufficient number of patients to be innovative. In that case, the surgeon should select his or her authority carefully and remain appropriately skeptical and positively critical. It is not about "how many" but rather "how" you perform. Our patients deserve no less than this.

Author details

Helena Buch Hesgaard^{1*} and Kenneth W. Wright²

*Address all correspondence to: hbh@dadlnet.dk

1 Copenhagen Eye and Strabismus Clinic, Copenhagen, Denmark

2 Keck School of Medicine, University of Southern California, Los Angeles, CA, USA

References

- [1] Buch H H, Vinding T. Acute acquired comitant esotropia of childhood: a classification based on 48 children. *Acta Ophthalmol* 2015 93: 568-574.
- [2] Hardesty HH, Boynton JR, Keenan JP. Treatment of intermittent exotropia. *Arch Ophthalmol*. 1978; 96:268–274.
- [3] Hudson HL, Feldon SE, Gilbert J. Late overcorrection of hypotropia in Graves ophthalmopathy. Predictive factors. *Ophthalmology* 1992;99: 356–360.
- [4] Ludvig I. Scar remodeling after strabismus surgery. *Trans Am Ophthalmol Soc*. 1999; 97:583–651.
- [5] MacEwen C, Gregson R. *Manual of strabismus surgery*. 1st ed. 2003. Elsevier.
- [6] Pediatric Eye Disease Investigator Group. Spontaneous resolution of early-onset esotropia: experience of the Congenital Esotropia Observational Study. *Am J Ophthalmol*. 2002;133:109–118.
- [7] Pediatric Eye Disease Investigator Group. The clinical spectrum of early-onset esotropia: experience of the Congenital Esotropia Observational Study. *Am J Ophthalmol*. 2002;133:102–108.
- [8] Pediatric Eye Disease Investigator Group. A randomized trial comparing part-time patching with observation for intermittent exotropia in children 12 to 35 months of age. *Ophthalmology*. 2015 Aug;122(8):1718–25.
- [9] Strube YN, Wright KW. *Pediatric ophthalmology and strabismus*. Oxford University Press. 2014.
- [10] Wiesel TN, Hubel DH. Binocular interaction in striate cortex of kittens reared with artificial squint. *J Neurophysiol*. 1965;28: 1041–1059.
- [11] Wright, K.W. *Color atlas of strabismus surgery. Strategies and techniques*. New York: Springer. 3rd ed. 2007, and 4th ed. 2015.
- [12] Wright K.W. My “10 commandments” for strabismus surgery. *Masters of surgery. Rev Ophthalmol*. 2015; May, 72–79.
- [13] Wright’s Strabismus Review. A comprehensive review made crazy easy. By Kenneth W. Wright. Editor Lisa S. Thompson. 2015.
- [14] Wright KW. Clinical optokinetic nystagmus asymmetry in treated esotropes. *J Pediatr Ophthalmol Strabismus* 1996;33:153–155.
- [15] Wright KW, Edelman PM, McVey JH, Terry AP, Lin M. High grade stereo acuity after early surgery for congenital esotropia. *Arch Ophthalmol*. 1994;122:913–919.

- [16] Wright KW, Bruce-Lyle L. Augmented surgery for esotropia associated with high hypermetropia. *J Pediatr Ophthalmol Strabismus* 1993;30:167–170
- [17] Høeg TB, Moldow B, Ellervik C, Klemp K, Erngaard E, la Cour M, Buch H. Danish Rural Eye Study: the association of preschool vision screening with the prevalence of amblyopia. *Acta Ophthalmol.* 2015;93:322-329.

IntechOpen

IntechOpen

