

# We are IntechOpen, the world's leading publisher of Open Access books Built by scientists, for scientists

**4,800**

Open access books available

**122,000**

International authors and editors

**135M**

Downloads

Our authors are among the

**154**

Countries delivered to

**TOP 1%**

most cited scientists

**12.2%**

Contributors from top 500 universities



**WEB OF SCIENCE™**

Selection of our books indexed in the Book Citation Index  
in Web of Science™ Core Collection (BKCI)

Interested in publishing with us?  
Contact [book.department@intechopen.com](mailto:book.department@intechopen.com)

Numbers displayed above are based on latest data collected.

For more information visit [www.intechopen.com](http://www.intechopen.com)



---

# Subconjunctival Mitomycin C Injection into Pterygium Decreases Its Size and Reduces Associated Complications

---

Mohammad Hossien Davari, Hoda Gheytsi and Esmat Davari

Additional information is available at the end of the chapter

<http://dx.doi.org/10.5772/60090>

---

## Abstract

**Purpose:** To evaluate the safety and efficacy of subconjunctival injection of low dose mitomycin C (MMC) in the management of pterygium.

**Patients and Methods:** This study was carried out from February 2006 to April 2007 in the eye clinic of Vali-e-Asr Hospital of Birjand University of Medical Sciences. Forty eyes with primary pterygia received 0.02 mg MMC (0.1 ml of 0.2 mg/ml solution, Kyowa Hakko Kogyo Co. Ltd., Tokyo, Japan) subconjunctivally injected into the body of the pterygium. Patients were followed at one day, one week, one month, six months and one year after injection. Patients were examined at all visits for conjunctivally erythematic, epithelial defects; intraocular pressure; topography; keratometry; and other complications (complete slit-lamp examinations).

**Results:** The only complications after subconjunctival MMC injection were mild chemosis, long discomfort, and redness in the site of injection for four days, which were seen in six patients (15%). Toxicity of MMC was not observed in any case. The size of pterygia reduced in 83% of cases and progression were not seen in any case. The amount of astigmatism reduced in 70% cases (mean 0.27 diopter).

**Conclusion:** Subconjunctival injection of MMC is an effective treatment and allows exact titration of MMC delivery to the activated fibroblasts and minimizes epithelial toxicity but long term follow up is required.

**Keywords:** pterygium, mitomycin C, subconjunctival, complication

---

## 1. Introduction

Pterygium is a fibrovascular overgrowth of degenerative conjunctiva tissue that extends across the limbus and invades the cornea [1, 2].

---

The risk factors for pterygium development include exposure to ultraviolet (UV) light, dust, wind, heat, dryness, and smoke [2].

The primary indication for surgical removal of pterygium is visual acuity reduction. The cause of this phenomenon is extension of remaining scar to visual axis [3]. Irregular astigmatism, reduced vision, discomfort and irritation, difficulty with contact lens wear, refractive surgery, and cosmetic deformity are other reasons for surgical intervention [3].

A wide range of surgical procedures for removal of pterygia have been reported [4]. However, recurrences after excision have been reported to be very high. For example, it has been reported as high as 30% to 80% with the bare sclera technique [5]. The conjunctiva auto graft transplantation effectively prevents pterygium recurrence [6, 7, 8].

MMC is an antibiotic, antineoplastic agent that selectively inhibits the synthesis of DNA, cellular division, and protein [9]. The mechanism of action of MMC seems to be inhibition of fibroblast proliferation at the level of the episclera [10, 11, 12]. The benefit of MMC is having prolonged, but not permanent, effectiveness on suppressing human fibroblasts [13, 14, 15].

Although multiple studies have reported recurrence rates of approximately 5% to 12% with the use of topical MMC [16, 17], this technique has been associated with rare but significant conjunctival and corneal toxicity [16]. In an attempt to decrease ocular morbidity, the intraoperative administration of MMC was applied directly to the sclera bed, which has gained increasing acceptance. Recently, combined pterygium removal with intraoperative MMC and conjunctiva auto grafting for primary and recurrent pterygium has been described [18].

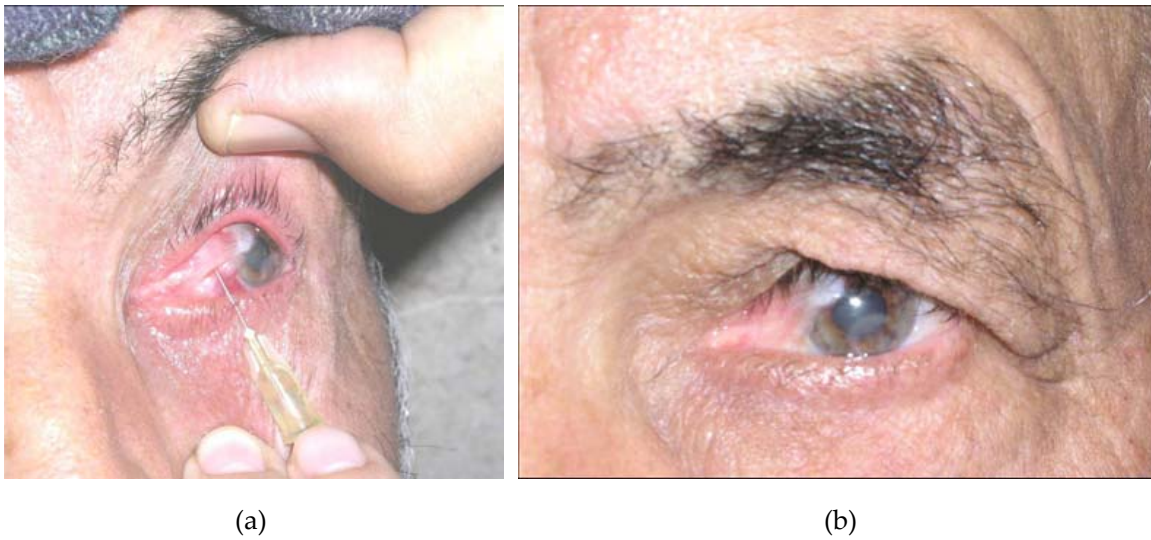The purpose of this study was to evaluate effectiveness by applying MMC at low concentration and low volume.

## 2. Patients and methods

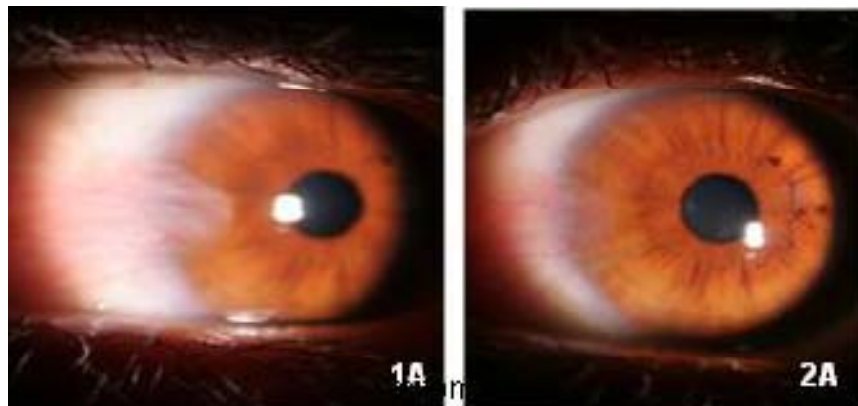
Forty consecutive patients (40 eyes) with primary pterygia who attended the eye clinic, Vali-Asr Hospital of Birjand University of Medical Sciences, between 2006 and 2007 were included in this study. All patients had primary pterygium grade I or II and were not previously operated. The grading used was as follows: Grade I: small primary pterygium, fibrous type, pinguecular, and classical type. Grade II: advanced primary pterygium with no optical zone involvement. Grade III: advanced primary pterygium with optical zone involvement. We selected only grade I and II.

A complete ocular examination, including slit-lamp examination and hematological examination, was performed on each patient. All surgeries were performed by one surgeon (Dr. Davari). Satisfaction of Ethical Clearance Committee accepted and all patients were given an explanation of the procedure and informed consent was obtained from all.

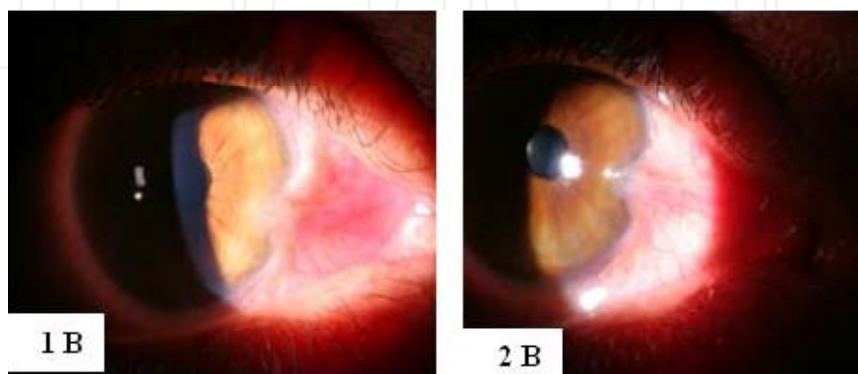
A drop of tetracaine 0.5% was instilled in the involved eye for topical anesthesia and the patients were injected subconjunctivally with a 30-gauge needle on an insulin syringe containing 0.1 ml of 0.2 mg/ml of MMC (Kyowa Hakko Kogyo Co. Ltd. Tokyo, Japan). The injection was done directly into the pterygium 1mm from limbos (Figure 1).



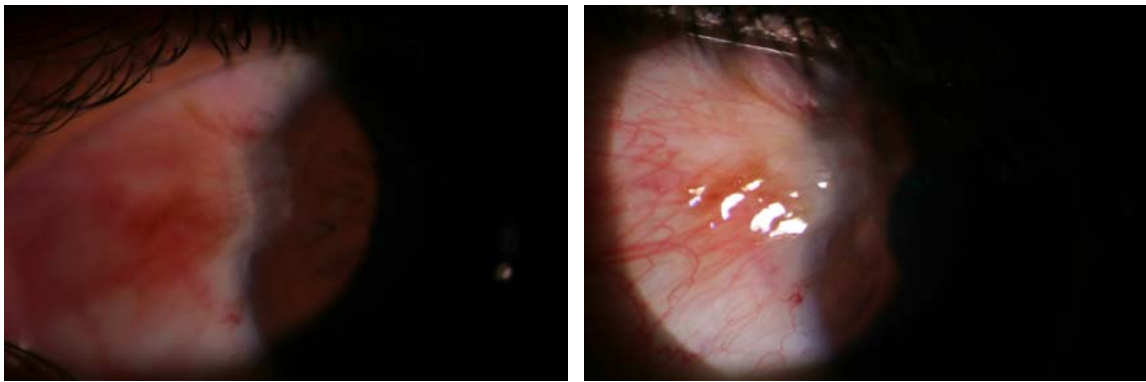
**Figure 1.** (a) Subconjunctival injection of MMC directly into pterygium, (b) After injection of MMC the degree of inflammation reduced.



**Figure 2.** (1A) Before MMC injection, (2A) After MMC injection



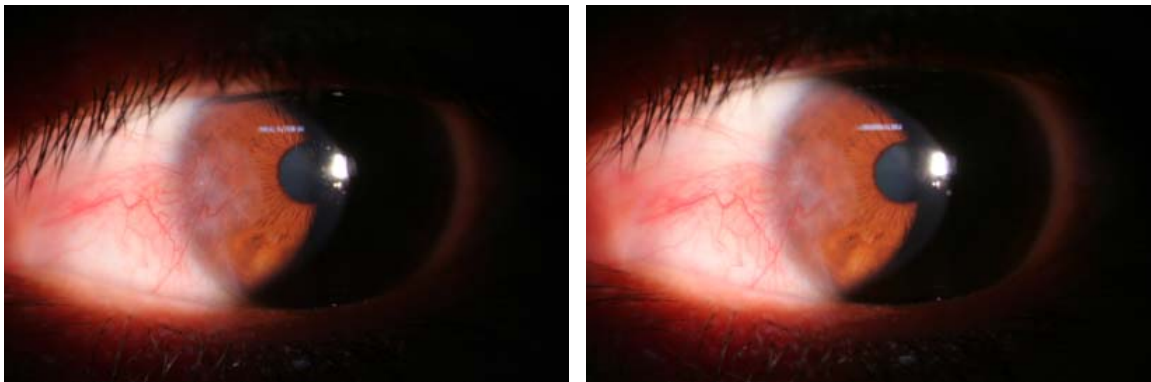
**Figure 3.** (1B) Before MMC injection, (2B) After MMC injection



(a)

(b)

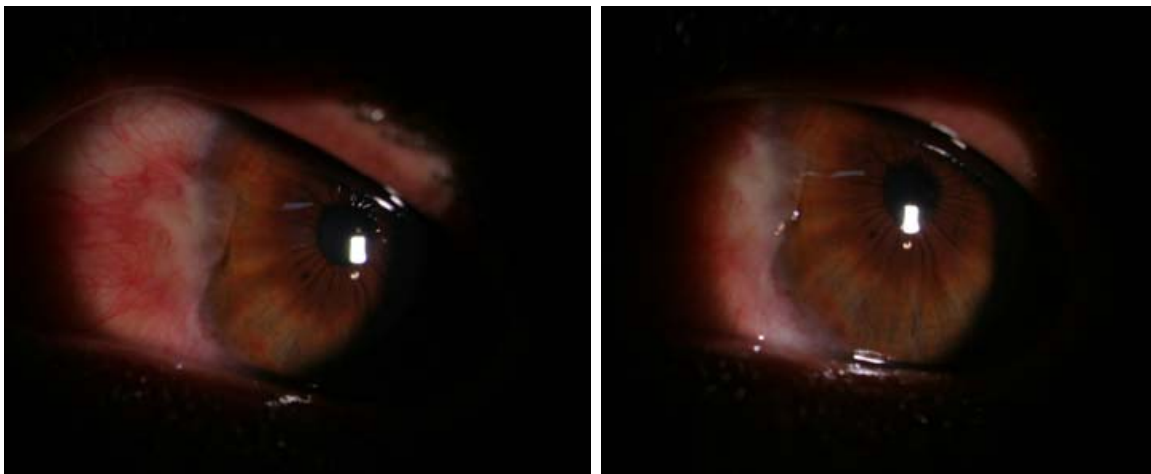**Figure 4.** (a) Before MMC injection, (b) After MMC injection



(a)

(b)

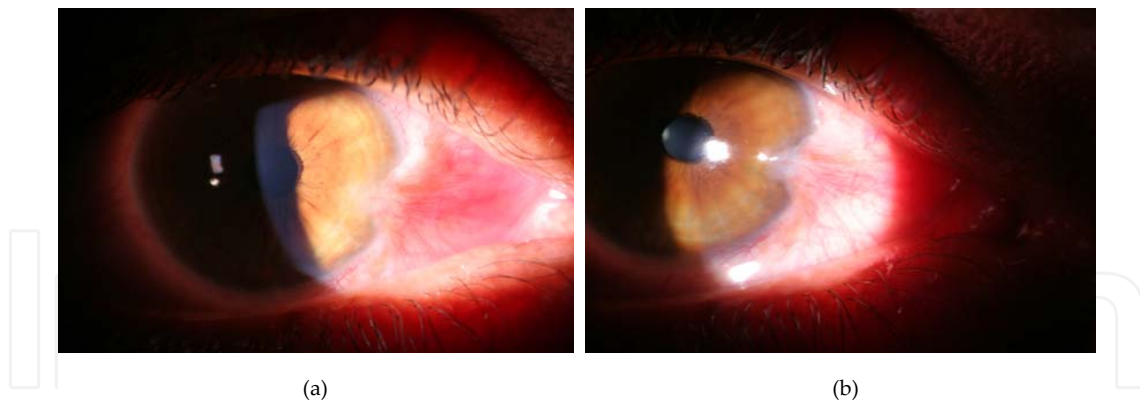**Figure 5.** (a) Before MMC injection, (b) After MMC injection



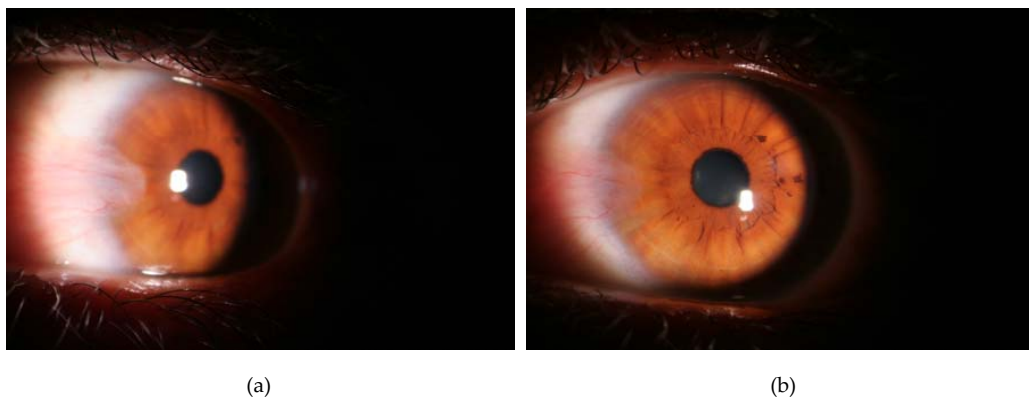
(a)

(b)

**Figure 6.** (a) Before MMC injection, (b) After MMC injection



**Figure 7.** (a) Before MMC injection, (b) After MMC injection



**Figure 8.** (a) Before MMC injection, (b) After MMC injection

All patients received one drop of chloramphenicol 0.5% and betamethasone 0.1% eye drops that were instilled four times daily for two days. After injection, patients were followed up at one day, one week, one month, six months, and one year. All patients were examined by a slit lamp at all visits for conjunctiva erythematic, epithelial defects, intraocular pressure, and other complications (complete slit-lamp examinations). The changes of pterygium size were evaluated by biomicroscope measurement (slit-lamp). (Base)  $\times$  (apex)  $\times$  (length) vs. mean size before and after MMC injection: (base means: up to down of pterygium in limbos, apex means: end of pterygium in cornea). The changes of refraction were also evaluated with topography and keratometer before and after injection.

Exclusion criteria were collagen vascular disease or other autoimmune diseases; pregnancy; ocular surface pathology or infectious, previous limbal surgery; and type III of pterygium.

### 3. Result

Of the 40 patients who participated in this study, 18 (45%) were males and 22(55%) were females. The mean age was 41.50 years. 16 (40%) left eye and 24 (60%) right eye. The patients

were followed up from 12 to 14 months after injection (the mean follow-up period was 12 months). According to this study, 22.50% were farmers, 45% were housewives, and 32.50% had other occupations.

Within 1–3 days after the subconjunctival injection of MMC, 6 patients complained of irritation accompanied with mild conjunctiva swelling, hyperemia, and tearing (15%). These processes were controlled completely by using betamethasone 0.1% more frequently within 1 week. The pterygia were less vascular and less inflamed at the 6th-month visit after MMC injection.

We detected the reduced size of pterygium (mean size before MMC injection: 5.3mm (base) ×2.3 (apex) ×2.4(length) vs. mean size after MMC injection: 5mm (base) ×2.1mm (apex) ×1.56mm (length)) with mean 0.48 mm (base means: up to down of pterygium in limbos, apex means: end of pterygium in cornea that were evaluated by biomicroscope measurement (slit-lamp)). The size of pterygium was reduced in 83% of cases, and in all cases there were not seen progression and reduced the amount of astigmatism (mean 0.27 diopter) in 70% cases that were evaluated by topography and keratometry {p=0.00} (Table 2). We also detected no significant change in visual acuity and intraocular pressure.

	Sex		Job			Eyes		Age	
	Male	Female	Farmer	Housewives	Others	Left	Right	<40 years	>40 years
Number	18	22	9	18	13	16	24	16	24
Percent	45%	55%	22.50%	45%	32.50%	40%	60%	40%	60%
Total	40 100%		40 100%			40 100%		40 100%	

**Table 1.** The prevalence of study participant according to sex, job, age, and affected eye

	Hyperemia	Tearing	Long discomfort	Subconjunctival hemorrhage	pigmentation
1	+	+	-	-	-
2	+	+	+	-	-
3	-	+	+	-	-
4	+	-	+	-	-
5	+	+	+	+	-
6	+	-	-	-	-

**Table 2.** Dear Authors, please add Caption

	Before injection	After injection	P Value
Average of size pterygium	2.40	1.56	P=0.00
Average of refraction	1.19	0.92	P=0.00
Average of keratometry	1.67	1.33	P=0.00

**Table 3.** Complication of MMC injection in 6 patients

## 4. Discussion

Primary pterygium is one of the most common corneal disorders in tropical countries such as India and south of Iran [4, 19]. A wide range of surgical procedures for removal of pterygia have been reported over the past decade, and several techniques are now available for the ophthalmic surgeon to choose from [4].

This study evaluated efficacy and complications of subconjunctival injection of MMC in treatment of primary pterygia. In fact, the potent effect of topical MMC on the conjunctiva epithelium has been demonstrated by its ability to prevent the recurrence of conjunctival intraepithelial neoplasia [14]. We use 0.1 ml of 0.2 mg/ml of MMC. Chen et al. [12] showed that a concentration of 0.10 mg/ml MMC inhibits fibroblast replication and that concentrations of 0.3 mg/ml actually cause death of fibroblasts.

Intraoperative use of MMC significantly retards epithelial healing in a dose-related manner in rabbit corneas [15]. In our study, 6 patients complained of irritation accompanied with mild conjunctiva swelling, hyperemia, and tearing (15%). These processes were controlled completely by using betamethasone 0.1% more frequently within one week. The pterygia were less inflamed at the 1st-month visit after MMC injection.

Recently, a new study evaluated adjunctive subconjunctival MMC (0.1 ml of 0.15 mg/ml) before pterygium excision. They reported recurrence rate of 6% with no severe complications [20, 21].

The advantage of low-dose subconjunctival MMC is that it is effective in preventing pterygium recurrence yet avoids the ocular surface toxicity associated with epithelial and bare sclera delivery of the medication. The medication is administered directly to the activated fibroblasts in the subconjunctival space, where it can work to avoid or diminish long-term epithelial healing difficulties associated with MMC. Intraoperative and postoperative MMC are two methods of adjunctive therapy that have been most commonly reported recently [22]. At the present time, we injected low dose subconjunctivally 0.1 ml of 0.2 mg/ml of MMC. Our short-term experience with MMC consistently shows no severe complications and reduces recurrence rate; these findings are similar to the study by Raiskup F et al. in 2004 [22]. Most of the complications of MMC are associated with persistent epithelial defects and ischemic sclera necrosis. Both of these complications are secondary to side effects produced by the direct action of MMC on these tissues. Because the epithelium and sclera are not target tissues for the MMC and because inadvertently treating these tissues does not contribute to the prevention of pterygia recurrence but is associated with significant side effects, the conjunctiva epithelium and sclera should be avoided. With subconjunctival application of MMC, the epithelial and sclera toxicity can be diminished; this occurred in our study. Eric D Donnenfeld et al reported that subconjunctival injection of MMC is an effective treatment before pterygium excision [23]. We chose their method but we used MMC in higher concentration (0.1 ml of 0.2 mg/ml) to reduce the size of pterygium.

In our study, the size of pterygium was reduced in 83% of cases and in all cases there were not seen progression and the amount of Astigmatism reduced (mean 0.27 diopter) in 70% cases



that were evaluated by topography and keratometry (Table 1). In research by Khakshoor H et al, they found that subconjunctival injection of MMC reduced size and recurrence rate of pterygia [24]. Our study shows similar results. Also in another study, Oguz H, in Nassau University Medical Center, East Meadow, New York, USA [25], studied 36 eyes of 36 patients prospectively that received 0.1 ml of 0.15 mg/ml MMC subconjunctivally injected into the head of the pterygium 1 month before bare sclera surgical excision. He reported: the pterygia resolved in 34 (94%) of 36 eyes, with a recurrence rate of 6% over a mean follow-up of 24.4 months. No wound-healing complication developed in any patient. Their findings are similar to our study.

Therefore, low recurrence rate and safety profile with a mean follow-up of longer than 12 months without complication show the efficacy of this treatment and compare favorably with previous studies with MMC in the treatment of pterygia.

Limitation of the study: Despite the fact that we did not observe any significant short-term complications after MMC use, we are aware that only 40 patients were available for evaluation in our study.

We feel that adjunctive use of MMC for pterygium is a safe procedure, but requires a strict selection of patients, controlled use of MMC, and long-term follow-up of these patients. In particular, a very long follow-up of the avascular conjunctival area is required.

## 5. Conclusion

Subconjunctival injection of MMC is an effective treatment, and that is a promising alternative in the management of pterygium, but long-term follow-up is required.

## Author details

Mohammad Hossien Davari<sup>1,2</sup>, Hoda Gheytsi<sup>3\*</sup> and Esmat Davari<sup>1</sup>

\*Address all correspondence to: hoda24masoud@yahoo.com

1 Ophthalmology Department Vali e Asre Hospital, Birjand University of Medical Science, Birjand, Iran

2 Atherosclerosis and Coronary Artery Research Center, Birjand University of Medical Science, Birjand, Iran

3 Josep Font Laboratory of Autoimmune Disease, IDIBAPS, Hospital Clinic, Barcelona, Spain, Spain

## References

- [1] Cameron ME. Pterygium throughout the world. St. Louis: Mosby; 1965.
- [2] Pang Y, Rose T. Rapid growth of pterygium after photorefractive keratectomy. *Optometry*. 2006; 77(10): 499-502.
- [3] Sodhi PK, Verma L, Ratan SK. The treatment of pterygium. *Surv Ophthalmol*. 2004; 49 (5): 541-542.
- [4] Panda A, Das GK, Tuli SW, Kumar A. Randomized trial of intraoperative mitomycin C in surgery for pterygium. *Am J Ophthalmol*. 1998; 125 (1): 59-63.
- [5] Wan Norliza WM, Raihan IS, Azwa JA, Ibrahim M. Scleral melting 16 years after pterygium excision with topical Mitomycin C adjuvant therapy. *Cont Lens Anterior Eye*. 2006; 29 (4):165-167.
- [6] Figueiredo RS, Cohen EJ, Gomes JA, Rapuano CJ, Laibson PR. Conjunctival autograft for pterygium surgery: how well does it prevent recurrence? *Ophthalmic Surg Lasers*. 1997; 28 (2): 99-104.
- [7] Kenyon KR, Wagoner MD, Hettinger ME. Conjunctival autograft transplantation for advanced and recurrent pterygium. *Ophthalmology*. 1985; 92 (11): 1461-1470.
- [8] Lewallen S. A randomized trial of conjunctival autografting for pterygium in the tropics. *Ophthalmology*. 1989; 96 (11): 1612-1614.
- [9] Frucht-pery J, Raiskup F, Ilsar M, Landau D, Orucov F and Solomon A. Conjunctival autografting combined with low-dose mitomycin C for prevention of primary pterygium recurrence. *Am J Ophthalmol*. 2006; 141: 1044-1050.
- [10] Gandolfi SA, Vecchi M, Braccio L. Decrease of intraocular pressure after subconjunctival injection of mitomycin in human glaucoma. *Arch Ophthalmol*. 1995; 113 (5): 582-585.
- [11] Donnenfeld ED, Perry HD, Wallerstein A, Caronia RM, Kanellopoulos AJ, Sforza PD, et al. Subconjunctival mitomycin C for the treatment of ocular cicatricial pemphigoid. *Ophthalmology*. 1999; 106 (1): 72-78.
- [12] Chen CW, Huang HT, Bair JS, Lee CC. Trabeculectomy with simultaneous topical application of mitomycin-C in refractory glaucoma. *J Ocul Pharmacol*. 1990; 6 (3): 175-182.
- [13] Salomão DR, Mathers WD, Sutphin JE, Cuevas K, Folberg R. Cytologic changes in the conjunctiva mimicking malignancy after topical mitomycin C chemotherapy. *Ophthalmology*. 1999; 106 (9):1756-1760.
- [14] Frucht-Pery J, Sugar J, Baum J, Sutphin JE, Pe'er J, Savir H, et al. Mitomycin C treatment for conjunctival-corneal intraepithelial neoplasia: a multicenter experience. *Ophthalmology*. 1997; 104 (12): 2085-2093.

- [15] Ando H, Ido T, Kawai Y, Yamamoto T, Kitazawa Y. Inhibition of corneal epithelial wound healing. A comparative study of mitomycin C and 5-fluorouracil. *Ophthalmology*. 1992; 99 (12): 1809-1814.
- [16] Rubinfeld RS, Pfister RR, Stein RM, Foster CS, Martin NF, Stoleru S, et al. Serious complications of topical mitomycin-C after pterygium surgery. *Ophthalmology*. 1992; 99 (11): 1647-1654.
- [17] Mutlu FM, Sobaci G, Tatar T, Yildirim E. A comparative study of recurrent pterygium surgery: limbal conjunctival autograft transplantation versus mitomycin C with conjunctival flap. *Ophthalmology*. 1999; 106 (4): 817-821.
- [18] Wong VA, Law FC. Use of mitomycin C with conjunctival autograft in pterygium surgery in Asian-Canadians. *Ophthalmology*. 1999; 106 (8): 1512-1515.
- [19] Zanjani H, Nikandish M, Salari AM, Heyrani Moghadam H and Dashipoor A. Efficacy and safety of subconjunctival mitomycin C and Daunorubicin in the treatment of pterygium. *Bina Ophthalmol*. 2007; 12 (3): 367-372.
- [20] Kee C, Pelzek CD, Kaufman PL. Mitomycin C suppresses aqueous human flow in cynomolgus monkeys. *Arch Ophthalmol*. 1995; 113 (2): 239-242.
- [21] Lam DS, Wong AK, Fan DS, Chew S, Kwok PS, Tso MO. Intraoperative mitomycin C to prevent recurrence of pterygium after excision: a 30-month follow-up study. *Ophthalmology*. 1998; 105 (5): 901-904
- [22] Raiskup F, Solomon A, Landau D, Ilsar M, Frucht-Pery J. Mitomycin C for pterygium: long term evaluation. *Br J Ophthalmol*. 2004; 88 (11): 1425-1428.
- [23] Donnenfeld ED, Perry HD, Fromer S, Doshi S, Solomon R, Biser S. Subconjunctival mitomycin C as adjunctive therapy before pterygium excision. *Ophthalmology*. 2003; 110 (5): 1012-1016.
- [24] Khakshoor H, Zarei S, Sharifi M, et al. Clinical result and complication of adjunctive subconjunctival mitomycin –C injection before pterygium excision. *Iran J Ophthalmol*. 2005; 18(2):70-6.
- [25] Oguz H. Mitomycin C and pterygium excision, *Ophthalmology*. 2003 Nov; 110(11): 2257-2258.