

# We are IntechOpen, the world's leading publisher of Open Access books Built by scientists, for scientists

**4,800**

Open access books available

**122,000**

International authors and editors

**135M**

Downloads

Our authors are among the

**154**

Countries delivered to

**TOP 1%**

most cited scientists

**12.2%**

Contributors from top 500 universities



**WEB OF SCIENCE™**

Selection of our books indexed in the Book Citation Index  
in Web of Science™ Core Collection (BKCI)

Interested in publishing with us?  
Contact [book.department@intechopen.com](mailto:book.department@intechopen.com)

Numbers displayed above are based on latest data collected.

For more information visit [www.intechopen.com](http://www.intechopen.com)



---

# Bacterial Endophthalmitis

---

S. Malhotra, S. Sharma, N. J. K. Bhatia, C. Hans and P. Kumar

Additional information is available at the end of the chapter

<http://dx.doi.org/10.5772/61608>

---

## Abstract

Endophthalmitis is an ocular inflammation involving vitreous cavity along with the retinal and uveal components of the eye mostly due to infectious agent. The source of infection could be exogenous or endogenous. Exogenous endophthalmitis results from direct inoculation as a complication of ocular surgery, foreign bodies or penetrating ocular trauma, while endogenous endophthalmitis results from haematogenous spread of organisms from a distant source of infection. Endophthalmitis often results in partial or complete loss of vision despite aggressive therapeutic and surgical intervention and hence it is considered as a medical emergency. Diagnosis of infectious agent is critical in the management of these agents. Intravitreal antimicrobial therapy along with anti-inflammatory agents is the key ingredient for successful management of endophthalmitis, while surgical procedures like vitrectomy become necessary in severe endophthalmitis cases. This is a brief review regarding classification, etiological agents causing endophthalmitis, diagnosis and therapeutic challenges of endophthalmitis that will help in improving the visual outcome.

**Keywords:** Bacterial endophthalmitis, diagnosis, therapeutic challenge

---

## 1. Introduction

Endophthalmitis is an ocular inflammation into the posterior segment of the eye usually involving vitreous cavity along with the retinal and uveal components of the eye [1] due to infectious agent, usually bacterial or fungal or non-infectious causes. Normally, the blood-ocular barrier prevents invasion from infective organisms, but if this is breached (directly through trauma or indirectly due to a change in its permeability secondary to inflammation), infection can occur. Endophthalmitis often results in partial or complete loss of vision despite aggressive therapeutic and surgical intervention and hence it is considered as a medical emergency [2, 3]. When inflammation spreads throughout the globe involving all the layers including the Tenon's capsule with or without involvement of the peri-ocular tissues, the

condition is known as panophthalmitis. Hence, in endophthalmitis there is involvement of all ocular tissues except the sclera while in panophthalmitis there is involvement of all ocular tissues including the sclera. Panophthalmitis is a devastating fulminant condition associated with complete loss of vision and with very poor prognosis [3].

Features	Infectious endophthalmitis	Non-infectious endophthalmitis
Symptoms	Severe vision loss with moderate to severe pain.	Vision loss is mild to moderate with mild pain.
Signs	Conjunctival congestion is seen along with hypopyon and fibrin deposits. Also vitreous opacity is prominent.	Conjunctival congestion, hypopyon and fibrin deposits are usually not seen. Vitreous opacity is usually mild.
Slit lamp examination	Retinal infiltrates and intra-retinal haemorrhages are common.	Retinal infiltrates and intra-retinal haemorrhages are very rarely seen.
Clinical course	Rapidly progressive.	Slow improvement.
Treatment	Antibiotics and surgery.	Topical and/or systemic corticosteroids.

**Table 1.** Difference between infectious and non-infectious endophthalmitis [4]

## 2. Sterile/non-infectious endophthalmitis

Sterile endophthalmitis is an acute intra-ocular inflammation of the vitreous cavity that resolves without the need of intra-vitreous antibiotics and/or vitreo-retinal surgery. In these cases if vitreous microbiological study is done, it needs to be culture negative. This condition has diverse etiologies and includes systemic auto-immune diseases, local ocular inflammations of unknown cause, endophthalmitis related to lens material and endophthalmitis attributable to intra-ocular foreign bodies.

Phacoanaphylactic endophthalmitis (lens-induced granulomatous inflammation) is a type of non-infectious endophthalmitis which represents an auto-immune response to lens protein. This is a rare consequence of lens injury which may occur after trauma causing rupturing of the lens capsule, or post surgery such as following extracapsular cataract extraction when residual lens cortex is present. There is a mixed neutrophilic and granulomatous response seen around the lens in histology [5].

Phacotoxic endophthalmitis is a condition which was previously used to cover a mixed group of conditions related to cataract surgery and intra-ocular lens implant surgery. However, since inflammation is seen mostly in the anterior segment, the term was changed to toxic anterior segment syndrome (TASS). TASS is caused due to reactions to chemicals (irrigation solutions, preservatives, drugs, denatured viscoelastics), IOL (intra-ocular lens) materials, instrument sterilization and preparation-related compounds [6,7]. TASS presents with marked decrease in vision and diffuse corneal oedema within 12–24 h of anterior segment surgery, most commonly cataract surgery and, more recently, it has been reported after phakic intra-ocular lens implantation [6,8].

Sterile endophthalmitis has also been noted following intra-ocular injection, post vitrectomy and after glaucoma drainage device implantation surgery. Intra-vitreous triamcinolone acetonide has also been associated with sterile endophthalmitis when triamcinolone crystals migrate into the anterior chamber [9]. Clinically, sterile endophthalmitis presents within 24 h of surgery, Gram stain and culture negative, involving the anterior segment in the case of TASS, and showing no response to antibiotics but improvement is seen with topical and/or oral steroids. However, it is difficult to rule out infectious etiology because some infectious cases may have rapid onset and have initial negative cultures [6].

### 3. Classification of bacterial endophthalmitis

Endophthalmitis can be categorized as exogenous and endogenous endophthalmitis. Exogenous endophthalmitis results from direct inoculation as a complication of any intra-ocular surgery (**post-operative endophthalmitis**) and/or blunt or penetrating ocular trauma (**post-traumatic endophthalmitis**). Destruction of intra-ocular tissues may be due to direct invasion by the organism and/or inflammatory mediators of the immune response. **Endogenous endophthalmitis** results from the haematogenous spread of organisms from a distant source of infection [10]. Rarely, keratitis (infection of the cornea), if left untreated, can result in corneal perforation and intra-ocular seeding of organisms leading to endophthalmitis [11]. According to British report, 59% of endophthalmitis were exogenous while 41% were endogenous in origin [12]. In comparison, another study from India suggested that 92.6% were exogenous endophthalmitis and only 7.4% were endogenous endophthalmitis [13]. There are multiple factors responsible for variation in incidence, namely, number of patients included in the study, duration of study, urban versus rural population, pre-disposing factors present, inpatient versus outpatient population and geographical areas of study.

#### 3.1. Post-operative endophthalmitis

Post-operative endophthalmitis is the most common form of endophthalmitis and it occurs most frequently following cataract surgeries like phacoemulsification and intra-ocular lens implantation. However, other procedures namely corneal surgeries (penetrating keratoplasty, keratoprosthesis insertion, refractive corneal surgeries), vitreous procedures (intra-vitreous injections, vitrectomies), glaucoma surgical treatments (blebs, glaucoma valve placements), procedures to correct retinal detachment including scleral buckling, and strabismus correction are also associated with varying risks of endophthalmitis. The organisms are generally acquired from eyelid margin and pre-ocular tear film [2,3]. Contributing factors for development of endophthalmitis include dry eye, corneal perforation, systemic immune dysfunction, previous presence of infection like bacterial conjunctivitis, cicatricial disorders (e.g. ocular cicatricial pemphigoid and Steven-Johnson), chronic use of topical antibiotics and both topical and oral corticosteroid use [11]. In various vitrectomies (Pars plana vitrectomy or 25 gauge vitrectomy), diabetes mellitus is recognized as an important risk factor for exogenous endophthalmitis [14]. Sometimes, cases of clustering of the endophthalmitis are seen, suggesting contaminated materials/solutions or problems with instrument sterilization as responsible [15,

16]. Bacterial infections are the most common cause of post-operative endophthalmitis, and Gram-positive isolates account for the majority of these cases [2]. Coagulase negative *Staphylococcus* accounts for majority of cases followed by *enterococci* and *streptococci* of viridans group. Among Gram-negative isolates, *Pseudomonas aeruginosa* endophthalmitis is identified [17, 18]. Fungal infections are less common and occur particularly in association with the use of contaminated ocular irrigation fluids [19]. *Candida* spp. (especially *C. parapsilosis*), *Aspergillus* spp. and *Fusarium* spp. are common fungal pathogens responsible for post-operative endophthalmitis [20]. *E. faecalis* is the causative agent in 4% to 8% of post-operative endophthalmitis cases and is isolated most frequently from infected filtering blebs following glaucoma surgery [10]. The visual outcome is poor and has become a key public health concern because of the emergence of antibiotic resistance to useful antibiotics including vancomycin [21].

Delayed onset infection (> 6 weeks post-operative) may occur due to sequestration of low-virulence organisms introduced at the time of surgery or to delayed inoculation of organisms [22, 23]. *S. epidermidis*, *Propionibacterium acnes*, filamentous bacteria (including *Actinomyces* and *Nocardia* sp.), *Hemophilus influenzae*, non-tuberculous mycobacteria (*M. abscessus*, *M. chelonae* etc.) and *candida* spp. are responsible for chronic or delayed endophthalmitis [24, 25]. In cases with delayed onset infection, organisms gain access to the eye through either wound abnormalities, suture tracks or filtering blebs. It is more common with glaucoma filtering surgery [26].

### 3.2. Post-traumatic endophthalmitis

Penetrating injuries are accompanied by higher infection rate of 1–17% compared to post-surgery cases [10]. The broad prevalence range is due to factors such as frequency of intra-ocular foreign bodies, distribution of trauma causes, and management strategies. Onset may be acute or delayed, but the most virulent organisms can destroy an eye within hours. Important risk factors for post-traumatic endophthalmitis are the presence of an intra-ocular foreign body (IOFB), the length of time between injury and foreign body removal, delay in closure of the globe, poorer visual acuity at presentation, virulence of organisms and the immune system of the affected individual [27]. Post-traumatic-endophthalmitis-associated isolates are mostly derived from the environment, and hence includes greater variety of organisms than those following ocular surgery. *Staphylococcus* and *Streptococcus* sp. are the most frequent pathogens, followed by *Bacillus cereus* and *P. aeruginosa* [28]. Filamentous fungi, especially *Aspergillus* sp. and *Fusarium* sp., are also responsible for post-traumatic endophthalmitis [29]. *Bacillus* infection is noteworthy as it causes rapid destruction of eye leading to decline in retinal function and vision loss within 24 to 48 h post-infection, despite aggressive treatment and/or surgical intervention. This suggests that even if the infected eye is rendered sterile by antibiotics, ocular damage continues to occur due to the bacterial toxins produced – haemolysins, lipases, enterotoxins and proteases – acting together [30].

### 3.3. Endogenous endophthalmitis

Endogenous endophthalmitis is relatively rare accounting for 2% to 8% of all endophthalmitis cases [31]. It results from the introduction of organisms into the eye as a result of haematoge-



nous spread from a remote primary site of infection [31]. Populations at greatest risk include immunocompromised patients like diabetes, HIV, organ transplant, cardiac disease and malignancy or those on immunosuppressive therapy, patients with prolonged indwelling devices and intra-venous drug abusers [32]. Endogenous endophthalmitis is more common with fungal isolates than with bacterial isolates. Most common fungal pathogens include *Candida* spp., *Aspergillus* sp. and *Fusarium* spp. *Candida albicans* remains the most important although others such as *C. glabrata*, *C. tropicalis*, *C. dubliniensis* and *C. krusei* are being increasingly detected [33]. *Aspergillus* sp. (*A. fumigatus* followed by *A. flavus*) have been reported less frequently than *Candida* sp., but *Aspergillus* endophthalmitis cause rapidly progressive retinal damage and is more visually devastating compared to *Candida* endophthalmitis [34]. Common causes of endogenous bacterial endophthalmitis include *S. aureus*, *B. cereus* and Gram-negative organisms, including *Escherichia coli*, *Neisseria meningitidis* and *Klebsiella* spp. [10]. *Bacillus* spp. is a primary cause of endogenous endophthalmitis in intra-venous drug abusers due to contaminated injections and drug solutions [10]. Rarely, protozoa like Microsporidia and Amoebae may be the pathogens for endogenous endophthalmitis [35]. It is seen that visual outcomes are poorer with endogenous fungal endophthalmitis compared to endogenous bacterial endophthalmitis. The common foci of infection may be urinary tract infection, septic arthritis, pneumonia and endocarditis [35]. Seriously ill patients may neglect eye symptoms until vision is permanently compromised. Hence, it has been recommended that ophthalmic screening should be routine in high-risk situations such as intra-venous drug use, long-term antibiotics, immunosuppressive therapy, primary or secondary immunodeficiency, prolonged central line use, debilitated patients and pre-mature infants [36].

### 3.3.1. Endophthalmitis associated with microbial keratitis

Cornea gets infected in situations like contact lens wearer, any pre-existing corneal disease and rarely due to dry cornea (as seen in chronic blepharconjunctivitis or dacrocystitis, tear film deficiency or topical steroid therapy). If corneal infection is severe enough to cause progressive ulceration of cornea, then it can lead to bacterial endophthalmitis [11].

The incidence rates [37, 38] and etiological agents of different types of endophthalmitis have been enumerated in Tables 2 and 3, respectively.

Source of infection	Causes	Incidence rate
Exogenous endophthalmitis		
1. Post-operative	Overall	0.05–0.3%
	Post-cataract surgery	0.02–0.11%
	Post-intravitreal injection	0.03–0.87%
	Post-penetrating keratoplasty	0.1–0.5%
	Post-keratoprosthesis	0–12.5%
	Glaucoma valve surgery	1.7–1.9%
	Filtering blebs	0.2–9.6%

Source of infection	Causes	Incidence rate
	Vitreotomy	0.05–0.14%
	Episcleral surgery	0.01%
	Strabismus surgery	Very rare (1 in 30,000)
1. Post-traumatic		1–17%
Endogenous endophthalmitis		2–8%

**Table 2.** Incidence rates of different types of endophthalmitis

Source of infection	Classification	Causative agents
Exogenous	<b>1. Post-operative endophthalmitis</b>	
	<b>Acute (within 6 weeks of surgery)</b>	Coagulase-negative staphylococci (Most common >60%), <i>Staphylococcus aureus</i> , viridans group streptococci, and enterococci. Gram-negative organisms like <i>Pseudomonas aeruginosa</i> [2]. Fungi like <i>Candida</i> spp. (especially <i>C. parapsilosis</i> ), <i>Aspergillus</i> spp. and <i>Fusarium</i> spp.
	<b>Delayed or chronic (after 6 weeks of surgery)</b>	<i>Propionibacterium acne</i> (most common), <i>Streptococcus</i> spp., coagulase negative staphylococci ( <i>S. epidermidis</i> ), filamentous bacteria (including <i>Actinomyces</i> and <i>Nocardia</i> sp.), <i>Hemophilus influenzae</i> , non-tuberculous mycobacteria ( <i>M. abscessus</i> , <i>M. chelonae</i> , etc.) and <i>candida</i> spp. ( <i>Candida parapsilosis</i> ).
	<b>2. Post-traumatic endophthalmitis</b>	Staphylococci (most common), <i>Bacillus cereus</i> , <i>Streptococci</i> , <i>P. aeruginosa</i> and polymicrobial infections. Filamentous fungi, especially <i>Aspergillus</i> sp. and <i>Fusarium</i> sp.
Endogenous	<b>Endogenous endophthalmitis</b>	Fungi like <i>Candida</i> spp. ( <i>Candida albicans</i> , <i>C. glabrata</i> , <i>C. tropicalis</i> , <i>C. dubliniensis</i> , <i>C. krusei</i> ), <i>Aspergillus</i> sp. ( <i>A. fumigatus</i> , <i>A. flavus</i> ) and <i>Fusarium</i> spp. Gram-positive bacteria include <i>S. aureus</i> , <i>B. cereus</i> and Gram-negative organisms, including <i>Escherichia coli</i> , <i>Neisseria meningitidis</i> and <i>Klebsiella</i> spp. Rarely, protozoa like Microsporidia and Amoeboae.

**Table 3.** Etiological agents of different types of endophthalmitis

#### 4. Clinical presentation

Clinical presentation of the disease depends on the virulence and toxin production of the infecting pathogen, the mechanism of introduction into the eye, how quickly treatment is initiated and the patient's age [10]. Symptoms of endophthalmitis range from a relatively

painless anterior chamber inflammation, such as that typically caused by *Staphylococcus epidermidis* to an indolent and protracted intra-ocular infection caused by *P. acnes*, to an explosive ocular and periorbital infection caused by *B. cereus* [10]. The clinical presentations of various endophthalmitis are depicted in Table 4.

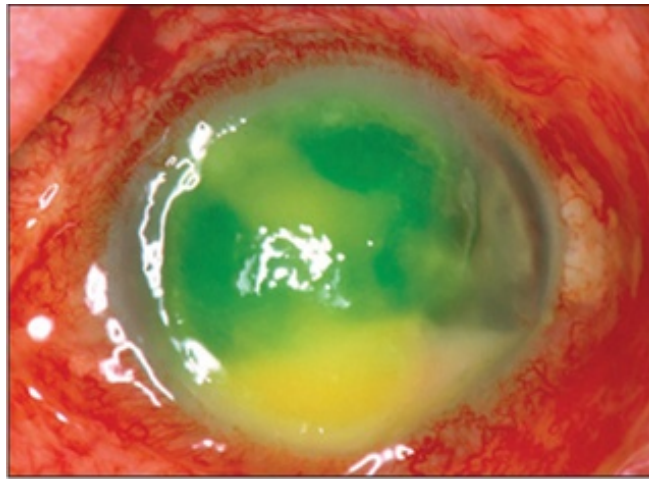
Types	Symptoms	Signs
<b>Acute post-operative endophthalmitis</b>	<ul style="list-style-type: none"> <li>• Sudden decrease of vision and increasing eye pain</li> <li>• Red eye, ocular discharge and blurring of vision [38, 39].</li> </ul>	<ul style="list-style-type: none"> <li>• Lid oedema, intense conjunctival injection and chemosis, corneal oedema, papillary fibrin membrane and hypopyon [Figures 1 and 2].</li> <li>• Severe inflammation in the anterior chamber and the vitreous [38, 39].</li> </ul>
<b>Delayed post-operative endophthalmitis</b>	<ul style="list-style-type: none"> <li>• Insidious decrease of vision and gradually increasing redness with minimal pain [40].</li> </ul>	<ul style="list-style-type: none"> <li>• Conjunctival injection, hypopyon, corneal oedema and clumps of exudates on the iris or around the pupillary margin.</li> </ul>
<b>Bleb associated endophthalmitis</b>	<ul style="list-style-type: none"> <li>• Rapidly worsening pain and vision</li> <li>• Red eye</li> </ul>	<ul style="list-style-type: none"> <li>• Marked conjunctival injection and hypopyon.</li> <li>• Bleb appears milky white with area of necrosis in the sclera (Figure 3).</li> </ul>
<b>Post-traumatic endophthalmitis</b>	Same as acute post-operative endophthalmitis, but more severe and early onset in <i>Bacillus cereus</i> infection (Figure 4).	Same as acute post-operative endophthalmitis <ul style="list-style-type: none"> <li>• Fever, proptosis and corneal oedema [38, 39].</li> </ul>
<b>Endogenous endophthalmitis</b>	<ul style="list-style-type: none"> <li>• Acutely ill immunocompromised patient presenting with decreased vision</li> </ul>	<ul style="list-style-type: none"> <li>• Lid and conjunctival oedema</li> <li>• Flame-shaped retinal haemorrhages.</li> <li>• Hypopyon, vitreous inflammatory reaction and microabscesses on the iris [39].</li> </ul>
<b>Candida endogenous endophthalmitis</b>	<ul style="list-style-type: none"> <li>• Decreased vision, floaters and pain</li> <li>• Usually bilateral and follow an indolent course</li> </ul>	<ul style="list-style-type: none"> <li>• Fluffy yellow white retinal lesions and retinal haemorrhages.</li> <li>• Hypopyon and widespread inflammation.</li> </ul>

Table 4. Clinical presentation of various endophthalmitis

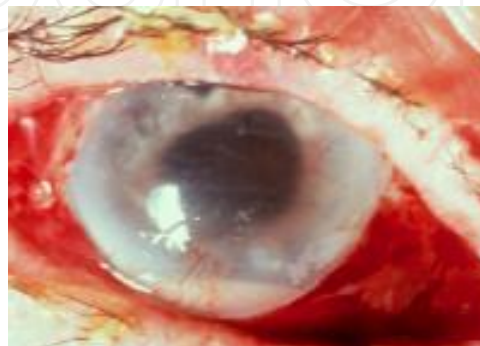

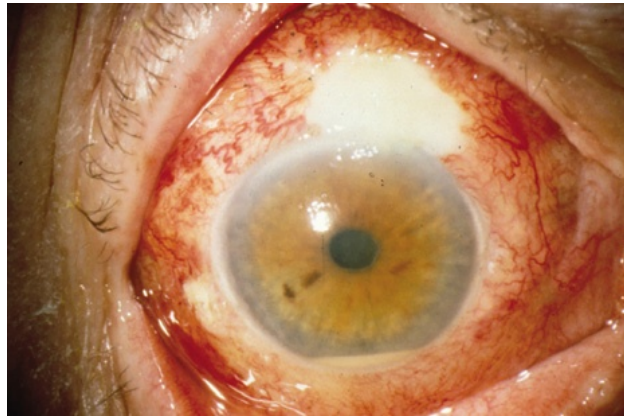Figure 1. Intense conjunctival congestion with corneal edema and hypopyon

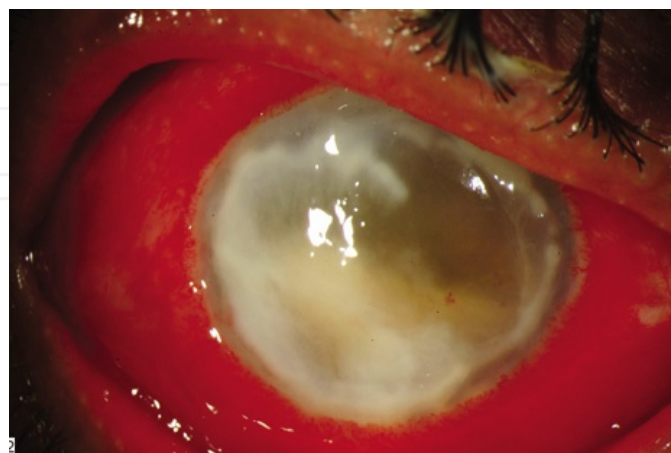




**Figure 2.** Endophthalmitis affecting the cornea



**Figure 3.** White bleb with intense conjunctival injection suggestive of bleb-associated endophthalmitis



**Figure 4.** Post-traumatic endophthalmitis caused by *Bacillus cereus* showing prominent conjunctival congestion, corneal ring infiltrate and dense hypopyon

## 5. Pathogenesis of bacterial endophthalmitis

### 5.1. Protective mechanisms in eye

#### 5.1.1. Blood–ocular fluid barrier

Under normal circumstances, the blood–ocular barrier provides a natural resistance against invading organisms and it ensures proper functioning of intra-ocular tissues and is essential for immune privilege [10]. The blood–ocular fluid barrier consists of inner and outer blood–retina barriers and the blood–aqueous humour barrier. The inner blood–retina barrier is formed by tight junctions between the endothelial cells and basement membrane of retinal capillaries and retinal pericytes, which control the blood supply for the inner retinal layers, preventing leakage of plasma constituents into the vitreous. The tight junctions between retinal pigment epithelial cells constitute the outer blood–retina barrier and control the blood supply to retinal photoreceptor cells and the choriocapillaris. The blood aqueous humour barrier is formed by the iris and ciliary epithelium and thus divides the highly perfused iris from its neighbouring compartments, the anterior chamber and the anterior vitreous [41]. Certain cytokines, such as transforming growth factor  $\beta$ ,  $\alpha$ -melanocyte stimulating hormone and vasoactive intestinal peptide, are known to have immunosuppressive property and have been detected in healthy aqueous humour [10].

#### 5.1.2. Anterior Chamber-Associated Immune Deviation (ACAID)

Ocular antigen presenting cells, namely macrophages and dendritic cells, are found in the iris and the choriocapillaris [42]. In most cases of post-operative endophthalmitis, bacteria enter the eye via the anterior chamber, where antigen presentation initially occurs and hence antigen presenting cells residing in the iris are the most likely to first encounter these pathogens. This process may be facilitated by the mild inflammatory reaction in the anterior segment, resulting from tissue manipulation of surgery. Retinal and uveal antigen presenting cells may not have access to antigen under physiological conditions but can activate during the later stages of infection, if the microbes have gained access to the posterior segment. When the defense mechanisms of immune privilege are overwhelmed, then only fulminant inflammation occurs [10].

#### 5.1.3. Invading mechanisms of organisms

Organisms causing endophthalmitis are mostly part of conjunctival flora. They adhere to IOLs and create microcolonies through biofilm formation and within biofilms they are protected from host inflammatory responses, both physically and through multiple genetic changes that alter antigenicity. Organisms in the biofilm are thus difficult to eradicate and may persist despite antibiotic treatment, resulting in relapsing endophthalmitis [43].

Various toxins and enzymes are produced and secreted by the invading organisms causing destruction of protective mechanisms in the eye in case of fulminant infection in eye. *B. cereus* produces a number of cytolysins and enzymes that could contribute to the rapid course and severity of endophthalmitis, including haemolysins, lipases, enterotoxins and proteases

[30]. *E. faecalis* strains frequently harbour conjugative plasmids that encode a cytolysin which effectively lyses both eukaryotic and prokaryotic cells [44]. Cytolysin causes destructive changes in retinal architecture and vitreal structures. Adhesin, aggregation substance, produced by enterococci is a virulence-enhancing factor and helps them to attach to membranous vitreous structures. *S. aureus* secretes cell wall-associated products and adhesions (e.g. clumping factor, fibronectin-binding protein and protein A) and extracellular virulence factors (e.g. toxins such as alpha-toxin, beta-toxin, gamma-toxin and leukocidin, proteases and lipases) which are responsible for high virulence of this organism in endophthalmitis. These virulence factors are controlled by quorum-sensing systems namely, *agr* (accessory gene regulator) and *sar* (staphylococcal accessory regulator) [45]. Hence, therapeutics designed to inactivate global regulation of *S. aureus* during the early stages of infection may be more effective in arresting tissue damage than targeting individual toxins.

## 6. Role of complement and proinflammatory cytokines in endophthalmitis

IL-1 initially mediates the acute-phase response, inducing other inflammatory mediators such as prostaglandins, phospholipase A2, collagenases and other proinflammatory cytokines (IL-6 and tumour necrosis factor alpha [TNF- $\alpha$ ]). IL-1 induces the breakdown of the blood–retina barrier and leukocyte recruitment into the intra-ocular tissue [10]. IL-6 induces production of acute phase proteins such as C-reactive protein and fibrinogen by the liver and promotes B- and T-cell differentiation [46]. In the eye, IL-6 plays a local role in negative feedback on IL-1 and TNF- $\alpha$  production. TNF- $\alpha$  also provokes an intra-ocular inflammatory reaction and acts synergistically with IL-1. IL-8 promotes the recruitment of neutrophils, and because dense neutrophil infiltration is a characteristic feature of endophthalmitis, its involvement in intra-ocular infection is probable but has not yet been determined [10].

## 7. Brief overview of pathogenesis

During bacterial growth, toxin production by virulent organisms results in loss of retinal function. Cell envelopes, fragments of peptidoglycan, and teichoic acid or lipopolysaccharides are released in intra-ocular spaces during intra-ocular growth or antibiotic killing. These components may come in contact with resident immune cells and stimulate them to produce pro-inflammatory cytokines or other immune mediators which initiate a cascade of inflammatory events, including increased permeability of the blood–ocular fluid barrier, with influx of additional soluble mediators and recruitment of phagocytic inflammatory cells to the site of infection. Inflammatory cells may in turn produce more inflammatory cytokines, in addition to toxic enzymes and reactive oxygen species. During the later stages of protracted endophthalmitis, lymphocytes migrate into inflamed intra-ocular tissues, and an immunoglobulin response results as shown in Figure 5. The ultimate result is the disruption of retinal architecture and death of non-regenerating retinal photoreceptor cells and a significant intra-ocular inflammatory response which can exacerbate the harmful effects of bacterial growth and toxin production by causing bystander damage [10].

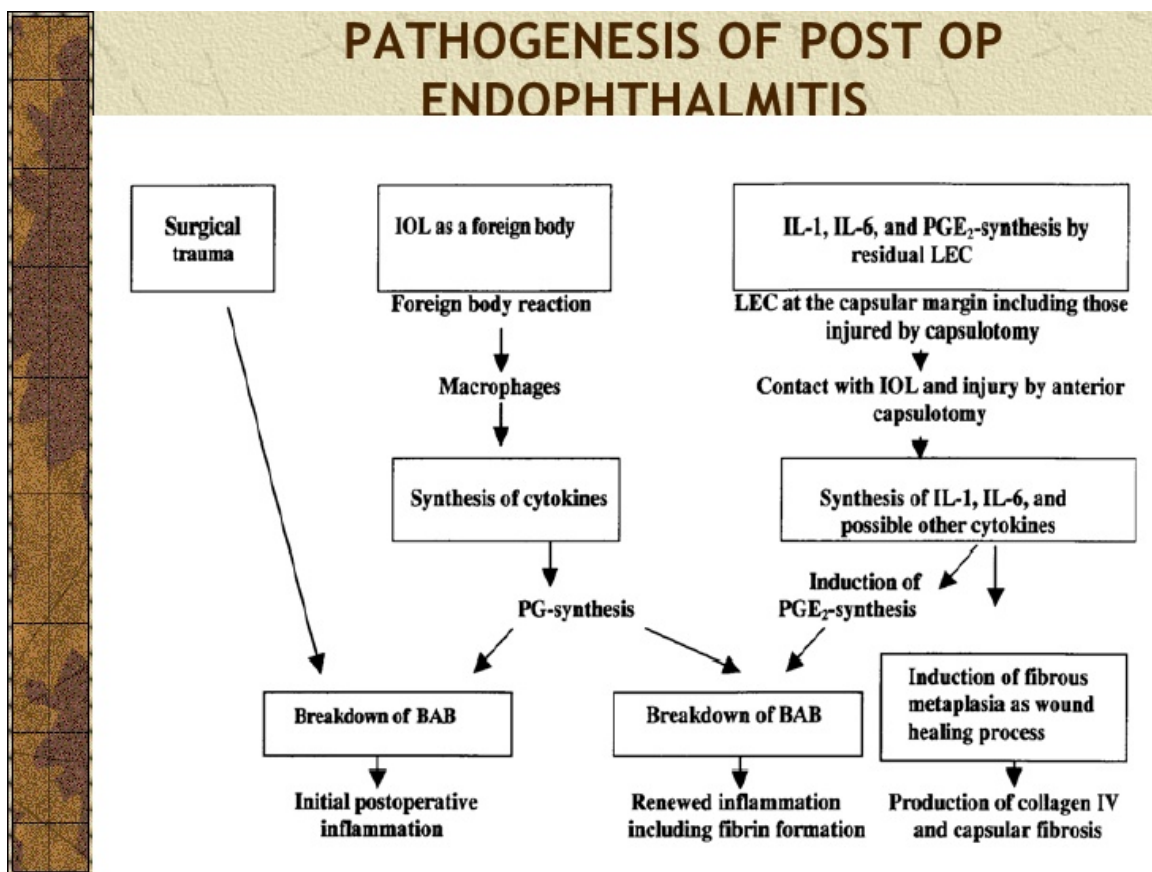


Figure 5. Brief overview of pathogenesis of bacterial endophthalmitis

## 7.1. Diagnosis of bacterial endophthalmitis

### 7.1.1. Laboratory diagnosis

The clinical diagnosis of endophthalmitis is confirmed by obtaining intra-ocular specimens like aqueous and vitreous specimen [47]. The possibility of isolating a microorganism from the vitreous specimen is 56–70%, whereas it is 36–40% from the anterior chamber (AC) humour [48]. Culture and sensitivity studies on aqueous and vitreous samples are necessary to determine the type of organism and antibiotic sensitivity.[9, 10] If endogenous bacterial endophthalmitis is suspected, a systemic workup for the source of infection is required, with cultures of blood, sputum and urine. Anterior chamber tap can be done by introducing 30-gauge needle on a tuberculin syringe to anterior chamber through limbus to obtain a 0.1 ml sample under topical anesthesia. The vitreous specimen can be obtained either by vitreous tap, vitreous biopsy or by using an automated vitrectomy instrument. In vitreous tap, a 21-gauge needle on a tuberculin syringe is used to obtain 0.1–0.2 ml of vitreous sample under sub-Tenon block. Vitreous biopsy can be taken using a 23-gauge vitrectomy cutter. Direct inoculation of the intra-ocular fluid specimen onto specific culture media is especially important when limited specimens are obtained. Specimens obtained with automated vitrectomy instruments can be processed by two methods. Vitrectomy specimen is either passed through 0.45 mm filter



paper that concentrates the microorganisms and particulate matter and filter paper is sectioned and distributed on the appropriate media or vitrectomy specimen is directly inoculated into standard blood culture bottle [49]. Specimens can be inoculated on 5% sheep blood agar for recovery of the most common bacterial and fungal isolates. Sabouraud dextrose agar is also inoculated for recovery of fungal isolates. Chocolate agar: can be used for the recovery of fastidious organisms (i.e. *Neisseria gonorrhoeae* and *Hemophilus influenzae*). Thioglycollate broth and anaerobic blood agar are useful for recovery of small numbers of aerobic or anaerobic (including *Propionibacterium acnes*) organisms from ocular fluids and tissues. Blood culture bottles contain specially prepared medium for the recovery of both aerobic and anaerobic bacteria and fungi and it can be directly inoculated by intra-ocular fluids. Immunologic and molecular genetic technologies enable rapid and specific identification of infectious agents. In culture negative cases, the additional use of polymerase chain reaction was reported to aid in the identification of the organism [49]. These real-time techniques have been used in both clinical and experimental settings, and their future use in this area appears promising [50, 51].

In the Endophthalmitis Vitrectomy Study (EVS), Gram stain result did not reveal any subgroups in which vitrectomy had a beneficial value and therefore is not useful in making initial therapeutic decisions [26]. Also in EVS, there was no difference in the culture positivity rate and operative complications between samples obtained by tap and those obtained by vitrectomy [52].

### 7.1.2. Imaging studies

In B-scan ultrasound of the posterior pole, choroidal thickening and ultrasound echoes in the vitreous support the diagnosis of endophthalmitis. Retained lens material and associated retinal detachment are also visible. The ultrasound also provides a baseline prior to intra-ocular intervention and allows assessment of the posterior vitreous face and areas of possible traction [53]. In traumatic cases, a CT scan can be performed, which may show thickening of the sclera and uveal tissues associated with various degrees of increased density in the vitreous and peri-ocular soft tissue structures. In endogenous cases, imaging modalities like two-dimensional echocardiography and chest x-ray can be done to rule out potential sources of infection.

## 8. Prevention of endophthalmitis

The most effective therapy for endophthalmitis is prevention. Sterile technique during any type of ocular surgery is important. All instruments for surgery should be thoroughly sterilized with autoclaving; tubing is preferably sterilized with ethylene oxide gas sterilizer. BSS (balanced salt solution) bottles should never be kept or used for more than one operating session. Proper preparation before any intra-ocular surgery including peri-ocular and ocular surface (cul-de-sac) sterilization with povidone iodine 5% applied for 3 min is the best means for prevention of endophthalmitis (superior to topical antibiotics) [54]. In allergic patients, 0.05% chlorhexidine can be used. Large bottles of diluted povidone iodine or chlorhexidine should be avoided and single-use vials be used as they get contaminated with *P. aeruginosa*. A

prophylactic antibiotic like topical 0.5% levofloxacin or ofloxacin one drop 1 h and one drop 30 min before surgery and three drops at 5 min intervals immediately following surgery is effective in reducing the rate of post-operative endophthalmitis according to the European Society of Cataract and Refractive Surgery (ESCRS) study [55]. Topical antibiotic should be continued four times a day for two weeks post-operatively. The use of antibiotics in the irrigation and infusion fluid is also an option. In addition, washing the surgical gloves whether containing talc or not, after wearing them in sterile saline and washing any surgical instrument before introducing it into the eye and avoiding touching any non-sterile place including the body surface with anything. Biodegradable scleral plugs impregnated with antibiotics, antiviral and anti-inflammatory drugs have been tested for drug release *in vitro*. Scleral plugs containing vancomycin, amikacin and dexamethasone have been used for slow delivery of drugs in the vitreal cavity at a concentration well above MIC (minimum inhibitory concentration) for a period of time needed to treat bacterial endophthalmitis in place of repeated vitreal injections [56, 57]. All patients with ocular penetration injuries should be treated with IV broad-spectrum antibiotics for 3 days. The common regimen is cefazolin 1 g tds and gentamycin 80 mg BD. If injury is through contaminated object, vancomycin 1 g bd (in slow infusion to prevent “red man” syndrome) should substitute cefazolin. In patients allergic to penicillins or cephalosporins, moxifloxacin 400 mg once a day may be used.

### 8.1. Treatment strategy for endophthalmitis

Endophthalmitis is an ocular emergency, and urgent treatment is required to reduce the potential of significant visual loss. Microbial endophthalmitis is a therapeutic challenge due to delicate anatomy and physiology of ocular tissues. Retina has a rich blood supply, but the vitreous and anterior chambers are avascular and are isolated from systemic circulation via blood–ocular fluid barrier [4]. These features represent a barrier for the delivery of cellular and humoral mediators of host immunity and also antimicrobial or anti-inflammatory agents administered systemically. This leaves clinicians with few treatment options like injecting drug directly into intra-ocular space, but there is a risk of vitreous or sub-retinal haemorrhaging, retinal toxicity, corneal abrasions, central artery occlusion, uveitis or lens opacification [58]. Also, retinal photoreceptor cells are highly sensitive not only to the offending pathogen and the resulting inflammatory response but also to antimicrobial agents administered locally to treat the infection [59].

### 8.2. Antimicrobial agents and anti-inflammatory agents

Outcome of endophthalmitis management depends on several factors, including the responsible pathogen, the patient’s age, the duration between injury and treatment, the therapy chosen and the condition of the eye upon presentation [60]. Delay in therapy results in poor visual outcome, especially in severe cases of endophthalmitis. Bacterial endophthalmitis is treated with repeated injection of antibiotics into the vitreous concurrently with systemic antibiotics, although some potentially effective antibiotics like vancomycin and aminoglycosides do not penetrate readily into the vitreous, due to the protective effect of the blood–ocular fluid barrier; however, intra-ocular inflammation increases the permeability of the blood–



ocular fluid barrier, enhancing penetration of systemic antibiotics into the vitreous cavity [61]. Another reason for poor systemic antibiotic effect in endophthalmitis is poor penetration through the blood flow because of the inflammation and necrosis of blood vessels. Because of variable penetration into the vitreous cavity of aminoglycosides, vancomycin and cephalosporins, the EVS evaluated their clinical efficacy in a post-cataract surgery endophthalmitis controlled trial and found that systemic antibiotics did not enhance visual outcomes in these patients. However, this recommendation does not hold true following other types of ocular surgery, trauma or suspected endogenous endophthalmitis [62]. Systemic antibiotics are important for therapeutic management of endogenous endophthalmitis where there is concomitant bacteremia, while intravitreal antibiotic is a key component for clinical management of exogenous bacterial endophthalmitis. Fluoroquinolones are currently used by many clinicians in combination with intravitreal antibiotics like vancomycin, amikacin and ceftazidime for severe endophthalmitis cases. The two drug regimens commonly used by clinicians include vancomycin (1 mg/0.1 ml) to cover Gram-positive organisms and a third-generation cephalosporin (ceftazidime 2 mg /0.1 ml) or amikacin (0.4 mg/0.1 ml) to cover Gram-negative organisms [63]. Repeated intravitreal injections of antibiotics may be necessary if there is no response to the initial therapy.

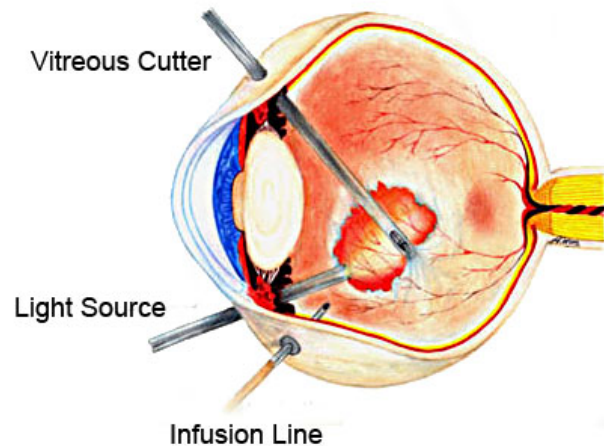
Fungal endophthalmitis carries a poor prognosis and there is no standard management available for treating this condition. In fungal endophthalmitis cases, systemic antifungal agents namely amphotericin with or without flucytosine or fluconazole are used. In fluconazole-resistant strains voriconazole may be helpful; however, information on new antifungal agents for endophthalmitis is limited. It is seen that chorioretinitis infections can be more readily cured with systemic antifungal agents, whereas more aggressive treatment including pars plana vitrectomy with intravitreal amphotericin (5–10mg/0.1mL) or voriconazole and systemic antifungal is required for patients with vitritis. Topical antifungal agents (natamycin 5%) are also included, especially in cases of corneal involvement [64].

The use of corticosteroids is controversial. In endophthalmitis, ocular inflammation is induced by growing bacteria and also due to breakdown of cell wall or other components due to use of antibiotics. This overt inflammatory response can damage sensitive neurologic tissues. They should not be administered without proper coverage of all infective microorganisms and when the infection is not controlled. Intravitreal dexamethosone in the concentration of 400 microgram in 0.1 ml has been used, but is contraindicated in fungal endophthalmitis [65].

### **8.3. Pars plana vitrectomy**

Although intravitreal antibiotic therapy can provide effective bacterial killing during endophthalmitis, vitrectomy is an appealing adjunct to management. Vitrectomy (surgical cutting and aspiration of vitreous contents and replacement with balanced salt solution) (Figure 6) debrides the vitreous cavity of bacteria, inflammatory cells and other toxic debris; promotes better diffusion of antibiotics; helps in obtaining adequate sampling for microanalysis and helps in speedy recovery of vision [66, 67]. Timing of vitrectomy is controversial, and investigators advocate aggressive early treatment with early vitrectomy in suspected bacterial metastatic endophthalmitis, and more conservative approach in suspected fungal cases. Also,

3 port pars plana 23 or 25 gauge complete vitrectomy is preferred over core vitrectomy. However, in an inflamed eye certain complications like retinal detachment, hypotony and phthisis bulbi can occur. The definite indications for vitrectomy include worsening of signs and symptoms, rapid progression, infections uncontrolled by systemic and /or intravitreal antibiotics, retinal necrosis, extensive subretinal abscess, retinal detachment and intra-ocular foreign body [65].



**Figure 6.** showing Cutting and aspiration of vitreous contents in pars plana vitrectomy

## 9. Conclusion

Endophthalmitis may cause severe visual loss and detailed understanding of the offending organisms and the intra-ocular host response and its early recognition is necessary for effective treatment of endophthalmitis and improving visual outcome. The key to successful therapy for endophthalmitis is rapid sterilization of the posterior segment by antibiotics and arrest of potentially harmful inflammation, while concurrently limiting risks associated with penetration of the eye by injections or surgery.

## Author details

S. Malhotra\*, S. Sharma, N. J. K. Bhatia, C. Hans and P. Kumar

\*Address all correspondence to: drshalinimalhotra@yahoo.com

Department of Microbiology, Dr. Ram Manohar Lohia Hospital and PGIMER, New Delhi, India

## References

- [1] Peyman G, Lee P, Seal DV. Endophthalmitis: Diagnosis and Management. Taylor & Francis, London & New York: 2004, pp. 1–278.
- [2] Kresloff MS, Castellarin AA, Zarbin MA. Endophthalmitis. *Surv Ophthalmol* 1998;43:193–224.
- [3] Kernt M, Kampik A. Endophthalmitis: pathogenesis, clinical presentation, management, and perspective. *Clin Ophthalmol* 2010;4:121–35.
- [4] Moshfeghi A, Rosenfeld PJ, Flynn HW Jr, et al. Endophthalmitis after intravitreal anti-vascular endothelial growth factor antagonists: a six-year experience at a university referral center. *Retina* 2011;31:662–8.
- [5] Marak Jr GE. Phacoanaphylactic endophthalmitis. Erratum in: *Surv Ophthalmol* 1992;36:454.
- [6] Mamalis N, Edelhauser HF, Dawson DG, Chew J, LeBoyer RM, Werner L. Toxic anterior segment syndrome. *J Cataract Refract Surg* 2006;32:324–33.
- [7] Holland SP, Morck DW, Lee TL. Update on toxic anterior segment syndrome. *Curr Opin Ophthalmol* 2007;18:4–8.
- [8] Carolee M, Cutler P, Jacob B, Sue C, Chris D, Henry EE, Nick M. Toxic anterior segment syndrome: Common causes *J Cataract Refractive Surg* July 2010;36(7):1073–80.
- [9] Stepien KE, Eaton AM, Jaffe GJ, Davis JL, Raja J, Feuer W. Increased incidence of sterile endophthalmitis after intravitreal triamcinolone acetonide in Spring 2006. *Retina* 2009;29:207–13.
- [10] Callegan MC, Engelbert M, Parke DW, Jett BD, Gilmore MS. Bacterial endophthalmitis: epidemiology, therapeutics, and bacterium-host interactions. *Clin Microbiol Rev* 2002;15:111–24.
- [11] Scott IU, Flynn HW, Feuer W, Pflugfelder SC, Alfonso EC, Forster RC, Miller D. Endophthalmitis associated with microbial keratitis. *Ophthalmology* 1996;103:1864–70.
- [12] Krause L, Bechrakis N, Heimann H, Kildal D, Foerster M. Incidence and outcome of endophthalmitis over a 13-year period. *Can J Ophthalmol* 2009;44:88–94.
- [13] Ramakrishnan R, Bharathi M, Shivkumar C, et al. Microbiological profile of culture-proven cases of exogenous and endogenous endophthalmitis: a ten-year retrospective study. *Eye (Lond)* 2009;23:945–56.
- [14] Bahrani HM, Fazelat AA, Thomas M, et al. Endophthalmitis in the era of small gauge transconjunctival sutureless vitrectomy – meta analysis and review of the literature. *Semi Ophthalmol* 2010;25:275–82.

- [15] Akçakaya AA, Sargin F, Erbil HH, et al. A cluster of acute-onset postoperative endophthalmitis over a 1-month period: investigation of an outbreak caused by an uncommon species. *Br J Ophthalmol* 2011;95:481–4.
- [16] Korah S, Braganza A, Jacob P, Balaji V. An “epidemic” of post cataract surgery endophthalmitis by a new organism. *Indian J Ophthalmol* 2007;55:464–6.
- [17] Jamulingam M, Parameswaran SK, Lysa S, Selvaraj M, Madhavan HN. A study on the incidence, microbiological analysis and investigations on the source of infection of postoperative infectious endophthalmitis in a tertiary care ophthalmic hospital: an 8-year study. *Indian J Ophthalmol* 2010;58:297–302.
- [18] Anand AR, Therese KL, Madhavan HN. Spectrum of aetiological agents of postoperative endophthalmitis and antibiotic susceptibility of bacterial isolates. *Indian J Ophthalmol* 2000;48:123–8.
- [19] Peponis V, Rosenberg P, Chalkiadakis SE, Insler M, Amariotakis A. Fungal scleral keratitis and endophthalmitis following pterygium excision. *Eur J Ophthalmol*. 2009;19:478–80.
- [20] Narang S, Gupta A, Gupta V, et al. Fungal endophthalmitis following cataract surgery: clinical presentation, microbiological spectrum, and outcome. *Am J Ophthalmol* 2001;132:609–17.
- [21] Huycke MM, Sahm DF, Gilmore MS. Multiple-drug resistant enterococci: the nature of the problem and an agenda for the future. *Emerg Infect Dis* 1998;4:239–49.
- [22] Forster RK. Etiology and diagnosis of bacterial postoperative endophthalmitis. *Ophthalmology* Apr 1978;85(4):320–6.
- [23] Arshinoff SA, Bastianelli PA. Incidence of postoperative endophthalmitis after immediate sequential bilateral cataract surgery. *J Cataract Refract Surg* Dec 2011;37(12):2105–14.
- [24] Adán A, Casaroli-Marano RP, Gris O, et al. Pathological findings in the lens capsules and intraocular lens in chronic pseudophakic endophthalmitis: an electron microscopy study. *Eye (Lond)* 2008;22:113–9.
- [25] Al-Mezaine HS, Al-Assiri A, Al-Rajhi AA. Incidence, clinical features, causative organisms, and visual outcomes of delayed-onset pseudophakic endophthalmitis. *Eur J Ophthalmol* 2009;19:804–11.
- [26] Soltau JB, Rothman RF, Budenz DL, Greenfield DS, Feuer W, Liebmann JM, Ritch R. Risk factors for glaucoma filtering bleb infections. *Arch. Ophthalmol* 2000;118:338–42.
- [27] Andreoli CM, Andreoli MT, Kloek CE, Ahuero AE, Vavvas D, Durand ML. Low rate of endophthalmitis in a large series of open globe injuries. *Am J Ophthalmol* 2009;147:601–8.

- [28] Vedantham V, Nirmalan PK, Ramasamy K, Prakash K, Namperumalsamy P. Clinico-microbiological profile and visual outcomes of post-traumatic endophthalmitis at a tertiary eye care centre in South India. *Indian J Ophthalmol* 2006;54:5–10.
- [29] Gupta A, Srinivasan R, Kaliaperumal S, Saha I. Post-traumatic fungal endophthalmitis—a prospective study. *Eye (Lond)* 2008;22:13–7.
- [30] Callegan MC, Kane ST, Cochran DC, et al. *Bacillus* endophthalmitis: roles of bacterial toxins and motility during infection. *Invest Ophthalmol Vis Sci* 2005;46:3233–8.
- [31] Romero CF, Rai MK, Lowder CY, and Adal KA. Endogenous endophthalmitis: case report and brief review. *Am Fam Phys* 1999;60:510–14.
- [32] Binder MI, Chua J, Kaiser PK, et al. Endogenous endophthalmitis: an 18-year review of culture- positive cases at a tertiary care center. *Medicine* 2003;82:97–105.
- [33] Ruhnke M, Rickerts V, Cornely OA, et al. Diagnosis and therapy of candida infections: joint recommendations of the German Speaking Mycological Society and the Paul-Ehrlich-Society for Chemotherapy. *Mycoses* 2011;54:279–310.
- [34] Lamaris GA, Esmaeli B, Chamilos G, et al. Fungal endophthalmitis in a tertiary care cancer center: a review of 23 cases. *Eur J Clin Microbiol Infect Dis* 2008;27:343–7.
- [35] Safneck JR. Endophthalmitis: a review of recent trends. *Saudi J Ophthalmol* 2012;26:181–9.
- [36] Khan A, Okhravi N, Lightman S. The eye in systemic sepsis. *Clin Med* 2002;2:444–8.
- [37] Lundstrom M, Wejde G, Stenevi U, et al. Endophthalmitis after cataract surgery: a nationwide prospective study evaluating incidence in relation to incision type and location. *Ophthalmology* 2007;114:866–70.
- [38] Behndig A, Montan P, Stenevi U, et al. One million cataract surgeries: Swedish National Cataract Register 1992–2009. *J Cat Refract Surg* 2011;37:1539–45.
- [39] Al-Mezaine HS, Kangave D, Al-Assiri A, Al-Rajhi AA. Acute-onset nosocomial endophthalmitis after cataract surgery: incidence, clinical features, causative organisms, and visual outcomes. *Cataract Refract Surg* 2009;35:643–9.
- [40] Al-Mezaine HS, Al-Assiri A, Al-Rajhi AA. Incidence, clinical features, causative organisms, and visual outcomes of delayed-onset pseudophakic endophthalmitis. *Eur J Ophthalmol* 2009;19:804–11.
- [41] Chaudhry IA, Shamsi FA, Elzaridi E, Al-Rashed W. Al-Amri AM, Al-Anezi F, Arat YO, Holck DEE. Outcome of treated orbital cellulitis from a tertiary eye care center in the Middle East. *Ophthalmology* 2007;114:345–54.
- [42] Cunha-Vaz JG. The blood-ocular barriers: past, present, and future. *Doc Ophthalmol* 1997;93:149–57.



- [43] Steptoe RJ, Holt PG, McMenamin PG. Functional studies of major histocompatibility class II-positive dendritic cells and resident tissue macrophages isolated from the rat iris. *Immunology* 1995;85:630–7.
- [44] Miller KV, Easley KM, Shanks RM, et al. Recurrent enterococcal endophthalmitis seeded by an intraocular lens biofilm. *J Cataract Refract Surg* 2011;37:1355–9.
- [45] Gilmore MS, Callegan MC, Jett BD. Enterococcus faecalis cytolysin and Bacillus cereus bi- and tri-component toxins. In: Alouf JE, Freer JH. (Eds.) *The Comprehensive Sourcebook of Bacterial Protein Toxins*, 2nd edn. Academic Press, London, United Kingdom 1999, pp. 419–434.
- [46] Projan SJ, Novick RP. The molecular basis of pathogenicity. In: Crossley KB, Archer GL. (Eds.) *The Staphylococci in Human Disease*. Churchill Livingstone, New York, NY, 1999, pp. 55–82.
- [47] Van Snick J. Interleukin-6: an overview. *Annu Rev Immunol* 1990;8:252–78.
- [48] Donahue SP, Kowalski RP, Jewart BH, et al. Vitreous cultures in suspected endophthalmitis: biopsy or vitrectomy? *Ophthalmology* 1993;100:452.
- [49] Spadea L, Fiasca A. Treatment of post-operative endophthalmitis. *Eur Ophthal Rev* 2012;6(3):149–56.
- [50] Joondeph BC, Flynn HW Jr, Miller D, et al. A new culture method for infectious endophthalmitis. *Arch Ophthalmol* 1989;107:1334.
- [51] Dworkin LL, Gibler TM, Van Gelder RN: Real-time quantitative polymerase chain reaction diagnosis of infectious posterior uveitis. *Arch Ophthalmol* 2002;120:1534–9.
- [52] Wittwer CT, Kuskawa N: Real-time PCR. In: Persing DH. (Ed.) *Molecular Microbiology: Diagnostic Principles and Practice*. Washington, DC: ASM Press, 2004, pp. 71–84.
- [53] Results of the Endophthalmitis Vitrectomy Study. A randomized trial of immediate vitrectomy and of intravenous antibiotics for the treatment of postoperative bacterial endophthalmitis. Endophthalmitis Vitrectomy Study Group, *Arch Ophthalmol* 1995;113:1479–96.
- [54] Chan IM, Jalkh AE, Trempe CL, Tolentino FI. Ultrasonographic findings in endophthalmitis. *Ann Ophthalmol* Aug 1984;16(8):778–84.
- [55] Alp BN, Elibol O, Sargon MF, et al. The effect of povidone iodine on the corneal endothelium. *Cornea* 2000;19:546–50.
- [56] ESCRS Endophthalmitis Study Group: Prophylaxis of postoperative endophthalmitis following cataract surgery: results of the ESCRS multi-centre study and identification of risk factors. *J Cataract Refract Surg* 2007;33:978–88.



- [57] Liu SJ, Kau YC, Liaw CW, Peng YJ. In vitro elution of vancomycin/amikacin/ steroid from solvent-free biodegradable scleral plugs. *Int J Pharm* 2009;370:75–80.
- [58] Peng YJ, Kau YC, Wen CW, Liu SJ. Solvent-free biodegradable scleral plugs providing sustained release of vancomycin, amikacin, and dexamethasone—an *in vivo* study. *J Biomed Mater Res Part A* 2010;94:426–32.
- [59] Nelson ML, Tennant MTS, Sivalingam A, et al. Infectious and presumed noninfectious endophthalmitis after intravitreal triamcinolone acetonide injection. *Retina* 2003;23:686–91.
- [60] Wiechens B, Neumann D, Grammer JB, Pleyer U, Hedderich J, Duncker GI. Retinal toxicity of liposome-incorporated and free ofloxacin after intravitreal injection in rabbit eyes. *Int Ophthalmol* 1998–1999;22:133–43.
- [61] Foster RE, Martinez JA, Murray TG, Rubsamens PE, Flynn HW, Forster RK. Useful visual outcomes after treatment of *Bacillus cereus* endophthalmitis. *Ophthalmology* 1996;103:390–7.
- [62] Ferencz JR, Assia EI, Diamantstein L, Rubinstein E. Vancomycin concentration in the vitreous after intravenous and intravitreal administration for postoperative endophthalmitis. *Arch Ophthalmol* 1999;117:1023–7.
- [63] Ferencz JR, Assia EI, Diamantstein L, Rubinstein E. Vancomycin concentration in the vitreous after intravenous and intravitreal administration for postoperative endophthalmitis. *Arch Ophthalmol* 1999;117:1023–7.
- [64] Recchia FM, Busbee BG, Pearlman RB, Carvalho-Recchia CA, Ho AC. Changing trends in the microbiologic aspects of postcataract endophthalmitis. *Arch Ophthalmol* 2005;123:341–6.
- [65] Lamarin GA, Esmali B, Chamilos G, et al. Fungal endophthalmitis in a tertiary care cancer center: a review of 23 cases. *Eur J Clin Microbiol Infect Dis* 2008;27:343–7.
- [66] Mathews AS, Pillai GS, Natasha R, Shetty M. Endogenous endophthalmitis – a review. *Kerala J Ophthalmol* 2011;23:25–31.
- [67] Fujii GY, De Juan E Jr, Humayun MS, et al. Initial experience using the transconjunctival sutureless vitrectomy system for vitreoretinal surgery. *Ophthalmol* 2002;109:1814–20.
- [68] Fine HF, Iranmanesh R, Iturralde D, Spaid RF. Outcomes of 77 consecutive cases of 23-gauge transconjunctival vitrectomy surgery for posterior segment disease. *Ophthalmol* 2007; 114:1197–200.