

We are IntechOpen, the world's leading publisher of Open Access books Built by scientists, for scientists

4,800

Open access books available

122,000

International authors and editors

135M

Downloads

Our authors are among the

154

Countries delivered to

TOP 1%

most cited scientists

12.2%

Contributors from top 500 universities



WEB OF SCIENCE™

Selection of our books indexed in the Book Citation Index
in Web of Science™ Core Collection (BKCI)

Interested in publishing with us?
Contact book.department@intechopen.com

Numbers displayed above are based on latest data collected.

For more information visit www.intechopen.com



Retroperitoneal and Retrograde Total Laparoscopic Hysterectomy – Technique with Three- and Five-millimeter Trocars

Eugenio Volpi, Elisa Peano, Giulia Moggio, Anna Silvia Pertusio, Paola Ballario and Luca Bernardini

Additional information is available at the end of the chapter

<http://dx.doi.org/10.5772/61649>

Abstract

In this chapter, we describe total laparoscopic hysterectomy (TLH) using retroperitoneal and retrograde technique: it combines the retroperitoneal coagulation of the uterine artery and the retrograde approach to the pelvic organs, as in oncological surgeries. We report our experience in applying this modified TLH with 3-mm instruments and without uterine manipulator, in order to demonstrate its safety and feasibility.

Keywords: Laparoscopy, Hysterectomy, Retroperitoneal hysterectomy, Retrograde

1. Introduction

Mini-invasive approaches have successfully been applied to an increasing number of gynecological procedures. Robotics represents now the state of the art in mini-invasive surgeries, especially in the USA, where it is available in many referral centers [1]. In Europe, laparoscopy is much more widely distributed: total laparoscopic hysterectomy (TLH) is, at present, the main alternative to abdominal hysterectomy (TAH) [2]. TLH is associated with less blood loss, shorter hospital stay, and low rate of infection and ileus in comparison to laparotomy. Patients can avoid painful abdominal incision and return more quickly to their activities [3].

Nowadays, the most diffuse technique for TLH involves intrafascial dissection of vascular pedicles and the use of a manipulator for the mobilization of the uterus and the cervix, as

described by the French and Finnish schools [2–5]. According to these authors, the transection of the uterine vessels is performed close to the uterus, medially to the ureter, as in conventional TAH. However, endometriosis, intra-ligamentary fibroids, previous pelvic infections and other anatomical variations could make coagulation or dessication of the ascending and descending branches difficult. Moreover, when coagulation is extensively performed, there is an increased risk of ureteral lesions [6–8]. In this chapter, we describe a modified technique of retroperitoneal (dissection of the uterine arteries) and retrograde (dissection of the bladder and vagina) TLH, with the aim to provide optimal control of the ureter and bleeding. The retroperitoneal laparoscopic approach was originally described by Kohler et al. [9] and Roman et al. [10]; the retrograde culdotomy was reported in the 190s by Delle Piane [11], Hudson and Chir [12], and more recently by Bristow et al. [13].

2. Technique

We described the technique of retroperitoneal and retrograde TLH in a previous paper [14]. Hereby, we report the critical steps of the procedure:

1. Patients are positioned in a dorsal lithotomy with legs apart and semi-flexed and the arms tucked at the sides. The monitor is placed between the patient legs or on her left foot if morcellation is foreseen, facing the two surgeons to facilitate an ergonomic working position. The equipment used is simple: a scissor, two grasping forceps, a washing-aspiration 5-mm device, and a 5-mm bipolar coagulation forceps. Recently, the LigaSure™ 5-mm 37-cm (Covidien LF1537) forceps was added to the instrumentation, avoiding the use of disposable scissors. No uterine manipulator is placed in situ.

We usually access the peritoneum by direct trocar insertion [15]. Only patients with story of surgeries are accessed via Palmer point and Verress needle. Five millimeter optics are used. Three 5-mm trocars are placed in the lower abdomen under direct vision, in the usual diamond-shaped position. Variations may be due to the uterine size: if the uterus has a size less than 13 weeks of pregnancy, the procedure can be started with two mini-laparoscopic trocars on the sides, keeping the umbilical and the suprapubic trocar of 5 mm. Only 3-mm grasping forceps and a 3-mm needle holder are used through the side ports.

The first surgical step is isolation of the ureter and of the uterine artery. The assistant surgeon moves medially the utero-ovarian ligament to stretch the broad ligament. The incision is made up to where the broad ligament overlies the iliac vessels, thus allowing to enter into the retroperitoneum. The peritoneum is opened parallel to the infundibulo-pelvic ligament above the crossing, with the external iliac artery taking care to move the ureter on the medial sheet of the peritoneum (Figure 1).

The ureter is then followed till the crossing with the uterine artery. After dissection, the uterine artery is coagulated at its origin from the internal iliac artery (Figure 2).

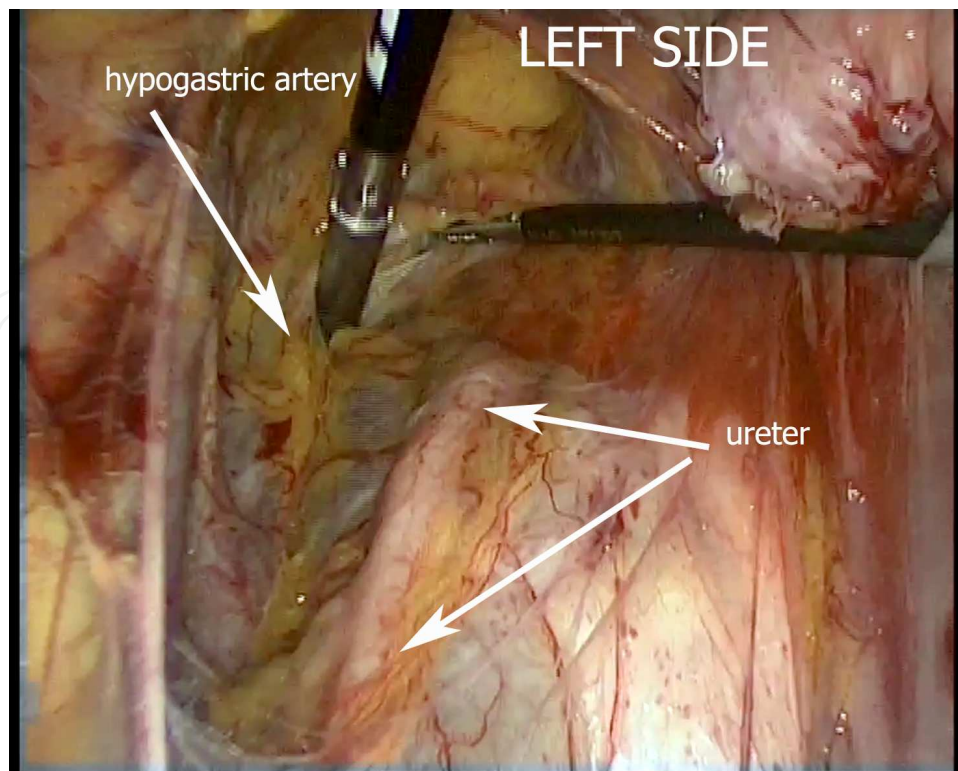


Figure 1. Access to retroperitoneum: the peritoneum is opened parallel to the infundibulo-pelvic ligament; the ureter is identified and followed till uterine artery.

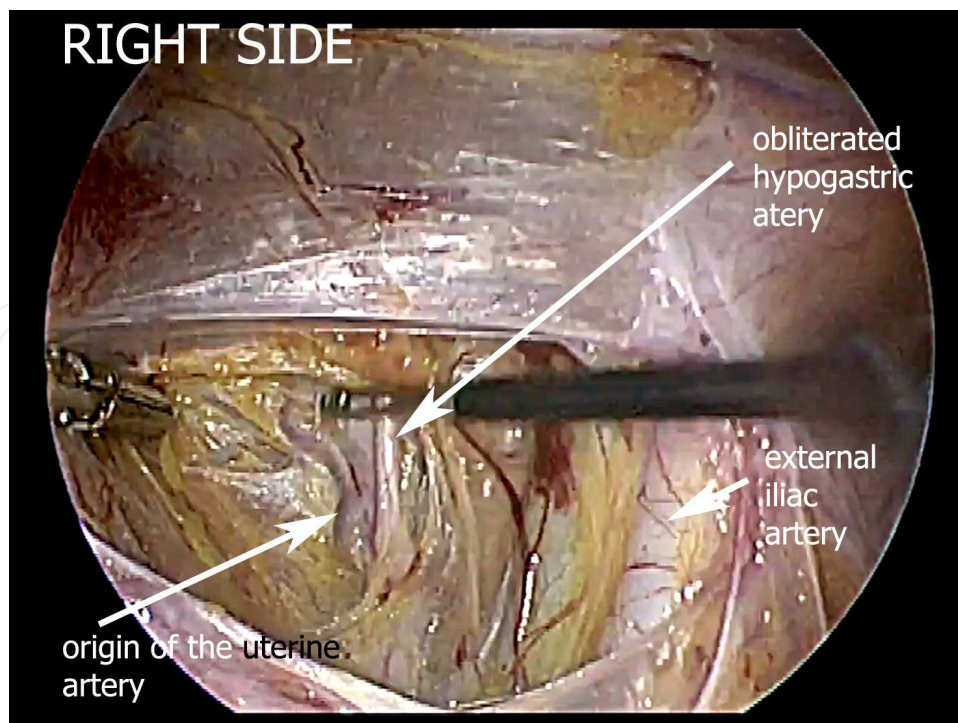


Figure 2. Identification and coagulation of uterine artery at its origin from the internal iliac artery.

We often grasp and coagulate the uterine veins altogether but do not transect the vessels (Figure 3). Since the infundibulo-pelvic ligament is not divided, any bowel interference during the operation is avoided by pulling medially the medial leaf. The same steps are repeated contralaterally.

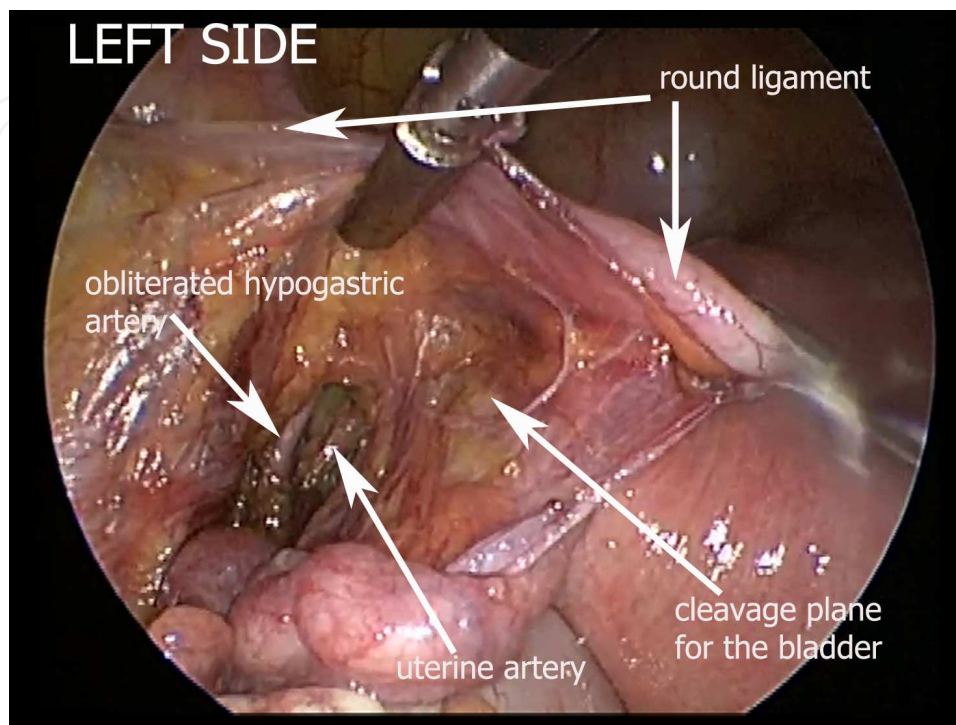


Figure 3. Uterine artery is coagulated but not transected.

2. The round ligament may or may not be divided at this time at the cross with the umbilical artery. Blunt dissection on the vesico-vaginal fascia is performed from the lateral to medial side (Figure 4). The vesico-uterine peritoneal fold is left aside and dissection initiated just distally to the uterine arteries following the pelvic fascia. Dissection is stopped when the white vaginal fornix is reached. At this point, the transection of the round ligament is completed by dividing all the anterior leaf down to the vesico-uterine peritoneal fold, in order to mobilize the bladder from connections to the lower uterine segment. The infundibulo-pelvic or the utero-ovarian ligaments are coagulated and transected after fenestration of the broad ligament with the ureter under control. This approach is important in patients who had previous surgery on the lower uterine segment (e.g. cesarean section).
3. The posterior leaf of the broad ligament is incised toward the posterior vaginal apex and recto-vaginal septum. Now, the uterine artery is coagulated again and transected, being the ureteral course directly visible. Parametrial and uterosacral ligaments may be cut at this time, but usually are controlled by retrograde resection.

By means of a ring forceps, the anterior fornix is exposed by a nurse. This is incised on the bulging of the rings and opened. A vaginal plug is then used to stop CO₂ loss. While the

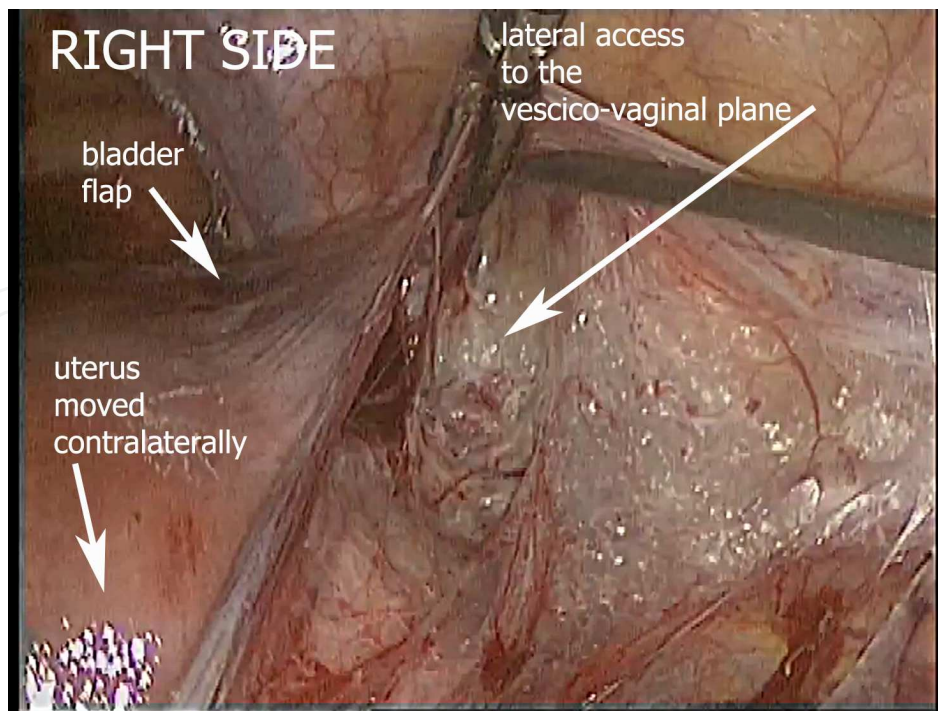


Figure 4. Blunt dissection of vesico-vaginal space.

assistant surgeon grasps and elevates the distal margin of the vagina, the first operator moves proximally the cervical margin of the vagina and starts the retrograde incision of the vagina (Figure 5). This is facilitated by strongly pulling the cervix cranially.

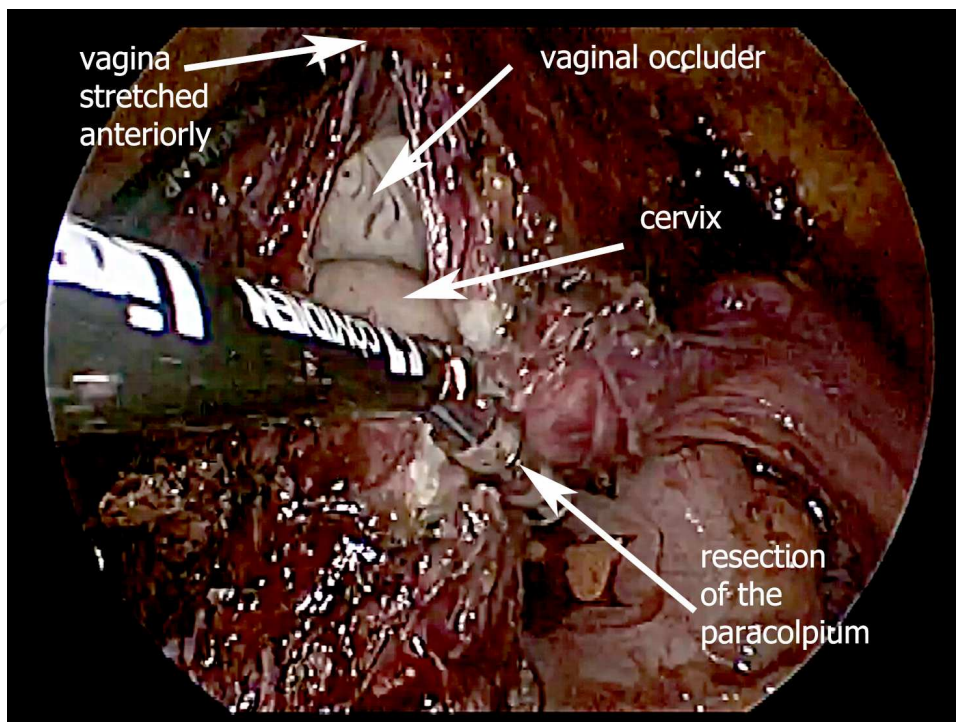


Figure 5. Beginning of retrograde incision of vagina.

Vagina, parametrium and utero-sacral ligaments are severed moving from anterior to posterior aspect and from the vagina toward the cervix, parallel to the ureteral course (Figure 6). During this step, the LigaSure™ forceps is useful since cutting and coagulation may be performed at the same time, while using bipolar forceps and scissors may be more difficult.

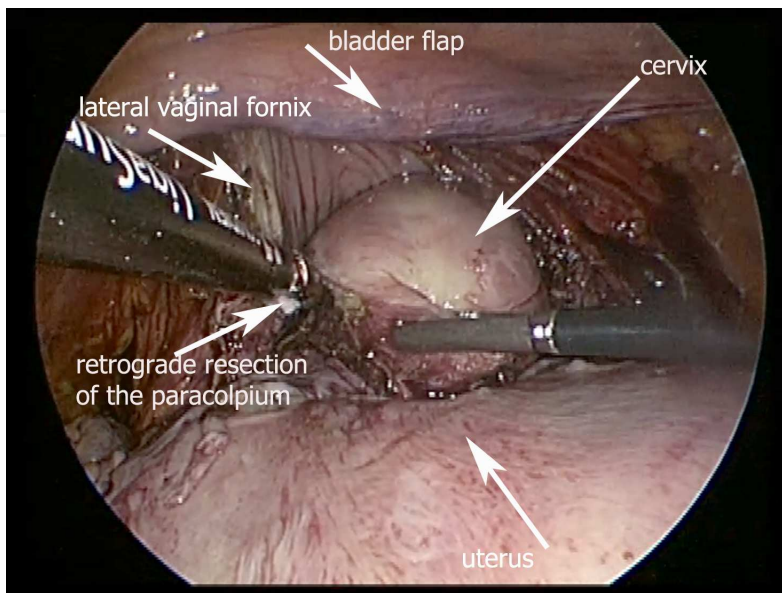


Figure 6. Retrograde dissection of paracolpium.

Classic vaginal morcellation to extract the uterus is performed. In case of very restricted vaginal access, the removal of the uterus is performed by abdominal morcellation.

Finally, the vagina is closed laparoscopically by a running suture using V-lock suture (Covidien) or Caprosyn (Ethicon) (Figures 7 and 8).

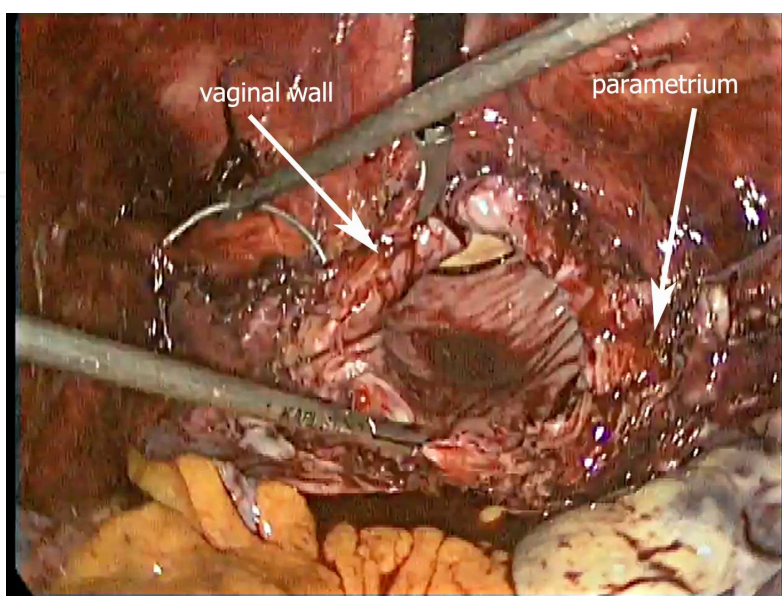


Figure 7. Beginning of vaginal suture.

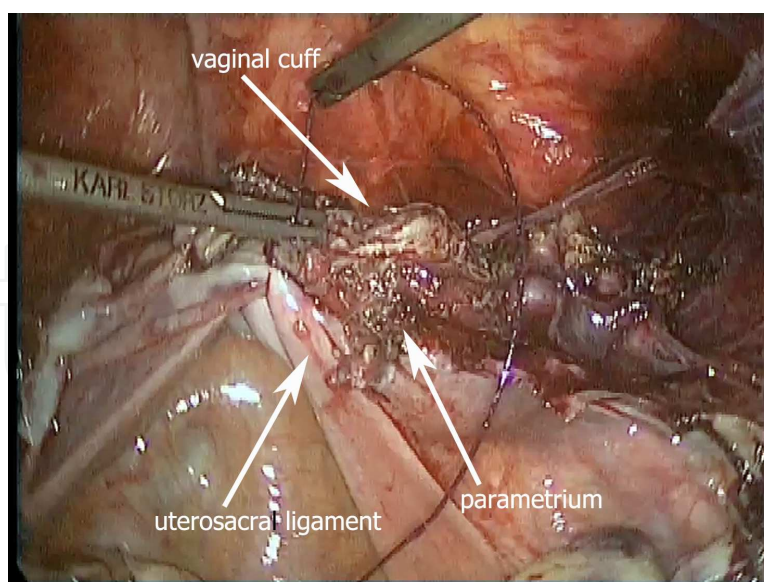


Figure 8. Closure of vaginal cuff.

3. Discussion

We report our experience in applying modified technique for TLH: we combine the retroperitoneal coagulation of the uterine artery and the retrograde approach to the pelvic organs. The retroperitoneal approach has been used mainly during vaginally assisted laparoscopic hysterectomies (VAH) [9, 10, 16–18], while the retrograde bladder dissection and the retrograde culdotomy have been described specifically for laparotomic oncological surgeries [11–13]. To date, just one study by Roman et al. reported the application of a retroperitoneal approach for total laparoscopic hysterectomy in case of enlarged uteri [10].

Up to now, after progressively setting up our technique, we have performed about 1, 000 of these procedures. However, this paper refers to 400 hysterectomies developed in two different hospitals from 2011 to 2013. In our experience, about 94% of hysterectomies can be performed laparoscopically, even if a limitation at 22-week size of the uterus is admitted. Moreover, our experience is reproducible with 3-mm trocars: in these cases, the size of the uterus has been limited to 13-week uterus. We think about the 3-mm experience simply as a scaling down from a previous experience with two 10-mm and two 5-mm trocars: surgical steps and operating time were the same.

We observed a low rate of complications. We registered two ureteral fistulas (0.5% in the last 3 years). The first fistula is a complication due to a very large (12 cm) infraligamentary fibroid: the pelvic ureter beyond uterine artery was longer than usual for the presence of the myoma and so dissection resulted in excessive devascularization. It was managed by re-implantation. The second occurred 16 days after surgery and it was managed by stenting. Both complications were late, at least after 10 days from surgical procedure. Six patients had bladder injury. The

lesion was sutured laparoscopically and the patients dismissed on the 3rd day with the catheter in situ. When the patients came back after 1 week of follow-up, the catheter was removed.

The rate of urologic complications observed in our experience may be justified by the absence of selection of the patients except for uterine size and is in agreement to that reported by similar studies using retroperitoneal approach [8–10, 20–22].

We also observed four cases of vaginal cuff dehiscence: this rate is similar to that of the literature.

Our results, in terms of operative time, mean blood loss, mean hospital stay and complications, based on about 400 cases, are comparable to those reported by most centers where laparoscopic hysterectomy is routinely performed according to the classic technique (intrafascial dissection and constant use of uterine manipulator) [9, 10, 23, 24].

Kohler et al. [9] demonstrated full safety and clinical advantages of an extraperitoneal technique: they reported optimal isolation, coagulation and transection of uterine artery and constant control of the ureter during the laparoscopic assistance to 267 vaginal hysterectomies. The interruption of blood supply through this approach especially helped the vaginal removal of enlarged uteri, when bleeding generally is a problem in vaginal operations. Seventy percent of these procedures were performed by residents with limited surgical experience; moreover, the use of neither not disposable instruments nor uterine manipulator allowed to reduce financial costs. Chang et al. [17] reported their experience in uterine artery ligation through retrograde tracking of the umbilical ligament: the blood loss (two patients lost >500 mL) was minimal and complication rate very low (two bladder laceration) in 225 laparoscopic-assisted vaginal hysterectomies for myomas or adenomyomas. The average time from identification of the umbilical ligament to ligation of the uterine artery was approximately 10 min and operations were performed by residents with aid of the attending physician. In our experience, the technique to dissect the uterine artery is different, but the time spent is similar.

Roman et al. described more than 50 cases of TLH for large uteri with uterine coagulation at its origin [10]. Their results confirmed that the retroperitoneal approach is feasible and reproducible by gynecological surgeons avoiding laparotomy for enlarged uteri. According to the authors, the key to a successful procedure is to perform the uterine devascularization before any other surgical step on uterus. In their department, one surgeon began practicing this technique and subsequently it was acquired and easily reproduced by others. These data have been confirmed by other authors [16, 17, 21–23].

For beginners, this modified TLH could seem more challenging than traditional intrafascial hysterectomy; nevertheless, it allows a right approach to more complex pelvic pathologies, as endometriosis or cancer, thanks to a progressive confidence with anatomical spaces and tissues. The retroperitoneal approach is, indeed, mandatory for pelvic lymphadenectomy and useful in case of symptomatic fibroids and ovarian cystectomies with severe adhesions [22]. For patients with fixed uterus or endometriosis, the preventive occlusion of the uterine arteries through downstream ureter tracking in the retroperitoneum decreases the risks of bleeding and ureteral injury; this alternative procedure also shortens the operative time and minimizes the conversion rate to laparotomy [18].

In our experience, the uterine manipulator is not useful: the first assistant can easily expose lateral aspect of uterus because it is free at the level of the isthmus. Furthermore, the position of the optics in the umbilicus can be maintained with an enlarged uterus, since the displacement given by manipulator needs that the camera is moved up, toward the xiphisternum. The disadvantage with a larger uterus is that all the movements are bound to the laparoscopic instruments and it may need more skills. The lateral approach to the uterine arteries and the retrograde resection of the vagina are independent from a uterine manipulator. In our opinion, it is in fact a cultural rather than a technical question.

The technique we described unifies for the first time in a single procedure different surgical steps already reported. Summarizing:

1. Uterine vessels are coagulated at their origin but not transected; the pararectal space is firstly opened.
2. The bladder is approached from the lateral aspect for a safer dissection, especially when anatomical difficulties are present.
3. The ureter is easily visible during the whole procedure.
4. The retrograde circular colpotomy is performed after minimal preparation of the rectovaginal septum being safely far from the ureter.
5. The whole surgery can be performed without uterine manipulator and with reusable instruments, decreasing the costs.

Oncological preparation of the surgical field as done during the creation of the Latzko's space (preparation of the uterine arteries at their origin) might seem excessive; nevertheless, post-operative course of our patients shows no differences with traditional TLH.

Moreover, our approach includes all the advantages of laparoscopic surgery such as magnification of the anatomy and pathology; access to the uterine vessels, vagina, rectum, and lymph nodes; better exposure of ureter; and achievement of clots drainage and hemostasis [24, 25].

In conclusion, our modified technique of extraperitoneal and retrograde laparoscopic hysterectomy, even if at first appears challenging, allows routine approach to almost all hysterectomies and can offer great prospects for research in gynecological surgery.

Author details

Eugenio Volpi, Elisa Peano, Giulia Moggio, Anna Silvia Pertusio, Paola Ballario and Luca Bernardini*

*Address all correspondence to: volpi.e@ospedale.cuneo.it

Department of Obstetrics and Gynecology, Ospedale S. Croce e Carle, Cuneo, Italy

References

- [1] Soto E, Lo Y, Friedman K, Soto C, Nezhat F, Chuang L, Gretz H. Total hysterectomy versus da Vinci robotic hysterectomy: Is using the robot beneficial ? *J Gynecol Oncol* 2011;22(4):253–9. doi: 0.3802/jgo.2011.22.4.253.
- [2] Wattiez A, Cohen SB, Selvaggi L. Laparoscopic hysterectomy. *Curr Opin Obstet Gynecol* 2002 Aug;14(4):417–22.
- [3] Canis M, Botchorishvili R, Ang C, Rabischong B, Jardon K, Wattiez A, Mage G. When is laparotomy needed in hysterectomy for benign uterine disease ? *J Minim Invasive Gynecol* 2008;15:38–43. doi: 10.1016/j.jmig.2007.09.003.
- [4] Kauko M. New techniques using the ultrasonic scalpel in laparoscopy. *Curr Opin Obstet Gynecol* 1998;10(4):303–305.
- [5] Einarsson JI, Suzuki Y. Total laparoscopic hysterectomy: 10 steps toward a successful procedure. *Rev Obstet Gynecol* 2009;2(1):57–64.
- [6] Ostrzenski A, Radolinski B, Ostrzenska KM. A review of laparoscopic ureteral injury in pelvic surgery. *Obstet Gynecol Surv* 2003;58(12):794–9.
- [7] Brummer THI, Jalkanen J, Fraser J, Heikkinen AM, Kauko M, Makinen J, Seppala T, Sjoberg J, Tomas E, Harkki P. FINHYST, a prospective study of 5279 hysterectomies. Complications and their risk factors. *Hum Reprod* 2011;26(7):1741–51. doi: 10.1093/humrep/der116.
- [8] Garry R, Fountain J, Brown J, Manca A, Mason S, Sculpher M, Napp V, Bridgman S, Gray J, Lilford R. Evaluate hysterectomy trial: a multicentre randomised trial comparing abdominal, vaginal and laparoscopic methods of hysterectomy. *Health Technol Assess* 2004;8:26, 1–140.
- [9] Kohler C, Hasenbein K, Klemm P, Tozzi R, Schneider A. Laparoscopic-assisted vaginal hysterectomy with lateral transection of the uterine vessels. *Surg Endosc* 2003;17:485–90.
- [10] Roman H, Zanati J, Friederich L, Resch B, Lena E, Marpeau L. Laparoscopic hysterectomy of large uteri with uterine artery coagulation at its origin. *JSL* 2008;12:25–9.
- [11] Delle Piane G. Surgery in the modern treatment of ovarian carcinoma. *Fifth World Congress of Gynecology and Obstetrics*. Sydney: Butterworth, 1967:473–96.
- [12] Hudson CN, Chir M. A radical operation for fixed ovarian tumors. *J Obstet Gynaecol Br Cwlth* 1968;75:1155–6.
- [13] Bristow RE, del Carmen MG, Kaufman HS, Montz FJ. Radical oophorectomy with primary stapled colorectal anastomosis for resection of locally advanced epithelial ovarian cancer. *J Am Coll Surg* 2003;197(4):565–74.

- [14] Volpi E, Bernardini L, Angeloni M, Cosma S, Mannella P. Retroperitoneal and retrograde total laparoscopic hysterectomy as a standard treatment in a community hospital. *Eur J Obstet Gynecol Reprod Biol* 2014;172:97–101. doi: 10.1016/j.ejogrb.2013.10.013.
- [15] Volpi E, Sismondi P. Semi-open direct trocar insertion method for induction of pneumoperitoneum at laparoscopy. *Gynaecol Endosc* 2002;11:197–200.
- [16] Shutz K, Possover M, Merker A, et al. Prospective randomized comparison of laparoscopic-assisted vaginal hysterectomy (LAVH) with abdominal hysterectomy (AH) for the treatment of the uterus weighing > 200g. *Surg Endosc* 2002;16:121–5.
- [17] Chang WC, Torng PL, Huang SC et al. Laparoscopic-assisted vaginal hysterectomy with uterine artery ligation through retrograde umbilical ligament trafficking. *J Minim Invasive Gynecol* 2005;12:336–42.
- [18] Hsu WC, Chang WC, Huang SC, Sheu BC, Torng PL, Chang DY. Laparoscopic-assisted vaginal hysterectomy for patients with extensive pelvic adhesions: a strategy to minimise conversion to laparotomy. *Aust New Zea J Obstet Gynaecol* 2007;47:230–34.
- [19] Sinha R, Sundaram M, Nikam YA, Hegde A, Mahajan C. Total laparoscopic hysterectomy with earlier uterine artery ligation. *J Minim Invasive Gynecol*. 2008;15(3):355–9. doi: 10.1016/j.jmig.2008.01.012.
- [20] Pan HS, Ko ML, Huang LW, Chang JZ, Hwang JL, Chen SC. Total laparoscopic hysterectomy (TLH) versus coagulation of uterine arteries (CUA) at their origin plus total laparoscopic hysterectomy (TLH) for the management of myoma and adenomyosis. *Minim Invasive Ther Allied Technol* 2008;17(5):318–22. Erratum in: *Minim Invasive Ther Allied Technol* 2008;17(6):370.
- [21] Gol M, Kizilyar A, Eminoglu M. Laparoscopic hysterectomy with retroperitoneal uterine artery sealing using LigaSure: Gazi hospital experience. *Arch Gynecol Obstet* 2007;276:311–4.
- [22] Reich H. Total laparoscopic hysterectomy: indications, techniques and outcomes. *Curr Opin Obstet Gynecol* 2007;19:337–44.
- [23] Nieboer TE, Johnson N, Lethaby A, Tavender E, Curr E, Garry R, van Voorst S, Mol BWJ, Kluivers KB. Surgical approach to hysterectomy for benign gynaecological disease. *Cochrane Database Syst Rev* 2009;8(3). doi: 10.1002/14651858.CD003677.
- [24] Ostrzenski A. A systematic arrangement of laparoscopic total abdominal hysterectomy: a new technique. *J Natl Med Assoc* 1999;91:404–9.
- [25] Dubuisson JB, De Dycker Y, Yaron M. The retroperitoneal approach in minimally invasive pelvic surgery. *Ann NY Acad Sci* 2006;1092:187–98.

