

We are IntechOpen, the world's leading publisher of Open Access books Built by scientists, for scientists

4,800

Open access books available

122,000

International authors and editors

135M

Downloads

Our authors are among the

154

Countries delivered to

TOP 1%

most cited scientists

12.2%

Contributors from top 500 universities



WEB OF SCIENCE™

Selection of our books indexed in the Book Citation Index
in Web of Science™ Core Collection (BKCI)

Interested in publishing with us?
Contact book.department@intechopen.com

Numbers displayed above are based on latest data collected.
For more information visit www.intechopen.com



Failure Mechanisms in Hip Resurfacing Arthroplasty

Hiran Wimal Amarasekera

Additional information is available at the end of the chapter

<http://dx.doi.org/10.5772/61146>

Abstract

Hip resurfacing arthroplasty has been a popular alternative for total hip replacement in young active patients since the early 1990s.

Early results have been promising and a large number of arthroplasties were performed in the United Kingdom, North America, and Western Europe during the last decade. However, due to a series of complications, such as pseudo-tumours, femoral neck fractures avascular necrosis and aseptic loosening, the long-term results were poor and failure rate has been high.

This chapter attempts to identify the different biological and biomechanical mechanisms that may contribute to these failures. It also discusses some considerations to be noted when designing resurfacing implants in the future.

This is a research study based on the author's primary research work carried out with retrieval specimens taken from failed hip arthroplasties.

Keywords: Hip Resurfacing, pseudo-tumours, retrieval specimens, metal-on-metal designs, surgical approaches, avascular necrosis, aseptic lymphocyte-dominated vasculitis-associated lesions (ALVAL)

1. Introduction

1.1. History

The concept of hip resurfacing arthroplasty or surface replacement of the hip was originally introduced by John Charnley in the 1950s [1] but had to abandon the idea due to high wear rate [2]. Since then, many surgeons, such as *Wagner et al* [3], have been using hip resurfacing arthroplasty as an alternative to total hip replacements (THR). [4, 5]

Due to high wear rate and metal plastic debris giving rise to a number of complications, this procedure did not gain popularity among orthopaedic surgeons until the early 1990s.

1.2. Modern hip resurfacing

In the early 1990s, there was resurgence in hip resurfacing arthroplasties when *McMinn et al.* introduced metal-on-metal-resurfacing. [6] Instead of metal-on-plastic, the design was changed to metal-on-metal. Since then, there has been a rapid increase in hip resurfacing throughout the world mainly in Europe, the United Kingdom [7], and North America peaking in late the 90s and the early part of this decade. [8]

The main reasons for this popularity among surgeons were the advantages of hip resurfacing as compared to the conventional hip replacements such as minimal bone loss, less dislocation rates, and easier conversion to a revision. Due to these factors resurfacing was introduced mainly as an alternative to THR in young active adults. [9] Modern hip resurfacing also addressed the problems associated with previous designs. The new design was built using better materials (metal-on-metal), modified surgical techniques including new surgical approaches, and better instrumentation for implant positioning. [10]

1.2.1. Indications for modern hip resurfacing

Indications were broad-based, but the ideal candidate is described as young, active adult males in their late forties to early sixties [9] with good bone stock having primary or secondary osteoarthritis.

Hip resurfacings have been done in young females [11], including patients with dysplasia and avascular necrosis (AVN) of the femoral head. [12]

1.2.2. Complications of hip resurfacing

There are many complications associated with hip resurfacing some are common for any orthopaedic procedure such as infection, nerve palsy, deep vein thrombosis, and dislocation. Even though the complications are similar the complication rates differ between hip resurfacing and total hip arthroplasty.

These complications can be classified in many ways:

1. Based on common and specific: Common to all hip arthroplasties and specific to hip resurfacing
2. Based on timing: Early and late
3. Based mainly on site of failure; femoral or acetabular components: Femoral, acetabular, both, or none

Common complications to all hip arthroplasty procedures include bleeding, nerve damage, deep vein thrombosis, malpositioning of implants, and dislocations. Out of these, dislocation is relatively rare in hip resurfacing compared to THR due to the larger size head in the femoral

component. However, the large head increase the surface area and can lead to high wear rates leading to eventual failure. Malpositioning is a contributory factor for the high wear rates. [13]

The complications that are more specific to hip resurfacing arthroplasty can be further divided into early and late complications.

The early complications are usually seen within the first weeks to the early years. These are loosening of implants, femoral neck fractures, femoral head notching [14] and AVN. [15]

The late complications are set of complications recognized recently, following the long-term outcome of patients. [16] Among these are osteolysis, pseudo-tumours, bone resorption, ALVAL, loosening of components, high metal ion levels in blood, and tissue metallosis. These complications can eventually lead to failure of the hip resurfacing implant. [17, 18]

2. Causes of failure/complications in hip resurfacing

1. AVN of the femoral head
2. Loosening of implants
3. Femoral neck fractures
4. Impingement
5. High metal ion levels in blood
6. Metallosis
7. Pseudo-tumours formation
8. ALVAL
9. Resorbtion of head

2.1. Pathogenesis of early complications

It is widely believed that early complications such as AVN, femoral neck fractures, and loosening of implants, are mainly associated with the decrease in the blood flow to the femoral head. Understanding the basic mechanisms of failure in each complication will help us to prevent these at present and design better implants in the future.

2.1.1. Reducing blood flow to the femoral head possibly leading to AVN and implant failure

This has been mainly attributed to the posterior surgical approach that reduces the femoral head blood flow by damaging the branches of the medial circumflex femoral artery. Unlike in THR where the femoral head and neck is removed in resurfacing the neck and part of the head is preserved, the blood flow to this area appear to play a crucial role in the long-term outcome. This is the main reason why many surgeons have challenged the posterior approach. Alternatively many surgical approaches have been tried. Many studies have attempted to demonstrate this by comparing the blood flow between posterior and other approaches [19 - 22].

Ganz et al has described trochanteric flip approach as an alternative surgical approach to the posterior approach to be used during hip resurfacing to preserve the blood flow. [23]

Even though many studies show a clear drop in blood flow intra-operatively during posterior approach, post-operatively some studies fail to establish a clinical significance and a direct link to this fall as a cause of AVN; other studies show this as a transient drop that recovers during the post-operative period [24]. Some have argued that AVN is not caused by the procedure. [25] Some have even used hip resurfacing as a treatment option for patients having established AVN and Perthes disease. [12, 26, 27, 28]

Due to these reasons, many studies have been conducted comparing different surgical approaches when hip resurfacing is performed. This has also led to many different surgical approaches being tried by many surgeons in the past decade. [29] The posterior, poster-lateral [30], direct lateral, Ganz trochanteric flip [31], direct anterior [32], and antero-lateral [33] approaches. [34] Some complications of resurfacings shown in Fig 1A-1C.

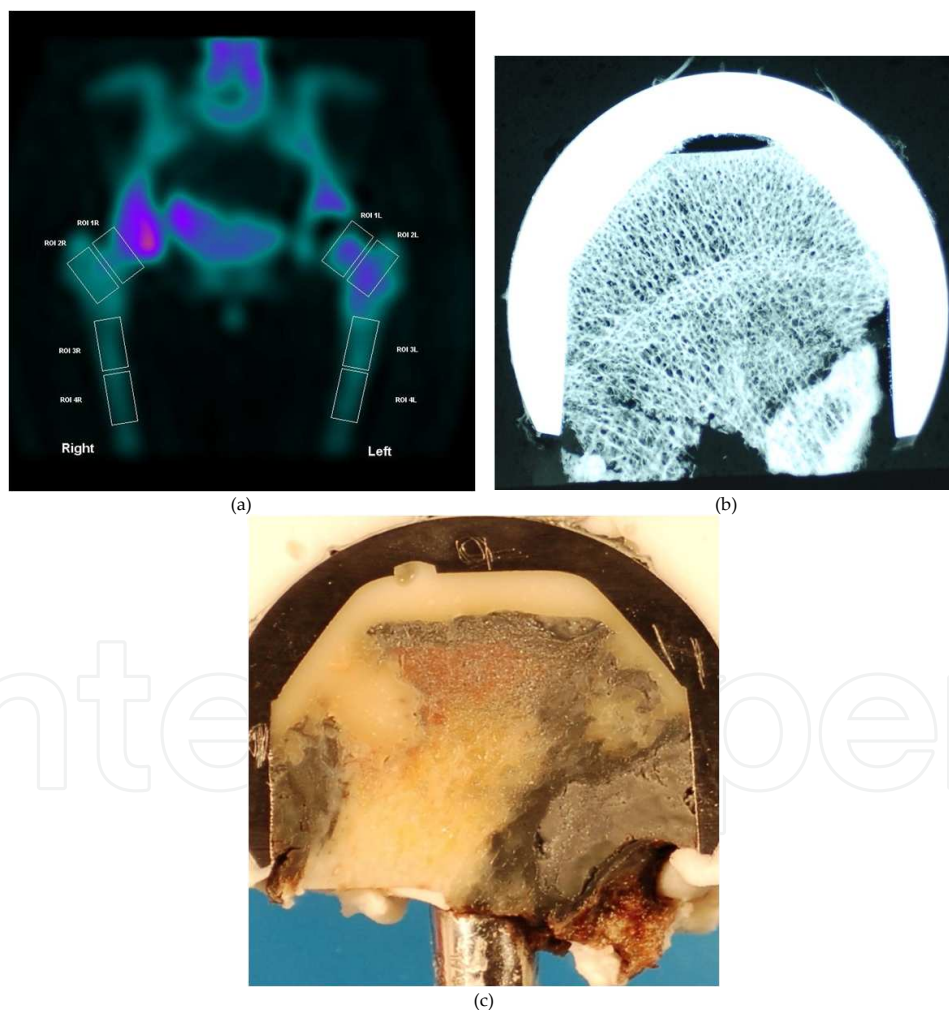


Figure 1. (a). Single cut section of a Single Positron emission Computed Tomography (SPECT) image. The most likely areas to develop AVN and fractures are ROI L (L: Operated, R: Normal). (b). Mocroradiograph shows bone thinning under the metal implant with a fracture at the lower margin. (c). The cut section of a retrieval head with metallosis and early pseudo-tumour formation

2.1.2. Femoral neck fractures following hip resurfacing

Femoral neck fractures is a common and specific complication of hip resurfacing (Fig. 1B and 2). There are many factors attributed to this including AVN, poor patient selection (patients with osteoporosis such as older age groups, post menopausal female patients), and poor implant positioning that may cause notching. [15] Some also believe that notching may affect the blood flow. [14] Proper patient selection and careful surgical technique is important to minimise neck fractures. [35 - 37]

The ideal patient for hip resurfacing is the young active adult male. [38] Hip resurfacing in post-menopausal females is not recommended. Hip resurfacing in younger females is a debatable issue among many surgeons as revision rates and femoral neck fractures appear to be higher in females than in males. [39] Bone density and good bone stock appear as an important feature to prevent complications. [40] Obesity is another risk factor for neck fractures. [35]

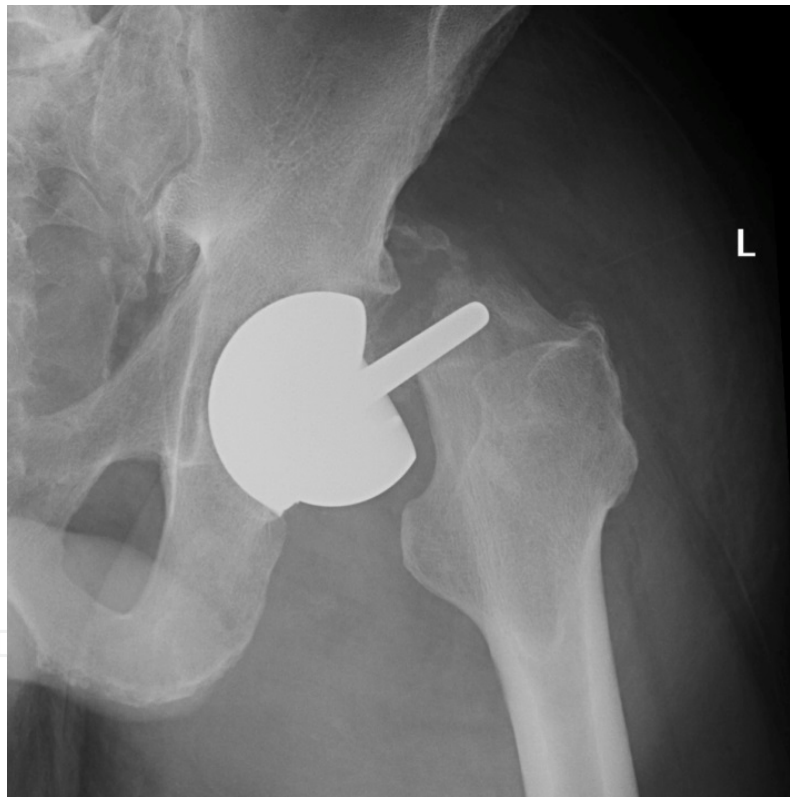


Figure 2. X-ray of a femoral neck fracture following hip resurfacing arthroplasty

2.1.3. Loosening of components

Loosening of components is another cause for early and late failure of resurfacing, mainly acetabular failure, in young adults. [41] Loosening can be further divided to acetabular, femoral or both. Loosening of components can be due to many reasons. Poor positioning, poor cementing, poor surgical technique, and infection can all cause loosening. Even though

cementing of both components are common, some prefer cementing the femoral head with un-cemented acetabular component, while some do not use cement at all. [42, 43] Initial failure rates for cemented acetabular component were high and led to the re-introduction of the cementless components. [44] If cement is used, the cementing technique becomes a key factor in improving long and short-term results. [45] Another complication associated with cementing is the possibility of thermal necrosis (Fig. 3) that can lead to loosening and this needs to be minimised for better outcomes. [46]

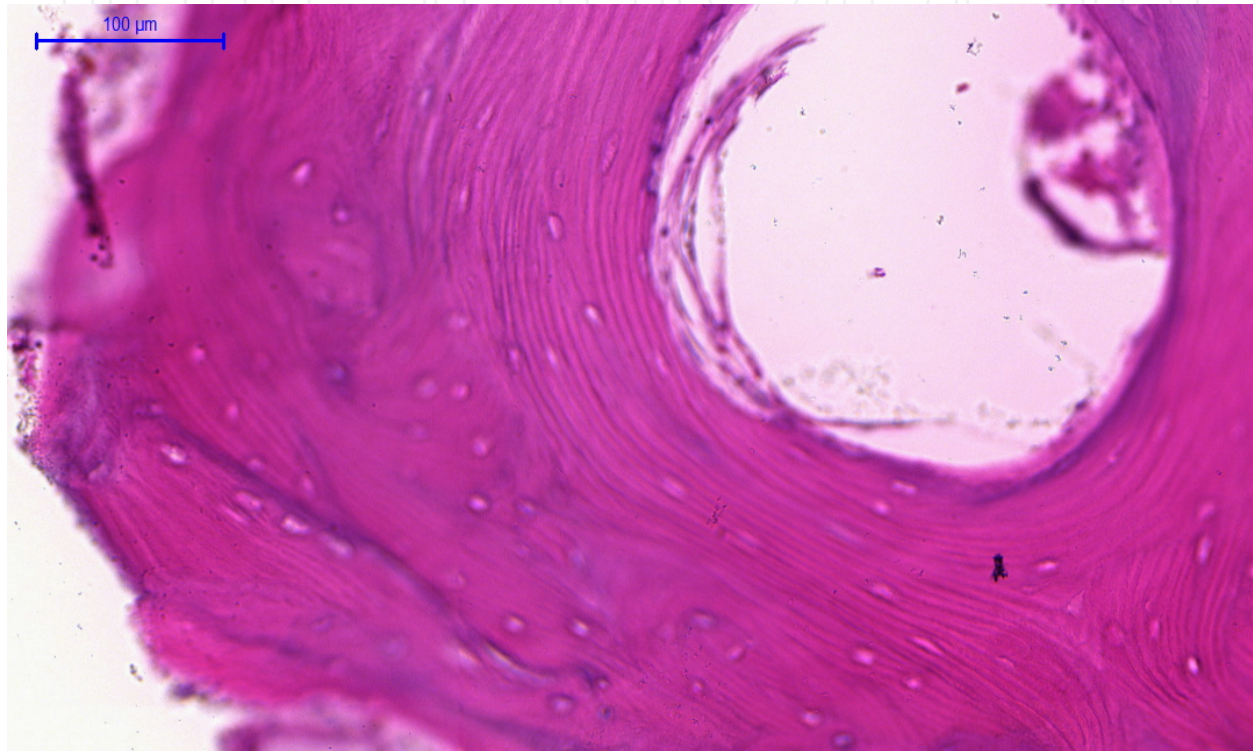


Figure 3. Features of necrosis at the margin of cemented implant with empty lacunae, most likely due to thermal necrosis (Cement metal interface) (H & E 20X)

2.2. Pathogenesis and possible mechanisms of failure in late complications

Most late complications that lead to eventual failure of the implants seem to be associated with high wear rates leading to increased metal ion released to soft tissues and blood leading to the following changes:

1. High metal ions in the blood
2. Metal sensitivity
3. Metallosis in tissues
4. ALVAL
5. Development of pseudo tumours (Fig. 4)

6. Osteolysis

7. Bone resorption

Pseudo-tumours have been reported [47] following resurfacing arthroplasty (Fig. 1C and 4). In a Canadian study of around 3,400 hips, pseudo-tumours were reported in four, giving a prevalence of 0.10%. [48].

The commonest hypothesis suggested for pseudo-tumour formation is the release of metal ions due to the increased surface area and malpositioning of implants. [49] This triggers a delayed Type IV hypersensitivity reaction leading to osteolysis and ALVAL presenting as pseudo tumours. [50 - 53]

Acetabular component malpositioning appear to cause more ALVAL formation due to high wear. [50, 54, 55] Blood metal ion levels, mainly Cobalt and chromium (Co and Cr), have been found to be high following resurfacing arthroplasty but the link between high blood ion levels and the formation of pseudo-tumours is not well established. [56] Some studies suggest the presence of asymptomatic pseudo-tumours with high blood ion levels among patients after resurfacing arthroplasty (RA). [57]

Blood metal ion levels may be high following both THR and RA, as many studies suggest [58 - 61], but the local effect on the hip may differ between the two.

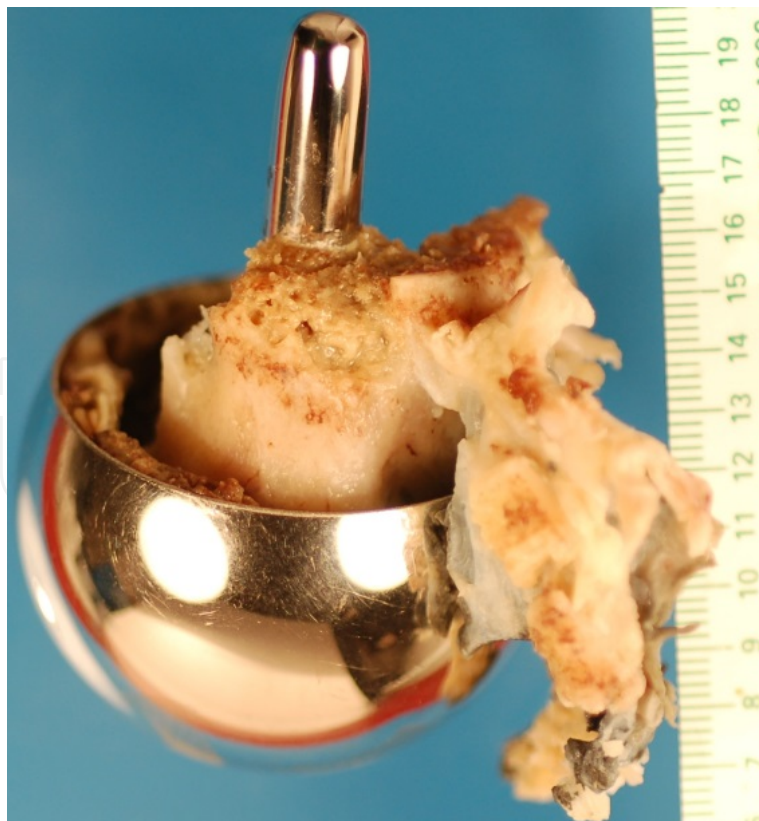


Figure 4. Retrieved head with extensive resorption of head osteolysis and growth of a pseudo-tumour

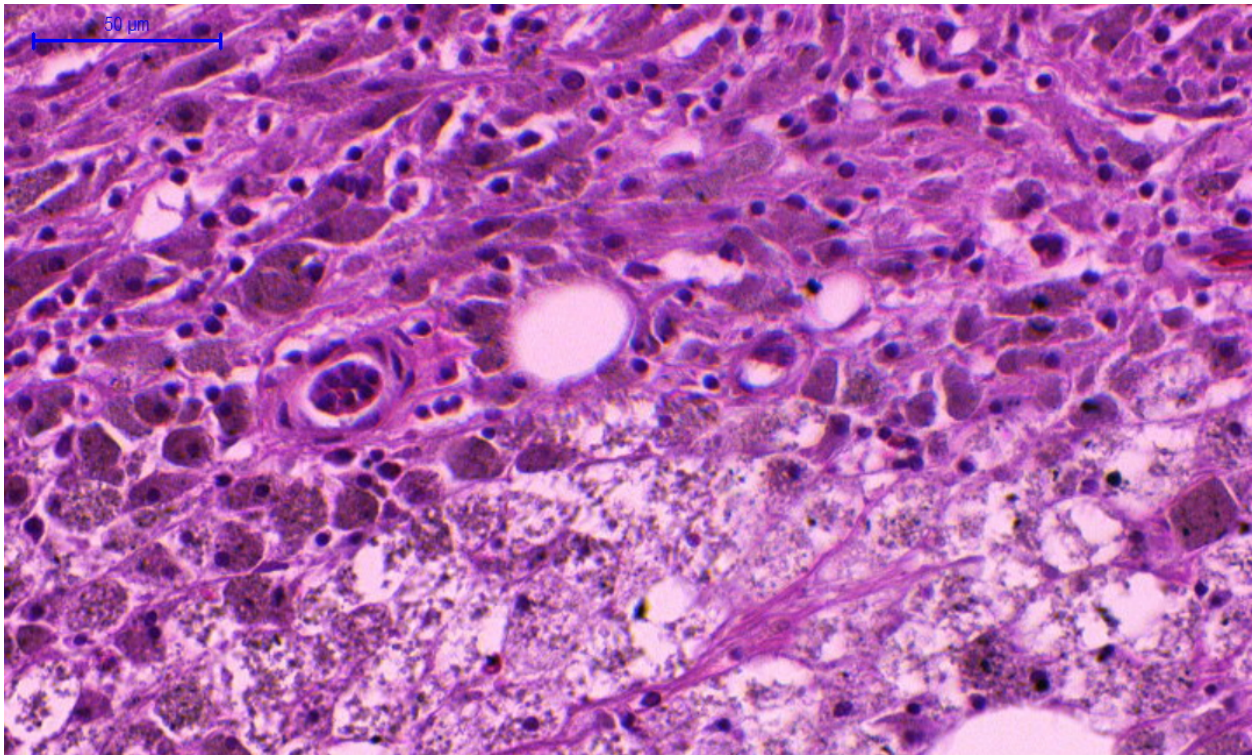


Figure 5. Large number of lymphocytic infiltration with metal particles engulfed macrophages forming multinucleated foreign body Giant cells (H & E 40X)

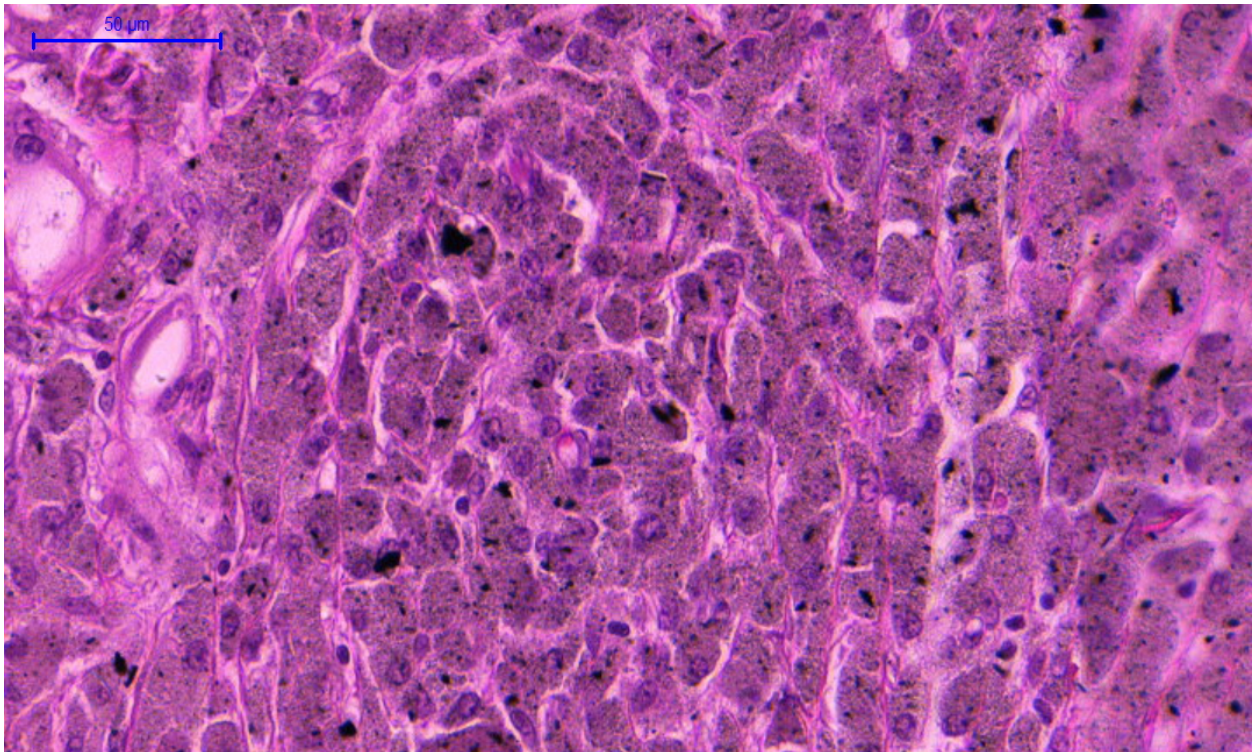


Figure 6. Large number of metal particles (black) seen in bone tissue from a retrieved femoral head (H & E 40X)

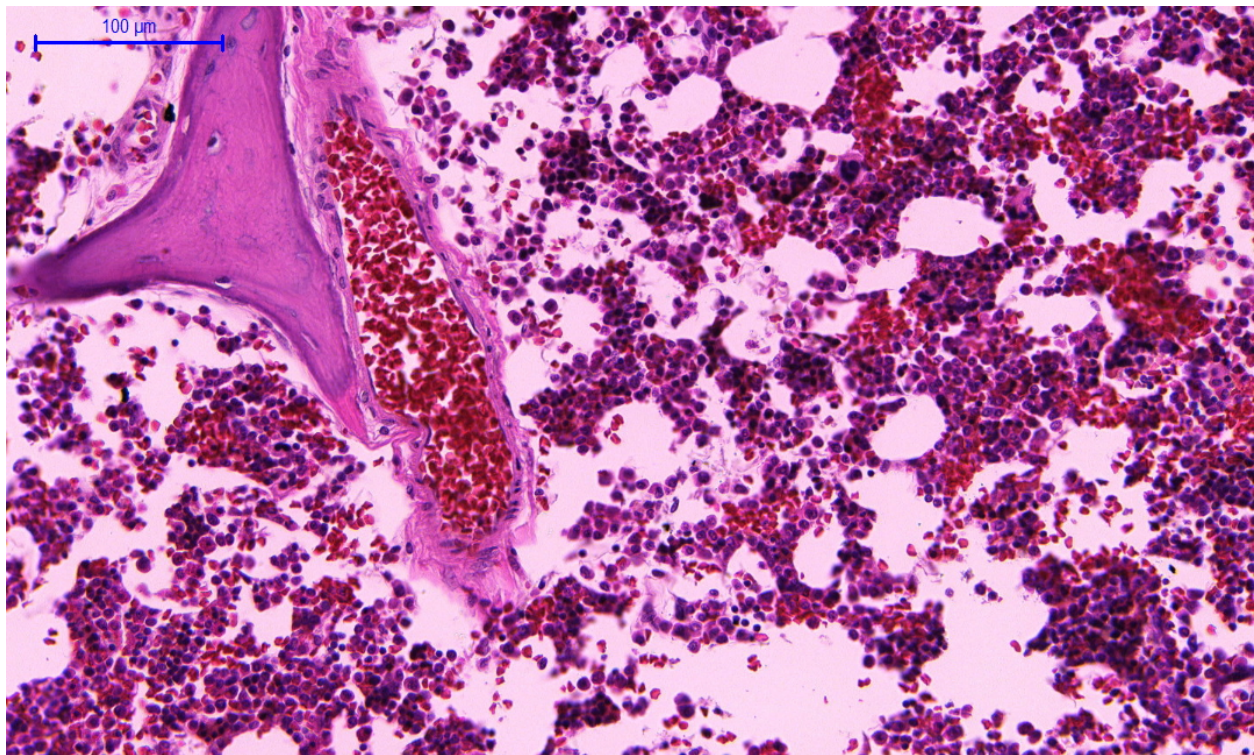


Figure 7. Highly vascular bone in osteolysis and pseudo-tumour formation showing a blood vessel, aggregation of lymphocytes inflammatory cells, and live bone characterised by nucleated lacunae (H & E 20X)

Pseudo-tumours appear to be highly vascular with blood vessels red blood cells, lymphocytes macrophages, and inflammatory cells with live bone until osteolysis occurs. (Figs. 1C, 5–7)

Common cause for aseptic failure of acetabular component is most likely due to osteolysis triggered by the metal particles. [62]

3. Hypothesis of late failure in hip resurfacing

After considering multiple factors that seem to contribute to the eventual failure of the resurfacing implant, I have recognized two possible pathways that may lead to the failure of the implant in the late stages. These are:

3.1. Uncoordinated osteoblast-osteoclast activity

This process seems to be similar to the process seen in fracture healing. However, compared to fracture healing, which occurs in a well-coordinated systematic stepwise manner, here it happens haphazardly. In osteoblastic activity, new bone formation and signs of healing is seen in one part of the bone; simultaneously, osteolysis bone breakdown and remodelling with osteoclastic activity is seen in the other end. Bone remodelling is a process that is essential in the healing of a bone where a fine balance exists between osteoclastic activity and osteoblastic activity. When this fine balance is broken, uncontrolled osteoclastic activity can cause destruc-

tion on a large volume of the femoral head leading to complete osteolysis and bone resorption. This is an uncoordinated process and as long as the initial stimuli that triggered remains, the process seems to continue and eventually leading to bone resorption.

This can present as loosening, pain, malpositioning, and femoral neck fractures. Over activity of osteoclasts initially lead to focal areas of destruction (Fig. 10) that eventually leads to osteolysis of the whole femoral head (Fig. 13). However, in patients where osteoclasts and osteoblast act in a normal coordinated way, well-formed new bone growth can occur resulting in a well-fixed and stable metal/cement bone interface (Fig. 12). The factors that cause increased uncontrolled osteoclasts activity are not clearly understood. This is an area that will need further research. In this series, we found both patterns in patients. A hypothesis of the probable pathway is given below (Fig. 8).

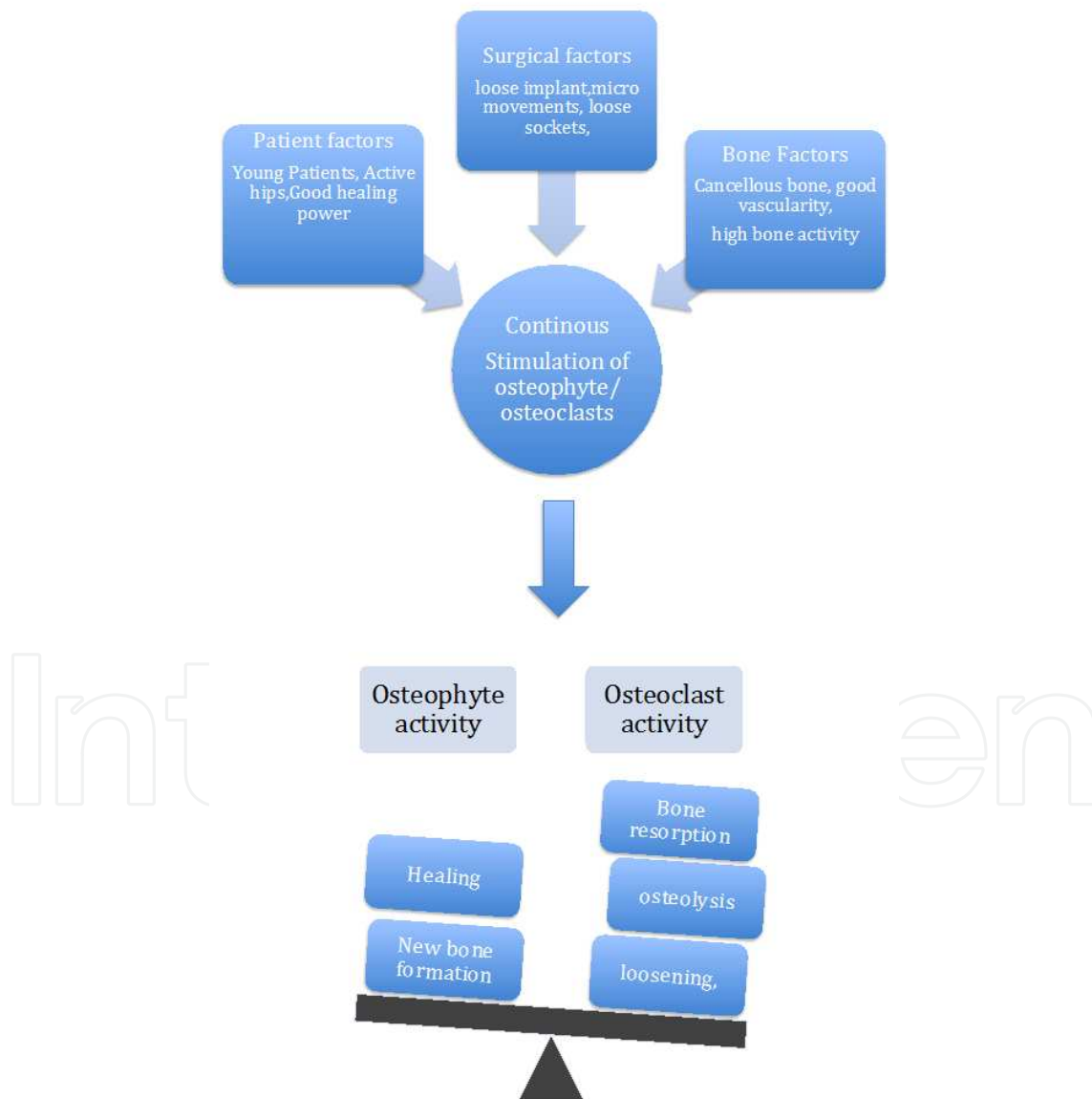


Figure 8. Multiple factors leading to increased bone activity

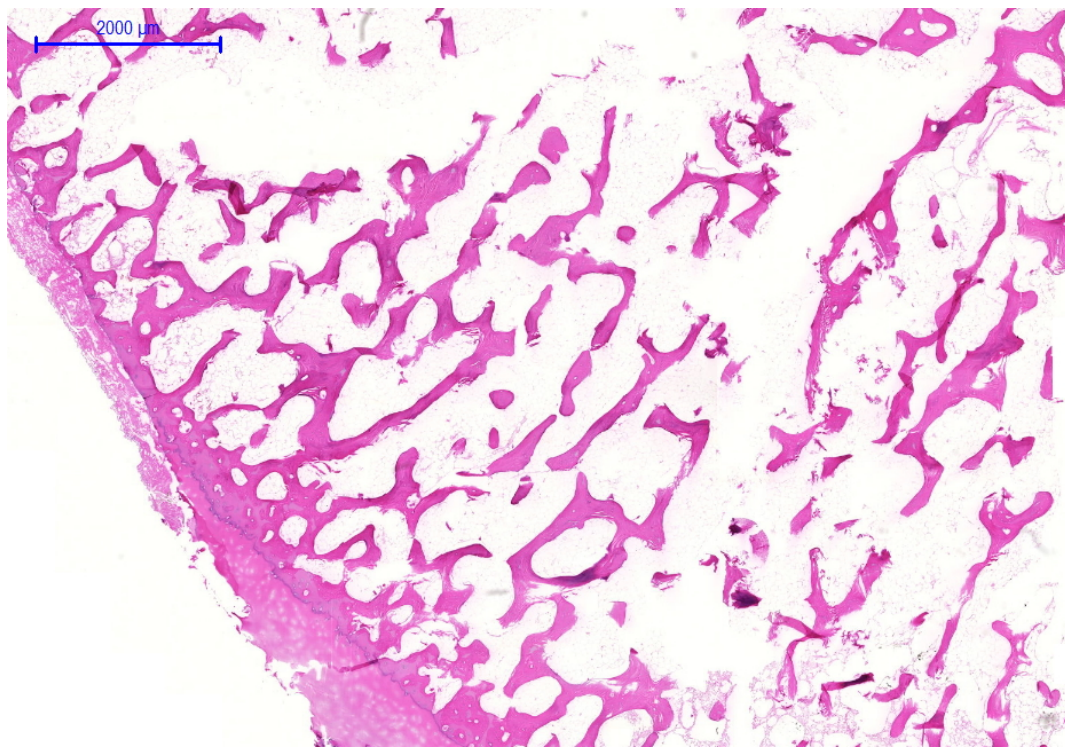


Figure 9. New bone formation from the outer margin while bone remodelling and resorption is shown from a more central area (above). (H & E P 8 ant slice 1X)

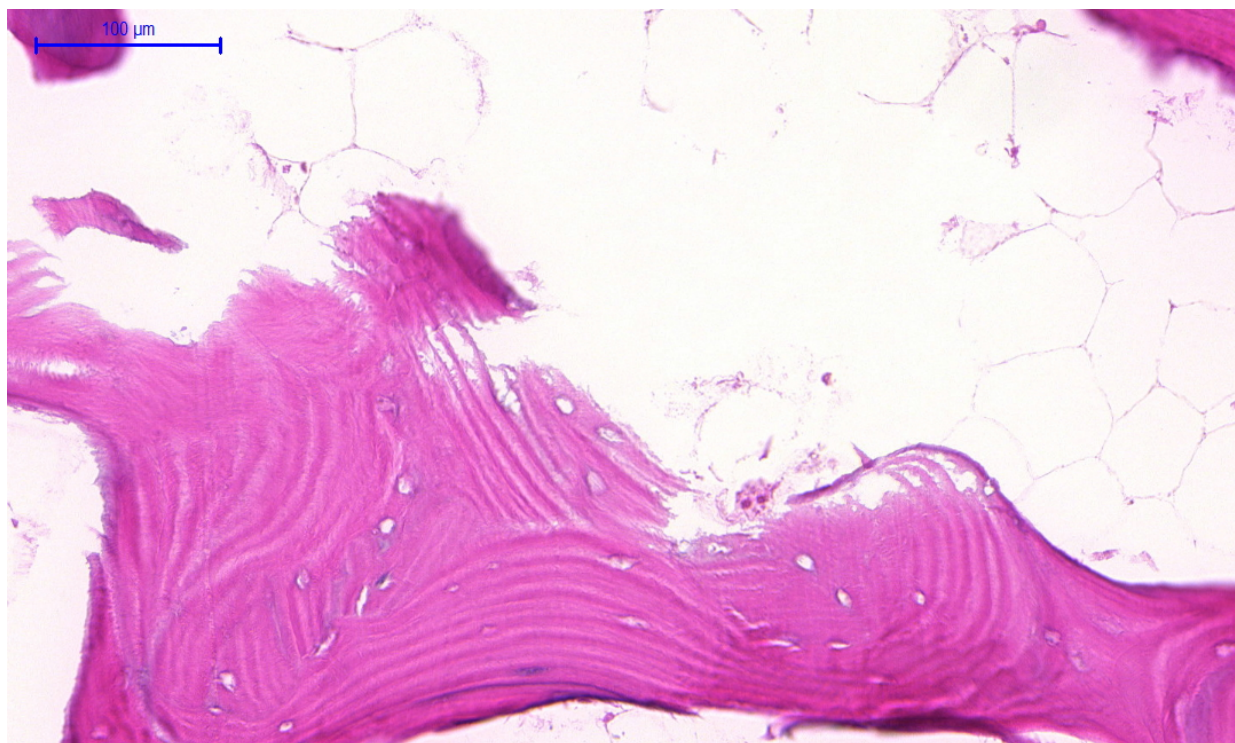


Figure 10. Slide of the central area showing osteoclastic activity with serrated bone margins with an osteoclast causing bone resorption. (H & E 20X)

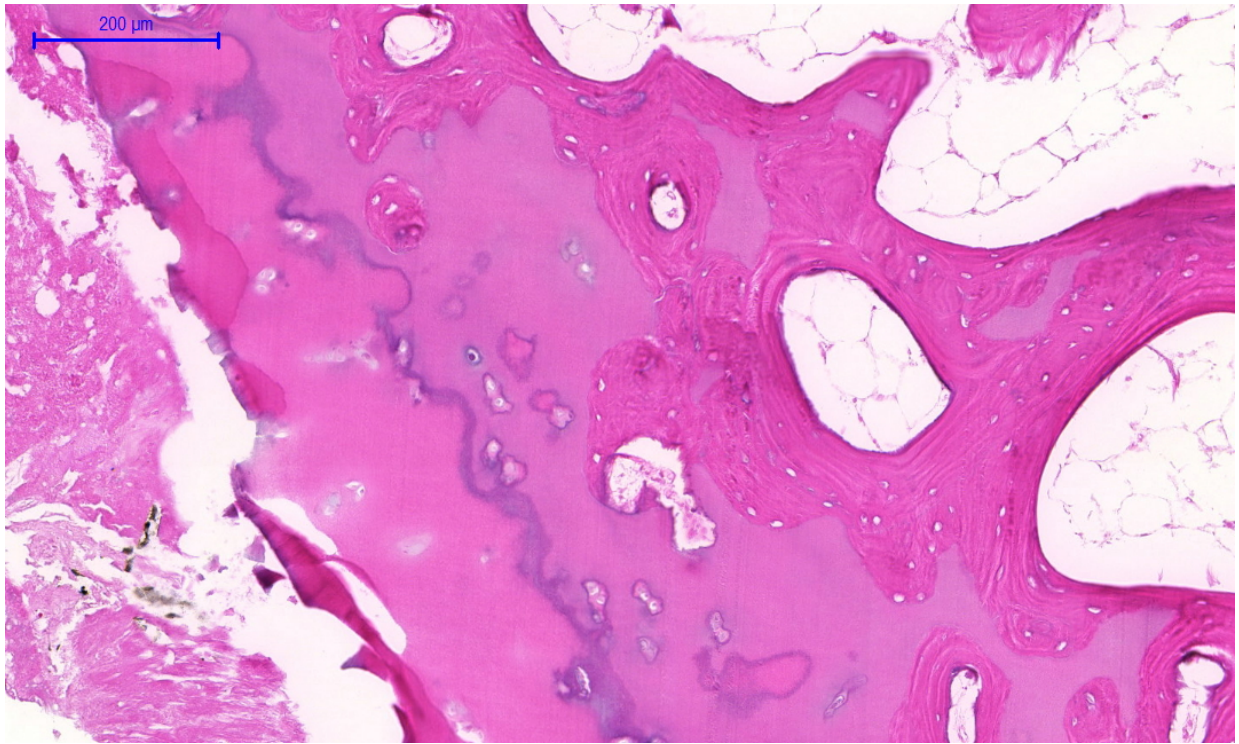


Figure 11. Same slide margin of the bone showing new bone formation (H & E 10X)

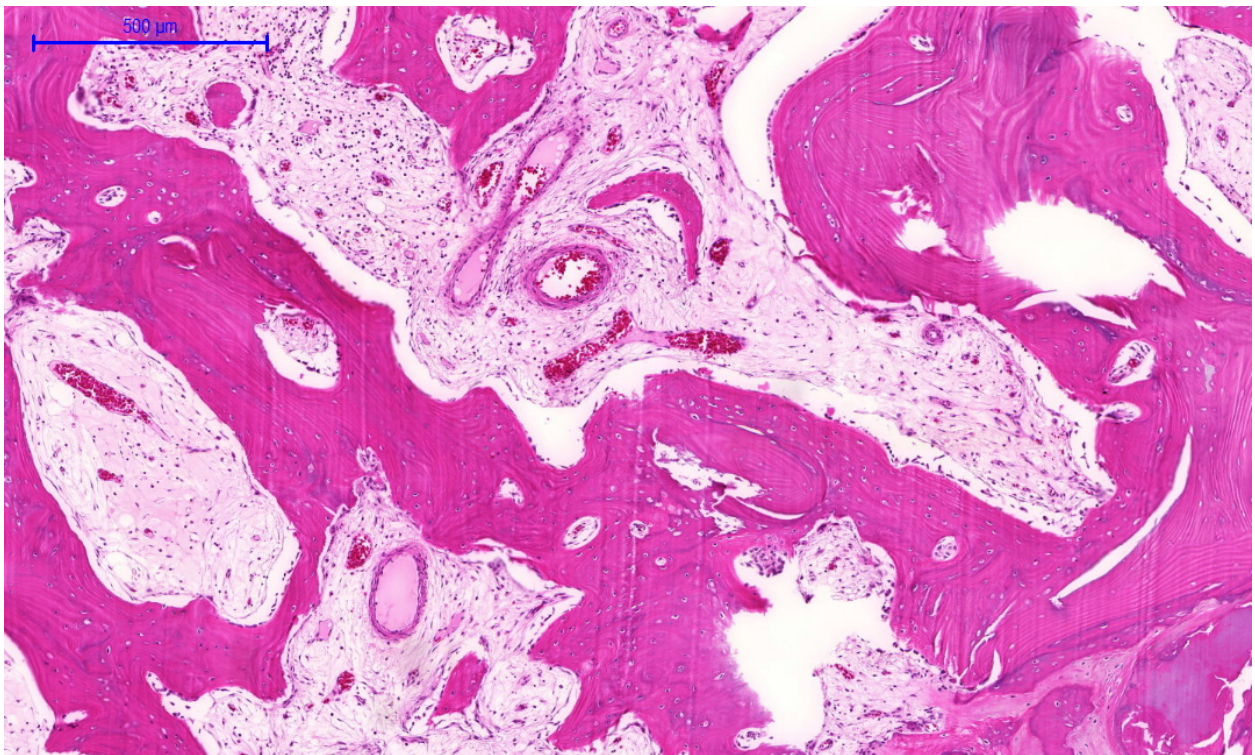


Figure 12. The posterior slice of the same patient (P8) with highly active bone with multiple blood vessels, new bone formation osteoblastic activity, live nucleated lacunae with minimal osteoclasts and bone resorption. (H & E P8 post slice 5x)

In contrast, patients showing loosening, gross osteolysis, bone resorption, show high osteoclastic activity with absence of osteoblastic features or new bone formation.

However, we also noted that both groups show good vascularity with active bones with good blood supply.

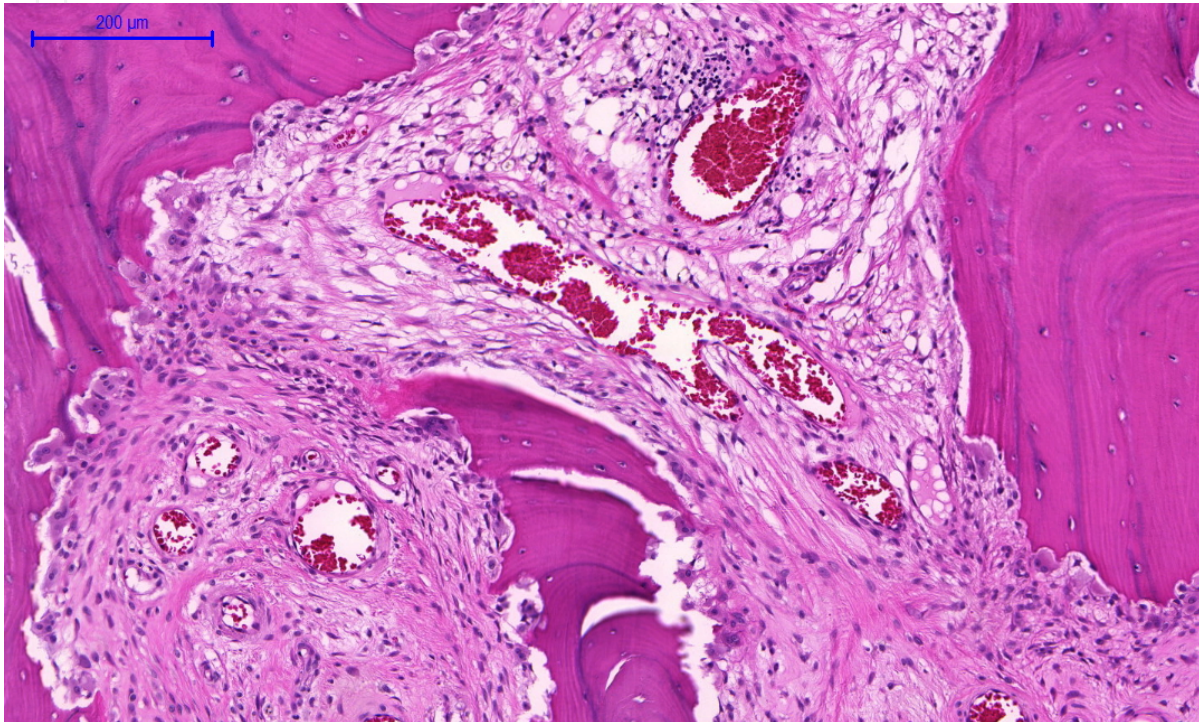


Figure 13. High osteoclastic activity leading to osteolysis along the bone showing serrated bone margin. Note the blood vessels showing good vascularity. (H & E 10x)

3.2. Immune response to foreign bodies leading to delayed hypersensitivity

This mechanism is more established as a number of studies has looked into metal ion release, osteolysis, pseudo-tumour formation, and ALVAL formation.

Metal ions have been implicated as triggering a foreign body type reaction leading to a delayed Type IV hypersensitivity. This has been attributed as a final common pathway leading to osteolysis bone destruction and failure. [51, 52, 57, 60] This may be a cause for unexplained groin pain seen in most of these [63] (Fig 13).

It is also worth mentioning that foreign body granulomas or pseudo-tumours per se may not lead to osteolysis. They can remain asymptomatic. [57, 47] However with time, as they grow in the bone and the under surface of the implant, they can act as a space occupying lesion separating the bone from the metal leading to loosening and malpositioning.

Secondly, they can also trigger immunological reactions that lead to osteolysis and femoral head resorption. As there is no direct evidence for this, this is another area that warrants further investigations and research.

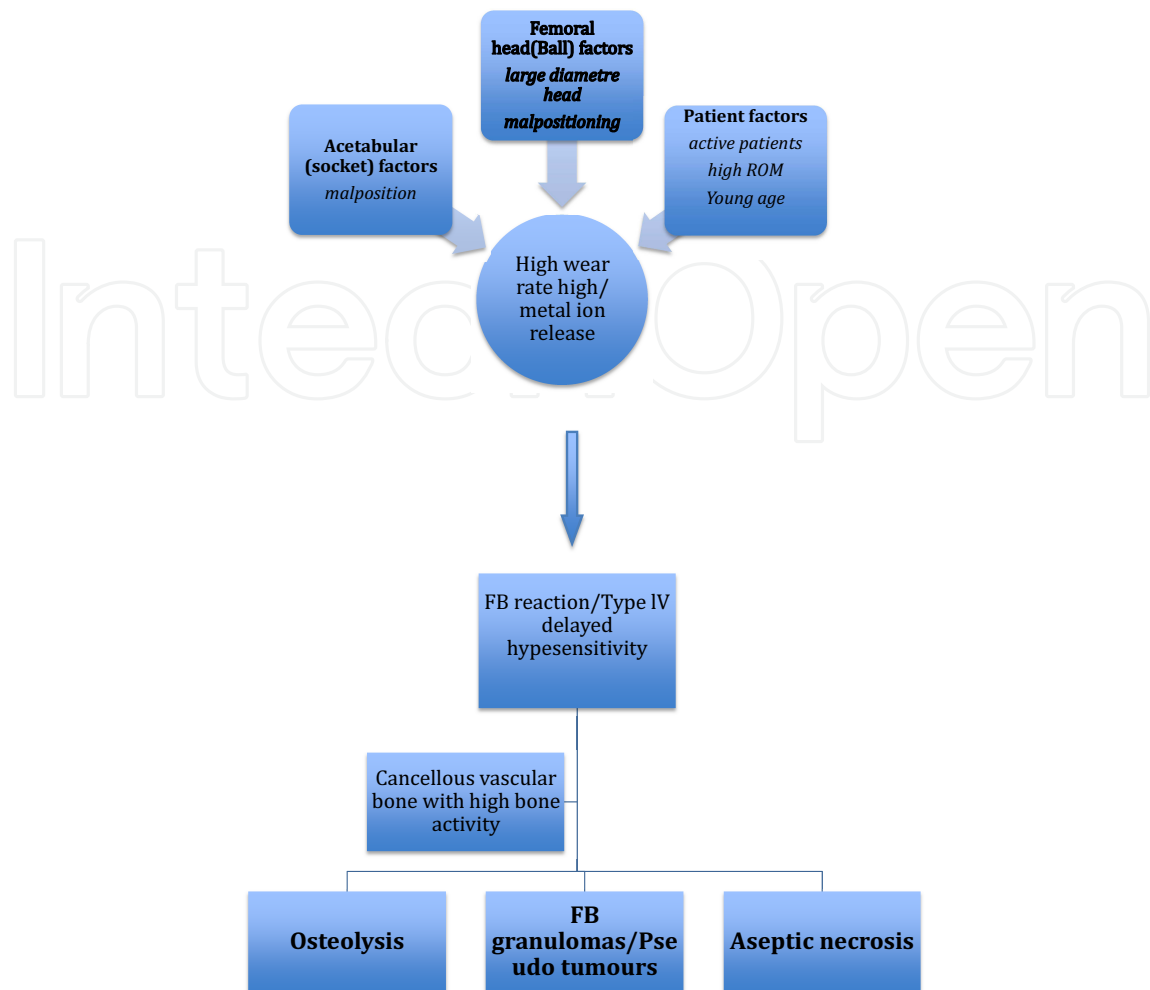


Figure 14. Mechanisms that may lead to immune response seen following hip resurfacing arthroplasty

4. Conclusions

There are many areas where new studies can be done to improve our understanding of the causes and mechanisms of failure of modern metal-on-metal hip arthroplasty.

As we have demonstrated, the causes for failure seem to be multifactorial (Fig. 14) partly due to the mechanisms that are well understood and partly due to mechanisms that at present are ill understood such as persistent groin pain and influence on metal ions.

We might have to rethink the design, taking into account that these biological factors such as femoral head and head neck are developmentally, functionally, structurally, and histologically different bones from the cortical bone. The interaction between metal and bone or cement and bone is different between the two bone types. Secondly, fixing the implant into the most mobile portion (ball of the hip joint) seem to act as a stimulation to trigger many biological responses and inflammatory reactions and immune reactions leading to new bone formation (osteoblastic response) or osteolysis (osteoclastic response).

Micro movement, caused by the loosening and release of high metal particles, made worse by a large diameter head in an environment of high bone activity with good vascularity and healing, in the femoral head seems to trigger ill-understood immune response that is osteoclastic in nature. As the fixation of the femoral component is totally dependant in this area of bone, any microscopic osteolysis can lead to loosening leading to further osteolysis and leading to a vicious cycle (Fig. 15). One option is to break this vicious cycle by having at least a part of the fixation in a less active cortical bone.

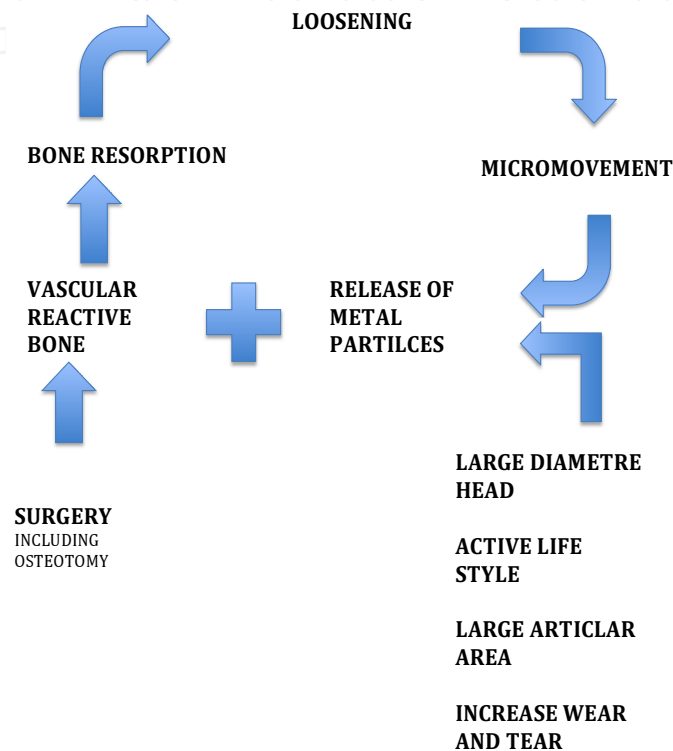


Figure 15. Vicious cycle leading to loosening

The exact relationship between the vascularity of the femoral head and the outcome of resurfacing arthroplasty is not well-established. On one hand, it is argued that vascularity is an essential element for the healing of the resurfaced femoral head to obtain a well-fixed component at the metal bone interface.

However, in spite of good vascularity, cementing can cause thermal necrosis (Fig. 3) at the cement bone interface; but all these implants do not seem to fail. "Does thermal necrosis result in failure of resurfacing arthroplasty?" is a research question that is worth exploring.

Secondly, a good vascular supply can act as a double-edged sword as it enhances bone activity, and with that can stimulate osteoclastic and immune responses (Fig. 13).

These cast doubts whether the trochanteric flip approach is necessarily a good thing as the bone activity in this approach is much higher than other approaches due to the additional osteotomy.

Thirdly, in patients who had AVN caused by non-surgical causes resurfacing arthroplasty [26, 64, 65] or partial resurfacing [66] has been used as a mode of treatment. Therefore, it is worth studying the long-term outcomes in this group in order for us to understand the relationship between vascularity and hip resurfacing.

This retrieval analysis did not demonstrate any relationship between the development of AVN and surgical approach.

One key drawback in finding the exact relationship between vascularity of the bone and AVN is the inability to work out the “critical ischemia” for bone tissue (minimal blood flow needed to keep the bone alive). Experiments that may help us to determine the “critical ischemia” of the femoral head will help us answer this question. [22]

Another limitation is difficulty in finding the bone activity in the femoral head covered by the metal implants. Even though SPECT [67, 68] and Positron Emission Tomography (PET) [69] have been used to study vascularity attenuation caused by the metal implants, they cause difficulty in interpreting the results accurately. [24, 70]

Patient No/Approach Non Posterior (NP) Posterior P	Last follow up since THR (M)	Persistent Problems (Y/N)
1 NP	42	Y (Groin Pain)
2 NP	26	N
3 NP	23	Y (Groin Pain)
4 NP	23	Y (Groin Pain)
5 NP	13	N
6 NP	Loss for follow up	
7 P	28	Died (? CAUSE) Infection
8 P	33	Y (Groin Pain)
9 P	25	Y (Groin Pain)
10 P	30	N
11 P	3.5	Y (Groin Pain)
12 P	21	N

Table 1. Follow up of revision surgery for failed hip resurfacing arthroplasty (note groin pain seem to be persistent even after revision in both groups).

According to this study, patients who had a revision for unexplained groin pain had groin pain even years after conversion to a THR (Table 1). The patients who had only a revision of acetabular component had to be revised within a mean duration of 14.5 months (10-16) to a THR due to persistent problems. These lead us to believe either the damage led to the devel-

opment of the groin pain that may be irreversible or initial factors that triggered the groin pain persists even after the conversion to a total hip replacement. Therefore, we need to rethink whether THR is the first and the only option in treating patients with persistent unexplained groin pain.

In conclusion, we believe that the failure of hip resurfacing is due to multiple factors, eventually leading to common pathological pathways leading to failure.

The significance of the contribution of each factor to the final pathways is not clear.

The fact that femoral component is fixed in the most mobile area of the joint in a relatively active patient, continuously moving the hip impacting on a relatively weak cancellous bone that constantly attempts to heal, while a large diameter head releasing high levels of metal ions leading to immunological response appear to be a recipe for disaster that finally leads to the failure of metal-on-metal hip resurfacing arthroplasty.

Acknowledgements

Special Thanks to Prof. Pat Campbell, Joint Replacement Centre University of California Los Angeles (UCLA), USA; Prof. Damian Griffin Warwick Orthopaedics, University of Warwick Medical School, University Hospitals of Coventry and Warwickshire, United Kingdom; Dr. Nick Parsons Warwick Orthopaedics, University of Warwick Medical School, University Hospitals of Coventry and Warwickshire, United Kingdom.

Author details

Hiran Wimal Amarasekera^{1,2*}

Address all correspondence to: hiruwan@hotmail.com

1 Neville Fernando Teaching Hospital and South Asian Institute of Medicine, Colombo , Sri Lanka

2 Warwick Orthopaedics, University of Warwick, Coventry, United Kingdom

References

- [1] Charnley J. Using Teflon in arthroplasty of the hip-joint. *The Journal of bone and joint surgery American volume* 1966;48(4):819.

- [2] McMinn D, Daniel J. History and modern concepts in surface replacement. *Proc Inst Mech Eng H* 2006;220(2):239-51.
- [3] Wagner H. Surface replacement arthroplasty of the hip. *Clinical orthopaedics and related research* 1978(134):102-30.
- [4] Head WC. Wagner surface replacement arthroplasty of the hip. Analysis of fourteen failures in forty-one hips. *The Journal of bone and joint surgery American volume* 1981;63(3):420-7.
- [5] Grujic H, Olerud S, Soreff J. Wagner resurfacing hip arthroplasty: preliminary results. *Acta Orthop Scand* 1982;53(5):785-9.
- [6] McMinn D, Treacy R, Lin K, et al. Metal on metal surface replacement of the hip. Experience of the McMinn prosthesis. *Clinical orthopaedics and related research* 1996(329 Suppl):S89-98.
- [7] National joint registry England and Wales, 2004.
- [8] Prime MS, Palmer J, Khan WS. The National Joint Registry of England and Wales. *Orthopedics* 2011;34(2):107-10.
- [9] McMinn DJ, Daniel J, Ziaee H, et al. Indications and results of hip resurfacing. *International orthopaedics* 2011;35(2):231-7.
- [10] Rechl H, Pilge H, Rudert M. [Development of hip resurfacing]. *Der Orthopade* 2008;37(7):626-33.
- [11] Gross TP, Liu F. Prevalence of dysplasia as the source of worse outcome in young female patients after hip resurfacing arthroplasty. *International orthopaedics* 2012;36(1):27-34.
- [12] Bose VC, Baruah BD. Resurfacing arthroplasty of the hip for avascular necrosis of the femoral head: a minimum follow-up of four years. *The Journal of bone and joint surgery British volume* 2010;92(7):922-8.
- [13] Underwood RJ, Zografos A, Sayles RS, et al. Edge loading in metal-on-metal hips: low clearance is a new risk factor. *Proc Inst Mech Eng H* 2012;226(3):217-26.
- [14] Beaulé PE, Campbell PA, Hoke R, et al. Notching of the femoral neck during resurfacing arthroplasty of the hip: a vascular study. *The Journal of bone and joint surgery British volume* 2006;88(1):35-9.
- [15] Kohan L, Field CJ, Kerr DR. Early complications of hip resurfacing. *The Journal of arthroplasty* 2012;27(6):997-1002.
- [16] Amstutz HC, Le Duff MJ. Eleven years of experience with metal-on-metal hybrid hip resurfacing: a review of 1000 conserve plus. *The Journal of arthroplasty* 2008;23(6 Suppl 1):36-43.

- [17] Morlock MM, Bishop N, Stahmer F, et al. [Reasons for failure of hip resurfacing implants. A failure analysis based on 250 revision specimens]. *Der Orthopade* 2008;37(7):695-703.
- [18] Morlock MM, Bishop N, Zustin J, et al. Modes of implant failure after hip resurfacing: morphological and wear analysis of 267 retrieval specimens. *The Journal of bone and joint surgery American volume* 2008;90 Suppl 3:89-95.
- [19] Amarasekera H, Costa M, Prakash U, et al. FEMORAL BLOOD FLOW DURING HIP RESURFACING: A COMPARISON OF TWO APPROACHES USING LASER DOPPLER FLOW MEASUREMENT. *Journal of Bone & Joint Surgery, British Volume* 2012;94-B(SUPP III):148.
- [20] Beaulé PE, Campbell P, Shim P. Femoral head blood flow during hip resurfacing. *Clinical orthopaedics and related research* 2007;456:148-52.
- [21] Griffiths DE, Acton K, Hull JB. Hip resurfacing with preservation of femoral head blood supply. *Surgeon* 2008;6(2):115-9.
- [22] Amarasekera HW, Costa ML, Foguet P, et al. The blood flow to the femoral head/neck junction during resurfacing arthroplasty: A COMPARISON OF TWO APPROACHES USING LASER DOPPLER FLOWMETRY. *The Journal of bone and joint surgery British volume* 2008;90(4):442-5.
- [23] Ganz R, Gill TJ, Gautier E, et al. Surgical dislocation of the adult hip: A TECHNIQUE WITH FULL ACCESS TO THE FEMORAL HEAD AND ACETABULUM WITHOUT THE RISK OF AVASCULAR NECROSIS. *The Journal of bone and joint surgery British volume* 2001;83-B(8):1119-24.
- [24] Amarasekera H, Roberts P, Costa M, et al. Scintigraphic assessment of bone status at one year following hip resurfacing: comparison of two surgical approaches using SPECT-CT scan. *Bone and Joint Research* 2012;1(1):86-92.
- [25] Campbell P, Mirra J, Amstutz HC. Viability of femoral heads treated with resurfacing arthroplasty. *The Journal of arthroplasty* 2000;15(1):120-2.
- [26] Boyd HS, Ulrich SD, Seyler TM, et al. Resurfacing for Perthes disease: an alternative to standard hip arthroplasty. *Clinical orthopaedics and related research* 2007;465:80-5.
- [27] Grecula MJ. Resurfacing arthroplasty in osteonecrosis of the hip. *Orthop Clin North Am* 2005;36(2):231-42, x.
- [28] Schmalzried TP. Total resurfacing for osteonecrosis of the hip. *Clinical orthopaedics and related research* 2004(429):151-6.
- [29] Gerdesmeyer L, Gollwitzer H, Bader R, et al. [Surgical approaches in hip resurfacing]. *Der Orthopade* 2008;37(7):650-8.

- [30] McBryde CW, Revell MP, Thomas AM, et al. The influence of surgical approach on outcome in Birmingham hip resurfacing. *Clinical orthopaedics and related research* 2008;466(4):920-6.
- [31] Beaulé PE, Shim P, Banga K. Clinical experience of Ganz surgical dislocation approach for metal-on-metal hip resurfacing. *The Journal of arthroplasty* 2009;24(6 Suppl):127-31.
- [32] Kreuzer S, Leffers K, Kumar S. Direct anterior approach for hip resurfacing: surgical technique and complications. *Clinical orthopaedics and related research* 2011;469(6):1574-81.
- [33] Jacobs MA, Goytia RN, Bhargava T. Hip resurfacing through an anterolateral approach. Surgical description and early review. *The Journal of bone and joint surgery American volume* 2008;90 Suppl 3:38-44.
- [34] H A. Surgical approaches to the hip joint and its clinical implications in adult hip arthroplasty. In: Knove P, ed. *Arthroplasty*. 1 ed. Croatia: INTECH, 2013:3-19.
- [35] Marker DR, Seyler TM, Jinnah RH, et al. Femoral neck fractures after metal-on-metal total hip resurfacing: a prospective cohort study. *The Journal of arthroplasty* 2007;22(7 Suppl 3):66-71.
- [36] Amanatullah DF, Cheung Y, Di Cesare PE. Hip resurfacing arthroplasty: a review of the evidence for surgical technique, outcome, and complications. *Orthop Clin North Am* 2010;41(2):263-72.
- [37] Amstutz HC, Takamura KM, Le Duff MJ. The effect of patient selection and surgical technique on the results of Conserve(R) Plus hip resurfacing--3.5- to 14-year follow-up. *Orthop Clin North Am* 2011;42(2):133-42, vii.
- [38] Della Valle CJ, Nunley RM, Barrack RL. When is the right time to resurface? *Orthopedics* 2008;31(12 Suppl 2).
- [39] Jameson SS, Langton DJ, Natsu S, et al. The influence of age and sex on early clinical results after hip resurfacing: an independent center analysis. *The Journal of arthroplasty* 2008;23(6 Suppl 1):50-5.
- [40] Bitsch RG, Jager S, Lurssen M, et al. Influence of bone density on the cement fixation of femoral hip resurfacing components. *Journal of orthopaedic research : official publication of the Orthopaedic Research Society* 2010;28(8):986-91.
- [41] Kim PR, Beaulé PE, Laflamme GY, et al. Causes of early failure in a multicenter clinical trial of hip resurfacing. *The Journal of arthroplasty* 2008;23(6 Suppl 1):44-9.
- [42] Hull P, Baxter JA, Lewis C, et al. Metal-on-metal hip resurfacing with uncemented fixation of the femoral component. A minimum 2 year follow up. *Hip international : the journal of clinical and experimental research on hip pathology and therapy* 2011.

- [43] Ritter MA, Lutgring JD, Berend ME, et al. Failure mechanisms of total hip resurfacing: implications for the present. *Clinical orthopaedics and related research* 2006;453:110-4.
- [44] Beaulé PE, Le Duff M, Campbell P, et al. Metal-on-metal surface arthroplasty with a cemented femoral component: a 7-10 year follow-up study. *The Journal of arthroplasty* 2004;19(8 Suppl 3):17-22.
- [45] Campbell P, Takamura K, Lundergan W, et al. Cement technique changes improved hip resurfacing longevity - implant retrieval findings. *Bulletin of the NYU hospital for joint diseases* 2009;67(2):146-53.
- [46] Gill HS, Campbell PA, Murray DW, et al. Reduction of the potential for thermal damage during hip resurfacing. *The Journal of bone and joint surgery British volume* 2007;89(1):16-20.
- [47] Malviya A, Holland JP. Pseudotumours associated with metal-on-metal hip resurfacing: 10-year Newcastle experience. *Acta Orthop Belg* 2009;75(4):477-83.
- [48] A survey on the prevalence of pseudotumors with metal-on-metal hip resurfacing in Canadian academic centers. *The Journal of bone and joint surgery American volume* 2011;93 Suppl 2:118-21.
- [49] Brooks P. Component malposition in hip resurfacing. *Orthopedics* 2010;33(9):646.
- [50] Delaunay C, Petit I, Learmonth ID, et al. Metal-on-metal bearings total hip arthroplasty: the cobalt and chromium ions release concern. *Orthop Traumatol Surg Res* 2010;96(8):894-904.
- [51] Akbar M, Brewer JM, Grant MH. Effect of chromium and cobalt ions on primary human lymphocytes in vitro. *J Immunotoxicol* 2011;8(2):140-9.
- [52] Kwon YM, Thomas P, Summer B, et al. Lymphocyte proliferation responses in patients with pseudotumors following metal-on-metal hip resurfacing arthroplasty. *Journal of orthopaedic research : official publication of the Orthopaedic Research Society* 2010;28(4):444-50.
- [53] Mahendra G, Pandit H, Kliskey K, et al. Necrotic and inflammatory changes in metal-on-metal resurfacing hip arthroplasties. *Acta Orthop* 2009;80(6):653-9.
- [54] Hart AJ, Skinner JA, Henckel J, et al. Insufficient Acetabular Version Increases Blood Metal Ion Levels after Metal-on-metal Hip Resurfacing. *Clinical orthopaedics and related research* 2011;469(9):2590-7.
- [55] Mai MC, Milbrandt JC, Hulsen J, et al. Acetabular cup malalignment after total hip resurfacing arthroplasty: a case for elective revision? *Orthopedics* 2009;32(11):853.
- [56] Kim PR, Beaulé PE, Dunbar M, et al. Cobalt and chromium levels in blood and urine following hip resurfacing arthroplasty with the Conserve Plus implant. *The Journal of bone and joint surgery American volume* 2011;93 Suppl 2:107-17.

- [57] Kwon YM, Ostlere SJ, McLardy-Smith P, et al. "Asymptomatic" pseudotumors after metal-on-metal hip resurfacing arthroplasty: prevalence and metal ion study. *The Journal of arthroplasty* 2011;26(4):511-8.
- [58] Antoniou J, Zukor DJ, Mwale F, et al. Metal ion levels in the blood of patients after hip resurfacing: a comparison between twenty-eight and thirty-six-millimeter-head metal-on-metal prostheses. *The Journal of bone and joint surgery American volume* 2008;90 Suppl 3:142-8.
- [59] Beaulé PE, Kim PR, Hamdi A, et al. A prospective metal ion study of large-head metal-on-metal bearing: a matched-pair analysis of hip resurfacing versus total hip replacement. *Orthop Clin North Am* 2011;42(2):251-7, ix.
- [60] Moroni A, Savarino L, Hoque M, et al. Do ion levels in hip resurfacing differ from metal-on-metal THA at midterm? *Clinical orthopaedics and related research* 2011;469(1):180-7.
- [61] Matthies A, Underwood R, Cann P, et al. Retrieval analysis of 240 metal-on-metal hip components, comparing modular total hip replacement with hip resurfacing. *The Journal of bone and joint surgery British volume* 2011;93(3):307-14.
- [62] Buechel FF, Drucker D, Jasty M, et al. Osteolysis around uncemented acetabular components of cobalt-chrome surface replacement hip arthroplasty. *Clinical orthopaedics and related research* 1994(298):202-11.
- [63] Campbell P, Shimmin A, Walter L, et al. Metal sensitivity as a cause of groin pain in metal-on-metal hip resurfacing. *The Journal of arthroplasty* 2008;23(7):1080-5.
- [64] Larson AN, McIntosh AL, Trousdale RT, et al. Avascular necrosis most common indication for hip arthroplasty in patients with slipped capital femoral epiphysis. *J Pediatr Orthop* 2010;30(8):767-73.
- [65] Drescher W, Pufe T, Smeets R, et al. [Avascular necrosis of the hip - diagnosis and treatment]. *Z Orthop Unfall* 2011;149(2):231-40; quiz 41-2.
- [66] Siguier T, Siguier M, Judet T, et al. Partial resurfacing arthroplasty of the femoral head in avascular necrosis. Methods, indications, and results. *Clinical orthopaedics and related research* 2001(386):85-92.
- [67] McMahan SJ, Young D, Ballok Z, et al. Vascularity of the femoral head after Birmingham hip resurfacing. A technetium Tc 99m bone scan/single photon emission computed tomography study. *The Journal of arthroplasty* 2006;21(4):514-21.
- [68] Leunig M, Ganz R. Vascularity of the femoral head after Birmingham hip resurfacing. A technetium Tc 99m bone scan/single photon emission computed tomography study. *The Journal of arthroplasty* 2007;22(5):784-5; author reply 85-6.
- [69] Forrest N, Welch A, Murray AD, et al. Femoral head viability after Birmingham resurfacing hip arthroplasty: assessment with use of [18F] fluoride positron emission

tomography. *The Journal of bone and joint surgery American* volume 2006;88 Suppl 3:84-9.

- [70] Amarasekera HW, Costa ML, Parsons N, et al. SPECT/CT bone imaging after hip resurfacing arthroplasty: is it feasible to use CT attenuation correction in the presence of metal implants? *Nuclear medicine communications* 2011;32(4):289-97.

IntechOpen

IntechOpen

