

# We are IntechOpen, the world's leading publisher of Open Access books Built by scientists, for scientists

4,800

Open access books available

122,000

International authors and editors

135M

Downloads

Our authors are among the

154

Countries delivered to

TOP 1%

most cited scientists

12.2%

Contributors from top 500 universities



WEB OF SCIENCE™

Selection of our books indexed in the Book Citation Index  
in Web of Science™ Core Collection (BKCI)

Interested in publishing with us?  
Contact [book.department@intechopen.com](mailto:book.department@intechopen.com)

Numbers displayed above are based on latest data collected.  
For more information visit [www.intechopen.com](http://www.intechopen.com)



---

# Experiences of 30 Years in Right Trisectionectomy for Huge Liver Tumor

---

Jing An Rui

Additional information is available at the end of the chapter

<http://dx.doi.org/10.5772/61175>

---

## Abstract

Hepatocellular carcinoma (HCC) is the fifth most common cancer in the world and the third leading cause of cancer-related deaths. Up to now, surgery remains to be the main curative strategy for hepatocellular carcinoma. In this article the author summarizes his experiences of 30 years in right trisectionectomy for huge liver tumor. A total of 459 primary liver cancer patients were hepatomized in author's group. Among them, 33 cases of right trisectionectomies were performed under continuous single interruption of the porta hepatis. The 1-, 3-, and 5-year survival rates were 71.9%, 40.6%, and 34.4%, respectively. The longest cancer-free survival of right trisectionectomy in our group is 26 years. In the author's another cohort, 51 patients underwent hepatectomy without allogeneic blood transfusion. Compared with the control group containing 60 patients who underwent hepatectomy with allogeneic blood transfusion, the morbidity and recurrence rates in the group without allogeneic blood transfusion were significantly decreased ( $P < 0.05$ ). Surgical anatomy study of the hepatic veins and case reports are also included in this article. Taken together, it is obvious that right trisectionectomy under continuous single interruption of the porta hepatis without allogeneic blood transfusion would benefit the patient with resectable huge HCC.

**Keywords:** primary liver cancer, right trisectionectomy, continuous single interruption of the porta hepatis, surgical anatomy of hepatic veins, major hepatectomy without allogeneic blood transfusion

---

## 1. Introduction

Hepatocellular carcinoma (HCC) is the fifth most common cancer in the world and the third leading cause of cancer-related deaths. More than 80% of HCC cases are from the Asian and African continents, and more than 50% of cases are from mainland China. It is estimated that more than 50% of liver cancers worldwide are attributable to HBV, and up to 89% of HBV-

---

related HCC cases are from developing countries [1]. Recently, increasing trends in HCC incidence have been reported from several western countries, including France, Australia, and the United States, mainly because of the rising incidence of HCV [2]. At least one million new cases of HCC occur annually, and mortality from this disease remains high despite treatment. It was reported that 10–20% of newly diagnosed HCCs are >10 cm in diameter, which is commonly defined as huge HCC. Patients with huge HCC who survive more than 5 years were rarely reported in the literature. Recently, it is reported that a 5-year survival rate is less than 3–5% if without treatment. The mean overall survival rates via treatments at 1 year, 3 years, and 5 years are 66.1%, 39.7%, and 32.5%, respectively, 93.5%, 70.1%, and 59.1% for early-stage patients [1, 3–5]. Several novel strategies have been developed for the therapy of HCC in recent years, and the outcomes have taken marked progress. However, recurrence and metastasis rates remain high. Up to now, surgery, including hepatectomy and liver transplantation, remains to be the main curative strategy for hepatocellular carcinoma.

The developing history of hepatic surgery is strongly involved in the history of bleeding control during hepatic resections. In the early 1900s, a small but significant step forward was made in liver surgery by J. Hogarth Pringle [6], who in 1908 described a method for digital compression of the hilar vessels to control hepatic bleeding from traumatic injuries. Since the middle of the last century, right trisectionectomy (previous trisegmentectomy) has been used for huge hepatic neoplasms covering right and left medial section (Figure 1). In 1975, Starzl [7] described and clearly defined in detail a safe technique of right trisectionectomy (Figure 2). Then he reported his experience on 30 cases of the operation in 1980, including malignant and benign hepatic lesion [8]. Rui [9] reported his experience of 33 cases of primary liver cancer patients undergoing right trisectionectomy.

## 2. Selection of patients for right trisectionectomy of huge liver tumor

Up to now, the treatment of huge liver cancers is still very difficult due to poor outcomes and higher mortality and morbidity [9–11]. A number of reports have indicated that right trisectionectomy is effective for extensive hepatic malignancy, based on patients who have had long-term survival after this operation [9,12,13].

The situations of tumor were detected mainly by image examinations, including B-type ultrasonography, computed tomography (CT), magnetic resonance imaging (MRI), and angiography. To assess liver function of the patients before operation, we adopted the classic Child–Pugh classification, the ICGR test, and some concrete parameters, as described in standards [9].

The feasibility of right trisectionectomy for a given patient must be carefully evaluated according to the following criteria [9]: (1) tumor(s), including less than 2 satellite nodules, must be limited to the right lobe and left medial portion of the liver (there is no evidence of cancer invasion in left lateral segment); (2) tumor mass with clear borders or a pseudocapsule, and there is no tumor thrombus in the trunk of the portal vein and hepatic vein; (3) there is no evidence of distant metastasis; (4) compensatory enlargement of the left lateral section should

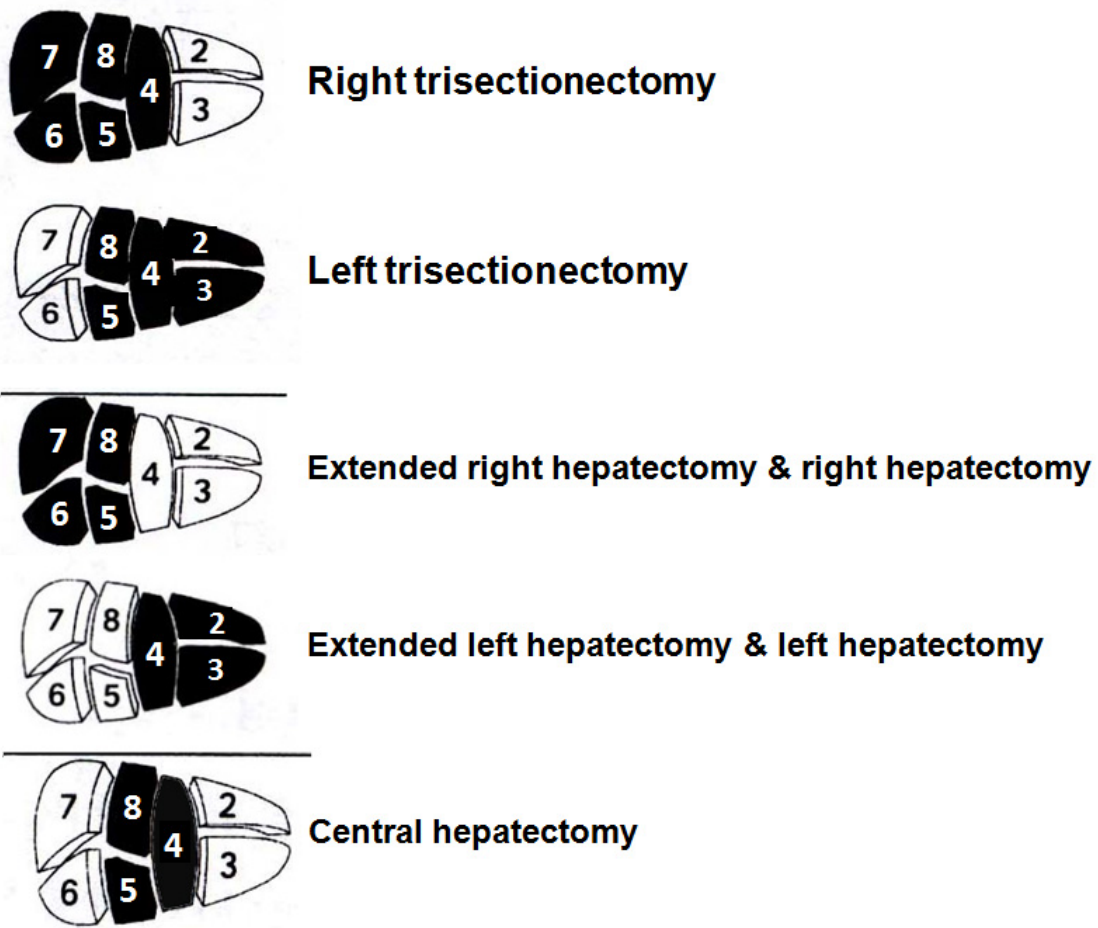


Figure 1. Photograph shows major hepatectomy. The regions in black color present the resected parts of the liver in various major hepatectomy.

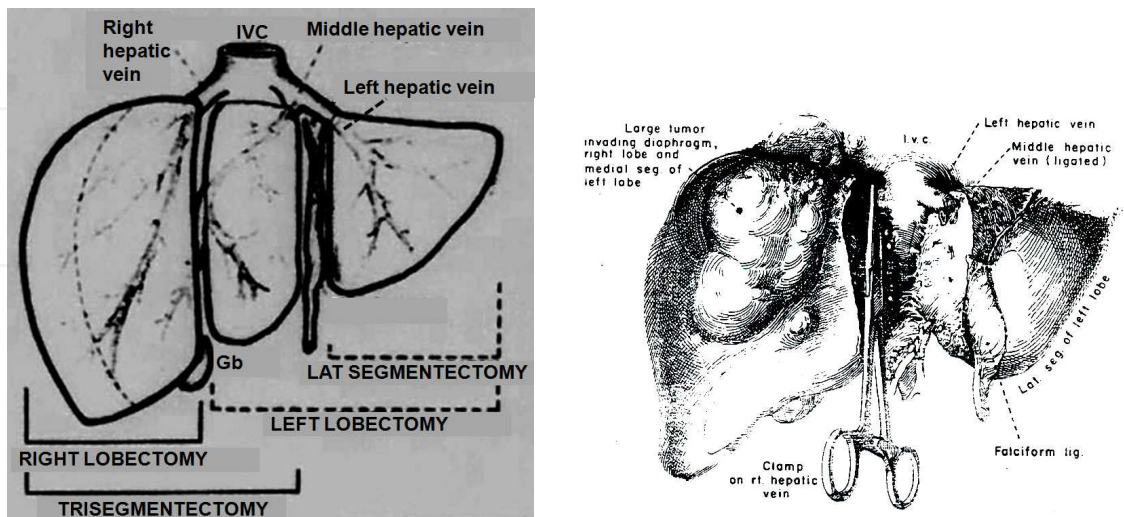


Figure 2. Photograph from Prof. TE Starzl shows right trisectionectomy.

be obvious; (5) the Child–Pugh classification of liver function must be grade “A” and the indocyanine green retention rate at 15 min (ICGR 15) should be lower than 15% before surgery; and (6) serum bilirubin is less than 34 mmol/L, serum albumin higher than 30 g/L, and serum prothrombin time larger than 60% before surgery.

A total of 459 primary liver cancer patients were hepatomized in our group. Among them, 33 cases of right trisectionectomies were performed. The patients included 24 males (72.7%) and 9 females (27.3%) with ages ranging from 15 to 69 years. Of the 33 cases, 28 (84.8%) were hepatitis B surface antigen (HBsAg) positive and 5 (15.2%) were negative. There were 8/33 cases (24.2%) with slight cirrhosis and 25/33 cases (75.8%) without cirrhosis; 22/33 cases (66.7%) were grade A in Child–Pugh classification, and 11/33 cases (33.3%) were grade B when the patients were hospitalized, but became grade A before surgical procedures through positive hepatic protective therapy; 27/33 cases (81.8%) with elevated serum  $\alpha$ -fetoprotein (the highest value of AFP was 20,000 ng/ml) and 6/33 cases (18.2%) with normal  $\alpha$ -fetoprotein. Sizes of tumor ranged from 8 to 20 cm. The stage of tumors was all IVa (T4N0M0). Pathological examination showed that 27 cases (81.8%) were hepatocellular carcinoma, 2 cases (6.1%) were cholangiocarcinoma, and 4 cases (12.1%) were mixed hepatocellular cholangiocarcinoma. Tumor thrombi were found in 17 cases (51.5%) in the right branch of the portal vein. Macroscopic satellite nodules were found in 15 cases (45.5%) and did not presented in left lateral section of the liver. All right trisectionectomies were performed under continuous single interruption of porta hepatis. The 1-, 3-, and 5-year survival rates after right trisectionectomy were 71.9%, 40.6%, and 34.4%, respectively [9]. The longest cancer-free survival of right trisectionectomy in our group is 26 years. This patient is still alive in Beijing. Recently, it is reported from The National Health and Family Planning Commission of The People's Republic of China that a mean of 5-year survival rate for HCC is 10.1% in China. It is obvious that right trisectionectomy would benefit the patients with resectable huge HCC.

### **3. Surgical procedures characterized by continuous single interruption of the porta hepatis for right trisectionectomy**

Foster said (1989), “Surgical technique is an art form. It can be very personal, based mostly on experience, or it can take a cookbook approach. For many standard operations, we follow in the ruts created by our teachers, perhaps adding a nuance or two called forth by an unusual situation or by a creative mind. Unfortunately, many years ago when I needed help, there was no available to teach me to operate on the liver” [14].

Multiple intermittent hepatic inflow occlusion for hepatic resection had been proposed. The significance of intermittent hepatic inflow occlusion for hepatectomy had been generally accepted [15]. Belghiti et al. [16] demonstrated that the intermittent interruption of flow through the porta hepatis with periods of 15 min of clamping and 5 min of unclamping led to better parenchymal tolerance than continuous flow interruption, especially in patients with abnormal liver parenchyma. The total ischemic time under intermittent interruption of flow through the porta hepatis for hepatectomy was approximately 30–90 min (2–6 times of

clamping for 15 min each time). Nevertheless, in 1988, Rui reported his work on hepatectomy for primary liver cancer in Queen Mary Hospital (Hong Kong) titled *100 Cases of Hepatectomy under Normothermic Continuously Single Interruption of Porta Hepatis without Mortality*. We performed successfully major hepatectomy (Figure 1) for totally about 600 patients with HCC combined mostly with cirrhosis under normothermic continuous single interruption of porta hepatis. These studies were summarized in 20 cases of hemihepatectomy [17]; 4 cases of right trisectomy [18]; 179 cases of major hepatectomy, including 54 patients in elderly group and 125 in the nonelderly group [19]; and 33 cases of right trisectomy [9]. In the 179 cases of major hepatectomy, the surgical procedures were shown in Tables 1 and 2. The postoperative complication rate was 10.6% (19/179), and the operative mortality was 1.1% (2/179). We noted that elderly HCC patients tend to presentations of significantly lower HBsAg positivity, smaller tumor sizes, less portal vein tumor thrombi (PVTT) and satellite nodule formation, earlier TNM staging, better differentiated tumors, less progressive, less aggressive, and less intrahepatically recurrence than that in the nonelderly. We found that Child–Pugh grading, PVTT, and Edmondson–Steiner grading independently predict postsurgical prognosis of elderly patients with HCC. In 2015, Uwatoko et al. [20] reported two cases of patients over 90 years old who underwent major hepatectomy for HCC, representing the oldest patients in the world to have done so. Generally, hepatectomy can be well tolerated for the elderly HCC patients, and a beneficial outcome similar to that of the nonelderly individuals can be expected, despite they had poorer liver function.

Surgical type	Elderly group (≥65 years) (n = 54 )	Nonelderly group (≤65 years ) (n= 125 )
Right trisectomy	2	23
Left trisectomy	1	1
Extended right hepatectomy	2	11
Extended left hepatectomy		3
Right hepatectomy	9	20
Left hepatectomy	2	11
Central hepatectomy		4
Combined segmentectomy	20	34
Segmentectomy	8	6
Left lateral segmentectomy	5	7
Nonanatomical resection	5	5

**Table 1.** Summary of surgical type in 179 major hepatectomy under normothermic continuous single interruption of porta hepatis

In all of the major hepatectomy performed in our cohorts, the ischemic time under continuous single interruption of porta hepatis lasts generally 15 to 20 min, occasionally 40 min. The mean

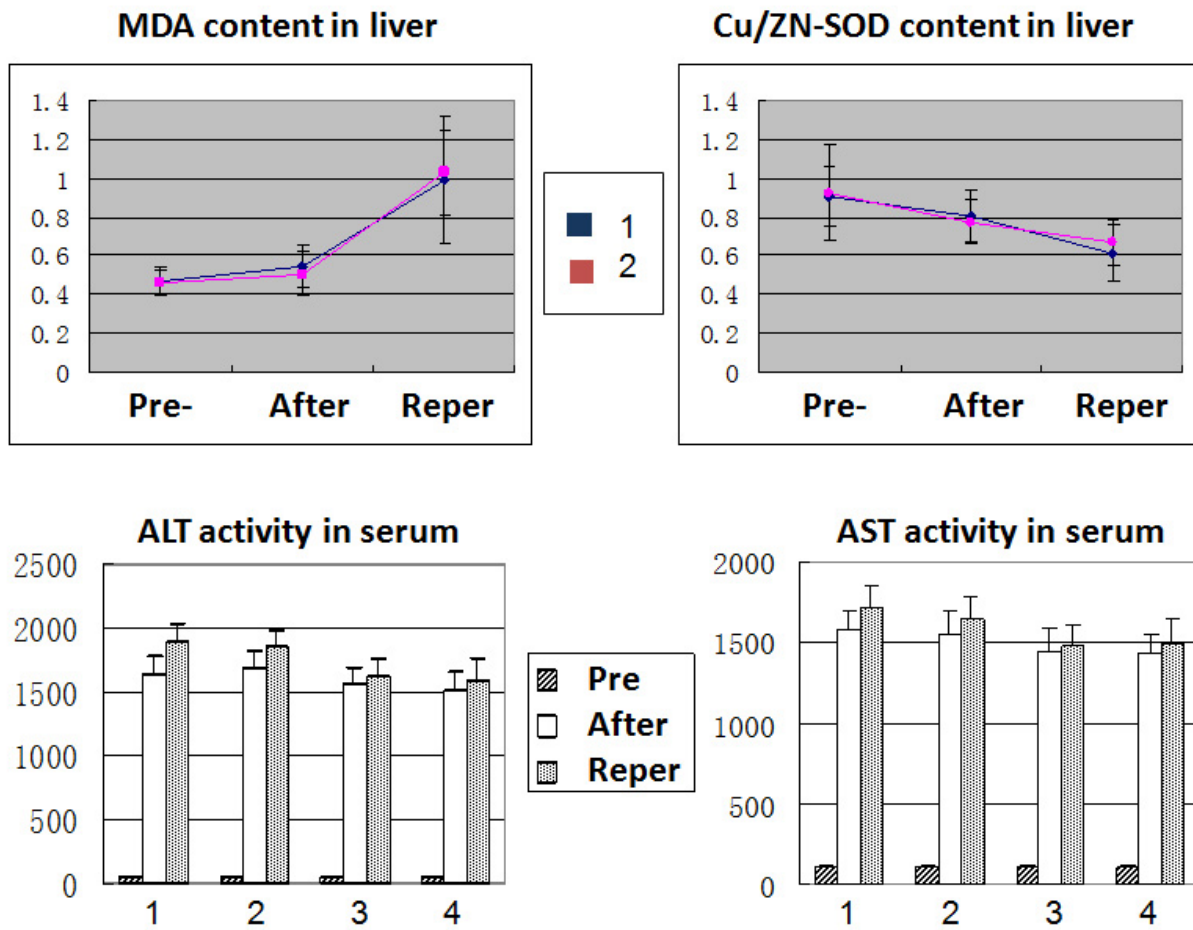
Year	Overall survival rate	Cancer-free survival rate
1	82.0%	73.1%
2	56.7%	53.2%
3	51.1%	46.0%
4	46.2%	44.5%
5	40.2%	38.1%

**Table 2.** Survival rate of 179 cases of major hepatectomy for HCC under single time interruption of the porta hepatis

ischemic time in our cohorts is 20.6 min, which is much less than that of multiple intermittent hepatic inflow occlusion of the porta hepatic for major hepatectomy. The mean bleeding amount is 400 ml (400–2000 ml). The mortality and morbidity rates were 1.2% and 24.7%, respectively, indicating that the procedure can be carried out safely. In the process of hepatic resection under normothermic continuous single interruption of porta hepatis, the operative blood losing is much less, and the operating time is much shorter than that under multiple intermittent hepatic inflow occlusion. Capussotti et al. [21] reported their results of a prospective, randomized clinical trial from Italy that is similar to our experience. It is obvious that major hepatectomy under normothermic continuous single interruption of porta hepatis can be well performed if the surgeon has meticulous skill in liver surgery. Therefore, the intermittent interruption of the porta hepatis may not be generally necessary. It is now commonly agreed that compared with intermittent multiple hepatic inflow occlusions, continuous single interruption of porta hepatis can simplify procedures, shorten operating time, and reduce blood losing, especially during transaction of liver parenchyma. In addition, it is well known that reperfusion injury following ischemia is a clinically important process that contributes significantly to tissue damage [22,23]. Continuous single interruption of the porta hepatis during liver resection not only diminishes blood losing but also may attenuate reperfusion injury following ischemia as compared with multiple intermittent interruption of the porta hepatis.

Moreover, we have demonstrated via animal experiment on rats that intermittent or continuous clamping leads to similar extent of postischemic liver injury after a total 40 min clamping of porta hepatis [24]. The total 40 min interruption of porta hepatis, either intermittently or continuously, may cause reversible liver injury shown mainly by ALT and AST, and slightly by MDA and SOD in rats (Figure 3). Structural alteration was seen in liver tissue and hepatocytes but could recover gradually after blood perfusion was restored. Notably, no significant difference is seen in biochemical and structural injury between multiple intermittent and continuous single interruption, i.e., continuous single interruption of porta hepatis within 40 min would not significantly enhance the reversible injury of either liver structure detected by light and electron microscopy or liver functions detected by ALT and AST compared with the injury resulted from multiple intermittent interruption. Moreover, the levels of MDA, which is a marker for injury of peroxidation, resulted from ischemia/reperfusion, and SOD, which represents the scavenging potential for oxygen free radical, have no significant difference

between continuous single interruption and intermittent interruption of porta hepatis for the total 40 min ischemia ( $p>0.05$ ). In addition, this experiment showed that GSH might be a protectant from liver injury that resulted from ischemia/reperfusion ( $p<0.05$ ) [22].



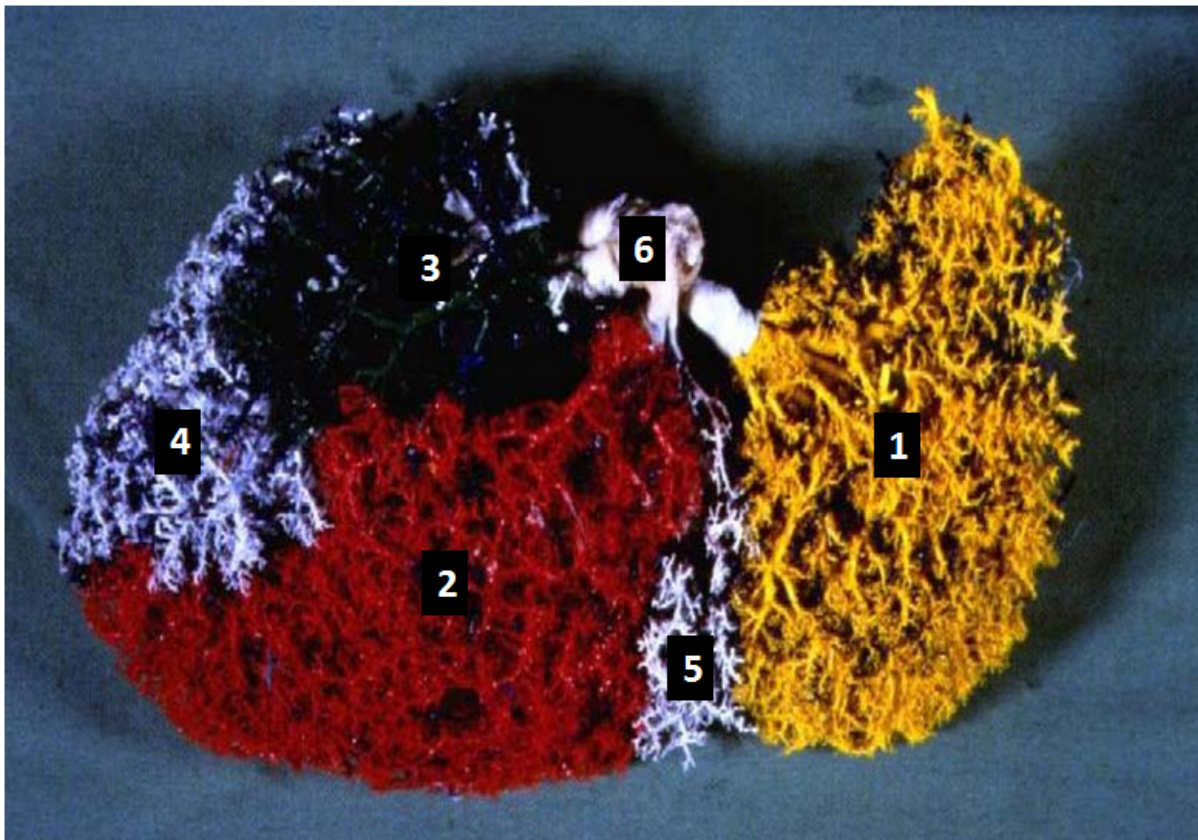
**Figure 3.** Comparison of liver injury induced by continuous single interruption and intermittent interruption of the porta hepatis via experiment on rats. Rats were divided into four groups ( $n = 8$ ): (1) treated by intermittent interruption twice for 20 min each time with an interval of 5 min, (2) treated by continuous single interruption for 40 min, (3) treated by intermittent in administration of GSH (reduced glutathione), and (4) treated by continuous single interruption for 40 min in administration of GSH through portal vein. Malondialdehyde (MDA) and Cu/Zn superoxide dismutase (SOD) are used for the detection of injury induced by oxygen free radical in ischemia/reperfusion and protection level, respectively. Blue color curve: intermittent interruption; red color curve: continuous single interruption. Pre: preinterruption of porta hepatis; After: postinterruption of porta hepatis; Reper: reperfusion after interruption. 1 vs 2 & 3 vs 4 :  $p>0.05$ ; 1 vs 3 & 2 vs 4 :  $p<0.05$ .

#### 4. Surgical anatomy study of the hepatic veins

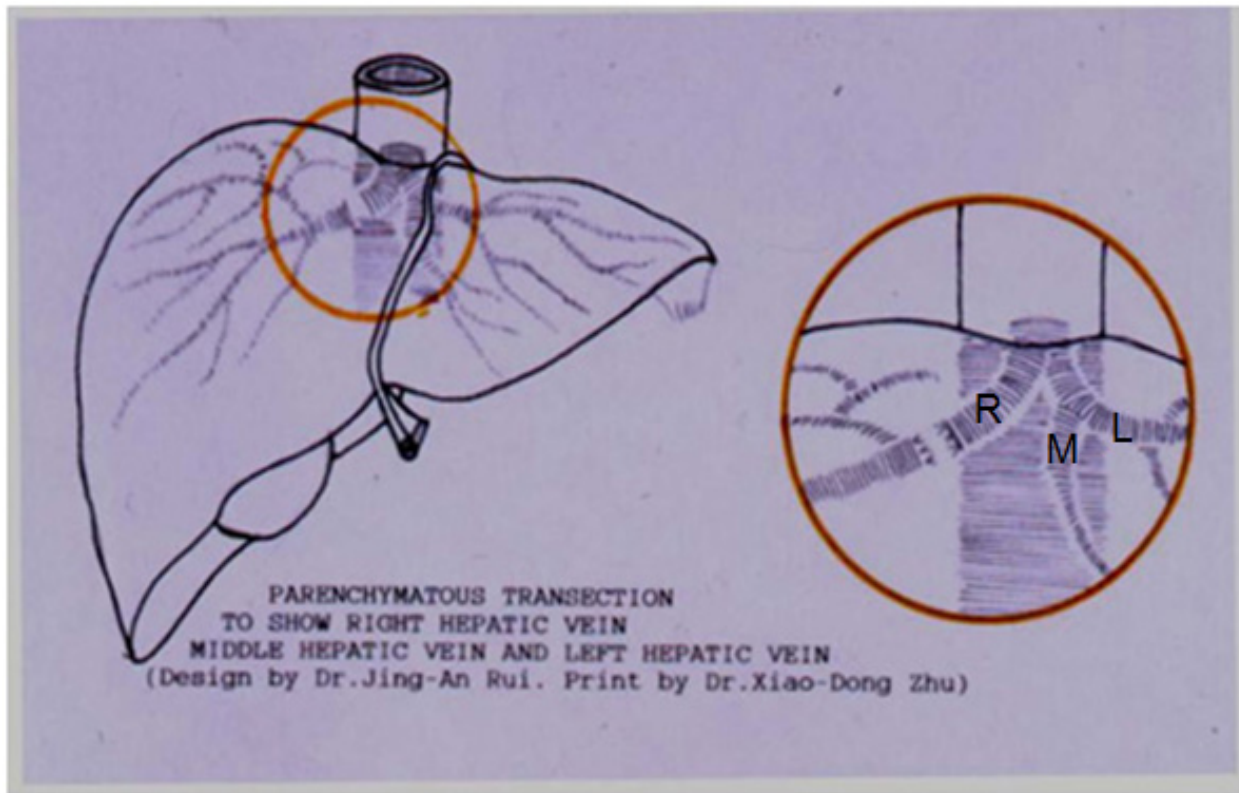
Major hepatectomy under single interruption of porta hepatis requires fast operation in resection of liver lesion. It is most important for the liver surgeon to proficiently know the liver surgical anatomy. Hepatic vein is importantly related to the liver surgery. If hepatic vein is



not treated perfectly in liver surgery, air embolization and bleeding may easily occur. Dai and Rui et al. [25] studied the anatomy of hepatic vein by perfusing ABS acetone solutions with various colors and then etching the liver parenchyma with HCl to show the draining variations of hepatic veins (Figure 4). We found that in 106 cases of livers from human fresh corpse, the draining variations of hepatic veins were rather popular. The variations appear mostly at Sg III, VI, and VII, least at Sg I, II, and VIII (Table 3). We also found that 80% (85/106) of middle vein and left vein join together into IVC (Figures 5 and 6), and 54.7% (58/106) middle vein is draining areas of VI, V, and VIII segments [25]. This work provides anatomic basis, especially when nonregular resection is performing and also warns to the liver surgeons to pay attention to the variations of hepatic veins. For example, during the execution of right trisectionectomy, the surgeons must carefully differentiate the middle hepatic vein (MHV) and the left hepatic vein (LHV) as well as their branch. In this case, the veins being taped must be MHV, as shown in Figure 6 (3,4), and RHV, as shown in Figure 6 (5,6), but not the HLV in Figure 6 (1,2) in the variants. As branches 1, 3, and 5 are rather thin, if any branch (such as 3 and 5 in Figure 6) of MHV and RHV is neglected and not taped, removing the liver being resected not only is impossible but also would subsequently lead to bleeding. Meanwhile, if the LHV or its branch (1,2) is taped, necrosis of the remnant liver parenchyma would happen. Any mistake would result in severe outcome.



**Figure 4.** Surgical anatomy study of hepatic veins. (1) Left hepatic vein (LHV); (2) middle hepatic vein (MHV); (3) right hepatic vein (RHV); (4) right posterior and inferior vein; (5) left intersectional plane vein; (6) IVC.

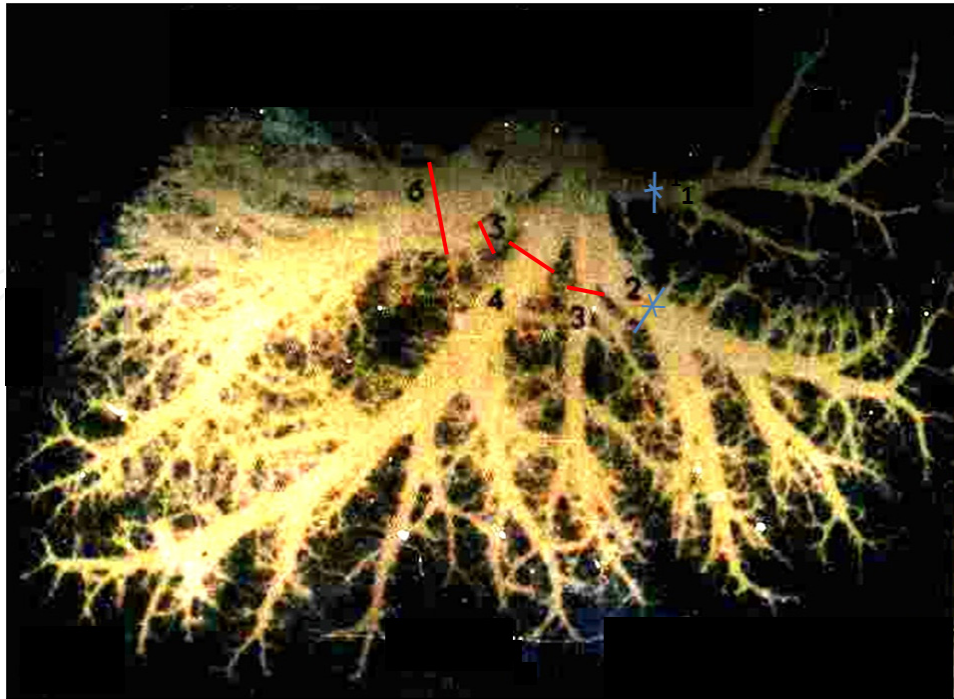


**Figure 5.** Photograph shows right hepatic vein (R), left hepatic vein (L), and Middle vein (M).

These veins run in the midplane of the liver (middle hepatic vein), the right intersectional plane (right hepatic vein), and the left intersectional plane (left hepatic vein). UV is the umbilical vein, which normally drains part of Sg 4 into the left hepatic vein.

<b>Right hepatic vein (R)</b>	Main type	49.0% (52/106)
	Disperse type	21.7% (23/106)
	Mix type	29.3% (31/106)
<b>Middle hepatic vein (M)</b>	Typical type	54.7% (58/106)
	Expand toward right type	19.8% (21/106)
	Expand toward left type	10.4% (11/106)
	Expand toward right and left type	8.5% (9/106)
	Contract type	6.6% (7/106)
<b>Left hepatic vein (L)</b>	Main type	69.8% (74/106)
	Disperse type	20.8% (22/106)
	Expand toward right type	9.4% (10/106)

**Table 3.** Variant rate of hepatic vein draining in 106 cases livers



**Figure 6.** The taping veins for right trisectionectomy in one type of variant. This figure shows one type of variant, i.e., middle vein and left vein joined together into IVC, in which 1 and 2 are of LHV and 3 and 4 are of MHC. During the execution of right trisectionectomy on this variant, the taped veins must be RHV (5,6) and MHV (3,4), but not LHV (1,2).

## 5. Surgical arts of right trisectionectomy

The aim of liver resection in hepatocellular carcinoma is to remove the cancer with minimal operative risk. The major causes of hospital mortality associated with hepatectomy are postoperative hepatic failure, bleeding, and postoperative septic complications. It is obvious that surgical arts (skills) are extremely important for an ideal outcome of hepatectomy. The surgical arts of right trisectionectomy applied in my group are as follows:

1. Continuous single interruption of porta hepatis has been conventionally applied to attenuate bleeding. Based on the majority of HCCs company cirrhotoses, the cirrhotic liver cannot tolerate liver ischemia as well as the normal liver. Compared with multiple intermittent hepatic inflow occlusion, continuous single interruption of porta hepatis significantly attenuates bleeding during hepatic resection. The author summarized a cohort of 459 cases hepatectomy for primary liver cancer patients. Among them, 33 cases of right trisectionectomies were performed. Continuous single interruption of porta hepatis has been applied for all of hepatectomy. The interruption of porta hepatis lasted 15 to 40 min. The operative mortality was 3.0% (1/33). These data suggested that continuous single interruption of the porta hepatis can be regarded as an effective and safe method to limit bleeding even if in right trisectionectomies [9].

2. Ultrasonic dissector (CUSA system 200) for dissecting hepatic parenchyma is applied, instead of previous finger fracture technique, introduced by Lin et al. [26]: The use of ultrasonic dissector makes the operative fields more clear.
3. Major hepatectomy without allogeneic blood transfusion has been advocated. Blood loss during liver resection is one of the most important factors affecting the perioperative outcomes of patients undergone hepatectomy. It has been accepted that infiltrative tumor type, surgical margin <10 mm and intraoperative blood transfusion are independent prognostic factors for overall survival [27,28]. Given that, cancer recurrence is the key factor related to overall survival. Besides the tiny tumor that was not able to be found and remains of cancer during surgical resection, the tumor recurrence after a curative hepatectomy generally resulted from the initiation and development of new lesion in the remnant liver, where apoptosis and proliferation of hepatocytes are both very active based on chronic hepatitis and cirrhoses. In other words, hepatocarcinogenesis in the remnant liver may occur *de novo*. It is well known that oncogenesis and development are tightly linked with immunosuppression. Perioperative transfusion of allogeneic blood would result in clinically significant effects on the recipient's immune system, including immunosuppression, and thus is associated with an increased rate of cancer recurrence, which has been confirmed in colorectal cancer, but is less known with other cancers [29,30]. We have demonstrated that major hepatectomy without allogeneic blood transfusion can reduce postoperative morbidity and recurrence rate of patients with hepatocellular carcinoma [25]. In this study, 51 patients were in the test group without allogeneic blood transfusion, and 60 patients were in the control group with allogeneic blood transfusion. In the test group the operative mortality and morbidity of major hepatectomy were 0% and 9.8%; the 1-, 2-, and 3-year recurrence rates were 24.1%, 27.6%, and 31.0%, respectively, as compared with the control group they were 3.3% and 28.3%; 43.5%, 54.3% and 58.7%, respectively. Statistically significant differences were seen in the morbidity and recurrence rates of patients with liver cancer between these two groups ( $P < 0.05$ ). In the test group, 62.7% of patients underwent autotransfusion in hepatectomy for hepatocellular carcinoma. One potential risk of autotransfusion is considered to be linked with circulating tumor cells planting back to the remnant liver and leading to HCC recurrence. Hirano et al. [31] further demonstrated the safety and effective of autotransfusion: the cumulative 10-year survival rate in autotransfusion group and allotransfusion group were 20% versus 8%. Therefore, the bleeding control is most important in hepatectomy for avoiding perioperative transfusion of allogeneic blood. The mechanism of harmful effects resulted from allotransfusion on morbidity and recurrence of patients undergone hepatectomy have been discussed in another article from Rui et al. [27].

## 6. Adjuvant therapy and therapy after recurrence

Surgical therapy is best combined with appropriate adjuvant therapies based on individual situations of the patient. In case of tumor recurrence, the first choice is resection of the resectable tumor. Nevertheless, either surgical therapy or nonsurgical therapy, transcatheter arterial

chemoembolization (TACE), radiofrequency ablation (RFA), percutaneous ethanol injection (PEI), cryotherapy coagulation therapy, ultrasound (US)-guided percutaneous microwave, high intensive focused ultrasound (HIFU), iodine<sup>125</sup> brachytherapy, immunotherapy, cytototherapy, etc., can be considered according to individual situations of the patient to perform personalized therapy.

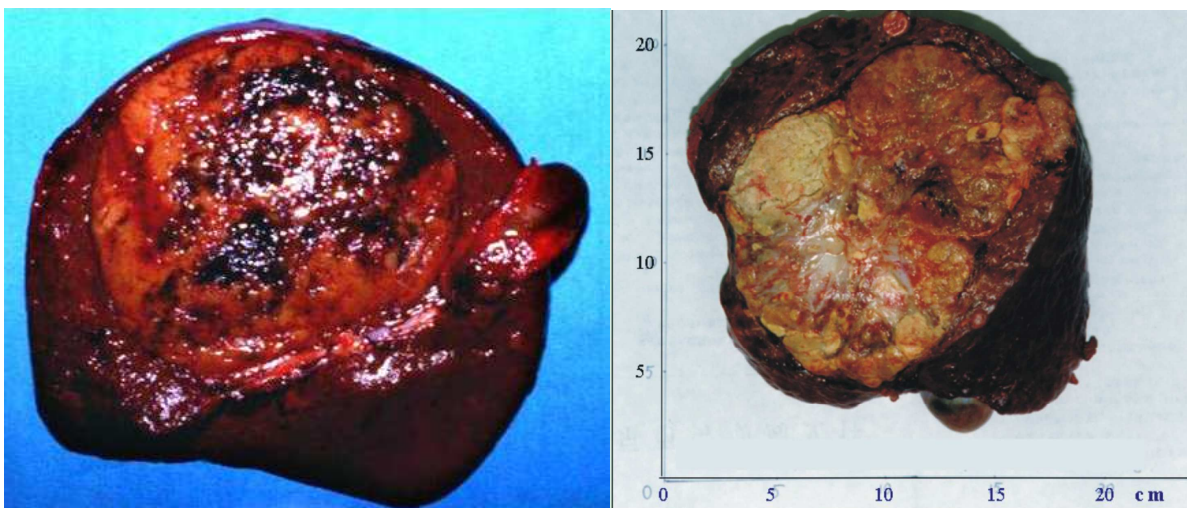
## 7. Case report

### 7.1. Case 1

The largest cancer-free survival time in our patients with huge HCC undergone right trisectionectomy has been more than 26 years. This patient is still alive in Beijing. The patient was a 57-year-old woman and diagnosed with hepatocellular carcinoma, and a right trisectionectomy was performed under continuous single interruption of the porta hepatic in 1988. The resected tumor weighted 2200 g (Figure 7, the left photograph).

### 7.2. Case 2

A 24-year-old man was diagnosed with hepatocellular carcinoma. A right trisectionectomy was performed under continuous single interruption of the porta hepatic. The intraoperation bleeding was 1500 ml. The patient accepted autologous blood transfusion (600 ml), and no allogeneic blood transfusion was administered. The resected tumor weighted 2500 g (Figure 7, the right photograph). The patient was discharged from hospital after recovery at 32 days after operation.



**Figure 7.** Tumors removed by right trisectionectomy.

### 7.3. Case 3

A 40-year-old male patient was suffering from hepatocellular carcinoma. The tumor diameter over 20 cm. One day, the tumor ruptured and the patient went into shock. Then the patient was urgently operated for right trisectionectomy. By follow-ups, the CT examination showed that no recurrence existed within 4 years after operation.

## 8. Conclusion

Right trisectionectomy is an effective and safe therapeutic strategy for huge HCC. Continuous single interruption of porta hepatis is an effective procedure in the attenuation of bleeding and shortening operation time based on skilled surgical manipulation and anatomical knowledge even in the treatment of huge tumor of primary liver cancers. Because of increasing morbidity and recurrence it is suggested to avoid allogeneic blood transfusion for patients undergone major hepatectomy. However, if necessary, autogeneic blood transfusion can be applied.

## Author details

Jing An Rui

Address all correspondence to: [drrlzhou@163.com](mailto:drrlzhou@163.com)

Department of Surgery, Peking Union Medical College Hospital, Chinese Academy of Medical Sciences, China

## References

- [1] Simonnetti, RG, Camma C, Fiorello, F, et al. Hepatocellular carcinoma. A worldwide problem and the major risk factors. *Dig Dis Sci.* 1991;36:962–972.
- [2] McClune AC, Tong MJ. Chronic hepatitis B and hepatocellular carcinoma. *Clin Liver Dis.* 2010;14(3):461–476.
- [3] Llovert JM, Burroughs A, Bruix J. Hepatocellular carcinoma. *Lancet.* 2003;362:1907–1917
- [4] Munoz N, Bosch X. Epidemiology of hepatocellular carcinoma. In: Okuda K, Ishak KG, eds. *Neoplasms of the liver 1988.* Springer-Verlag, Berlin, Germany, pp. 3–19.
- [5] Rustgi VK. Epidemiology of hepatocellular carcinoma. *Gastroenterol Clin North Am.* 1987;16:545–551.

- [6] Pringle JH. Notes on arrest of hepatic hemorrhage due to trauma. *Ann Surg.* 1908;48:541–549.
- [7] Starzl, TE, Bell RH, Beart RW. Hepatic trisegmentectomy and other liver resection. *Surg Gynecol Obstet.* 1975;141:429–437.
- [8] Starzl TE, Koep LJ, Weil R 3rd, Lilly JR, Putnam CW, Aldrete JA. Right trisegmentectomy for hepatic neoplasms. *Surg Gynecol Obstet.* 1980;150:208–214
- [9] Rui JA, Wang SB, Chen SG, Zhou L. Right trisectionectomy for primary liver cancer. *World J Gastroenterol.* 2003;9(4):706–709.
- [10] Hanazaki K, Kajikawas S, Shimozawa N. Hepatic resection for large hepatocellular carcinoma. *Am J Surg.* 2001;181:347–353.
- [11] Regimbeau JM, Farges O, Shen BY. Is surgery for large hepatocellular carcinoma justified? *J Hepatol.* 1999;31:1062–1068.
- [12] Sugiura Y, Nakamura S, Lida S. Extensive resection of the bile ducts combined with liver resection for cancer of the main hepatic duct junction: a cooperative study of the keio Bile Duct Cancer Study Group. *Surgery.* 1994;155:445–451.
- [13] Yamamoto M, Miura K, Yoshioka M. Disease-free survival for 9 years after liver resection for stage IV gallbladder cancer: report of a case. *Surg Today.* 1995;25:750–753.
- [14] Foster JH. Liver resection techniques. *Surg Clin North Am.* 1989;69(2):235–249.
- [15] Man K, Lo CM, Liu CL, et al. Effects of the intermittent Pringle manoeuvre on hepatic gene expression and ultrastructure in a randomized clinical study. *Br J Surg.* 2003;90:183–198.
- [16] Belghiti J, Noun R, Malafosser R, et al. Continuous versus intermittent portal triad clamping for liver resection: a controlled study. *Ann Surg.* 1999;229:369–375.
- [17] Rui JA, Wang K, Su Y, Li ZW, Wang CF, Wu JX, Zhao P. Right trisegmentectomy for primary liver cancer—a report of 4 cases with review of literature. *Zhonghua Zhong Liu Za Zhi.* 1991;13:37–39. Zhou Li, Rui JA, Wang SB. Outcomes and prognostic factors of cirrhotic patients with hepatocellular carcinoma after radical major hepatectomy. *World J Surg.* 2007;31:1782–1787.
- [18] Rui JA, Qu JY, Su Y, Li ZW, Wang K, Zhu GJ, Wu JX, Chen GJ, Wang CF, Mao XW. Hemihepatectomy under hepato-portal interruption at normal temperature for liver malignancies: a report of 20 patients. *Zhonghua Zhong Liu Za Zhi.* 1987;9:221–223.
- [19] Zhou L, Rui JA, Wang SB, et al. Clinicopathological features, post-surgical survival and prognostic indicators of elderly patients with hepatocellular carcinoma. *EJSO.* 2006;32:767–772.

- [20] Uwatoko S, Yamamoto K, Sasaki T, Fukumori D, Igimi H, Yamamoto M, Yamamoto F, Yamashita Y. Age is no longer a limit: two cases of hepatectomy in patients over 90 years old. *Case Rep Gastroenterol*. 2015;9(1):49–55.
- [21] Capussotti L, Nuzzo G, Polastri R, et al. Continuous versus intermittent portal triad clamping during hepatectomy in clinical trial. *Hepatogastroenterology*. 2003;50:1073–1077.
- [22] Mitchell RN and Cotran RS. Cell Injury, Adaptation and Death. In: *Basic pathology* (7th ed.). Singapore: Elsevier; 2003. p. 9
- [23] Lannan KL, Sahler J, Spinelli SL, Phipps RP, Blumberg N. Transfusion immunomodulation—the case for leukoreduced and (perhaps) washed transfusions. *Blood Cells Mol Dis*. 2013;50(1):61–8.
- [24] Zhou Li, Rui JA, Zhou RL, Peng XM, Wang SB, Chen SG, Qu Q, Zhao YP. Liver injury after intermittent or continuous hepatic pedicle clamping and its protection by reduced glutathione. *Hepatobiliary Pancreat Dis Int*. 2004;3:209–213.
- [25] Dai YH, Ji QY, Liu JH and Rui JA. Applied anatomy study on drainage of human segmental hepatic veins. *Zhonghua Zhong Liu Za Zhi*. 1988;26:568–571.
- [26] Lin TY, Lee CS, Chen KM, Chen CC. Role of surgery in the treatment of primary carcinoma of the liver: a 31-year experience. *Br J Surg*. 1987;74:839–842.
- [27] Rui JA, Zhou L, Chu QF, Wang SB, Chen SG, Qu Q, Wei X, Han K, Zhang N, Zhao HT. Major hepatectomy without blood transfusion: report of 51 cases. *Chin Med J*. 2004;117(5):673–676.
- [28] Rui JA. Major hepatectomy without blood transfusion for hepatocellular carcinoma. In: Lau JWY. *Hepatocellular Carcinoma-Clinical Research*. Rijeka: InTech; 2011. pp. 197–208
- [29] Refaai MA, Blumberg N. Transfusion immunomodulation from a clinical perspective: an update. *Expert Rev Hematol*. 2013;6(6):653–63.
- [30] Cata JP, Wang H, Gottumukkala V, Reuben J, Sessler DI. Inflammatory response, immunosuppression, and cancer recurrence after perioperative blood transfusions. *Br J Anaesth*. 2013;110(5):690–701.
- [31] Hirano T, Yamanaka J, Iimuro Y, Fujimoto J. Long-term safety of autotransfusion during hepatectomy for hepatocellular carcinoma. *Surg Today*. 2005;35(12):1042–1046.



