

We are IntechOpen, the world's leading publisher of Open Access books Built by scientists, for scientists

4,800

Open access books available

122,000

International authors and editors

135M

Downloads

Our authors are among the

154

Countries delivered to

TOP 1%

most cited scientists

12.2%

Contributors from top 500 universities



WEB OF SCIENCE™

Selection of our books indexed in the Book Citation Index
in Web of Science™ Core Collection (BKCI)

Interested in publishing with us?
Contact book.department@intechopen.com

Numbers displayed above are based on latest data collected.

For more information visit www.intechopen.com



Diagnostic and Therapeutic Challenges in Nonparasitic Liver Cysts

Mirela Patricia Sîrbu Boeți, Mirela Boroș,
Vlad Herlea, Amalia Petrișor and Irinel Popescu

Additional information is available at the end of the chapter

<http://dx.doi.org/10.5772/61057>

Abstract

Nonparasitic hepatic cysts constitute a heterogeneous group of disorders. A proper diagnosis of hepatic cyst is necessary in order to adopt the best treatment. The term hepatic cyst usually refers to simple hepatic cysts. Nonparasitic hepatic cysts are also linked to genetic disorders such as polycystic liver disease (PLD) with/without autosomal dominant polycystic kidney disease (ADPKD) or Caroli disease. Generally, patients with nonparasitic hepatic cysts less than 3 cm are asymptomatic. These cysts become symptomatic when are large, multiple, or complicated. Percutaneous abdominal ultrasound is the best imaging modality to diagnose hepatic cysts but must be completed by other imaging and serological tests. It is important to differentiate simple hepatic cyst from hydatid cyst, cystadenoma, and cystadenocarcinoma before proceeding with the treatment. Sometimes the diagnosis is very challenging. Asymptomatic single liver cysts need only surveillance, but symptomatic and complicated ones require therapeutic intervention. Percutaneous aspiration of the cyst under ultrasound guidance is a mini-invasive procedure generally associated with sclerotherapy. The highest success rates were reported for laparoscopic or open cyst fenestration. Liver transplantation is indicated for patients with severe PLD.

Keywords: Simple hepatic cyst, serous hepatic cyst, nonparasitic hepatic cyst, polycystic liver disease

1. Introduction

Nonparasitic hepatic cysts encompass a heterogeneous group of disorders, which differ in etiology, prevalence, and manifestations. The term hepatic cyst usually refers to solitary nonparasitic cysts of the liver, also known as simple cysts. Generally, hepatic cysts are incidentally found during surgery and more frequently during imaging examinations for other reasons. Nowadays, due to the imaging procedures, prevalence of nonparasitic hepatic cysts is found increased up to 18% in adult population [1]. The incidence is higher in females older than 50 years.

1. Definition

Nonparasitic hepatic cysts encompass a heterogeneous group of disorders, which differ in etiology, prevalence, and manifestations. The term hepatic cyst usually refers to solitary nonparasitic cysts of the liver, also known as simple cysts.

2. Classification and etiology

2.1. Serous/simple hepatic cyst

Hepatic serous or simple cysts may be single or multiple and are considered to be congenital. They are derived from aberrant bile ducts that have apparently lost communication with the biliary tree and continue to secrete intramural fluid [2]. Microscopically, they are lined by a single layer of cuboid, columnar, flattened (Figure 1) or pseudostratified (Figure 2), or by stratified epithelial cells (Figure 3), resembling biliary epithelial cells.

2. Classification and etiology

2.1. Serous/simple hepatic cyst

Hepatic serous or simple cysts may be single or multiple and are considered to be congenital. They are derived from aberrant bile ducts that have apparently lost communication with the biliary tree and continue to secrete intramural fluid [2]. Microscopically, they are lined by a single layer of cuboid, columnar, flattened (Figure 1) or pseudostratified (Figure 2), or by stratified epithelial cells (Figure 3), resembling biliary epithelial cells.

Hepatic serous or simple cysts may be single or multiple and are considered to be congenital. They are derived from aberrant bile ducts that have apparently lost communication with the biliary tree and continue to secrete intramural fluid [2]. Microscopically, they are lined by a single layer of cuboid, columnar, flattened (Figure 1) or pseudostratified (Figure 2), or by stratified epithelial cells (Figure 3), resembling biliary epithelial cells.

Hepatic serous or simple cysts may be single or multiple and are considered to be congenital. They are derived from aberrant bile ducts that have apparently lost communication with the biliary tree and continue to secrete intramural fluid [2]. Microscopically, they are lined by a single layer of cuboid, columnar, flattened (Figure 1) or pseudostratified (Figure 2), or by stratified epithelial cells (Figure 3), resembling biliary epithelial cells.

Hepatic serous or simple cysts may be single or multiple and are considered to be congenital. They are derived from aberrant bile ducts that have apparently lost communication with the biliary tree and continue to secrete intramural fluid [2]. Microscopically, they are lined by a single layer of cuboid, columnar, flattened (Figure 1) or pseudostratified (Figure 2), or by stratified epithelial cells (Figure 3), resembling biliary epithelial cells.

Hepatic serous or simple cysts may be single or multiple and are considered to be congenital. They are derived from aberrant bile ducts that have apparently lost communication with the biliary tree and continue to secrete intramural fluid [2]. Microscopically, they are lined by a single layer of cuboid, columnar, flattened (Figure 1) or pseudostratified (Figure 2), or by stratified epithelial cells (Figure 3), resembling biliary epithelial cells.

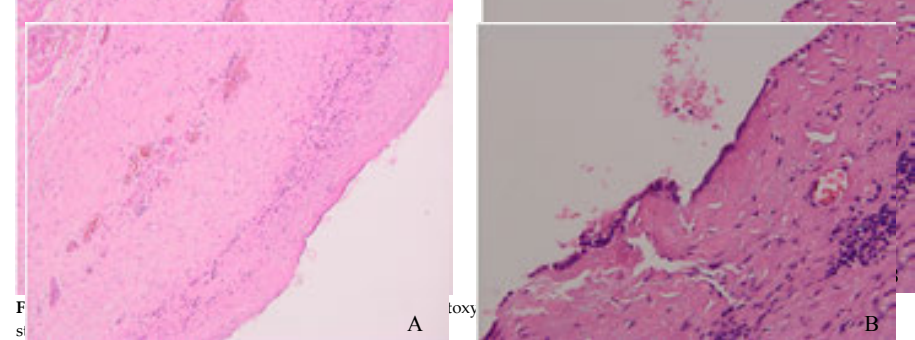


Figure 1. Serous cyst with flattened epithelium. (A) Hematoxylin and eosin staining ×100. (B) Hematoxylin and eosin staining ×400.

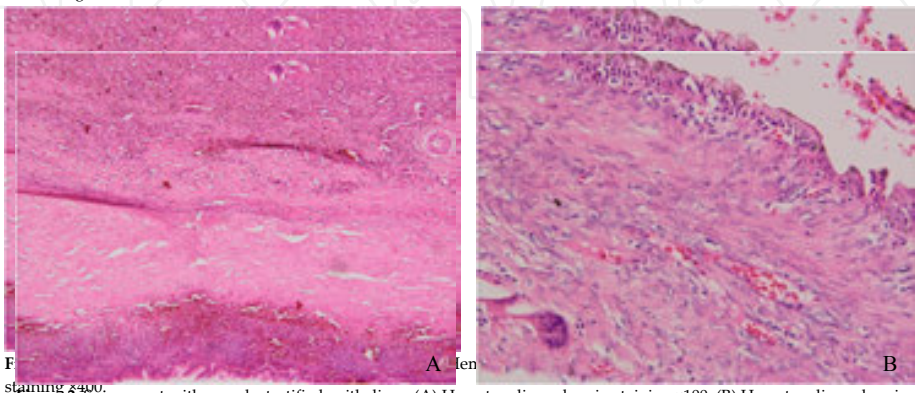


Figure 2. Serous cyst with pseudostratified epithelium. (A) Hematoxylin and eosin staining ×100. (B) Hematoxylin and eosin staining ×400.

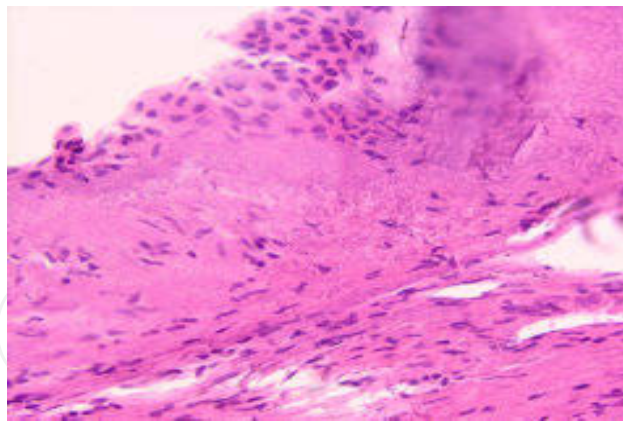


Figure 3. Serous simple cyst with stratified cuboidal epithelium. Hematoxylin and eosin staining $\times 200$.

2.2. Polycystic liver disease

Serous hepatic cysts are also linked to genetic disorders such as polycystic liver disease (PLD) with/without autosomal dominant polycystic kidney disease (ADPKD) or Caroli disease. Isolated PLD is associated with heterozygous mutations in *PRKCSH* or *SEC63* genes. PLD associated with ADPKD is linked with mutations in the *PKD1* or *PKD2* gene [3]. Overall prevalence is similar for both genders, but females develop a more severe liver disease. Pregnancy, multiparity, and use of steroids increase the risk for severe hepatic cystic disease.

Gigot and collaborators have described a classification for patients with polycystic liver disease based on the number and size of hepatic cysts and residual normal liver parenchyma between the cysts. This description is based on preoperative computed tomography (CT) [4]. Also, this classification can delineate the therapeutic strategy [5].

- Type I—less than 10 large cyst (7–10 cm) with large areas of noncystic parenchyma
- Type II—diffuse involvement of liver parenchyma by medium-sized cysts (5–7 cm) with remaining large areas of noncystic parenchyma
- Type III—massive, diffuse involvement of liver parenchyma by small- and medium-sized cysts (less than 5 cm) and only a few areas of normal liver parenchyma between cysts [2, 4, 5]

It is of exquisite importance to differentiate hepatic cyst from hydatid hepatic cyst, hepatic cystadenoma, and hepatic cystadenocarcinoma before proceeding with the treatment. In certain situations, it can be very challenging to properly diagnose a hepatic cystic mass [6, 7]. There are also rare hepatic cystic lesions that must be taken into consideration [8]. In pediatric population, the surgeon should be aware of the wide range of other types of liver cysts to ensure appropriate treatment [9].

2.3. Localized Caroli disease or solitary dilatation of intrahepatic biliary duct

Caroli disease is an autosomal recessive inheritance linked to mutation in *PKHD1* gene. It is classified as type V choledochal cyst by the Todani classification [10]. The cystic lesions are

- Type II diffuse polycystic disease [6, 7]. The parents may have hepatic cystic lesions that must be less than 5 cm in diameter. In pediatric population, the surgeon should be aware of the wide range of other types of liver cysts to ensure appropriate treatment [9].

It is of utmost importance to differentiate hepatic cyst from hydatid hepatic cyst, hepatic cystadenoma, and hepatic cystadenocarcinoma. To achieve this goal, the treatment of intrahepatic biliary duct is very challenging to properly diagnose a hepatic cystic mass [6, 7]. There are also rare hepatic cystic lesions that must be taken into consideration [8]. In pediatric population, the surgeon should be aware of the wide range of other types of liver cysts to ensure appropriate treatment [9].

2.3. Localized Caroli disease or solitary dilatation of intrahepatic biliary duct

Caroli disease is an autosomal recessive inheritance linked to mutation in PKHD1 gene. It is classified as a type Caroli choledochal cyst by the Todani classification [10]. The cystic lesions are depicted as irregular in shape, fusiform, or axially saccular (Figures 4A). On MRCP they are seen to communicate with biliary tree (Figure 4B). On gross examination of the operative specimen, the cystic cavity contains biliary sludge and even gallstones (Figure 5).

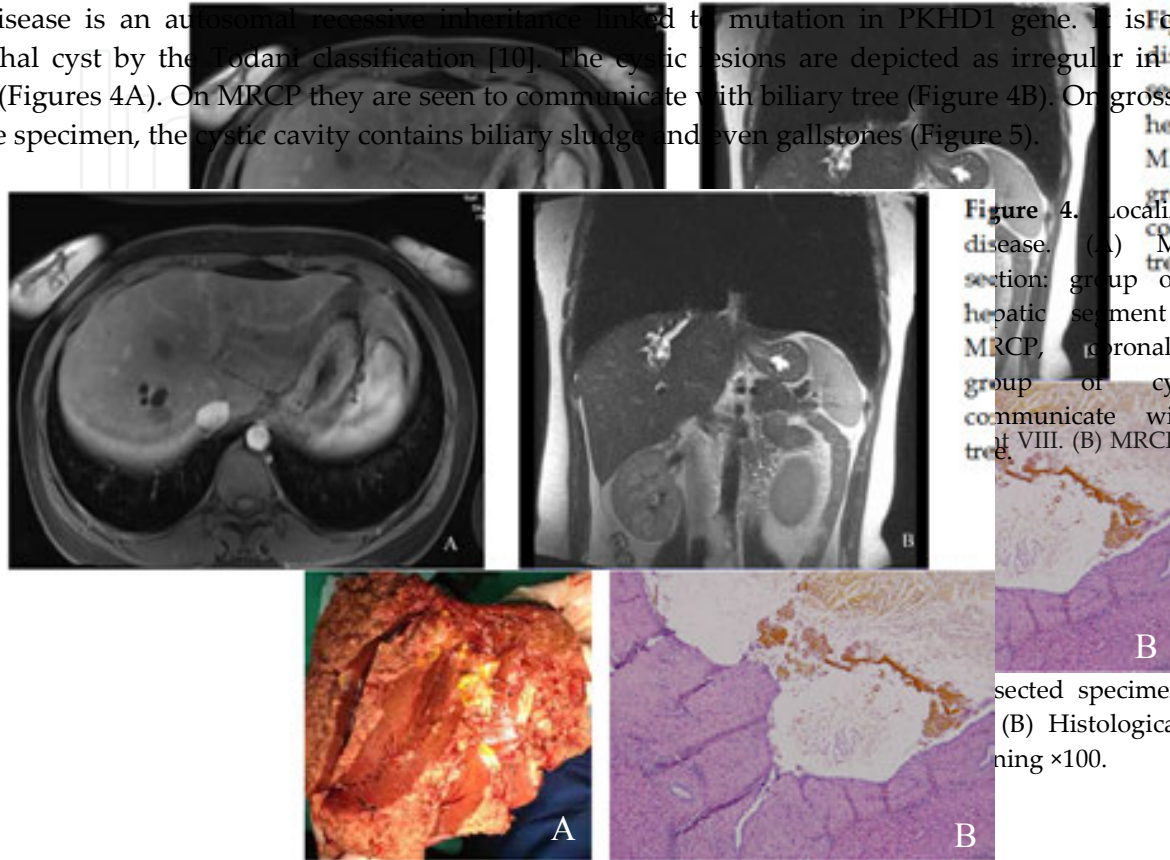


Figure 4. Localized Caroli disease. (A) MRI, axial section: group of cysts in hepatic segment VIII. (B) MRCP, coronal section: group of cysts that communicate with biliary tree.

Figure 5. Localized Caroli disease. (A) Resected specimen with biliary cysts filled with bile sludge. (B) Histological examination of the intrahepatic biliary duct. In native and contrast enhanced CT fails to observe papilloma, the bile duct dilatation may be confused with a hepatic serous cyst. ERCP can demonstrate the communication between the cystic lesion and the bile duct [11].

Localized Caroli disease (A) Resected specimen with biliary cysts filled with bile sludge. (B) Histological examination of the intrahepatic biliary duct. In native and contrast enhanced CT fails to observe papilloma, the bile duct dilatation may be confused with a hepatic serous cyst. ERCP can demonstrate the communication between the cystic lesion and the bile duct [11].

2.4. Intrahepatic biliary papilloma

Biliary papilloma represents a tumorous growth of the bile duct epithelia in the bile duct lumen and can cause a localized dilatation of the intrahepatic bile duct. If native and contrast enhanced CT fails to observe the biliary papilloma, the bile duct dilatation may be confused with the hepatic serous cyst. ERCP can demonstrate the communication between the cystic lesion and the bile duct [11].

2.5. Biliary cystadenoma and biliary cystadenocarcinoma

Biliary cystadenoma and biliary cystadenocarcinoma are characterized by multilocular cysts with internal septation and epithelial lining composed of columnar to cuboidal cells capable of mucin production. They usually contain clear mucinous fluid and rarely bloody fluid. Bloody fluid often signifies a malignant component [12]. The septa may show calcifications. Biliary cystadenoma is a very rare, cystic lesion of the liver that usually occurs in middle-aged women. The exact etiology of this insidiously progressive tumor is unknown. These cysts may originate from a congenitally aberrant bile duct or directly from a primitive hepatobiliary stem cell.

Cystadenoma of the liver is characterized by multilocular cysts with internal septation and epithelial lining composed of columnar to cuboidal cells capable of mucin production. They usually contain clear mucinous fluid and rarely the fluid may be bilious, purulent, proteinaceous, or hemorrhagic. Bloody fluid often signifies a malignant component [12]. The septa may show calcifications.

Two subgroups are distinguished by presence or absence of mesenchymal (ovarian like) stroma between an inner epithelial lining and an outer layer of collagenized connective tissue (Figure 6).

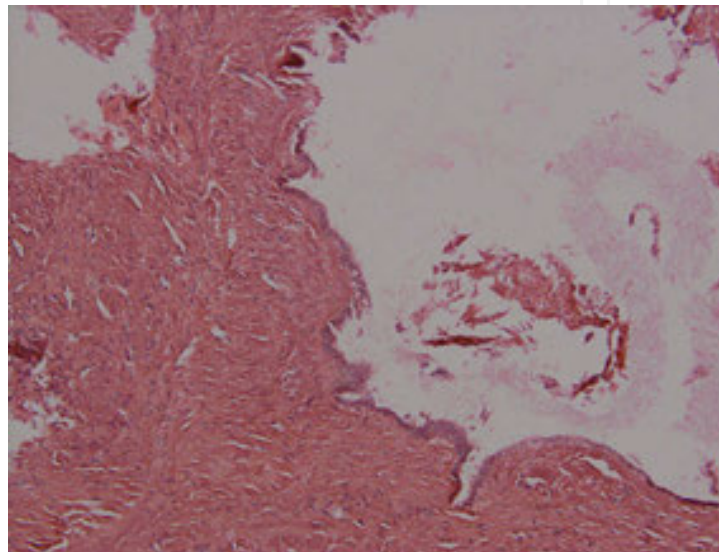


Figure 6. Cystadenoma without mesenchymal stroma. Hematoxylin and eosin staining $\times 200$.

The mesenchymal stroma resembles primitive mesenchyme, and cell differentiation varies from smooth muscle or fibroblasts to adipocytes or capillaries. Cystadenoma with mesenchymal stroma occurs exclusively in women (Figure 7) possibly as a consequence of the female milieu influence, while cystadenoma without mesenchymal stroma predominates in men [13].

Mesenchymal stroma may give rise to both cystadenocarcinoma and sarcomas. Intrahepatic biliary cystadenoma cannot be clearly differentiated from cystadenocarcinoma before operation. Some authors consider the diagnostic value of the analysis of serum and aspirated cyst fluid for tumor markers. However, elevated carbohydrate antigen CA 19-9 and carcinoembryonic antigen CEA has been associated both with cystadenoma and cystadenocarcinoma [14]. Only histopathologic exam can certainly differentiate it from malignant degeneration. Being considered a premalignant lesion, surgical excision seems to be a wise decision in patients with intrahepatic biliary cystadenoma. If not completely resected, the recurrence in biliary cystadenoma is greater than 90% [12]. Moreover, if malignancy is not recognized, a simple fenestration may prove catastrophic to patient. Patients with cystadenocarcinoma with mesenchymal stroma have a good prognosis, whereas cystadenocarcinoma in men, which is not associated with mesenchymal stroma, has a worse prognosis, even after complete excision [15].

The mesenchymal stroma resembles primitive mesenchyme, and cell differentiation varies from smooth muscle or fibroblasts to adipocytes or capillaries. Cystadenoma with mesenchymal stroma occurs exclusively in women (Figure 7) possibly as a consequence of the female milieu influence, while cystadenoma without mesenchymal stroma predominates in men [13].

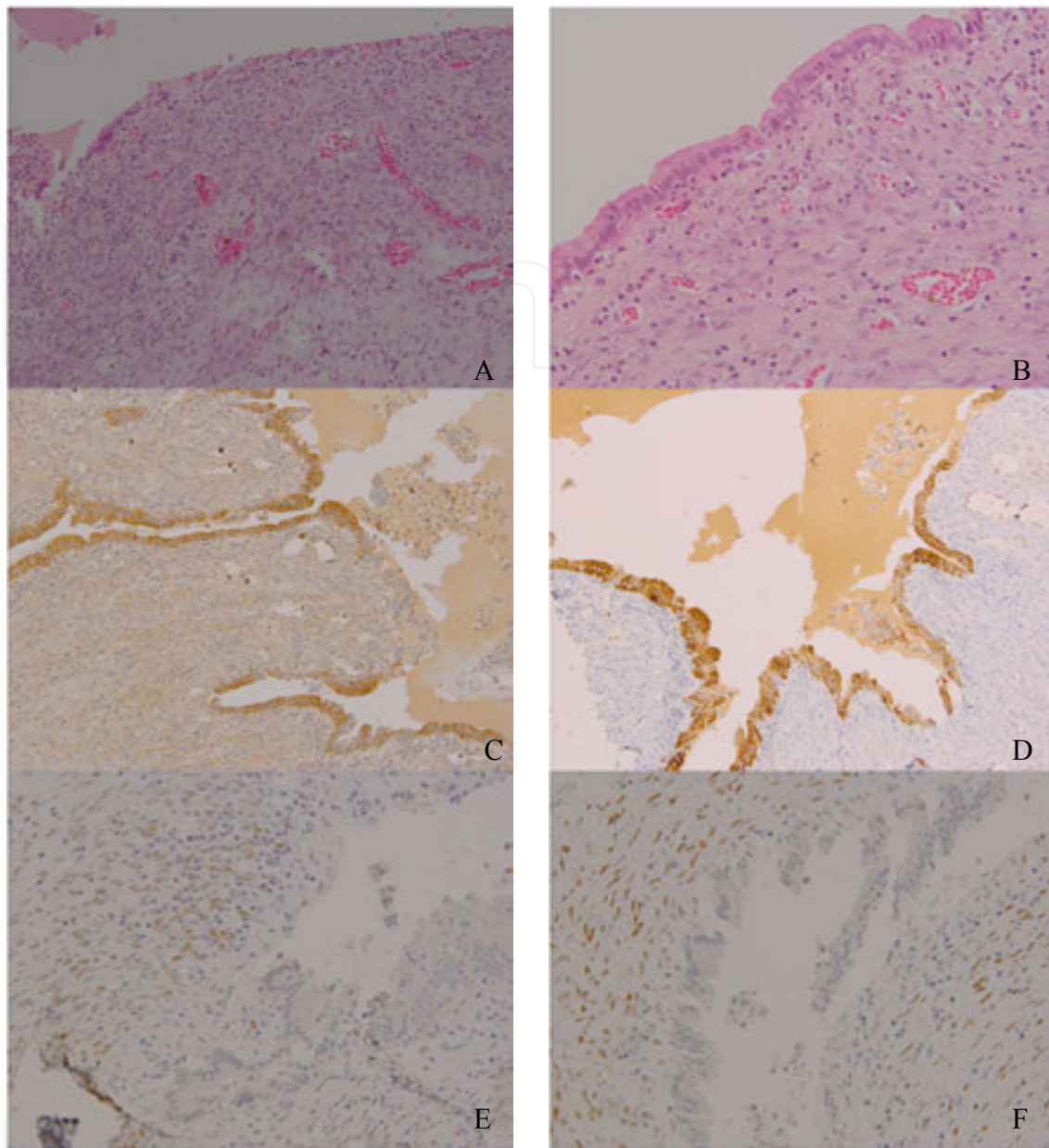


Figure 7. Cystadenoma with mesenchymal stroma. (A) Hematoxylin and eosin staining $\times 200$. (B) Hematoxylin and eosin staining $\times 400$. (C) Immunohistochemical staining CK7 $\times 200$. Cyst epithelium is positive for CK7. (D) Immunohistochemical staining CK8-18 $\times 200$. Cyst epithelium is positive for CK8-18. (E) Immunohistochemical staining ER $\times 400$. Mesenchymal stroma contains cells (brown cells) that are positively stained for estrogen receptors. (F) Immunohistochemical staining PgR $\times 400$. Mesenchymal stroma contains cells (brown cells) that are positively stained for progesterone receptors.

2.6. Bile duct hamartoma

Bile duct hamartomas, also called von Meyenburg complexes, originate from embryonic bile ducts that fail to involute. Generally, they are encountered as an incidental finding at imaging, laparotomy, or autopsy. Macroscopically, they are cyst-like, grayish-white nodular lesions of 0.1-1.5 cm diameter that do not communicate with the biliary tree. Sometimes they are

associated with Caroli's disease, PLD and congenital fibrosis. In case of intraoperative discovery, they may be misdiagnosed as liver metastases.

2.7. Ciliated hepatic foregut cyst

Ciliated hepatic foregut cysts are rare foregut developmental malformation usually solitary and unilocular. Generally, these are situated in the central segments of the liver (Figure 8). These cysts are characterized by the typical microscopic finding of four layers (the inner ciliated, pseudostratified, columnar epithelium; subepithelial connective tissue; smooth muscle layer; and an outer fibrous layer at microscopic examination). Squamous metaplasia may be present with potential transformation into squamous cell carcinoma. Malignant transformation to squamous cell carcinoma with aggressive behavior has been reported in 3% of adult cases [4, 16].

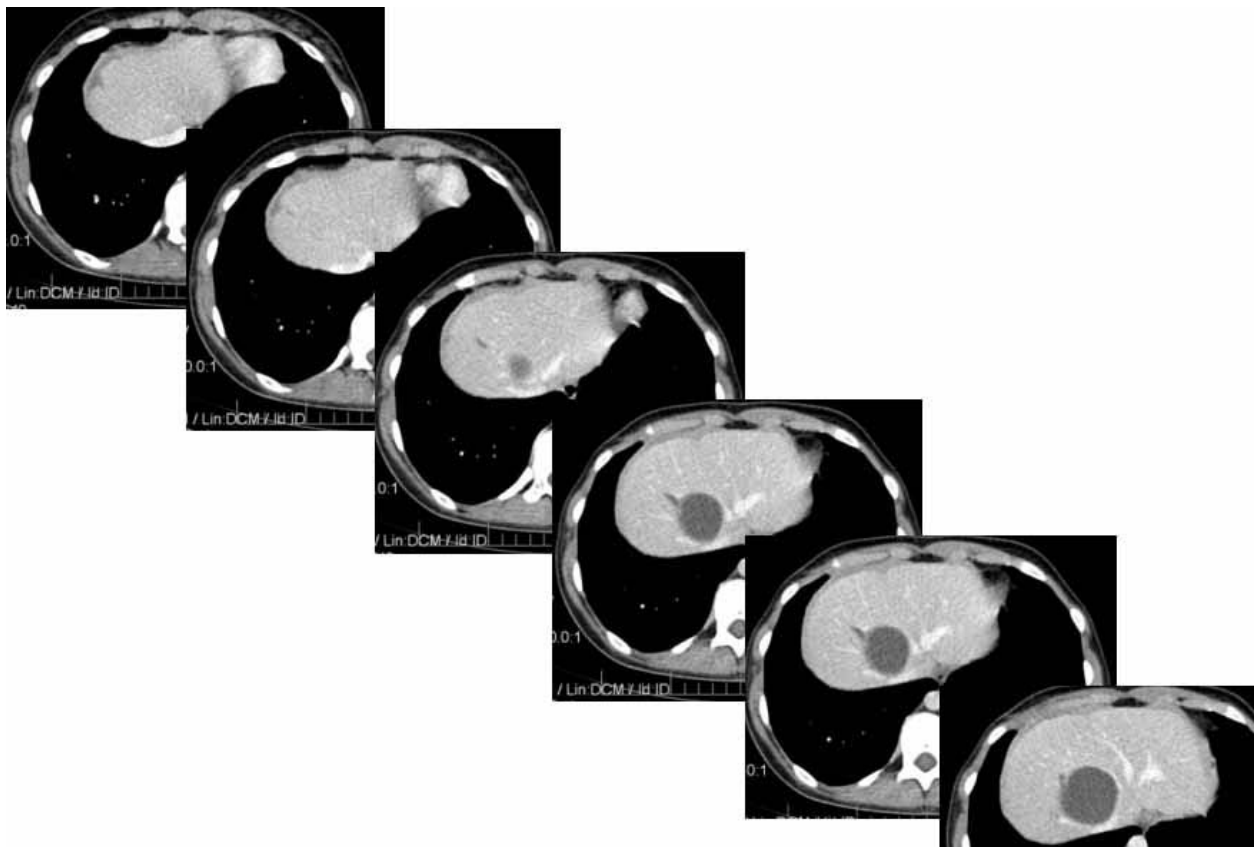


Figure 8. CT series showing a hepatic cyst situated in segment VIII, with an extension that is traced on the hepatic surface, raising the question of ciliated hepatic foregut cyst in a 14-year-old girl. The patient was submitted to open surgery due to the close proximity with the inferior vena cava and hepatic vein.

2.8. Intrahepatic pancreatic pseudocyst

Hepatic pseudocyst secondary to acute pancreatitis is extremely rare and is generally situated in the left lobe. A high level of amylase in the aspirated fluid confirms the diagnosis. Asymp-

omatic intrahepatic pseudocyst can be treated conservatively, and symptomatic intrahepatic pseudocyst can be managed either percutaneously or surgically [17].

2.9. Posttraumatic hepatic cyst

Only those symptomatic or of uncertain nature need treatment.

2.10. Biloma

Biloma appears as a cystic mass. It is caused by spontaneous, traumatic, or iatrogenic rupture of the biliary system.

2.11. Peribiliary cysts

Peribiliary cysts are mostly encountered in cirrhotic patients with portal hypertension or after liver transplantation. The cysts are located along the portal pedicles. Usually they are small and asymptomatic.

2.12. Liver hematoma

Liver hematomas are cystic lesions that develop after trauma, liver biopsy, or surgery.

2.13. Hepatic epidermoid cyst

Liver epidermoid cysts are extremely rare. These malformations have been diagnosed in pediatric patients, with the youngest one being 5 months years old. The importance of resection of such cystic lesions in pediatric population resides in the need of elimination of a lesion lined by squamous epithelium with possible squamous metaplasia that can potentially undergo malignant transformation, resulting in squamous cell carcinoma.

2.14. Postcholecystectomy hepatic cystic mass

The term of gossypiboma derived from the Latin term gossypium is used to define a forgotten surgical material in the body after surgery. Sometimes gossypiboma has a cyst-like appearance on imaging tests.

2.15. Hepatic endometriosis

So far only 22 cases of hepatic endometrioma have been reported in the literature [18]. Hepatic endometriosis should be considered in women of any age presenting with a hepatic cystic mass, with or without previous endometriosis history. Frozen sections of intraoperative transhepatic biopsy are necessary to avoid radical hepatectomy in order to decrease postoperative morbidity and mortality. However, the diagnosis is confirmed through histological immunostaining. Complete pericystectomy is necessary to avoid recurrence.

So far only 22 cases of hepatic endometrioma have been reported in the literature [18]. Hepatic endometriosis should be considered in women of any age presenting with a hepatic cystic mass, with or without previous endometriosis history. Frozen sections of intraoperative transhepatic biopsy are necessary to avoid radical hepatectomy in order to decrease postoperative morbidity and mortality. However, the diagnosis is confirmed through histological immunostaining. Complete pericystectomy is necessary to avoid recurrence.

2.16. Hepatic vascular tumors

2.16. Hepatic vascular tumors

There are hepatic vascular tumors with predominantly solid appearance at gross examination but with vascular appearance on imaging. Solid appearance due to high water content with cyst-like appearance on pathological diagnosis is seen in the liver water docteur. Histopathological diagnosis must differentiate between lymphangioma, hemangioma, and angiosarcoma on a differential (Figure 8), and sarcoma (Figure 9).

2.17. Liver metastases

Liver metastases from pancreatic, colon, renal, endometrial, and neuroendocrine have cyst-like appearance on imaging tests.

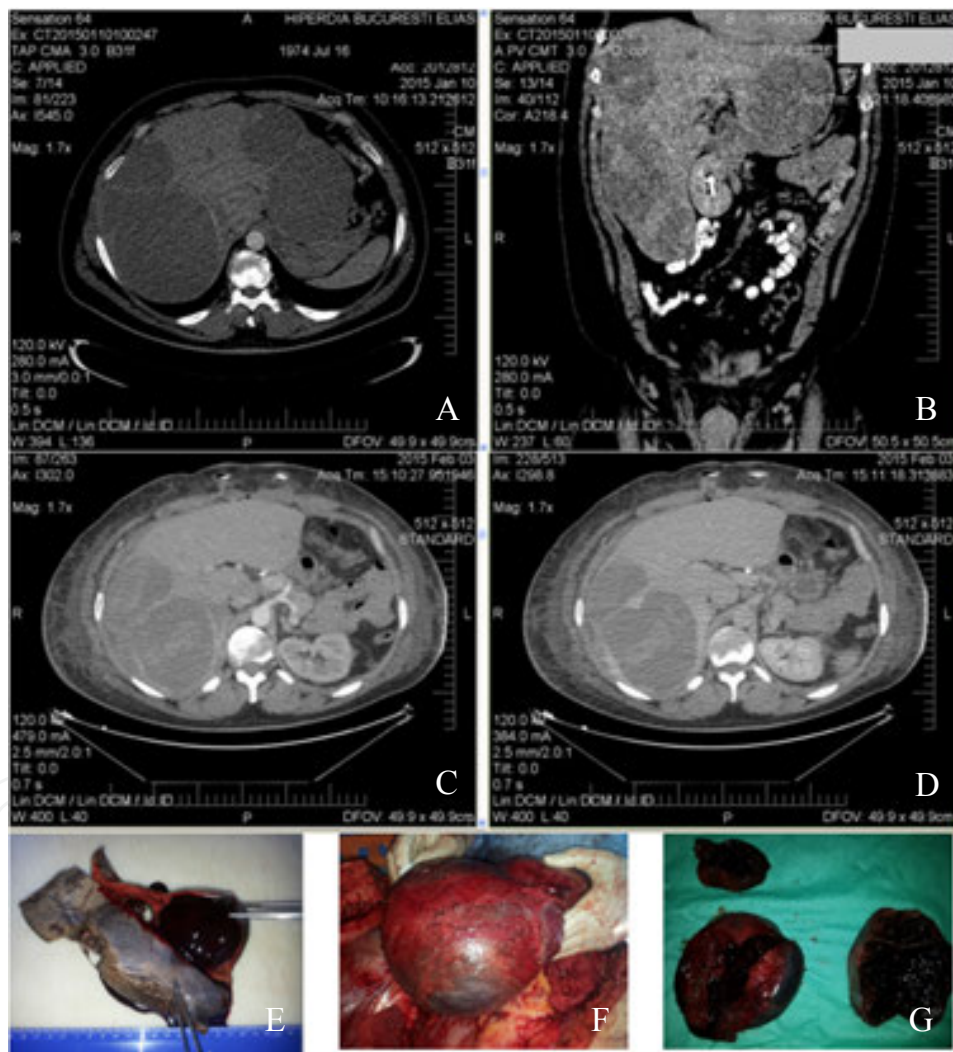


Figure 9. Hepatomegaly caused by multiple bilateral liver vascular tumors with cystic features on CT and operative specimen.

Figure 9. Hepatomegaly caused by multiple bilateral liver vascular tumors with cystic features on CT and operative specimen. (A) CT axial view, (B) CT coronal view, (C) CT with IV contrast axial view, after left lateral sectionectomy. (D) CT without contrast axial view, after left lateral sectionectomy. (E) Resected specimen after left lateral sectionectomy with hemorrhagic cystic feature on section. (F) Intraoperative aspect of resected specimen after the hepatectomy. (G) Resected specimen in the right lobe, typical hepatomegaly for the tumors located in the right lobe, with hemorrhagic cystic feature on section.

3. Clinical manifestations

Generally, patients with nonparasitic hepatic cysts less than 3 cm are asymptomatic [2]. Cysts are classified as “large” when they are greater than 4 cm in the longest diameter. If the diagnosis of hepatic serous cyst is clear, there is no need of treatment, unless it becomes symptomatic, has a diameter more than 5 cm, or if the cyst grows rapidly within a short period of time [19].

Around 15% of patients with liver cysts develop symptoms at some stage in life. When the patients start complaining, the most common symptom is pain in the right upper quadrant. Other encountered symptoms are nausea, vomiting, abdominal meteorism, shoulder or lumbar pain, dyspnea, and/or postprandial fullness. Hepatic cysts become symptomatic when they are large, fast growing, multiple, or complicated.

3.1. Complications

Complications occur in approximately 10% of patients [20]. Obstructive jaundice, portal hypertension, intracystic hemorrhage, infection, intraperitoneal and/or intrahepatic rupture, torsion, and inflammation represent complications of nonparasitic hepatic cysts [21–24]. The compression exerted by a large hepatic cyst on the adjacent structures can manifest as cardiac arrhythmia or inferior vena cava thrombosis [25, 26]. The vicinity with the cholecyst can cause its functional disturbance with consecutive gallstones.

Hemorrhage into a simple liver cyst is rather uncommon but poses issues regarding differential diagnosis. The differential diagnosis between intracystic hemorrhage, cystadenoma, and cystadenocarcinoma is difficult with the imaging studies currently available. One consequence is to assume a simple cyst with intracystic hemorrhage as being neoplastic lesion and perform an unnecessary hepatectomy. The other consequence is to assume a neoplastic lesion as being benign and perform laparoscopic fenestration with subsequent peritoneal dissemination of malignant cells.

There are situations when an intracystic hemorrhage occurs unrecognized. Even if no acute symptoms supervene, the hemorrhage causes a rapid enlargement of the cyst, raising suspicion of malignant degeneration.

Infection of hepatic cyst can occur through common bile duct or blood stream. The most common encountered microorganisms are *Escherichia coli* and *Klebsiella pneumoniae*. *Proteus*, *Bacteroides*, and *Clostridium* are also incriminated in infection of hepatic cysts. The most likely source of infection for simple liver cysts is the gastrointestinal tract. Diverticulitis of the sigmoid colon and gut manipulation during abdominal operations have been found to be the cause of infectious complications of hepatic cysts [27]. The patients with diabetes mellitus, undergoing chronic hemodialysis or immunosuppressive therapy (e.g., after kidney transplant in patient with polycystic liver and kidney disease), are prone to develop such infections.

The patient with infected liver cyst presents with acute onset of right upper quadrant abdominal pain, diarrhea, and/or fever. There are situations when pain is absent, and the only symptoms are fever and malaise that render a complete workup to rule out other causes.

The rupture of serous hepatic cyst is a rare complication that needs emergency intervention. The cyst rupture is generally secondary to trauma, but a spontaneous one is also possible. The cyst fluid can enter the pleural or peritoneal cavity, causing pain in right upper quadrant or even diffuse abdominal pain due to peritoneal irritation.

Granuloma degeneration is a rare complication of the hepatic cysts (Figure 10). In severe form, it can resemble malignant invasion into surrounding tissues. The differential diagnosis is difficult to make even intraoperatively. Extensive excision of involved tissues is sometimes necessary [28]. Eventually histology delineates the diagnosis.

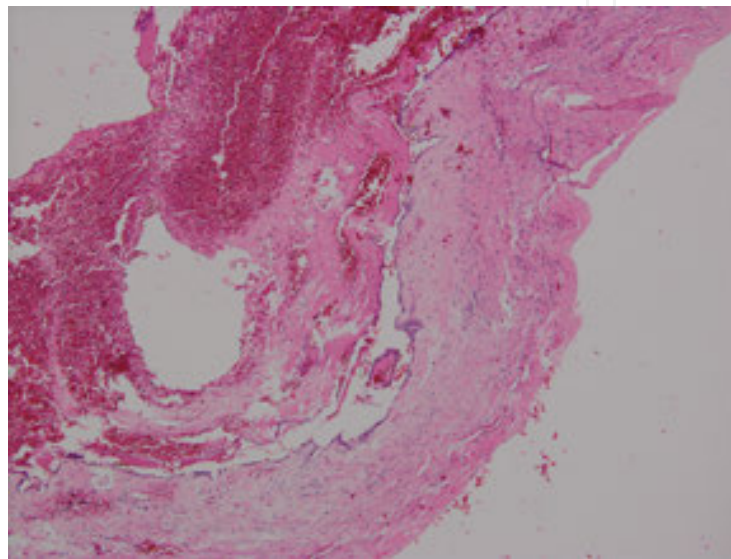


Figure 10. Serous cyst with granulomatous transformation, hyaline collagen fibrosis and focal, nonspecific chronic inflammation. Hematoxylin and eosin staining $\times 100$.

4. Diagnosis

Percutaneous abdominal ultrasonography (US) is the best imaging modality for diagnosis of serous hepatic cysts. US is generally the first choice diagnostic procedure because it is sensitive, specific, noninvasive, and readily available. The typical appearance of simple cyst on US is as follows: round or oval anechoic mass, well circumscribed, with thin and smooth borders or indiscernible walls, strong posterior echo enhancement, without mural vegetations, calcifications, or septations (Table 1).

Although US can offer reliable data regarding relations of the hepatic cysts to the vascular and biliary tree, the standard diagnostic protocol in our clinic includes CT with i.v. contrast substance. MRI is also useful to establish a correct diagnosis (Algorithm 1) [29].

Intraoperative use of an ultrasound probe, where the abdominal wall thickness is not an issue, allows the placement of a higher MHz ultrasound transducer directly on the liver surface. Therefore, intraoperative ultrasound images are much sharper and well defined than those

obtained through a transabdominal approach. Intraoperative US not only confirms the diagnosis but also adds important information to define the relation between the cysts and the surrounding structures (portal and hepatic veins, inferior vena cava, bile ducts), especially in deeply located cysts. Intraoperative US is also used to guide the surgeon for cyst approach in case no capsular expression is found. For laparoscopy, specially designed ultrasound probe and software are necessary.

	Simple cyst	Cystic echinococcosis	Alveolar echinococcosis	Cystadenoma and cystadenocarcinoma
Border	Sharp and smooth	Laminated, thick	Irregular	Irregular
Shape	Spherical or oval	Round or oval	Irregular	Round or oval
Echo pattern	Anechoic	Anechoic or atypical	Hyperechogenic outer ring and hypoechogenic centre	Hypoechogenic, with hyperechogenic floating material, fluid–fluid sedimentation
Appearance	No septa	Multiseptated	Multivesicular	Septations and/or papillary projections
Posterior acoustic feature	Relative accentuation of echoes	Dorsal shadowing (calcified areas)	Dorsal shadowing (calcified areas)	Dorsal shadowing (calcified areas)

Table 1. Ultrasonographic features for the diagnosis of monocystic diseases of the liver

CT and MRI can resolve the diagnosis of the doubtful cases and provide more information on the location of the cyst and relations with the great vessels and biliary tree. Thus, CT and/or MRI are mandatory for an appropriate treatment planning. US, CT, and MRI are complementary in evaluation of hepatic cysts. Based on imagistic examinations, parasitic cysts, neoplastic degeneration, and complications must be ruled out before pursuing any therapy decision.

On CT scan, simple hepatic cysts are well-defined, space occupying, round or oval-shaped, thin-walled, homogenous masses, with a density close to water (0–5 Hounsfield) and modest enhancement after contrast injection.

The presence of septa is not a common feature of the simple cyst, but multiple contiguous cysts can simulate it. For countries where hydatid disease is endemic, the differential diagnosis must include it because it is essential for therapeutic decision making.

The injection of intravenous contrast allows the manifestation of a possible communication between the cyst and the biliary tree on CT and MRI [29]. The communication of the hepatic cyst with the bile ducts can also be visualized using cystography, intraoperative cholangiography, and ERCP.

The mural calcifications are nonspecific but are usually present in echinococcal cysts and malignant lesions.

MRI provides valuable information concerning the nature of the cyst content and helps differentiating between blood and mucin [12]. MRI can identify a hypointense pseudocapsule

characteristic of the echinococcal cyst. MRI, especially associated with MRCP, is helpful for the diagnosis of biliary cysts, localized Caroli disease (Figure 4), intrahepatic biliary cystadenoma, and cystadenocarcinoma.

A liver cyst with intracystic hemorrhage appears as a heterogeneous echogenic cyst on US. For improved US imaging, an ultrasound contrast substance (e.g., Levovist, Bayer Australia Limited; SonoVue, Bracco International B.V.) can be used. The procedure is known as contrast-enhanced ultrasound (CEUS) and uses a microbubble agent that produces multiple small (approximately 3 μm) stabilized air bubbles when suspended in water. After intravenous injection of Levovist, Doppler enhancement of the blood pool is observed for 2–5 min, followed by a late hepatosplenic phase that lasts for more than 30 min. If no enhancement of the intracystic structures but an enhanced smooth cyst wall is observed on Levovist US, then an intracystic clot is suspected. On plain CT, the hemorrhagic cyst appears heterogeneous low-density (Figure 11). On MRI, T1-weighted images reveal the clot as low intensity and the fluid as high intensity, whereas T2-weighted images show the clot as low intensity and the fluid as high intensity [30].

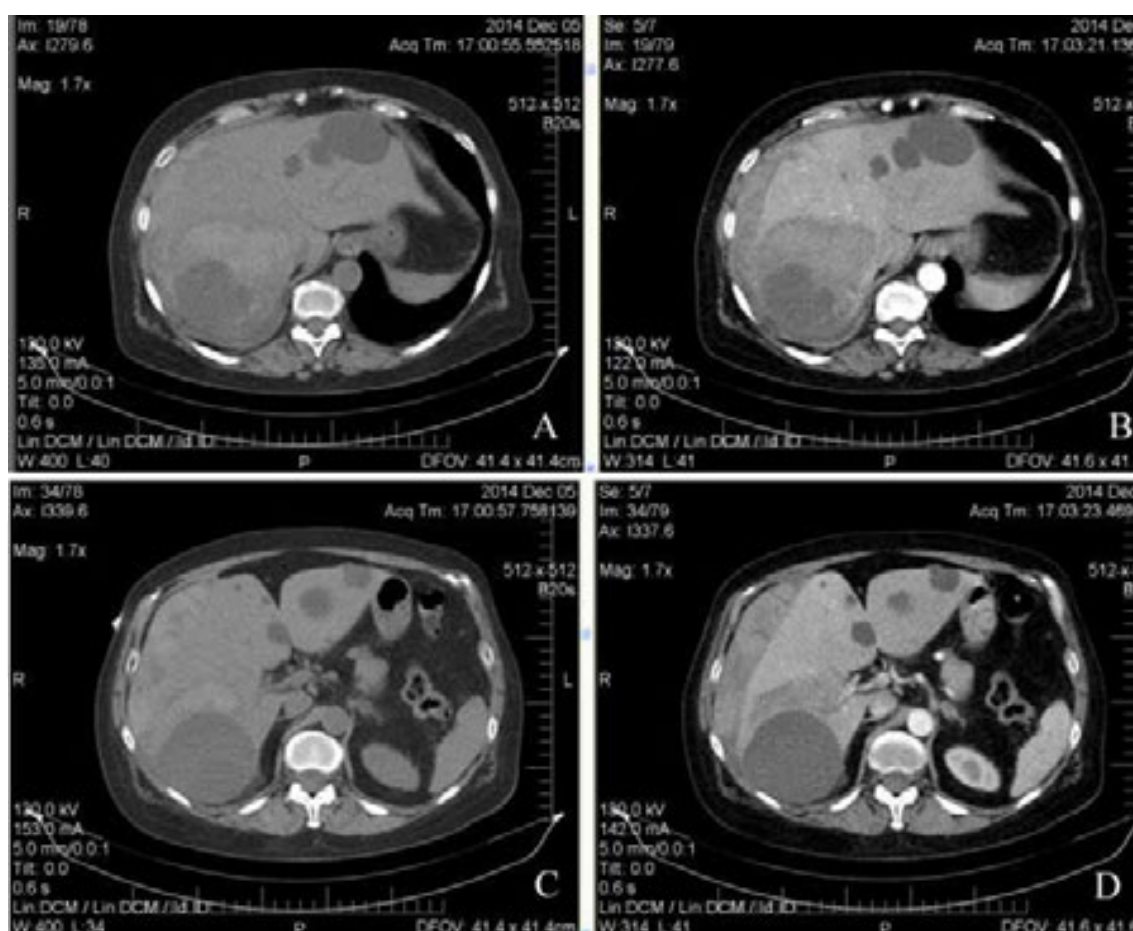


Figure 11. CT, axial view: multiple hepatic cysts, the largest cyst, located in segment VI–VII is ruptured in hepatic parenchyma; intracystic hematoma and extensive subcapsular hematoma are visible on the right hepatic lobe. (A, C) Native examination; (B,D) Examination with i.v. contrast administration.

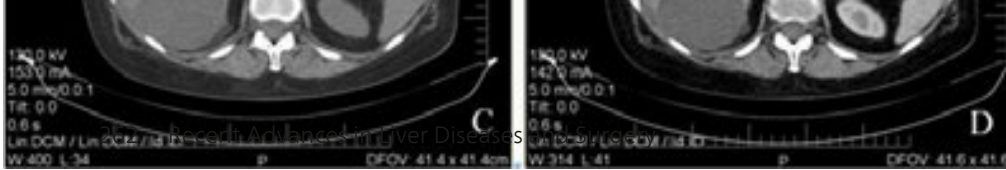


Figure 11. CT, axial view: multiple hepatic cysts, the largest cyst, located in segment VI–VII is ruptured in hepatic parenchyma; intracystic hematoma and extensive subcapsular hematoma are visible on the right hepatic lobe. (A, C) Native examination; (B, D) with i.v. contrast administration.

On US, the differential diagnosis between intracystic hemorrhage and neoplastic degeneration may be challenging when intracystic parietal protrusions are identified (Figure 12). If no Doppler signal exists, these protrusions may be interpreted as sedimentations of hematin on the cyst wall. On macroscopic examination during operation, these protrusions have the equivalent of the blackish-brown deposits that stain the cyst wall. If Doppler signal is certified in the intracystic mural protrusions, then malignancy is highly considered.

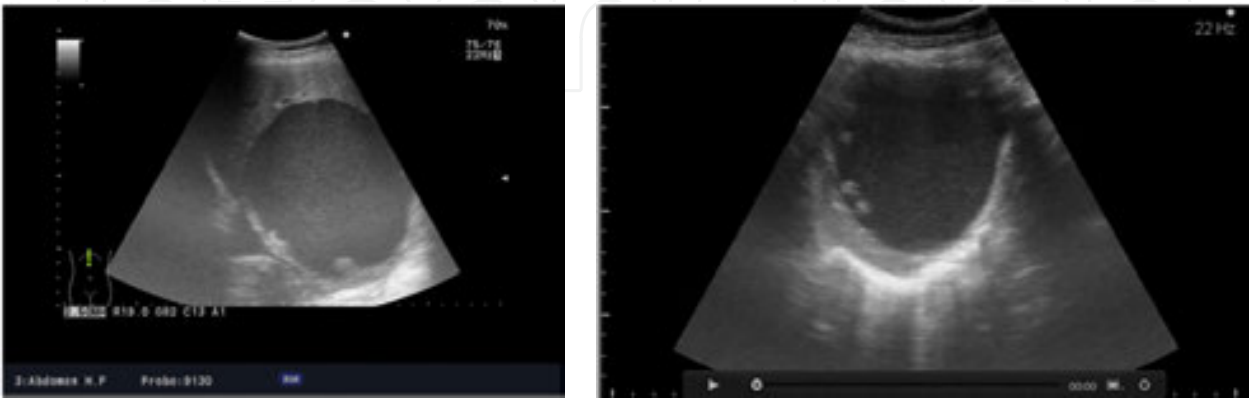


Figure 12. Transabdominal US for a cystic mass in the liver: the mass is anechoic, homogenous, with thin border, without calcifications, but with small hyperchoic parietal protrusions that do not change with patient's position. On Doppler examination, these protrusions are avascular and on CT are not visible. The intraoperative and histological diagnosis was serous hepatic cyst with hemorrhagic content. Cystadenocarcinoma had to be ruled out. Patient was submitted to open surgery.

Gallium scintigraphic study can be used to search for the site of infection in a patient with a previous diagnosis of simple hepatic cyst [27]. 18-F-fluorodeoxyglucose is useful for the detection of cyst infection using positron emission tomography in patients with multiple liver and renal cysts [31]. In a patient diagnosed with hepatic cyst, any febrile status should raise the question of its possible infectious complication.

In case of cyst rupture, on imaging scans, irregularities of the partially evacuated cyst wall, heterogeneous content, fluid under the liver capsule, or free liquid in the peritoneal or pleural cavity are depicted.

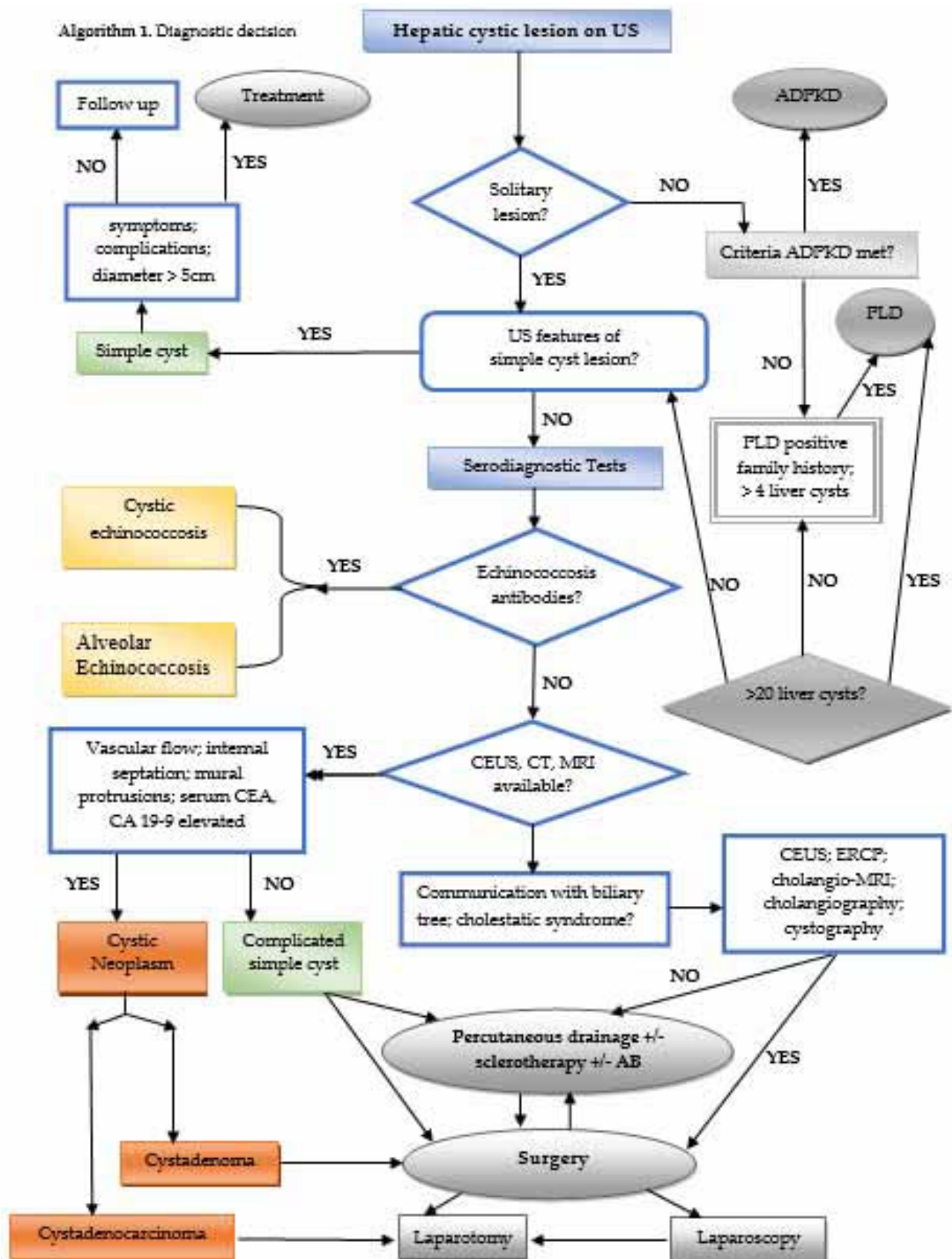
Nonparasitic hepatic cysts may coexist with other hepatic lesions, bringing out the issue of correlation the lesion with the patient's symptoms and also of adopting the right management decision.

Nonparasitic hepatic cysts may coexist with other hepatic lesions, bringing out the issue of correlation the lesion with the patient's symptoms and also of adopting the right management decision.

9

Nonparasitic cysts may coexist with parasitic ones (Figure 13). Even if the size of nonparasitic cyst does not justify its fenestration, it is recommended to solve both types of cysts in the same operation in order to avoid future misdiagnosis between the nonparasitic and parasitic cyst.

Nonparasitic hepatic cysts may coexist with other benign or malignant liver tumors. When a benign tumor lesion (e.g., hepatic hemangioma) is diagnosed besides hepatic cyst, there is an issue regarding which lesion should be treated to elevate the pain in the right upper quadrant (Figure 14).



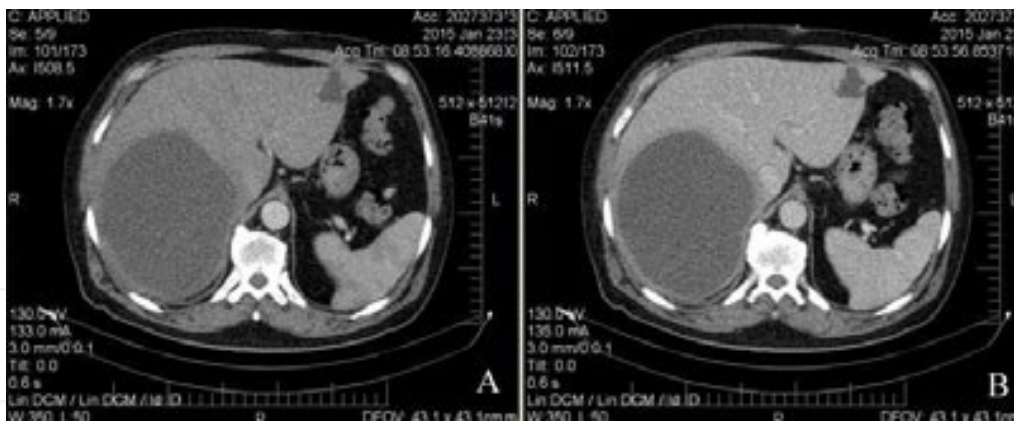


Figure 13. CT, axial view: voluminous hydatid cyst in the right hepatic lobe and small cyst mass in segment II-III. (A) Native; (B) after administration of i.v. contrast.

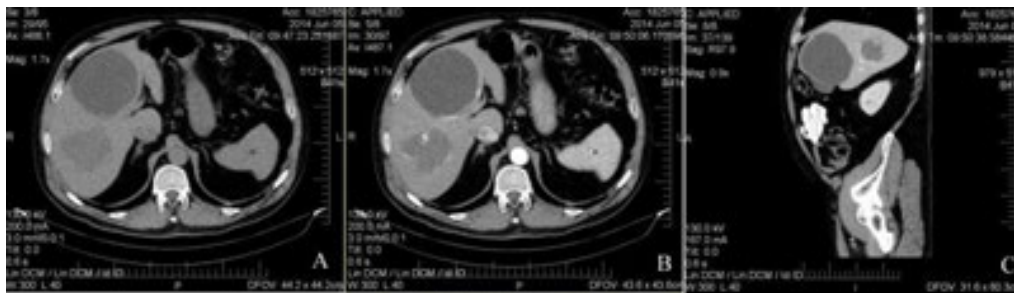


Figure 14. CT showing coexistence of two hepatic lesions: central simple hepatic cyst, in close proximity with gallbladder, and hepatic hemangioma in segment VI. (A) Axial view, native; (B) axial view, after i.v. contrast, arterial phase; (C) sagittal view, after i.v. contrast, arterial phase. Patient was submitted to laparoscopic fenestration of the hepatic cyst. The operation was successful in abolishing the right quadrant pain.

Nonparasitic cysts can also coexist with peripheral cholangiocarcinoma. The association was found in patients with PLD after kidney transplantation. The presence of liver metastasis from colorectal cancer was also found in patients with PLD (Figure 15).

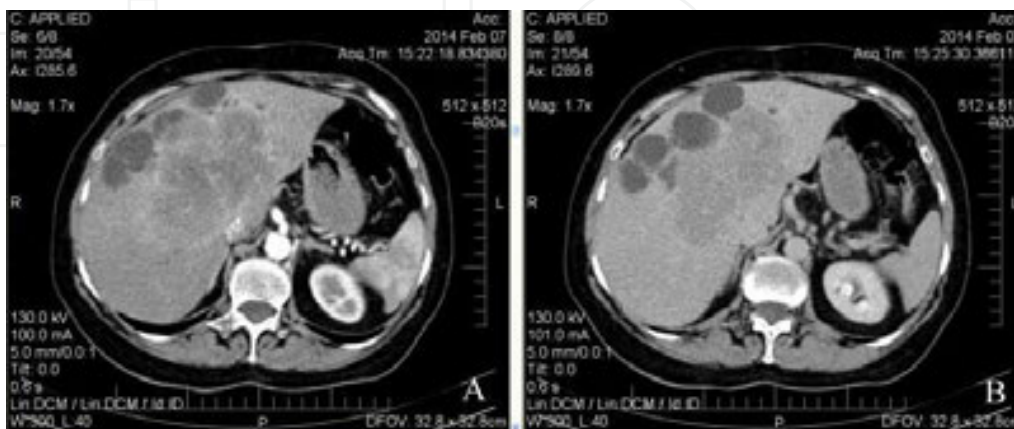


Figure 15. CT, axial view, with (A) and without (B) i.v. contrast showing coexistence of a bulk solid liver metastasis from colonic cancer in a patient with previously known PLD.

Serological tests for *Echinococcus* are electrosyneresis, hemagglutination, and ELISA (enzyme-linked immunosorbent assay) (the latter two being quantitative) [32]. The specific serology for *Echinococcus* has a sensitivity of 80% in the diagnostic process of parasitic cysts.

Serum tumor markers (e.g., CA 19-9 and CEA) must be checked to rule out neoplasia.

Right upper pain requires workup to exclude other associated pathology that may be the only or in addition responsible for causing the symptoms. Thus the surgeon should rule out cholelithiasis, gastroesophageal reflux disease, peptic ulcer disease, acute gastritis, or colorectal cancer. Upper and lower gastrointestinal endoscopy can reveal such pathologies and help avoiding misdiagnosis and mistreatment based solely on the pain supposedly caused by the hepatic cyst.

5. Treatment

Asymptomatic single liver cysts do not require treatment or surveillance. Symptomatic and complicated hepatic cysts require therapeutic intervention (Algorithm 2). It is considered that surgery is necessary for cyst of more than 5 cm in diameter. The primary indication for surgery is troublesome pain.

5.1. Percutaneous treatment

Percutaneous aspiration under ultrasound guidance of the cyst fluid is a mini-invasive procedure with a high recurrence rate if it is not associated with injection of a sclerosing agent in the remnant cavity.

Percutaneous treatment is performed on an inpatient basis under local anesthesia with lidocaine or sedation. For cyst puncture, an 18-gauge aspiration needle can be used. The puncture line must be chosen through normal hepatic parenchyma to avoid fluid leakage into peritoneal cavity. To prevent intracystic bleeding during evacuation caused by the sharp contact of the needle with the cyst wall, a 6- to 7-F catheter can be used instead. After complete evacuation of the cyst, the fluid is sent to cytological and bacteriological examination. Even in the absence of obvious signs of communication of the cyst with the biliary tree, this possibility must also be ruled out before injecting the sclerosant. Otherwise, an irreversible sclerosing cholangitis may supervene. There are available some imagistic methods to check the communication between liver cyst and biliary ducts. The most feasible and reliable method is the injection of a diluted US contrast agent (e.g., 2–4 drops of SonoVue, Bracco International B.V. in 40–200 ml 0.9% saline) in the evacuated cyst. The volume of contrast agent injected is the same or lower than the aspirated one [33]. Other alternative methods in ruling out cyst–biliary tree communication are cystography, ERCP, and bile duct scintigraphy [23].

Only after the absence of biliary communication is certified, the instillation of the sclerosant is allowed. One has to choose from a list of sclerosing agents that include ethanol [34–36],

minocycline hydrochloride [37], tetracycline chloride [38], hypertonic saline solution [39], polidocanol [40], and ethanolamine oleate [41].

Ethanol has remained the most used sclerosing agent. It destroys the cell lining of the cystic cavity and discontinues the cystic fluid secretion. Different concentrations of ethanol (95–99%) and different volumes (10–50% of the cystic volume) have been reported. The exposure time varies from 10 min to 4 h. In order to minimize ethanol side effects, time exposure to ethanol should be less than 60 min. When using ethanol instillation, the cyst must be completely evacuated, a condition that is not necessary when using other sclerosing agents. After complete cyst evacuation, its walls collapse hampering the thorough distribution of sclerosant, with the risk of its subsequent lobulation. The other sclerosants are active in small concentration and do not need complete evacuation of the cystic fluid. When the cyst is only partially evacuated, the misplacement of needle tip is also avoided. The residual fluid is progressively resorbed through microscopic communication between the cyst and the surrounding liver parenchyma. Polidocanol needs only one application. Its application is painless and hence no intracystic anesthesia or sedation is required [33].

The percutaneous treatment can be repeated when necessary. Percutaneous drainage must be done under antibiotic prophylaxis. The recommended antimicrobial is ciprofloxacin because cephalosporins (e.g., cefazolin) were not found totally successful in preventing cyst infection after drainage [42]. Even if infection of the remnant cavity occurs, it can be remitted by oral Ciprofloxacin (500 mg twice daily) associated or not with clindamycin (300 mg three times daily) [42]. Oral ciprofloxacin is also indicated as the first line treatment in infected cysts [43].

5.2. Radiofrequency ablation

Radiofrequency ablation (RFA) for the treatment of hepatic cysts with the largest diameter up to 10 cm was reported to be efficient, safe, and free from complications [44].

5.3. Surgical treatment

High success rates in the treatment of hepatic cysts were reported being associated with laparoscopic or open deroofting [24].

5.3.1. Laparoscopic approach

Laparoscopic fenestration was first reported by Z'graggen in 1991 [45]. Being associated with low recurrence rate, reduced morbidity, and short hospital stay, laparoscopic fenestration tends to become the standard treatment for the simple hepatic cysts.

The indications for laparoscopic approach are determined not by the size but the location of the cysts, being limited to those located in the segments II, III, IV, V, and VI (Figure 16) [29]. However, some authors advocate that the use of a flexible laparoscope facilitates the laparoscopic approach of lesions located in the postero-superior segments of the liver (segments I, VII, and VIII) [46]. Hepatic cysts that cannot be entirely explored laparoscopy are not candidates for laparoscopic approach.

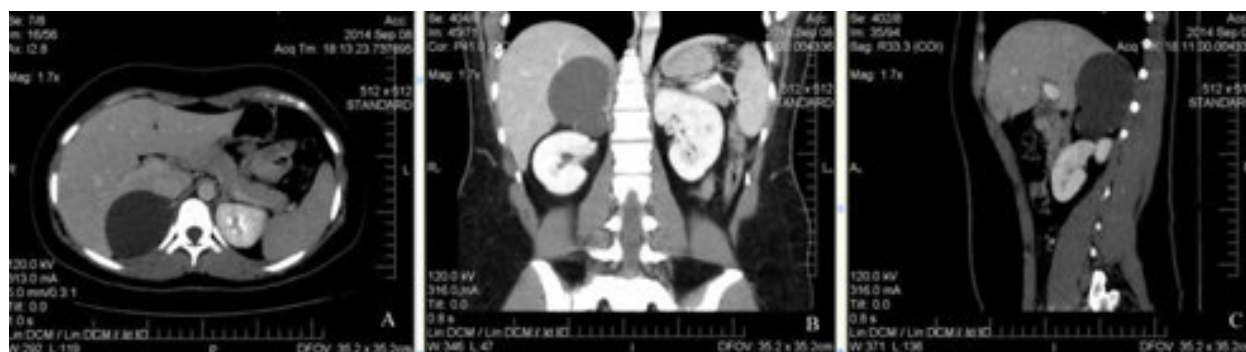

Figure 16. CT showing serous hepatic cyst in segment VI-VII. (A) Axial view, (B) coronal view, and (C) sagittal view. Laparoscopic approach is not indicated for such localization of the hepatic cyst.

Laparoscopy is not suitable for fenestration in case of close proximity of the cyst wall to the hepatic veins and inferior vena cava (Figure 17) [47].

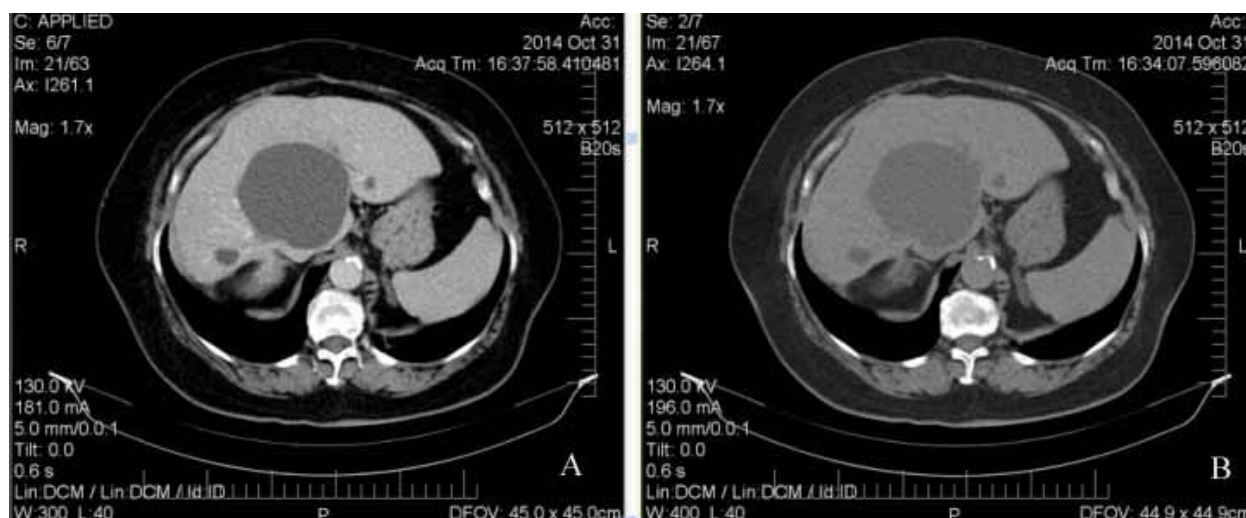


Figure 17. CT, axial view, with contrast (A) and without contrast (B): large simple hepatic cyst in contact with the inferior vena cava and hepatic veins and other two small cysts in proximity. Patient was submitted to open surgery.

Previous laparotomies or laparoscopies are not considered contraindications to the laparoscopic approach.

A 30° laparoscope is used. A medium CO₂ insufflation and an intra-abdominal pressure less than 12 mm Hg should be used to avoid gas embolism. Liver veins are little prone to collapse in the supine position. The effect of venous gas embolism depends on the rate of CO₂ infusion and its volume. For adults, the potentially lethal volume is estimated at 200–300 ml or 3–5 ml/kg [48]. Surgeons must routinely purge laparoscopic tubing systems with CO₂ gas. If the system is not adequately purged with CO₂ gas before, substantial amounts of air (containing 79% of the insoluble N₂) may be insufflated into the peritoneal cavity from the tubing and may cause air embolism [48]. Generally, the patient lies in the supine position with/without abducted legs or lithotomy position on the operating table. A left side-lying position of the patient can help approaching liver cysts located in the segments V-VI.

The operative procedure in the standard operation of fenestration is performed using three or four ports. One 10-mm trocar is inserted into the abdominal cavity through the umbilicus as an observation port. The main operating hole is located under the xiphoid and is made to accommodate a 10- or 12-mm trocar. Another hole is placed in the right upper quadrant of the abdomen at the medioclavicular line for insertion of a 5-mm trocar. An additional port can be placed for exposure, depending on the cyst localization.

On video inspection, the liver mass appears exteriorized on the hepatic surface with a translucent wall. If the serous hepatic cyst has no complication, there are no tight adhesions to the surrounding tissues. Instead, if the cyst is complicated by inflammation, infection, or hemorrhage, the surface of the corticalized cyst may develop tight adhesions to the surrounding organs and the cyst wall appears thick and thus indistinguishable from other hepatic cysts (e.g., hydatid cyst, pyogenic abscess, and tuberculoma) (Figure 18).

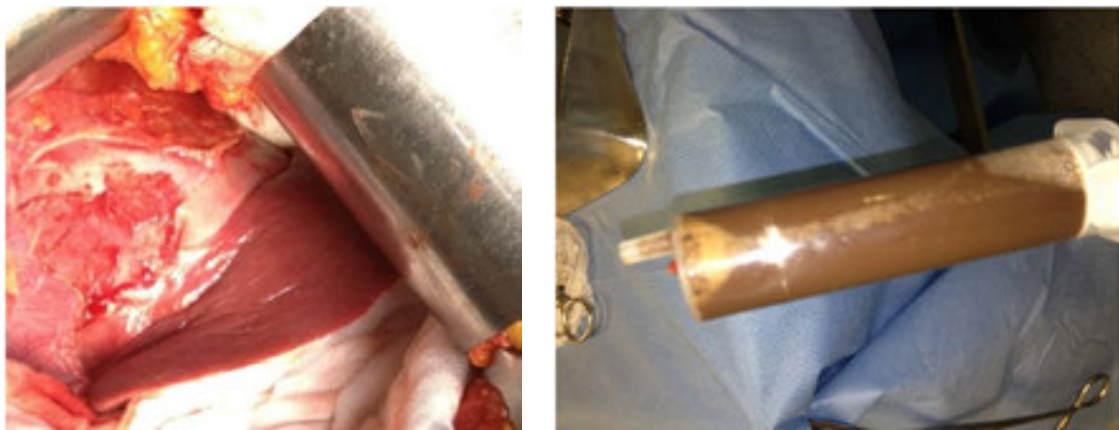

Figure 18. Serous cyst in segment IV, V, and VIII. (A) Intraoperative aspect of complicated hepatic cyst with adhesions to the diaphragm and with thick wall that make it undistinguishable from hydatid cyst. (B) Intraoperative aspect of a thick wall that make it undistinguishable from hydatid cyst. The brownish color is likely the result of an unrecognized intracystic hemorrhage.

After cyst evacuation, a large access to the cavity of the duct should be obtained. The walls of the cyst are carefully inspected to identify possible lesions, possibly malignant and neoplastic changes. Any wall must be biopsied and sent to the frozen section. All lesions should be malignant and neoplastic changes. If the laparoscopy is converted to an open operation, plastic changes are found, the laparotomy is done, the cyst is separated, and visualized, then the performed microscopic exams, intracystic septa, or cystadenoma appearance on frozen sections, hepatoma can be performed laparoscopically, or clearly all the affected segments.

Any suspected communication with the bile duct should be carefully investigated intraoperatively. Some authors consider the closure of the open bile duct under laparotomy to be a more rational choice [49]. Other authors advocate for laparoscopic closure of the communication with the bile duct [50]. Recurrence is low if wide cyst wall resection is accomplished. Fenestration can be carried out by electrocautery hook, bipolar scissors, high frequency bipolar electrocoagulation LigaSure™ (Valleylab, Tyco International Healthcare, Boulder, CO), Ethicon Ultracision Harmonic Scalpel LCS-5 (Ethicon, Cincinnati, Ohio), or cutting stapler. Argon beam coagulation may complete hemostasis. The cystic dome is resected up to 3–5 mm from the hepatic parenchyma to avoid hemorrhage and bile leakage from the sut edge section is liver parenchyma. The resected cyst is sent for permanent histopathologic evaluation. If the cyst is not well corticalized on the liver capsule and the standard unroofing of the cyst is considered of inadequate size that is an predispose to recurrence, then the cyst wall should be excised including a 3- to 4-mm rim of hepatic parenchyma. If the bile is spilled along the cystic edge, a hemostatic clip or a tie suture can be applied [46].

In case of aspiration of a straw-colored liquid and in the absence of bile staining of the cystic wall, intraoperative cholangiography is not indicated. However, in case of bile contamination of the cyst or compression of the biliary tree, intraoperative cholangiography is required to evaluate the biliary tree [51]. Intraoperatively missed biliary communication could lead to prolonged biliary fistula and even biliary peritonitis.

Sclerosant or alcohol application on the remnant wall of the cyst is recommended to prevent possible further fluid secretion by cyst epithelium and, hence, hepatic cyst recurrence. The great omentum should be packed into larger cavities to decrease dead space and prevent fluid collection. An omental flap transposition is recognized as an important

complete hemostasis. The cystic dome is resected up to 3–5 mm from the hepatic parenchyma to avoid hemorrhage and bile leakage from the cut edge of the liver parenchyma. The resected cyst is sent for frozen section and permanent histopathologic evaluation. If the cyst is not well corticalized on the liver capsule and the standard unroofing of the cyst is considered of inadequate size that can predispose to recurrence, then the cyst wall should be excised including a 3- to 4-mm rim of hepatic parenchyma. If the bile is spotted along the cystic edge, a hemostatic clip or a tie suture can be applied [46].

In case of aspiration of a straw-colored liquid and in the absence of bile staining of the cystic wall, intraoperative cholangiography is not indicated. However, in case of bile contamination of the cyst or compression of the biliary tree, intraoperative cholangiography is required to evaluate the biliary tree [51]. Intraoperatively missed biliary communication could lead to prolonged biliary fistula and even biliary peritonitis.

Sclerosant or alcohol application on the remnant wall of the cyst is recommended to prevent possible further fluid secretion by cyst epithelium and, hence, hepatic cyst recurrence. The great omentum should be packed into larger cavities to decrease dead space and prevent fluid collection. An omental flap transposition is recognized as an important aid in reducing the risk of cyst recurrence, but it is contraindicated in infected cysts.

The drainage of the remnant cavity must meet the declivity principle, especially for those cysts situated in the upper liver segments. The main reason for reconstitution of the cyst after operation is the coverage of the remnant cavity by the diaphragm. To establish a dry residual cavity after fenestration of liver cysts located in the segments VII and VIII, the vacuum effect of the respiratory movements of the diaphragm should be counteracted by an efficient external drainage. The drainage tube should be left in place until complete cessation of the secretion certified by ultrasound evaluation. The use of pigtail catheters for drainage is preferred to the usual drainage tubes for upper sited liver cysts. The realization of an efficient external drainage might be accomplished by transparenchymatous placement of the tube.

The atypical hepatic resections for large and/or multiple hepatic cysts that occupy more segments are laparoscopically feasible if performed by surgeons with advanced training in this technique. Most of these atypical hepatectomies involve the left lobe (Figure 19). Generally, the cut surface of the liver remains covered by the cyst wall.

5.3.2. *Single-incision laparoscopy*

Single-incision laparoscopic surgery can reach the effect of “no scar” and can be safely and effectively carried out in these patients. The operation is performed using a dedicated port such SILSTM Port (Covidien, MA, USA), GelPort® Laparoscopic System (Applied Medical, CA, USA), QuadPort+ (Olympus, PA, USA), or X-cone (Karl Storz, Germany). However, three trocars can also be used by their insertion into abdominal cavity through one 2.5-cm incision designed along the ventral midline on the upper edge of the umbilicus. The incision is sufficient to accommodate one 10-mm trocar and two 5-mm trocars [19]. The abdominal drainage tube can be appropriately placed through the same incision at the end of cyst fenestration. If the telescope cannot directly observe the liver cyst, the patient is not suited for single-incision laparoscopic surgery.

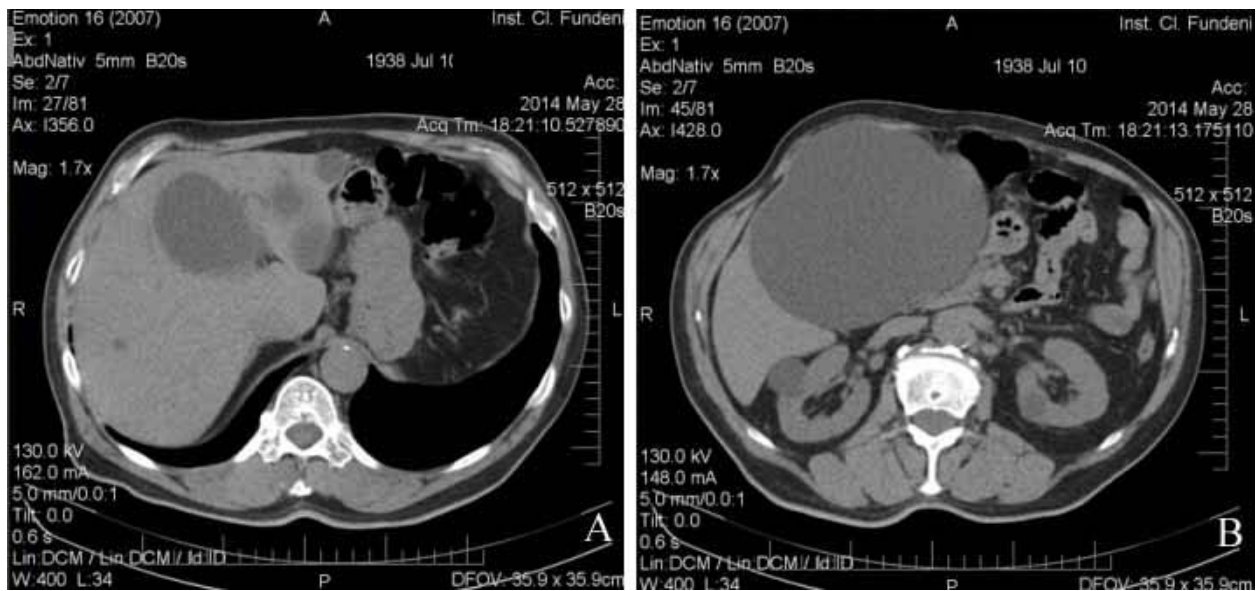


Figure 19. Patient with PLD and ADPKD operated by laparoscopic approach for hepatic cysts. CT in axial view shows small serous cysts grouped in segments II and III (A) and a large serous cyst in segment IV (B). Laparoscopic intervention was successfully performed.

Minilaparoscopic-assisted transvaginal approach is also mentioned [52].

5.3.3. Robotic approach

Robotic surgery is another possible approach, and it has been used in our clinic for nonparasitic hepatic cyst fenestration. The use of the Da Vinci robotic surgical system has certain technical advantages over the standard laparoscopic technique in case of the posterior location of the liver cysts [53]. However, conversion to laparoscopic or open surgery in case of difficulty is laborious and time consuming and could be life-threatening in a dire emergency.

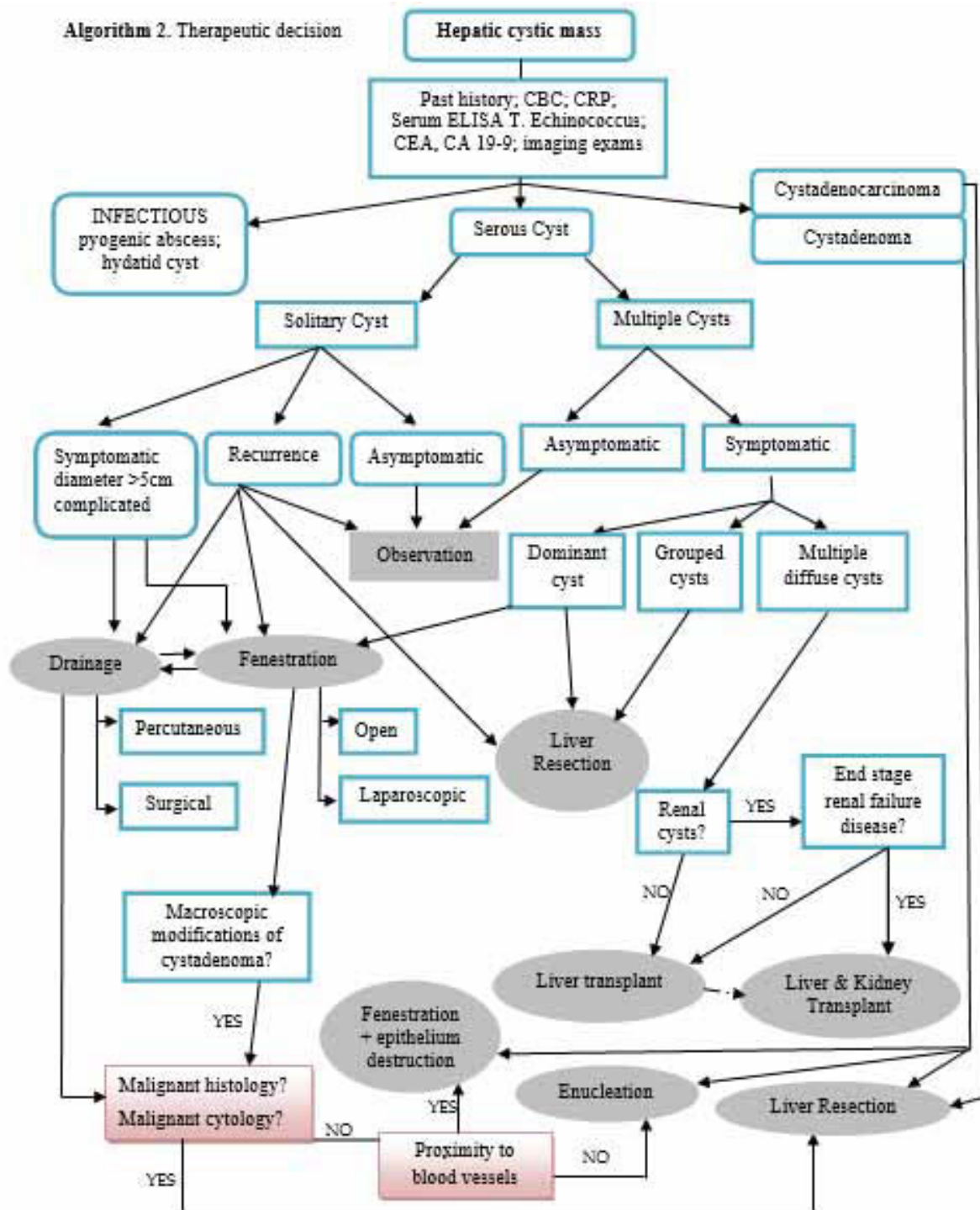
5.3.4. Classic approach

The communication between cystic cavity and bile duct encountered during operation can be managed in different ways. The suture of the biliary communication is enough, but the means of doing that depend on different surgeons. Cystojejunostomy is mentioned by some authors [54], but it became history in our clinic. Biliary-enteric anastomosis is necessary if there is a concern of postoperative leak or intrahepatic biliary obstruction after suture control [55].

If cystadenoma is suspected, due to its malignant potential, the recommended therapy is laparoscopic or open cyst enucleation or liver resection. But if any suspicion of cystadenocarcinoma exists or especially if malignancy is proved by cytology of aspirated cyst fluid or frozen sections, the surgical decision should be open liver resection with tumor-free margins.

Enucleation is generally feasible due to the existence of a well-defined plane between the cyst wall and the normal liver parenchyma that is generally avascular (Figure 20). For cysts centrally situated, with an increased risk of intraoperative hemorrhage, Pringle maneuver

Algorithm 2. Therapeutic decision



brings clear benefits. If there is a direct contact of the cyst wall with the portal pedicle, hepatic vein, or inferior vena cava, that portion of the wall can be abandoned if no malignancy is identified on frozen sections (Figure 21). However, there still remains the risk of abandoning malignant areas or malignant degeneration of the remnant cyst wall over time. For this reason,

ation is generally feasible due to the existence of a well-defined plane between the cyst wall and the normal hepatic parenchyma that is generally avascular (Figure 20). For cysts centrally situated, with an increased risk of intraoperative hemorrhage, Pringle maneuver brings clear benefits. If there is a direct contact of the cyst wall with the portal pedicle, or inferior vena cava, that portion of the wall can be abandoned if no malignancy is identified on frozen section. However, there still remains the risk of abandoning malignant areas or malignant degenerating cyst wall over time. For this reason, it is recommended to destroy the epithelium lining of the remnant cyst wall by electrofulguration or argon beam coagulation.

The effective treatment for an infected hepatic cyst is antibiotherapy combined with percutaneous drainage of malignant cytology and/or histopathology, the only potentially curative treatment is complete removal of the cyst, usually by a major liver resection with 1 cm free margin [45]. A shortening of time for sclerosant instillation is suggested by others [56]. In case of failure of the mentioned treatment, there is a need for surgery.

By authors. A shortening of time for sclerosant instillation is suggested by others [56]. In case of failure of the mentioned treatment, there is a need for surgery.

Intracystic or intraparenchymatous hemorrhage is certain, the active bleeding with negative hemodynamic is an emergency operation. Otherwise, the percutaneous treatment may be the first option.

In dealing with cyst rupture, there is no standard therapy. In the presence of peritoneal irritation for internal hemorrhage, emergency operation is the rule. In the absence of such signs, the management may vary from conservative treatment with close observation to surgical intervention [57].

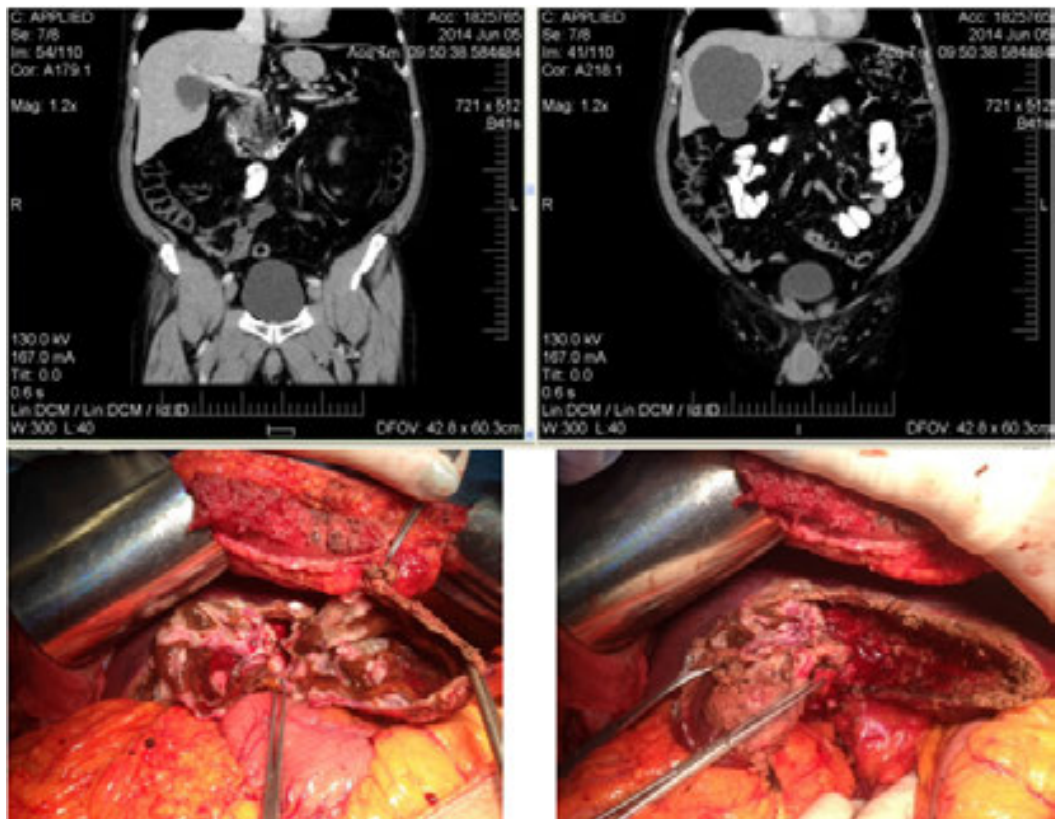


Figure 20. Recurrent cyst in segments IV–V with close proximity to the right portal pedicle (A) and gallbladder (B) on CT, coronal views. Intraoperative view of the gallbladder (B) on CT, coronal views. Intraoperative aspect of a thick cyst wall (C) and of hepatic parenchyma after cyst enucleation (D).

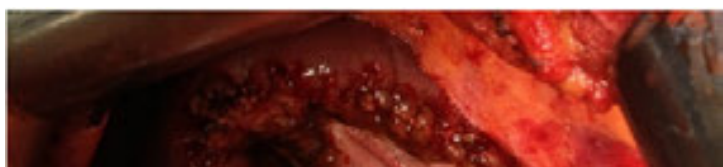

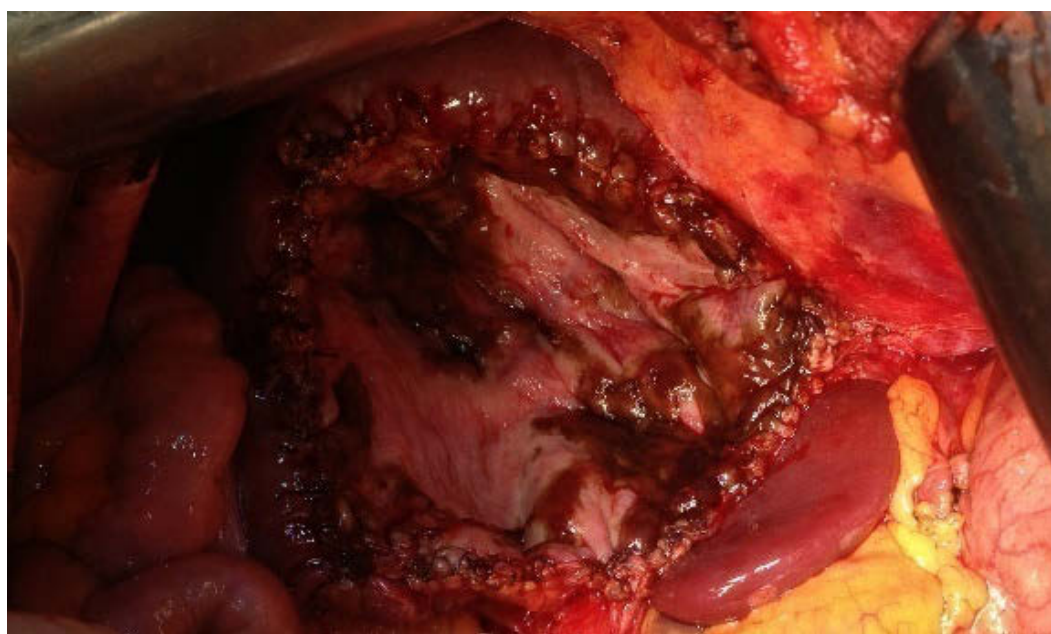


Figure 21. Intraoperative feature of the abandoned wall of a huge serous cyst that occupied segments IV and VIII and contained a chocolate-like fluid. The hemostasis on the hepatic rim was achieved by continuous suture.

5.3.5. Treatment of PLD

The appropriate treatment of PLD is based on Gigot's classification on CT findings. Most current therapies are invasive. However, the conservative management with lanreotide, a long-acting somatostatin analogue, is promising, being associated with a reduction of liver volume in PLD [58, 59]. Sclerotherapy is considered ineffective in the management of PLD. Laparoscopic fenestration is feasible only for PLD type I in Gigot's classification (Figure 22). For type II, open fenestration is indicated. For type III, only liver resection or liver transplantation is permitted in symptomatic patients. If liver transplantation is anticipated, fenestration or resection should be avoided to decrease postoperative morbidity and mortality.

5.3.6. Liver transplantation for PLD

Most of the patients with PLD have combined liver and kidney cystic disease. There are questions regarding whether kidney and liver transplantation must be performed and whether these transplants should be performed simultaneously or consecutively. The patients with advanced renal failure (dialysis or predialysis stage) need combined liver and kidney replacement. However, those patients who have normal renal function do not need a combined transplantation. It was reported that maximum 33% of the patients who first received a liver transplant alone needed a kidney transplant later [60]. In many patients, the renal function improves after orthotopic liver transplantation (OLT), possibly due to the release of compartment syndrome. Massive hepatomegaly causes an abdominal compartment syndrome that negatively affects renal function which can be reversed after OLT. Other authors argue that a combined liver and kidney transplantation should be performed even in patients with limited

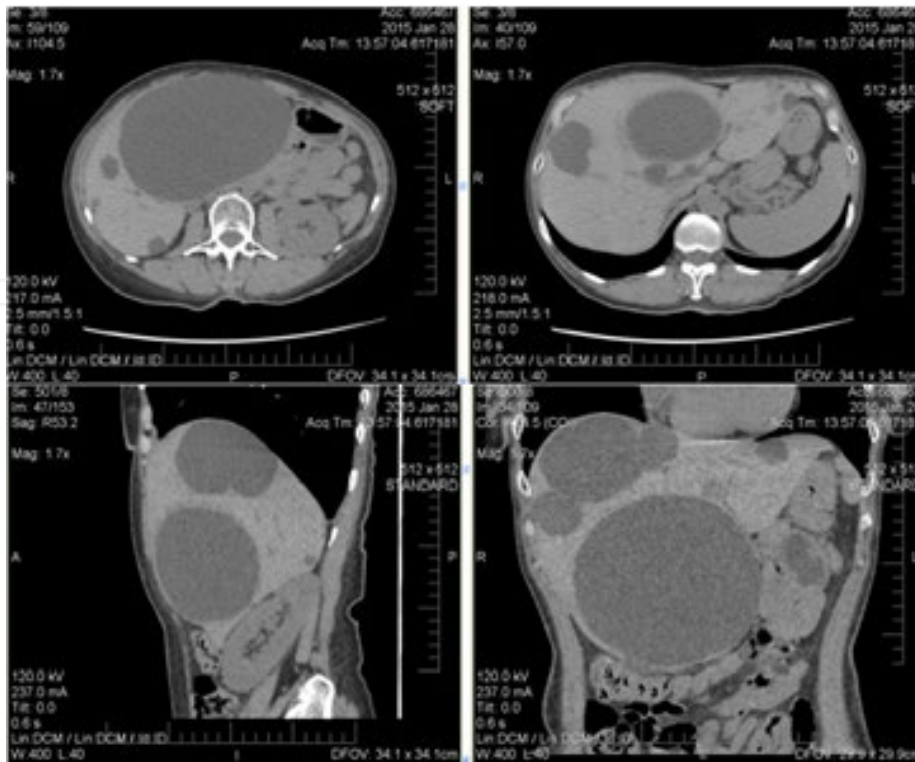


Figure 22. CT for a female patient with PLD submitted to laparoscopic

fenestration of the largest cysts situated in the hepatic segments IV–V, and VII–VIII. **Figure 22.** CT for a female patient with PLD submitted to laparoscopic fenestration of the largest cysts situated in the hepatic segments IV–V, and VII–VIII. (A) Axial view of the upper liver. (B) Axial view of the lower liver. (C) Sagittal view of the liver. (D) Coronal view of the liver.

5.3.6. Liver transplantation for PLD

renal dysfunction or even normal renal function. This strategy is justified by the progression of cystic renal disease after OLT and the immune advantage in transplanting both organs harvested from the same donor, rather than having to perform a third-party kidney trans-

plantation later [61]. Most of the patients with PLD have combined liver and kidney cystic disease. There are questions regarding whether kidney and liver transplantation must be performed and whether these transplants should be performed simultaneously or consecutively. The patients with advanced renal failure (dialysis or predialysis stage) need combined liver and kidney replacement. However, those patients who have normal renal function do not need a combined transplantation. It was reported that maximum 33% of the patients who first received a liver transplant alone needed a kidney transplant later [60]. In many patients, the renal function improves after orthotopic liver transplantation (OLT), possibly due to the potential hazards associated with OLT procedure and postoperative immunosuppression, and the release of compartment syndrome. Massive hepatomegaly causes an abdominal compartment syndrome that negatively affects renal function which can be reversed after OLT. Other authors argue that a combined liver and kidney transplantation should be performed even in patients with limited renal dysfunction or even normal renal function. This handicap. Generally, these patients have preserved liver function and normal model for end stage liver disease (MELD) score if they do not have renal involvement [63].

OLT is a rare procedure for PLD. It represents approximately 1% of all indications [62]. Total hepatectomy followed by OLT offers the chance of definitive treatment. The indication of OLT may be too drastic considering the absence of immediately life-threatening liver failure, the potential hazards associated with OLT procedure and postoperative immunosuppression, and the organ shortage. Indications for OLT in PLD are massive hepatomegaly, compartment syndrome, and clinically advanced malnutrition that produce severe physical and social handicap. Generally, these patients have preserved liver function and normal model for end stage liver disease (MELD) score if they do not have renal involvement [63].

Two drawbacks to OLT for patients with PLD are the susceptibility to infection caused by severe malnutrition and overimmunosuppression and further degradation of renal function caused by immunosuppression. Therefore, the maintenance of immunosuppression in such patients must be lower than usual and the steroids should be discontinued after 3 months. It is also important not to delay OLT in these patients; otherwise, complications such portal vein thrombosis, portal hypertension, Budd–Chiari syndrome, peripheral cholangiocarcinoma, and liver failure may result in poorer tolerance of the patient to procedure, increased graft loss, and increased costs [62].

The first report of OLT for PLD was by Kwork and Lewin in 1988, but the patient died intraoperatively of intractable bleeding. In 1990, Starzl successfully performed OLT on 4 patients with PLD.

OLT in PLD is technically challenging because of the massive organomegaly (Figure 23). If OLT is anticipated on a

The first report of OLT for PLD was by Kwork and Lewin in 1988, but the patient died intraoperatively of intractable bleeding. In 1990, Starzl successfully performed OLT on 4 patients with PLD.

OLT in PLD is technically challenging because of the massive organomegaly (Figure 23). If OLT is anticipated on a patient with PLD, then any other surgical interventions should be withheld in order to avoid massive intraoperative bleeding and thus transfusion requirements.

The anatomic position of the vessels is not respected in patients with PLD. In total hepatectomy, dissection starts in the liver hilum because it is the only structure that lies at a near-normal anatomic position. Hepatic artery, portal vein, and principal biliary duct are identified. No attempt is made to control the suprahepatic vena cava at the beginning of dissection. Early attempts at controlling it may result in its laceration, fatal bleeding, and pulmonary air embolism. Patients with PLD have little portal hypertension and spontaneous portocaval shunts and thus poor tolerance of portal clamping [62]. The surgeons must be prepared for portal bypass if hypotension develops when portal vein is clamped. Other surgeons systematically use portal bypass. By dissecting portal vein for cannulation, a broad exposure of the intrahepatic vena cava is obtained. The decision of inferior vena cava resection is made based on the intraoperative conditions determined during the dissection phase [64]. Some surgeons choose to continue the dissection of the liver en bloc with the native vena cava and eventually safely control the suprahepatic vena cava. The en bloc resection of the liver with the native vena cava is justified by the fact that usually the cava vein is embedded within an extremely voluminous caudate lobe [62]. There are other surgeons who performed dissection of liver parenchyma from IVC. Cysts were aspirated to facilitate final access to the suprahepatic inferior vena cava. However, one should be prepared for vein control through transdiaphragmatic or transsternal approach.

Transcatheter embolization has been proposed to decrease arterial supply of the cysts and thus reduce the liver size and may be beneficial prior to liver transplantation [65].

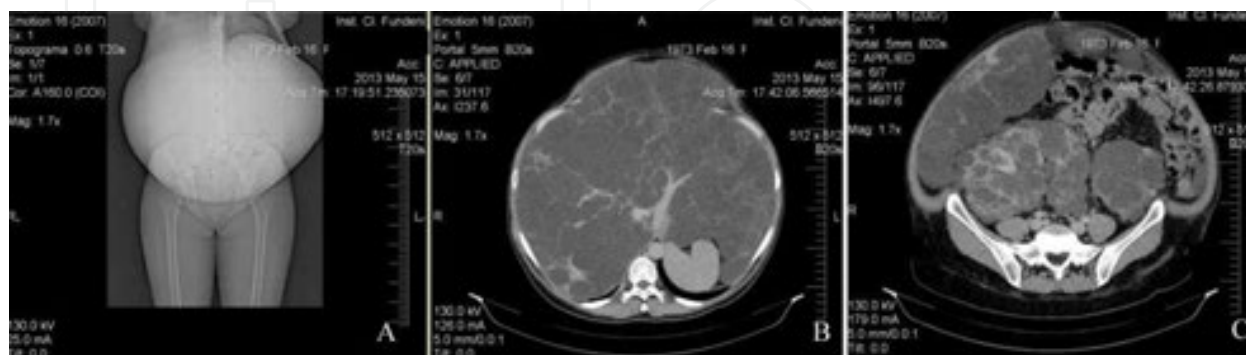


Figure 23. Female patient with PLD and ADPKD with indication for liver transplantation. (A) Body topography with huge abdomen volume. (B) CT, axial view: extensive hepatomegaly with multiple diffuse hepatic cysts entirely occupying the liver parenchyma. (C) CT, axial view: extensive hepatomegaly with the inferior border of the liver reaching the pelvis; multiple bilateral kidney cysts with both kidney displaced in the pelvis.

6. Outcomes

The most frequent complications encountered in the treatment of the simple hepatic cysts are hemorrhage and infection of the residual cavity. Recurrence of the hepatic cystic mass in the same location must be differentially interpreted based on the previous treatment, elapsed time from the treatment, histological type and size of the cyst, and existing symptoms.

In case of early recurrence of the hepatic cystic mass after percutaneous treatment, absence of malignancy criteria and symptoms, the treatment may vary from simple observation by US scan to surgical treatment, based on the patient's consent.

In case of early recurrence of hepatic cystic mass of similar size after percutaneous sclerotherapy or laparoscopic fenestration and malignancy criteria absence, the treatment may vary from percutaneous treatment to open surgery. An intracystic hematoma should be suspected as a cause of hepatic mass persistence especially when it is associated with inflammatory and/or internal hemorrhage symptoms. Percutaneous drainage is the first choice in the treatment of hematoma. In case of active bleeding and/or hemodynamic instability, emergency surgical intervention is indicated.

If the patient develops symptoms of infection associated with the persistence of hepatic cystic mass, hepatic abscess should be suspected as a complication and antibiotic treatment should be initiated empirically followed by further adjustments depending on bacterial cultures. If the symptoms persist and localization of the abscess permits, the percutaneous drainage is advisable. If the symptoms do not remit under antibiotics or the percutaneous drainage is not feasible, the patient must be referred to surgery.

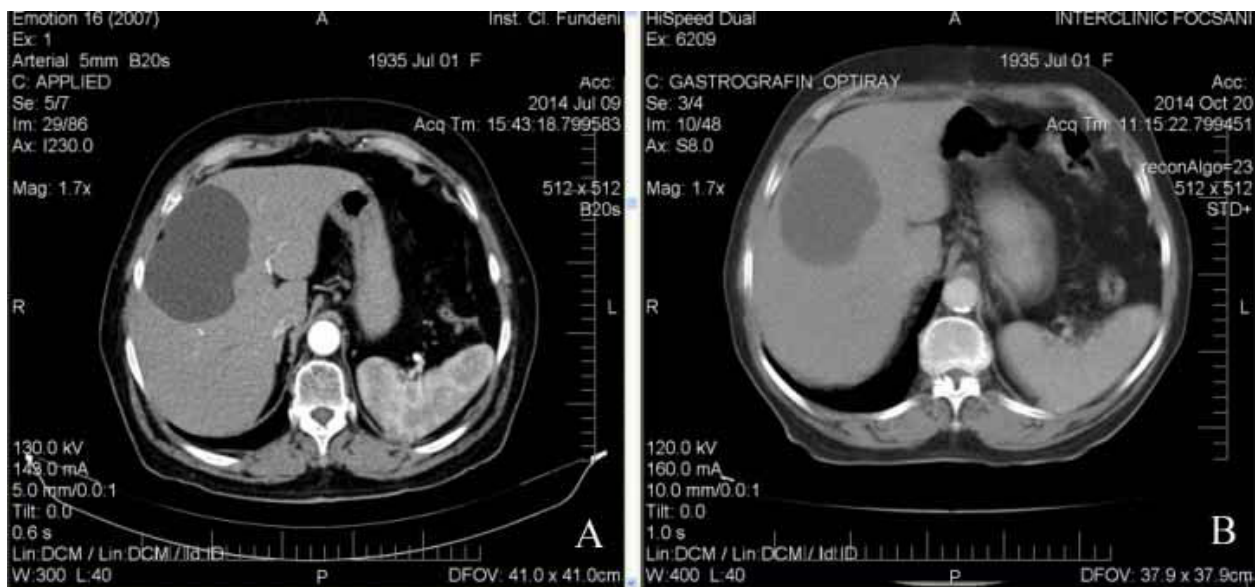


Figure 24. CT for central hepatic serous cyst (segments IV, V VII) (A) with recurrence after 3 months (B), having similar size and causing the same symptoms to the patient

In case of late recurrence after laparoscopic or classic fenestration for hepatic cyst, with documented US follow-up that initially attests the cyst remission, it should be reasonable to highly consider complete surgical removal of the recurrent cyst even if there are no serologic, imagistic, or histological criteria of malignancy (Figure 24).

The rate of symptomatic recurrence after percutaneous sclerotherapy is around 20%.

Laparoscopic unroofing or marsupialization can completely relieve symptoms from either simple lesions or PLD, with the procedure's morbidity, mortality, and recurrence rates being, respectively, 2%, 0%, and 2% for patients with simple cysts, and 25%, 0%, and 5% for patients with PLD. For infected cysts, the procedure of choice is percutaneous drainage, with morbidity, mortality, and recurrence rates for simple cysts being 0%, 0%, and 75%, respectively, and for PLD, 0%, 0%, and 20%, respectively [54]. The conversion rate from laparoscopy to laparotomy is less than 10% [66]. Postoperative morbidity in open deroofing of the hepatic cysts has been reported to be significantly higher than in laparoscopic procedure (33% versus 13%) but the difference may reflect the selection of more difficult cases for open surgery [66]. No mortality is acceptable for surgical therapy of hepatic cysts, unless liver transplantation is considered. Survival rate after OLT for PLD has been reported as high as 90% [67].

Abbreviations

AB—antibiotherapy

ADPKD—autosomal dominant polycystic kidney disease (ADPKD)

CA 19-9—carcinoma antigen 19-9

CBC—cell blood count

CEA—carcinoembryonic antigen

CEUS—contrast enhanced ultrasonography

CRP—C reactive protein

CT—computer tomography

ERCP—endoscopic retrograde cholangiopancreatography

MRCP—magnetic resonance cholangiopancreatography

MRI—magnetic resonance imaging

OLT—orthotopic liver transplantation

PLD—polycystic liver disease

US—ultrasonography

Acknowledgements

This study was supported by the Health, EEA-JRP-RO-NO-2013-1-0363 programme, through the project No. 4 SEE/30.06.2014, with the title "Hepatocellular carcinoma stratification based on noninvasive markers" and acronym HEPMARK.

Author details

Mirela Patricia Sîrbu Boeți^{1,2*}, Mirela Boroș³, Vlad Herlea^{4,5}, Amalia Petrișor² and Irinel Popescu^{1,2}

*Address all correspondence to: paboet@yahoo.com

1 Department of Liver Transplantation and General Surgery, Fundeni Clinical Institute, Bucharest, Romania

2 Carol Davila University of Medicine and Pharmacy, Bucharest, Romania

3 Department of Radiology, Medical Imaging and Interventional Radiology, Fundeni Clinical Institute, Bucharest, Romania

4 Department of Pathology, Fundeni Clinical Institute, Bucharest, Romania

5 Titu Maiorescu University, Faculty of Medicine, Bucharest, Romania

References

- [1] Carrim ZI, Murchison JT. The prevalence of simple renal and hepatic cysts detected by spiral computed tomography. *Clin Radiol.* 2003; 58: 626–9.
- [2] Macedo FI. Current management of noninfectious hepatic cystic lesions: a review of the literature. *World J Hepatol.* 2013; 5: 462–9.
- [3] Cnossen WR, Drenth JP. Polycystic liver disease: an overview of pathogenesis, clinical manifestations and management. *Orphanet J Rare Dis.* 2014; 1: 69.
- [4] Russel RT, Pinson CW. Surgical management of polycystic liver disease. *World J Gastroenterol.* 2007; 13: 5052–9.
- [5] Ramia JM, de La PR, Figueras J, Garcia-Parreno J. [Benign non-parasitic hepatic cystic tumours]. *Cir Esp.* 2011; 89: 565–73.

- [6] Zhang YL, Yuan L, Shen F, Wang Y. Hemorrhagic hepatic cysts mimicking biliary cystadenoma. *World J Gastroenterol*. 2009; 15: 4601–3.
- [7] Bakoyiannis A, Delis S, Triantopoulou C, Dervenis C. Rare cystic liver lesions: a diagnostic and managing challenge. *World J Gastroenterol*. 2013; 19: 7603–19.
- [8] Miller JH. The ultrasonographic appearance of cystic hepatoblastoma. *Radiology*. 1981; 138: 141–3.
- [9] Rogers TN, Woodley H, Ramsden W, Wyatt JI, Stringer MD. Solitary liver cysts in children: not always so simple. *J Pediatr Surg*. 2007; 42: 333–9.
- [10] Ohmoto K, Shimizu M, Iguchi Y, Yamamoto S, Murakami M, Tsunoda T. Solitary cystic dilatation of the intrahepatic bile duct. *J Clin Pathol*. 1997; 50: 617–8.
- [11] Aoki S, Okayama Y, Kitajima Y, et al. Intrahepatic biliary papilloma morphologically similar to biliary cystadenoma. *J Gastroenterol Hepatol*. 2005; 20: 321–4.
- [12] Tsepelaki A, Kirkilesis I, Katsiva V, Triantafyllidis JK, Vagianos C. Biliary cystadenoma of the liver: case report and systematic review of the literature. *Ann Gastroenterol*. 2009; 22: 278–83.
- [13] Dixon E, Sutherland FR, Burak K, McKinnon G, May G. Cystadenoma of the liver without mesenchymal stroma in a female following hormonal therapy for acne. *HPB (Oxford)* 2001; 3: 183–6.
- [14] Dixon E, Sutherland FR, Mitchell P, McKinnon G, Nayak V. Cystadenomas of the liver: a spectrum of disease. *Can J Surg*. 2001; 44: 371–6.
- [15] Vogt DP, Henderson JM, Chmielewski E. Cystadenoma and cystadenocarcinoma of the liver: a single center experience. *J Am Coll Surg*. 2005; 200: 727–33.
- [16] Khoddami M, Kazemi AM, Alvandimanesh A. Ciliated hepatic foregut cyst: two case reports in children and review of the literature. *Case Rep Med*. 2013; 2013: 372017.
- [17] Balzan S, Kianmanesh R, Farges O, et al. Right intrahepatic pseudocyst following acute pancreatitis: an unusual location after acute pancreatitis. *J Hepatobiliary Pancreat Surg*. 2005; 12: 135–7.
- [18] Hansman MF, Ryan JA, Jr., Holmes JH, et al. Management and long-term follow-up of hepatic cysts. *Am J Surg*. 2001; 181: 404–10.
- [19] Wu S, Li Y, Tian Y, Li M. Single-incision laparoscopic surgery versus standard laparoscopic surgery for unroofing of hepatic cysts. *JSLS*. 2014; 18: 246–51.
- [20] Murphy BJ, Casillas J, Ros PR, Morillo G, Albores-Saavedra J, Rolfes DB. The CT appearance of cystic masses of the liver. *Radiographics*. 1989; 9: 307–22.
- [21] Poggi G, Gatti C, Delmonte A, Teragni C, Bernardo G. Spontaneous rupture of non-parasitic hepatic cyst. *Int J Clin Pract*. 2006; 60: 99–103.

- [22] Takahashi G, Yoshida H, Mamada Y, Taniai N, Bando K, Tajiri T. Intracystic hemorrhage of a large simple hepatic cyst. *J Nippon Med Sch.* 2008; 75: 302–5.
- [23] Terada N, Shimizu T, Imai Y, *et al.* Benign, non-parasitic hepatic cyst causing obstructive jaundice. *Intern Med.* 1993; 32: 857–60.
- [24] Bistriz L, Tamboli C, Bigam D, Bain VG. Polycystic liver disease: experience at a teaching hospital. *Am J Gastroenterol.* 2005; 100: 2212–7.
- [25] Ker J. The liver and right atrium-hepatic cyst as a cause of arrhythmia. *Clin Med Insights Cardiol.* 2010; 4: 63–7.
- [26] Musielak MC, Singh R, Hartman E, Bernstein J. Simple hepatic cyst causing inferior vena cava thrombus. *Int J Surg Case Rep.* 2014; 5: 339–41.
- [27] Mori E, Akai Y, Matsumoto T, *et al.* Hepatic cyst infection in a healthy older male. *BMJ Case Rep.* 2012; 2012.
- [28] Kawashita Y, Kamohara Y, Furui J, *et al.* Destructive granuloma derived from a liver cyst: a case report. *World J Gastroenterol.* 2006; 12: 1798–801.
- [29] Cappellani A, Zanghi A, Di VM, Menzo EL, Conti P. Nonparasitic cysts of the liver: laparoscopic treatment and long-term results. *Ann Ital Chir.* 2002; 73: 85–8.
- [30] Akiyama T, Inamori M, Saito S, *et al.* Levovist ultrasonography imaging in intracystic hemorrhage of simple liver cyst. *World J Gastroenterol.* 2008; 14: 805–7.
- [31] Bleeker-Rovers CP, de Sevaux RG, van Hamersvelt HW, Corstens FH, Oyen WJ. Diagnosis of renal and hepatic cyst infections by 18-F-fluorodeoxyglucose positron emission tomography in autosomal dominant polycystic kidney disease. *Am J Kidney Dis.* 2003; 41: E18–21.
- [32] Beyrouiti MI, Beyrouiti R, Bouassida M, *et al.* [Hydatid cysts of the spigelian lobe (segment I) of the liver: clinical and therapeutic particularities]. *Presse Med.* 2007; 36: 1732–7.
- [33] Sparchez Z, Radu P, Zaharie F, Al HN, Sparchez M. Percutaneous treatment of symptomatic non-parasitic hepatic cysts. Initial experience with single-session sclerotherapy with polidocanol. *Med Ultrason.* 2014; 16: 222–8.
- [34] Moorthy K, Mihssin N, Houghton PW. The management of simple hepatic cysts: sclerotherapy or laparoscopic fenestration. *Ann R Coll Surg Engl.* 2001; 83: 409–14.
- [35] Benzmira J, Ronot M, Fuks D, *et al.* Hepatic cysts treated with percutaneous ethanol sclerotherapy: time to extend the indications to haemorrhagic cysts and polycystic liver disease. *Eur Radiol.* 2014; 24: 1030–8.
- [36] Blonski WC, Campbell MS, Faust T, Metz DC. Successful aspiration and ethanol sclerosis of a large, symptomatic, simple liver cyst: case presentation and review of the literature. *World J Gastroenterol.* 2006; 12: 2949–54.

- [37] Ohhira M, Yamada M, Murazumi Y, *et al.* [Intracystic infusion therapy of minocycline hydrochloride for benign hepatic cysts]. *Nihon Ronen Igakkai Zasshi*. 1995; 32: 33–8.
- [38] Lopes HM, Portela FA, Silva Pontes JM, Leitao MJ, Ribeiro JC, Freitas DS. Treatment of benign hepatic cysts by instillation of tetracycline hydrochloride. *Hepatogastroenterology*. 1998; 45: 496–9.
- [39] Jusufovic R, Zerem E. Percutaneous treatment of symptomatic non-parasitic benign liver cysts with 20% NaCl solution. *Med Arh*. 2011; 65: 35–7.
- [40] Spârchez Z, Radu P, Zaharie F, Al Hajjar N, Spârchez M. Percutaneous treatment of symptomatic non-parasitic hepatic cysts. Initial experience with single-session sclerotherapy with polidocanol. *Med Ultrason*. 2014; 16: 222–8.
- [41] Yamamoto K, Sakaguchi H, Anai H, *et al.* Sclerotherapy for simple cysts with use of ethanolamine oleate: preliminary experience. *Cardiovasc Intervent Radiol*. 2005; 28: 751–5.
- [42] Wijnands TF, Lantinga MA, Drenth JP. Hepatic cyst infection following aspiration sclerotherapy: a case series. *J Gastrointestin Liver Dis*. 2014; 23: 441–4.
- [43] Lantinga MA, Geudens A, Gevers TJ, Drenth JP. Systematic review: the management of hepatic cyst infection. *Aliment Pharmacol Ther*. 2014.
- [44] Du XL, Ma QJ, Wu T, Lu JG, Bao GQ, Chu YK. Treatment of hepatic cysts by B-ultrasound-guided radiofrequency ablation. *Hepatobiliary Pancreat Dis Int*. 2007; 6: 330–2.
- [45] Z'graggen K, Metzger A, Klaiber C. Symptomatic simple cysts of the liver: treatment by laparoscopic surgery. *Surg Endosc*. 1991; 5: 224–5.
- [46] Lee DH, Cho JY, Han HS, *et al.* Laparoscopic treatment of hepatic cysts located in the posterosuperior segments of the liver. *Ann Surg Treat Res*. 2014; 86: 232–6.
- [47] Amendolara M, Bucca D, Barbarino C, *et al.* Surgical management of symptomatic simple hepatic cysts. *G Chir*. 2012; 33: 17–20.
- [48] Kjeld T, Hansen EG, Holler NG, Rottensten H, Hyldegaard O, Jansen EC. Resuscitation by hyperbaric exposure from a venous gas emboli following laparoscopic surgery. *Scand J Trauma Resusc Emerg Med*. 2012; 20: 51.
- [49] Cui W, Zhou HY, Zhang YH, Zhang T, Li Q. Surgical management of non-parasitic hepatic cyst with biliary communication: a case report. *Cancer Biol Med*. 2013; 10: 110–3.
- [50] Masatsugu T, Shimizu S, Noshiro H, *et al.* Liver cyst with biliary communication successfully treated with laparoscopic deroofing: a case report. *JLS*. 2003; 7: 249–52.
- [51] Kaneya Y, Yoshida H, Matsutani T, *et al.* Biliary obstruction due to a huge simple hepatic cyst treated with laparoscopic resection. *J Nippon Med Sch*. 2011; 78: 105–9.

- [52] Castro-Perez R, Dopico-Reyes E, Acosta-Gonzalez LR. Minilaparoscopic-assisted transvaginal approach in benign liver lesions. *Rev Esp Enferm Dig.* 2010; 102: 357–64.
- [53] Berelavichus SV, Kriger AG, Starkov I, Shishin KV, Gorin DS, Poliakov IS. [Robotic-assisted and laparoscopic hepatic resections for nonparasitic cysts of posterior liver segments]. *Khirurgiia (Mosk)* 2013; 14–9.
- [54] Mazza OM, Fernandez DL, Pekolj J, *et al.* Management of nonparasitic hepatic cysts. *J Am Coll Surg.* 2009; 209: 733–9.
- [55] Koffron A, Rao S, Ferrario M, Abecassis M. Intrahepatic biliary cystadenoma: role of cyst fluid analysis and surgical management in the laparoscopic era. *Surgery.* 2004; 136: 926–36.
- [56] Ishii K, Yoshida H, Tani ai N, Moneta S, Kawano Y, Tajiri T. Infected hepatic cyst treated with percutaneous transhepatic drainage. *J Nippon Med Sch.* 2009; 76: 160–4.
- [57] Ueda J, Yoshida H, Tani ai N, Mineta S, Kawano Y, Uchida E. A case of spontaneous rupture of a simple hepatic cyst. *J Nippon Med Sch.* 2010; 77: 181–5.
- [58] Gevers TJ, Chrispijn M, Wetzels JF, Drenth JP. Rationale and design of the RESOLVE trial: lanreotide as a volume reducing treatment for polycystic livers in patients with autosomal dominant polycystic kidney disease. *BMC Nephrol.* 2012; 13: 17.
- [59] Temmerman F, Gevers T, Ho TA, *et al.* Safety and efficacy of different lanreotide doses in the treatment of polycystic liver disease: pooled analysis of individual patient data. *Aliment Pharmacol Ther.* 2013; 38: 397–406.
- [60] Jeyarajah DR, Gonwa TA, Testa G, *et al.* Liver and kidney transplantation for polycystic disease. *Transplantation.* 1998; 66: 529–32.
- [61] Benedetti E, Pirenne J, Troppmann C, *et al.* Combined liver and kidney transplantation. *Transpl Int.* 1996; 9: 486–91.
- [62] Pirenne J, Aerts R, Yoong K, *et al.* Liver transplantation for polycystic liver disease. *Liver Transpl.* 2001; 7: 238–45.
- [63] Smira G, Matei E, Gheorghe L, Popescu I. The MELD score exception for polycystic liver disease. *Chirurgia (Bucur.)* 2013; 108: 418–21.
- [64] Kornasiewicz O, Dudek K, Bugajski M, Najnigier B, Krawczyk M. Choice of transplantation techniques and indications for liver transplantation in polycystic liver disease in patients with no signs of end-stage liver disease. *Transplant Proc.* 2008; 40: 1536–8.
- [65] Takei R, Ubara Y, Hoshino J, *et al.* Intravascular embolization therapy in patients with enlarged polycystic liver. *Am J Kidney Dis.* 2014; 63: 937–44.
- [66] Scheuerlein H, Rauchfuss F, Franke J, *et al.* Clinical symptoms and sonographic follow-up after surgical treatment of nonparasitic liver cysts. *BMC Surgery.* 2013; 13:42-49
- [67] Swenson K, Seu P, Kinkhabwala M, *et al.* Liver transplantation for adult polycystic liver disease. *Hepatology.* 1998; 28: 412–5.