

We are IntechOpen, the world's leading publisher of Open Access books Built by scientists, for scientists

4,800

Open access books available

122,000

International authors and editors

135M

Downloads

Our authors are among the

154

Countries delivered to

TOP 1%

most cited scientists

12.2%

Contributors from top 500 universities



WEB OF SCIENCE™

Selection of our books indexed in the Book Citation Index
in Web of Science™ Core Collection (BKCI)

Interested in publishing with us?
Contact book.department@intechopen.com

Numbers displayed above are based on latest data collected.
For more information visit www.intechopen.com



Cervical Disc Arthroplasty – A Clinical Review

Christopher Paul O’Boynick and Bruce V. Darden II

Additional information is available at the end of the chapter

<http://dx.doi.org/10.5772/61128>

Abstract

Anterior cervical discectomy and fusion (ACDF) has long been considered the gold standard for treating myelopathy and radiculopathy due to disk degeneration. One major complication of this procedure is adjacent segment degeneration. Cervical disc arthroplasty (CDA) has been proposed as an alternative to ACDF and as a means to reduce ASD. This chapter briefly recounts the advent of CDA. Additionally, it describes the most common implants and biomechanical properties associated with those designs. Critical to CDA is meticulous operative technique including implant positioning and hemostasis. Data in the form of FDA IDE studies and more recent meta-analyses of existing studies have demonstrated non-inferiority of CDA when compared to ACDF. This chapter also reviews the most common complications associated with CDA including heterotopic ossification and ankylosis of the involved segment. While more technically demanding than ACDF, CDA does represent a viable alternative in the proper patient.

Keywords: Cervical disc, disc arthroplasty, spine surgery

1. Introduction

Anterior cervical discectomy and fusion (ACDF) has long been considered the gold standard for treating myelopathy and radiculopathy due to disk degeneration [1]. Secondary to this success it has become the archetype by which all subsequent techniques are judged. The clinical success of ACDF is evident across the literature, reaching as far back as the middle of the last century [1-4].

As with any surgical intervention, ACDF is not without its complications. The most notable of these complications is adjacent segment degeneration (ASD). Described as the radiographic appearance of degenerative changes above or below a fused segment, this anomaly has a reported incidence of up to 92% in some studies [5]. Instrumental in its management is understanding the difference between adjacent segment degeneration and adjacent segment disease. The latter being degeneration severe enough to cause clinical symptoms and/or require surgical intervention [6]. Keeping this distinction in mind, Hilibrand et al. [6] described a 3% chance of symptomatic ASD per year following ACDF. In the symptomatic group approximately two thirds required a repeat surgery. Taking the group as a whole, 25% demonstrated new symptoms within 10 years of the index procedure. Goffin et al. [7] demonstrated similar rates of ASD between older patients treated for degeneration and younger patients treated in the traumatic setting. Combining this data with the biomechanical studies demonstrating increased motion and intradiscal pressures at juxtafusal levels, it stands to reason that altered biomechanics following ACDF may play a role in ASD.

Complications related to graft materials have also come under scrutiny. In addition to increased operative time, iliac crest harvest has been linked to numerous complications including donor site pain, infection, nerve injury, and pelvic fracture [8, 9]. While allograft options do eliminate the risks listed above it does carry the risk of disease transmission [10].

Nonunion is also a risk associated with ACDF. Rates of 3%-11% have been reported in the literature for single-level fusions with rates increasing to over 25% in multi-level cases [1, 11].

It is with these complications in mind, that alternatives to fusion have come to the forefront in treating cervical degenerative disease.

Cervical disk arthroplasty (CDA) has come of age over the last two decades. From its crude beginnings in the 1950's, through its re-emergence in the late 80's and 90's, CDA has evolved to include multiple devices and bearing options. The following chapter will work to describe the most clinically relevant implants, outline the current state of the art, and highlight the results of landmark studies for this emerging procedure.

2. Implants

The implants described in the following section were chosen based on relevant data that will be described in the clinical outcomes section. It is not meant to be a representation of all available devices.

2.1. The Porous-Coated Motion Cervical arthroplasty (PCM) (Figure 1)

The PCM made by Nuvasive (San Diego, California) consists of a cobalt-chrome-molybdenum (CrCoMo) alloy with an ultra-high molecular weight polyethylene (UHMWPE) insert. The concave surface of the superior endplate articulates with the convex superior surface of the polyethylene over a large radius of curvature. The endplates have a coating of titanium/calcium phosphate in addition to serrated edges to promote ingrowth. The disk is designed to

match the natural contour of the uncovertebral joint. This design allows for minimal limitations of range of motion and minimal constraint.



Figure 1. PCM (Courtesy of Nuvasive, San Diego, California)

2.2. ProDisc-C (Figure 2)

ProDisc-C made by Synthes (West Chester, Pennsylvania) has a ball and socket design, with endplates made of a cobalt-chrome alloy. Initial fixation comes from keels on each endplate combined with titanium plasma spray to promote bony in-growth. The bearing surface has an articulating dome of UHMWPE secured to the inferior endplate and a concave socket integral to the superior endplate. The implant allows for motion only in a specific range.



Figure 2. ProDisc-C (Courtesy of Synthes Spine, West Chester, Pennsylvania)

2.3. Bryan cervical disc prosthesis (Figure 3)

Bryan Cervical Disc Prosthesis made by Medtronic Sofamor Danek (Memphis, Tennessee) consists of a nucleus made of polyurethane between two titanium alloy endplates in a clamshell configuration. The two bearing surfaces in the arthroplasty at the interfaces between the nucleus and the endplates are contained by a polyurethane sheath that attaches to the endplates. Sterile saline is injected between the outer sheath and the nucleus as lubricant as part of the implantation. Ideally, this sheath contains any wear debris and prevents soft tissue in-growth. The endplates have a titanium porous coating and a flange to prevent migration. This implant is unconstrained.



Figure 3. Bryan Cervical Disc (Courtesy of Medtronic Sofamor Danek, Memphis, Tennessee)

2.4. Prestige (Figure 4)

The current prestige disc replacement has a long history. Its initial design was taken from the technology developed by Cummins et al. and acquired by Medtronic Sofamor Danek (Memphis, Tennessee). Over many derivations the implant has morphed from a stainless steel ball and socket articulation into a cobalt chrome alloy with a ball and groove design. This allows for coupled motion. The implant uses locking screws as well as grit blasted implant surfaces for fixation. In its most recent design change the Prestige LP moved to titanium ceramic composition and traded the flange and locking screw construct for a titanium plasma spray with rails for immediate fixation.

2.5. Mobi-C (Figure 5)

The Mobi-C LDR spine (Austin, Texas) is a metal on the UHMWPE device. It has mobile bearing technology allowing both the superior and inferior endplates to articulate with the polyethylene for an increased range of motion. The articulation between the insert and the inferior endplate is limited by two lateral stops on the inferior endplate. The endplates, made




Figure 4. Evolution of the Prestige Cervical Disc (Courtesy of Medtronic Sofamor Danek, Memphis, Tennessee)

of cobalt chromium alloy, are coated with plasma sprayed titanium and a hydroxyapatite coating to promote ingrowth.



Figure 5. Mobi-C (Courtesy of LDR, Austin, Texas)

3. Biomechanics

Critical to understanding the biomechanics of cervical disc replacement is a knowledge of normal cervical spine kinematics. Normal motion in the subaxial cervical spine requires

coupled motions at the disc space. There is anterior-posterior translation during flexion and extension as well as lateral translation during bending and axial rotation. Secondary to this complex motion is the concept of varying constraint through normal cervical spine range of motion. During flexion the facet joints unshingle and provide less constraint across the involved disc. During extension the opposite occurs and the motion segment becomes more constrained. Understanding the varying amounts of constraint in the native disc is vital when considering the concept of constraint within an implant. Huang et al. [12] defines constraint in the cervical spine as a limitation of anterior-posterior translation typically found during normal flexion and extension activity. An unconstrained or semi-constrained device theoretically allows for more natural motion across a given segment. On the other hand, a constrained implant dictates all motion at that segment and could result in decreased motion and more stress across the segments as the implant and facet joints work against each other. Additionally, the complex nature of each motion segment results in varying centers of rotation. Building on the work of Penning and Amevo [13, 14], the normalized instantaneous centers of rotation were identified and can be seen in Figure 6 [15]. These centers of rotation become increasingly important with respect to implant positioning particularly for devices with a more constrained design. Failure to position the implant appropriately could result in increasing strain on the facets. Figure 7 demonstrates ideal placement on the lateral view with slightly asymmetric insertion on the AP. Ideal placement can be seen in figures 13 and 14.

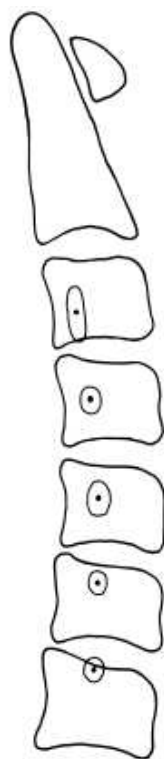

Figure 6. Mean instantaneous axes of rotation for each level of the cervical spine. Circles represent a two standard deviation range of distribution. Knowledge of their location is instrumental for proper placement of CSA implants. (Image reprinted from Bogduk N, Mercer S. Clin Biomechanics, 2000 [15])

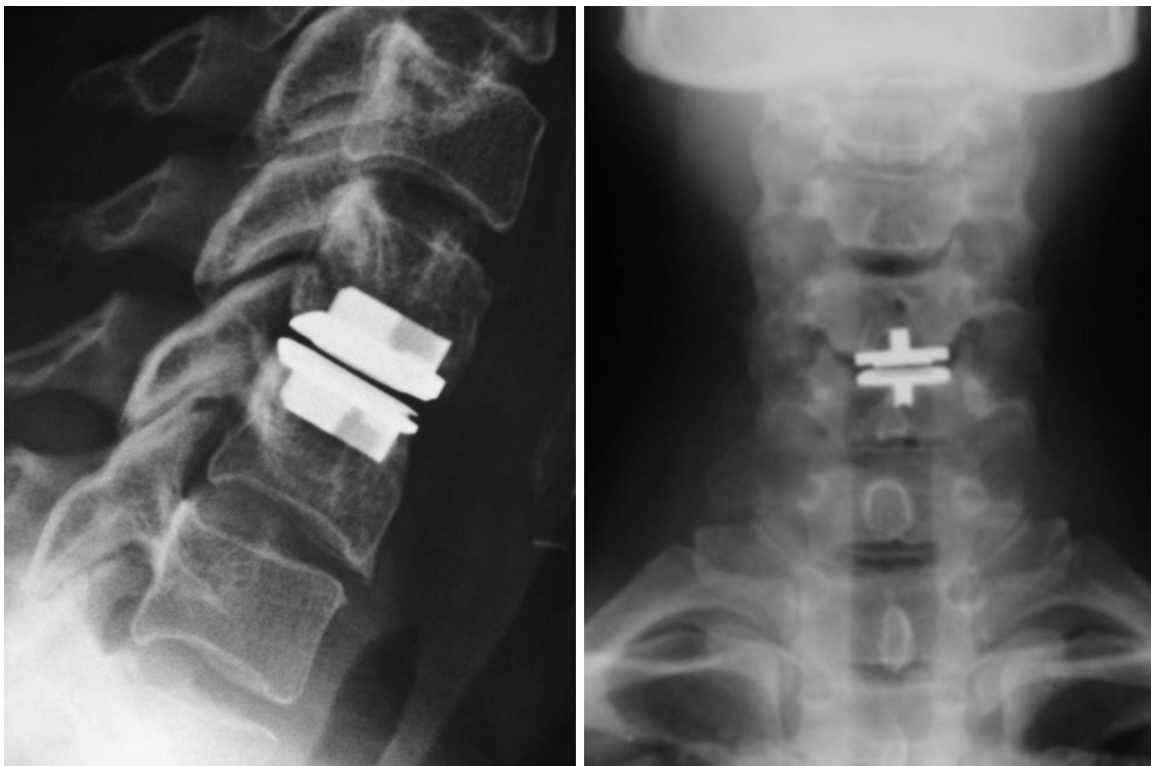


Figure 7. AP and lateral radiographs of a ProDisc-C

4. Surgical technique

- **Patient positioning:** Proper positioning is key to proper orientation and alignment of the prosthesis. Obtaining anatomic lordosis is critical prior to procedure commencement. This can be achieved with a rolled towel or similar placed behind the neck. Additionally, AP and lateral fluoroscopic imaging is necessary to ensure proper placement of the implant. The head should be secured to prevent rotation. The shoulders may be taped with caudal retraction as necessary for visualization. Figures 8 and 9 demonstrate proper positioning.
- **Approach and discectomy:** A standard Smith-Robinson approach may be utilized and the index level exposed. The center of the vertebral body must be identified for proper implant placement (Figure 10). Aggressive hemostasis will help to prevent blood loss and reduce risk of heterotopic ossification. Additionally, the surgeon must obtain parallel distraction of the disc space (Figure 11), release the foramen bilaterally, and re-establish normal disc height prior to implant placement.
- **Device insertion:** Implant placement and fixation should be done under fluoroscopic guidance utilizing implant specific devices as outlined in each respective technique guide (Figure 12). The surgical site should be thoroughly irrigated and closed in a standard fashion.

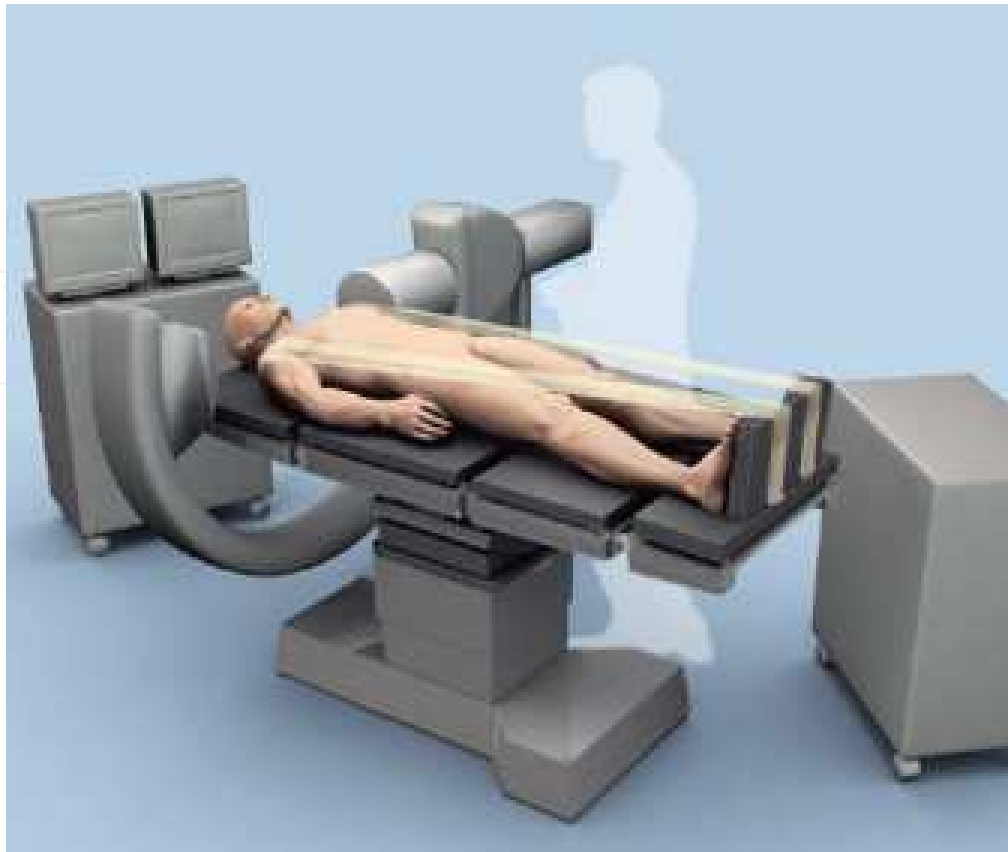


Figure 8. Illustrations of proper positioning for cervical disc replacement (Courtesy of Synthes Spine, West Chester, Pennsylvania)

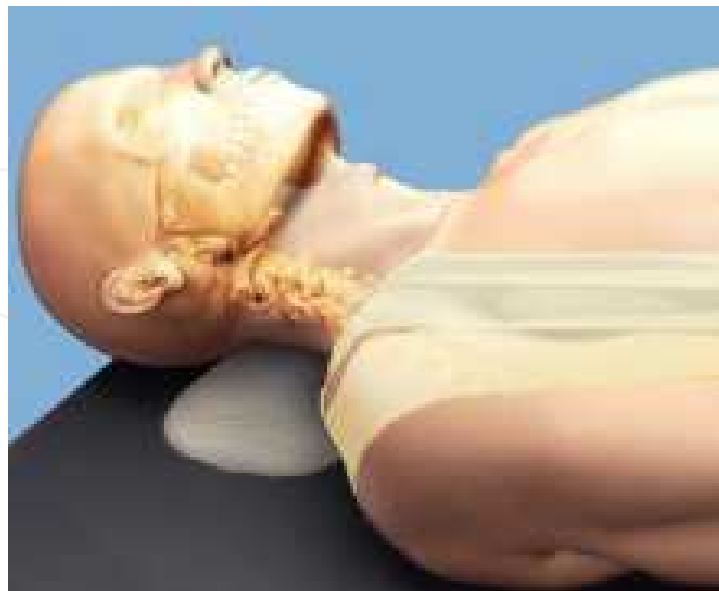

Figure 9. Illustrations of proper positioning for cervical disc replacement (Courtesy of Synthes Spine, West Chester, Pennsylvania)

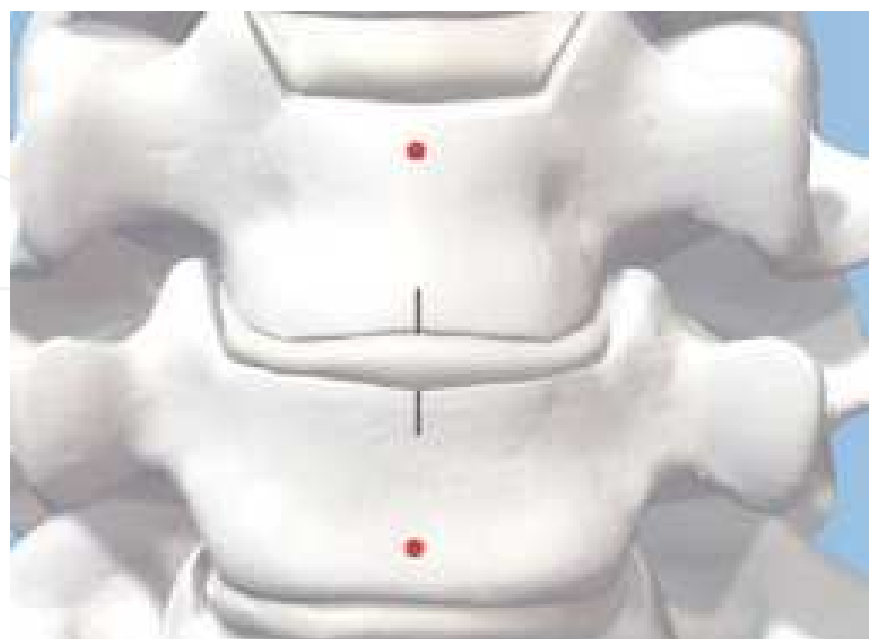


Figure 10. Illustrations of midline identification of the vertebral body and parallel distraction of the disc space for optimal implant placement (Courtesy of Synthes Spine, West Chester, Pennsylvania)

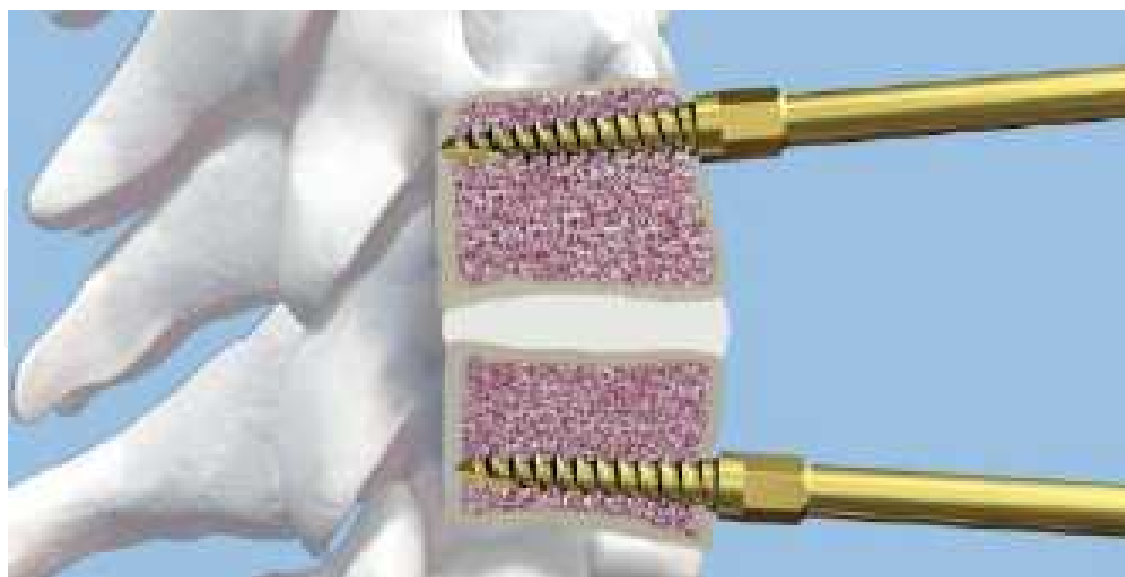

Figure 11. Illustrations of midline identification of the vertebral body and parallel distraction of the disc space for optimal implant placement (Courtesy of Synthes Spine, West Chester, Pennsylvania)

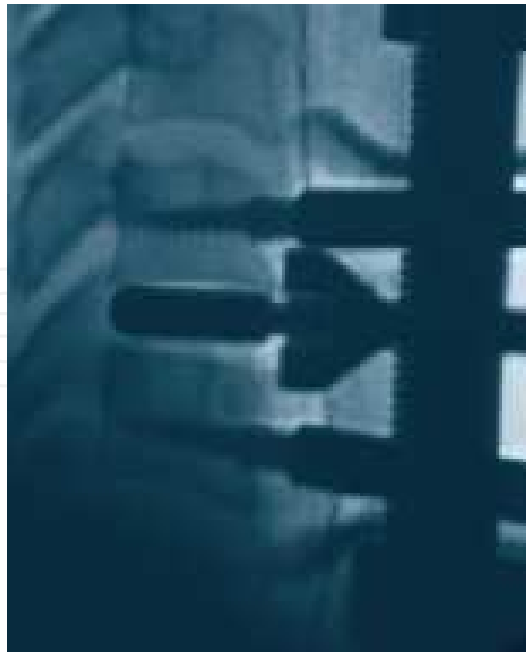

Figure 12. Lateral fluoroscopic view demonstrating optimal trial placement along the posterior margin of the vertebral bodies. Note the parallel distraction of the endplates and placement of the distraction pins. (Courtesy of Synthes Spine, West Chester, Pennsylvania)

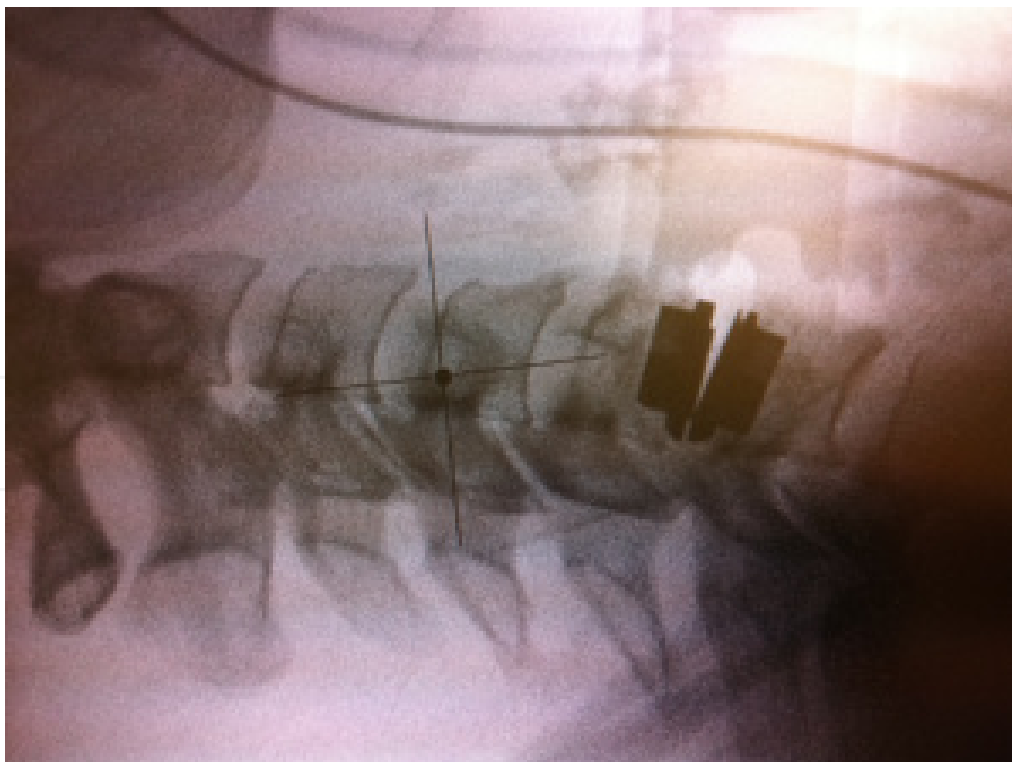


Figure 13. Intra-operative views showing optimal placement of cervical disc arthroplasty in the AP and lateral views (Courtesy of Synthes Spine, West Chester, Pennsylvania)

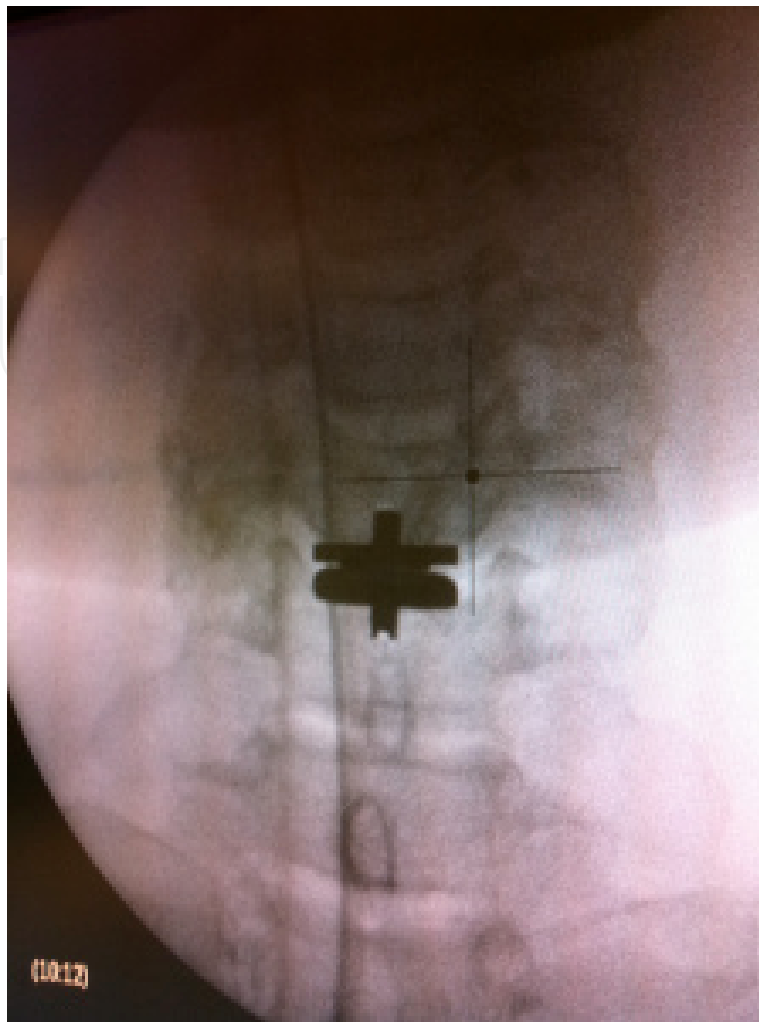


Figure 14. Intra-operative views showing optimal placement of cervical disc arthroplasty in the AP and lateral views (Courtesy of Synthes Spine, West Chester, Pennsylvania)

5. Clinical outcomes

Most of the data available surrounding CDA, at least in the US, is the result of numerous clinical evaluations as part of the US FDA IDE studies. This data from these individual studies has been summarized previously by many authors and will be touched on later in this section. Some of the most recent data comes in the form of meta-analyses of these existing studies as well as retrospective review of large clinical databases.

McAfee et al. [16] performed a meta-analysis of four FDA IDE studies examining four separate CDA devices. At 24 months, over 1200 patients were available across all studies for evaluation. Pooling all this data, a significant treatment effect favoring arthroplasty was demonstrated with an overall success rate of 78% for CDA compared to 71% for ACDF. This significance was also borne out in the subcomponent analysis for neurological status and survivorship. Their overall conclusions suggest superiority of CDA compared to ACDF.

Gao et al. [17] reviewed 27 randomized clinical trials. Twelve of these demonstrated level 1 evidence with the remaining studies identified as level 2. The arthroplasty group had lower VAS neck and arm pain scores, better neurological success, and fewer secondary procedures. The remaining variables including duration of hospital stay, NDI, and rates of adverse events demonstrated no significant difference across the groups.

Davis et al. [18] reported a four year follow up on 2-level disc replacement versus ACDF. This study is part of the US FDA IDE study evaluating the Mobi-C device. Of the 225 patients receiving CDA, 202 were available for follow up along with 89 of the original 105 patients receiving ACDF. ASD was found in 86% of ACDF cases compared with 42% of CDA cases. Rates of subsequent surgeries were also elevated in the ACDF group at 15% compared to 4% with CDA. From the baseline, CDA patients improved more in NDI, SF-12, patient satisfaction, and overall success when compared to ACDF. Another study, again looking at the Mobi-C device in single-level constructs over the course of four years identified significantly higher rates of subsequent surgery and adjacent segment disease in the ACDF group when compared to CDA [19]. At no point during this study were CDA scores significantly worse than ACDF scores with respect to NDI, VAS, or SF-12.

Heller et al. [20] published two-year results on the Bryan FDA IDE study. They had over 200 in each group available at follow up. At two years, the Bryan patients had improved NDI scores, VAS scores, and higher overall success when compared to ACDF. The longest follow-up study of the Bryan disc comes from the work of Goffin and his colleagues out of Europe [21]. This was a multicenter, prospective, non-randomized study, which included both multi-level and single-level constructs. At their 4-6-year follow up, there were 89 single-level patients and nine two-level patients available for examination. All patients remained clinically improved compared to preoperatively. Nearly 90% had good or excellent results based on Odum's criteria. Kaplan-Meier analysis showed and estimated success rate over 90% at the seven-year mark.

The Prestige disc (ST or LP) does not have the long-term data yet to match the longer but non-randomized study of the Bryan disc. Mummaneni et al. [22] presented the results of the Prestige ST at two years. Again, this data was from a prospective, randomized, multicenter trial between ACDF and CDA. With better than 75% follow up, the rate of adjacent level surgery was statistically greater for the ACDF patients versus the CDA group. This trend continued with respect to neurological success favoring CDA in 93% of patients compared to 84% of ACDF patients. Overall success including improved NDI, maintained neurological improvement, and the absence of implant related adverse events again favored CDA 79% vs. ACDF 68%. SF-36, VAS, and NDI showed no differences at the two-year time point. A two-year prospective trial out of Japan showed no difference between ACDF and CDA with the Prestige LP when evaluating VAS, NDI, SF-36, or Japanese Orthopedic Association scores [23].

Data on the ProDisc-C IDE study comes from Murrey et al. [24]. Similar to previous studies the 1:1 randomized, controlled, multicenter trial had over 100 patients available in each arm at two-year follow up. Each group had improvement in the clinical parameters measured but no significant difference was elucidated between groups. Rates of revision surgery, however, did favor the CDA group (2%) compared to ACDF (8.5%). Delamarter in 2010, re-examined

the ProDisc-C IDE data in addition to 136 patients that received CDA in the continued access arm of the study [25]. Again, clinical parameters improved significantly from baseline in both groups. Mirroring the work of Murrey et al., the rates of secondary surgical procedures were higher in those patients receiving ACDF (11%) vs. CDA (3%). Half of these ACDF patients required adjacent segment surgery while the other half required revision ACDF for pseudarthrosis at the index level. While three CDA patients required conversion to fusion for axial pain, none required surgical intervention at adjacent segments.

Phillips et al. [26] most recently published on the two-year results of the PCM US FDA IDE clinical trial. At two years the follow-up rate was nearly 90% (195) for the PCM group and 82% (151) for the ACDF group. Similar to data presented previously, all patients had significant improvement from baseline in clinical scores. The mean NDI was significantly lower in the CDA group compared to ACDF ($p=0.029$). Reported dysphagia scores were also lower in the CDA group. Overall success rates determined by combined NDI scores, lack of complications, no need for revision surgery, and radiographic evidence of motion (PCM) and fusion (ACDF) favored PCM (75%) over ACDF (65%) with a $p=0.02$. Overall findings from this study suggest at minimum an equivalency between ACDF and CDA with the PCM device.

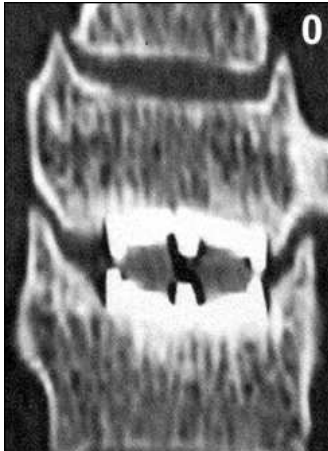

In 2008, Riew et al. examined the effectiveness of CDA in the setting of myelopathy due to single level disc herniation [27]. This study combined subset data from both the Bryan trial and the Prestige trials. Myelopathy was diagnosed based on hyperreflexia, presence of clonus, or a Nurick grade of greater than or equal to 1. Radiographic diagnosis was limited to single-level disc disease and patients with multi-level lesions were excluded. In comparing myelopathic patients that underwent CDA vs. ACDF, there was no significant difference between groups with respect to clinical improvement. This data suggests that CDA is a viable treatment option for patients with cervical myelopathy resulting from single level pathology.

6. Heterotopic ossification

Heterotopic ossification (HO) is frequently associated with CDA and has a reported prevalence approaching nearly 70% by some authors [28-34]. Similar to the previously described clinical results some of the most recent data comes from meta-analysis, which demonstrated an average prevalence of 45% at one year and 58% at two years [35]. HO is not unique to a single device. The rates associated with Bryan Disc, Mobi-C, and ProDisc-C are 21%, 53%, and 71% respectively [33]. Not surprisingly, the risk of HO formation increases with multi-level instrumentation from 41% to 75% in one reported study [36]. To date, no other causal relationship has been elucidated between HO rates and diagnosis, alcohol, tobacco, operative level, operative time, or pre-existing ossified lesions [29, 34]. Secondary to its increasing prevalence a classification scheme was proposed by McAfee et al. [37] adapted from systems previously used to describe hip and lumbar spine HO. This simple system attempts to quantify the amount of HO while qualifying the remaining motion at the involved segment [Table 1].

Briefly, grade 0 shows no HO, while grade IV represents complete ankylosis across the segment [37]. Incidentally, there is some evidence that post-operative NSAID use may reduce the rates

of HO formation. Review of the continued access arm of Delamarter et al. [25] in which NSAIDS were more frequently prescribed demonstrated no ankylosis at the treated level compared with five grade IV lesions in the initial IDE study at four years. Mehren et al. [28] showed a two-fold decrease in the rate of grade IV HO between two centers in their multicenter trial in which NSAIDS were routinely prescribed postoperatively at one site but not at the other. Currently, there is no published data suggesting a correlation between HO and a negative clinical outcome following CDA. Barbagallo et al. [38] found HO in over 40% of CDA patients but no difference in reported functional scoring between groups. Some segmental motion was preserved in 94% with some grade of HO. It should be noted that current follow-up data on HO is still short term and the long-term natural history as well as its implications for index level and adjacent level motion remains to be seen.

Class	Description
<p>0</p> 	<p>No HO present</p>
<p>I</p> 	<p>HO present but is not in the disc space and does not appear to interfere with motion</p>

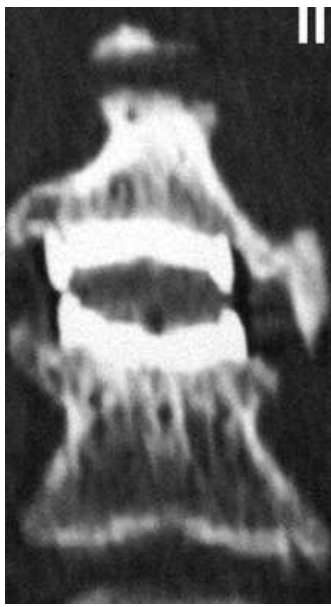
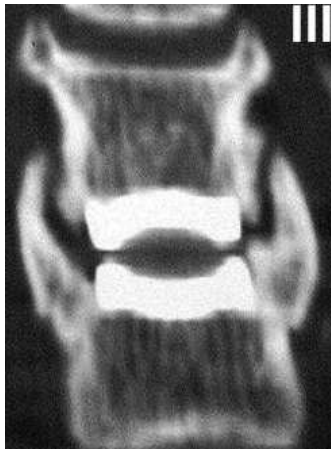
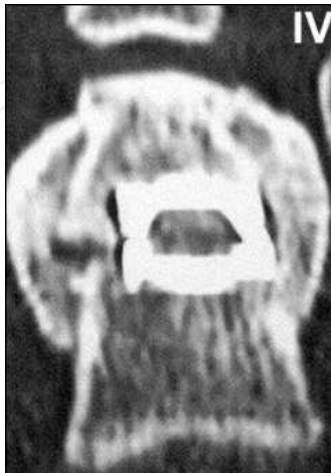
Class	Description
II	 <p>HO has violated the disc space and may be affecting the normal function of the prosthesis</p>
III	 <p>Bridging ossifications may limit function of the implant, but motion remains</p>
IV	 <p>Bridging HO resulting in complete fusion of the segment</p>

Table 1. Classification of HO Scale with computed tomography images (Adapted from [37])

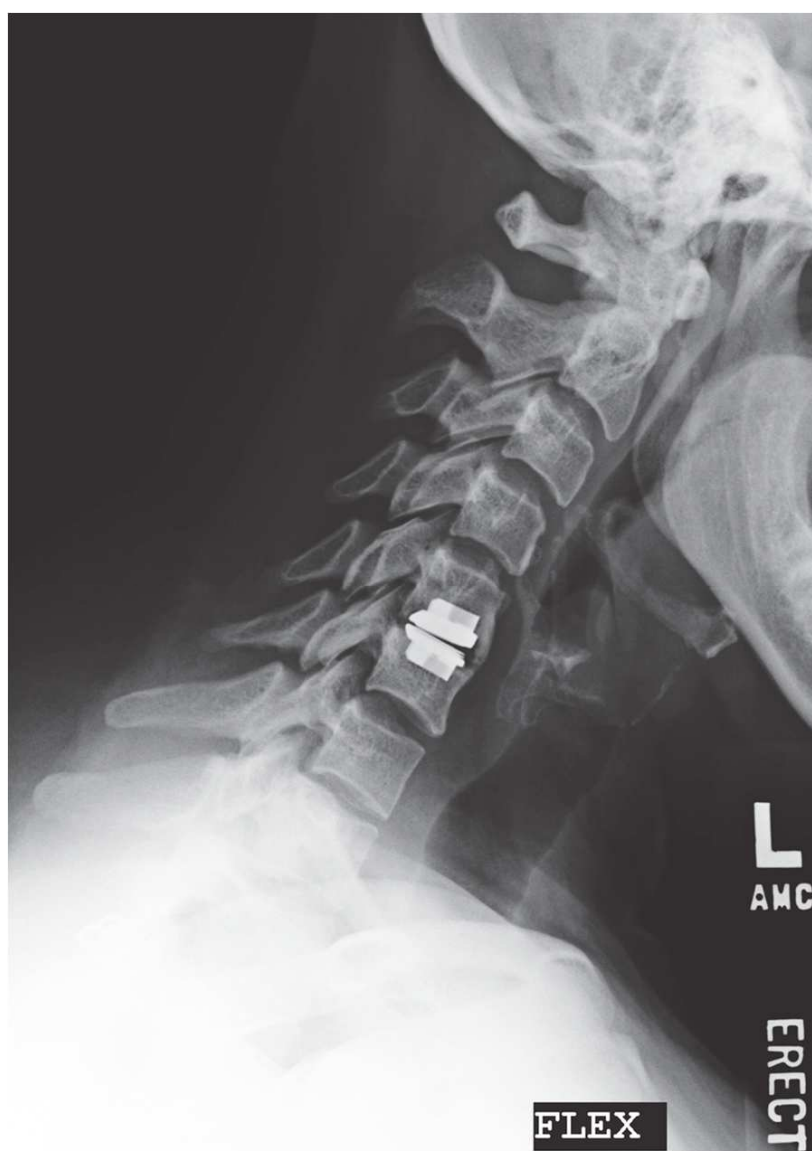

Figure 15. Lateral radiograph of ProDisc-C with HO formation and preserved motion

7. Complications, infection, and wear

To date, none of the large clinical series have reported catastrophic neurological complications. As described above, the rates of revision surgery at the index level have been on par or better when compared with ACDF in a non-inferiority study design. The authors are unaware of any published reports of CDA revision secondary to infection.

No chapter on arthroplasty would be complete without a discussion on wear and osteolysis. According to work done on the Bryan disc by Anderson et al., [39] the particles generated were larger than those associated with hip and knee arthroplasty and occurred in a much smaller volume. In a mouse model there was no evidence of local or systemic inflammatory response.

A brief search of the literature identified two case reports of local inflammatory response in the setting of CDA. The first [40] involved return of radicular symptoms following a metal-on-metal CDA. Repeat MRI revealed a posterior soft tissue mass encroaching on the spinal canal. Surgical exploration revealed hypertrophic cartilaginous material and chronic inflammatory debris. The patient was treated with explantation and conversion to ACDF. After revision surgery, the patient had complete resolution of symptoms. The second case reported by Tumialan and Gluf [41] recounts a 30-year-old male that developed axial neck pain nine months postoperatively. Repeat imaging studies revealed progressive osteolysis on the superior endplate. Infection workup was negative and revision to ACDF was completed without complication. Examination of the implant showed no abnormal wear characteristics and the authors hypothesized that the process was related to a local immune response.

Table 2 highlights the most common complications associated with CDA.

Approach	Infections, hollow viscera injury, vascular injury, dysphagia
Technique	Malposition, improper sizing, migration, end plate fracture, subsidence, heterotopic ossification (Figure 14), ankylosis (Figure 15)
Implant	Heterotopic ossification, implant failure, wear debris (inflammatory response)

Table 2. Complications of Cervical Spinal Arthroplasty

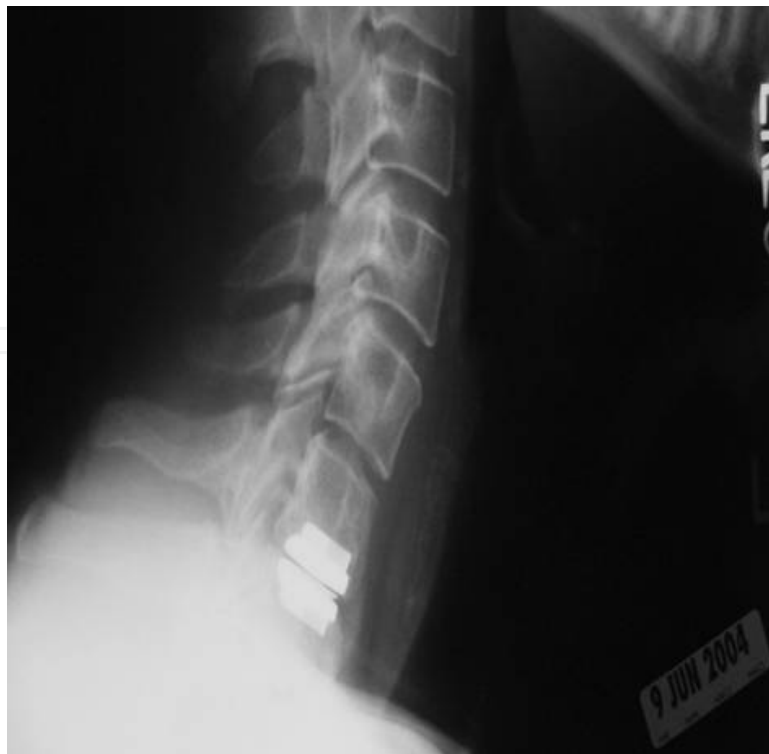

Figure 16. Ankylosis of a cervical disc arthroplasty

8. Conclusions

Cervical disc arthroplasty has evolved significantly since its introduction over 60 years ago. Multiple randomized, controlled, multicenter trials have been performed to assess its validity compared to the gold standard of ACDF. Unfortunately, despite the large trials the numbers are still small and the long-term follow up remains to be seen. Recent meta-analyses of existing data have attempted to extrapolate this data and do show promise for CDA but again only time will tell.

Author details

Christopher Paul O'Boynick* and Bruce V. Darden II

*Address all correspondence to: coboynic@gmail.com

OrthoCarolina Spine Center, Charlotte, USA

References

- [1] Bohlman HH, Emery SE, Goodfellow DB, et al. Robinson anterior cervical discectomy and arthrodesis for cervical radiculopathy: Long-term follow-up of one hundred and twenty-two patients. *J Bone Joint Surg Am* 1993;75 1298-1307.
- [2] Bailey R, Badgely C. Stabilization of the cervical spine by anterior fusion. *Journal of Bone and Joint Surgery Am* 1960;42(4) 565-594.
- [3] Robinson R, Smith G. Anterolateral cervical disc removal and interbody fusion for cervical disc syndrome. *Bull. John Hopkins Hospital* 1955;96 223-224.
- [4] Gore DR, Sepic SB. Anterior cervical fusion for degenerated or protruded discs: A review of one hundred forty-six patients. *Spine* 1984;(9) 667-71.
- [5] Goffin J, Geusens E, Vantomme N, et al. Long-term follow-up after interbody fusion of the cervical spine. *Journal of Spinal Disorders and Techniques* 2004;17(2) 79-85.
- [6] Hilibrand AS, Carlson GD, Palumbo MA, et al. Radiculopathy and myelopathy at segments adjacent to the site of a previous anterior cervical arthrodesis. *Journal of Bone and Joint Surgery Am* 1999;(81) 519-528.
- [7] Goffin J, Van Loon J, VanCalenbergh F, et al. Long-term results after anterior cervical fusion and osteosynthetic stabilization for fractures and/or dislocation of the cervical spine. *Journal of Spinal Disorders and Techniques* 1995;(8) 500-508.

- [8] Brown CA, Eismont FJ. Complications in spinal fusion. *Orthop Clin North Am* 1998;(29) 679-699.
- [9] Summers BN, Einstein SM. Donor site pain from the ilium: A complication of lumbar spine fusion. *J Bone Joint Surg Br* 1989;(71) 677-680.
- [10] Mroz TE, Joyce MJ, Lieberman IH, et al. The use of allograft bone in spine surgery: Is it safe? *Spine J* 2009;(9) 303-308.
- [11] Brodke DS, Zdeblick TA. Modified Smith-Robinson procedure for anterior cervical discectomy and fusion. *Spine* 1992;(17) S427-430.
- [12] Huang RC, Girardi FP, Cammisa FP et al. The implications of constraint in lumbar total disc replacement. *Journal of Spinal Disorders and Techniques* 2003;(16) 412-417.
- [13] Penning L. Normal movements of the cervical spine. *Am J Roentgenol* 1978;(130) 317-326.
- [14] Amevo B, Worth D, Bogduk N. Instantaneous axis of rotation of the typical cervical motion segments: A study in normal volunteers. *Clinical Biomechanics* 1991;(6) 111-117.
- [15] Bogduk N, Mercer S. Biomechanics of the cervical spine. I: Normal kinematics. *Clinical Biomechanics* 2000;(15) 633-648.
- [16] McAfee P, Reah C, Gilder K, et al. A meta-analysis of comparative outcomes following cervical arthroplasty or anterior cervical fusion. *Spine* 2012;(37) 943-952.
- [17] Gao Y, Ming L, Tao L, Fuguo H, et al. A meta-analysis comparing the results of cervical disc arthroplasty with anterior cervical discectomy and fusion (ACDF) for the treatment of symptomatic cervical disease. *J Bone Joint Surg Am* 2013;(95) 555-561.
- [18] Davis RJ, Nunley PD, Kim KD, et al. Two-level total disc replacement with Mobi-C cervical artificial disc versus anterior discectomy and fusion: A prospective, randomized, controlled multicenter clinical trial with 4-year follow results. *J Neurosurg Spine* 2015;(22) 15-25.
- [19] Hisey MS, Bae HW, Davis R, et al. Prospective, randomized comparison of cervical total disc replacement versus anterior cervical fusion: Results at 48 months follow-up. *J Spinal Disord Tech* 2014; Epub ahead of print.
- [20] Heller JG, Sasso RC, Papadopoulos SM, Anderson PA, Fessler RG et al. Comparison of Bryan Cervical Disc Arthroplasty with anterior cervical decompression and fusion. *Spine* 2009;(34) 101-107.
- [21] Goffin J, VanLoo J, VanCalenbergh F et al. A clinical analysis of 4-6 year follow-up results after cervical disc replacement using the Bryan Cervical Disc Prosthesis. *J Neurosurg Spine* 2010;(12) 261-9.

- [22] Mummaneni et al. Clinical and radiographic analysis of cervical disc arthroplasty compared with allograft fusion: A randomized controlled trial. *J Neurosurg Spine* 2007;(6) 198-209.
- [23] Peng CW, Yue WM, Abdul B et al. Intermediate results of the Prestige LP cervical disc replacement: Clinical and radiological analysis with minimum two-year follow-up. *Spine* 2011;(36) 105-111.
- [24] Murrey et al. Results of the prospective, randomized, controlled Food and Drug Administration Investigational Device Exemption Study of the ProDisc-C total disc replacement versus anterior discectomy and fusion for the treatment of one level symptomatic cervical disc disease. *Spine Journal* 2009;(9) 275-286.
- [25] Delamarter RB, Murrey D, Janssen MI et al. Results of 24 months from the prospective, randomized, multicenter investigation device exemption trial of ProDisc-C versus anterior cervical discectomy and fusion with 4-year follow-up and continued access patients. *SAS Journal* 2010;(4) 122-128.
- [26] Phillips FM, Lee JY, Geiser FH, et al. A prospective, randomized, controlled clinical investigation comparing PCM cervical disc arthroplasty with anterior cervical discectomy and fusion. 2-year results from the US FDA IDE clinical trial. *Spine* 2013;(38) E907-918.
- [27] Riew KD, Buchowski JM, Sasso R, Zdeblick T, Metcalf NH, Anderson PA. Cervical disc arthroplasty compared with arthrodesis for the treatment of myelopathy. *J Bone Joint Surg Am* 2008;(90) 2354-2364.
- [28] Mehren C, Suchomel P, Grochulla F, et al. Heterotopic ossification in total cervical artificial disc replacement. *Spine* 2006;31(24):2802-6.
- [29] Leung C, Casey AT, Goffin J, et al. Clinical significance of heterotopic ossification in cervical disc replacement: A prospective multicenter clinical trial. *Neurosurgery*. 2005;57(4):759-63; discussion 63.
- [30] Heidecke V, Burkert W, Brucke M, et al. Intervertebral disc replacement for cervical degenerative disease--clinical results and functional outcome at two years in patients implanted with the Bryan cervical disc prosthesis. *Acta neurochirurgica* 2008;150(5): 453-9; discussion 9.
- [31] Beaurain J, Bernard P, Dufour T, et al. Intermediate clinical and radiological results of cervical TDR (Mobi-C) with up to 2 years of follow-up. *European spine journal: Official publication of the European Spine Society, the European Spinal Deformity Society, and the European Section of the Cervical Spine Research Society*. 2009;18(6): 841-50.
- [32] Suchomel P, Jurak L, Benes V, 3rd, et al. Clinical results and development of heterotopic ossification in total cervical disc replacement during a 4-year follow-up. *European spine journal: Official publication of the European Spine Society, the European*

Spinal Deformity Society, and the European Section of the Cervical Spine Research Society 2010;19(2):307-15.

- [33] Yi S, Kim KN, Yang MS, et al. Difference in occurrence of heterotopic ossification according to prosthesis type in the cervical artificial disc replacement. *Spine* 2010;35(16):1556-61.
- [34] Lee JH, Jung TG, Kim HS, et al. Analysis of the incidence and clinical effect of the heterotopic ossification in a single-level cervical artificial disc replacement. *The spine journal: Official journal of the North American Spine Society* 2010;10(8):676-82.
- [35] Chen J, Wang X, Bai W, et al. Prevalence of heterotopic ossification after cervical total disc arthroplasty: a meta-analysis. *European spine journal: Official publication of the European Spine Society, the European Spinal Deformity Society, and the European Section of the Cervical Spine Research Society* 2012;21(4):674-80.
- [36] Wu JC, Huang WC, Tsai HW, et al. Differences between 1- and 2-level cervical arthroplasty: More heterotopic ossification in 2-level disc replacement: Clinical article. *Journal of neurosurgery Spine*. 2012;16(6):594-600.
- [37] McAfee PC, Cunningham BW, Devine J, et al. Classification of heterotopic ossification (HO) in artificial disk replacement. *Journal of spinal disorders & techniques* 2003;16(4):384-9.
- [38] Barbagallo GM, Corbino LA, Olindo G, et al. Heterotopic ossification in cervical disc arthroplasty: Is it clinically relevant? *Evidence-based spine-care journal* 2010;1(1): 15-20.
- [39] Anderson PA, Sasso RC, Rouleau JP, et al. The Bryan Cervical Disc: wear properties and early clinical results. *Spine Journal* 2004;(4) 5303-5309.
- [40] Cavanaugh DA, Nunley PD, Kerr EJ, et al. Delayed hyper-reactivity to metal ions after cervical disc arthroplasty: A case report and literature review. *Spine* 2009;34(7) E262-265.
- [41] Tumialan LM and Gluf, Wm. Progressive vertebral body osteolysis after cervical arthroplasty. *Spine* 2011;36(14) 973-8.

