

We are IntechOpen, the world's leading publisher of Open Access books Built by scientists, for scientists

4,800

Open access books available

122,000

International authors and editors

135M

Downloads

Our authors are among the

154

Countries delivered to

TOP 1%

most cited scientists

12.2%

Contributors from top 500 universities



WEB OF SCIENCE™

Selection of our books indexed in the Book Citation Index
in Web of Science™ Core Collection (BKCI)

Interested in publishing with us?
Contact book.department@intechopen.com

Numbers displayed above are based on latest data collected.
For more information visit www.intechopen.com



Endoscopic Treatment of Pancreatic Diseases

Borislav Vladimirov, Plamen Getzov and
Radina Ivanova

Additional information is available at the end of the chapter

<http://dx.doi.org/10.5772/60589>

Abstract

Endoscopic therapy has been increasingly recognized as an effective method of treatment in selected patients with pancreatic diseases. Various endoscopic procedures, classical and modified, are used for the complex treatment of acute and chronic pancreatitis, as well as their complications. In pancreatic carcinoma, some endoscopic methods are applied mainly as palliative measures. There are still open questions regarding the placing and timing of various endoscopic procedures in the multidisciplinary management approach of pancreatic diseases.

Keywords: endoscopy, EUS, acute pancreatitis, pancreatic cancer

1. Introduction

Acute pancreatitis (AP) is a disease with multiple etiologies and an increasing incidence, showing a wide spectrum of outcomes – from a mild, self-limited to severe, life-threatening illness [1]. According to the revised Atlanta classification of 2012, AP can be either edematous interstitial pancreatitis or necrotizing pancreatitis, involving necrosis of the peripancreatic tissues and/or pancreatic parenchyma [2]. In AP, there are 3 degrees of severity: mild, moderate, and severe – mild AP lacks both organ failure and local complications; moderately severe AP has transient organ failure (<2 days), local complications, and/or exacerbation of a coexistent disease; and severe AP is defined by the presence of persistent organ failure (≥ 2 days). Local complications are classified according to the presence of fluid or solid (necrosis) component as acute peripancreatic fluid collections, pseudocysts, acute (pancreatic/peri-

pancreatic) necrotic collection, and walled-off necrosis. Acute peripancreatic fluid collection is a true fluid collection that develops in the early phase of interstitial edematous AP, lacks a wall, and usually resolves without intervention. Pancreatic pseudocysts (PPC) are encapsulated collections of fluid with a well-defined inflammatory wall and with minimal or no necrosis, which usually occurs more than 4 weeks after onset of AP. Acute necrotic collections (ANCs) are present in the first 4 weeks of the necrotizing AP and contain variable amounts of solid (necrotic) and fluid material secondary to pancreatic and/or peripancreatic necrosis. Walled-off pancreatic necrosis (WOPN) represents the mature phase of an ANC, confined by a wall of reactive tissue which develops usually 4 or more weeks after the onset of necrotizing disease. Both ANCs or WOPN can be sterile or infected. Severe AP is estimated to occur in up to 20% of patients and is associated with high morbidity and mortality (approximately 15%) due to the development of sterile or infected necrosis, sepsis, and progressive multisystem organ failure [3, 4]. Development of infected necrosis is observed in 25%–70% of patients with necrotizing disease and usually requires an intervention to control the sepsis [5, 6]. Currently, endoscopic therapy, including various endoscopic procedures, is a part of multidisciplinary management of AP. It is indicated as a minimal invasive method of therapy in selected cases with acute biliary pancreatitis and local complications of AP. In addition, pancreatic endotherapy has been demonstrated to be effective in selected cases of idiopathic AP.

1.1. Endoscopic management in acute biliary pancreatitis

The most common cause of AP is gallstones. In most of the patients presenting with acute biliary pancreatitis the gallstones pass spontaneously to the duodenum but in minority of patients (about 20%) the persistent biliary obstruction can lead to cholangitis and severe AP [1]. The duration of bile duct obstruction is an important contributing factor for the severity of AP. It was reported that pancreatic necrosis develops more often when the biliary obstruction exceeds 48 h [7]. In the past, urgent surgery to decompress the bile duct soon after the diagnosis of pancreatitis was associated with increased mortality [8, 9]. Endoscopic retrograde cholangiopancreatography (ERCP) is a less invasive method to clear the bile duct and it could favorably affect the clinical outcome of AP if utilized properly [10, 11]. It is generally accepted that early ERCP and endoscopic sphincterotomy (ES) are indicated in cases with acute cholangitis and obstructive jaundice [12, 13]. In such patients, early ERCP and ES, preferably within 72 h from the onset of AP, ameliorate the symptoms and the progression of AP [14]. There is no clear consensus on the benefit from the endoscopic approach in patients with ERCP in patients with elevated liver function tests and obstructive jaundice with a septic-appearing picture and severe disease graded by an accepted scoring system. The role and timing of ERCP in patients with acute biliary pancreatitis have been evaluated in a number of clinical trials and meta-analysis (Figure 1) [12, 13, 15–23]. The authors of the first study found that patients with predicted severe biliary pancreatitis (using modified Glasgow criteria) had fewer complications if they underwent ERCP within 72 h (24% vs 61%) compared to the control group on conservative management [15]. After excluding the patients with concomitant acute cholangitis (the most probable to benefit from early ERCP), the difference remained (15% vs 60%). Similar results were reported in another randomized study, in which the ERCP was performed within 24 h after admission [12]. The early ERCP group with predicted severe

pancreatitis had fewer complications (13% vs 54%) compared to the patients group on conservative treatment. One multicenter study evaluated the benefit of early ERCP in preventing severe AP in patients without acute cholangitis and/or biliary obstruction (serum bilirubin levels < 5 mg / dl) [13]. Their results showed no superiority of early ERCP regarding morbidity and/or mortality in the study group, but also an unusually high mortality (8%) among the patients with predicted mild pancreatitis. The most recent meta-analysis, including 7 randomized trials (n=757), found no evidence that early routine ERCP significantly affects mortality or local/systemic complications, regardless of the predicted severity of biliary pancreatitis, but it should be considered in patients with coexisting cholangitis or biliary obstruction [23]. Among the trials that included patients with cholangitis, the early routine ERCP strategy significantly reduced mortality, local and systemic complications as defined by the Atlanta Classification. Among trials that included patients with biliary obstruction, the early routine ERCP strategy was associated with a significant reduction in local complications as defined by authors of the primary study, but a nonsignificant trend toward reduction of local and systemic complications as defined by the Atlanta Classification. Although accurate prediction of common bile duct stones in acute biliary pancreatitis is warranted to select patients for early therapeutic ERCP, it should be noted that predicting their presence in the early stages of disease with complete liver biochemistry, transabdominal ultrasonography, or CT is unreliable [24]. In cases with severe biliary pancreatitis, the differential diagnosis between acute cholangitis and severe AP with systemic inflammatory response syndrome may be also difficult [10, 11]. In cases with suspected biliary obstruction, magnetic resonance cholangio-pancreatography (MRCP) or endoscopic ultrasound (EUS) when accessible are the preferred diagnostic modalities to identify it [25-28]. In patients with AP, the sensitivity and specificity of EUS and ERCP were the same (96% vs 96% and 85% vs 92%, respectively) for detecting choledocholithiasis [27]. By their use, ERCP would be reserved for patients with strong evidence of obstruction. In 2012, the IAP/APA (International Association of Pancreatology/American Pancreatic Association) evidence-based guidelines for the management of AP has been published [29]. It provides recommendations concerning the key topic on multidisciplinary management of AP. The following recommendations for the management of acute biliary pancreatitis, classified to their GRADE strength (1-strong, 2-weak) and quality of evidence (A - high, B - moderate, C- low) have been given: "ERCP is not indicated in predicted mild biliary pancreatitis without cholangitis. ERCP is probably not indicated in predicted severe biliary pancreatitis without cholangitis. ERCP is probably indicated in biliary pancreatitis with common bile duct (CBD) obstruction. ERCP is indicated in patients with biliary pancreatitis and cholangitis. Urgent ERCP (<24 h) is required in patients with acute cholangitis. Currently, there is no evidence regarding the optimal timing of ERCP in patients with biliary pancreatitis without cholangitis. MRCP and EUS may prevent a proportion of ERCPs that would otherwise be performed for suspected common bile duct stones in patients with biliary pancreatitis who do not have cholangitis, without influencing the clinical course. EUS is superior to MRCP in excluding the presence of small (<5mm) gallstones. MRCP is less invasive, less operator-dependent and probably more widely available than EUS. Therefore, in clinical practice there is no clear superiority for either MRCP or EUS.

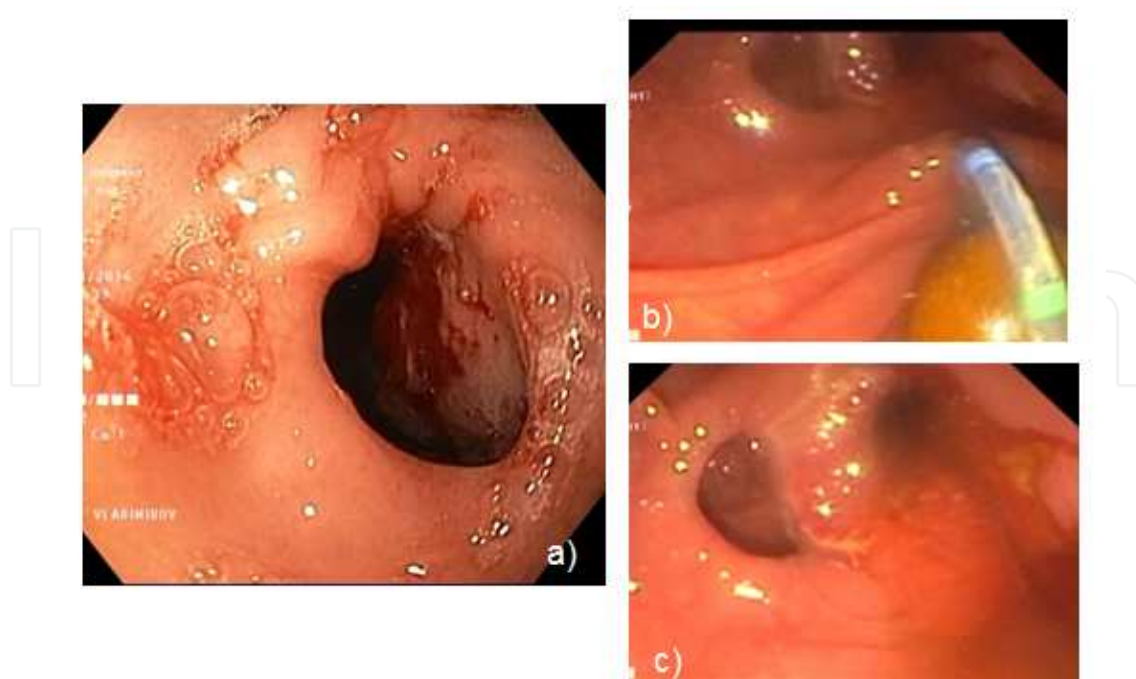


Figure 1. Endoscopic management of acute biliary pancreatitis. a) A view of compression of duodenal wall by enlarged gall bladder. b) Papillary sphincterotomy with extraction of impacted gall stone. c) A periampullary diverticulum neighboring on sphincterotomy.

1.2. Endoscopic management of local complications in AP (pancreatic necrosis/WOPN, PPC, disrupted pancreatic duct)

In the last years, the minimally invasive interventions for management of necrotizing pancreatitis have replaced the traditional open necrosectomy. Laparotomy and immediate surgical debridement of the infected necrotic tissue have been the gold standard treatment for a long time [5, 30]. This concept has been changed by multiple reports showing that early surgical intervention for pancreatic necrosis could result in a worse prognosis compared to cases where surgery is delayed or avoided [31-35]. Besides percutaneous drainage and minimally invasive surgery, endoscopic transmural drainage (ETD) and necrosectomy have an increasing role as an alternative to open surgery. The results of different multicenter studies and randomized trials, as well as systematic reviews, evidence-based guidelines and consensus statements have supported the safety and efficacy of endoscopic and other minimally invasive techniques in the management of severe AP and its complications [1, 29-32, 35-44]. In summary, intervention is primarily indicated for infected necrosis and less often for symptomatic sterile necrosis. They should be delayed 4 weeks or longer after the onset of disease, for better demarcation and liquefaction of the necrosis. Both the step-up approach using percutaneous drainage followed by minimally invasive video-assisted retroperitoneal debridement and endoscopic necrosectomy have been shown to have superior outcomes to traditional open necrosectomy with respect to short-term and long-term morbidity. Applicability of these techniques depends on the availability of specialized expertise and a multidisciplinary team dedicated to the management of severe AP and its complications [38]. According to the guidelines of IAP/APA

(2012), common indications for intervention (either radiological, endoscopic, or surgical) in necrotizing pancreatitis are clinical suspicion or documented infected necrotizing pancreatitis with clinical deterioration, preferably when the necrosis has become walled-off [29]. At present, there are insufficient data to define subgroups of patients with suspected or confirmed infected necrotizing pancreatitis who would benefit from a different treatment strategy, but percutaneous catheter or ETD should be the first step in the treatment of these patients, followed by endoscopic or surgical necrosectomy if needed. In the multicenter randomized trial, including 88 patients with infected necrotizing pancreatitis, the Dutch Pancreatitis Study group showed that the step-up approach of percutaneous (retroperitoneal) catheter drainage and followed, if needed, by minimally invasive necrosectomy, decreased major short-term complications (40% vs 70%) and costs as compared to primary open necrosectomy [36]. The rates of late complications as diabetes and exocrine pancreatic insufficiency were also lower in the step-up cohort of patients. Lately published trial by the same group, in which the patients were randomized to endoscopic transgastric versus open necrosectomy, demonstrated a lower rate of proinflammatory response, organ failure, and major complications in patients undergoing EUS-guided necrosectomy as compared to surgical necrosectomy [41]. The results from a currently performed multicenter randomized controlled trial (TENSION trial) comparing endoscopic transluminal to minimally invasive surgical step-up approach are awaited [45]. A small proportion of patients with documented infected necrosis who remain clinically stable can be managed with antibiotics alone, without the need for percutaneous catheter drainage or necrosectomy. Future studies should compare (initial) antibiotic treatment of infected necrosis with other, more invasive, strategies [29]. The vast majority of patients with sterile necrotizing pancreatitis can be managed without intervention. Indications for intervention (either radiological, endoscopic, or surgical) in this group of patients are: ongoing gastric outlet, intestinal, or biliary obstruction due to mass effect of WOPN; persistent symptoms ("persistent unwellness") in patients with WOPN without signs of infection; disconnected duct syndrome in the presence of persisting symptomatic collection with necrosis. Rare complications requiring (nonsurgical) intervention in the follow-up after sterile necrotizing pancreatitis are pancreaticopleural fistula, pancreatic ascites, and a "true" (no necrosis found in the collection on MR or ultrasonography) symptomatic pseudocyst.

Several comprehensive reviews discussing indications, timing, standard and novel approaches, outcomes, and complications regarding ETD and necrosectomy in infected necrotizing pancreatitis have been published recently [2, 3, 38, 39, 42-47]. The technique of endoscopic transluminal necrosectomy (ETN) involves a transmural (transgastric or transduodenal) access to the WOPN, followed by large-caliber balloon dilation of the tract between the collection and the gastrointestinal wall, allowing the insertion of an endoscope into the collection to visualize the necrotic material, mechanical debridement, and lavage. A variety of tools, such as baskets, snares, and nets have been used to remove the necrotic tissue. A stent (plastic/metal) is left in place at the end of the procedure to keep the fistula patent and to allow access into the necrotic cavity at a later session. Most patients with severe AP complicated by WOPN require multiple sessions to achieve radiographic and clinical success. One recent systematic review on the ETN of pancreatic necrosis found that a median of 4 (1-35) sessions are needed to achieve resolution of the necrotic collection [42]. EUS-guided necrosectomy is increasingly used due to the ability

of EUS to visualize and determine the optimal access into the collection, to avoid intervening blood vessels, to assess the contents of the cavity, and to visualize bleeding into the collection and other complications during and immediately after the procedure [46]. One recent systematic review reported that EUS-guided necrosectomy has been performed in 283 published cases so far [48]. Currently used endoscopic accessories during ETN are designed for other purposes and are not optimal in achieving adequate necrotic debridement in a limited time. The authors of one study showed that drainage of necrotic collections with multiple instead of a single transmural access, placing multiple stents and a nasocystic drainage in each tract (multiple transluminal gateway technique), led to better long-term clinical outcomes [49]. Other authors reported that the use of hydrogen peroxide in their small case series facilitates the removal of necrotic debris, but the benefit and potential complications need to be further investigated [50, 51]. The use of metal stents specially designed for drainage of pancreatic fluid collections was also reported in small case studies and the results regarding their efficacy are awaited [52-54].

The summary results of various studies show that ETN is an effective minimally invasive treatment in infected necrotizing pancreatitis. It was reported that the success rate of peroral endoscopic drainage/debridement of WOPN was 81% of 53 studied patients [55]. Results from a multicenter US series demonstrated a resolution rate of 91% (95/104 patients with WOPN) as the mean time to resolution was 4.1 mo from the initial procedure [56]. A recent systematic review, including 15 studies (455 patients), reported that with ETN definitive successful treatment was achieved in 81% of patients, mortality was 6%, and complications occurred in 36% of patients [44]. Bleeding was the most common complication (18%), following perforations to the peritoneum. Other reported complications included infection, aspiration, stent migration, occlusion, pancreatic duct damage, complications of sedation, and gas embolism. In the systematic review on EUS-guided necrosectomy, it was found that the mean technical and clinical success rates were 100% and 88%, respectively; mean overall complication rate was 28%, and mean overall recurrence rate was 7% [48]. The results of one recently published systematic review and meta-analysis of ETN for WOPN (8 studies) showed that the mean time of ETN after onset of AP was 7 weeks; the mean size of the necrotic cavity was 12.87 cm and the weighted mean number of endoscopic procedures needed to resolve the necrotic cavity was 4.09 [43]. The pooled proportion of successful resolution of pancreatic necrosis using ETN was 81.84% and that of recurrence after ETN was 10.88%. Complications were noted in 21.33% of patients, including bleeding, sepsis, and perforation. For pancreatic necrosis that did not resolve, surgery was performed in 12.98% of patients. The authors of this meta-analysis conclude that ETN is safe and effective at treating patients with symptomatic WOPN and offers the advantage of minimally invasive endoscopic treatment without transabdominal surgery but better techniques and equipment are still needed to improve procedural efficiency. The decisions to perform ETN should be made by advanced endoscopists in collaboration with a multidisciplinary team with the facilities and personnel to manage these complex patients.

Symptomatic pancreatic pseudocysts (abdominal pain, gastric outlet, obstructive jaundice) and disrupted pancreatic duct in AP are also indicated for endoscopic therapy. The literature data show that the incidence of APFC in acute edematous pancreatitis is around 40% and development of PPC is approximately 10% of these cases [57]. Earlier it had been

reported that pseudocysts result from pancreatic duct disruption in up to 10%–25% of cases with AP and in 20%–40% of chronic pancreatitis (CP) cases [58]. Endoscopic drainage of PPC (transpapillary, transmural, or combination of the both) has been demonstrated as effective minimally invasive method for their treatment in a number of studies. The results regarding technical success, recurrence, and complications rates will be discussed below, in endoscopic therapy of PPC in CP.

Disruption of the pancreatic duct (PD) secondary to pancreatic necrosis occurs in attacks of AP and leads to leakage of the pancreatic secretion and its accumulation inside the abdomen in the neighborhood of the pancreas and pseudocyst formation [4]. It may also result in pancreatic ascites or pancreatic fistulae. Endoscopic treatment of the disrupted PD includes transpapillary stent bridging of the pancreatic leak or diverting pancreatic duct flow [59]. The efficacy of these techniques has been demonstrated in several studies [60–62]. Complete duct disruptions are refractory to transpapillary stenting because the upstream disconnected segment maintains secretion. Therefore, ETD has arisen as the procedure of choice for cases with complete duct disruptions [62].

1.3. Endoscopic therapy in idiopathic acute pancreatitis

Idiopathic AP is defined as pancreatitis with no etiology established after initial laboratory and imaging tests (transabdominal ultrasound and CT in the appropriate patient) [63]. Patients with idiopathic AP should be evaluated at specialized centers on pancreatic diseases, applying combined multidisciplinary approach, including advanced endoscopy [1]. Various anatomic (pancreas divisum, anomalous anomalous pancreatobiliary duct junction, choledochal cysts/cholechocele, periampullary diverticulae, ampullary tumors) and physiologic anomalies (sphincter of Oddi dysfunction/SOD) can contribute to recurrent episodes of AP and many of them can often be diagnosed and treated endoscopically [3, 64, 65]. The diagnostic role of ERCP can help define specific causative factors in patients with idiopathic AP, but its major limitation is the risk of post-ERCP pancreatitis, which varies from 5% to 10% and reaches 30% in cases with SOD. For this reason, diagnostic and therapeutic endoscopy in these cases should be performed in specialized units.

Pancreas divisum (PD) is reported in about 20% of patients with acute recurrent pancreatitis [65]. Endoscopic therapy in PD includes minor papilla sphincterotomy, papillary dilation, stent placement, or a combination of these techniques. Endoscopic and surgical therapy are comparably effective in 70%–90% of patients with PD but endoscopic therapy as minimally invasive method is preferred in most cases [66]. In patients with dilated dorsal duct or abnormal function test, and no ductal strictures upstream of the minor papilla, sphincterotomy is the procedure of choice. A short-term dorsal pancreatic duct stent placement is recommended to avoid postprocedure complications. Although endoscopic therapy has been proved effective in a large percentage of cases with PD, there is only one small randomized controlled trial [67]. The authors reported that in the treatment group, 9 out of 10 patients (90%) had no further episodes of AP during a 3-year follow-up, while 6 of 9 patients (67%) who were randomized to no treatment had at least one episode.

Endoscopic management, including biliary sphincterotomy alone, is also the method of choice for patients with uncomplicated type 3 choledochal cyst/choledochoceles. Treatment of most other choledochal cysts is mostly surgical because for their potential of malignant degeneration [3]. The presence of periampullary diverticulum, although rarely, can also be a cause for acute relapsing pancreatitis. Endoscopic sphincterotomy in a small series of patients was found to be effective with no further episodes of AP during the follow-up period [68]. It has been estimated that 5%–14% of patients with benign or malignant pancreatobiliary tumors present with idiopathic AP [69-72]. Pancreatic cancer should be suspected in any patient >40 years of age with idiopathic pancreatitis, especially those with a prolonged or recurrent course [72]. Ampullary tumors can be resected either surgically or endoscopically [3]. It was reported that endoscopic treatment (snare polypectomy with sphincterotomy) was successful in the removal of ampullary tumors with no ductal invasion in up to 90% of cases [73, 74]. Procedure-related pancreatitis could be reduced by prophylactic stent placement and a long-term surveillance with endoscopic biopsies was recommended.

Sphincter of Oddi dysfunction is a nonmalignant condition resulting in impairment in sphincteric physiology, leading to outflow obstruction. SOD is reported in about one-third of cases with recurrent pancreatitis [65]. The diagnosis is confirmed by endoscopic SO manometry. In documented SOD, endoscopic therapy includes biliary and/or pancreatic sphincterotomy. Prophylactic pancreatic stenting for two weeks after sphincterotomy has shown to reduce the incidence of post-ERCP pancreatitis [75]. Clinical improvement after sphincterotomy has been reported in 55%–95% of patients, depending on the type of SOD, and manometric recordings [76, 77]. The analyses of published studies (237 patients with follow-up ranging from a mean of 3 months to 5 years) showed that favorable outcomes are the highest in type I SOD cases (83%–100%) while in type II SOD patients long-term symptom relief was reported in up to 79%, depending on whether manometry was abnormal. One recent study, including 69 patients with recurrent AP and pancreatic SOD randomized to biliary sphincterotomy with and without pancreatic sphincterotomy showed that the recurrence of pancreatitis was similar in both groups (48.5% vs 47.2%) [78].

2. Endoscopic therapy in chronic pancreatitis

In recent years with advances in technology, endoscopic therapy is one effective management option in CP along with medical and surgical treatments. Endoscopy became preferable management in selected patients with CP because of high success rate and low morbidity and mortality. The results are comparable to surgery [79-82]. In addition, the procedure may be repeated with no extra risk [83]. Endoscopic therapy may reduce or eliminate the need for surgical procedures, may serve as a bridge to surgery in poor operative candidates, and can predict the response to surgical therapy [84-85]. If endoscopic therapy is unsuccessful, surgical therapy is still a potential option for most patients.

Today endoscopic therapy is performed in patients with CP who are unlikely to respond or have failed medical therapy, or when it is necessary to resort to long-term opioid administra-

tion [83, 86-89]. The aims of endoscopic therapy in CP are to relieve outflow obstruction of main pancreatic duct (MPD) to control of pain, as well as to manage complications such as ductal strictures, calculi, pseudocysts, and biliary strictures [83, 86-90]. Endoscopic therapy is based on different techniques and procedures, such as ERCP, pancreatic sphincterotomy, pancreatic stones extraction, pancreatic and biliary stenting, and drainage of pseudocysts. Extracorporeal shockwave lithotripsy (ESWL) for MPD stones may be combined with endoscopic procedures. Advances in EUS have improved PPC drainage and cannulation of inaccessible MPD, as well as celiac plexus block [83, 86, 87, 89].

We evaluated the endoscopic methods of therapy in patients with CP (n=114, group), and compared the results to those of control group of patients, treated by conventional conservative methods (n=100, group) [91]. All cases were followed-up for a period of 3 years. The early and late results showed that endoscopic treatment led to clearance of common pancreatic duct by stone extraction (82% and 71%), control of strictures/fistulae by stenting (76% and 68%), (Figure 2), and pseudocyst decompression by cystogastrostomy under EUS plus dilation and stenting (73% and 30%), (Figure 3). Symptoms improvement, especially pain, was observed in 86% versus 17% (6th month) and 70% versus 14% (3rd year) in group and group , respectively ($p<0.001$). Endoscopic treatment significantly reduced the incidence of new pancreatic attack ($p<0.01$). New formation of pancreatic duct stones occurred in 2/17 patients. Replacement of pancreatic prostheses was needed in 41%. New ductal or parenchymal changes were observed in 25%. According to these data we suggest that endoscopic procedures are one alternative strategy in chronic pancreatitis with impaired drainage, leading to pancreatic duct or pseudocysts drainage, reductions of pain and incidence of pancreatic attack, but recurrent and complications rates are higher.

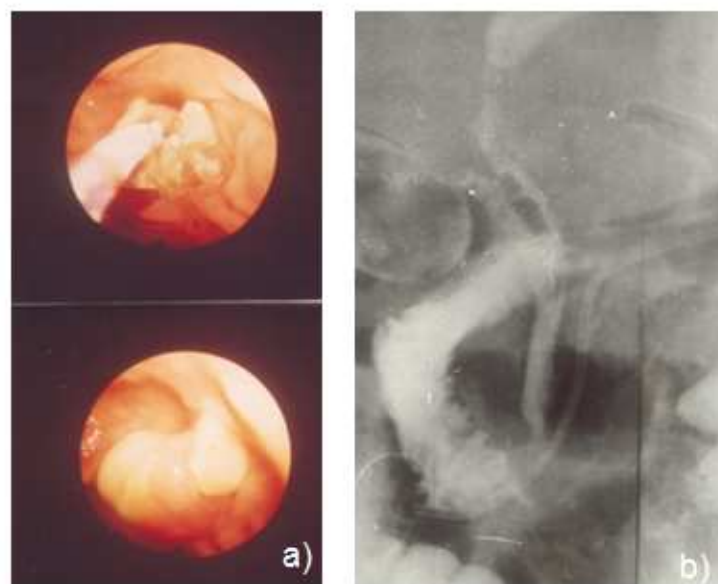


Figure 2. a, b) Endoscopic therapy in CP- insertion of endoprosthesis in a case with pancreatic ductal stricture.

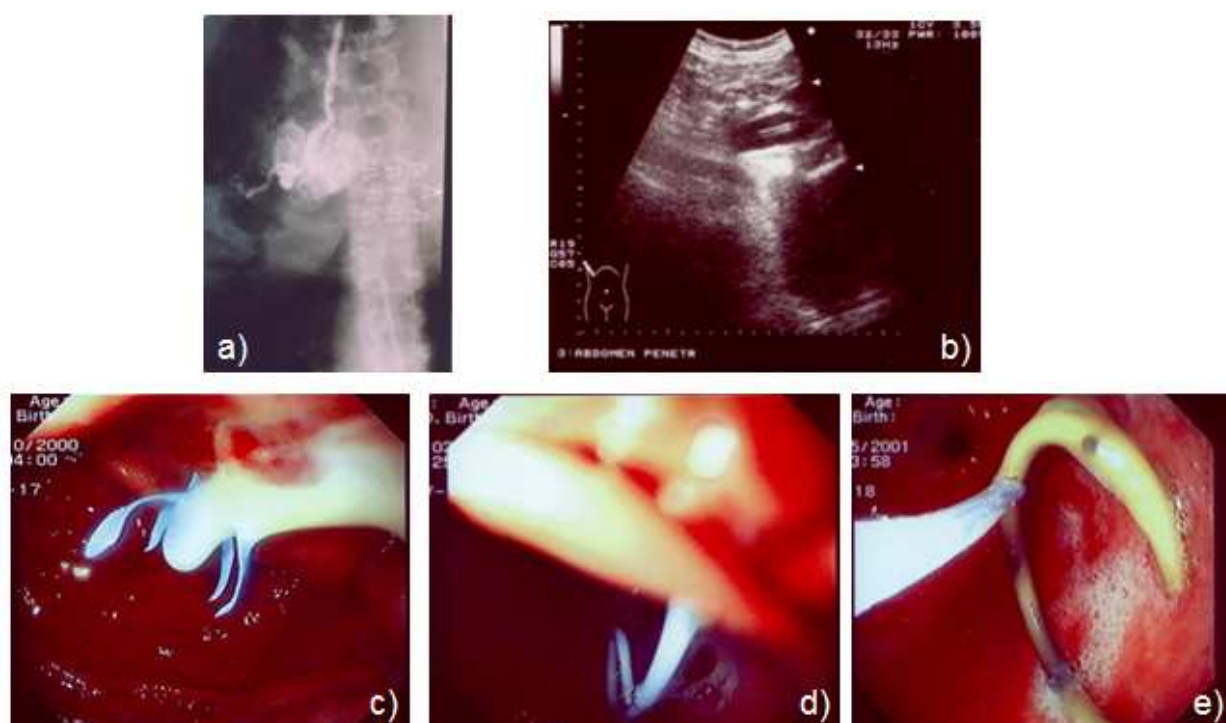


Figure 3. a, b, c, d, e) EUS-guided transgastric drainage of pancreatic pseudocyst in a case with CP.

In the last 10 years, there are accumulating data for the utility of endoscopic therapy and its efficacy and limitations in various painful conditions and complications associated with CP.

2.1. Painful uncomplicated CP

In the last version of the European Society of Gastrointestinal Endoscopy (ESGE) Guideline [86] on endoscopic treatment of painful uncomplicated CP, the following recommendations are given:

“Endoscopic therapy is the first-line therapy for painful uncomplicated CP. The clinical response should be evaluated at 6–8 weeks. If it appears unsatisfactory, the patient’s case should be discussed again in a multidisciplinary team with endoscopists, surgeons, and radiologists and surgical options should be considered, in particular in patients with a predicted poor outcome following endoscopic therapy” (*Recommendation grade B*).

Randomized controlled clinical trials comparing endoscopic and surgical pain treatment in CP showed better results for surgery [92–94]. In [92], it was reported that pain relief was 15% for endoscopic therapy versus 34% for surgery after 5 years of follow-up. It has been discussed that these results showed that neither of these options is satisfactory, and also that endoscopic therapy was not optimal [86]. ESWL and cumulative stenting were not used, and endoscopic therapy was not repeated in the case of recurring symptoms. In the trials of [93, 94], the initial stenting period was relatively short as stents were removed when the stricture had disappeared on the pancreatogram, but recurrence was observed when pain and stricture persisted. This is in contrast to most other studies, in which stenting is continued for 1–2 years. In

addition, included were patients with advanced disease with strictures and stones, as well as opioid-dependence. For these reasons, the results cannot be extrapolated to all patients with CP [86]. The long-term follow-up after endoscopic therapy in a total of 1890 patients with CP showed that 83% of them had no need of pancreatic surgery [82, 95-99]. In addition, surgery was associated with higher morbidity (18%–53%) and mortality (0%–5%) in comparison with endoscopic therapy of CP (3%–9% morbidity and 0%–4% mortality) [82, 100-103]. Pain relief was observed in 70%–94% of patients in the short-term followed-up, and in 52%–82% of patients in the long-term followed-up endoscopic treatment [104-108]. Similar results of endoscopic decompression therapy were found in patients with all types of obstruction, including calculi alone, stenosis alone, or a combination of both [87, 104]. After endotherapy, the number of pain-related hospitalizations and the need for analgesics decreased, but patients' quality of life was not improved significantly [89, 96, 109]. According to the Spanish Pancreatic Club's recommendations for the diagnosis and treatment of CP, endoscopic decompression treatment is less effective and has shorter-term effects compared to surgery [88]. Endoscopic pain treatment has been shown to be effective for patients with a dilated MPD, particularly when various endoscopic techniques are combined [88, 89]. Reference [88] shows also some limitations of endoscopic treatment. Better pain control following surgery compared to endoscopic therapy was observed in randomized clinical trials, but both endoscopic and surgical therapy had been tested in a randomized trial versus medical therapy. It is difficult to assess pain control of endoscopic therapy in long-term studies without a control group, given the tendency of its decreasing effects over time. Finally, endotherapy is a technically difficult and an operator-dependent procedure. ESGE experts [86] have shown some factors independently associated with long-term (≥ 2 years) successful endoscopic pain relief. These factors include: the obstructive calcifications in the head of the pancreas; short disease duration and low frequency of pain attacks before endoscopic therapy; complete MPD stone clearance; absence of MPD stricture at initial endoscopic therapy; and discontinuation of alcohol and tobacco during follow-up [96, 97, 99, 110-111].

In a painful CP with minimal or no ductal change with absence of ductal strictures or stones (mild CP according to Cambridge classification), endoscopic pancreatic sphincterotomy (EPS) is a method of therapy and it offers symptomatic relief in some of these patients. Both the standard pull type and the needle knife sphincterotomy over a stent can be performed [83, 87]. A total of 64% pain relief on follow-up of 6.5 years was reported following EPS in patients with idiopathic CP [112]. Other authors observed high success rates of 98% and low complication rates of around 4% in retrospective analysis [113].

Risks of pancreatic sphincterotomy include early complications of pancreatitis (2%–12%), bleeding (0%–3%) and perforations (<1%), and late complications of sphincter stenosis (up to 10%) [83, 87, 114]. Placement of a nasopancreatic tube or pancreatic stent can reduce their incidence [87, 102]. In reference [87], a 3 Fr single-pigtail plastic stent, 4–6 cm in length had been used to prevent postprocedure pancreatitis. The small-diameter single-pigtail stent generally passes into the gastrointestinal tract within 7–14 days without the need for a second endoscopic procedure for stent retrieval. A randomized study showed a higher incidence of pancreatitis in high-risk patients following pull-type sphincterotomy as compared to the

needle knife technique [115]. Restenosis is reported in around 14% of patients on long-term follow-up [116]. It is less common after the pull-type EPS with longer incision than the needle knife technique [117]. On the other hand, the use of EPS as a single therapeutic manipulation in patients with mild CP has not been studied well [86-89]. Therefore, endoscopic therapy is recommended as the first-line therapy for painful uncomplicated CP only in patients with moderate or marked changes at pancreatography according to the Cambridge classification.

2.2. Pancreatic duct stones

Nonsurgical clearance of stones obstruction of MPD can be achieved by ESWL or endoscopy alone, and by both of these techniques [83, 86-90]. In most patients, EPS with or without a biliary sphincterotomy via the major or minor papilla is performed to facilitate removal of pancreatic stones. The MPD stones are often impacted and difficult to extract, but up to 50% of MPD stones can be removed effectively by standard techniques, including endoscopic sphincterotomy or stone retrieval with a balloon, basket, and/or forceps alone [90, 101, 118-120]. Endoscopic stent placement, mechanical lithotripsy, intracorporeal lithotripsy with a pulse-dye laser, or electrohydraulic lithotripsy, are other possibilities [90, 121-125]. Adding ESWL increases clearance rates to 60%–90% [90]. The best candidates for endoscopic removal are MPD stones of the head or body with upstream MPD dilation [87, 90]. These devices are used to sweep or capture pancreatic duct stones to deliver stones, sludge, and debris out of the duct system and into the small-bowel lumen. Extraction balloons are very safe to use during ERCP [126]. Smaller pancreatic stone baskets are more effective if the duct lumen is less than 5 mm. In a case series, it was reported that endoscopic balloon dilation (12–15 mm) of the pancreatic orifice after sphincterotomy is a safe technique that facilitates the removal of large radiolucent stones from the MPD [127]. Further studies are needed before routine use of such large balloons can be recommended. On the other hand, in [86], the low success rate in a retrospective series of endoscopic stone extraction using Dormia baskets is discussed. In addition, mechanical lithotripsies are associated with relatively high morbidity rates in retrospective multicenter series [125].

ESWL has been usually used to facilitate the removal of PD stones during therapeutic endoscopy, especially in larger stones more than 5 mm in size [83, 86-90]. ESWL is now accepted as the standard of care in treatment of MPD stones. ESWL is highly effective at fragmenting radiopaque and radiolucent stones with high level of spontaneous elimination of stone fragments and pain relief [83, 86, 88, 90, 101]. In ESGE Guideline [86], successful stone fragmentation following ESWL has been defined as stones broken into fragments ≤ 2 or 3 mm, or by the demonstration of a decreased stone density at X-ray, an increased stone surface, and a heterogeneity of the stone which may fill the MPD and adjacent side branches. The ESGE Guideline group prefers the latter definition [86]. Performance of ESWL prior to endoscopy was associated with the success of MPD stone clearance in a retrospective study [111]. A meta-analysis of 17 studies with a total of 491 patients revealed a clearance rate between 37% and 100% and decreasing pain [128]. A review of 11 studies with over 1100 patients showed successful stone fragmentation in 89% [129]. Other authors reported complete clearance in 76% of 1000 patients and partial clearance in another 17% patients following ESWL and endother-

apy for large stones [101]. According to their opinion, patients with pain and large MPD stones in the head or body can be treated by ESWL. Patients with isolated calculi in the tail; multiple MPD strictures; extensive calculi in head, body, and tail; associated head mass; pseudocysts; and pregnancy are excluded from ESWL [83]. In [86], it has been discussed that in the majority of series, stones targeted by ESWL were mostly obstructive radiopaque MPD stones with a minimal diameter in the range of 2–5 mm. It has been also confirmed that factors significantly associated with success of MPD stone clearance after ESWL included the presence of a single stone, and confinement of calculi to the head of the pancreas.

A few studies have advocated the use of ESWL alone followed by spontaneous expulsion of fragments [83]. Patients frequently require several ESWL sessions to achieve stone clearance from the duct [130]. The results of uncontrolled series, including 350 patients followed-up for 44 months, showed spontaneous MPD stone clearance in 70%–88% of patients and long-term pain relief in 78% of patients [98, 131], whereas other investigators have had less impressive results [109, 132]. It has been discussed that complete removal rates differ among institutions [90]. These differences may be due to the type of lithotripter used, the power setting, the number of shocks delivered, the number of treatment sessions, and differences regarding the definition of complete removal of pancreatic stones among institutions. A randomized controlled trial of 55 patients compared the performance of ESWL plus ERCP or ESWL alone [111]. The only significant differences between the groups were the longer hospital stay and a higher treatment cost in the ESWL plus ERCP group. ESWL is a relatively safe technique. The minor complications from ESWL include skin or duodenal lesions, exacerbation of pancreatitis, mild abdominal discomfort, and asymptomatic hyperamylasemia. Acute pancreatitis attributed to ESWL has been reported in 6.0%–12.5% of patients after ESWL “alone” for treating calcified CP [97, 98, 111, 131]. Serious complications after ESWL have been reported in less than 1% of patients [133]. The reported morbidity and mortality rates are 5.8% and 0.05%, respectively [97, 98, 101, 124]. Contraindications to ESWL include coagulation disorders, pregnancy, and presence in the shockwave path of bone, calcified aneurysms, or lung tissue [86]. Implanted cardiac pacemakers are not universally contraindicated to ESWL [134].

Finally, ESWL combined or not with ERCP is recommended as the first-line therapy for painful uncomplicated CP. The last ESGE Guideline [86] recommended: “For treating patients with radiopaque stones ≥ 5 mm obstructing the MPD, ESWL as a first step, immediately followed by endoscopic extraction of stone fragments. In centers with considerable experience with ESWL, ESWL alone should be preferred over ESWL systematically combined with ERCP (Recommendation grade B). Endoscopic attempts to extract radiopaque MPD stones without prior stone fragmentation should be considered only for stones <5 mm, preferably low in number, and located in the head or body of the pancreas. Intraductal lithotripsy should be attempted only after failure of ESWL (*Recommendation grade D*)”. Intraductal laser or electrohydraulic lithotripsy are second-line interventions after failed ESWL, with success rates for stone fragmentation of 47%–83% [135, 136]. Stone dissolution therapy may have a role only in patients in whom all other methods have failed and who are not surgical candidates [86].

Several studies reported that pain relapse occurs more frequently with incomplete stone removal [97, 137, 138]. In contrast, other series reported no difference in pain relapse rates

between complete and incomplete removal groups [132, 139]. In one study, all patients with relapse had intraductal pancreatic stones, suggesting that the main cause of pain relapse is recurrent (or remnant) pancreatic stones [97]. Failure to achieve pain relief despite adequate clearance of the pancreatic duct stones indicates other mechanisms of pain in patients with CP.

2.3. Pancreatic ductal strictures

Endoscopic therapy is indicated for single strictures in the head while isolated strictures in the tail or multiple strictures are not amenable to endotherapy [85, 87]. Prior to MPD stenting, EPS of the major or minor papilla has been performed [83, 86, 87, 140]. Stricture dilation with Teflon bougies, Sohendra stent retriever, or a balloon dilator is also performed prior to stenting in most cases. High-grade strictures require dilation prior to insertion of the endoprosthesis [86, 87]. Because chronic pancreatitis-related MPD strictures may be very tight and resilient, dilation alone of the pancreatic duct stenosis is not a useful treatment [87, 88]. Large bore plastic stents should be deployed as they have longer patency [140]. Stents measuring 8.5 Fr or 10 Fr in diameter are used in most studies. A retrospective study of 163 patients showed that thinner MPD stents (≤ 8.5 Fr) are associated with 3 times more frequent hospitalizations for abdominal pain than 10-Fr stents [141]. In addition, stents should be kept in place for a long time (1–2 years) and require replacement in cases of obstruction and recurring symptoms [142]. MPD stenting for a short duration (6 months) has been shown to be poorly effective. The recurrence rate of pain after the stent removal was 30%–48%; as such pain often improves when a new stent is placed [86, 95, 105, 106]. In [140], a protocol was followed where a single stent was placed across a stricture and exchanged every 6 months or when the patient was symptomatic. Stents were placed for 24 months. Patients were restented if symptoms recurred. Surgery was considered if patients responded to stent placement but needed frequent or repeated stenting. Placement of a single pancreatic plastic stent achieves MPD stricture resolution in nearly 60% of cases [86]. Cumulative data from several trials showed that pancreatic stenting is technically successful in 85%–98% of cases, revealed pain relief in 65%–95%. Sustained pain relief was observed between 32% and 90% of patients on follow-up of 14–69 months [85, 105–108, 143, 144]. Recurrence of strictures was reported in 38% of patients after 2-year follow-up [96]. Restenting was reported in 22%–30% of patients, and 4%–26% of patients had pancreatic surgery. A pancreas divisum anatomy might require longer/multiple stenting because it is associated with more frequent relapse of MPD stricture and of pain after stent removal compared with MPD stenting in patients without pancreas divisum. Simultaneous placement of multiple pancreatic stents was reported to be of additional benefit. Other authors reported that after removal of a single stent, the stricture was dilated and multiple (mean of 3) plastic stents 8.5–11.5 Fr diameter were placed [145]. The stents were removed 12 months later. Stricture resolution was observed in 95% and pain relief in 84% on a 38-month follow-up.

Complications related to pancreatic stenting are reported between 6% and 39% [80, 105, 106, 143, 144]. They are usually mild and managed conservatively [83]. Mild pancreatitis is the most frequent complication of MPD stenting. Occlusion of stents requires stent exchange. Usually stent exchange was performed every 3 months or when symptoms developed [105–107]. The aim of an “on-demand” stent exchange schedule is to reduce the number of ERCP sessions

because occlusion usually occurs within 2–3 months, but symptoms of CP recur between 6 and 12 months [104]. Using of “on-demand” stent exchange schedule associate rare occurrence of pancreatic abscesses and sepsis [80, 95], and failure to decrease the number of ERCP sessions [95, 105]. MPD stent migration was present in 10% of patients [121]. Distal migration and impaction on the duodenal wall can cause perforation while proximal migration into the pancreas is a technical challenge for the endoscopist [83]. Proximal or distal stent migrations as well as pancreatic abscesses requiring surgery have rarely been reported. Because of elevated risk for pancreatic cancer, tissue samples are needed before endotherapy [146]. In addition, MPD stents may produce ductal changes, including strictures or focal areas of chronic pancreatitis [147, 148]. However, these changes may improve with time.

The ESGE recommended “treating dominant MPD stricture by inserting a single 10-Fr plastic stent, with stent exchange planned within 1 year even in asymptomatic patients to prevent complications related to long-standing pancreatic stent occlusion (Recommendation grade C)” [86]. Simultaneous placement of multiple, side-by-side, pancreatic stents could be applied more extensively, particularly in patients with MPD strictures persisting after 12 months of single plastic stenting. From this point of view, the ESGE Guideline recommended that available options (e.g., endoscopic placement of multiple simultaneous MPD stents, surgery) be discussed by a multidisciplinary team (Recommendation grade D) [86]. In Spanish Pancreatic Club’s guideline is pointed that pancreatic stenting is effective for treating short-term pain in patients with pancreatic duct stenosis, but it requires multiple ERCPs during follow-up, as well as pancreatic stents must be maintained for at least 12 months [88].

The search for an ideal pancreatic stent continues and a new “wing stent” to prevent clogging as well as an “S” shaped stent to prevent migration are undergoing evaluation [107, 149]. In one study in 20 patients, inserted self-expandable, uncovered Wallstents and partially or totally covered Wallstents in 18 patients with CP associated with dominant stricture of the MPD [150]. The results using uncovered Wall stents were unsatisfactory because of frequent stent dysfunction caused by tissue ingrowth (65%) through the wire mesh. In cases using partially or totally covered stents, epithelial hyperplasia and stent migration were the major late complications. The authors concluded that self-expandable stents provided disappointing results. The use of covered self-expandable metal stents (CSEMS) for pancreatic strictures now is also under evaluation. Preliminary data show that CSEMS is safe. They also allow pain relief and resolution of MPD strictures in a majority of patients, but no follow-up longer than 1 year is available [86]. The initially used CSEMS had the disadvantage of stent migration. A new “bumpy stent” has antimigratory properties and its contours adapted to the MPD. The stents were extracted at 3 months and were effective in resolving the MPD strictures [151, 152]. However, they were associated with the formation of de novo focal MPD strictures (16% of 32 patients). Further trials are needed to evaluate their long-term efficacy and safety. According to the ESGE Guideline [86], uncovered SEMS should not be inserted in MPD strictures (Recommendation grade D); temporary placement of fully CSEMS holds promise but it should be performed only in the setting of trials with approval of the institutional review board (Recommendation grade C).

Endosonography-guided access and drainage (ESGAD) of the MPD in CP-related MPD stricture includes puncturing the MPD through the gastric or duodenal wall, obtaining a pancreatogram and advancing a guide wire into the MPD to proceed with transpapillary (rendezvous technique) or transmural drainage [129]. The duodenal route is preferred [85]. ESGAD was effective in obtaining MPD drainage and pain relief (between 50% and 100%) in selected patients with painful obstructive CP with mild morbidity. Some data have shown pain relief dropped with time from 69% to 20% after 450 days [153, 154]. In addition, some patients had a diagnosis of cancer within a year of the procedure. Reported complications related to ESGAD of the MPD are between 0% and 55% [91-94]. Most of them include relatively mild postprocedure pain, but severe pancreatitis, perforation, bleeding, and hematoma have been also observed [153-158]. No procedure-related mortality has been reported. Migration and occlusion of stents occur in 20%–55% of patients, necessitating endoscopic reintervention. No mortality was observed. On the basis of these data, ESGE [86] recommended: “ESGAD of the MPD is indicated in carefully selected patients; patients considered for ESGAD should be referred to tertiary centers with appropriate equipment and expertise (Evidence level 3, Recommendation grade D).” Potential indications for ESGAD of the MPD include patients with a symptomatic MPD obstruction and failed conventional transpapillary MPD drainage. In a randomized trial comparing endoscopic transampullary drainage of the MPD and operative pancreaticojejunostomy, complete or partial pain relief was achieved in 32% of the patients receiving endoscopic drainage and in 75% of the patients receiving surgery [93]. The rate of complications, length of hospital stay, and changes in pancreatic function were similar between the two treatment groups, but patients receiving endoscopic treatment required more procedures than those in the surgery group (median of 8 vs 3). These data show that surgical drainage of the MPD was more effective than endoscopic treatment in patients with obstruction of the MPD related to CP.

2.4. Endoscopic Ultrasound-guided Celiac Plexus Block (EUS-guided CPB)

Patients who have failed to respond to intensive medical or endoscopic therapy and are not candidates suitable for surgery can be provided relief from pain by EUS-guided CPB. EUS-guided CPB is one option for life-quality improvement for patients with CP, and it can be used in patients with nondilated MPD [159]. A combination of corticosteroids (triamcinolone) and local anesthetic agents (bupivacaine) is injected into celiac plexus nerves and around the celiac plexus under EUS guidance [83, 86-88]. Celiac plexus neurolysis (CPN) involves injection of a neurolytic agent (absolute alcohol) into the celiac plexus to ablate or destroy the ganglia, thereby interrupting pain transmission [87]. There is no difference between central versus bilateral injections in EUS-guided CPB [160]. No benefit of adding triamcinolone to bupivacaine was observed [161]. Some investigators prefer to reserve alcohol to patients with cancer-related pain [162]. In [48] it has been discussed that alcohol-based EUS-guided CPN provided pain relief in 59%. Therefore, this procedure is effective in pain control due to CP, but with a relatively lower efficacy compared to oncologic disease. The development of techniques or new injected drugs seems to be needed.

Meta-analyses have reported that EUS-guided CPB provides pain relief in 51%–59% of patients with painful CP for a period of 3–6 months [87, 163, 164]. In a prospective series of 90 patients,

the proportion of patients with pain relief decreased from 55% immediately after EUS-guided CPB to 10% at 24 weeks [165]. However, the efficacy of this therapy remains unclear. Patients who are younger than 45 years or have previous pancreatic surgery are less likely to benefit. In two randomized controlled trials, EUS-guided CPB appears to be associated with better outcomes and low incidence of side effects, and patient preference, as well as is more cost-effective than CT-guided route [166, 167]. In addition, EUS-guided route is not associated with severe complications such as paraplegia and aortic pseudoaneurysms [168, 169]. EUS-guided nerve block can produce diarrhea, hypertension due to sympathetic blockade because of the relatively unopposed visceral parasympathetic activity [87, 164, 170].

The most common (30%–40% of patients) complications of EUS-guided CPB include transient diarrhea, abdominal pain/pain exacerbation, and hypotension. However, they are usually mild and self-limiting [48, 164, 171-172]. There are also infrequent reports of retroperitoneal bleeding, peripancreatic abscess, abdominal ischemia, permanent paralysis, and also death [48, 87]. It has been proposed that the risk of serious morbidity and mortality should be weighed against expected benefits particularly in patients with a long life-expectancy (i.e., patients with CP).

ESGE experts [86] recommended considering CPB only as a second-line treatment for pain in CP. EUS-guided CPB should be preferred over percutaneous CPB (Recommendation grade C).

2.5. Pancreatic Pseudocyst (PPC) in CP

Endoscopic treatment is indicated for symptomatic PPC (abdominal pain, gastric outlet obstruction, early satiety, weight loss, or jaundice) and infected or enlarging PPC [86, 88, 89, 173]. In most series, spontaneous resolution of PPC in CP is rare (0%–9%) [174-176]. Only a single series reported a higher (26%–39%) resolution rate after a long follow-up [87, 177]. The duration and size of the pseudocyst do not accurately predict the probability of spontaneous resolution or the development of complications, but larger (>4 cm) and/or longer-lasting (>6 weeks) pseudocysts are generally the ones that require active treatment [178]. Therefore, prophylactic treatment can be performed in selected asymptomatic patients with aim to prevent complications as pancreatic-pleural fistula, cysts >5 mm lasting for over 6 weeks, compression of major vessels, intracystic hemorrhage, cyst wall >5 mm, and PPC with advanced MPD changes or pancreaticolithiasis (presence of large pancreatic stones in MPD) [178, 179].

Many factors such as the size of the pseudocyst, bulging on the gut lumen, ductal communication, coagulopathy/portal hypertension, tolerance to multiple procedures, and symptoms can affect PPS management. Endoscopic therapy of PPC includes insertion of a drain from the digestive lumen into the PPC, through the digestive wall (“transmural drainage”), through the papilla (“transpapillary drainage”), or a combination of these routes. Transpapillary PPC drainage is reserved for the case of direct communication between the PPC and the MPD, as well as for small cysts (<6 cm size) [83, 180-183]. Transmural drainage is used for PPC which bulge into the lumen of stomach or duodenum, and the distance between the gut wall and the pseudocyst is less than 1 cm, with no intervening major vascular structures [83, 86, 89].

Transduodenal drainage offers the best success when compared to transgastric drainage. This is because cystoduodenal fistulas tend to remain patent

longer than cystogastric fistulas. A chronic cyst with clear liquid contents can be drained with one or more stents. On the other hand, an infected cyst may be aided by irrigation with a nasocystic catheter [87]. Placement of pigtailed stents is better when compared to straight stents. Straight stents are associated with a higher rate of bleed (around 7%) as well as migration [184]. Stents should be left in place for a longer duration as their removal within 2 months is associated with a higher incidence of PPC recurrence [86, 185]. Pseudoaneurysm can complicate management of PPC because of the associated hemorrhage and consequent high mortality [186]. Prophylactic embolization of pseudoaneurysms prior to drainage of an adjacent PPC has been recommended [140]. EUS is ideal for drainage of nonbulging PPC and cysts up to 4 cm from the stomach or duodenal wall [187], as well as in patients with portal hypertension [87]. In the presence of collaterals, the site of drainage is better identified with EUS, thus making the procedure safer. Technical success of endoscopic treatment is usually defined as the ability to insert at least one stent from the PPC to the digestive lumen, or resolution of the fluid collection but not necessarily of symptoms [184, 188-189]. Short-term clinical success is usually defined as complete relief of the initial symptoms with a decrease in PPC diameter of at least 30%–50% at 1 month [190]. In a summary of clinical trials, stent placement was technically successful in 89% of the cases, with a success rate of 80%–95% at most centers, a recurrence rate of 10%–20%. Complications as bleeding, infection, perforation and leak were observed in 3%–34% and death in 0.3%–1% [86, 87, 184]. An infection is more likely with transpapillary drainage and a leak is more likely with transmural drainage. Routine antibiotic administration is needed for drainage of PPC [191]. These results are comparative or better than surgery. In addition, compared with surgery, endoscopic drainage of uncomplicated PPC provides similar long-term results at a lower cost, with shorter hospital stay, and better quality of life during the first 3 months following treatment. Procedure-related mortality is slightly lower with the endoscopic method [86]. Randomized controlled trials and large reviews of noncomparative historical series of endoscopic and surgical treatments have also showed that drainage via EUS is better or similar than surgery [189, 192-194]. In [189], transmural and transpapillary drainage in 116 patients with PPC was compared. Successful resolution of symptoms and collection occurred in 88% of the cases. No significant differences were observed related to drainage technique or drainage site. In three nonrandomized studies, transpapillary drainage was used for smaller PPCs than transmural drainage [182, 190, 195]. Transpapillary drainage was associated with lower morbidity (1.8% vs 15.4%) and similar long-term success (94.6% vs 89.7%) than transmural drainage.

Technical success was higher with EUS-transmural PPC drainage compared to conventional guidance in randomized controlled trials [188, 193]. All patients with failed conventional drainage had a successful EUS-guided drainage. The complication rate was similar when PPCs are drained with or without EUS guidance [188, 190]. Cystoduodenostomy is associated with more long-term success than cystogastrostomy (83.1% vs 64.0%, respectively) but identical morbidity (10%) [196]. PPC drainage with a single stent and a stenting duration ≤ 6 weeks were independently associated with failure of endoscopic treatment [184].

On the base of these data, the ESGE Guideline [86] recommended endoscopic therapy as the first-line therapy for uncomplicated chronic PPC for which treatment is indicated and that are within endoscopic reach (Recommendation grade A). "If transmural pseudocyst drainage is indicated in the absence of luminal bulging, it should be performed under EUS guidance (Recommendation grade A). For small collections communicating with the MPD in the head or body of the pancreas, use transpapillary drainage first. Cystoduodenostomy should be preferred over cystogastrostomy if both routes are deemed equally feasible. For transmural PPC drainage, insert at least two double-pigtail plastic stents (Recommendation grade D); these should not be retrieved before cyst resolution as determined by cross-sectional imaging and not before at least 2 months of stenting (Recommendation grade B). In the case of portal hypertension, transmural drainage should be performed under EUS guidance. If arterial pseudoaneurysms are detected in the vicinity of the PPC, arterial embolization should be considered prior to PPC drainage (Recommendation grade D), and antibiotic prophylaxis for endoscopic PPC drainage (Recommendation grade D)." In addition, the ESGE also recommended "besides transmural PPC drainage, attempting transpapillary bridging of MPD ruptures with a plastic stent. If the MPD rupture cannot be bridged, transmural stents should be left in place for as long as the disconnected pancreatic tail secretes pancreatic juice (typically, for years) (Recommendation grade D)."

2.6. CP-related biliary strictures

Generally accepted indications for treatment of CP-related biliary strictures are secondary biliary cirrhosis, biliary stones, progression of biliary stricture, cases with symptoms or asymptomatic elevation of serum alkaline phosphatase (>2 or 3 times the upper limit of normal values), and/or raised serum bilirubin for longer than 1 month [83, 86, 87, 197]. Biliary brushing as well as EUS-guided fine-needle aspiration is required to exclude the possibility of cancer [86, 87]. Endoscopic treatment for biliary strictures includes stricture dilation using single or multiple side-by-side plastic stents, as well as covered SEMs. Biliary strictures secondary to CP respond less well to stenting than all other benign biliary strictures because of less frequent resolve at the time of stent removal and are associated with more frequent relapses [198-200]. The presence of pancreatic head calcification is an important factor for failure of endoscopic therapy with single plastic biliary stent, but this factor may be less relevant if simultaneous multiple plastic stents are used [201, 202]. Some studies have shown that cholestasis can be effectively resolved in the short-term setting by plastic biliary stenting [203, 204]. Patients without restenosis showed improvement of hepatic fibrosis after long-term stenting [205]. Single plastic biliary stents are associated with poor resolution and higher relapse rate [83, 86]. Sustained benefit is seen in around 25% of patients on follow-up of 46 months [206]. Placement of simultaneous multiple plastic stents in CP-related biliary strictures is technically successful in over 95% of patients and offers the best results [83, 86]. Complete therapy requires approximately four ERCP procedures and stents exchanges performed every 3 months for minimum 1 year [83, 207]. On the other hand, in the latter series, stents were exchanged at ERCP only if they were clogged [86]. Single stents provided relief in 31% of 350 patients as compared to 62% in 50 patients who received multiple stents [83]. One nonrandomized study compared single and multiple biliary plastic stents in CP [202]. Clinically, success was reported

in 92% with multiple stents as compared to 24% with single stents. Plastic biliary stents placement in patients with alcoholic CP has been reported to be associated with high incidence of cholangitis, because of poor patient compliance with scheduled stent exchanges [208]. Treatment with uncovered SEMS is associated with a high long-term morbidity and not recommended. Placement of covered SEMS is an investigational option for CP-related biliary stenosis [86, 200, 209, 210]. Other authors reported that the use of SEMS for long-term stenting of benign biliary strictures due to CP was safe and that it provided successful and prolonged biliary drainage in a selected group of patients in whom surgical intervention was not possible or desirable [211]. A multicenter trial using fully covered SEMS in 127 patients of CP concluded that these prostheses are useful for treatment of biliary strictures in patients with CP [212]. In one systematic review of studies published from 2000 to 2012, the success rate and complications of covered SEMS versus multiple plastic stents in CP-related benign biliary strictures were compared [200]. A total of 12 SEMS (376 patients) and 13 plastic stent studies (570 patients) met the final inclusion criteria. A tendency to successful use of SEMS in strictures related to CP was shown. In SEMS use, the incidence of late adverse events was lower in CP-related strictures and the median number of ERCP was lower – 1.5 versus 3.9. Larger, prospective, randomized long-term studies are required to confirm these results [87].

There has been no head-to-head study comparing single or multiple plastic stents and metal stents in biliary strictures due to CP and surgery [83]. According to [88], surgery is the treatment of choice for symptomatic biliary stenosis. Stents should be reserved for patients with high surgical risk to temporarily stabilize or improve them for surgery or for patients who refuse surgical treatment. In such cases, the best results are obtained with the placement of multiple stents or metal-covered stents [202, 213].

The ESGE Guideline [86] recommends: “The choice between endoscopic and surgical treatment should rely on local expertise, local or systemic patient co-morbidities (e.g., portal cavernoma, cirrhosis) and expected patient compliance with repeat endoscopic procedures (Recommendation grade D). If endoscopic therapy is elected, the ESGE recommends temporary (1-year) placement of multiple, side-by-side, plastic biliary stents (Recommendation grade A). Because of the risk of fatal septic complications, a recall system should be set up to care for patients who do not present for scheduled stent exchanges. In cases of relapsing stricture after stent removal at 1 year, the options available, including surgical biliary drainage, should be evaluated by a multidisciplinary team (Recommendation grade D)”.

Today, there are many effective new and standard endoscopic techniques for the treatment of CP, especially in patients with pain and dilated main pancreatic duct because of intraductal calculi and/or strictures, as well as symptomatic or complicated pseudocysts, and CP-related biliary strictures. Today, there is also better patient selection for specific techniques, leading to more effective treatment. Earlier endoscopic therapy is more effective, less invasive than surgery, and is associated with low morbidity and mortality. In addition, it can be repeated and does not interfere with subsequent surgical procedure. Endotherapy became the first-line treatment in selected patients with CP.

3. Endoscopic therapy in Pancreatic Cancer (PC)

In the last years, the role of endoscopy as a part of multidisciplinary management of PC has increased. Endoscopy (ERCP) and mainly endoscopic ultrasound (EUS) with EUS-FNA and/or core biopsy are one of the most sensitive methods for the diagnosis and staging of PC. Therapeutic endoscopy has an important role in the palliation of patients with inoperable PC, including endoprosthesis stent placement in cases with biliary or duodenal obstruction, and EUS-guided CPN to control the pain. Various EUS-guided procedures, as tumor ablation, injection of antitumor agents, fiducial placement, and brachytherapy have been used for therapy of selected cases with PC.

3.1. Endoscopic therapy in biliary/duodenal obstruction

PC is among the tumors with the worst prognosis, with very high mortality rate. Most cases with PC are diagnosed at an advanced stage when surgical resection is not possible. Patients with unresectable PC often develop biliary and/or duodenal obstruction during the course of their disease, which are related with various complications and negative impact on quality of life, and not rarely are a cause for discontinuation of chemotherapy [214, 215]. In the past, surgical bypasses (biliary–digestive and gastro–jejunal anastomoses) were used for palliative treatment of biliary or duodenal obstruction, but currently endoscopic stenting is the preferred method. In the literature, several studies have compared the endoscopic and surgical palliative treatment of jaundice or duodenal obstruction in patients with unresectable PC [216-223]. The summary results show an advantage to endoscopic treatment in terms of quality of life, duration of hospitalization, and cost. The results of meta-analysis by the Cochrane Collaboration showed that rate of technical success and short-term efficacy in comparison of palliative endoscopic biliary drainage and surgical drainage for obstructing pancreatic carcinoma were similar, but the morbidity and duration of hospitalization are higher for surgical bypass [217, 218]. It was reported by various authors that endoscopic treatment of duodenal stenosis compared to bypass surgery was related with fewer complications, shorter hospitalization, and lower cost [219-223].

Endoscopic treatment of biliary obstruction includes placement of biliary stent (plastic or SEMS) during ERCP. The procedure is often associated with sphincterotomy, which facilitates the insertion of the prosthesis or its eventual replacement [214]. The results of randomized clinical studies showed that the success rate of endoscopic biliary stenting is over 90% of unselected patients with PC, with a morbidity of 5% [217]. The type of prosthesis does not influence the success rate of stent insertion and short-term efficacy, defined as regression of jaundice, pruritus, and a decrease of serum bilirubin more than 20%. If cholangitis develops or if bilirubin fails to fall by 20% within the first week after stent insertion, the patency and position of the stent must be verified [214]. Placement of SEMS is the cost-saving strategy, as plastic stents are associated with higher risk of recurrent biliary obstruction and consequently with need of additional procedures and hospitalizations [217, 224-229]. On the basis of cost-effectiveness analyses, the insertion of a metal prosthesis (more expensive but with a longer duration of patency) has been recommended if the patient's life expectancy is longer than 4

months [230]. Insertion of SEMS was advised in cases with biliary SEMS occlusion, as it provided longer patency and survival and decreased the number of subsequent procedures by 50% (compared to plastic stents) [229]. Technical failure during ERCP is encountered in up to 10% of cases due to various factors (duodenal obstruction, anatomical variations, periampullary diverticulum, tightness of the stricture) [214, 215]. In these cases, percutaneous transhepatic biliary drainage (PTBD), EUS-guided biliary drainage (BD), and surgical drainage are possible alternatives. The technical success rate for PTBD placement is 90% if the intrahepatic system is dilated and 70% in a nondilated system. The morbidity is 7% and the mortality is 5%, and it is contraindicated in the presence of ascites and coagulopathy. The results of recent systematic review on studies of EUS-guided biliary drainage (1127 published cases) showed that the mean technical and clinical success rates were of 91% and 88%, respectively, with the mean overall complication rate of 26% and mortality 0.4% [48]. The authors of one recent study of 25 patients with unresectable malignant biliary obstruction and a previous failed ERCP attempt reported 100% technical and clinical success after the use of one of both procedures – percutaneous transhepatic biliary drainage or EUS-guided BD – with no difference in incidence of adverse events [231]. It is summarized that EUS-guided BD appears to be a valid alternative to percutaneous BD, showing similar efficacy and safety [48]. EUS-guided BD can be performed by one of the following approaches: direct transluminal stenting via transgastric or transduodenal route, by rendezvous technique passing a guidewire through an intrahepatic or extrahepatic access to the papilla, and by antegrade stent placement. EUS-guided transhepatic access was associated with a higher incidence of complications compared to the extrahepatic route (30.5% vs 9.3%), although the both access routes showed similar success rates [232]. In comparison the outcomes of rendezvous technique and transluminal approach of EUS-guided BD it was found that the effectiveness and safety of the both techniques were the same [233].

Endoscopic treatment of duodenal stenosis, due to invasion of PC, includes placement of an SEMS through the duodenoscope (Figure 4) [214, 215, 234]. The reported success rate is 92%–100% and rapid alimentary recovery (usually within 24 h) occurs in 75%–93% of cases [217]. Early complications have been reported in 2%–12% of cases, including perforation, gastrointestinal hemorrhage, aspiration pneumonia, jaundice or cholangitis, acute pancreatitis. The main cause of failure is downstream obstruction by unrecognized carcinomatosis, insufficient length to bridge the stenosis, prosthetic obstruction (food impaction or tumor ingrowth), or migration of the prosthesis [214]. Duodenal stenting should be reserved for symptomatic stricture since the introduction of prostheses into noncritical strictures is associated with a greater risk of stent migration. In appearance of prosthetic obstruction, a repeat procedure may be necessary (approximately 15% of cases) with insertion of a new prosthesis through the original stent [223]. If endoscopic insertion of a duodenal stent is impossible, a percutaneous transgastric approach is alternative. In cases with associated jaundice, endoscopic management begins with the placement of a metal biliary stent and followed by placement of the duodenal stent. The biliary drainage must always precede the duodenal stent placement [235]. If a biliary stent has previously been placed, its patency should be confirmed before placing the duodenal stent and replaced if necessary. If jaundice develops after duodenal stenting, the alternatives approaches to the biliary tract as PTBD or EUS-guided BD could be used.

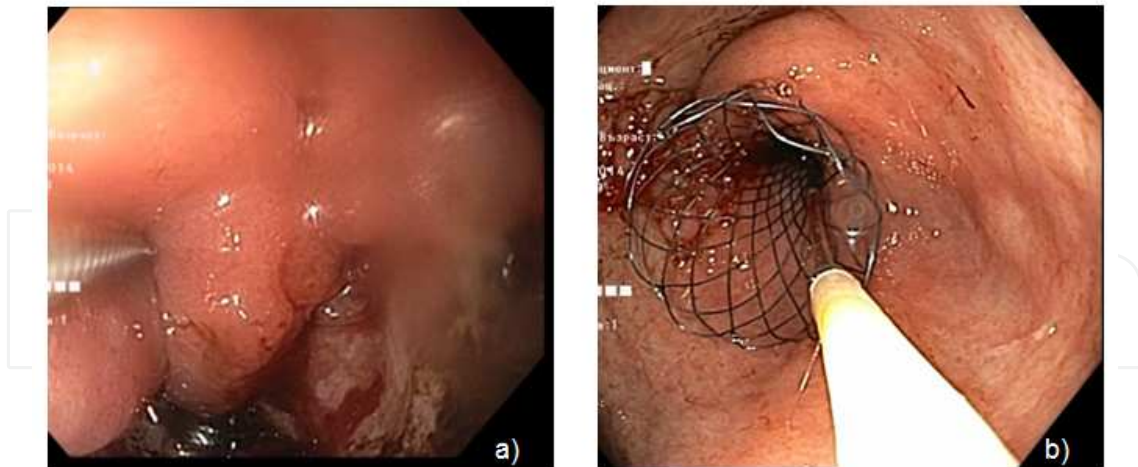


Figure 4. Palliative endoscopic management of PC. a) A view of pyloric infiltration and duodenal obstruction in a case with PC. b) Insertion of SEMS.

3.2. Endoscopic therapy for pain relief

Pain is reported in the majority of patients with advanced pancreatic cancer (90%) and its palliation is often difficult [215]. About 15% of patients with inoperable PC, having dilated main pancreatic beyond the stricture and an “obstructive” pain related to meals, may potentially benefit from endoscopic pancreatic stenting [236]. It was reported that pancreatic stenting may be obtained in more than 80% of these selected patients, with low morbidity (less than 10%), and no procedure-related mortality; approximately 60% of patients treated because of “obstructive” pain become symptom-free, and another 20%–25% significantly reduce the amount of analgesic drugs. In the last years, a number of studies have shown that effective pain control can be achieved in 70%–90% of advanced PC with EUS-guided celiac plexus neurolysis (CPN) [48, 163, 163, 237-244]. Significant reduction of pain scores 12 weeks after CPN was observed in 30 patients with advanced intraabdominal malignancy, while 91% of these patients required same or less pain medication and 88% of patients had persistent improvement in their pain score [237]. In one retrospective analysis of response to CPN in a cohort 64 patients with PC, it was found that visualization of the celiac ganglia was the best predictor of response: patients with visible ganglia were >15 times more likely to respond [242]. The results of two meta-analyses (including 8 studies/283 patients and 5 studies/119 patients) showed that the pooled proportion of patients that experienced pain relief was 80.1% and 72.5% after alcohol-based EUS-CPN [163, 164]. In a recent randomized clinical trial of 96 patients with advanced pancreatic cancer who were randomly assigned to early EUS-guided CPN or to conventional pain management, greater pain relief and a tendency toward lower morphine consumption was observed in the EUS-guided CPN group at 3 months [240]. It was also demonstrated that EUS-guided CPN significantly reduced pain, at 4 and 8 weeks, and opioid consumption in comparison with opioids intake alone [241]. It was summarized that EUS-guided CPN is superior to analgesic therapy in reducing pain in patients with PC. The results of one study, including 50 patients with PC, showed that there were no differences

regarding the onset or duration of pain relief in comparison between central and bilateral alcohol injections in EUS-guided CPN [243]. Some authors found that EUS-direct celiac ganglia neurolysis is superior to conventional EUS-guided CPN in inducing pain relief, with a higher treatment response rate (73.5% vs 45.5%) and complete response rate (50.0% vs 18.2%) [244].

3.3. EUS-guided antitumor therapies

For a short time, the use of various EUS-guided antitumor treatments has been reported in patients with locally advanced PC. The efficacy of EUS-guided ethanol injection alone or in combination with paclitaxel in pancreatic cystic lesions was reported in several studies [245-250]. A pilot study reported the efficacy of EUS-guided ethanol lavage in 25 patients with different cystic pancreatic lesions, with no side effects or complications during follow-up [245]. It was found that EUS-guided ethanol lavage led to a greater reduction in cyst size compared to simple saline injection (43% vs 11%) and resulted in complete cyst ablation in 33% of cases (12 out of 36) [246]. Follow-up by CT scan at 2 years of patients who had obtained complete cyst ablation after treatment showed persistent resolution of pancreatic cystic lesions in 75% of cases [247]. Addition of paclitaxel to ethanol injection showed a greater treatment rate of pancreatic cystic lesions compared to ethanol alone, with observed complete resolution in 62% of patients after 1-year follow-up [248, 249]. In addition, the use of EUS-guided ethanol injection was reported also in a small number of patients with pancreatic insulinoma [251-253]. In 3/5 patients with insulinoma, EUS-guided ethanol injection was related with symptoms resolution and no complications [251]. The main potential problem of EUS-guided ethanol ablation is the risk of acute pancreatitis due to diffusion of alcohol outside the lesion into the main pancreatic duct and/or the pancreatic parenchyma [254].

EUS-fine needle injection (FNI) is a simple technique to deliver chemotherapeutic agents into tumoral tissue for the treatment of locally advanced pancreatic cancer [48]. The technical success rate of all the studies about EUS-FNI reached 100%, paralleling the ability of performing EUS-FNA for cytological diagnosis. The clinical outcome varied greatly according to the different chemical or biological agents being tested [255]. In the literature, there are few small-size studies reporting the safety and feasibility of direct injection of different agents in patients with PC. One study tested the safety and efficacy of FNI of allogeneic mixed lymphocyte culture in 8 patients with locally advanced PC [256]. The authors reported that the procedure was safe and two partial responses and one minor response were reported (median survival 13.2 months). In other study (n=21 patients with PC), assessing the effect of EUS-FNI of adenovirus ONYX-015 in combination with systemic gemcitabine reported 2 patients with partial regression and 2 with minor response, but 4 serious adverse events (2 sepsis and 2 duodenal perforations) [257]. In the pilot study (n=7) with EUS-FNI of immature dendritic cells (inductors of primary T-cell response against tumor antigens), there were 1 complete and 3 partial responses reported and no adverse events [258]. In a multicenter study (n=50), the effect of EUS-FNI of TNFerade (a replication-deficient adenovirus vector carrying the TNF- α gene) in combination with systemic fluorouracil was tested [259]. The investigators observed 1 complete response, 3 partial responses, and 12 patients with stable disease after treatment as additionally 7 patients became suitable for surgery. The safety, tolerability, and preliminary

efficacy of EUS-FNI of BC-819 (a DNA plasmid developed to target the expression of diphtheria-toxin gene under the control of H19 regulatory sequences) in combination with chemoradiotherapy was tested in 6 patients with PC – 3 of them showed partial response and the other 2 patients who were downstaged were able to undergo surgical resection [260]. It is summarized that direct intratumoral of various agents through FNI in patients with advanced PC is technically easy, safe and can induce tumor downstaging in some cases. The role of this method for cancer therapy will increase with the refinement of echoendoscopes, delivery systems, and novel local antitumor agents [261-263].

EUS-guided radiofrequency ablation (RFA) could be also used as an alternative procedure of treatment in unoperable patients with PC, but its translation into clinical practice has been restricted because of limited data and procedure-related risks [264]. The performance and effectiveness of EUS-guided RFA has been tested in several experimental studies, using porcine models [264-266]. In one study, the safety and efficacy of EUS-guided cryothermal ablation was assessed in 22 patients with locally advanced PC [267]. Using a newly developed cryotherm probe, combining radiofrequency with cryogenic cooling, the authors reported that the procedure was technically successful in 16 patients (72%) with a reduction in tumor size in 6 of them and well-tolerability [56]. It is summarized that EUS-guided cryothermal ablation is feasible in a subset of patients with locally advanced pancreatic cancer, but their safety and clinical outcome need to be investigated in future studies.

Brachytherapy is a useful method for local control of various malignant tumors, including pancreas [48, 215]. The placement of radioactive seeds allows steady radiation, leading to localized ablation and avoiding the radiation of normal tissues surrounding the malignant lesion. The feasibility, safety, and efficacy of EUS-guided implantation of iodine radioactive seeds in patients with locally advanced PC were assessed in a few studies [48, 268-270]. It was reported around 80% rate of positive response (decrease in tumor size) or stable disease, as well as improvements of pain scores and performance status scores. Adverse event rate was 0%–20%. Hematologic toxicity (neutropenia, thrombocytopenia, and anemia) was usually mild. Other complications reported less frequently were pancreatitis and pseudocyst formation. [268]. The studies demonstrated the technical feasibility of EUS-guided implantation of radioactive seeds in PC but larger studies evaluating the clinical outcome in a multimodality approach, combining chemotherapy and/or radiotherapy are needed [215, 238].

EUS-guided fiducial placement to facilitate stereotactic radiotherapy was assessed in several studies and was shown that it is a safe and precise, less invasive procedure [48, 215, 238, 271]. The placement of radiopaque fiducials inside or near the tumor allows performance of targeted radiotherapy with higher doses while sparing adjacent healthy tissue. Two studies of EUS-guided fiducial placement in a total of 101 patients with locally advanced PC reported high technical and clinical success rates (88%–90%) [272, 273]. Overall complication rate was low with only few minor adverse events (1 patient – a minor bleeding from the site of EUS needle entrance and 2 – mild pancreatitis). Migration of the gold fiducials was reported in 7% of cases. Another study observed no differences in visibility, migration, number of fiducial placement, technical difficulty, as well as in complication rate comparing two different types of fiducials (traditional vs coiled) [274].

In conclusion, today endoscopic therapy with or without EUS is an approved management option in selected patients with acute or chronic pancreatitis, or pancreatic cancer, showing the advantages of a minimally invasive method of treatment. It should be performed in specialized centers with an available multidisciplinary team.

Author details

Borislav Vladimirov^{1*}, Plamen Getzov² and Radina Ivanova³

*Address all correspondence to: borislavvladimirov@yahoo.com

1 Clinic of Gastroenterology, University Hospital Tz. Joanna, Medical University of Sofia, Bulgaria

2 Department of imaging diagnostics, University Hospital Tz. Joanna, Medical University of Sofia, Bulgaria

3 Laboratory of clinical pathology, University Hospital of Endocrinology, Medical University of Sofia, Bulgaria

References

- [1] Tenner S, Baillie J, DeWitt J, Vege SS, American College of Gastroenterology. American College of Gastroenterology guideline: management of acute pancreatitis. *Am J Gastroenterol* 2013;108(9):1400–1415.
- [2] Banks PA, Bollen TL, Dervenis C, Gooszen HG et al. Acute Pancreatitis Classification Working Group. Classification of acute pancreatitis – 2012: revision of the Atlanta classification and definitions by international consensus. *Gut* 2013;62(1):102–111.
- [3] Bahr MH, Davis BR, Vitale GC. Endoscopic management of acute pancreatitis. *Surg Clin North Am* 2013;93(3):563–584.
- [4] Zerem E. Treatment of severe acute pancreatitis and its complications. *World J Gastroenterol* 2014;20(38):13879–13892.
- [5] Werner J, Feuerbach S, Uhl W, Büchler MW. Management of acute pancreatitis: from surgery to interventional intensive care. *Gut* 2005;54:426–436.
- [6] Büchler MW, Gloor B, Müller CA et al. Acute necrotizing pancreatitis: treatment strategy according to the status of infection. *Ann Surg* 2000;232:619–626.
- [7] Acosta JM, Rubio Galli OM, Rossi R et al. Effect of duration of ampullary gallstone obstruction on severity of lesions of acute pancreatitis. *J Am Coll Surg* 1997;184:499–505.

- [8] Kelly TR. Gallstone pancreatitis: the timing of surgery. *Surgery* 1980;88:345–350.
- [9] Runkel NS, Buhr HJ, Herfarth C. Outcome after surgery for biliary pancreatitis. *Eur J Surg* 1996;162(4):307–313.
- [10] Beltsis A, Kapetanios D. Early ERCP in acute biliary pancreatitis: 20 years of dispute. *Ann Gastroenterol* 2010;23(1):27–30.
- [11] Kapetanios DJ. ERCP in acute biliary pancreatitis. *World J Gastrointest Endosc* 2010; (1):25–28.
- [12] Fan ST, Lai EC, Mok FP et al. Early treatment of acute biliary pancreatitis by endoscopic papillotomy. *N Engl J Med* 1993;328:228–232.
- [13] Fölsch UR, Nitsche R, Lüdtke R et al. Early ERCP and papillotomy compared with conservative treatment for acute biliary pancreatitis. The German Study Group on Acute Biliary Pancreatitis. *N Engl J Med* 1997;336:237–242.
- [14] Uhl W, Warshaw A, Imrie C et al. IAP guidelines for the surgical management of acute pancreatitis. *Pancreatology* 2002;2:565–573.
- [15] Neoptolemos JP, London NJ, James D et al. Controlled trial of urgent endoscopic retrograde cholangiopancreatography and endoscopic sphincterotomy versus conservative management for acute pancreatitis due to gallstones. *Lancet* 1988;3:979–983.
- [16] Neoptolemos JP, Carr-Locke DL, London N et al. ERCP findings and the role of endoscopic sphincterotomy in acute gallstone pancreatitis. *Br J Surg* 1988;75:954–960.
- [17] Nowak A, Nowakowska-Dulawa E, Marek T et al. Final results of the prospective, randomized, controlled study on endoscopic sphincterotomy versus conventional management in acute biliary pancreatitis. *Gastroenterology* 1995;108:A380.
- [18] Vladimirov B, Jaramov N, Grigorov N et al. Endoscopic versus conservative treatment of acute gallstone pancreatitis – early results and prevention of recurrence. *Gut* 2002;51(Suppl III):A246 (abstract).
- [19] Oria A, Cimmino D, Ocampo C et al. Early endoscopic intervention versus early conservative management in patients with acute gallstone pancreatitis and biliopancreatic obstruction: a randomized clinical trial. *Ann Surg* 2007;245:10–17.
- [20] Ayub K, Imada R, Slavin J. Endoscopic retrograde cholangiopancreatography in gallstone-associated acute pancreatitis. *Cochrane Database Syst Rev* 2004;CD003630.
- [21] Moretti A, Papi C, Aratari A et al. Is early endoscopic retrograde cholangiopancreatography useful in the management of acute biliary pancreatitis? A meta-analysis of randomized controlled trials. *Dig Liver Dis* 2008;40:379–385.
- [22] Petrov MS, van Santvoort HC, Besselink MG et al. Early endoscopic retrograde cholangiopancreatography versus conservative management in acute biliary pancreatitis

- without cholangitis: a meta-analysis of randomized trials. *Ann Surg* 2008;247:250–257.
- [23] Tse F, Yuan Y. Early routine endoscopic retrograde cholangiopancreatography strategy versus early conservative management strategy in acute gallstone pancreatitis. *Cochrane Database Syst Rev* 2012;5:CD009779.
- [24] Van Santvoort HC, Bakker OJ, Besselink MG et al. Prediction of common bile duct stones in the earliest stages of acute biliary pancreatitis. *Endoscopy* 2011;43(1):8–13.
- [25] Romagnuolo J, Bardou M, Rahme E et al. Magnetic resonance cholangiopancreatography: a meta-analysis of test performance in suspected biliary disease. *Ann Intern Med* 2003;139:547–557.
- [26] Garrow D, Miller S, Sinha D et al. Endoscopic ultrasound: a meta-analysis of test performance in suspected biliary obstruction. *Clin Gastroenterol Hepatol* 2007;5:616–623.
- [27] Stabuc B, Drobne D, Ferkolj I et al. Acute biliary pancreatitis: detection of common bile duct stones with endoscopic ultrasound. *Eur J Gastroenterol Hepatol* 2008 ; 20:1171–1175.
- [28] Ledro-Cano D. Suspected choledocholithiasis: endoscopic ultrasound or magnetic resonance cholangio-pancreatography? A systematic review. *Eur J Gastroenterol Hepatol* 2007;19:1007–1011.
- [29] Working Group IAP/APA Acute Pancreatitis Guidelines. IAP/APA evidence-based guidelines for the management of acute pancreatitis. *Pancreatology* 2013 Jul–Aug; 13(4 Suppl 2):e1–e15.
- [30] Nieuwenhuijs VB, Besselink MG, van Minnen LP, Gooszen HG. Surgical management of acute necrotizing pancreatitis: a 13-year experience and a systematic review. *Scand J Gastroenterol Suppl* 2003;(239):111–116.
- [31] van Baal MC, van Santvoort HC, Bollen TL et al. Systematic review of percutaneous catheter drainage as primary treatment for necrotizing pancreatitis. *Br J Surg* 2011;98:18–27.
- [32] Zerem E, Imamović G, Sušić A, Haračić B. Step-up approach to infected necrotising pancreatitis: a 20-year experience of percutaneous drainage in a single centre. *Dig Liver Dis* 2011;43:478–483.
- [33] Doctor N, Philip S, Gandhi V et al. Analysis of the delayed approach to the management of infected pancreatic necrosis. *World J Gastroenterol* 2011;17:366–371.
- [34] Mier J, León EL, Castillo A et al. Early versus late necrosectomy in severe necrotizing pancreatitis. *Am J Surg* 1997;173:71–75.
- [35] Besselink MG, Verwer TJ, Schoenmaeckers EJ et al. Timing of surgical intervention in necrotizing pancreatitis. *Arch Surg* 2007;142:1194–1201.

- [36] van Santvoort HC, Besselink MG, Bakker OJ et al. A step-up approach or open necrosectomy for necrotizing pancreatitis. *N Eng J Med* 2010;362:1491–1502.
- [37] Mukai S, Itoi T, Moriyasu F. Interventional endoscopy for the treatment of pancreatic pseudocyst and walled-off necrosis (with videos). *J Hepatobiliary Pancreat Sci* 2014;21(10):E75–E85.
- [38] Freeman ML, Werner J, van Santvoort HC et al. International multidisciplinary panel of speakers and moderators. Interventions for necrotizing pancreatitis: summary of a multidisciplinary consensus conference. *Pancreas* 2012;41(8):1176–1194.
- [39] Voermans RP1, Besselink MG, Fockens P. Endoscopic management of walled-off pancreatic necrosis. *J Hepatobiliary Pancreat Sci* 2015;22(1):20–26.
- [40] Baron TH, Kozarek RA. Endotherapy for organized pancreatic necrosis: perspectives after 20 years. *Clin Gastroenterol Hepatol* 2012;10(11):1202–1207.
- [41] Bakker OJ, van Santvoort HC, van Brunschot S et al. Endoscopic transgastric vs surgical necrosectomy for infected necrotizing pancreatitis: a randomized trial. *JAMA* 2012;307(10):1053–1061.
- [42] Haghshenas Kashani A, Laurence JM, Kwan V et al. Endoscopic necrosectomy of pancreatic necrosis: a systematic review. *Surg Endosc* 2011;25(12):3724–3730.
- [43] Puli SR, Graumlich JF, Pamulaparthi SR, Kalva N. Endoscopic transmural necrosectomy for walled-off pancreatic necrosis: a systematic review and meta-analysis. *Can J Gastroenterol Hepatol* 2014;28(1):50–53.
- [44] van Brunschot S, Fockens P, Bakker OJ et al. Endoscopic transluminal necrosectomy in necrotising pancreatitis: a systematic review. *Surg Endosc* 2014;28(5):1425–1438.
- [45] van Brunschot S, van Grinsven J, Voermans RP et al. Transluminal endoscopic step-up approach versus minimally invasive surgical step-up approach in patients with infected necrotising pancreatitis (TENSION trial): design and rationale of a randomised controlled multicenter trial [ISRCTN09186711]. *BMC Gastroenterol* 2013;13:161.
- [46] Bang JY, Varadarajulu S. Endoscopic ultrasound-guided management of pancreatic pseudocysts and walled-off necrosis. *Clin Endosc* 2014;47(5):429–431.
- [47] Baron TH, Thaggard WG, Morgan DE, Stanley RJ. Endoscopic therapy for organized pancreatic necrosis. *Gastroenterology* 1996;111:755–764.
- [48] Fabbri C, Luigiano C, Lisotti A et al. Endoscopic ultrasound-guided treatments: are we getting evidence based – a systematic review. *World J Gastroenterol* 2014;20(26):8424–8448.
- [49] Varadarajulu S, Phadnis MA, Christein JD, Wilcox CM. Multiple transluminal gateway technique for EUS-guided drainage of symptomatic walled-off pancreatic necrosis. *Gastrointest Endosc* 2011;74:74–80.

- [50] Abdelhafez M, Elnegouly M, Hasab Allah MS et al. Transluminal retroperitoneal endoscopic necrosectomy with the use of hydrogen peroxide and without external irrigation: a novel approach for the treatment of walled off pancreatic necrosis. *Surg Endosc* 2013;27:3911–3920.
- [51] Siddiqui A, Easler J, Strongin A et al. Hydrogen peroxide-assisted endoscopic necrosectomy for walled-off pancreatic necrosis: a dual center pilot experience. *Dig Dis Sci* 2014;59:687–690.
- [52] Itoi T, Binmoeller KF, Shah J et al. Clinical evaluation of a novel lumen-apposing metal stent for endosonography-guided pancreatic pseudocyst and gallbladder drainage (with videos). *Gastrointest Endosc* 2012;75:870–876.
- [53] Yamamoto N, Isayama H, Kawakami H et al. Preliminary report on a new, fully covered, metal stent designed for the treatment of pancreatic fluid collections. *Gastrointest Endosc* 2013;77:809–814.
- [54] Moon JH, Choi HJ, Kim DC et al. A newly designed fully covered metal stent for lumen apposition in EUS-guided drainage and access: a feasibility study (with videos). *Gastrointest Endosc* 2014;79:990–995.
- [55] Papachristou GI, Takahashi N, Chahal P et al. Peroral endoscopic drainage/debridement of walled-off pancreatic necrosis. *Ann Surg* 2007;245:943–951.
- [56] Gardner TB, Coelho-Prabhu N, Gordon SR et al. Direct endoscopic necrosectomy for the treatment of walled-off pancreatic necrosis: results from a multicenter US series. *Gastrointest Endosc* 2011;73:718–726.
- [57] Klöppel G. Pseudocyst and other non-neoplastic cyst of the pancreas. *Semin Diagn Pathol* 2000;17:7–15.
- [58] O'Malley VP, Cannon JP, Postier RG. Pancreatic pseudocysts: cause, therapy and results. *Am J Surg* 1985;150:680–2.
- [59] Kozarek RA, Ball TJ, Patterson DJ et al. Endoscopic transpapillary therapy for disrupted pancreatic duct and peripancreatic fluid collections. *Gastroenterology* 1991;100:1362–1370.
- [60] Varadarajulu S, Noone TC, Tutuian R et al. Predictors of outcome in pancreatic duct disruption managed by endoscopic transpapillary stent placement. *Gastrointest Endosc* 2005;61:568–575.
- [61] Lawrence C, Howell DA, Stefan AM et al. Disconnected pancreatic tail syndrome: potential for endoscopic therapy and results of long-term follow-up. *Gastrointest Endosc* 2008;67:673–679.
- [62] Telford JJ, Farrell JJ, Saltzman JR et al. Pancreatic stent placement for duct disruption. *Gastrointest Endosc* 2002;56:18–24.

- [63] Al-Haddad M, Wallace MB. Diagnostic approach to patients with acute idiopathic pancreatitis, what should be done? *World J Gastroenterol* 2008;14:1007–1010.
- [64] Kedia S, Dhingra R, Garg PK. Recurrent acute pancreatitis: an approach to diagnosis and management. *Trop Gastroenterol* 2013;34(3):123–135.
- [65] Testoni PA. Acute recurrent pancreatitis: etiopathogenesis, diagnosis and treatment. *World J Gastroenterol* 2014;20(45):16891–16901.
- [66] Lans JJ, Geenen JE, Johanson JF, Hogan WJ. Endoscopic therapy in patients with pancreas divisum and acute pancreatitis: a prospective, randomized, controlled clinical trial. *Gastrointest Endosc* 1992;38:430–434.
- [67] Liao Z, Gao R, Wang W et al. A systematic review on endoscopic detection rate, endotherapy, and surgery for pancreas divisum. *Endoscopy* 2009;41:439–444.
- [68] Katsinelos P, Paroutoglou G, Chatzimavroudis G et al. Endoscopic sphincterotomy for acute relapsing pancreatitis associated with periampullary diverticula: a long-term follow-up. *Acta Gastroenterol Belg* 2007;70(2):195–8.
- [69] Simpson WF, Adams DB, Metcalf JS et al. Nonfunctioning pancreatic neuroendocrine tumors presenting as pancreatitis: report of four cases. *Pancreas* 1988;3:223–231.
- [70] Kohler H, Lankisch PG. Acute pancreatitis and hyperamylasaemia in pancreatic carcinoma. *Pancreas* 1987;2:117–119.
- [71] Robertson JF, Imrie CW. Acute pancreatitis associated with carcinoma of the ampulla of Vater. *Br J Surg* 1987;74:395–397.
- [72] Bank S, Indaram A. Causes of acute and recurrent pancreatitis. Clinical considerations and clues to diagnosis. *Gastroenterol Clin North Am* 1999;28:571–589.
- [73] Attasaranya S, Abdel Aziz AM, Lehman GA. Endoscopic management of acute and chronic pancreatitis. *Surg Clin North Am* 2007;87:1379–402.
- [74] Adler DG, Baron TH, Davila RE et al. ASGE guideline: the role of ERCP in disease of the biliary tract and the pancreas. *Gastrointest Endosc* 2005;62(1):1–8.
- [75] Tarnasky PR, Palesch YY, Cunningham JT et al. Pancreatic stenting prevents pancreatitis after biliary sphincterotomy in patients with sphincter of Oddi dysfunction. *Gastroenterology* 1998;115:1518–24.
- [76] Hall TC, Dennison AR, Garcea G. The diagnosis and management of Sphincter of Oddi dysfunction: a systematic review. *Langenbecks Arch Surg* 2012;397:889–898.
- [77] Heetun ZS, Zeb F, Cullen G et al. Biliary sphincter of Oddi dysfunction: response rates after ERCP and sphincterotomy in a 5-year ERCP series and proposal for new practical guidelines. *Eur J Gastroenterol Hepatol* 2011;23:327–333.

- [78] Cote GA, Imperiale TF, Schmidt SE et al. Similar effects of biliary, with or without pancreatic, sphincterotomy in treatment of idiopathic recurrent acute pancreatitis. *Gastroenterology* 2012;143:1502–1509.
- [79] Bradley EL. Long term results of pancreaticojejunostomy in patients with chronic pancreatitis. *Am J Surg* 1987;153:207–213.
- [80] Cremer M, Devière J, Delhaye M et al. Stenting in severe chronic pancreatitis: results of medium term follow-up in seventy-six patients. *Endoscopy* 1991;23:171–176.
- [81] Schnellendorfer T, Lewin DN, Adams DB. Operative management of chronic pancreatitis: longterm results in 372 patients. *J Am Coll Surg* 2007;204:1039–1045.
- [82] Rösch T, Daniel S, Scholz M et al. Endoscopic treatment of chronic pancreatitis: a multicenter study of 1000 patients with long-term follow-up. *Endoscopy* 2002;34:765–771.
- [83] Tandan M, Reddy D N. Endotherapy in chronic pancreatitis. *World J Gastroenterol* 2013;19(37):6156–6164.
- [84] Boustière C, Veitch A, Vanbiervliet G et al. Endoscopy and antiplatelet agents. European Society of Gastrointestinal Endoscopy (ESGE) Guideline. *Endoscopy* 2011;43:445–461.
- [85] Tringali A, Boskoski I, Costamagna G. The role of endoscopy in the therapy of chronic pancreatitis. *Best Pract Res Clin Gastroenterol* 2008;22:145–165.
- [86] Dumonceau JM, Delhaye M, Tringali A et al. Endoscopic treatment of chronic pancreatitis: European Society of Gastrointestinal Endoscopy (ESGE) Clinical Guideline. *Endoscopy* 2012;44(8):784–800.
- [87] Yoo BM, Lehman GA. Update on endoscopic treatment of chronic pancreatitis. *Korean J Intern Med* 2009;24(3):169–179.
- [88] de-Madaria E, Abad-González A, Aparicio JR et al. The Spanish Pancreatic Club's recommendations for the diagnosis and treatment of chronic pancreatitis: part 2 (treatment). *Pancreatology* 2013;13(1):18–28.
- [89] Frulloni L, Falconi M, Gabbrielli A et al. Italian consensus guidelines for chronic pancreatitis. *Dig Liver Dis* 2010;42 Suppl 6:S381–S406.
- [90] Choi EK, Lehman GA. Update on endoscopic management of main pancreatic duct stones in chronic calcific pancreatitis. *Korean J Intern Med* 2012;27(1):20–9.
- [91] Vladimirov B, Mitova R, Grigorov N, Damjanov D, Korukov B, Parvanov P. Endoscopic versus conventional conservative therapy in chronic pancreatitis. Second Congress of Serbian gastroenterologists with international participation. 1–2.09.2011, Belgrade, *Arch. Gastroenterohepatology*, p.117.

- [92] Díte P, Ruzicka M, Zboril V, Novotný I. A prospective, randomized trial comparing endoscopic and surgical therapy for chronic pancreatitis. *Endoscopy* 2003;35(7):553–558.
- [93] Cahen DL, Gouma DJ, Nio Y et al. Endoscopic versus surgical drainage of the pancreatic duct in chronic pancreatitis. *N Engl J Med* 2007;356(7):676–684.
- [94] Cahen DL, Gouma DJ, Laramée P et al. Long-term outcomes of endoscopic vs surgical drainage of the pancreatic duct in patients with chronic pancreatitis. *Gastroenterology* 2011;141(5):1690–1695.
- [95] Binmoeller KF, Jue P, Seifert H et al. Endoscopic pancreatic stent drainage in chronic pancreatitis and a dominant stricture: long-term results. *Endoscopy* 1995;27:638–644.
- [96] Delhaye M, Arvanitakis M, Verset G et al. Long-term clinical outcome after endoscopic pancreatic ductal drainage for patients with painful chronic pancreatitis. *Clin Gastroenterol Hepatol* 2004;2:1096–1106.
- [97] Tadenuma H, Ishihara T, Yamaguchi T et al. Long-term results of extracorporeal shockwave lithotripsy and endoscopic therapy for pancreatic stones. *Clin Gastroenterol Hepatol* 2005;3:1128–1135.
- [98] Inui K, Tazuma S, Yamaguchi T et al. Treatment of pancreatic stones with extracorporeal shock wave lithotripsy: results of a multicenter survey. *Pancreas* 2005;30:26–30.
- [99] Farnbacher MJ, Mühldorfer S, Wehler M et al. Interventional endoscopic therapy in chronic pancreatitis including temporary stenting: a definitive treatment? *Scand J Gastroenterol* 2006;41:111–117.
- [100] Diener MK, Rahbari NN, Fischer L et al. Duodenum-preserving pancreatic head resection versus pancreatoduodenectomy for surgical treatment of chronic pancreatitis: a systematic review and meta-analysis. *Ann Surg* 2008;247:950–961.
- [101] Tandan M, Reddy DN, Santosh D et al. Extracorporeal shock wave lithotripsy and endotherapy for pancreatic calculi – a large single center experience. *Indian J Gastroenterol* 2010;29:143–148.
- [102] Hookey LC, RioTinto R, Delhaye M et al. Risk factors for pancreatitis after pancreatic sphincterotomy: a review of 572 cases. *Endoscopy* 2006;38:670–676.
- [103] Dumonceau J-M, Andriulli A, Deviere J et al. European Society of Gastrointestinal Endoscopy (ESGE) guideline: prophylaxis of post-ERCP pancreatitis. *Endoscopy* 2010;42:503–515.
- [104] Morgan DE, Smith JK, Hawkins K, Wilcox CM. Endoscopic stent therapy in advanced chronic pancreatitis: relationships between ductal changes, clinical response, and stent patency. *Am J Gastroenterol* 2003;98:821–826.

- [105] Eleftherladis N, Dinu F, Delhaye M et al. Long-term outcome after pancreatic stenting in severe chronic pancreatitis. *Endoscopy* 2005;37:223–230.
- [106] Vitale GC, Cothron K, Vitale EA et al. Role of pancreatic duct stenting in the treatment of chronic pancreatitis. *Surg Endosc* 2004;18:1431–1434.
- [107] Ishihara T, Yamaguchi T, Seza K et al. Efficacy of s-type stents for the treatment of the main pancreatic duct stricture in patients with chronic pancreatitis. *Scand J Gastroenterol* 2006;41:744–750.
- [108] Weber A, Schneider J, Neu B et al. Endoscopic stent therapy for patients with chronic pancreatitis: results from a prospective follow-up study. *Pancreas* 2007;34:287–294.
- [109] Brand B, Kahl M, Sidhu S et al. Prospective evaluation of morphology, function, and quality of life after extracorporeal shockwave lithotripsy and endoscopic treatment of chronic calcific pancreatitis. *Am J Gastroenterol* 2000;95:3428–3438.
- [110] Dumonceau JM, Devière J, Le Moine O et al. Endoscopic pancreatic drainage in chronic pancreatitis associated with ductal stones: long term results. *Gastrointest Endosc* 1996;43:547–555.
- [111] Dumonceau J-M, Costamagna G, Tringali A et al. Treatment for painful calcified chronic pancreatitis: extracorporeal shock wave lithotripsy versus endoscopic treatment: a randomised controlled trial. *Gut* 2007;56:545–552.
- [112] Gabbrielli A, Mutignani M, Pandolfi M et al. Endotherapy of early onset idiopathic chronic pancreatitis: results with long-term follow-up. *Gastrointest Endosc* 2002;55:488–493.
- [113] Ell C, Rabenstein T, Schneider HT, Ruppert T et al. Safety and efficacy of pancreatic sphincterotomy in chronic pancreatitis. *Gastrointest Endosc* 1998;48:244–249.
- [114] Papachristou GI, Baron TH. Complication of therapeutic endoscopic retrograde cholangiopancreatography. *Gut* 2007;56:854–868.
- [115] Varadarajulu S, Wilcox CM. Randomized trial comparing needle-knife and pull-sphincterotome techniques for pancreatic sphincterotomy in high-risk patients. *Gastrointest Endosc* 2006;64:716–722.
- [116] Kozarek RA, Ball TJ, Patterson DJ et al. Endoscopic pancreatic duct sphincterotomy: indications, technique, and analysis of results. *Gastrointest Endosc* 1994;40:592–598.
- [117] Siegel JH, Cohen SA. Pull or push pancreatic sphincterotomy for sphincter of Oddi dysfunction? A conundrum for experts only. *Gastrointest Endosc* 2006;64:723–725.
- [118] Ong WC, Tandan M, Reddy V et al. Multiple main pancreatic duct stones in tropical pancreatitis: safe clearance with extracorporeal shockwave lithotripsy. *J Gastroenterol Hepatol* 2006;21:1514–1518.

- [119] Lehman GA. Role of ERCP and other endoscopic modalities in chronic pancreatitis. *Gastrointest Endosc* 2002;56: S237–S240.
- [120] Green JE, Vennes JA, Silvis SE. Resume of a seminar on endoscopic retrograde sphincterotomy (ERS). *Gastrointest Endosc* 1981;27:31–38.
- [121] Adler DG, Lichtenstein D, Baron TH et al. The role of endoscopy in patients with chronic pancreatitis. *Gastrointest Endosc* 2006;63:933–937.
- [122] Costamagna G, Gabbrielli A, Mutignani M et al. Extracorporeal shock wave lithotripsy of pancreatic stones in chronic pancreatitis: immediate and medium-term results. *Gastrointest Endosc* 1997;46:231–236.
- [123] Smits ME, Rauws EA, Tytgat GN, Huibregtse K. Endoscopic treatment of pancreatic stones in patients with chronic pancreatitis. *Gastrointest Endosc* 1996;43:556–560.
- [124] Delhaye M, Vandermeeren A, Baize M, Cremer M. Extracorporeal shock-wave lithotripsy of pancreatic calculi. *Gastroenterology* 1992;102:610–620.
- [125] Farnbacher MJ, Schoen C, Rabenstein T et al. Pancreatic duct stones in chronic pancreatitis: criteria for treatment intensity and success. *Gastrointest Endosc* 2002;56:501–506.
- [126] Thomas M, Howell DA, Carr-Locke D et al. Mechanical lithotripsy of pancreatic and biliary stones: complications and available treatment options collected from expert centers. *Am J Gastroenterol* 2007;102:1896–1902.
- [127] Maydeo A, Bhandari S, Bapat M. Endoscopic balloon sphincteroplasty for extraction of large radiolucent pancreatic duct stones (with videos). *Gastrointest Endosc* 2009;70:798–802.
- [128] Guda NM, Partington S, Freeman ML. Extracorporeal shock wave lithotripsy in the management of chronic calcific pancreatitis: a meta-analysis. *JOP* 2005;6:6–12.
- [129] Nguyen-Tang T, Dumonceau JM. Endoscopic treatment in chronic pancreatitis, timing, duration and type of intervention. *Best Pract Res Clin Gastroenterol* 2010;24:281–298.
- [130] Maydeo A, Soehendra N, Reddy N, Bhandari S. Endotherapy for chronic pancreatitis with intracanalicular stones. *Endoscopy* 2007;39:653–658.
- [131] Ohara H, Hoshino M, Hayakawa T et al. Single application extracorporeal shock wave lithotripsy is the first choice for patients with pancreatic duct stones. *Am J Gastroenterol* 1996;91:1388–1394.
- [132] Adamek HE, Jakobs R, Buttman A et al. Long term follow up of patients with chronic pancreatitis and pancreatic stones treated with extracorporeal shock wave lithotripsy. *Gut* 1999;45:402–405.

- [133] Karakayali F, Sevmis S, Ayvaz I et al. Acute necrotizing pancreatitis as a rare complication of extracorporeal shock wave lithotripsy. *Int J Urol* 2006;13:613–615.
- [134] Platonov MA, Gillis AM, Kavanagh KM. Pacemakers, implantable cardioverter/defibrillators, and extracorporeal shockwave lithotripsy: evidence-based guidelines for the modern era. *J Endourol* 2008;22:243–247.
- [135] Hirai T, Goto H, Hirooka Y et al. Pilot study of pancreatoscopic lithotripsy using a 5-fr instrument: selected patients may benefit. *Endoscopy* 2004;36:212–216.
- [136] Howell DA, Dy RM, Hanson BL et al. Endoscopic treatment of pancreatic duct stones using a 10F pancreatoscope and electrohydraulic lithotripsy. *Gastrointest Endosc* 1999;50:829–833.
- [137] van der Hul R, Plaisier P, Jeekel J et al. Extracorporeal shock-wave lithotripsy of pancreatic duct stones: immediate and long-term results. *Endoscopy* 1994;26:573–578.
- [138] Sauerbruch T, Holl J, Sackmann M, Paumgartner G. Extracorporeal lithotripsy of pancreatic stones in patients with chronic pancreatitis and pain: a prospective follow up study. *Gut* 1992;33:969–972.
- [139] Schneider HT, May A, Benninger J et al. Piezoelectric shock wave lithotripsy of pancreatic duct stones. *Am J Gastroenterol* 1994;89:2042–2048.
- [140] Delhaye M, Matos C, Devière J. Endoscopic technique for the management of pancreatitis and its complications. *Best Pract Res Clin Gastroenterol* 2004;18:155–181.
- [141] Sauer BG, Gurka MJ, Ellen K et al. Effect of pancreatic duct stent diameter on hospitalization in chronic pancreatitis: does size matter? *Pancreas* 2009;38:728–731.
- [142] Ponchon T, Bory RM, Hedelius F et al. Endoscopic stenting for pain relief in chronic pancreatitis: results of a standardized protocol. *Gastrointest Endosc* 1995;42:452–456.
- [143] Smits ME, Badiga SM, Rauws EA et al. Long-term results of pancreatic stents in chronic pancreatitis. *Gastrointest Endosc* 1995;42:461–467.
- [144] Boursier J, Quentin V, Le Tallec V et al. Endoscopic treatment of painful chronic pancreatitis: evaluation of a new flexible multiperforated plastic stent. *Gastroenterol Clin Biol* 2008;32:801–805.
- [145] Costamagna G, Bulajic M, Tringali A et al. Multiple stenting of refractory pancreatic duct strictures in severe chronic pancreatitis: long-term results. *Endoscopy* 2006;38:254–259.
- [146] Faigel DO, Eisen GM, Baron TH et al. Tissue sampling and analysis. *Gastrointest Endosc* 2003;57:811–816.
- [147] Smith MT, Sherman S, Ikenberry SO et al. Alterations in pancreatic ductal morphology following polyethylene pancreatic stent therapy. *Gastrointest Endosc* 1996;44:268–275.

- [148] Sherman S, Hawes RH, Savides TJ et al. Stent-induced pancreatic ductal and parenchymal changes: correlation of endoscopic ultrasound with ERCP. *Gastrointest Endosc* 1996;44:276–282.
- [149] Raju GS, Gomez G, Xiao SY et al. Effect of a novel pancreatic stent design on short-term pancreatic injury in a canine model. *Endoscopy* 2006;38:260–265.
- [150] Eisendrath P, Deviere J. Expandable metal stents for benign pancreatic duct obstruction. *Gastrointest Endosc Clin N Am* 1999;9:547–554.
- [151] Park DH, Kim M-H, Moon S-H et al. Feasibility and safety of placement of a newly designed, fully covered self-expandable metal stent for refractory benign pancreatic ductal strictures: a pilot study (with video). *Gastrointest Endosc* 2008;68:1182–1189.
- [152] Moon S-H, Kim M-H, Park DH et al. Modified fully covered self-expandable metal stents with antimigration features for benign pancreatic duct strictures in advanced chronic pancreatitis, with a focus on the safety profile and reducing migration. *Gastrointest Endosc* 2010;72:86–91.
- [153] Tessier G, Bories E, Arvanitakis M et al. EUS-guided pancreatogastrostomy and pancreatobulbostomy for the treatment of pain in patients with pancreatic ductal dilatation inaccessible for transpapillary endoscopic therapy. *Gastrointest Endosc* 2007;65:233–241.
- [154] Kahaleh M, Hernandez AJ, Tokar J et al. EUS-guided pancreaticogastrostomy: analysis of its efficacy to drain inaccessible pancreatic ducts. *Gastrointest Endosc* 2007;65:224–230.
- [155] Brauer BC, Chen YK, Fukami N, Shah RJ. Single-operator EUS-guided cholangiopancreatography for difficult pancreaticobiliary access (with video). *Gastrointest Endosc* 2009;70:471–479.
- [156] François E, Kahaleh M, Giovannini M et al. EUS-guided pancreaticogastrostomy. *Gastrointest Endosc* 2002;56:128–133.
- [157] Mallery S, Matlock J, Freeman ML. EUS-guided rendezvous drainage of obstructed biliary and pancreatic ducts: report of 6 cases. *Gastrointest Endosc* 2004;59:100–107.
- [158] Will U, Fueeldner F, Thieme A-K et al. Transgastric pancreatography and EUS-guided drainage of the pancreatic duct. *J Hepatobiliary Pancreat Surg* 2007;14:377–382.
- [159] Michaels AJ, Draganov PV. Endoscopic ultrasonography guided celiac plexus neurolysis and celiac plexus block in the management of pain due to pancreatic cancer and chronic pancreatitis. *World J Gastroenterol* 2007;13:3575–3580.
- [160] LeBlanc JK, DeWitt J, Johnson C et al. A prospective randomized trial of 1 versus 2 injections during EUS-guided celiac plexus block for chronic pancreatitis pain. *Gastrointest Endosc* 2009;69:835–842.

- [161] Stevens T, Costanzo A, Lopez R et al. Adding triamcinolone to endoscopic ultrasound-guided celiac plexus blockade does not reduce pain in patients with chronic pancreatitis. *Clin Gastroenterol Hepatol* 2012;10:186–191.
- [162] Pateman J, Williams MP, Filshie J. Retroperitoneal fibrosis after multiple coeliac plexus blocks. *Anaesthesia* 1990;45:309–310.
- [163] Puli SR, Reddy JBK, Bechtold ML et al. EUS-guided celiac plexus neurolysis for pain due to chronic pancreatitis or pancreatic cancer pain: a meta-analysis and systematic review. *Dig Dis Sci* 2009;54:2330–2337.
- [164] Kaufman M, Singh G, Das S et al. Efficacy of endoscopic ultrasound guided celiac plexus block and celiac plexus neurolysis for managing abdominal pain associated with chronic pancreatitis and pancreatic cancer. *J Clin Gastroenterol* 2010;44:127–134.
- [165] Gress F, Schmitt C, Sherman S et al. Endoscopic ultrasound-guided celiac plexus block for managing abdominal pain associated with chronic pancreatitis: a prospective single center experience. *Am J Gastroenterol* 2001;96:409–416.
- [166] Gress F, Schmitt C, Sherman S et al. A prospective randomized comparison of endoscopic ultrasound- and computed tomography-guided celiac plexus block for managing chronic pancreatitis pain. *Am J Gastroenterol* 1999;94:900–905.
- [167] Santosh D, Lakhtakia S, Gupta R et al. Clinical trial: a randomized trial comparing fluoroscopy guided percutaneous technique vs. endoscopic ultrasound guided technique of coeliac plexus block for treatment of pain in chronic pancreatitis. *Aliment Pharmacol Ther* 2009;29:979–984.
- [168] Sett SS, Taylor DC. Aortic pseudoaneurysm secondary to celiac plexus block. *Ann Vasc Surg* 1991;5:88–91.
- [169] Davies DD. Incidence of major complications of neurolytic coeliac plexus block. *J R Soc Med* 1993;86:264–266.
- [170] Sahai AV, Lemelin V, Lam E, Paquin SC. Central vs. bilateral endoscopic ultrasound-guided celiac plexus block or neurolysis: a comparative study of short-term effectiveness. *Am J Gastroenterol* 2009;104:326–329.
- [171] Levy MJ, Topazian MD, Wiersema MJ et al. Initial evaluation of the efficacy and safety of endoscopic ultrasound-guided direct ganglia neurolysis and block. *Am J Gastroenterol* 2008;103:98–103.
- [172] O'Toole TM, Schmulewitz N. Complication rates of EUS guided celiac plexus blockade and neurolysis: results of a large case series. *Endoscopy* 2009;41:593–597.
- [173] Habashi S, Draganov PV. Pancreatic pseudocyst. *World J Gastroenterol* 2009;15:38–47.
- [174] Andrén-Sandberg A, Dervenis C. Pancreatic pseudocysts in the 21st century. Part II: natural history. *JOP* 2004;5:64–70.

- [175] Talar-Wojnarowska R, Wozniak B, Pazurek M, Malecka-Panas E. Outcome of pseudocysts complicating chronic pancreatitis. *Hepatogastroenterology* 2010;57:631–634.
- [176] Cheruvu CV, Clarke MG, Prentice M, Eyre-Brook IA. Conservative treatment as an option in the management of pancreatic pseudocyst. *Ann R Coll Surg Engl* 2003;85:313–316.
- [177] Gouyon B, Lévy P, Ruszniewski P et al. Predictive factors in the outcome of pseudocysts complicating alcoholic chronic pancreatitis. *Gut* 1997;41:821–825.
- [178] Yeo CJ, Bastidas JA, Lynch-Nyhan A et al. The natural history of pancreatic pseudocysts documented by computed tomography. *Surg Gynecol Obstet* 1990;170:411–417.
- [179] Lerch MM, Stier A, Wahnschaffe U et al. Pancreatic pseudocysts: observation, endoscopic drainage, or resection? *Dtsch Arztebl Int* 2009;106:614–621.
- [180] Barkin JS, Hyder SA. Changing concepts in the management of pancreatic pseudocysts. *Gastrointest Endosc* 1989;35:62–64.
- [181] Baron TH, Harewood GC, Morgan DE et al. Outcome differences after endoscopic drainage of pancreatic necrosis, acute pancreatic pseudocysts, and chronic pancreatic pseudocysts. *Gastrointest Endosc* 2002;6:7–17.
- [182] Barthet M, Lamblin G, Gasmi M et al. Clinical usefulness of a treatment algorithm for pancreatic pseudocysts. *Gastrointest Endosc* 2008;67:245–252.
- [183] Cremer M, Deviere J, Engelholm L. Endoscopic management of cysts and pseudocysts in chronic pancreatitis: long-term follow-up after 7 years of experience. *Gastrointest Endosc* 1989;35:1–9.
- [184] Cahen D, Rauws E, Fockens P et al. Endoscopic drainage of pancreatic pseudocysts: long-term outcome and procedural factors associated with safe and successful treatment. *Endoscopy* 2005;37:977–983.
- [185] Arvanitakis M, Delhaye M, Bali MA et al. Pancreatic-fluid collections: a randomized controlled trial regarding stent removal after endoscopic transmural drainage. *Gastrointest Endosc* 2007;65:609–619.
- [186] Balachandra S, Siriwardena AK. Systematic appraisal of the management of the major vascular complications of pancreatitis. *Am J Surg* 2005;190:489–495.
- [187] Sanchez Cortes E, Maalak A, Le Moine O et al. Endoscopic cystenterostomy of non-bulging pancreatic fluid collections. *Gastrointest Endosc* 2002;56:380–386.
- [188] Park DH, Lee SS, Moon S-H et al. Endoscopic ultrasound-guided versus conventional transmural drainage for pancreatic pseudocysts: a prospective randomized trial. *Endoscopy* 2009;41:842–848.

- [189] Hookey LC, Debroux S, Delhaye M et al. Endoscopic drainage of pancreatic fluid collections in 116 patients: a comparison of etiologies, drainage techniques, and outcomes. *Gastrointest Endosc* 2006;63:635–643.
- [190] Kahaleh M, Shami VM, Conaway MR et al. Endoscopic ultrasound drainage of pancreatic pseudocyst: a prospective comparison with conventional endoscopic drainage. *Endoscopy* 2006;38:355–359.
- [191] Banerjee S, Shen B, Baron TH et al. Antibiotic prophylaxis for GI endoscopy. *Gastrointest Endosc* 2008;67:791–798.
- [192] Rosso E, Alexakis N, Ghaneh P et al. Pancreatic pseudocyst in chronic pancreatitis: endoscopic and surgical treatment. *Dig Surg* 2003;20:397–406.
- [193] Varadarajulu S, Lopes TL, Wilcox CM et al. EUS versus surgical cyst-gastrostomy for management of pancreatic pseudocysts. *Gastrointest Endosc* 2008;68:649–655.
- [194] Varadarajulu S, Bang JY, Sutton BS et al. Equal efficacy of endoscopic and surgical cystogastrostomy for pancreatic pseudocyst drainage in a randomized trial. *Gastroenterology* 2013;145:583–590.
- [195] Binmoeller KF, Seifert H, Walter A et al. Transpapillary and transmural drainage of pancreatic pseudocysts. *Gastrointest Endosc* 1995;42:219–224.
- [196] Beckingham IJ, Krige JE, Bornman PC et al. Endoscopic management of pancreatic pseudocysts. *Br J Surg* 1997;84:1638–1645.
- [197] Frey CF, Suzuki M, Isaji S. Treatment of chronic pancreatitis complicated by obstruction of the common bile duct or duodenum. *World J Surg* 1990;14:59–69.
- [198] Kahaleh M, Behm B, Clarke BW et al. Temporary placement of covered self-expandable metal stents in benign biliary strictures: a new paradigm? (with video) *Gastrointest Endosc* 2008;67:446–454.
- [199] Mahajan A, Ho H, Sauer B et al. Temporary placement of fully covered self-expandable metal stents in benign biliary strictures: midterm evaluation (with video). *Gastrointest Endosc* 2009;70:303–309.
- [200] Siiki A, Helminen M, Sand J, Laukkarinen J. Covered self-expanding metal stents may be preferable to plastic stents in the treatment of chronic pancreatitis-related biliary strictures: a systematic review comparing 2 methods of stent therapy in benign biliary strictures. *J Clin Gastroenterol* 2014;48(7):635–643.
- [201] Kahl S, Zimmermann S, Genz I et al. Risk factors for failure of endoscopic stenting of biliary strictures in chronic pancreatitis: a prospective follow-up study. *Am J Gastroenterol* 2003;98:2448–2453.
- [202] Catalano MF, Linder JD, George S et al. Treatment of symptomatic distal common bile duct stenosis secondary to chronic pancreatitis: comparison of single vs. multiple simultaneous stents. *Gastrointest Endosc* 2004;60:945–952.

- [203] Farnbacher MJ, Rabenstein T, Ell C et al. Is endoscopic drainage of common bile duct stenoses in chronic pancreatitis up-to-date? *Am J Gastroenterol* 2000;95:1466–1471.
- [204] Vitale GC, Reed DN Jr, Nguyen CT et al. Endoscopic treatment of distal bile duct stricture from chronic pancreatitis. *Surg Endosc* 2000;14:227–231.
- [205] Hammel P, Couvelard A, O'Toole D et al. Regression of liver fibrosis after biliary drainage in patients with chronic pancreatitis and stenosis of the common bile duct. *N Engl J Med* 2001;344:418–423.
- [206] Barthet M, Bernard JP, Duval JL et al. Biliary stenting in benign biliary stenosis complicating chronic calcifying pancreatitis. *Endoscopy* 1994;26:569–572.
- [207] Tabibian J, Asham E, Goldstein L et al. Endoscopic treatment with multiple stents for post-liver-transplantation nonanastomotic biliary strictures. *Gastrointest Endosc* 2009;69:1236–1243.
- [208] Kiehne K, Fölsch UR, Nitsche R. High complication rate of bile duct stents in patients with chronic alcoholic pancreatitis due to noncompliance. *Endoscopy* 2000;32:377–380.
- [209] Cahen DL, Rauws EA, Gouma DJ et al. Removable fully covered self-expandable metal stents in the treatment of common bile duct strictures due to chronic pancreatitis: a case series. *Endoscopy* 2008;40:697–700.
- [210] Behm B, Brock A, Clarke BW et al. Partially covered self-expandable metallic stents for benign biliary strictures due to chronic pancreatitis. *Endoscopy* 2009;41:547–551.
- [211] van Berkel AM, Cahen DL, van Westerlo DJ et al. Self-expanding metal stents in benign biliary strictures due to chronic pancreatitis. *Endoscopy* 2004;36:381–384.
- [212] Deviere JM, Reddy DN, Puspok A et al. Preliminary results from a 187 patient multicenter prospective trial using metal stents for treatment of benign biliary strictures. *Gastrointest Endosc* 2012;75: AB123.
- [213] Avula H, Sherman S. What is the role of endotherapy in chronic pancreatitis? *Therap Adv Gastroenterol* 2010;3:367–382.
- [214] Maire F, Sauvanet A. Palliation of biliary and duodenal obstruction in patients with unresectable pancreatic cancer: endoscopy or surgery? *J Visc Surg* 2013;150(3 Suppl):S27–S31.
- [215] Madrigal E, Chennat J. Endoscopic Management of Pancreatic Cancer: from Diagnosis to Palliative Therapy. In: Srivastava S. (ed.) *Pancreatic Cancer – Clinical Management*, Rijeka: InTech, 2012, pp. 213–236.
- [216] Artifon ELA, Sakai P, Cunha JEM et al. Surgery or endoscopy for palliation of biliary obstruction due to metastatic pancreatic cancer. *Am J Gastroenterol* 2006;101:2031–2037.

- [217] Moss AC, Morris E, Mac Mathuna P. Palliative biliary stents for obstructing pancreatic carcinoma. *Cochrane Database Syst Rev* 2006;02:CD004200.
- [218] Moss AC, Morris E, Leyden J et al. Malignant distal biliary obstruction: a systematic review and meta-analysis of endoscopic and surgical bypass results. *Cancer Treat Rev* 2007;33:213–221.
- [219] Chandrasegaram MD, Eslick GD, Mansfield CO et al. Endoscopic stenting versus operative gastrojejunostomy for malignant gastric outlet obstruction. *Surg Endosc* 2012;26:323–329.
- [220] Jeurnink SM, Polinder S, Steyerberg EW, Kuipers EJ, Siersema PD. Cost comparison of gastrojejunostomy versus duodenal stent placement for malignant gastric outlet obstruction. *J Gastroenterol* 2010;45:537–543.
- [221] Kneuert PJ, Cunningham SC, Cameron JL et al. Palliative surgical management of patients with unresectable pancreatic adenocarcinoma: trends and lessons learned from a large, single institution experience. *J Gastrointest Surg* 2011;15:1917–1927.
- [222] Fiori E, Lamazza A, Volpino P et al. Palliative management of malignant antro-pyloric strictures Gastroenterostomy vs. endoscopic stenting. A randomized prospective trial. *Anticancer Res* 2004;24:269–271.
- [223] Rudolph HU, Post S, Schlüter M, Seitz U, Soehendra N, Kähler G. Malignant gastroduodenal obstruction: retrospective comparison of endoscopic and surgical palliative therapy. *Scand J Gastroenterol* 2011;46:583–590.
- [224] Arguedas MR, Heudebert GH, Stinnett AA, Wilcox CM. Biliary stents in malignant obstructive jaundice due to pancreatic carcinoma: a cost-effectiveness analysis. *Am J Gastroenterol* 2002;97:898–904.
- [225] Rogart JN. The plastic biliary stent: an obsolete device for managing pancreatic cancer? *J Clin Gastroenterol* 2010;44:389–390.
- [226] Wasan SM, Ross WA, Staerckel GA, Lee JH. Use of expandable metallic biliary stents in resectable pancreatic cancer. *Am J Gastroenterol* 2005;100:2056–2061.
- [227] Chen VK, Arguedas MR, Baron TH. Expandable metal biliary stents before pancreaticoduodenectomy for pancreatic cancer: a Monte-Carlo decision analysis. *Clin Gastroenterol Hepatol* 2005;3:1229–1237.
- [228] Boulay BR, Gardner TB, Gordon SR. Occlusion rate and complications of plastic biliary stent placement in patients undergoing neoadjuvant chemoradiotherapy for pancreatic cancer with malignant biliary obstruction. *J Clin Gastroenterol* 2010;44:452–455.
- [229] Rogart JN, Boghos A, Rossi F et al. Analysis of endoscopic management of occluded metal biliary stents at a single tertiary care center. *Gastrointest Endosc* 2008;68:676–682.

- [230] Yeoh KG, Zimmerman MJ, Cunningham JT et al. Comparative costs of metal versus plastic biliary stent strategies for malignant obstructive jaundice by decision analysis. *Gastrointest Endosc* 1999;49:466–471.
- [231] Artifon EL, Aparicio D, Paione JB et al. Biliary drainage in patients with unresectable, malignant obstruction where ERCP fails: endoscopic ultrasonography-guided choledochoduodenostomy versus percutaneous drainage. *J Clin Gastroenterol* 2012;46:768–774.
- [232] Dhir V, Artifon EL, Gupta K et al. Multicenter study on endoscopic ultrasound guided expandable biliary metal stent placement: choice of access route, direction of stent insertion, and drainage route. *Dig Endosc*. 2014; 26:430-435.
- [233] Khashab MA, Valeshabad AK, Modayil R et al. EUS-guided biliary drainage by using a standardized approach for malignant biliary obstruction: rendezvous versus direct transluminal techniques (with videos). *Gastrointest Endosc* 2013;78:734–741.
- [234] Varadarajulu S, Banerjee S, Barth B et al. Enteral stents. *Gastrointest Endosc* 2011;74:455–464.
- [235] Kim KO, Kim TN, Lee HC. Effectiveness of combined biliary and duodenal stenting in patients with malignant biliary and duodenal obstruction. *Scand J Gastroenterol* 2012;8–9:962–967.
- [236] Costamagna G, Alveras P, Palladino F et al. Endoscopic pancreatic stenting in pancreatic cancer. *Can J Gastroenterol*.1999;13:481–487.
- [237] Wiersema MJ, Wiersema LM. Endosonography-guided celiac plexus neurolysis. *Gastrointest Endosc* 1996;44:656–662.
- [238] Ramesh J, Varadarajulu S. Interventional endoscopic ultrasound. *Dig Dis* 2008;26:347–355.
- [239] Penman ID, Rösch T. EUS 2008 Working Group document: evaluation of EUS-guided celiac plexus neurolysis/block (with video). *Gastrointest Endosc* 2009;69: S28–S31.
- [240] Wyse JM, Carone M, Paquin SC et al. Randomized, double-blind, controlled trial of early endoscopic ultrasound-guided celiac plexus neurolysis to prevent pain progression in patients with newly diagnosed, painful, inoperable pancreatic cancer. *J Clin Oncol* 2011;29:3541–3546.
- [241] Arcidiacono PG, Calori G, Carrara S et al. Celiac plexus block for pancreatic cancer pain in adults. *Cochrane Database Syst Rev* 2011;(3):CD007519.
- [242] Ascunze G, Ribeiro A, Reis I et al. EUS visualization and direct celiac ganglia neurolysis predicts better pain relief in patients with pancreatic malignancy (with video). *Gastrointest Endosc* 2011;73:267–274.

- [243] LeBlanc JK, Al-Haddad M, McHenry L et al. A prospective, randomized study of EUS-guided celiac plexus neurolysis for pancreatic cancer: one injection or two? *Gastrointest Endosc* 2011;74:1300–1307.
- [244] Doi S, Yasuda I, Kawakami H, Hayashi T et al. Endoscopic ultrasound-guided celiac ganglia neurolysis vs. celiac plexus neurolysis: a randomized multicenter trial. *Endoscopy* 2013;45:362–369.
- [245] Gan SI, Thompson CC, Lauwers GY, Bounds BC, Brugge WR. Ethanol lavage of pancreatic cystic lesions: initial pilot study. *Gastrointest Endosc* 2005;61:746–752.
- [246] DeWitt J, McGreevy K, Schmidt CM, Brugge WR. EUS-guided ethanol versus saline solution lavage for pancreatic cysts: a randomized, double-blind study. *Gastrointest Endosc* 2009;70:710–723.
- [247] DeWitt J, DiMaio CJ, Brugge WR. Long-term follow-up of pancreatic cysts that resolve radiologically after EUS-guided ethanol ablation. *Gastrointest Endosc* 2010;72:862–866.
- [248] Oh HC, Seo DW, Lee TY et al. New treatment for cystic tumors of the pancreas: EUS-guided ethanol lavage with paclitaxel injection. *Gastrointest Endosc* 2008;67:636–642.
- [249] Oh HC, Seo DW, Song TJ et al. Endoscopic ultrasonography-guided ethanol lavage with acitaxel injection treats patients with pancreatic cysts. *Gastroenterology* 2011;140:172–179.
- [250] DiMaio CJ, DeWitt JM, Brugge WR. Ablation of pancreatic cystic lesions: the use of multiple endoscopic ultrasound-guided ethanol lavage sessions. *Pancreas* 2011;40:664–668.
- [251] Levy MJ, Thompson GB, Topazian MD et al. US-guided ethanol ablation of insulinomas: a new treatment option. *Gastrointest Endosc* 2012;75:200–206.
- [252] Jürgensen C, Schuppan D, Naser F et al. EUS-guided alcohol ablation of an insulinoma. *Gastrointest Endosc* 2006;63:1059–1062.
- [253] Deprez PH, Claessens A, Borbath I et al. Successful endoscopic ultrasound-guided ethanol ablation of a sporadic insulinoma. *Acta Gastroenterol Belg* 2008;71:333–337.
- [254] Giovannini M. Concentration-dependent ablation of pancreatic tissue by EUS-guided ethanol injection. *Gastrointest Endosc* 2007;65:278–280.
- [255] Wallace MB, Sabbagh LC. EUS 2008 Working Group document: evaluation of EUS-guided tumor ablation. *Gastrointest Endosc* 2009;69: S59–S63.
- [256] Chang KJ, Nguyen PT, Thompson JA et al. Phase I clinical trial of allogeneic mixed lymphocyte culture (cytoimplant) delivered by endoscopic ultrasound-guided fine-needle injection in patients with advanced pancreatic carcinoma. *Cancer* 2000;88:1325–1335.

- [257] Hecht JR, Bedford R, Abbruzzese JL et al. A phase I/II trial of intratumoral endoscopic ultrasound injection of ONYX-015 with intravenous gemcitabine in unresectable pancreatic carcinoma. *Clin Cancer Res* 2003;9:555–561.
- [258] Irisawa A, Takagi T, Kanazawa M et al. Endoscopic ultrasound-guided fine-needle injection of immature dendritic cells into advanced pancreatic cancer refractory to gemcitabine: a pilot study. *Pancreas* 2007;35:189–190.
- [259] Hecht JR, Farrell JJ, Senzer N et al. EUS or percutaneously guided intratumoral TNFerade biologic with 5-fluorouracil and radiotherapy for first-line treatment of locally advanced pancreatic cancer: a phase I/II study. *Gastrointest Endosc* 2012;75:332–338.
- [260] Hanna N, Ohana P, Konikoff FM et al. Phase 1/2a, dose-escalation, safety, pharmacokinetic and preliminary efficacy study of intratumoral administration of BC-819 in patients with unresectable pancreatic cancer. *Cancer Gene Ther* 2012;19:374–381.
- [261] Klapman JB, Chang KJ. Endoscopic ultrasound-guided fine-needle injection. *Gastrointest Endosc Clin N Am* 2005;15:169–177, x.
- [262] Chang KJ. EUS-guided fine needle injection (FNI) and anti-tumor therapy. *Endoscopy* 2006;38 Suppl 1:S88–S93.
- [263] Verna EC, Dhar V. Endoscopic ultrasound-guided fine needle injection for cancer therapy: the evolving role of therapeutic endoscopic ultrasound. *Therap Adv Gastroenterol* 2008;1:103–109.
- [264] Kim HJ, Seo DW, Hassanuddin A et al. EUS-guided radiofrequency ablation of the porcine pancreas. *Gastrointest Endosc* 2012 Nov;76(5):1039–1043.
- [265] Varadarajulu S, Jhala NC, Drelichman ER. EUS-guided radiofrequency ablation with a prototype electrode array system in an animal model (with video). *Gastrointest Endosc* 2009 Aug;70(2):372–376.
- [266] Gaidhane M, Smith I, Ellen K et al. Endoscopic ultrasound-guided radiofrequency ablation (EUS-RFA) of the pancreas in a porcine model. *Gastroenterol Res Pract* 2012;2012:Art. ID 431451.
- [267] Arcidiacono PG, Carrara S, Reni M et al. Feasibility and safety of EUS-guided cryothermal ablation in patients with locally advanced pancreatic cancer. *Gastrointest Endosc* 2012;76:1142–1151.
- [268] Sun S, Xu H, Xin J et al. Endoscopic ultrasound-guided interstitial brachytherapy of unresectable pancreatic cancer: results of a pilot trial. *Endoscopy* 2006;38:399–403.
- [269] Jin Z, Du Y, Li Z et al. Endoscopic ultrasonography-guided interstitial implantation of iodine 125-seeds combined with chemotherapy in the treatment of unresectable pancreatic carcinoma: a prospective pilot study. *Endoscopy* 2008;40:314–320.

- [270] Chang KJ, Lee JG, Holcombe RF et al. Endoscopic ultrasound delivery of an antitumor agent to treat a case of pancreatic cancer. *Nat Clin Pract Gastroenterol Hepatol* 2008;5:107–111.
- [271] Ammar T, Cote GA, Creach KM et al. Fiducial placement for stereotactic radiation by using EUS: feasibility when using a marker compatible with a standard 22-gauge needle. *Gastrointest Endosc* 2010;71:630–633.
- [272] Park WG, Yan BM, Schellenberg D et al. EUS-guided gold fiducial insertion for image-guided radiation therapy of pancreatic cancer: 50 successful cases without fluoroscopy. *Gastrointest Endosc* 2010;71:513–518.
- [273] Sanders MK, Moser AJ, Khalid A et al. EUS-guided fiducial placement for stereotactic body radiotherapy in locally advanced and recurrent pancreatic cancer. *Gastrointest Endosc* 2010;71:1178–1184.
- [274] Khashab MA, Kim KJ, Tryggestad EJ et al. Comparative analysis of traditional and coiled fiducials implanted during EUS for pancreatic cancer patients receiving stereotactic body radiation therapy. *Gastrointest Endosc* 2012;76:962–971.