

# We are IntechOpen, the world's leading publisher of Open Access books Built by scientists, for scientists

4,800

Open access books available

122,000

International authors and editors

135M

Downloads

Our authors are among the

154

Countries delivered to

TOP 1%

most cited scientists

12.2%

Contributors from top 500 universities



WEB OF SCIENCE™

Selection of our books indexed in the Book Citation Index  
in Web of Science™ Core Collection (BKCI)

Interested in publishing with us?  
Contact [book.department@intechopen.com](mailto:book.department@intechopen.com)

Numbers displayed above are based on latest data collected.  
For more information visit [www.intechopen.com](http://www.intechopen.com)



---

# **New Frontiers in Managing Clival Tumors – The Extended Endoscopic Endonasal Approach**

---

G. Cossu, R.T. Daniel, M. George, F. Parker,  
N. Aghakhani, M. Levivier and M. Messerer

Additional information is available at the end of the chapter

<http://dx.doi.org/10.5772/60553>

---

## **Abstract**

Clival lesions still represent a challenge for neurosurgeons. A variety of expansive process, either benign or malignant, may be identified in the clival and paraclival region.

Surgery of this region with classical open approaches is associated with a significant rate of complication, and the treatment is risky despite technological progress. The acceptance and utilization of endoscopic techniques on a regular basis in transsphenoidal surgery have allowed its application to regions far beyond the *sella turcica*, such as to reach the clival and paraclival region.

Long-term follow-up studies show how the extent of oncological resection is related to long-term prognosis for the most common clival malignancies. Gross total removal is therefore mandatory, and the selection of the best surgical approach is essential for the achievement of this goal.

The choice of the surgical approach depends on the location and the extent of the lesion. Through a complete overview of surgical anatomy, we propose a surgical classification with three corridors in the sagittal plane and three zones in the coronal plane. We finally summarize the indications and the limits for the endoscopic technique. In selected cases, endoscopic approaches allow similar oncological outcomes as classical open approaches with a lower rate of complications.

**Keywords:** Clival tumors, Clival chordoma, Clival chondrosarcoma, Meningioma, Extended endoscopic endonasal approach, Skull base surgery

## 1. Introduction

The clival region may be involved in a copious number of disorders. The most common clival lesions are chordomas, but meningiomas, chondroma and chondrosarcoma may also occur. Furthermore, the clivus may be secondarily invaded by a variety of metastatic malignancies. A radical excision is related to long-term prognosis and survival and a gross total resection is the *primum movens* of every surgical procedure when judged possible. The deep location and the presence of important neurovascular structures make of the clivus a challenging working area. Surgery of this region through classical open approaches implies neurovascular and cerebral retraction with a significant rate of neurological morbidities. Neurosurgeons have thus progressively searched for innovative ways to reach the clival region and to limit the complication rate.

Endoscopy started to be used as a diagnostic tool [1, 2] and then developed as a therapeutic option for sellar lesions [3, 4]. During the last decades, endoscopic techniques were applied to the skull base with encouraging results in terms of surgical resection and rate of complications [5]. Clear advantages of endoscopic surgery are principally a limited retraction on neurovascular structures with a concomitant wide vision and large exposure. Furthermore, patients have no external marks, and the length of hospitalization is normally shorter than with open procedures.

According to their location and extension, clival tumors may be reached through an anterior approach, as extended subfrontal, Le Fort I, transoral approach or maxillotomy, or through a lateral approach as the transpterygoid or infratemporal craniotomy or as the transpetrosal or far lateral approach. The endoscopic technique may represent a valid alternative to these open approaches, and the aim of this chapter is to expose the expanded endoscopic approach as first-line treatment in well-selected patients.

## 2. Preoperative evaluation

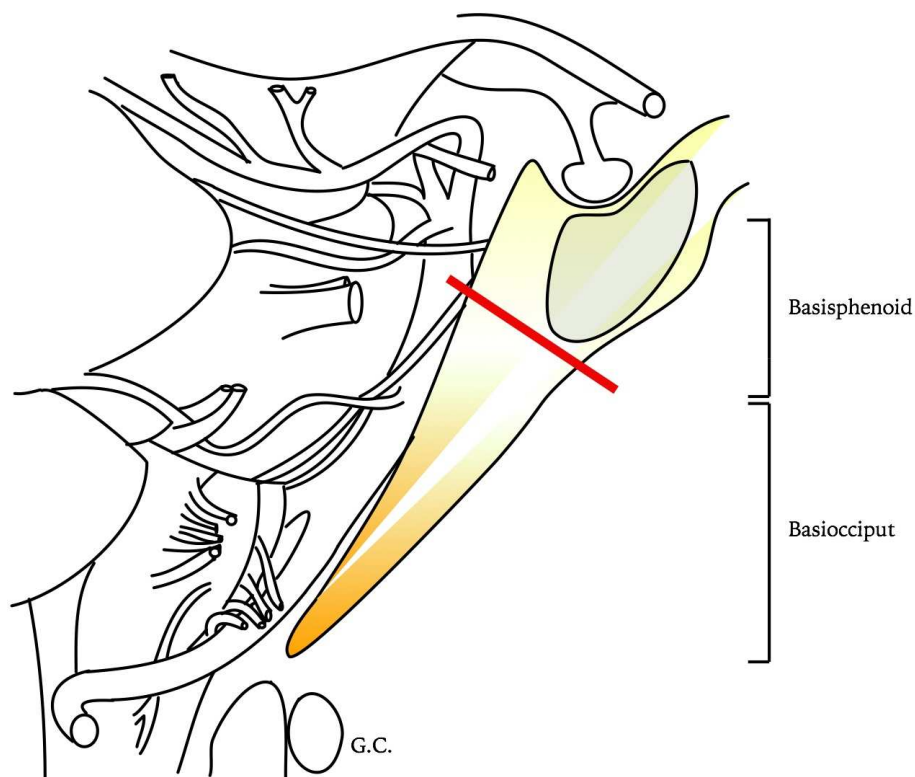
A satisfying preoperative evaluation implies T1 and T2-weighted MRI sequences, with and without gadolinium administration, to evaluate the extent and the precise localization of the lesion in the axial, coronal and sagittal plane. A high-resolution skull base CT scan with bone windows will help to plane the surgical approach and to evaluate bone invasion and osseous pneumatization. A CT angiography will then help to characterize vessels' characteristics, in particular of the ICA, and their reciprocal relationship with the lesion, thus defining the extent of resection. A 3D-scannographic reconstruction may better help understanding the real surgical anatomy of the ventral skull base, with a particular concern for the location of foramen lacerum and vidian canal. Patients should also have an ENT evaluation with a specialized neuro-otological examination and undergo a preoperative endonasal endoscopy to plan the access for the surgery.

### 3. Surgical procedure

#### 3.1. Surgical anatomy and classification of the surgical approach

The clivus separates the nasopharynx from the posterior cranial fossa and a natural access is possible through the nasal cavities.

From a purely anatomical point of view, the clivus is traditionally divided into basisphenoid (sphenoid body) and basiocciput (basilar part of the occipital bone) (Figure 1).

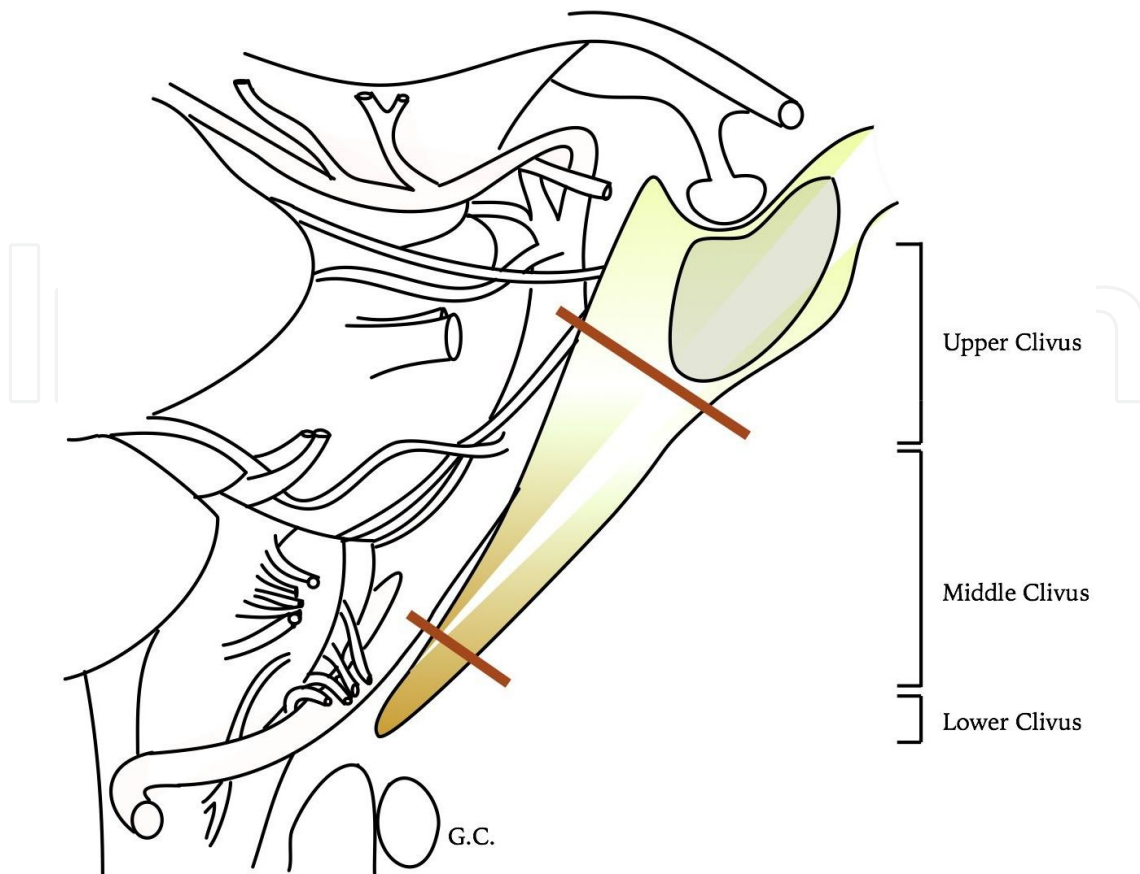


**Figure 1.** Anatomical classification of the clivus, which is divided into basisphenoid and basiocciput. Classically the sphenoid body forms the basisphenoid while the basiocciput belongs to the occipital bone.

From a surgical point of view, the clivus has classically been divided into [6] (Figure 2):

- an upper clivus extending from the dorsum sellae to the plane of Dorello canal;
- a middle clivus extending from the Dorello canal to the pars nervosa of the jugular foramen;
- a lower clivus extending from the pars nervosa of the jugular foramen to the foramen magnum.

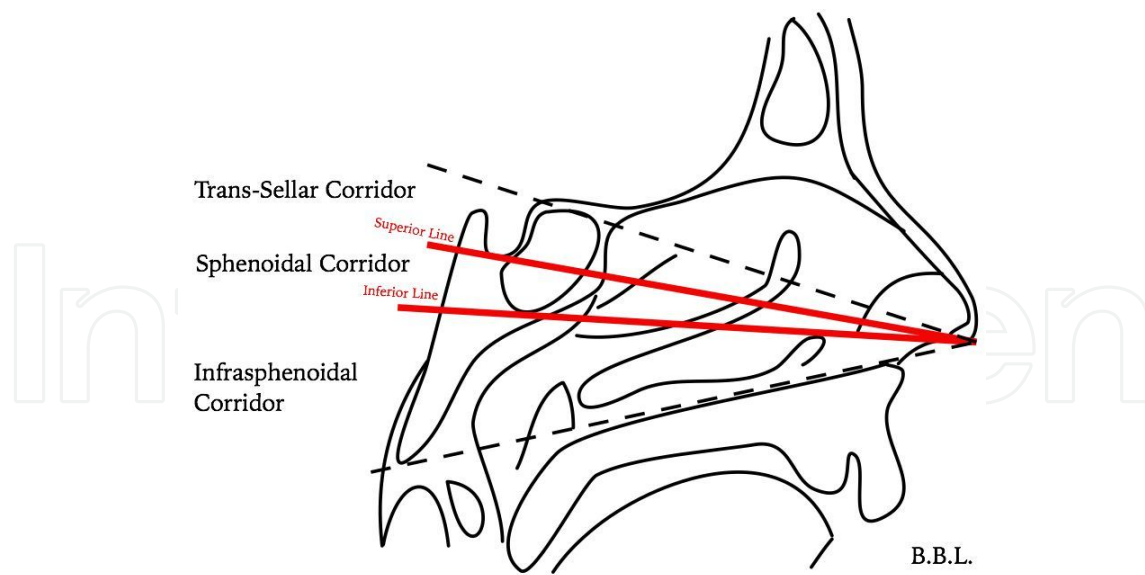
The choice of the surgical approach depends on the location and extension of the lesion, which are the principal determinants for the extent of bone removal. The relationship between the lesion and the pneumatization of the sphenoidal sinus represents the basis of our surgical classification proposed here.



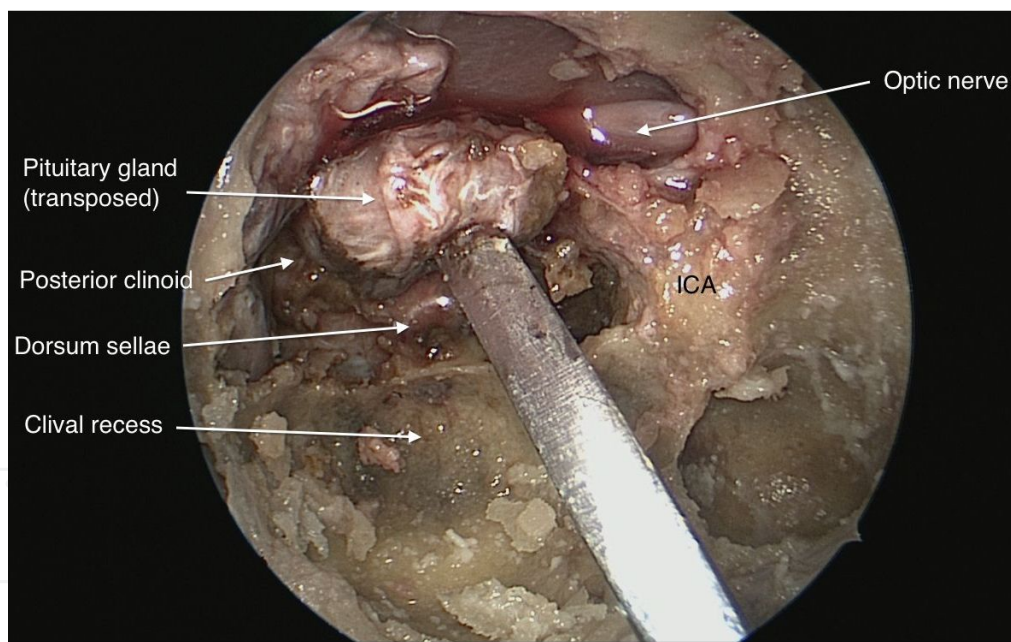
**Figure 2.** Surgical classification of the clivus. The upper third extends from the dorsum sellae to the Dorello canal. The middle third extends inferiorly till the jugular foramen, while the inferior third extends to the foramen magnum.

Three corridors may be identified in the sagittal plane, separated by two lines (Figure 3). The superior line joins the nostril with the sellar floor, while the inferior line joins the nostril with the inferior wall of the sphenoidal sinus. The superior line separates the trans-sellar corridor, used for lesions of the anterior cranial base and extending till the posterior clinoid process, and the sphenoidal corridor, where the natural pneumatization allows a direct access to the sellar and retrosellar region without the necessity to transpose the pituitary gland as in the trans-sellar corridor [7] (Figure 4). In front of a well-pneumatized sphenoid sinus, the sphenoidal corridor gives an excellent access to mid-clival lesions. The inferior line separates the sphenoidal corridor from the infra-sphenoidal corridor, used to access to the lower part of the clivus after the lateralization of the *longus capitis* and *longus colli* muscles. The identification of the foramen magnum and hypoglossal canals is fundamental to safely use this corridor. A different inclination of the endoscope in the sagittal plane combined with a more or less pronounced flexion or extension of the head of the patient allows direct access to one of the three corridors.

According to our endoscopic conception, three zones are also identified in the coronal plane: the median, paramedian and lateral zone (Figure 5). The medial line, extending from the medial wall of the cavernous sinus to the medial border of the foramen lacerum, separates the median from the paramedian zone. The lateral line, extending from the lateral wall of the



**Figure 3.** Sagittal view showing the three surgical corridors: the trans-sellar, the sphenoidal and the infra-sphenoidal corridors. The corridor must be chosen on the basis of the location of the lesion. Head flexion and the use of angulated endoscope may help in performing the procedure.

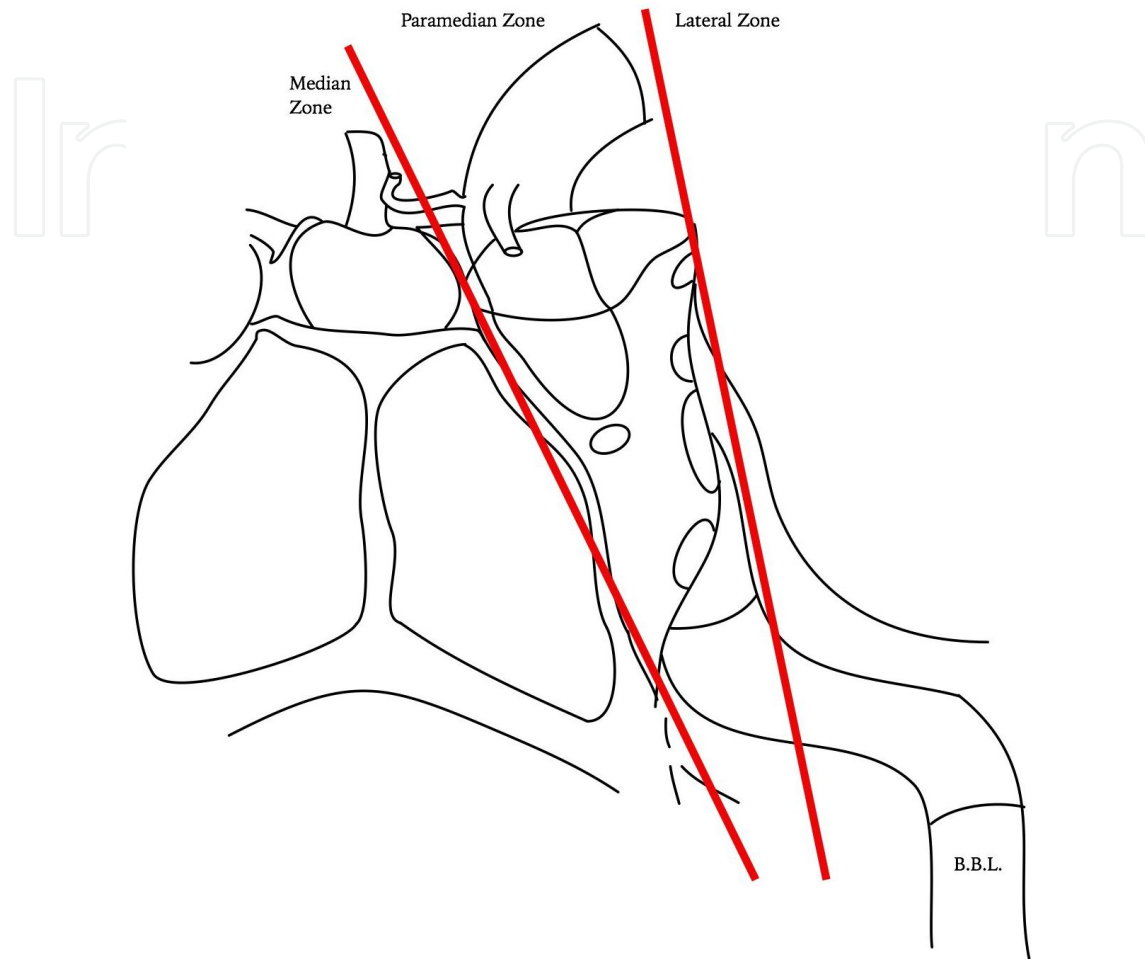


**Figure 4.** Cadaveric view of a trans-sellar corridor. The pituitary is transposed to drill out the posterior clinoids and the dorsum sellae. The posterior ethmoidal cells are also opened and the left optic nerve is here exposed.

cavernous sinus to the lateral edge of the foramen lacerum, separates the paramedian zone from the lateral zone.

To work safely in the paramedian zone, the identification of the vidian nerve and of the ICA is fundamental [8]. Lesions limited to the median and paramedian zones may be completely

excised through an endoscopic approach, while for lesions extending to the lateral zone a pterygoid or infratemporal craniotomy may be preferred or combined with endoscopy.



**Figure 5.** Coronal representation of the three coronal zones. The cavernous sinus and the foramen lacerum represent two important landmarks. A lesion situated solely in the median or paramedian zone may be completely resected through an endoscopic approach. For lesions extending to the lateral zone a combined approach must be considered.

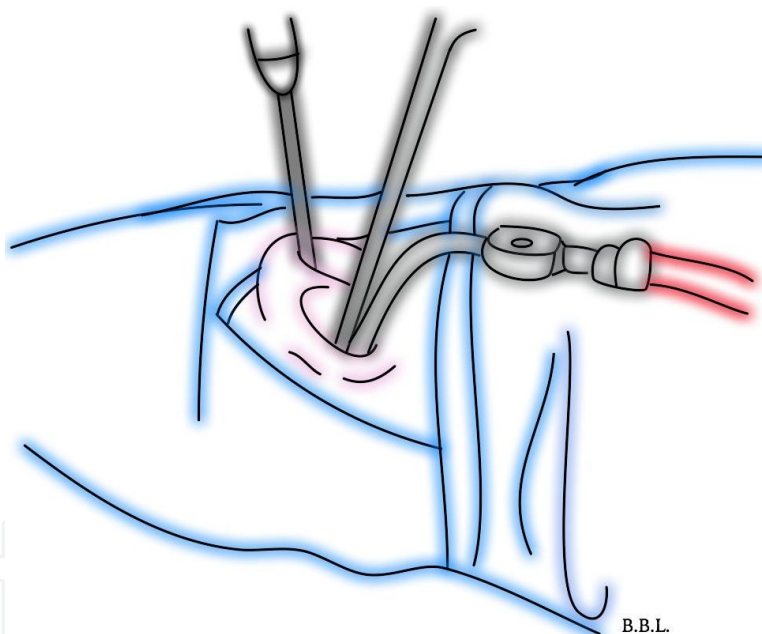
### 3.2. Operative technique

In most centers, an interdisciplinary team consisting of a neurosurgeon and an otolaryngologist performs the surgery. The patient is positioned supine with the head elevated of 30° and slightly hyperextended. A general anesthesia is performed with an orotracheal intubation. As nerves retraction represent one of the main risk, intraoperative neuromonitoring is performed, allowing direct monitoring of cranial nerve function. Direct stimulation through a monopolar device is commonly used, with a frequency of 1Hz, a monophasic negative 200  $\mu$ s duration and a 1 to 5 mA intensity stimulation. Eyeball movements are thus monitored through electrodes capturing the displacement of the retina dipole to evaluate the integrity of oculomotor, trochlear and abducens nerves. The frontalis, orbicularis oculi, orbicularis ori and

mentalis muscles are evaluated to monitor the functionality of the facial nerve. Electrodes incorporated in the endotracheal tube (Xomed®) are used for glossopharyngeal and vagus nerves while electrodes in trapezius and hypoglossal muscles are used to monitor accessory-spinal and hypoglossal nerves respectively. Somatosensory evoked potentials and brain stem auditory potentials are also used as complement for brainstem function assessment.

Some centers guide their extent of resection with a neuronavigation system and a Doppler ultrasonography to better visualize adjacent vascular structures as the sphenopalatine artery, the ICA and the basilar artery.

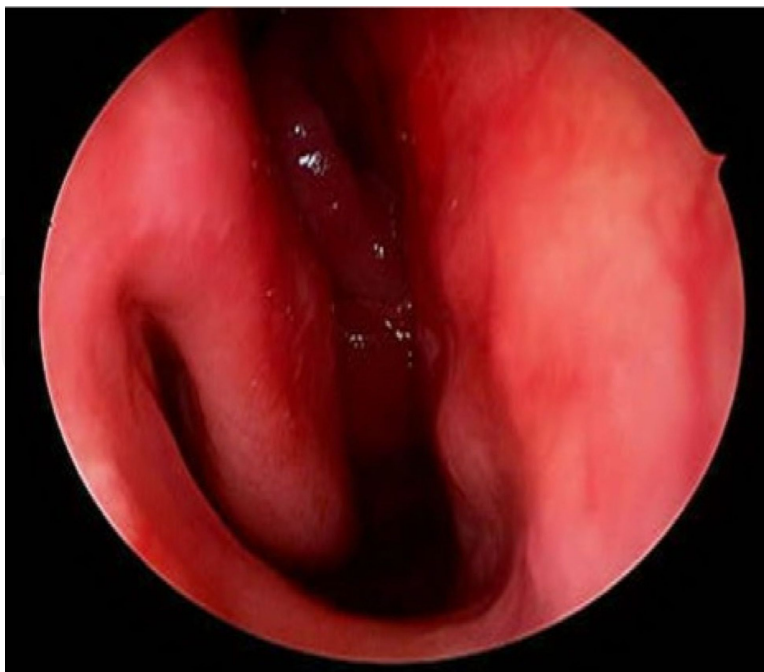
A binostril approach is used according to the four-hand technique (Figure 6). The procedure is performed with a hand-held short 0°, 30° or 45° endoscope till the sellar floor opening. The endoscope is classically first introduced from the right nostril unless the preoperative endonasal evaluation showed a preferential way in the left nostril. The endoscope is oriented slightly rostrally to better visualize the clivus and normally handled in the nostril contralateral to the lesion during the operative procedure.



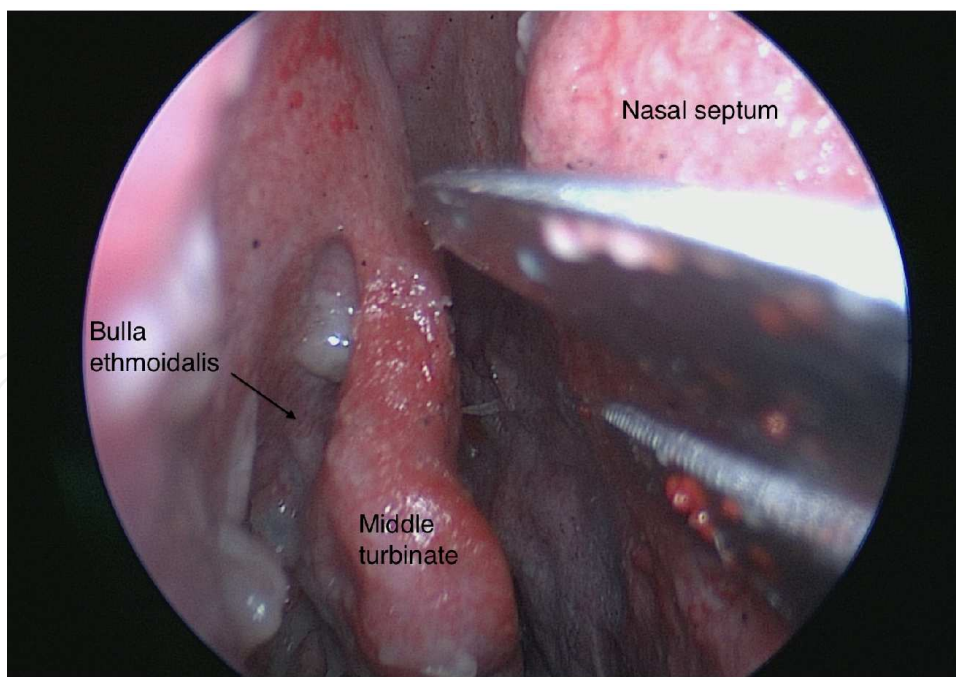
**Figure 6.** Representation of the *four-hand technique*. The endoscopic is kept by the operative aid in the nostril contralateral to the lesion, while the surgeon freely operates with both hands in the other nostril. This technique implies the presence of two well-trained operators and a strong collaboration between the two surgeons.

Through the endonasal approach, the inferior turbinate is encountered first, then the medial and the superior one, which may be resected or just retracted (Figure 7). To obtain a wider surgical corridor, a resection of the middle and superior turbinates is preferred for extended endoscopic approaches [9, 10, 11, 12, 13] (Figure 8 and 9). Turbinectomies allows also a better visualization of branches of the sphenopalatine arteries, important to preserve for the closure stage.



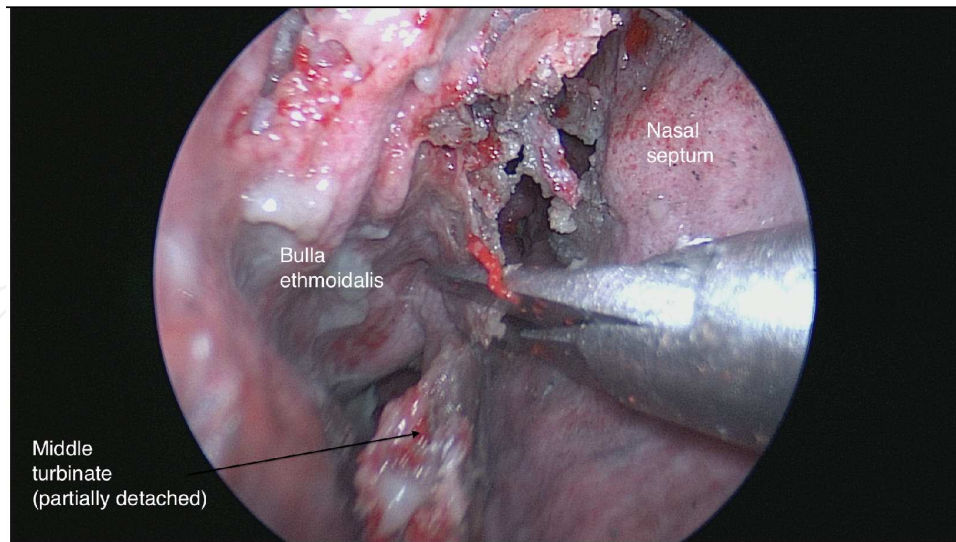


**Figure 7.** *In vivo* visualisation of the right nasal cavity through a 0° endoscope. At the beginning of the endonasal approach the inferior turbinate is first visualized (left). More deeply the middle turbinate is identified and laterally displaced or resected to gain a wider access to the clival region.

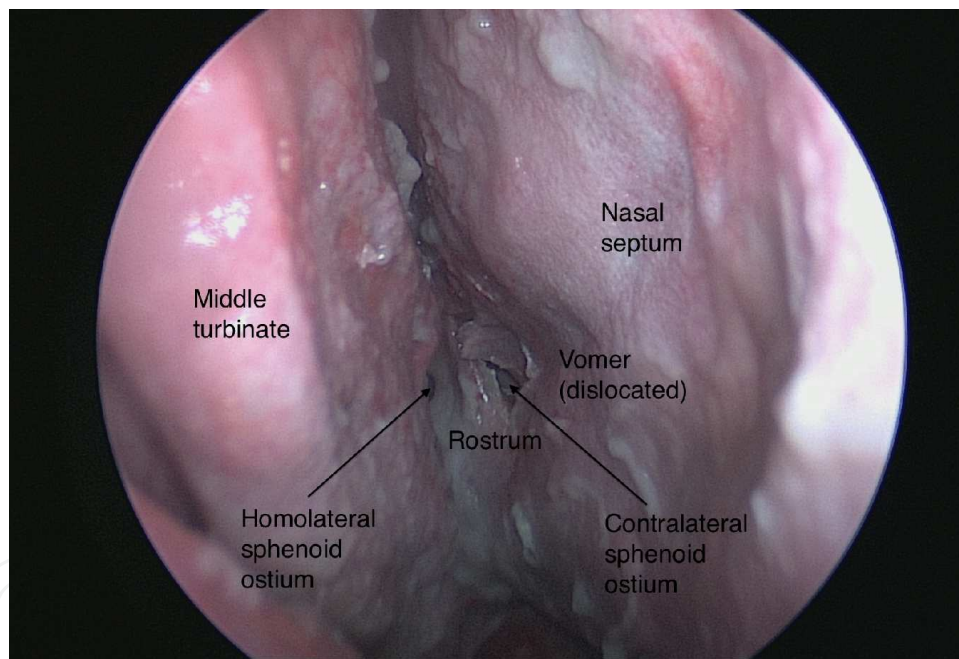


**Figure 8.** Cadaveric view of the right nasal fossa. The middle turbinate is visualized as well as the bulla ethmoidalis in the lateral wall of the nasal cavity.

The coanes and the inferior wall of the sphenoid sinus are identified.



**Figure 9.** A middle turbinectomy is performed in a cadaveric specimen. A wider endonasal access is thus obtained for more extended approaches. The middle turbinate may then be used during the closure stage.

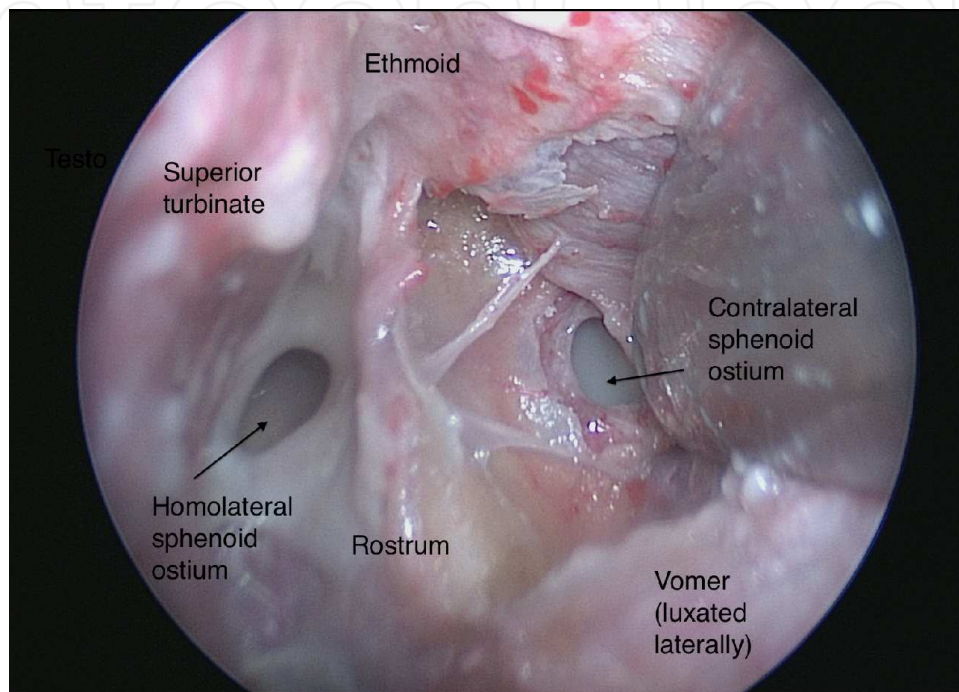


**Figure 10.** Cadaveric view showing sphenoid rostrum exposition after the septal mucosa is incised and the vomer is dislocated laterally. The two sphenoid ostia are here visualized, giving access to the sphenoid sinus.

The mucosa is incised with an endoscopic knife over the vomer (Figure 10) and retracted laterally until the vidian nerve, which represents the lateral limit for exposure and resection. The vidian nerve conducts in fact to the junction between the horizontal portion of the petrous ICA and the vertical paraclival segment of the ICA at the foramen lacerum.

After vomer sublaxation and bilateral wide sphenoidotomies (Figure 11), the following steps of the surgery depend on the location and the extent of surgery (Figure 12). The osseous

structure of the clivus is exposed and resected through a diamond burr drill (Figure 13) and secondarily a 1 and 2 mm Kerrison bone punch, according to a cranio-caudal direction from the inferior wall of the sphenoid ostium down to the foramen magnum (Figure 14). The paraclival ICA represents the lateral limit for exposure at this level. If necessary the ICA can be carefully dissected and mobilized in the medio-lateral plane to provide adequate access to the tumor in the paramedian zone.

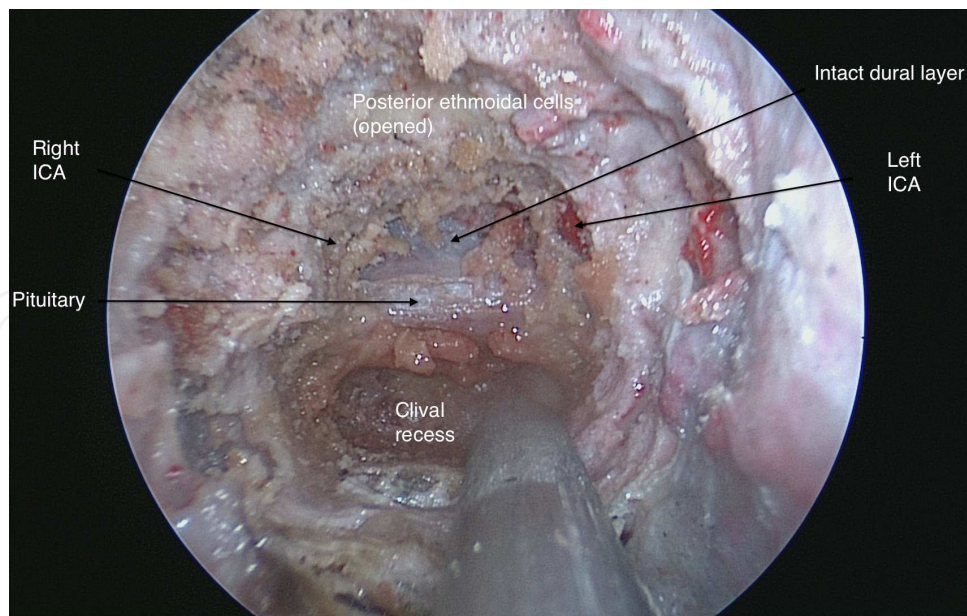


**Figure 11.** Bilateral exposition of the sphenoid ostia. A bilateral sphenoidotomy is then performed through a diamond drill and a small Kerrison bone punch to gain access to the sphenoid sinus.

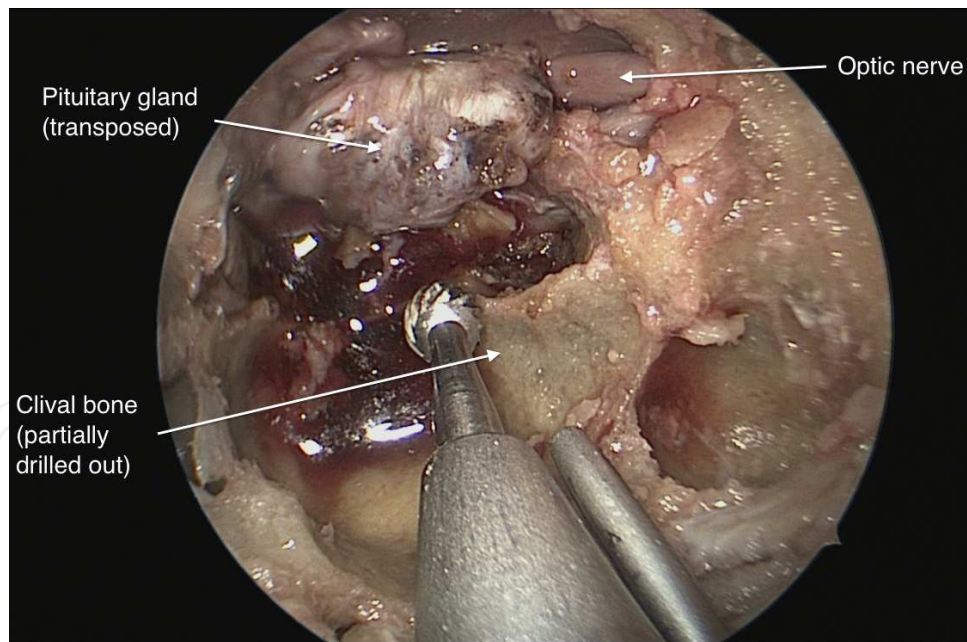
The lateral extension of bone removal is defined by the pterygoid canal, which is found about 5mm lateral to the vomer-sphenoid junction. The vidian nerve may be followed proximally till the pterygoid canal. The lateral boundaries limiting bone resection are thus represented in a craniocaudal fashion by the cavernous sinus, paraclival carotid arteries and the foramen lacerum.

The dura is thus exposed and the integrity of the basilar plexus, situated between the two layers of the dura of the upper clivus, should be respected to avoid copious bleeding. Bleeding from the basilar venous plexus is in fact often difficult to cauterize, but it may be managed with the use of hemostatic materials (FloSeal Hemostatic Matrix®, Bayer Healthcare SA) and packing. The abducens nerve may be identified as traversing laterally the basilar plexus, and the paraclival ICA is also found.

For intradural lesions, a median longitudinal incision can be made initially on the outer layer of the dura. Then the internal layer is opened, with the visualization of the prepontine cistern and basilar artery (Figure 14).

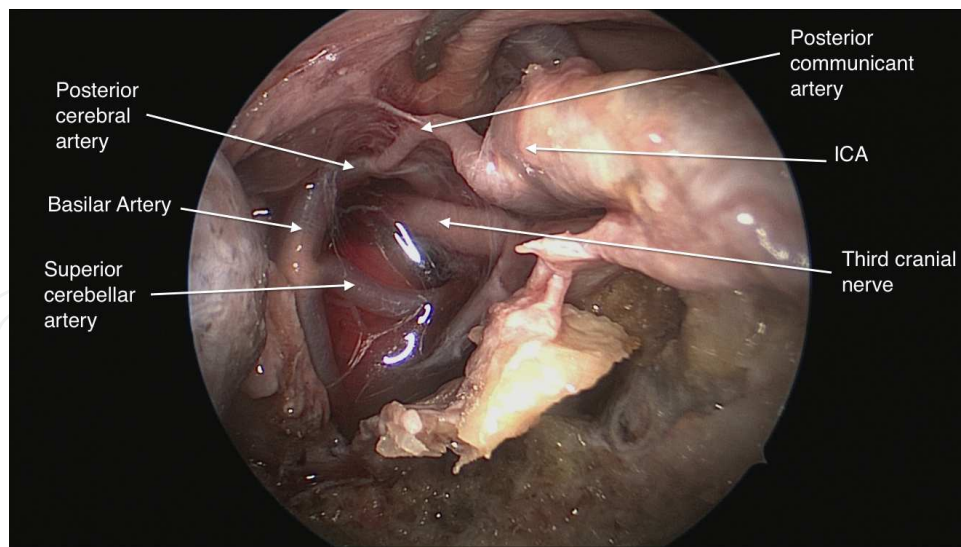


**Figure 12.** After a wide opening, the surgeon can choose the best sagittal corridor to reach the clival region of interest. The pituitary may be transposed to follow the supra-sellar corridor and gain access to the dorsum sellae or to the posterior clinoids or the clivus may be further drilled inferiorly. The lateral limits for the exposition are represented by the paraclival ICA. The vidian nerve should be identified and followed as it conducts directly to the foramen lacerum and may guide in defining the lateral limits of dissection.



**Figure 13.** Drilling of the clival bone. The drilling is performed in a cranio-caudal fashion. It is important to respect dural integrity during this process.

The lesion is removed under endoscopic guidance in a piecemeal fashion with ultrasound dissectors. Intraoperative pathologic examination of tumor tissue is generally performed to decide on the extent of tumor resection on the basis of diagnosis.



**Figure 14.** Exposition of the preoptine cistern in a cadaveric specimen. The two layers of the dura are opened and the posterior circulation is visualized.

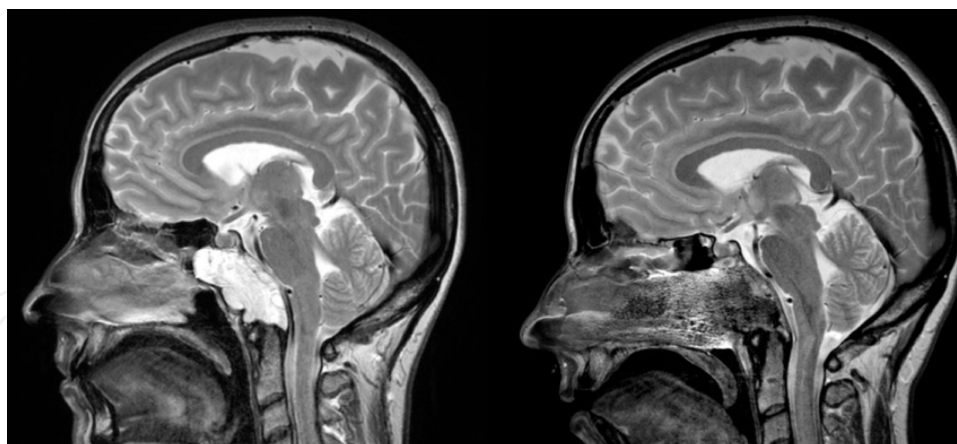The closure step is as important as the dissection and excision steps. A nasoseptal flap vascularized by the septal branches of the sphenopalatine artery may be prepared at the beginning of the procedure and displaced in the oropharynx, under the soft palate, to be protected during the surgery. It is important that the size of the pedicle of the flap stays sufficiently large to avoid necrosis of its borders. The use of the Hadad flap is now widespread, and it has allowed a significant reduction in the rate of postoperative CSF leaks after endoscopic techniques.

The reconstruction surface should be widened: flaps tend easily to shrink and we proposed the superposition of two nasoseptal flaps vascularized by branches of the posterior septal arteries in a lambdoid shape to ensure a correct closure. The middle turbinate resected at the beginning of the procedure may also be superimposed to increase the sealing in combination with biologic glue (Tisseel, Fibrin Sealant®, Baxter AG).

### 3.3. Indications/management

Chordomas are slow-growing extra-axial tumors deriving from vestigial remnants of the notochord and the most common site at the sacrum and the clivus. A male predominance was described (3:1). They are considered low-grade malignancies but locally aggressive with a high recurrence rate. For this reason, gross total resection is fundamental but often difficult to achieve because of tumor extension and invasiveness and the proximity of important neurovascular structures. At clinical presentation, intracranial extension has normally occurred and complete resection is difficult in most cases (Figure 15).

When invading the basion, the most common presentation is represented by the XIIth cranial nerve palsy, while when the middle part of the clivus is interested (most common), chordomas may manifest as nasopharyngeal obstructive masses in cases of ventral extension or with VIth cranial nerve palsy in cases of dorsal extension. Chordomas arising at the upper third of the



**Figure 15.** This young patient presented with neck pain. Preoperative sagittal T2-weighted cerebral MRI (left), showing a lesion involving the whole clivus. The sphenoidal and infrasphenoidal corridors were used to resect the lesion through EEEA. The postoperative MRI (right) shows a gross total resection of the lesion. The lesion was completely extradural. The patient was free of disease at 5-years follow-up.

clivus may present with hypopituitarism signs or bitemporal hemianopia due to chiasmal compression.

A lateral extension may also occur with consequent invasion of cavernous sinus in the upper part of the clivus or it may manifest with otologic symptoms like deafness, tinnitus and vertigo or facial paralysis because of involvement of the petrous bone.

Chondrosarcomas are malignant tumors derived from cartilaginous tissue arising from bone or soft tissues. They are less aggressive than other sarcomas but the natural history is characterized by multiple local recurrences after surgical excision. Distant metastases are rare. Both sexes are equally affected. About 75% of all cranial chondrosarcoma arise at the skull base, in particular in the middle cranial fossa. Imaging shows mottled calcifications within a soft tissue mass. Clinical manifestations are similar to those described for chordomas. Expansive lesions involving primarily the petrous apex may expand anteriorly and involve the clivus.

Meningiomas in particular may arise in close proximity to the porus acusticus or from a separate origin on the face of the petrous bone, and they may slowly extend to the clival region. They are five times more frequent in women, and the main clinical presentation is with vestibulocochlear symptoms. Secondarily, peripheral facial weakness or facial numbness are found accompanied by indirect signs of clival involvement in more advanced cases.

A complete local resection should be attempted along with resection or cauterization of dural attachment to minimize the risk of local recurrence.

The goal of every oncologic surgery should be gross total resection. However, to avoid complications and preserve neurovascular structures is the first compromise to accept when working in the clival region, and this is the first principle to guide the extent of resection.

Lesions showing wide intracavernous sinus extension, vascular encasement (ICA or vertebral artery) or brainstem involvement should be preoperatively planned as subtotal resection.

Furthermore, the extended endoscopic approach may be used as a valid alternative for debulking surgery or in palliative cases to limit the symptomatology of the patient or to allow a following complementary treatment, as radiotherapy or proton beam radiotherapy.

Traditionally clival lesions were treated through different trans-cranial approaches with a consequent important brain retraction, and a high risk of injury for the vessels and nerves crossed during the procedure [14-22].

The increased confidence in endoscopic techniques allowed a widespread application of the extended endoscopic approach to treat clival lesions. The first cadaveric study conducted in 2002 showed the feasibility of the procedure [23] and since then endoscopy has not ceased to find other applications. The main advantage is related to the avoidance of brain retraction and nerves crossing. Technological advancements allowed the development of a specialized instrumentation to work properly in the endonasal route, and many centers are pushing the application of endoscopic techniques far beyond the midline. Thanks to angled instruments, a dynamic 360° view may be obtained [24].

The results of the extended endoscopic approach for clival chordomas have been widely reported [7, 25-29]. In terms of gross total removal, it was equivalent or superior to classical open approaches [30, 31]. The extent of resection is the most important prognostic factors for survival in these cases, with a survival at 5 years of follow up dropping from 90% for GTR to 52% for partial resection [22]. The principal determinants for the surgical resection are the tumor volume and the lateral extension. The literature analysis shows how endoscopy represents an excellent approach for median lesions, with good results, especially for extradural lesions.

Following the increased experience with endoscopic techniques for extradural clival tumors, some centers started to use the trans-clival approach for the management of intradural tumors with good operative results [11, 13, 25, 31-33].

For lateral lesions or intradural lesions, however, the endoscopic approach is more complex, and it should be combined with traditional open approaches. After an excision as radical as possible, a complementary treatment through fractionated radiotherapy, stereotactic radiosurgery or proton beam radiotherapy represents the best management policy [34].

The tumor may thus be divided ideally into different compartments, which may be approached through a different surgical technique, endoscopic or transcranial, or treated with external irradiation. This conception allows minimizing the neurological morbidity and the complication rate because each technique is used safely. Furthermore, it is possible to realize a maximal resection with minimal access.

### **3.4. Complications**

Both the extent of resection and the rate of complications are related to the experience of the first operator. The reconstructive step is as crucial as the excisional step, and it may be even more complicated in cases of large skull base defects. The first descriptive studies about the endoscopic skull base surgery reported an incidence of cerebrospinal fluid (CSF) leaks as high as 33.3% [27]. This complication may represent a medical emergency when not perceived in time because of the risk of infectious meningitis. CSF leak may be treated either with a surgical

revision or conservatively with a lumbar drain. The main determinant factor is the surgeon's judgment about any intraoperative source of leakage. The CSF leak rate was severely reduced during the last years after the introduction of the vascularized nasospetal flap as described by Hadad [35], the gasket type seal and the multi-layered closure technique. The lumbar drain, which once was systematically used in the early postoperative period, may thus be avoided in most cases with a precocious mobilization of patients.

Infectious complications may be treated either with medical therapy or with surgical revision.

Vascular lesions may also occur, with early or delayed hemorrhagic complications (intracranial hematoma occurred in about 6% of cases according to Carrabba et al [36]). Though a careful dissection is realized, damage to the ICA may occur, often with catastrophic results. A preoperative occlusion test may help evaluate the consequences of an eventual ICA sacrifice. The consequences of an intraoperative ICA sacrifice may vary from the death of the patients to permanent neurological deficit to a simple Horner syndrome.

Cranial nerve palsies are significantly less frequent with the endoscopic approach when compared to the open approaches and transient in the majority of cases [36]. The majority of patients report an improvement in preoperative cranial nerve palsy due to surgical decompression. After surgery, patients mostly complain about transient minor symptoms as headache, blurred vision and nasal obstruction.

Patients having a postoperative syndrome of inappropriate antidiuretic hormone hypersecretion are also reported, as well as manifestations of hypopituitarism as a consequence of pituitary manipulation.

### **3.5. Limitations**

Classical open approaches continue to be the gold standard for lesions extending lateral to the internal carotid artery, the vertebral arteries or lateral to the optic nerve, into the mastoid or inferior to the dens.

The excision of tumors extending into the cavernous sinus is actually possible with the endoscopic technique, but the postoperative cranial nerve palsy remains significant. A subtotal resection is performed in the majority of cases and the residual tumor may be treated with adjuvant stereotactic radiosurgery.

Furthermore, for intradural tumors a combined approach (extended endoscopic endonasal approach with transcranial microsurgery) is preferred.

## **4. Conclusion**

The expanded endoscopic approach provides a good exposure to efficiently treat lesions of the clival region. This minimally invasive technique allows obtaining satisfying results in terms of oncological resection without skin incision and neurovascular retraction in a cohort of well-selected patients.



## Author details

G. Cossu<sup>1\*</sup>, R.T. Daniel<sup>1</sup>, M. George<sup>2</sup>, F. Parker<sup>3</sup>, N. Aghakhani<sup>3</sup>, M. Levivier<sup>1</sup> and M. Messerer<sup>1,3</sup>

\*Address all correspondence to: giulia.cossu@chuv.ch

1 Department of Neuroscience, Neurosurgical Unit, University Hospital of Lausanne, University of Lausanne, Faculty of Medicine and Biology, Lausanne, Switzerland

2 Department of E.N.T., University Hospital of Lausanne, University of Lausanne, Faculty of Medicine and Biology, Lausanne, Switzerland

3 Department of Neurosurgery, Kremlin Bicêtre Hospital, University of Paris Sud, Faculty of Medicine, Paris, France

The authors have no personal, financial or institutional interest.

## References

- [1] Stammberger H, Posawetz W. Functional endoscopic sinus surgery. Concept, indications and results of the Messerklinger technique. *European Archives of Oto-Rhino-Laryngology : Official Journal of the European Federation of Oto-Rhino-Laryngological Societies*. 1990;247(2):63-76.
- [2] Messerklinger W. [Role of the lateral nasal wall in the pathogenesis, diagnosis and therapy of recurrent and chronic rhinosinusitis]. *Laryngologie, Rhinologie, Otologie*. 1987;66(6):293-9.
- [3] Cappabianca P, Cavallo LM, De Divitiis E. Endoscopic endonasal transsphenoidal surgery. *Neurosurgery*. 2004;55(4):933-40; discussion 40-1.
- [4] Carrau RL, Jho HD, Ko Y. Transnasal-transsphenoidal endoscopic surgery of the pituitary gland. *The Laryngoscope*. 1996;106(7):914-8.
- [5] Kassam AB, Gardner P, Snyderman C, Mintz A, Carrau R. Expanded endonasal approach: fully endoscopic, completely transnasal approach to the middle third of the clivus, petrous bone, middle cranial fossa, and infratemporal fossa. *Neurosurgical Focus*. 2005;19(1):E6.
- [6] Liu JK, Decker D, Schaefer SD, Moscatello AL, Orlandi RR, Weiss MH, et al. Zones of approach for craniofacial resection: minimizing facial incisions for resection of anterior cranial base and paranasal sinus tumors. *Neurosurgery*. 2003;53(5):1126-35; discussion 35-7.

- [7] Kassam AB, Prevedello DM, Thomas A, Gardner P, Mintz A, Snyderman C, et al. Endoscopic endonasal pituitary transposition for a transdorsum sellae approach to the interpeduncular cistern. *Neurosurgery*. 2008;62(3 Suppl 1):57-72; discussion 4.
- [8] Kassam AB, Vescan AD, Carrau RL, Prevedello DM, Gardner P, Mintz AH, et al. Expanded endonasal approach: vidian canal as a landmark to the petrous internal carotid artery. *Journal of Neurosurgery*. 2008;108(1):177-83.
- [9] Kassam A, Snyderman CH, Mintz A, Gardner P, Carrau RL. Expanded endonasal approach: the rostrocaudal axis. Part I. Crista galli to the sella turcica. *Neurosurgical Focus*. 2005;19(1):E3.
- [10] Kassam A, Snyderman CH, Mintz A, Gardner P, Carrau RL. Expanded endonasal approach: the rostrocaudal axis. Part II. Posterior clinoids to the foramen magnum. *Neurosurgical Focus*. 2005;19(1):E4.
- [11] Cappabianca P, Cavallo LM, Esposito F, De Divitiis O, Messina A, De Divitiis E. Extended endoscopic endonasal approach to the midline skull base: the evolving role of transsphenoidal surgery. *Advances and Technical Standards in Neurosurgery*. 2008;33:151-99.
- [12] De Notaris M, Cavallo LM, Prats-Galino A, Esposito I, Benet A, Poblete J, et al. Endoscopic endonasal transclival approach and retrosigmoid approach to the clival and petroclival regions. *Neurosurgery*. 2009;65(6 Suppl):42-50; discussion 2.
- [13] Schwartz TH, Fraser JF, Brown S, Tabae A, Kacker A, Anand VK. Endoscopic cranial base surgery: classification of operative approaches. *Neurosurgery*. 2008;62(5):991-1002; discussion 5.
- [14] Al-Mefty O, Ayoubi S, Smith RR. The petrosal approach: indications, technique, and results. *Acta Neurochirurgica Supplementum*. 1991;53:166-70.
- [15] Asaoka K, Terasaka S. Combined petrosal approach for resection of petroclival meningioma. *Neurosurgical Focus*. 2014;36(1 Suppl):1.
- [16] Goel A, Desai K, Muzumdar D. Surgery on anterior foramen magnum meningiomas using a conventional posterior suboccipital approach: a report on an experience with 17 cases. *Neurosurgery*. 2001;49(1):102-6; discussion 6-7.
- [17] Hakuba A, Liu S, Nishimura S. The orbitozygomatic infratemporal approach: a new surgical technique. *Surgical Neurology*. 1986;26(3):271-6.
- [18] Javed T, Sekhar LN. Surgical management of clival meningiomas. *Acta Neurochirurgica Supplementum*. 1991;53:171-82.
- [19] MacDonald JD, Antonelli P, Day AL. The anterior subtemporal, medial transpetrosal approach to the upper basilar artery and ponto-mesencephalic junction. *Neurosurgery*. 1998;43(1):84-9.

- [20] Samii M, Knosp E. Approaches to the Clivus: Approaches to No Man's Land. Berlin: Springer-Verlag Berlin and Heidelberg GmbH & Co. K; 23 December 2011. p. 184.
- [21] Seifert V, Raabe A, Zimmermann M. Conservative (labyrinth-preserving) transpetrosal approach to the clivus and petroclival region--indications, complications, results and lessons learned. *Acta Neurochirurgica*. 2003;145(8):631-42; discussion 642.
- [22] Sen C, Triana AI, Berglind N, Godbold J, Shrivastava RK. Clival chordomas: clinical management, results, and complications in 71 patients. *Journal of Neurosurgery*. 2010;113(5):1059-71.
- [23] Alfieri A, Jho HD, Tschabitscher M. Endoscopic endonasal approach to the ventral cranio-cervical junction: anatomical study. *Acta Neurochirurgica*. 2002;144(3):219-25; discussion 25.
- [24] Cappabianca P, Alfieri A, De Divitiis E. Endoscopic endonasal transsphenoidal approach to the sella: towards functional endoscopic pituitary surgery (FEPS). *Minimally Invasive Neurosurgery : MIN*. 1998;41(2):66-73.
- [25] Stippler M, Gardner PA, Snyderman CH, Carrau RL, Prevedello DM, Kassam AB. Endoscopic endonasal approach for clival chordomas. *Neurosurgery*. 2009;64(2):268-77; discussion 77-8.
- [26] Frank G, Sciarretta V, Calbucci F, Farneti G, Mazzatenta D, Pasquini E. The endoscopic transnasal transsphenoidal approach for the treatment of cranial base chordomas and chondrosarcomas. *Neurosurgery*. 2006;59(1 Suppl 1):ONS50-7; discussion ONS7.
- [27] Dehdashti AR, Karabatsou K, Ganna A, Witterick I, Gentili F. Expanded endoscopic endonasal approach for treatment of clival chordomas: early results in 12 patients. *Neurosurgery*. 2008;63(2):299-307; discussion 9.
- [28] Hong Jiang W, Ping Zhao S, Hai Xie Z, Zhang H, Zhang J, Yun Xiao J. Endoscopic resection of chordomas in different clival regions. *Acta Oto-Laryngologica*. 2009;129(1):71-83.
- [29] Solares CA, Fakhri S, Batra PS, Lee J, Lanza DC. Transnasal endoscopic resection of lesions of the clivus: a preliminary report. *The Laryngoscope*. 2005;115(11):1917-22.
- [30] Al-Mefty O, Borba LA. Skull base chordomas: a management challenge. *Journal of Neurosurgery*. 1997;86(2):182-9.
- [31] Fraser JF, Nyquist GG, Moore N, Anand VK, Schwartz TH. Endoscopic endonasal minimal access approach to the clivus: case series and technical nuances. *Neurosurgery*. 2010;67(3 Suppl Operative):ons150-8; discussion ons8.
- [32] Cavallo LM, Messina A, Gardner P, Esposito F, Kassam AB, Cappabianca P, et al. Extended endoscopic endonasal approach to the pterygopalatine fossa: anatomical study and clinical considerations. *Neurosurgical Focus*. 2005;19(1):E5.

- [33] Cavallo LM, Messina A, Cappabianca P, Esposito F, De Divitiis E, Gardner P, et al. Endoscopic endonasal surgery of the midline skull base: anatomical study and clinical considerations. *Neurosurgical Focus*. 2005;19(1):E2.
- [34] Daniel RT, Tuleasca C, Messerer M, Negretti L, George M, Pasche P, et al. Optimally invasive skull base surgery for large benign tumors. In: Berouma M, editor. *Minimally Invasive Skull Base Surgery*: Nova Science Publishers, Inc.; 2013.
- [35] Hadad G, Bassagasteguy L, Carrau RL, Mataza JC, Kassam A, Snyderman CH, et al. A novel reconstructive technique after endoscopic expanded endonasal approaches: vascular pedicle nasoseptal flap. *The Laryngoscope*. 2006;116(10):1882-6.
- [36] Carrabba G, Dehdashti AR, Gentili F. Surgery for clival lesions: open resection versus the expanded endoscopic endonasal approach. *Neurosurgical Focus*. 2008;25(6):E7.

