

# We are IntechOpen, the world's leading publisher of Open Access books Built by scientists, for scientists

**4,800**

Open access books available

**122,000**

International authors and editors

**135M**

Downloads

Our authors are among the

**154**

Countries delivered to

**TOP 1%**

most cited scientists

**12.2%**

Contributors from top 500 universities



**WEB OF SCIENCE™**

Selection of our books indexed in the Book Citation Index  
in Web of Science™ Core Collection (BKCI)

Interested in publishing with us?  
Contact [book.department@intechopen.com](mailto:book.department@intechopen.com)

Numbers displayed above are based on latest data collected.

For more information visit [www.intechopen.com](http://www.intechopen.com)



---

# Ovarian Cancer Research in the Post Genomic Era — Challenges and Opportunities

---

Alicia A. Goyeneche and Carlos M. Telleria

Additional information is available at the end of the chapter

<http://dx.doi.org/10.5772/60600>

---

## Abstract

The field of ovarian cancer research is undergoing major re-examination. Pathologists are defining the disease in new terms, and—having observed discrepancies in its actual cell(s) and tissue(s) of origin—are asking whether or not ovarian cancer truly represents one disease or a complex group of diseases. Further complexity was unveiled after sequencing a large number of high-grade serous ovarian cancer tumor samples (the most frequent ovarian cancer histotype). The experiments uncovered the existence of at least four different molecular subtypes, which standard pathological assessment cannot determine. These discoveries propelled a need for designing novel model systems to study the disease and to develop therapies tailored to the molecular genetics of the tumor. Though there has been no major breakthrough as regards overall patient survival of ovarian cancer in the last 50 years, this chapter summarizes the many challenges and fascinating opportunities scientists face in altering the fatal course of this disease.

**Keywords:** Epithelial ovarian cancer (EOC), the cancer genome atlas (TCGA), patient-derived xenografts (PDXs), peritoneal ovarian carcinomatosis, tumor burden, tumor dormancy, minimal residual disease (MRD), high-grade serous ovarian cancer (HGSOC), Genetically engineered mouse models (GEMM), single nucleotide polymorphisms (SNPs), Calculator of Ovarian Carcinoma Subtype Prediction (COSP)

## 1. Introduction

### 1.1. Ovarian cancer represents various diseases

Epithelial ovarian cancer (EOC) is the deadliest gynecological disease. Over 70% of patients are diagnosed at late stages when the disease has disseminated within the abdominopelvic cavity. This is due to a lack of specific symptoms and valid biomarkers to look out for in early screenings, a consequence of the poor understanding of the disease's pathobiology. Upon late diagnosis, the standardized treatment is surgery (to remove all macroscopic disease within the abdominal cavity), followed by 6 cycles of a platinating, DNA-damaging agent combined with a taxane that disrupts microtubule function. Ninety percent of patients with late diagnosis, despite showing a promising initial response to standard of care treatment, ultimately relapse and die of the disease. The 5-year survival rate for EOC has remained below 35% over the past 20 years (rev.in [1-6]).

EOC genetically and biologically represents various diseases with different sites of origin that share common anatomical locations in the abdominal cavity when symptomatic [6]. EOCs are histologically classified as low-grade serous carcinoma, endometrioid carcinoma, clear-cell carcinoma, mucinous carcinoma, and high-grade serous ovarian carcinoma (HGSOC) [4]. Mucinous ovarian tumors are frequently the result of metastatic gastrointestinal cancers. Clear ovarian cancers and endometrioid ovarian cancers likely originate from endometrioid lesions, whereas serous ovarian cancers have 3 likely sites of origin: (1) the secretory cells of the distal fallopian tubes, (2) the ovarian surface epithelium, and (3) a niche of cells found in the hilum region of the ovary in a transitional area among the ovarian surface epithelium, the mesothelium, and the tubal epithelium [7, 8]. Among serous ovarian cancers, the low-grade serous tumors often carry wild-type p53 gene, are chromosomally stable and frequently unresponsive to platinum therapy, and carry Ras mutations. In contrast, HGSOC are p53 mutant and usually highly responsive to platinum therapy, and carry widespread DNA copy changes and wild-type Ras [9].

HGSOC is the most aggressive subtype of EOC, represents the majority of cases of EOC, and causes almost 70% of all deaths from this disease [9]. The Cancer Genome Atlas (TCGA) network reported the genetic sequencing of 489 tumors histopathologically classified as HGSOC [10]. The study confirmed, in a larger cohort of patients, that the genetic signature of HGSOC involves mutation of tumor suppressor p53 in 96-97% of cases, as previously described in a smaller cohort [11], with almost 50% of the tumors having dysregulation of the homologous recombination DNA repair pathway. The study led to revisiting HGSOC in terms of its biology, response to chemotherapy, clinical outcome, and genetic subtypes [6, 9, 12].

## 2. There are insufficient model systems to study ovarian cancer in vivo

The stagnation in successfully treating patients with EOC is compounded with an insufficiency of model systems to study the disease when harbored within the abdominopelvic cavity. Four

main approaches have been used to study EOC in vivo in mice: (1) genetically engineered mouse models (GEMM) that develop EOC from the epithelium of the ovaries [13-15] or the oviducts (fallopian tubes) [16, 17]; (2) syngeneic models in which mouse EOC cells are orthotopically xenografted into the ovarian bursa [18] or the peritoneal cavity [19] of immunocompetent mice; (3) patient-derived xenografts (PDX) models in which the tumors of the patients are transplanted into the peritoneal cavity of severe immunodeficient mice (deficient in T-cells, B-cells and NK cells) [20-22]); and (4) xenografts of human EOC cells into the flanks or the abdominal cavity of nude, T-cell deficient mice [23]. Current GEMM of EOC facilitate studying the disease from its inception. Yet, due to a lack of highly specific promoters to target the presumed cells of origin, the GEMM do not develop the same genetic lesions carried by patients, and, hence, do not recapitulate the human phenotype in its entirety (rev.in [24, 25]). The use of mouse EOC cells xenografted in immunocompetent mice is highly relevant since the disease can be assessed in the presence of an intact immune system; however, the number of available models is limited [18, 19]. PDX closely recapitulate the histology of the patient's sample when placed within the peritoneal cavity as a finely minced tumor with some variability depending on the host mice. For instance, when human ovarian cancer tissues are xenografted in SCID (C.B-17/IcrHsd-Prkdc<sup>scid</sup> Lyst<sup>tg</sup>) mice, the human stroma accompanying the cancer cells is rapidly replaced with mouse stroma [22]. In contrast, in severe immunodeficient NOD-SCID IL2R $\gamma$ <sup>null</sup> (NSG) mice lacking acquired and innate immunities [26], the tumor associated human stromal cells (e.g. fibroblasts and lymphocytes) remain functional for an extended period of time [20]. Nevertheless, the xenograft of EOC into the peritoneal cavity of immunosuppressed mice recapitulates only a late phase of disease as the cells are directly deposited into the peritoneal cavity of a host. Clearly, each model system for recapitulating EOC in mouse models has shortcomings.

### **3. The progression of epithelial ovarian cancer within the abdominopelvic cavity is not easy to assess**

Studies involving the implantation of EOC cells in the peritoneal cavity (intraperitoneally; i.p.) of host mice are limited when compared to the number of studies done using EOC cells xenografted subcutaneously (s.c.) (rev.in [25, 27]). One main reason for this discrepancy is that the growth of s.c. tumors can be monitored easily using precision calipers; yet, this site fails to represent the environment of the abdominal cavity in which EOC thrive. The struggle to analyze disease progression in the peritoneal cavity is that it requires sophisticated, non-invasive, imaging approaches to follow the development of internal tumor nodules in a context of a lack of well-defined parameters of tumor burden [28]. In most studies done with i.p. xenografts, tumor burden has been assessed by recording overall survival [23], noting volume of ascites accumulated [29], or calculating the total mass of what is considered tumoral tissue after collection from the abdominal cavity at necropsy [30]. More recently, non-invasive imaging methods to evaluate tumor progression in longitudinal studies have been developed, yet their application in evaluating EOC within the peritoneal cavity has been limited [25]. Overall, information as to how EOC develops within the abdominal cavity is scarce. Preferred

sites of anatomical distribution of the tumors remain unknown as do their histopathology and molecular genetics.

#### **4. Peritoneal ovarian cancer needs to be studied in different regions of the abdominopelvic cavity**

It is feasible that solid nodules that develop, for instance, in the omentum, have a different genetic profile when compared with sibling nodules found in other sites, such as the diaphragm, the surface of the liver, the bowel, or the lower pelvic cavity. This might be due to tissues (to which each tumor foci must adapt) having different histological and physiological micro-environments, likely impinging on the behavior of the cancer cells. Depending on the nearby tissue microenvironment, cancer cells may hijack otherwise non-malignant cells in a different manner depending on the anatomical location of the foci. As a consequence, this differential tumor adaptation to the environment may explain the apparent heterogeneity observed in tumors found within the peritoneal cavity of patients at the moment of debulking surgery, sometimes leading to difficulties in making the correct histopathological diagnosis of the overall disease. Thus, there is an urgent need to (1) standardize, across a genetically-defined group of available EOC cell lines, a common set of histopathological and genetic biomarkers of disease growing in the abdominal cavity; and (2) determine if such biomarkers, despite being expressed from the same cell types of origin, show heterogeneity according to the site within the abdominal cavity where the tumor develops. For instance, evidence suggests that omental vs. ovarian sites of HGSOC patients show variability in the host stromal responses among the sites [31]. Another study using biopsies from different sites within the peritoneal cavity of patients with HGSOC show heterogeneity or clonal diversity among the tumor sites manifested by single nucleotide polymorphisms (SNPs) associated with differentially expressed genes [32].

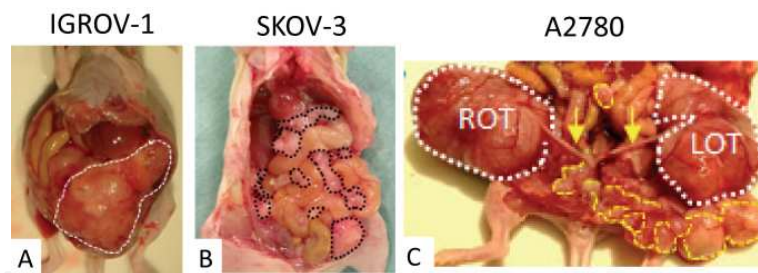
One tool currently available for characterizing the histopathological subtype of ovarian carcinomas is the Calculator of Ovarian Carcinoma Subtype Prediction (COSP), which is an algorithm that encompasses 9 predictive biomarkers and is used to differentiate histotypes of EOCs. The algorithm is freely accessible [33] and permits the scoring by immunohistochemistry, using standardized antibodies and incubation procedures, the abundances of WT1 (Wilms Tumor 1), p16 (cyclin dependent kinase inhibitor 2A; CDKN2A), DKK1 (dickkopf homolog 1), VIM (vimentin), p53 (TP53), PRG (progesterone receptor), TFF3 (trefoil factor 3 [intestinal]), HNF1B (hepatocyte nuclear factor 1 $\beta$ ) and MDM2 (mouse double minute 2). The scores for these markers are 0 or 1, except for p53 that has scores of 0 (no expression denoting null p53), 1 (low abundance for wild type p53), or 2 (high abundance for mutant p53). For instance, for the Kuramochi ovarian cancer cell line (see later Table 1), the algorithm predicts a HGSOC histotype with 97% probability, whereas for the popular A2780 ovarian cancer cell line (see later Fig.1), the algorithm predicts an endometrioid histotype with 94% probability [34]. A limitation to the algorithm is its difficulty in clearly differentiating between low-grade and high-grade serous histotypes. However, low-grade serous ovarian carcinomas only account for ~3% of all [35]. Furthermore, a combination of histological assessment and



molecular genetic profiles should be able to distinguish between these two serous ovarian cancer subtypes.

## 5. Most popular epithelial ovarian cancer cell lines used to study peritoneal carcinomatosis in mouse models give rise to disparate intra-abdominal disease phenotypes

Common EOC cell lines, utilized for years in preclinical studies, were evaluated for their ability to cause i.p. tumors [23]. ES-2, A2780, and HEY cells (all originally diagnosed as undifferentiated carcinomas), OV2008 (likely originated from an endometrial carcinoma), and SKOV-3 (which depicts a clear-cell adenocarcinoma histotype in xenografts) all develop intra-abdominal tumors in less than 3 months. The tumors are described as “dense solid,” often accompanied by accumulation of cellular ascites. Our experience with widely used EOC cell lines reveals different times for the establishment of the xenografts and highly diverse anatomical depiction of the solid growths within the abdominal cavity among the different cell lines. IGROV-1 cells generate large solid masses termed omental cakes that expand toward the lower pelvic cavity (Fig.1A). SKOV-3 cells develop small yet multiple nodules in the mesentery and the omentum (Fig.1B), while A2780 cells develop large solid masses, taking the ovaries and the lower pelvic cavity (Fig.1C). The diversity in anatomical growths is likely due to the varied histotypes and genetic profiles represented by these cell lines (see later) [36].



**Figure 1.** Peritoneal disease caused by IGROV-1 (A), SKOV-3 (B), and A2780 (C) EOC cells. The images were taken after 4 weeks of injection for IGROV-1, 10 weeks for SKOV-3, and 6 weeks for A2780 tumors. In A, the growth within the peritoneal cavity is mostly confined to an “omental cake” (white area). In B, dotted black areas show solid tumors adhering to fat in the pelvic region, intestines, and mesentery. In C, right (ROT) and left (LOT) ovarian tumors clearly are connected to the uterine horns (yellow arrows). Ovaries carrying tumors have more blood supply and are larger than the rest of the peritoneal, pale nodules (yellow pattern).

## 6. The majority of epithelial ovarian cancer cell lines used for preclinical studies do not embody the most frequent histotype of the disease

Based on the genetic signatures published from over 50 human ovarian cancer cell lines widely available, out of the approximately 100 that have been described in the literature [36-38], it is

apparent that the vast majority of the cell lines overwhelmingly used for over 30 years to study the disease have a genotype which does not resemble the most predominant histotype of EOC, HGSOCs. This may be a major contributing factor in the failure to bring new and effective treatments of HGSOC to clinical practice.

The cell lines currently characterized as likely representing HGSOC [36-38] were developed in the 1970s and 1980s and have been poorly described. Oftentimes they lack information on the original histopathological diagnosis, are poorly linked to patient data, and were developed from ascites or solid nodules following an array of protocols not always clearly stated. It is imperative that biomedical researchers worldwide join efforts to develop new, highly standardized and annotated ovarian cancer cell lines. These cell lines should be developed under similar isolation and culture protocols as to prevent inter-laboratory variations in their behavior, thus accelerating the creation of new knowledge in the field of preclinical ovarian cancer modelling and therapy. By taking advantage of the progress made in the area of molecular genetics and ovarian cancer biology, it is time to generate new cell lines that genetically and histopathologically can be characterized as pertaining, for instance, to the HGSOC histotype, and, within it, to each one of the molecular subtypes described by Tothill et al. [39] and later on confirmed in a larger cohort of patients [10]. Additionally, there is a timely opportunity to utilize these biological resources with the objective of standardizing mouse models of intra-abdominal disease caused by genetically-identified HGSOC cells.

## **7. The need for an expanded definition of tumor burden when referring to peritoneal ovarian cancer carcinomatosis**

Limiting preclinical analysis of tumor burden to overall survival, tumor mass, or volume of ascites accumulated is not sufficient if we are to find early metrics of response to new therapies as well as early signs and symptoms of the disease. Re-defining tumor burden in peritoneal ovarian cancer in a comprehensive manner should provide investigators worldwide with multifaceted metrics—*anatomical, physiological, and behavioral*—to be followed to understand the biology of the progression of EOC and, most importantly, that of the most frequent HGSOC type. The metrics should also allow inter-laboratory and inter-cell line comparisons of HGSOC as a unique disease, provide standardized benchmarks for testing new preclinical therapies, reveal markers of disease state with clinical implications for earlier diagnosis, and provide a baseline reference for the validation of new HGSOC cell lines established from patients with well-documented medical history and annotated histopathological diagnosis of HGSOC.

Based on recently published genotypes [36-38], it is feasible to begin redefining peritoneal ovarian tumor burden by utilizing the currently available cell lines that have the highest probability of genetically representing HGSOC (some examples are displayed in Table 1). Despite that each cell line was established using different culture conditions, we should standardize all cell lines to grow under the same culture conditions to avoid bias and proceed to authenticate them using DNA microsatellite short tandem repeats (STR) as recently

recommended [37]. Only cell lines which match their STR public genetic database 90-100% should be used worldwide [40]. Validated cell lines may be injected i.p. in the lower pelvic region of widely available immunosuppressed female mice lacking T-cell function (Hsd: Athymic Nude-*Foxn1*<sup>nu</sup>) or in severe immunodeficient NOD/SCID/IL2R $\gamma$ <sup>null</sup> mice lacking acquired and innate immunities [26]. Disease progression can then be followed and the signs and symptoms contrasted against non-cancerous, age-matched controls studied in parallel.

The animals can be monitored to record body weight, abdominal circumference, body temperature, and food/water intake to build a clinical history of each animal as the disease progresses, using biomarkers of tumor progression [41]. The experimental animals and age-matched, non-cancer controls also can be subjected to a battery of behavioral tests to assess visceral pain, motor function, and depression-like behavior (helplessness and social withdrawal). In animal models of EOC, depressive-like behaviors may be facilitated by the production of inflammatory cytokines from the cancer cells acting at the level of brain regions like the hippocampus [42, 43] and thus, may be a sensitive marker of disease state. Finally, these parameters can be completed with longitudinal, intra-abdominal anatomy of the tumor-carrying mice using non-invasive imaging approaches (e.g. micro-ultrasound) [44, 45]. The recorded images can then be analyzed longitudinally to identify the formation and progression of intra-abdominal solid masses and accumulation of ascites fluid. On selected masses, it is also possible to study vascularity using 3D power Doppler ultrasound [46, 47].

Cell Line	Original Histological Classification
KURAMOCHI*	undifferentiated
OVSAHO*	serous
SNU119*	serous
COV362*	endometrioid
OVCAR4*	undifferentiated
COV318*†	serous
JHOS4*†	serous
PEO1**†	serous
PEO4**†	serous
PEO6**	serous
PEO14**†	serous
TO14**	serous
PEO23**†	serous
PEA1**†	serous
PEA2**†	serous

\* [36]; \*\* [38]; † [37].

**Table 1.** Epithelial ovarian cancer cell lines with likely HGSOC genomic classification.

The accumulation of bloody ascites in the abdominopelvic cavity suggests that changes in vascular integrity, with possible effects on blood pressure and oxygen delivered, are taking



place. Indeed, declines in oxygenation and blood pressure have been suggested as biomarkers of peritoneal tumor progression [28]. Thus, as part of a comprehensive approach for assessing tumor burden, we suggest determining the level of peripheral blood oxygen saturation [48] and blood pressure [49]. Finally, we propose completing the assessment of tumor burden by taking a blood sample from the animals in order to (1) measure cancer antigen CA-125 used as a biomarker of EOC disease progression [50]; (2) study hematological parameters that can be altered due to tumor burden—e.g. red and white blood cell counts, platelets, hemoglobin concentration, and hematocrit; (3) perform chemical analysis of GOT (glutamic oxaloacetic transaminase) and GPT (glutamic pyruvic transaminase) as surrogate markers of hepatic function; (4) measure serum levels of creatinine and urea as surrogate markers of renal function; and (5) measure serum levels of estradiol and progesterone, since they impact the outcome of the behavioral tests suggested above.

## 8. Understanding all cellular components of advanced disease

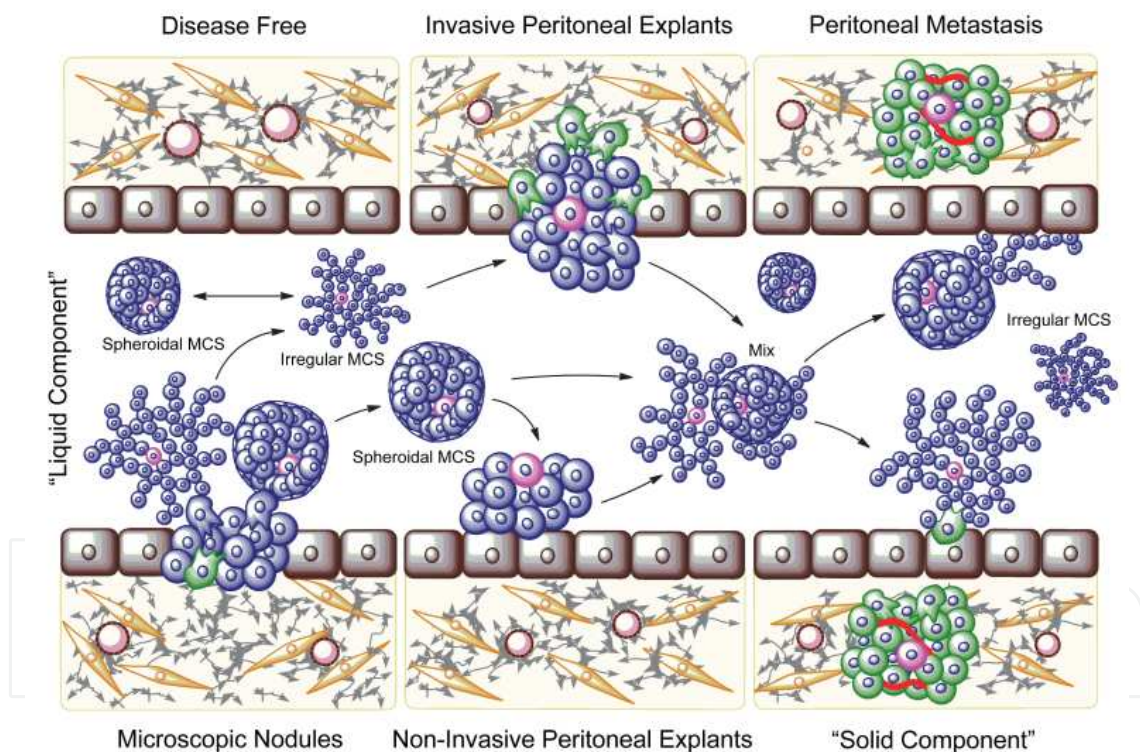
In ovarian cancer, metastasis through the vasculature is rare and a very late manifestation of the disease. Instead, ovarian cancer cells are prone to spread by direct extension from the ovaries to adjacent tissues, or to detach from the primary ovarian tumor directly into the peritoneal cavity where they seed the mesothelium of the omentum, diaphragm, bowel serosa, and the entire peritoneum [51-53]. Widespread visceral and intestinal wall metastases with formation of adhesions between the loops of the bowel cause intestinal obstruction, prevent normal nutrition, and become a primary cause of death [1].

The high incidence (65%) of peritoneal malignant effusions in ovarian cancer patients at advanced presentation [54, 55], and the development of symptoms due to ascites accumulation at diagnosis as well as recurrence [56], suggest that the “liquid” component is an active pathogenic manifestation of the disease. Ovarian cancer cells isolated from peritoneal ascites of major ovarian cancer histological types were described as organized structures of different sizes and heterogeneous morphology [57]. Furthermore, multicellular structures isolated directly from ascites were shown capable of adhering *ex vivo* to components of the extracellular matrix and to monolayers of mesothelial cells, suggesting their participation in the dissemination of ovarian cancer [58]. Cancer cells isolated from ascites and metastatic secondary sites exhibit a higher percentage of stemness markers when compared to their primary tumors [59-61]. Additionally, cancer-associated proteins and mRNAs are differentially expressed in peritoneal effusions when compared to primary carcinomas or solid metastases. Lastly, there is a differential gene expression among peritoneal effusions when comparing samples at diagnosis (pre-chemotherapy) vs. samples at recurrence (post-chemotherapy) [62]. Altogether, these data suggest that cancer cells within effusions—the “liquid” component of ovarian cancer—represent a biomarker of tumor evolution toward a more aggressive/advanced disease phenotype of poor prognosis.

Most of our understanding of the biology of ovarian cancer multicellular structures is based on the premise that mono-dispersed ovarian cancer cells, when gathering together either by

enforced gravity or prevention of adhesion, mimic the program of assembly followed by ovarian cancer multicellular structures found within malignant effusions [63, 64]. Therefore, it is of importance to define if ovarian cancer multicellular structures found in ascites represent aggregation following shedding from solid tumors or, instead, are active products of disease selection and critical drivers of disease advancement and prognosis (Fig.2).

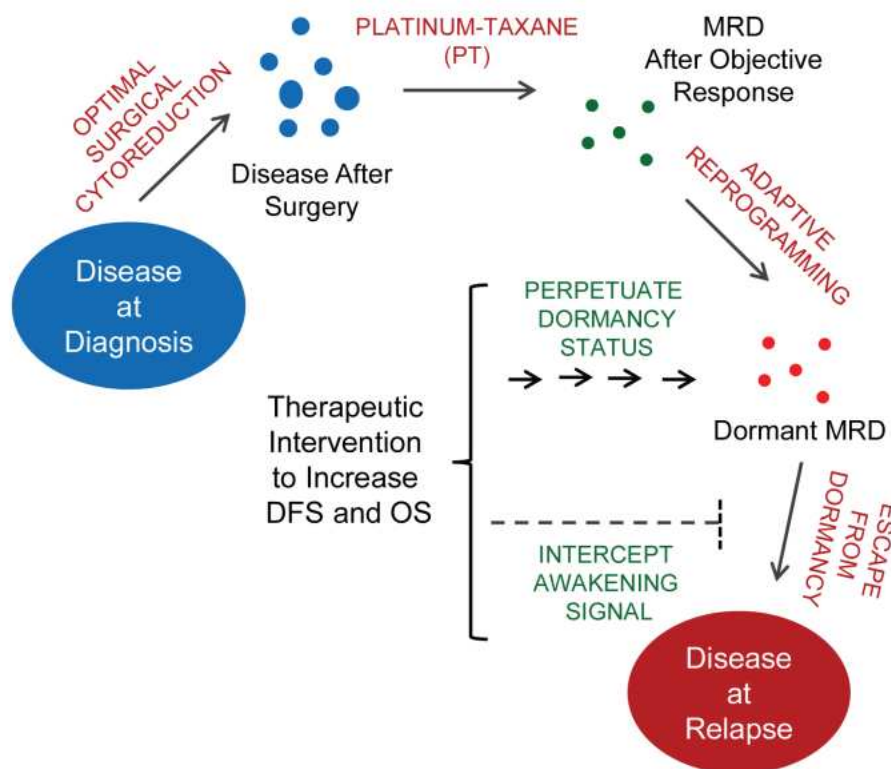
While the presence of multicellular structures in ascites was reported over 25 years ago [57], their biology has been studied using in vitro platforms and multicellular structures that were forced to form from ovarian cancer cell lines by using either gravity or non-adherent conditions. We should investigate the pathogenic capacity of unforced, spontaneously arranged ovarian cancer multicellular structures in vivo. If a key mechanism for ovarian cancer progression takes place within the “liquid” component of the disease, then multicellular structures may represent a druggable target. Developing therapeutic interventions to interrupt formation of multicellular structures free-floating in the peritoneal fluid may be an efficient way of interrupting disease advancement.



**Figure 2.** Proposed model for the role of ovarian cancer multicellular structures (MCS) in peritoneal carcinomatosis. Selected cells from microscopic nodules with distinctive capacity to form MCS, adapt, survive, and grow in the peritoneal fluid developing irregular and organized spheroidal MCS that might evade chemotherapy and/or preserve ovarian cancer initiating cells (CIC), leading to a feed-forward, chemo-resistant, and self-renewal recurrent seeding. MCS committed to develop the solid component of the disease will adhere, disaggregate, migrate, and invade the mesothelial cell layer covering the surface of the peritoneum (maroon), and form foci that neo-vascularize and grow (green). Other MCS might develop non-invasive nodules that amplify the cellularity within the “liquid” compartment causing ascites. Blue: highly differentiated ovarian cancer cells. Pink: less differentiated ovarian cancer cells with self-renewal capacity. Red: new blood vessels. Gray: extracellular matrix. Yellow: fibroblasts.

## 9. Understanding dormancy after “successful” standard of care (surgery and chemotherapy)

Although most patients diagnosed with ovarian cancer undergo remission after optimal surgical cytoreduction and platinum-taxane chemotherapy, microscopic foci of cells manage to survive within the peritoneal cavity and recreate the illness. Recurrence develops a more aggressive phenotype for which current therapies almost always fail (rev.in [1-6]). Thus, understanding the biology of minimal residual disease is crucial in developing effective therapies for ovarian cancer.



**Figure 3.** Hypothetical model of ovarian cancer dormancy after debulking surgery and platinum–taxane (PT) therapy, relapse after chemotherapy-associated dormancy, and potential stages of the disease where therapeutic intervention is envisioned. DFS, disease free survival; OS, overall survival. MRD, minimal residual disease.

Within the minimal residual disease, ovarian cancer cells are in a unique, subclinical, biological stage termed dormancy. Long recognized in the clinic, *dormancy* describes a period of time that can last many years between primary therapy and recurrence of metastatic disease (rev.in [65]). In ovarian cancer, dormancy was reported to be represented by small, poorly vascularized fibrotic nodules located on the surface of the peritoneum in patients undergoing second-look surgery after front-line debulking operation and chemotherapy [66]. Dormant cancer cells are usually defined as survivors of primary therapy likely containing drug-resistant, tumor-

initiating cells. They are kept either in a status of cell cycle arrest (quiescence) or equilibrium among proliferating and dying cells to preserve constant micro-tumor mass (rev.in [65]). Attempts to eliminate dormant ovarian cancer cells with maintenance therapies have not been efficient: they extend progression-free survival but not overall survival [67, 68].

It is important to investigate the magnitude and location of the disease still present following an objective response to front-line therapy, and characterize the adaptive molecular reprogramming after chemotherapy leading to the dormant status of the cells comprising the minimal residual disease (Fig.3). Chemotherapy-associated tumor dormancy and awakening from dormancy likely have defined molecular signatures that can be unveiled by combined use of currently available transcriptomic, proteomic, and epigenomic platforms that can be integrated utilizing multipronged bioinformatic tools. Knowing the mechanism(s) ovarian cancer cells utilize to achieve dormancy in the peritoneum and awake from it will provide two potential avenues for intervention as follows: (1) perpetuation of the dormant status of the cancer; and/or (2) interception of the awakening signal that causes disease relapse (Fig.3).

Whereas total elimination of ovarian cancer cells is the ideal goal, the alternative approach of keeping ovarian cancer in a chronic dormant state is highly relevant as this would categorize ovarian cancer patients with an objective response to front-line standard of care as having a chronic manageable disease or “cancer without disease.”

## 10. Conclusions

Progresses made in the field of molecular oncology within the last decade have been remarkable. The use of RNA sequencing, micro RNA expression profiles, mutation analysis, shotgun proteomics, reverse-phase protein arrays, and epigenomic platforms, together with novel imaging tools, should be applied in uncovering the hidden secrets of ovarian cancer initiation and progression, and in developing early diagnostic tools. Understanding the location and molecular behavior of the abdominopelvic minimal residual disease after otherwise efficient front-line chemotherapy should lead to the discovery of new molecular targets for disease interception that can be exploited to prevent recurrence. We are at a point in time in which we have a unique opportunity to utilize the vast state-of-the-art technological armamentarium developed in the past decade to revisit the basic biology of peritoneal ovarian cancer and renew hopes for bettering the prognosis of this deadly disease.

## Acknowledgements

This research was supported by award CA164622 from the National Cancer Institute, the National Institutes of Health (NIH), funds from the Division of Basic Biomedical Sciences of the Sanford School of Medicine of the University of South Dakota, and a donation from the SuFuDu Drumline. We thank Nahuel Telleria for proofreading the manuscript.



## Author details

Alicia A. Goyeneche<sup>1</sup> and Carlos M. Telleria<sup>2\*</sup>

\*Address all correspondence to: carlos.telleria@mcgill.ca

1 Division of Basic Biomedical Sciences, Sanford School of Medicine, The University of South Dakota, Vermillion, South Dakota, USA

2 Department of Pathology, McGill University, Montreal, Canada

## References

- [1] Bast RC, Jr., Hennessey B, Mills GB. The biology of ovarian cancer: new opportunities for translation. *Nature Reviews Cancer*. 2009;9:415-28.
- [2] Bast RC, Jr. Molecular approaches to personalizing management of ovarian cancer. *Annals of Oncology : Official Journal of the European Society for Medical Oncology / ESMO*. 2011;22 Suppl 8:viii5-viii15.
- [3] Coleman RL, Monk BJ, Sood AK, Herzog TJ. Latest research and treatment of advanced-stage epithelial ovarian cancer. *Nature Reviews Clinical Oncology*. 2013;10:211-24.
- [4] Kurman RJ, Shih Ie M. Molecular pathogenesis and extraovarian origin of epithelial ovarian cancer--shifting the paradigm. *Human Pathology*. 2011;42:918-31.
- [5] Romero I, Bast RC, Jr. Minireview: human ovarian cancer: biology, current management, and paths to personalizing therapy. *Endocrinology*. 2012;153:1593-602.
- [6] Vaughan S, Coward JI, Bast RC, Jr., Berchuck A, Berek JS, Brenton JD, et al. Rethinking ovarian cancer: recommendations for improving outcomes. *Nature Reviews Cancer*. 2011;11:719-25.
- [7] Auersperg N. The origin of ovarian carcinomas: a unifying hypothesis. *International Journal of Gynecological Pathology : Official Journal of the International Society of Gynecological Pathologists*. 2011;30:12-21.
- [8] Flesken-Nikitin A, Hwang CI, Cheng CY, Michurina TV, Enikolopov G, Nikitin AY. Ovarian surface epithelium at the junction area contains a cancer-prone stem cell niche. *Nature*. 2013;495:241-5.
- [9] Bowtell DD. The genesis and evolution of high-grade serous ovarian cancer. *Nature Reviews Cancer*. 2010;10:803-8.



- [10] Cancer Genome Atlas Research N. Integrated genomic analyses of ovarian carcinoma. *Nature*. 2011;474:609-15.
- [11] Ahmed AA, Etemadmoghadam D, Temple J, Lynch AG, Riad M, Sharma R, et al. Driver mutations in TP53 are ubiquitous in high grade serous carcinoma of the ovary. *The Journal of Pathology*. 2010;221:49-56.
- [12] Berns EM, Bowtell DD. The changing view of high-grade serous ovarian cancer. *Cancer Research*. 2012;72:2701-4.
- [13] Connolly DC, Bao R, Nikitin AY, Stephens KC, Poole TW, Hua X, et al. Female mice chimeric for expression of the simian virus 40 TAG under control of the MISIR promoter develop epithelial ovarian cancer. *Cancer Research*. 2003;63:1389-97.
- [14] Laviolette LA, Garson K, Macdonald EA, Senterman MK, Courville K, Crane CA, et al. 17beta-estradiol accelerates tumor onset and decreases survival in a transgenic mouse model of ovarian cancer. *Endocrinology*. 2010;151:929-38.
- [15] Orsulic S, Li Y, Soslow RA, Vitale-Cross LA, Gutkind JS, Varmus HE. Induction of ovarian cancer by defined multiple genetic changes in a mouse model system. *Cancer Cell*. 2002;1:53-62.
- [16] Karst AM, Levanon K, Drapkin R. Modeling high-grade serous ovarian carcinogenesis from the fallopian tube. *Proceedings of the National Academy of Sciences of the United States of America*. 2011;108:7547-52.
- [17] Kim J, Coffey DM, Creighton CJ, Yu Z, Hawkins SM, Matzuk MM. High-grade serous ovarian cancer arises from fallopian tube in a mouse model. *Proceedings of the National Academy of Sciences of the United States of America*. 2012;109:3921-6.
- [18] Roby KF, Taylor CC, Sweetwood JP, Cheng Y, Pace JL, Tawfik O, et al. Development of a syngeneic mouse model for events related to ovarian cancer. *Carcinogenesis*. 2000;21:585-91.
- [19] McCloskey CW, Goldberg RL, Carter LE, Gamwell LF, Al-Hujaily EM, Collins O, et al. A new spontaneously transformed syngeneic model of high-grade serous ovarian cancer with a tumor-initiating cell population. *Frontiers in Oncology*. 2014;4:53.
- [20] Bankert RB, Balu-Iyer SV, Odunsi K, Shultz LD, Kelleher RJ, Jr., Barnas JL, et al. Humanized mouse model of ovarian cancer recapitulates patient solid tumor progression, ascites formation, and metastasis. *PloS One*. 2011;6:e24420.
- [21] Elkas JC, Baldwin RL, Pegram M, Tseng Y, Slamon D, Karlan BY. A human ovarian carcinoma murine xenograft model useful for preclinical trials. *Gynecologic Oncology*. 2002;87:200-6.
- [22] Weroha SJ, Becker MA, Enderica-Gonzalez S, Harrington SC, Oberg AL, Maurer MJ, et al. Tumorgrafts as in vivo surrogates for women with ovarian cancer. *Clinical Can-*

- cer Research : An Official Journal of the American Association for Cancer Research. 2014;20:1288-97.
- [23] Shaw TJ, Senterman MK, Dawson K, Crane CA, Vanderhyden BC. Characterization of intraperitoneal, orthotopic, and metastatic xenograft models of human ovarian cancer. *Molecular Therapy : The Journal of the American Society of Gene Therapy*. 2004;10:1032-42.
- [24] Garson K, Gamwell LF, Pitre EM, Vanderhyden BC. Technical challenges and limitations of current mouse models of ovarian cancer. *Journal of Ovarian Research*. 2012;5:39.
- [25] Lengyel E, Burdette JE, Kenny HA, Matei D, Pilrose J, Haluska P, et al. Epithelial ovarian cancer experimental models. *Oncogene*. 2014;33:3619-33.
- [26] Ito M, Hiramatsu H, Kobayashi K, Suzue K, Kawahata M, Hioki K, et al. NOD/SCID/gamma(c)(null) mouse: an excellent recipient mouse model for engraftment of human cells. *Blood*. 2002;100:3175-82.
- [27] Konstantinopoulos PA, Matulonis UA. Current status and evolution of preclinical drug development models of epithelial ovarian cancer. *Frontiers in Oncology*. 2013;3:296.
- [28] Workman P, Aboagye EO, Balkwill F, Balmain A, Bruder G, Chaplin DJ, et al. Guidelines for the welfare and use of animals in cancer research. *British Journal of Cancer*. 2010;102:1555-77.
- [29] Hu L, Hofmann J, Lu Y, Mills GB, Jaffe RB. Inhibition of phosphatidylinositol 3'-kinase increases efficacy of paclitaxel in in vitro and in vivo ovarian cancer models. *Cancer Research*. 2002;62:1087-92.
- [30] Hu L, Hofmann J, Zaloudek C, Ferrara N, Hamilton T, Jaffe RB. Vascular endothelial growth factor immunoneutralization plus Paclitaxel markedly reduces tumor burden and ascites in athymic mouse model of ovarian cancer. *The American Journal of Pathology*. 2002;161:1917-24.
- [31] Kobel M, Turbin D, Kalloger SE, Gao D, Huntsman DG, Gilks CB. Biomarker expression in pelvic high-grade serous carcinoma: comparison of ovarian and omental sites. *International Journal of Gynecological Pathology : Official Journal of the International Society of Gynecological Pathologists*. 2011;30:366-71.
- [32] Cowin PA, George J, Fereday S, Loehrer E, Van Loo P, Cullinane C, et al. LRP1B deletion in high-grade serous ovarian cancers is associated with acquired chemotherapy resistance to liposomal doxorubicin. *Cancer Research*. 2012;72:4060-73.
- [33] Kalloger SE, Kobel M, Leung S, Mehl E, Gao D, Marcon KM, et al. Calculator for ovarian carcinoma subtype prediction. *Modern Pathology : An Official Journal of the United States and Canadian Academy of Pathology, Inc*. 2011;24:512-21.

- [34] Anglesio MS, Wiegand KC, Melnyk N, Chow C, Salamanca C, Prentice LM, et al. Type-specific cell line models for type-specific ovarian cancer research. *PloS One*. 2013;8:e72162.
- [35] Kobel M, Kalloger SE, Huntsman DG, Santos JL, Swenerton KD, Seidman JD, et al. Differences in tumor type in low-stage versus high-stage ovarian carcinomas. *International Journal of Gynecological Pathology : Official Journal of the International Society of Gynecological Pathologists*. 2010;29:203-11.
- [36] Domcke S, Sinha R, Levine DA, Sander C, Schultz N. Evaluating cell lines as tumour models by comparison of genomic profiles. *Nature Communications*. 2013;4:2126.
- [37] Beaufort CM, Helmijr JC, Piskorz AM, Hoogstraat M, Ruigrok-Ritstier K, Besselink N, et al. Ovarian cancer cell line panel (OCCP): clinical importance of in vitro morphological subtypes. *PloS One*. 2014;9:e103988.
- [38] Cooke SL, Ng CK, Melnyk N, Garcia MJ, Hardcastle T, Temple J, et al. Genomic analysis of genetic heterogeneity and evolution in high-grade serous ovarian carcinoma. *Oncogene*. 2010;29:4905-13.
- [39] Tothill RW, Tinker AV, George J, Brown R, Fox SB, Lade S, et al. Novel molecular subtypes of serous and endometrioid ovarian cancer linked to clinical outcome. *Clinical Cancer Research : An Official Journal of the American Association for Cancer Research*. 2008;14:5198-208.
- [40] Marx V. Cell line authentication demystified. *Nature Methods*. 2014;11:483-8.
- [41] Hunter JE, Butterworth J, Perkins ND, Bateson M, Richardson CA. Using body temperature, food and water consumption as biomarkers of disease progression in mice with Emu-myc lymphoma. *British Journal of Cancer*. 2014;110:928-34.
- [42] Lamkin DM, Lutgendorf SK, Lubaroff D, Sood AK, Beltz TG, Johnson AK. Cancer induces inflammation and depressive-like behavior in the mouse: modulation by social housing. *Brain, Behavior, and Immunity*. 2011;25:555-64.
- [43] Yang M, Kim J, Kim JS, Kim SH, Kim JC, Kang MJ, et al. Hippocampal dysfunctions in tumor-bearing mice. *Brain, Behavior, and Immunity*. 2014;36:147-55.
- [44] Graham KC, Wirtzfeld LA, MacKenzie LT, Postenka CO, Groom AC, MacDonald IC, et al. Three-dimensional high-frequency ultrasound imaging for longitudinal evaluation of liver metastases in preclinical models. *Cancer Research*. 2005;65:5231-7.
- [45] Wirtzfeld LA, Wu G, Bygrave M, Yamasaki Y, Sakai H, Moussa M, et al. A new three-dimensional ultrasound microimaging technology for preclinical studies using a transgenic prostate cancer mouse model. *Cancer Research*. 2005;65:6337-45.
- [46] Jugold M, Palmowski M, Huppert J, Woenne EC, Mueller MM, Semmler W, et al. Volumetric high-frequency Doppler ultrasound enables the assessment of early anti-

- angiogenic therapy effects on tumor xenografts in nude mice. *European Radiology*. 2008;18:753-8.
- [47] Xuan JW, Bygrave M, Jiang H, Valiyeva F, Dunmore-Buyze J, Holdsworth DW, et al. Functional neoangiogenesis imaging of genetically engineered mouse prostate cancer using three-dimensional power Doppler ultrasound. *Cancer Research*. 2007;67:2830-9.
- [48] Verhoeven D, Teijaro JR, Farber DL. Pulse-oximetry accurately predicts lung pathology and the immune response during influenza infection. *Virology*. 2009;390:151-6.
- [49] Feng M, Whitesall S, Zhang Y, Beibel M, D'Alecy L, DiPetrillo K. Validation of volume-pressure recording tail-cuff blood pressure measurements. *American Journal of Hypertension*. 2008;21:1288-91.
- [50] Rustin GJ, Bast RC, Jr., Kelloff GJ, Barrett JC, Carter SK, Nisen PD, et al. Use of CA-125 in clinical trial evaluation of new therapeutic drugs for ovarian cancer. *Clinical Cancer Research : An Official Journal of the American Association for Cancer Research*. 2004;10:3919-26.
- [51] Lengyel E. Ovarian cancer development and metastasis. *The American Journal of Pathology*. 2010;177:1053-64.
- [52] Naora H, Montell DJ. Ovarian cancer metastasis: integrating insights from disparate model organisms. *Nature Reviews Cancer*. 2005;5:355-66.
- [53] Tan DS, Agarwal R, Kaye SB. Mechanisms of transcoelomic metastasis in ovarian cancer. *The Lancet Oncology*. 2006;7:925-34.
- [54] Davidson B, Risberg B, Reich R, Berner A. Effusion cytology in ovarian cancer: new molecular methods as aids to diagnosis and prognosis. *Clinics in Laboratory Medicine*. 2003;23:729-54, viii.
- [55] Puls LE, Duniho T, Hunter JE, Kryscio R, Blackhurst D, Gallion H. The prognostic implication of ascites in advanced-stage ovarian cancer. *Gynecologic Oncology*. 1996;61:109-12.
- [56] Kipps E, Tan DS, Kaye SB. Meeting the challenge of ascites in ovarian cancer: new avenues for therapy and research. *Nature Reviews Cancer*. 2013;13:273-82.
- [57] Allen HJ, Porter C, Gamarra M, Piver MS, Johnson EA. Isolation and morphologic characterization of human ovarian carcinoma cell clusters present in effusions. *Experimental Cell Biology*. 1987;55:194-208.
- [58] Burleson KM, Casey RC, Skubitz KM, Pambuccian SE, Oegema TR, Jr., Skubitz AP. Ovarian carcinoma ascites spheroids adhere to extracellular matrix components and mesothelial cell monolayers. *Gynecologic Oncology*. 2004;93:170-81.

- [59] Alvero AB, Chen R, Fu HH, Montagna M, Schwartz PE, Rutherford T, et al. Molecular phenotyping of human ovarian cancer stem cells unravels the mechanisms for repair and chemoresistance. *Cell Cycle*. 2009;8:158-66.
- [60] Bapat SA, Mali AM, Koppikar CB, Kurrey NK. Stem and progenitor-like cells contribute to the aggressive behavior of human epithelial ovarian cancer. *Cancer Research*. 2005;65:3025-9.
- [61] Zhang S, Balch C, Chan MW, Lai HC, Matei D, Schilder JM, et al. Identification and characterization of ovarian cancer-initiating cells from primary human tumors. *Cancer Research*. 2008;68:4311-20.
- [62] Davidson B, Reich R, Trope CG, Wang TL, Shih Ie M. New determinates of disease progression and outcome in metastatic ovarian carcinoma. *Histology and Histopathology*. 2010;25:1591-609.
- [63] Burleson KM, Hansen LK, Skubitz AP. Ovarian carcinoma spheroids disaggregate on type I collagen and invade live human mesothelial cell monolayers. *Clinical and Experimental Metastasis*. 2004;21:685-97.
- [64] Shield K, Ackland ML, Ahmed N, Rice GE. Multicellular spheroids in ovarian cancer metastases: Biology and pathology. *Gynecologic Oncology*. 2009;113:143-8.
- [65] Goss PE, Chambers AF. Does tumour dormancy offer a therapeutic target? *Nature Reviews Cancer*. 2010;10:871-7.
- [66] Gadducci A, Tana R, Landoni F, Ferrari F, Peiretti M, Perrone F, et al. Analysis of failures and clinical outcome of advanced epithelial ovarian cancer in patients with microscopic residual disease at second-look reassessment following primary cytoreductive surgery and first-line platinum-based chemotherapy. *European Journal of Gynaecological Oncology*. 2013;34:213-7.
- [67] Markman M, Liu PY, Moon J, Monk BJ, Copeland L, Wilczynski S, et al. Impact on survival of 12 versus 3 monthly cycles of paclitaxel (175 mg/m<sup>2</sup>) administered to patients with advanced ovarian cancer who attained a complete response to primary platinum-paclitaxel: follow-up of a Southwest Oncology Group and Gynecologic Oncology Group phase 3 trial. *Gynecologic Oncology*. 2009;114:195-8.
- [68] Perren TJ, Swart AM, Pfisterer J, Ledermann JA, Pujade-Lauraine E, Kristensen G, et al. A phase 3 trial of bevacizumab in ovarian cancer. *The New England Journal of Medicine*. 2011;365:2484-96.



