

We are IntechOpen, the world's leading publisher of Open Access books Built by scientists, for scientists

4,800

Open access books available

122,000

International authors and editors

135M

Downloads

Our authors are among the

154

Countries delivered to

TOP 1%

most cited scientists

12.2%

Contributors from top 500 universities



WEB OF SCIENCE™

Selection of our books indexed in the Book Citation Index
in Web of Science™ Core Collection (BKCI)

Interested in publishing with us?
Contact book.department@intechopen.com

Numbers displayed above are based on latest data collected.
For more information visit www.intechopen.com



Endoscopic Management of Pediatric Airway and Esophageal Foreign Bodies

Phillip L. Chaffin, Jonathan M. Grischkan,
Prashant S. Malhotra and Kris R. Jatana

Additional information is available at the end of the chapter

<http://dx.doi.org/10.5772/60590>

Abstract

The use of endoscopy is critical to the management of pediatric tracheobronchial and esophageal foreign bodies. Children may present with nonspecific symptoms, and the diagnosis can be difficult when the ingestion or aspiration events go unwitnessed. Advances in endoscopic techniques and the use of optical graspers in the removal of foreign bodies in children have helped decrease morbidity and mortality. In this chapter, the history, clinical presentations, workup, and management for pediatric aerodigestive foreign bodies are discussed.

Keywords: foreign body, pediatric airway, esophagus, endoscopic, aspiration, ingestion

1. Introduction

The history of endoscopic management of pediatric foreign bodies was predated by significant innovations allowing for the evolution of adult and pediatric bronchoesophagology. Prior to these advances, tracheotomy was the accepted method for successful removal of airway foreign bodies [1]. In 1806, Philipp Bozzini, reported using the "lichtleiter" or "light conductor" to visualize the upper esophagus using candle illumination [2]. While his instruments and methods did not gain wide acceptance during his lifetime, they set the stage for further innovations that occurred over the ensuing decades. Desormeaux, a urologist, is credited with coining the term "endoscopy" in 1867 [3] and is considered by most to be the "Father of

Endoscopy" [4]. Kussmaul is credited with performing the first direct esophagoscopy, and his student Killian further explored these techniques and instrumentation. Mikulicz further refined the techniques and instrumentation of esophagoscopy, bringing it into more common use [5].

In 1895, Alfred Kirstein, a laryngologist in Berlin who was familiar with the work of Kussmaul and Mikulicz, was the first to directly visualize the larynx and trachea [6]. Killian became interested in Kirstein's achievements and began to practice laryngoscopy on cadavers and tracheotomized patients. In 1897, he was the first to remove a foreign body from the right mainstem bronchus of an adult via the translaryngeal route. His contributions and achievements have prompted many to consider him the "Father of Bronchoscopy" [7]. Following these innovations, tracheoscopy and bronchoscopy became accepted surgical techniques.

Chevalier Jackson became interested in laryngology while studying medicine in Pennsylvania and eventually furthered his studies in London. After learning the techniques of his mentors and as an instrument maker, he created an esophagoscope allowing for direct visualization of the esophagus. With this design, he was successful in removing esophageal foreign bodies from both adults and children. Jackson further refined his technique and the instruments he used, eventually developing the largest endoscopy clinic in the world [5]. Through the innovations of Jackson and his predecessors, the techniques for removal of esophageal and airway foreign bodies was perfected, reducing the mortality from foreign body ingestion or aspiration from more than 50% to less than 2% [5].

2. Endoscopic equipment

Modern endoscopic equipment is available in various sizes and configurations to accommodate patient age and size, and the use of flexible vs. rigid endoscopic equipment are both available (Figure 1). There are some clear advantages to the use of rigid bronchoscopy for removal of a tracheobronchial foreign body. The scope is designed to have ventilating ports so the anesthesia circuit can be directly attached for active ventilation and control of the airway during the procedure.

Flexible bronchoscopy can be done with insufflation techniques in the oropharynx or through the scope, but the channel on the scope is small, thus limiting flow of gas. Alternatively, the flexible scope can be passed through a secured endotracheal tube (Figure 2). If the foreign body cannot fit through the endotracheal tube, then this creates a problem for removal with the tube in place. The foreign body forceps have more limited sizes with flexible bronchoscopy, and there is also less control of the scope itself since it can bend to various configurations. Certainly in our experience, flexible bronchoscopy can be a useful adjunct to removal of foreign bodies, as it can give more distal visualization of the lower airways for small food particles, like nuts, that may fall further than the rigid scopes can reach. Such smaller, distal airways can be irrigated with saline and additional attempts using flexible or rigid bronchoscopy can then be utilized to remove these small fragments using endoscopic optical graspers or suction.




Figure 1. A) Various non-optical and optical graspers used for removal of foreign bodies from the aerodigestive tract. B) Rigid, ventilating bronchoscopes of various sizes. Selection depends on the age of the patient and size of the airway.

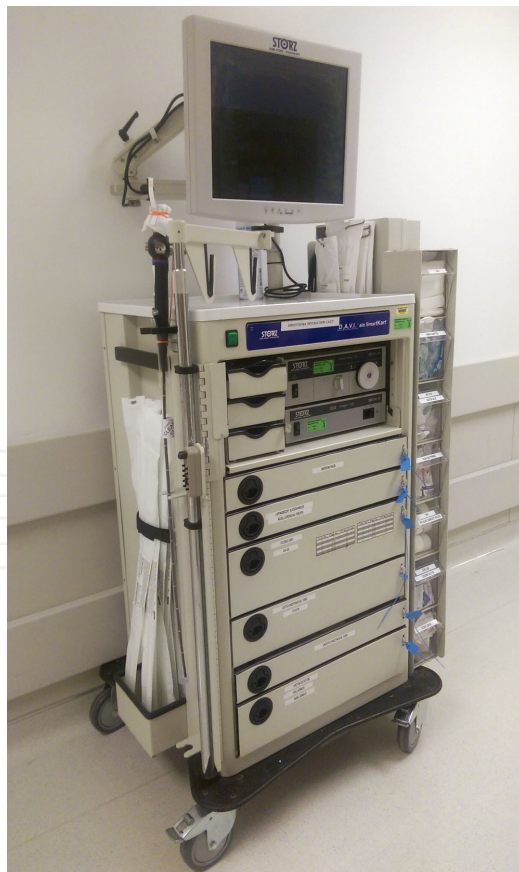

Figure 2. Flexible bronchoscopy cart setup.

For esophagoscopy, the use of the rigid scope allows for use of the same endoscopic optical graspers used in airway cases. While many esophageal foreign bodies are safely removed with flexible endoscopy, the rigid scope does not require insufflation of the esophagus with air and using rigid equipment, more direct visualization of the insertion through the upper esophageal sphincter can be made. There are fewer options for types of graspers available for the flexible esophagoscope. In our opinion, the endoscopic optical graspers themselves used through the rigid scope allow for enhanced visualization and easier foreign body removal (Figure 3).




Figure 3. An example of an endoscopic, optical coin grasper, with a fine tooth at the tip, which allows the coin to pivot or swivel through the path of least resistance through the esophagus during removal.

3. Relevant airway anatomy

The upper aerodigestive tract extends from the lips and nasal vestibule to the upper esophagus and trachea and mainstem bronchi. It can be divided into anatomic subsites, including the nasal cavity, nasopharynx, oropharynx, hypopharynx, larynx, trachea, bronchi, and esophagus.

With regard to the nasal cavity, foreign bodies typically get lodged between the inferior turbinate and the septum. As the nasal cavity is part of the airway, care must be taken during removal attempts in the office setting to avoid converting this upper airway foreign body into a lower airway foreign body.

Several differences between the adult and pediatric airway exist that the endoscopist should consider when evaluating and treating patients with aerodigestive foreign bodies. First, the infantile larynx is positioned much higher in the neck. Additionally, the neonatal larynx is

approximately one-third the size of the adult larynx, with the narrowest portion being at the level of the cricoid cartilage and not at the level of the glottis, as in adults [8]. A small reduction in the size of the pediatric airway can have significant and devastating consequences. The size of the airway must be kept in mind when choosing the appropriate size of the bronchoscope. As a general rule, the largest size ventilating scope that can be placed based on age of the child and size of subglottis, allows for optimal ventilation, visualization, and endoscopic removal.

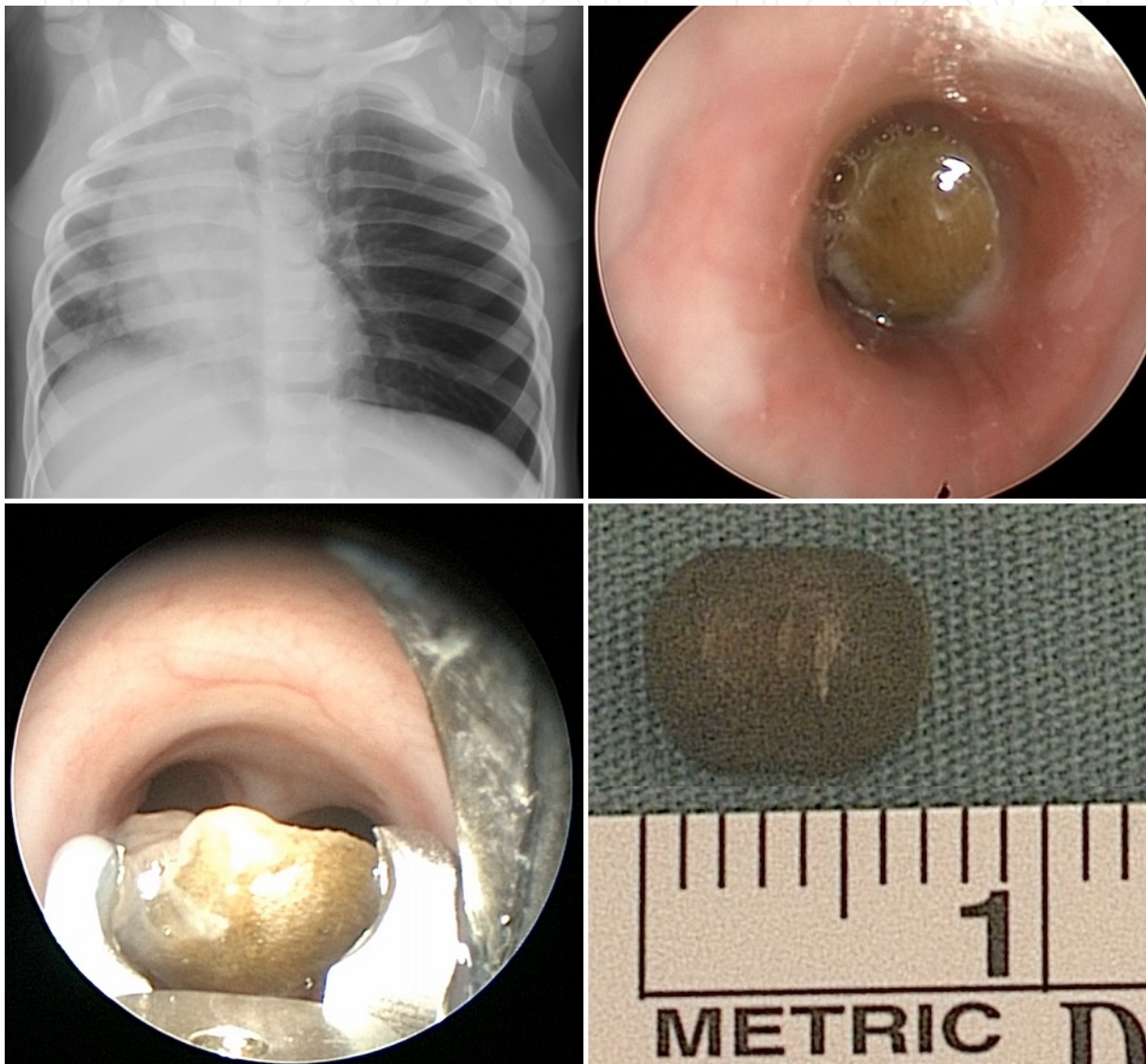


Figure 4. A 13-month old presented to the emergency room with wheezing and coughing. The child had reportedly put something into its mouth earlier that day. An A-P plain film showed hyperinflation of the left lung with right-sided mediastinal shift. There was no radiopaque foreign body noted on the plain film. Direct laryngoscopy with rigid bronchoscopy revealed a left mainstem foreign body, consistent with half of a wooden bead that was removed with an endoscopic optical forceps.

The presence of a foreign body within the tracheobronchial tree can lead to a ball-valve effect, resulting in early hyperinflation of the lung ipsilateral to the foreign body (Figure 4). Over

time, the obstructed lung segment becomes atelectatic. In addition to its physical obstruction, the presence of a foreign body disrupts the normal mucociliary clearance of the tracheobronchial tree. These factors can contribute to the rapid accumulation of secretions and subsequent superimposed pneumonia [9].

The right mainstem bronchus creates a more obtuse angle with the trachea when compared to the left mainstem bronchus, leading to a higher incidence of right-sided airway foreign bodies [10].

4. Relevant esophageal anatomy

There are several anatomic considerations that can lead to arrested passage of an esophageal foreign body through the digestive tract and into the stomach. These sites include the upper esophageal sphincter or cricopharyngeus, the mid-esophagus where the aortic arch crosses, and the lower esophageal sphincter. Additionally, there are a few pathologic conditions that can predispose pediatric patients to dysphasia and esophageal foreign bodies, including vascular rings and slings.

5. Pediatric airway foreign bodies

5.1. Epidemiology

Airway foreign bodies represent an important cause of pediatric morbidity and mortality both in developed and developing countries. According to the US CDC's Morbidity and Mortality Weekly Report, nonfatal choking-related episodes among children less than 14 years old were responsible for approximately 17,000 emergency room visits in the year 2001 alone, with an estimated rate of 29.9 episodes per 100,000 children. The incidence was greatest in patients less than 1 year old (140.4 per 100,000) and steadily declined with increasing age. Seventy-seven percent of patients presenting with choking-related symptoms were three years old or younger. In their data, there was a higher incidence in males (55.1%) and a higher incidence of food-related substances when compared to nonfoods (59.5% vs. 31.4%, 9% unknown) [11]. The most commonly aspirated foreign bodies include round, hard foods such as nuts, seeds, beans, corn, and berries [12].

In Tan et al.'s 10-year retrospective review of children treated for airway foreign bodies via bronchoscopy, they reported a male preponderance (63.7%) in a series of 135 cases. Three quarters of their patients were under 3 years of age [13]. Both of these trends mirror that of other published series [14–16]. Tan proposed that the higher incidence of foreign body aspiration in younger children was due to their poor oro-motor control and their lack of dentition, in addition to their propensity to explore the world with their mouths.

Prior to the advent of modern endoscopic techniques, the reported mortality from aspirated foreign bodies was as high as 50% or greater [5]. Following the advent of endoscopic techniques

and increased public awareness, the mortality rate of patients with foreign bodies is approximately 1% [17]. The total number of foreign body--related deaths in the United States is estimated to be between 500 and 2000 [13].

The nasal cavity is the most common sub-site for foreign bodies when considering the entire upper aerodigestive tract, accounting for approximately two-thirds of all foreign bodies. In Chinski's study of aerodigestive tract foreign bodies in Argentina, 1559 nasal foreign bodies were reported. The most common objects found in the nose in decreasing order were pearls, stationery, food, seeds/nuts/beans, pins/nails/metal, other inorganic materials and stones, followed by other less common items, including 1 button battery and 11 magnets [18]. The majority of nasal foreign bodies occur on the patient's right side, with this trend increasing with the patient's age [19]. Interestingly, some studies have demonstrated a decreased incidence of nasal foreign bodies during the summer months [20]. Others have commented on the increased incidence of nasal foreign bodies during the months of January, March, April, and October, coinciding with the months near Christmas, Easter, and Halloween when children are exposed to more toys and treats [19].

5.2. Clinical evaluation

5.2.1. Nasal foreign bodies

Many nasal foreign bodies are asymptomatic, presenting only because their placement was witnessed or admitted (Figure 5). Unwitnessed or untreated nasal foreign bodies may present with a variety of symptoms, including unilateral purulent rhinorrhea or nasal obstruction, halitosis, epistaxis, sinusitis, or a combination of these symptoms [19, 21]. A nasal septal hematoma should be differentiated from a nasal foreign body (Figure 6). In a European study assessing complications and hospitalizations due to nasal foreign bodies, Gregori et al. demonstrated that battery nasal foreign bodies were more likely to experience complications and require hospitalizations when compared to many other types of nasal foreign bodies [21]. As with other studies regarding aerodigestive foreign bodies, they reported a fairly high incidence of children placing nasal foreign bodies while under adult supervision (38%).

5.2.2. Laryngeal and tracheobronchial foreign bodies

Foreign bodies of the laryngotracheobronchial tree can present with varying degrees of airway symptoms depending on their location, shape, size relative to airway, and chronicity.

Laryngeal Foreign Bodies

Foreign bodies of the larynx, while infrequent, are associated with the most devastating outcomes. In addition to more common symptoms associated with foreign bodies of the trachea and bronchi, these patients are more likely to present with hoarseness, aphonia, drooling, stridor, and drooling. Complete obstruction can cause cyanosis, respiratory distress, and respiratory arrest followed by death. Persistent irritation can lead to significant laryngeal edema that can persist and cause significant symptoms even after foreign body removal [10, 22].

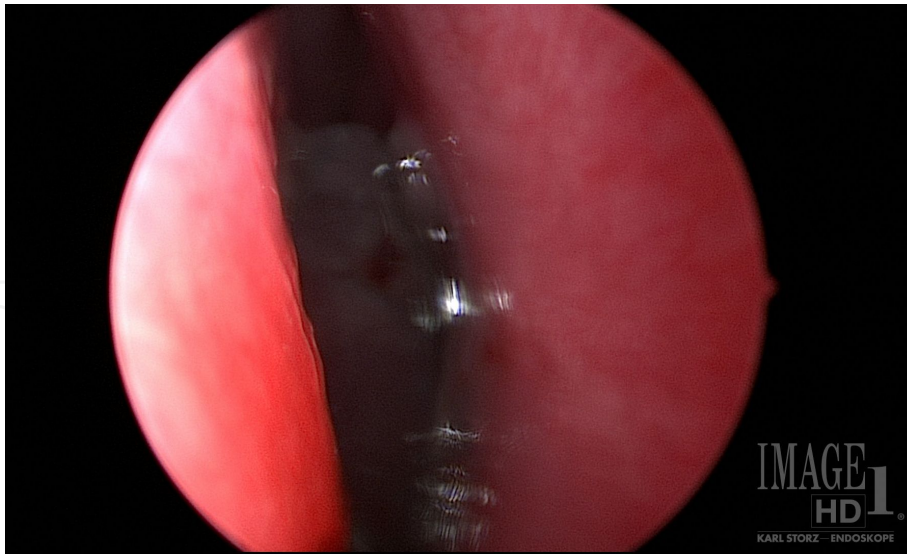


Figure 5. Right nasal foreign body, a piece of broken glass, placed by a 5-year old boy. This was removed in the operating room, instead of clinic setting, due to sharp edges and risk of bleeding following removal.

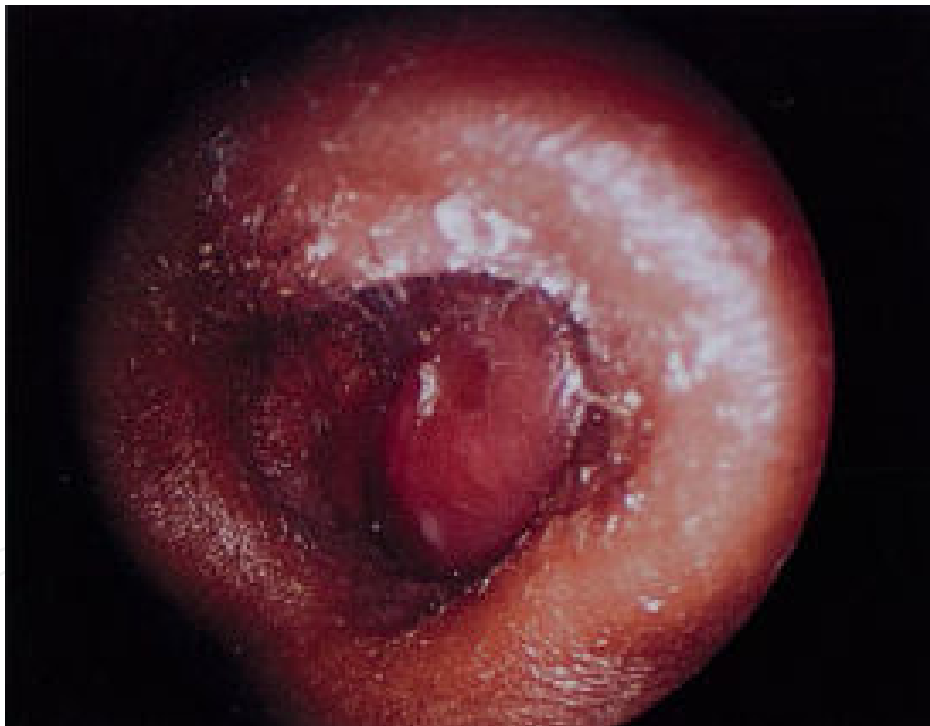

Figure 6. Right nasal septal hematoma after nasal trauma could be mistaken for a foreign object; the mucoperichondral flap is fluctuant to palpation with a cotton tip applicator. Surgical drainage is the required treatment to prevent abscess formation and cartilage necrosis.

Tracheal Foreign Bodies

Patients with tracheal foreign bodies may present with biphasic stridor, a dry cough with an associated "sharp crack" or "slap" when a moving foreign body impacts the subglottis. Patients

may place themselves in the "tripod" position, leaning forward with elbows or hands on their knees. There may also be a dramatic shift in symptoms when the patient changes positions, owing to the mobility of the foreign body [22].

Bronchial Foreign Bodies

In Tan et al.'s series, the most common presenting symptoms of tracheobronchial foreign bodies were "choking, coughing, gagging" with 91.8% of patients presenting in this manner. This was followed by "wheezing" in 84.4% of patients and finally the classic triad of "coughing, wheezing, and reduced breath sounds" in only 57% of patients. Less common symptoms reported in their series included fever, pneumonia, stridor, chest pain, blood stained mucous, restlessness, throat discomfort, sternal discomfort, increased seizure episodes, and nose bleed [13].

5.3. Radiographic evaluation

A thorough history and physical exam are paramount in the evaluation of a child with suspected foreign body and can frequently lead to a diagnosis without the need for further diagnostic workup or imaging. Traditionally, plain film radiography has been advocated for patients with suspected foreign body aspiration. A-P and lateral plain films may reveal a radiopaque foreign body within the tracheobronchial tree. Additionally, sequelae from the presence of the foreign body may be recognized, including air-trapping with associated mediastinal shift, atelectasis, or pneumonia from long-standing foreign body. Decubitus films may demonstrate lack of dependent mediastinal shift on the side ipsilateral to the foreign body [23].

The use of plain film radiography does not need to be routinely employed in patients where there is a high index of suspicion for foreign body based on history and physical examination. In a 6-year retrospective review of 93 cases of possible airway foreign body cases, Silva et al. reported a imaging study sensitivity and specificity of 74% and 45%, respectively [24]. In a series of 232 patients with pre-operative radiography in whom foreign bodies confirmed via bronchoscopy, 110 had plain film imaging that was considered normal by the surgeon (47%). For patients with radiology reports, 42% of patients with bronchial foreign bodies and 81% of patients with tracheal foreign bodies had negative imaging reports. The same study did note that patients with long-standing foreign bodies are more likely to have positive findings on plain film radiography when compared to patients with foreign bodies that have been present for less than 24 h [25]. In their retrospective reviews, neither Assefa nor Brown found sufficient evidence to support the routine use of decubitus films in the identification of airway foreign bodies, citing the lack of sensitivity [23, 26].

Some studies have reported on the diagnostic utility of CT imaging and CT virtual bronchoscopy, with reported sensitivities and specificities ranging from 90% to 100% [27, 28]. Foreign bodies that are radiolucent on plain films may be identified on CT. The risks of ionizing radiation and the inability to concurrently diagnose and treat foreign body aspiration should be recognized when considering these modalities.

Despite negative imaging studies, if the history is concerning for possible aspiration, then endoscopic evaluation should still be considered given the potential morbidity and mortality of airway foreign bodies.

5.4. Airway foreign body removal

Nasal foreign bodies can frequently be managed in the clinic if the object is in the anterior nasal cavity. After removal, confirmation using nasal endoscopy can ensure that no additional retained foreign body is present. Objects that are difficult to grasp or that are posterior within the nasal cavity may require sedation or a general anesthetic removal. If the object is round, using a right angle probe behind it and pulling anterior is safest, to avoid propelling the object into the pharynx or causing it to be aspirated into the lower tracheobronchial tree. Other upper airway foreign bodies require direct laryngoscopy and removal with endoscopic visualization of the pharynx and larynx (Figure 7). These are considered an emergency as they can potentially lead to lower airway obstruction if the object is aspirated. When done in the operating room, the endoscopist must be prepared for emergent bronchoscopy, should the object fall distally during induction of anesthesia. Thorough discussion with the anesthesia team on the plan prior to induction must take place. All potential non-optical and optical graspers should be available to quickly use as needed. In addition, instrumentation for emergent tracheostomy placement should be immediately available should the need arise. Figures 8-14 demonstrate a variety of cases where endoscopic management was performed.

5.4.1. Anesthetic considerations

The choice of anesthetic technique should be based on a discussion between the surgeon and anesthesiologist. Pediatric airway and esophageal foreign body removal is performed under general anesthesia. Anesthetic induction can be achieved either by inhalation of volatile anesthetic gas or intravenous medications. Anesthesia can then be maintained with spontaneous ventilation or paralysis with control of the airway. This choice is surgeon and anesthesiologist dependent, but should be agreed upon prior to the start of the procedure.

Especially in the case of tracheobronchial foreign bodies, constant and deliberate communication regarding the airway should be maintained between the surgical and anesthesia teams. This situation represents a true “shared airway” [29, 30].

An age-appropriate size bronchoscope and one size smaller should always be set up for tracheobronchial foreign bodies. A back-up fiberoptic light source is helpful in case one fails during the procedure. Given that the rigid bronchoscope itself is a means of ventilation, strategic use of the instrument during the procedure is important. For example, if the oxygen saturations drop, the telescope can be removed and this increases the ventilating diameter, and therefore the volume of airflow through the bronchoscope tube with occlusion of the proximal end with a cap. The mouth and nose can be manually sealed around the scope to create some “positive pressure” as needed. Optical graspers of various shapes can be easily passed through the bronchoscope while maintaining ventilation, and foreign bodies can be removed under direct endoscopic visualization. The surgeon must ensure all equipment is

functional, available, and all desired instruments fit through the bronchoscope size selected prior to the patient's anesthetic induction.

Tracheostomy is rarely required; however, equipment should be immediately available for obtaining an emergent surgical airway in the management of airway foreign bodies. This is always discussed with the parents during the informed consent process.

5.4.2. Adjunctive procedures

In the rare case where the foreign body cannot be removed endoscopically, additional interventions may be required. As a temporizing measure, the use of extracorporeal membrane oxygenation (ECMO) may allow oxygenation in a case of inability to ventilate [31]. This is a highly specialized technique that is not available in all centers. It allows oxygenation of the blood and maintenance of circulation until a definitive plan for removal can be facilitated.

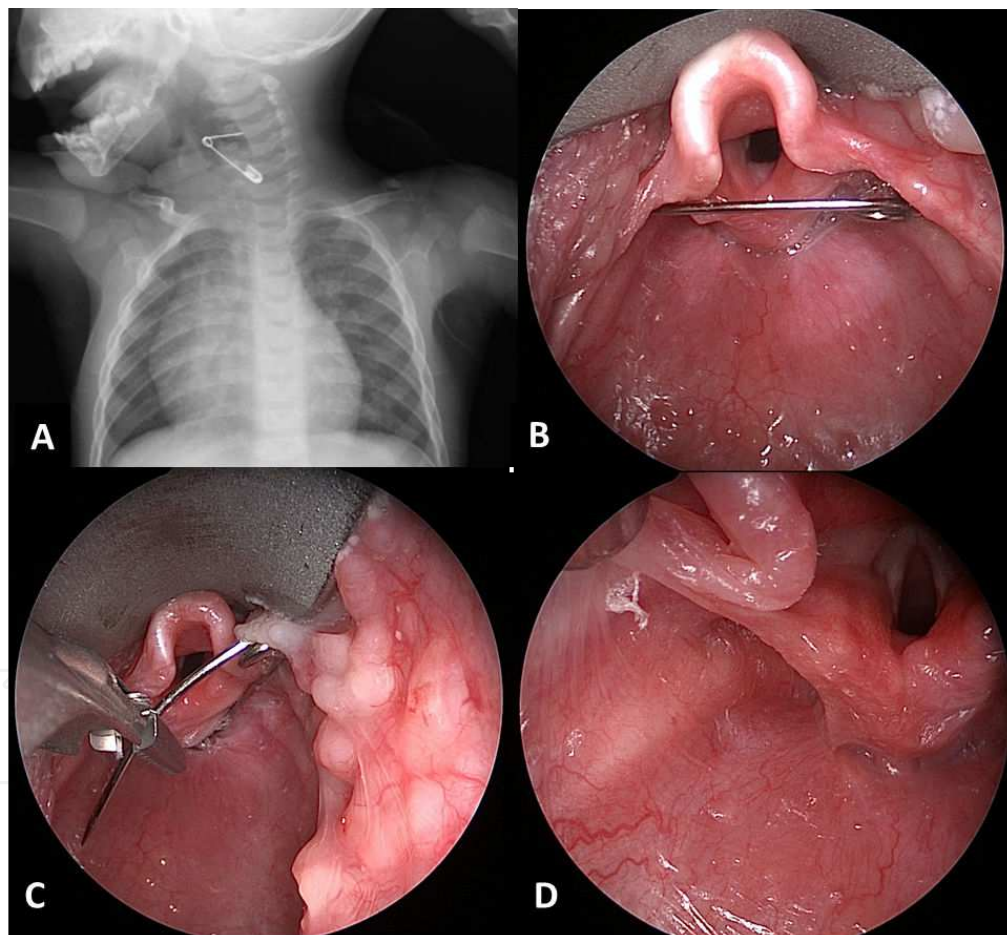


Figure 7. An 11-month old with an open safety pin in the upper airway. The patient presented with irritability and drooling of several hours duration, and the mother felt the child might have put something into its mouth. A-P and lateral plain films confirmed the diagnosis.

In cases where the foreign body cannot be removed endoscopically, open approaches may be required [32]. Cervical esophagostomy for proximal esophageal foreign bodies, or thoracoto-

my with bronchotomy, may be required for tracheobronchial foreign bodies. In these rare cases, close collaboration with pediatric thoracic surgeons or pediatric surgeons is required.

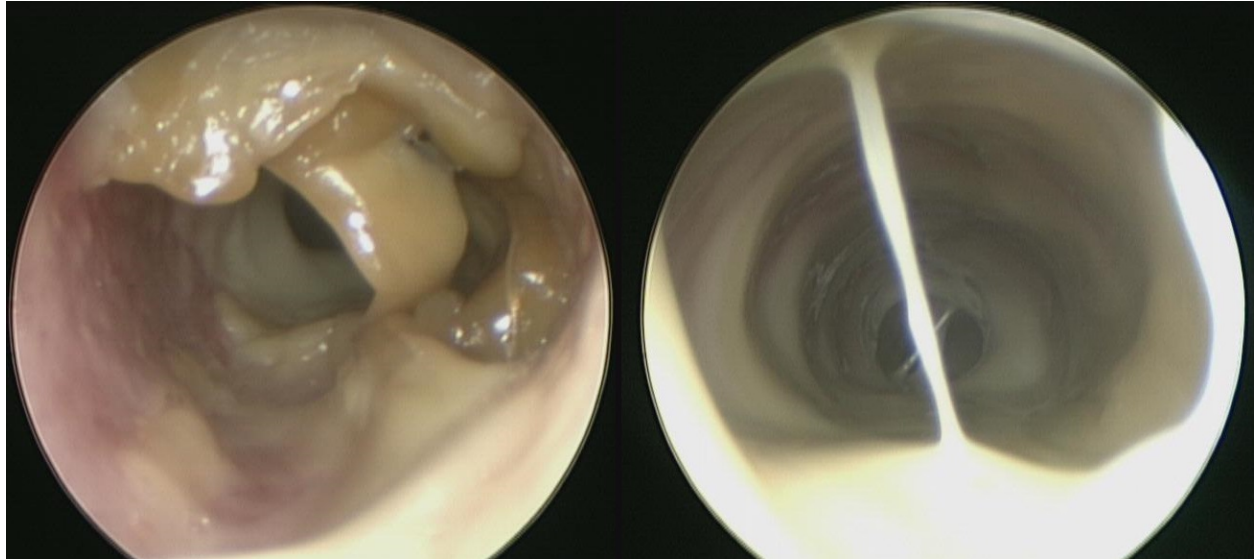


Figure 8. A 9-year-old patient presenting with cough and stridor with concurrent fever. Direct laryngoscopy with rigid bronchoscopy revealed bacterial tracheitis. Tracheal casts can cause airway symptoms similar to aspirated foreign bodies.

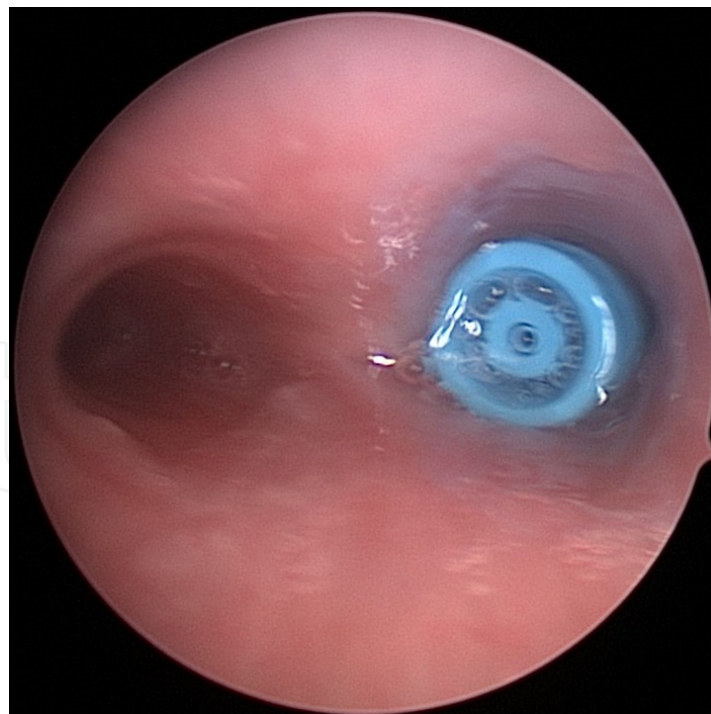


Figure 9. A 12-month old presented to the Emergency Department with increased work of breathing and stridor after reportedly having swallowed a piece of a pen. Plain film imaging was unrevealing. Given the clinical presentation, the patient underwent direct laryngoscopy with rigid bronchoscopy, revealing a plastic foreign body in the right main-stem bronchus.

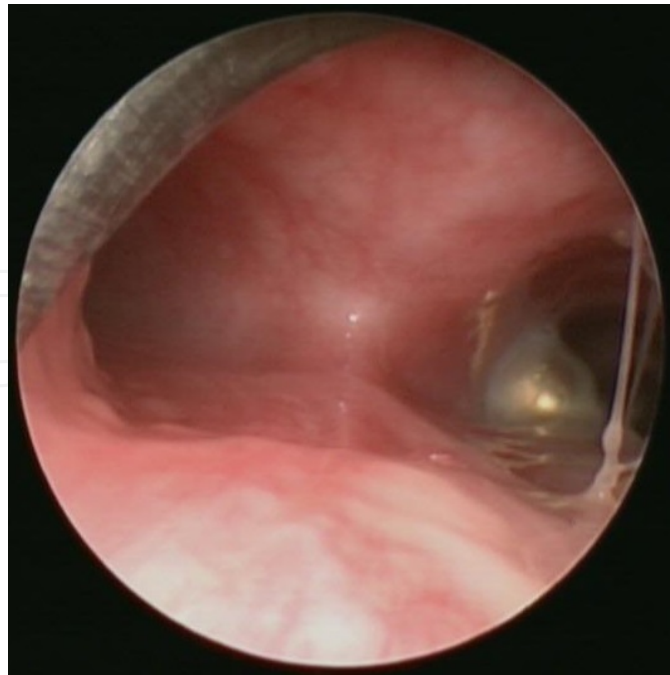


Figure 10. A 12-month old presenting with respiratory symptoms and concern for foreign body aspiration. Direct laryngoscopy with rigid bronchoscopy confirms a high-powered magnet sphere within the right mainstem bronchus. Another was trapped in the esophagus directly behind this. This has the potential to cause a tracheoesophageal fistula given magnetic strength and tissue necrosis between the two magnets. Severe injuries are more common in the lower gastrointestinal tract causing perforation when more than one of these is swallowed (this child had additional magnetic spheres in the small bowel which caused transmural necrosis and perforation requiring repair).

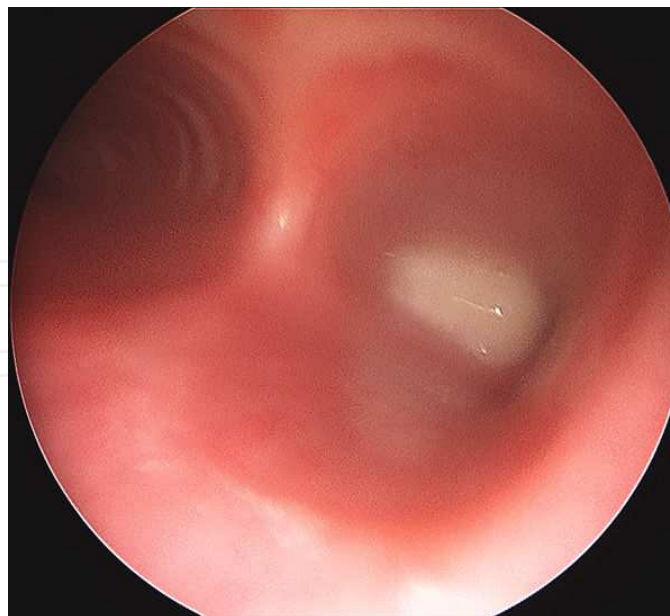


Figure 11. While having a tooth extracted at a dentist office, this child accidentally aspirated the tooth, found in the right mainstem bronchus.

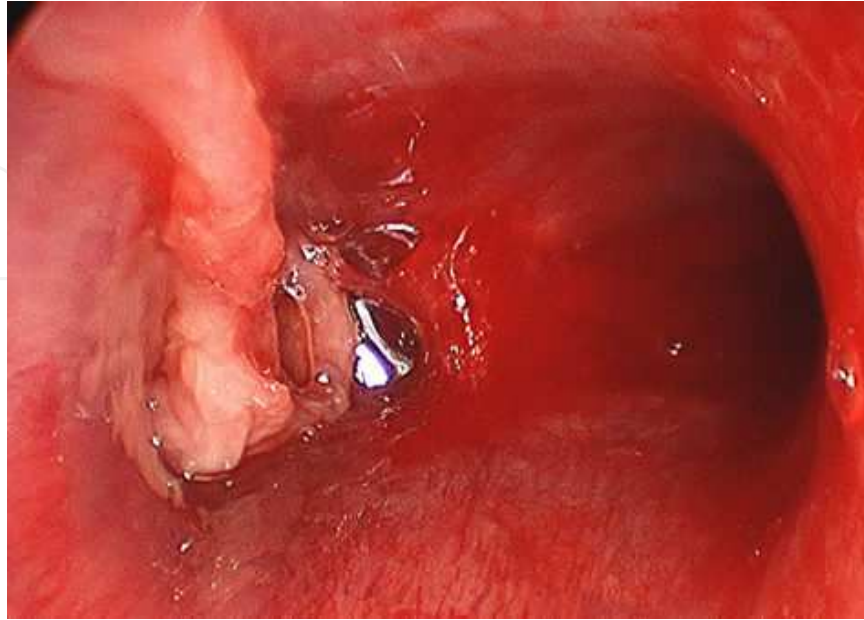


Figure 12. Plastic bronchitis in a patient with congenital heart disease, showing a cast in the left bronchial tree.

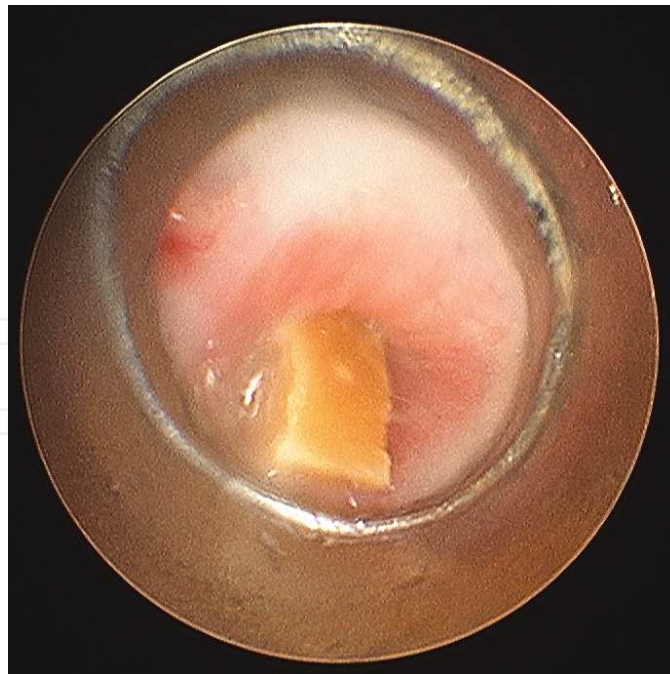


Figure 13. A 2-year-old boy was given peanuts by an older sibling, choked, was in severe respiratory distress, found to have several fragments in the lower airways. These were removed with optical graspers through the rigid bronchoscope.

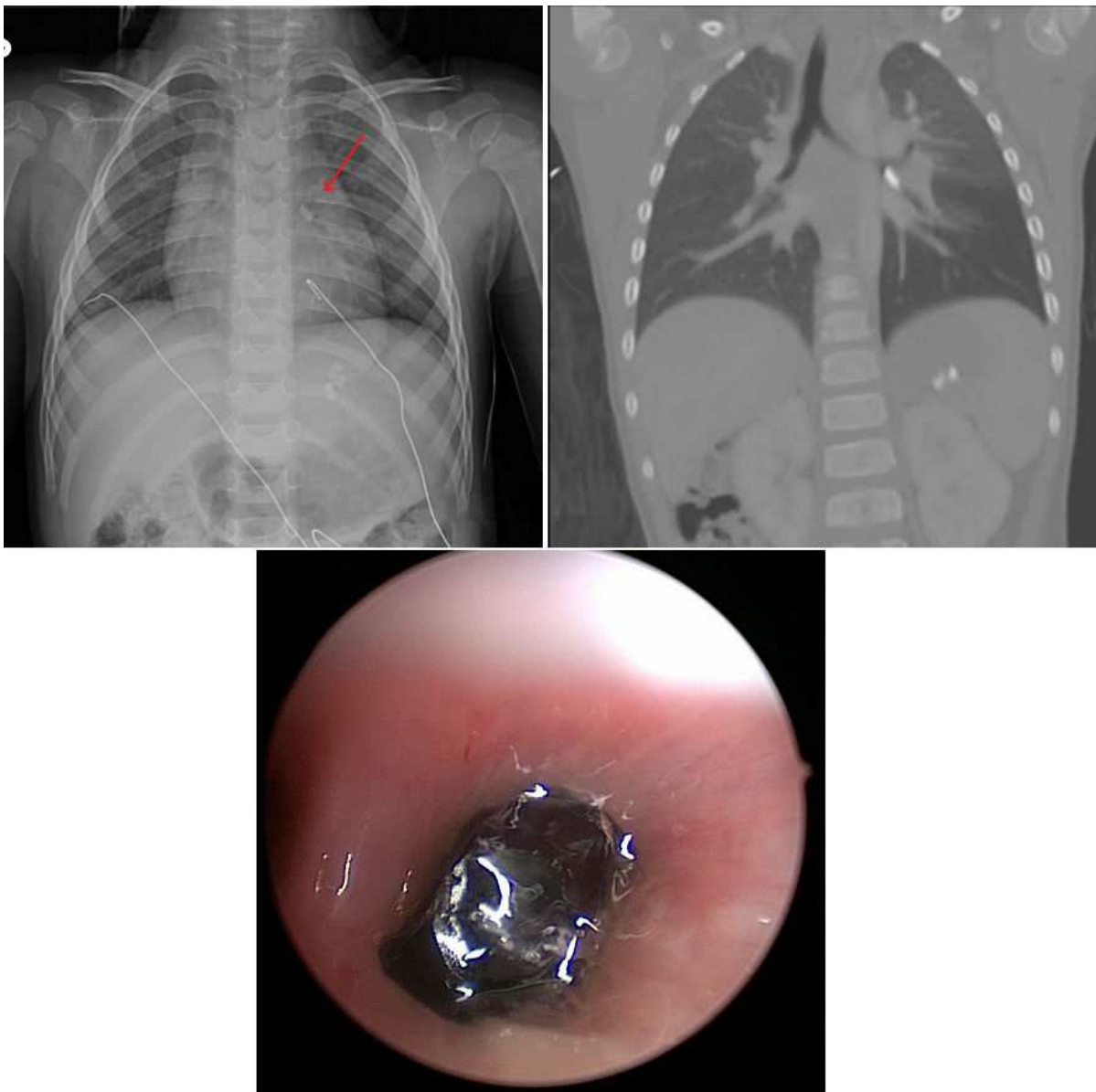


Figure 14. A 2-year-old patient presented to the Emergency Department with multiple facial lacerations following a motor vehicle accident during which she was ejected through the passenger side window. She had no respiratory symptoms as presentation. As part of her trauma workup, she underwent both plain film and CT imaging of the chest, both showed a possible left-sided airway foreign body. Direct laryngoscopy with bronchoscopy confirmed the diagnosis, and the object was endoscopically removed without difficulty.

6. Pediatric Esophageal Foreign Bodies

6.1. Epidemiology

Foreign body ingestion is a relatively common occurrence, with an estimated 100, 000 cases per year in the United States alone. Like airway foreign bodies, the majority of cases occur in children aged between 6 months and 3 years [33]. For the majority of esophageal foreign bodies,

a child's caregiver either witnesses or suspects that their child has ingested a foreign body [34]. While the majority of ingested foreign bodies will pass on their own, there is still a real risk of significant morbidity and mortality. Of all patients with esophageal foreign bodies seeking medical attention, 80%–90% pass the foreign body without any intervention, 10%–20% require endoscopic removal, and only 1% require surgical removal [33]. It has been estimated that 1,500 deaths occur annually in the United States alone due to foreign body ingestion [35].

Recently, there has been a sharp rise in the use of button-battery powered hand-held electronic equipment. This has coincided with a rise in the incidence of button battery--related emergency department visits [36].

6.2. Clinical presentation

As with airway foreign bodies, a thorough history and physical exam are critical in the workup of the pediatric patient with a suspected esophageal foreign body. As previously stated, frequently, a caregiver has witnessed the ingestion and can positively identify the object, which may have implications regarding urgent intervention, such as in the case of an ingested button battery or magnet.

Many esophageal foreign body ingestions go unwitnessed and a large proportion of these pass without incident or development of symptoms [37]. When children do have symptoms, they tend to be nonspecific and can lead to a missed or delayed diagnosis. In a retrospective review by Arana et al. of 325 pediatric patients presenting with esophageal foreign bodies, only 54% of patients had transient symptoms at the time of ingestion [38]. When patients are symptomatic, they primarily present with nonspecific gastrointestinal or pulmonary complaints, including coughing, choking, gagging, drooling, odynophagia, and/or dysphagia. Patients may also present with stridor or wheezing due to inflammation of adjacent tracheobronchial mucosa.

In their retrospective study of 248 cases of patients undergoing esophagogastroduodenoscopy (EGD) for foreign body removal, Denney et al. assessed the incidence of esophageal injury as it related to presenting symptoms. In their series, 59 children (30%) were found to have mucosal ulceration. They found that a presenting complaint of substernal pain correlated with mucosal ulceration, whereas symptoms of vomiting, respiratory distress, and drooling did not. The vast majority of foreign bodies in their series were coins (81%) and 8 cases of batteries were reported. They did not comment on any injuries from batteries [34].

6.3. Radiographic evaluation

The patient's clinical presentation should be corroborated with imaging to ensure that a foreign body requiring urgent removal is not misdiagnosed [35]. Imaging for esophageal foreign body workup should typically include the chest and abdomen in both AP and lateral planes (Figure 15). It should be noted, however, that about 1/3 of foreign bodies are radiolucent [38].

Jatana et al. reported on the utility of plain film radiography in distinguishing esophageal coins from button batteries [39]. They described the "double ring" or "halo" sign created by a button

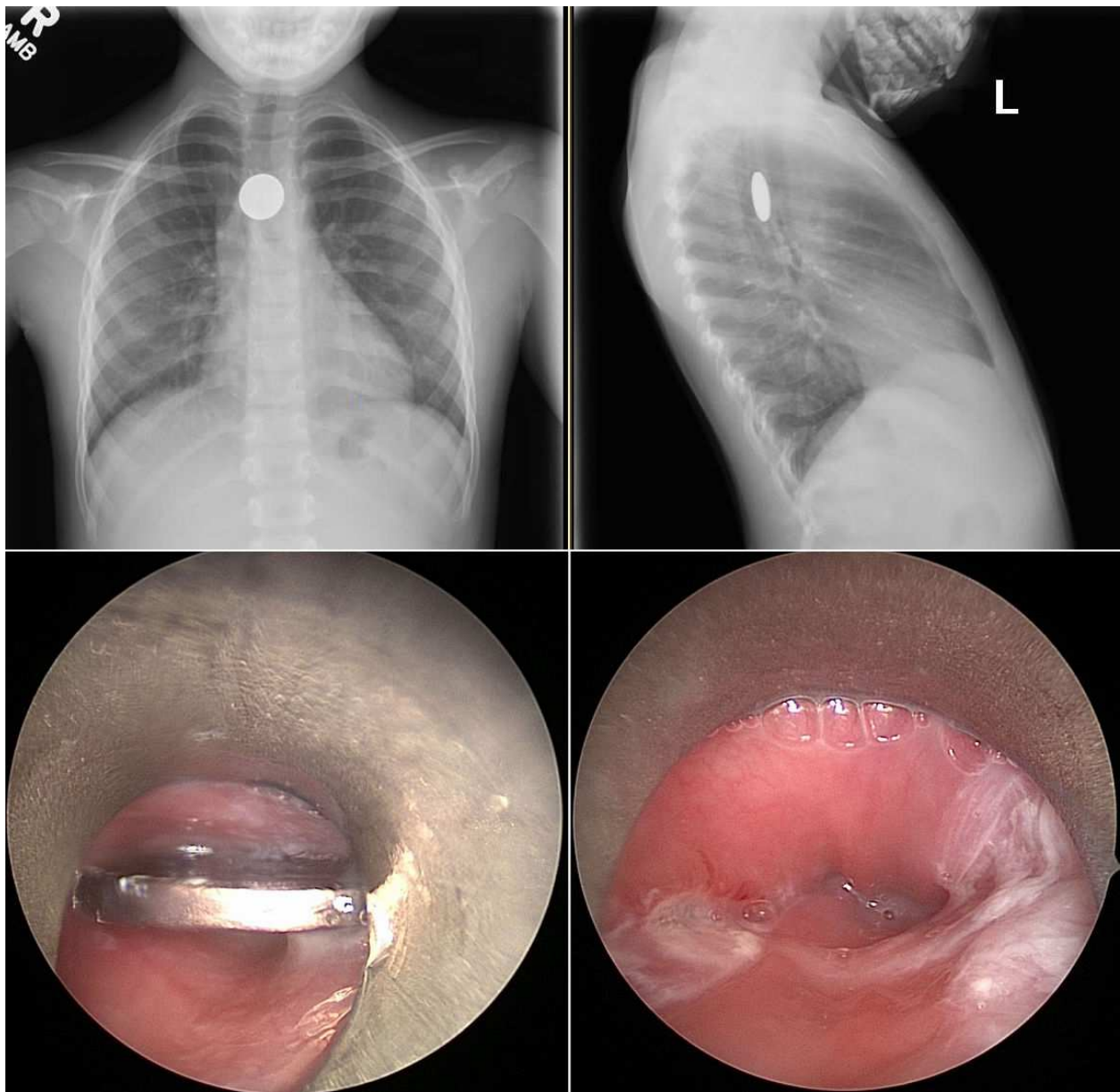


Figure 15. A 5-year old presented to the Emergency Department with several episodes of emesis. She admitted to swallowing a penny while at day care earlier that day. A-P and lateral plain films confirmed the diagnosis of an esophageal foreign body. A penny was identified and removed via rigid esophagoscopy. Minimal esophageal mucosal irritation was noted.

battery on an A-P plain film (Figure 16). The 20mm 3 volt lithium batteries consistently demonstrate this finding. They also demonstrated the "step-off" that can be seen on lateral plain films of button batteries, though they caution that some new thinner button batteries will not demonstrate this finding. Clinicians must not rely on lateral x-rays alone.

Many experts argue against the use of contrast studies for diagnosing esophageal foreign bodies given the increased risk of aspiration with a foreign body obstructing the esophagus. The presence of contrast could compromise the ability of the endoscopist to find the foreign body during retrieval and may also limit mucosal assessment [41]. In addition, the contrast

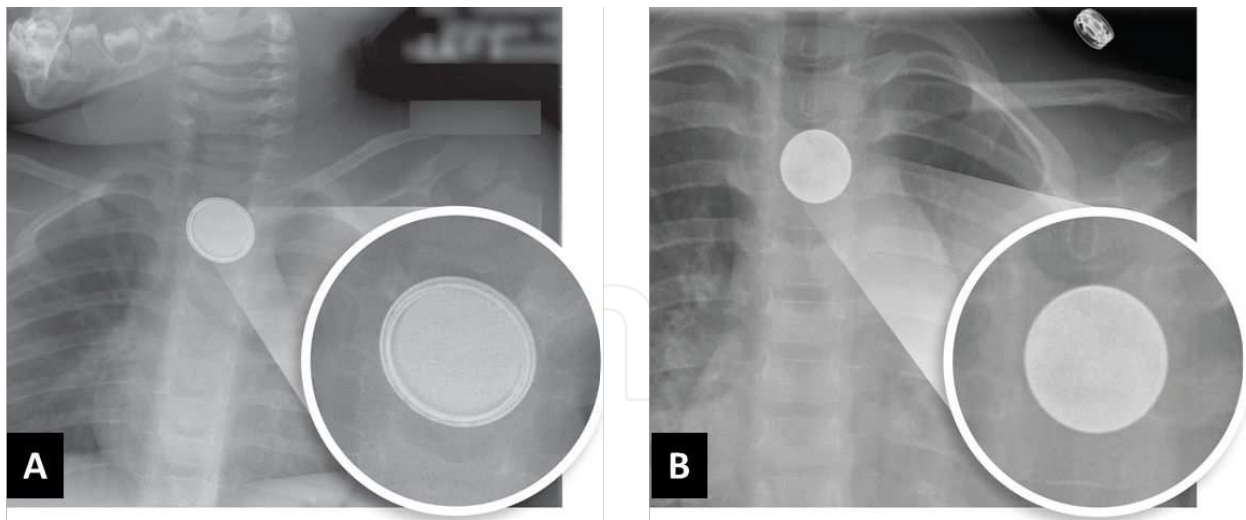


Figure 16. A) Button battery in upper esophagus. B) Coin in upper esophagus. By zooming into the foreign body, the “double ring or halo sign” can be clearly seen for the battery. Zooming into the image is most helpful for differentiation. Reproduced with permission, Jatana [40].

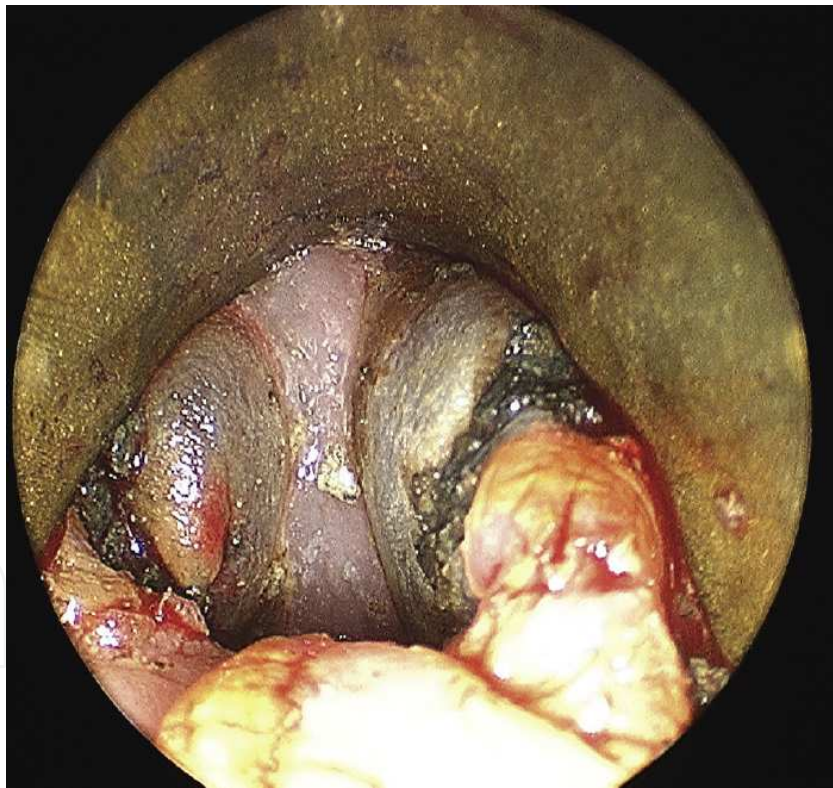


Figure 17. Esophageal injury secondary to a button battery in a 4-year old. The injury involves the muscular layer of the esophagus. Reproduced with permission, Jatana [40].

typically pushes back general anesthesia 8 h, and delays operative intervention. Esophagram does have a role in assessing for esophageal perforation or stricture due to foreign bodies, but generally only after operative removal of the foreign body.

Several authors have described the utility of hand-held metal detectors in the management of patients with suspected coin ingestion. Younger et al. performed a 2-year prospective study of patients presenting for evaluation of esophageal foreign bodies. With a hand-held metal detector, they were able to positively identify the presence and location of esophageal coins in all 26 patients who had positive plain films [42]. Lee et al. performed a systematic review of 11 studies and found that the sensitivity and specificity of identifying the presence of coins was 99.4% and 100%, respectively, when compared to plain films. They do note however, that non-coin metal objects were not detected as frequently as coins in one study reviewed. The authors point out the benefit of avoiding ionizing radiation when using a hand-held metal detector [43].

Repeat imaging has a role in the management of esophageal foreign bodies that are managed expectantly. An x-ray can ensure that an esophageal foreign body has passed into the stomach. In addition, should the object not be found in the stools over time, repeat abdominal x-ray can confirm that there is no retained opaque foreign body in the lower gastrointestinal tract.

6.4. Esophageal foreign body removal

Management of esophageal foreign bodies varies considerably based on several factors, including anatomic location, type of foreign body, patient presenting symptoms, and existing complications. A button battery lodged in the esophagus is an emergency. The current generated around the battery causes hydroxide ion to form at the negative pole, causing rapid injury. Serious injury can occur in only 2 h. The 20 mm diameter, 3 volt lithium batteries cause the most severe injury as they combine high power, with large enough size to get stuck; these are frequently used in many household electronics [39]. A common misconception is that the leaking battery acid is the major source of mucosal injury, rather than the generated electrical current. In addition, “dead” batteries, meaning those that no longer have enough charge to power their intended electronics, can still have enough residual electrical current to cause mucosal injury (Figure 17).

Coins lodged in the esophagus can be managed with an initial period of observation, and if they fail to pass into the stomach, can be removed endoscopically.

Rigid esophagoscopy allows for the scope to be placed under constant direct visualization for removal of the foreign body using endoscopic optical graspers that are most suited for the object. In general, a second-look esophagoscopy can not only confirm the absence of any additional non-opaque foreign bodies, but also assess any injury to the esophageal wall. If a perforation is suspected, keeping the patient with nothing by mouth and obtaining an esophagram is best. When probable perforation or known severe circumferential injury exists, consideration of placing a nasogastric tube under direct visualization through the rigid scope can serve as temporary means of nutrition and keep the region stented open to avoid complete stricture. It should also be kept in mind that when severe injury exists, advancing the esophagoscope past the site of injury can potentially lead to greater injury.

7. Complications of pediatric airway foreign bodies

The most feared acute complication of airway foreign bodies is complete airway obstruction with cardiopulmonary arrest and death. Wheezing is very common after the procedure and close monitoring in the hospital setting is required until symptoms have stabilized. Pneumonia is common due to lower airway obstruction and should be appropriately treated with antibiotics. Intraoperative cultures can be taken to help guide treatment. Given that injury can occur to the tracheobronchial tree, pneumomediastinum and pneumothorax can occur. When the airway is severely inflamed, bleeding and granulation tissue can limit visualization, and the decision to do a planned second-look bronchoscopy must be made to ensure no retained foreign body is present. Laryngeal injury when removing an airway foreign body can occur.

8. Complications of pediatric esophageal foreign bodies

Children who develop a fever after removal of any esophageal foreign body should be assessed for an esophageal perforation by esophagram. Other potential complications include: bleeding or major arterial fistula, mediastinitis, mediastinal abscess, respiratory distress (secondary tracheomalacia/compression), tracheoesophageal fistula, vocal cord paresis/paralysis, esophageal stricture, and death. Repeat endoscopy to follow healing of significant esophageal injury is an alternative to follow-up esophagram, and has the advantage of allowing for debridement or dilation of early stricture formation.

9. Conclusions

The management of pediatric airway and esophageal foreign bodies carries the potential for morbidity and mortality, and can be challenging to diagnose if an unwitnessed aspiration or ingestion occurs in a young child. The symptoms can be somewhat nonspecific, not easily differentiated from common viral illnesses in children. Clinical decision making based on thorough history and physical examination is critical. Centers with airway surgeons and endoscopists trained in foreign body management, and with pediatric ICU care are best equipped to manage the most complex cases in the children.

Author details

Phillip L. Chaffin, Jonathan M. Grischkan, Prashant S. Malhotra and Kris R. Jatana*

*Address all correspondence to: Kris.Jatana@nationwidechildrens.org

Department of Otolaryngology-Head and Neck Surgery, Nationwide Children's Hospital and Wexner Medical Center at Ohio State University, Columbus, Ohio, USA

References

- [1] Gross SD, Samuel D. A practical treatise on foreign bodies in the air-passages (Internet). Philadelphia, Blanchard and Lea; 1854 (cited 2015 Jan 4). p. 498. Available from: <http://archive.org/details/practicaltreagros>
- [2] Bush RB, Leonhardt H, Bush IM, Landes RR. Dr. Bozzini's Lichtleiter: A translation of his original article (1806). *Urology*. 1974 Jan;3(1):119–23.
- [3] Desormeaux AJ, Antonin J, Hunt RP. The endoscope, and its application to the diagnosis and treatment of affections of the genito-urinary passages: lessons given at Necker Hospital (Internet). Chicago: Robert Fergus' Sons, printers; 1867 (cited 2015 Jan 4). Available from: <http://archive.org/details/65910730R.nlm.nih.gov>
- [4] Moore I. Peroral Endoscopy: An historical survey from its origin to the present day. *J Laryngol Otol*. 1926 Jun;41(06):361–82.
- [5] Marsh BR. Historic development of bronchoesophagology. *Otolaryngol Head Neck Surg*. 1996 Jun;114(6):689–716.
- [6] Thorner MM. A Utoscopy of the larynx and of the trachea. *J Am Med Assoc*. 1896 Feb 8;XXVI(6):265–7.
- [7] Zöllner F. Gustav Killian, father of bronchoscopy. *Arch Otolaryngol Chic Ill* 1960. 1965 Dec;82(6):656–9.
- [8] Hartnick CJ, Hansen MC, Gallagher TQ, editors. *Pediatric Airway Surgery* (Internet). S. Karger AG; 2012 (cited 2015 Jan 4). Available from: <https://www.karger.com/Book/Home/255642>
- [9] Jackson C. *Bronchoscopy and esophagoscopy*. WB Saunders; 1922.
- [10] Kenna MA, Bluestone CD. Foreign Bodies in the Air and Food Passages. *Pediatr Rev*. 1988 Jul 1;10(1):25–31.
- [11] Nonfatal choking-related episodes among children--United States, 2001. *MMWR Morb Mortal Wkly Rep*. 2002 Oct 25;51(42):945–8.
- [12] Gregori D, Salerni L, Scarinzi C, Morra B, Berchialla P, Snidero S, et al. Foreign bodies in the upper airways causing complications and requiring hospitalization in children aged 0-14 years: results from the ESFBI study. *Eur Arch Oto-Rhino-Laryngol Off J Eur Fed Oto-Rhino-Laryngol Soc EUFOS Affil Ger Soc Oto-Rhino-Laryngol - Head Neck Surg*. 2008 Aug;265(8):971–8.
- [13] Tan HKK, Brown K, McGill T, Kenna MA, Lund DP, Healy GB. Airway foreign bodies (FB): a 10-year review. *Int J Pediatr Otorhinolaryngol*. 2000 Dec 1;56(2):91–9.
- [14] Shubha AM, Das K. Tracheobronchial foreign bodies in infants. *Int J Pediatr Otorhinolaryngol*. 2009 Oct;73(10):1385–9.

- [15] Skoulakis CE, Doxas PG, Papadakis CE, Proimos E, Christodoulou P, Bizakis JG, et al. Bronchoscopy for foreign body removal in children. A review and analysis of 210 cases. *Int J Pediatr Otorhinolaryngol*. 2000 Jun 30;53(2):143–8.
- [16] Chapin MM, Rochette LM, Annest JL, Haileyesus T, Conner KA, Smith GA. Nonfatal choking on food among children 14 years or younger in the United States, 2001-2009. *Pediatrics*. 2013 Aug;132(2):275–81.
- [17] Trachea Foreign Bodies. 2013 Jul 9 (cited 2015 Jan 5); Available from: <http://emedicine.medscape.com/article/764615-overview>
- [18] Chinski A, Foltran F, Gregori D, Ballali S, Passali D, Bellussi L. Foreign bodies in children: A comparison between Argentina and Europe. *Int J Pediatr Otorhinolaryngol*. 2012 May 14;76, Supplement 1:S76–9.
- [19] Claudet I, Salanne S, Debuisson C, Maréchal C, Rekhroukh H, Grouteau E. Corps étranger nasal chez l'enfant. *Arch Pédiatrie*. 2009 Sep;16(9):1245–51.
- [20] François M, Hamrioui R, Narcy P. Nasal foreign bodies in children. *Eur Arch Otorhinolaryngol*. 1998;255(3):132–4.
- [21] Gregori D, Salerni L, Scarinzi C, Morra B, Berchialla P, Snidero S, et al. Foreign bodies in the nose causing complications and requiring hospitalization in children 0-14 age: results from the European survey of foreign bodies injuries study. *Rhinology*. 2008 Mar;46(1):28–33.
- [22] Rodríguez H, Passali GC, Gregori D, Chinski A, Tiscornia C, Botto H, et al. Management of foreign bodies in the airway and oesophagus. *Int J Pediatr Otorhinolaryngol*. 2012 May 14;76, Supplement 1:S84–91.
- [23] Assefa D, Amin N, Stringel G, Dozor AJ. Use of decubitus radiographs in the diagnosis of foreign body aspiration in young children. *Pediatr Emerg Care*. 2007 Mar;23(3):154–7.
- [24] Silva AB, Muntz HR, Clary R. Utility of conventional radiography in the diagnosis and management of pediatric airway foreign bodies. *Ann Otol Rhinol Laryngol*. 1998 Oct;107(10 Pt 1):834–8.
- [25] Zerella JT, Dimler M, McGill LC, Pippus KJ. Foreign body aspiration in children: Value of radiography and complications of bronchoscopy. *J Pediatr Surg*. 1998 Nov;33(11):1651–4.
- [26] Brown JC, Chapman T, Klein EJ, Chisholm SL, Phillips GS, Osincup D, et al. The utility of adding expiratory or decubitus chest radiographs to the radiographic evaluation of suspected pediatric airway foreign bodies. *Ann Emerg Med*. 2013 Jan;61(1):19–26.
- [27] Kocaoglu M, Bulakbasi N, Soylu K, Demirbag S, Tayfun C, Somuncu I. Thin-section axial multidetector computed tomography and multiplanar reformatted imaging of

children with suspected foreign-body aspiration: Is virtual bronchoscopy overemphasized? *Acta Radiol Stockh Swed* 1987. 2006 Sep;47(7):746–51.

- [28] Haliloglu M, Ciftci AO, Oto A, Gumus B, Tanyel FC, Senocak ME, et al. CT virtual bronchoscopy in the evaluation of children with suspected foreign body aspiration. *Eur J Radiol*. 2003 Nov;48(2):188–92.
- [29] Zur KB, Litman RS. Pediatric airway foreign body retrieval: surgical and anesthetic perspectives. *Paediatr Anaesth*. 2009 Jul;19, Suppl 1:109–17.
- [30] Fidkowski CW, Zheng H, Firth PG. The anesthetic considerations of tracheobronchial foreign bodies in children: a literature review of 12, 979 cases. *Anesth Analg*. 2010 Oct;111(4):1016–25.
- [31] Park AH, Tunkel DE, Park E, Barnhart D, Liu E, Lee J, et al. Management of complicated airway foreign body aspiration using extracorporeal membrane oxygenation (ECMO). *Int J Pediatr Otorhinolaryngol (Internet)*. 2014 Oct (cited 2015 Jan 7); Available from: <http://linkinghub.elsevier.com/retrieve/pii/S016558761400576X>
- [32] Ulkü R, Onen A, Onat S, Özçelik C. The value of open surgical approaches for aspirated pen caps. *J Pediatr Surg*. 2005 Nov;40(11):1780–3.
- [33] Wyllie R. Foreign bodies in the gastrointestinal tract. *Curr Opin Pediatr*. 2006;18(5):563–4.
- [34] Denney W, Ahmad N, Dillard B, Nowicki MJ. Children will eat the strangest things: a 10-year retrospective analysis of foreign body and caustic ingestions from a single academic center. *Pediatr Emerg Care*. 2012;28(8):731–4.
- [35] Uyemura MC. Foreign body ingestion in children. *Am Fam Physician*. 2005 Jul 15;72(2):287–91.
- [36] Sharpe SJ, Rochette LM, Smith GA. Pediatric battery-related emergency department visits in the United States, 1990-2009. *Pediatrics*. 2012 Jun;129(6):1111–7.
- [37] Dahshan A. Management of ingested foreign bodies in children. *J Okla State Med Assoc*. 2001 Jun;94(6):183–6.
- [38] Arana A, Hauser B, Hachimi-Idrissi S, Vandenplas Y. Management of ingested foreign bodies in childhood and review of the literature. *Eur J Pediatr*. 2001;160(8):468–72.
- [39] Jatana KR, Litovitz T, Reilly JS, Koltai PJ, Rider G, Jacobs IN. Pediatric button battery injuries: 2013 task force update. *Int J Pediatr Otorhinolaryngol*. 2013 Sep;77(9):1392–9.
- [40] Jatana K. Button Battery Injuries in Children: A Growing Risk. *Everything Matters in Patient Care*. Nationwide Children's Hospital, Columbus, OH; 2013.

- [41] Eisen GM, Baron TH, Dominitz JA, Faigel DO, Goldstein JL, Johanson JF, et al. Guideline for the management of ingested foreign bodies. *Gastrointest Endosc.* 2002 Jun;55(7):802–6.
- [42] Younger RM, Darrow DH. Handheld metal detector confirmation of radiopaque foreign bodies in the esophagus. *Arch Otolaryngol Neck Surg.* 2001 Nov 1;127(11):1371–4.
- [43] Lee J, Ahmad S, Gale C. Detection of coins ingested by children using a handheld metal detector: a systematic review. *Emerg Med J EMJ.* 2005 Dec;22(12):839–44.

IntechOpen