

# We are IntechOpen, the world's leading publisher of Open Access books Built by scientists, for scientists

**4,800**

Open access books available

**122,000**

International authors and editors

**135M**

Downloads

Our authors are among the

**154**

Countries delivered to

**TOP 1%**

most cited scientists

**12.2%**

Contributors from top 500 universities



**WEB OF SCIENCE™**

Selection of our books indexed in the Book Citation Index  
in Web of Science™ Core Collection (BKCI)

Interested in publishing with us?  
Contact [book.department@intechopen.com](mailto:book.department@intechopen.com)

Numbers displayed above are based on latest data collected.  
For more information visit [www.intechopen.com](http://www.intechopen.com)



---

# Brain Hydatid Cyst

---

Said Hilmani

Additional information is available at the end of the chapter

<http://dx.doi.org/10.5772/60820>

---

## Abstract

Brain echinococcosis is the most common brain parasitic infection in the world. It happens in a very rare location, representing 1% to 2% all cases with hydatid disease. It is more common by approximately 50–70% in pediatric population and young adults with a male predominance. The definite hosts of echinococcus are various carnivores; man is an accidental host. The growth of hydatid cysts is usually slow and asymptomatic, and clinical manifestations are caused by compression of the involved organ. CT provides definitive results of diagnosis. It shows hydatid cyst as a spherical, well defined, thin walled, homogeneous and non-enhancing cystic lesion without peripheral oedema. Dowling technic is the most commonly done procedure designed to give birth to the intact cyst by irrigating saline between cyst wall-brain interfaces. Medical treatment can be indicated in multiple locations and in cases with peroperative rupture. Prognosis is often good, but some complications can occur after surgery and depend on the location, the size, the number of cysts and the technique used.

**Keywords:** Brain hydatid cyst, Echinococcosis, CT, Dowling technic

---

## 1. Introduction

Echinococcosis, also referred to as hydatid disease, is a general term used to define zoonosis caused by Echinococcus tapeworms, or cestodes. There are four types of Echinococci, the most common seen worldwide is Echinococcus granulosus whose adult form parasite the dog's small intestine and the larval form that develops in humans, and alveolar echinococcosis, caused by *Echinococcus multilocularis* and restricted to the northern hemisphere (12). Echinococcosis of the central nervous system is the most common brain parasitic infection in the world. It is a

cosmopolitan anthroponosis and represents a significant public health problem. Humans are the accidental intermediate host in the life cycle of this genus. Intracranial pressure, seizure and focal deficit are common signs. CT scan and MRI are the choice exams. Surgery is the radical treatment.

## 2. Epidemiology

Hydatid disease is endemic in Mediterranean countries, Middle East, South America, North Africa and Australia (14). The achievement pulmonary pleura is the second frequency (15–40%) after the liver and associated to brain localization in 30% (7). Intracranial hydatid disease is rare, with reported incidence of 1–2% of all cases with hydatid disease (1,5). There are less than 5 cases per year in our practice (15). Cerebral hydatid disease is more common in pediatric population and young adults approximately 50–70%, with a male predominance. Sixty percent of our patients were males (9,15). Patients with cerebral hydatid cysts may have hydatid cysts in other organs in 10% to 28% of the cases, especially hepatic, pulmonary and other organs. In general abdominal ultrasound and chest X-ray are sufficient to determine those locations.

## 3. Pathophysiology

Hydatid disease is due to the larval form of *Taenia dog*. The definite hosts of echinococcus are various carnivores, the common being the dog, which develop the adult worm in the gut following ingestion of the larvae that are present in the tissues of the intermediate host (typically sheep and goats and occasionally, humans) and then go on to develop in the visceral tissue, particularly in the liver and lungs. Man is an accidental host. He gets infected through the faeco-oral route by ingestion of food contaminated by dog faeces containing ova of the parasite or by direct contact with dogs. The embryos pass through the wall of the gut into the portal system and are carried to the liver where most larvae get entrapped and encysted. Some may reach the lungs and occasionally, some may pass through the capillary filter of the liver and lungs and get entry into the systemic circulation, to the brain or bone (6). The cerebral hydatid cysts are slow growing and present late when they increase in size and become large. There is no consensus on the growth rate of the hydatid cysts of the brain and has been variably reported between 1.5 and 10 cm/year (5). Intracranial hydatid cyst may also be classified as primary or secondary. The primary cysts are formed as a result of direct infestation of the larvae in the brain without demonstrable involvement of other organs. In the human host, a hydatid cyst can lead to life-threatening complications, such as cyst rupture, with the spread of new cysts, and bacterial infection.

There are some risk factors. Rural origin of adult patients was reported in over 70% of cases (1). Exposure may be the result of contact with dogs from breeders, farmers, butchers, veterinarians, or during recreational activities (hunting). Comorbidity is observed in some adults patients such as hypertension, diabetes, chronic lung disease or hepatitis.

## 4. Pathology

Hydatid cyst is formed by two membranes. First is an outer circular membrane made of concentric layers acidophilic, soft and acellular, milky characteristic appearance. And another is an internal germinal membrane, thin, grainy and nucleate. The cyst contains a liquid compound NaCl, carbohydrate, protein and lipid. This liquid has a spring water appearance if the cyst is healthy, opalescent or purulent if infected. Daughter vesicles fertile cyst containing 10 to 100 scolex, born of the germinal membrane and bathed in liquid hydatid. This explains the interest to evacuate the block cyst to avoid dissemination. Between brain tissue and cyst volume increase, forms a third membrane or adventitious, easy peel and helps to better remove the cyst fluid (3).

## 5. Clinical presentation

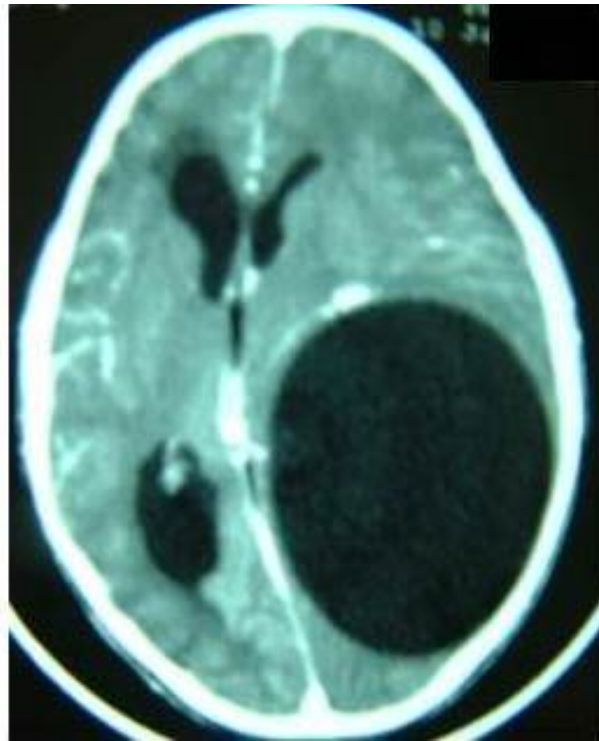
The growth of hydatid cysts is usually slow and asymptomatic, and clinical manifestations are caused by compression of the involved organ. The average time before diagnosis is 7 months (15 days to 3 years). The patients with intracranial hydatid cysts usually present with features of raised intracranial pressure may be complicated by blindness or loss consciousness; focal neurological deficit and seizure. Papilloedema is usually present in patients with intracranial hydatid cysts at the time of diagnosis.

## 6. Diagnosis

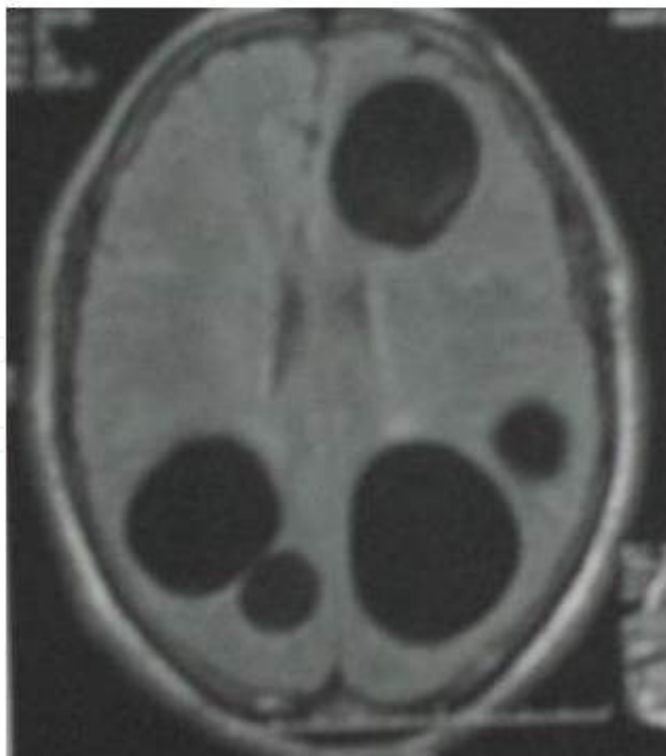### 6.1. Imagery

CT provides definitive results of diagnosis. The exact location, size and number of hydatid cysts in the brain can be determined with a CT scan. However, MR is becoming more and more widely used as a diagnostic tool as it can show details that cannot be seen on CT (18). CT scan and MRI characteristically show hydatid cyst as a spherical, well defined, thin walled, homogeneous and non-enhancing cystic lesion without peripheral oedema. The fluid density is generally equal to that of CSF. The cyst wall usually show a rim of low signal intensity on both T1- and T2-weighted images (Figures 1 and 2). The presence of daughter cysts is considered pathognomonic but has been rarely reported (18). Compression of the midline structures and ventricles are seen in most of the cases, however surrounding oedema is usually absent in uncomplicated cases.

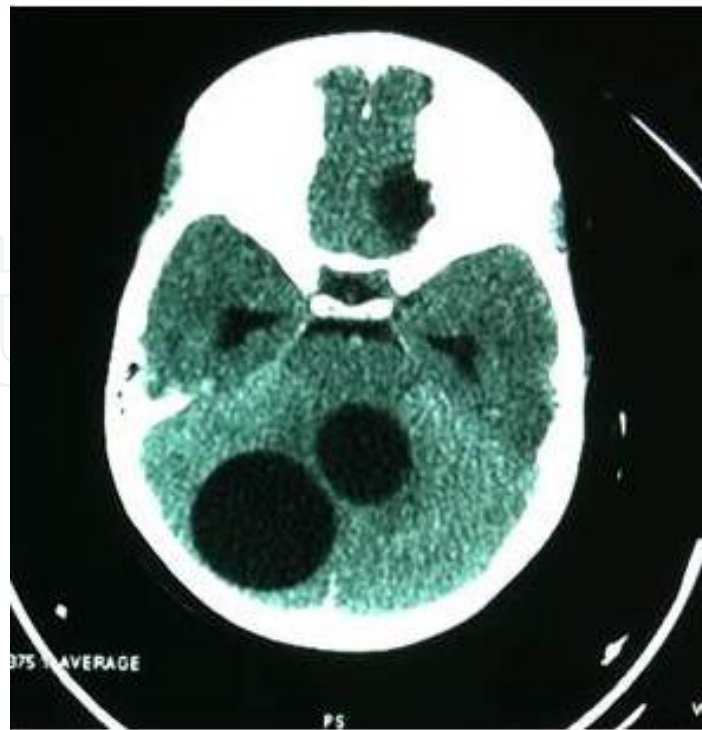
Intracranial hydatid can occur anywhere within the brain, but are more frequently located in the supratentorial compartment, especially in the middle cerebral artery territory. The parietal lobe is the most common site with 69% (11). Cerebellar location (Figure 3) is rare and serious with the risk of cerebral herniation and very rarely in the ventricles (18).



**Figure 1.** CT scan of solitary cerebral hydatid cyst.



**Figure 2.** MRI T1 weighted image of multiple cerebral hydatid cyst.

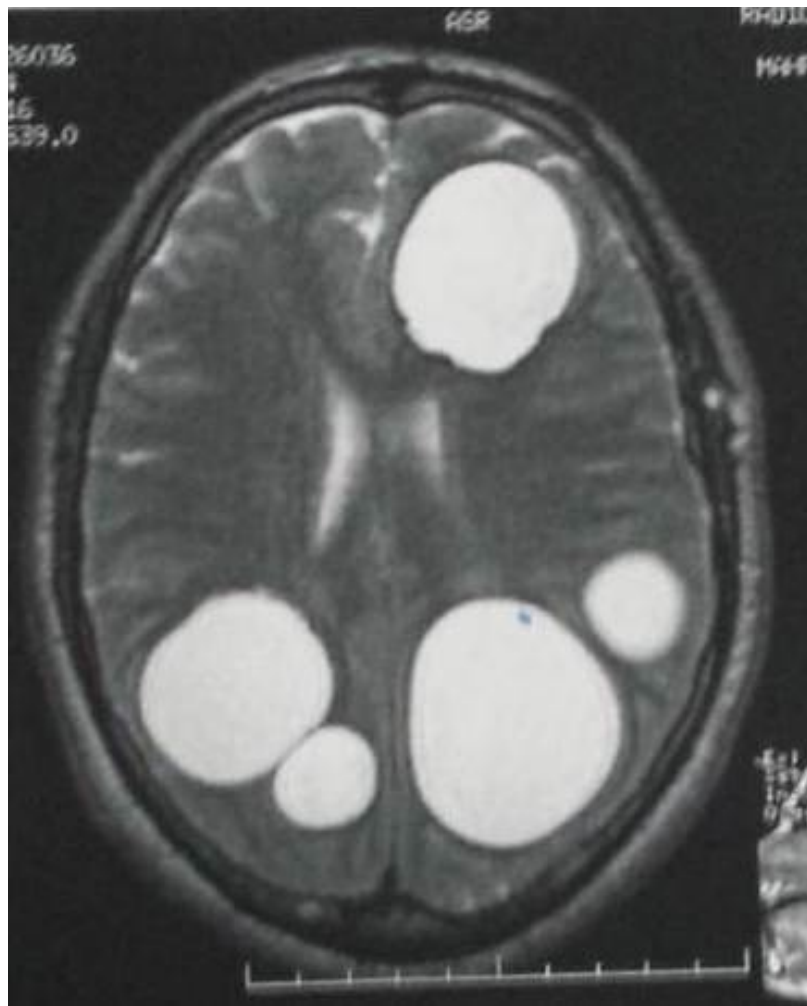


**Figure 3.** CT scan of double cerebellar hydatid cyst.

Exceptionally the skull can be reached after meningeal invasion (10). Cysts may be single or multiple (Figure 4), uni- or multiloculated. Intracranial hydatid cysts are commonly solitary in 93% (11). Multiple intracranial cysts are rare (18). We have reported 3.4% of each multiple and multiloculated hydatid cysts (15). They result from spontaneous, traumatic or surgical rupture of a solitary primary cyst or as a consequence of a cyst rupture elsewhere and embolization of hydatids to the brain. In those cases it is necessary to search a cardiac location (2). A few cases of calcified or infected cyst were reported in the literature as in our series (10,11). The differential diagnosis of intracerebral hydatid cysts includes cystic lesions such as arachnoid cyst, cystic tumor of the brain and pyogenic abscess. In contrast to hydatid cysts, arachnoid cysts are not spherical in shape and not surrounded entirely by brain substance. Arachnoid cysts are extra-axial masses that may deform adjacent brain. Cystic tumors of the brain could be differentiated by the enhancement of the mural nodule. When a pyogenic abscess shows a cyst-like central necrotic area, peripheral oedema is almost always present and the rim enhances intensely following contrast administration (18). Proton MR spectroscopy and diffusion-weighted MR imaging have been used to distinguish between cerebral abscess and cystic or necrotic brain tumor. Shukla-Dave et al. (16) reported three cases of hydatid cysts demonstrated an increase in lactate, acetate and succinate.

## 6.2. Biology

The definitive diagnosis is by physical imaging methods – CT and MRI. Immunodiagnosis can also play an important complementary role. It is useful not only for primary diagnosis but also for follow-up of patients after surgical or pharmacological treatment. The enzyme-linked



**Figure 4.** MRI T2 weighted image of multiple cerebral hydatid cyst.

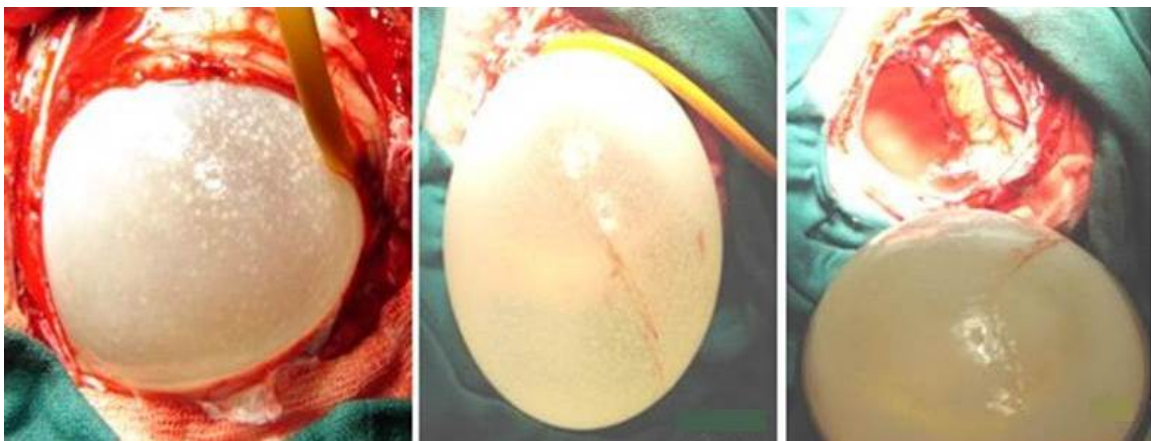
immunosorbent assay (ELISA), the indirect immunofluorescence antibody test, immunoelectrophoresis, and immunoblotting are the hydatid serological testing in laboratory application (12,17). ELISA for specific anti-echinococcus IgG and IgE titer detection is frequently used in cystic echinococcosis serological diagnosis and screening, as it requires a short preparation time, and shows a sensitivity and specificity of 95%. (11). But in primary brain location, it is rarely positive. It was positive in less than 4% in our series. Hyper-eosinophilia can be observed in cases with other visceral location. In the literature, cystic echinococcosis diagnosis and follow-up eosinophil cell counts have usually been considered of limited value because it is significantly high in no more than half of CE affected patients (6). Sedimentation rate is normal in healthy cyst, and can be accelerated if infected.

## 7. Treatment

The treatment of hydatid cyst is surgical and the aim of surgery is to excise the cyst in toto without rupture to prevent recurrence and anaphylactic reaction.

## 7.1. Surgery

The most commonly done procedure designed to give birth to the intact cyst by irrigating saline between cyst wall-brain interfaces (Figure 5). This technique, reported by Dowling and improved by Arana-Iniguez, is possible because of minimal adhesions around the cyst wall (4). Aspiration of the cystic contents through puncturing during the surgery for deep-seated cyst or cysts which located in critical areas is an alternative method, especially as multiple hydatid cysts resulting from the rupture of a primary cyst are infertile and have no broad capsule which permits the use of Dowling technique. Scolicide product use, as hypertonic saline serum, is essential to protect the brain parenchyma and the risk of dissemination in cases of intraoperative rupture. For multiple and bilateral hydatid cysts the surgery must be done in several times.



**Figure 5.** Dowling technique of solitary cerebral hydatid cyst.

## 7.2. Medical treatment

Only a few reports are available mentioning the efficacy of drug therapy. Albendazole therapy in a daily dose of 10 mg/kg, taken for four months, is a broad spectrum oral antihelminthic drug, which act by blocking glucose uptake of the larvae and the adult worm. The glycogen storage is depleted and thereby decreasing the ATP formation resulting in the death of the parasite (8). We think that medical treatment can be indicated in multiple locations and in cases with preoperative rupture.

## 8. Post-operative complications

Same complications can occur after surgery and depend on the location, the size, the number of cysts and the technique used. Hyperthermia within non meningitis or superinfection of the residual cavity, can be related to the translational phenomenon of brainstem during the evacuation of the cyst. It can be avoided by keeping the head turned to the opposite side of the lesion.



## 9. Evolution

Total recovery of the neurological deficit occurs in the majority of cases “90% in our practice”. The risk of recurrence is about 19% and is correlated with the rate of intraoperative rupture of the cyst (6). The mortality is about 9% and is not negligible. Morbidity associated to hydatid cyst boils down a focal deficit or seizure (13).

## 10. Conclusion

Cerebral hydatid cyst is a rare disease that occurs in children with a history of contact with dogs. The definite hosts of echinococcus are various carnivores – man is an accidental host. It is most often manifested by intracranial hypertension, seizures and focal neurological deficit. The diagnosis is strongly suspected to brain CT scan. It show hydatid cyst as a spherical, well defined, thin walled, homogeneous and non-enhancing cystic lesion without peripheral oedema. MRI is especially useful in cases of hydatid cyst revamped to make the differential diagnosis with other cystic intracranial process. The positive hydatid serology is only suggestive. The treatment of choice is surgery with total removal without rupture, using Dowling technic, except in deep location. Medical treatment can be indicated in multiple locations and in cases with peroperative rupture. The prognosis is usually good if early diagnosis and out of multiple brain locations that pose a serious therapeutic problem.

## Author details

Said Hilmani\*

Address all correspondence to: hilmani.said@yahoo.fr

Neurosurgical Department, Hassan II University, Casablanca, Morocco

## References

- [1] Abbassioun K, Amirjamshidi A. Diagnosis and management of hydatid cyst of the central nervous system: Part 2 : hydatid cysts of the skull, orbit and spine. *Neurosurgery*, Vol. 11, March 2001: 10–16.
- [2] Ait Ben Ali S, Hilmani S, Choukri M, Sami A, El Azhari A, Achouri M, Ouboukhlik A, El Kamar A, Boucetta M. Multiple cerebral hydatid cysts of cardiac origin. *Neurochirurgie*. 1999 Dec;45(5):426–429.

- [3] Alzain TJ, Alwitry SH, Khalili HM. Multiple intracranial hydatidosis. *Acta Neurochirurgica*. 2002, 144, 1179–1185.
- [4] Arana Iniquez R. Echinococcus. Infection of the Nervous System. *Hand Book of Clinical Neurology, Part III*, Eds. Vinken PJ, Bruyn GW, Elsevier/North Holland Biomedical Press, Amsterdam 1978; 175–208.
- [5] Bouaziz M. Calcified cerebral hydatid cyst: a case report. *Sante*. 2005 Apr–Jun; 15.
- [6] Cappello E, World J. *Gastroenterol*. 2013 December 28; 19(48): 9351–9358
- [7] Ciurea AV, Vasilescu G, Nuteanu L, Carp N. Cerebral hydatid cyst in children. Experience of 27 cases. *Childs Nerv Syst*. 1995 Dec; 11(12): 679–685.
- [8] Golematis B, Lakiotis G, Pepsidou GP et al. Albendazole in the conservative treatment of multiple hydatid disease. *Sinai J Med*. 1989; 56: 53–55.
- [9] Haliloglu M, Saatci I, Akhan O, Ozmen MN, Besim A. Spectrum of imaging findings in pediatric hydatid disease. *AJR Am J Roentgenol*. 1997;169:1627–1631.
- [10] Hilmani S, Bertal A, Lakhdar A, Ouboukhlik A, Elkamar A, Elazhari A. Craniocerebral hydatid cyst. *J Neurosurg*. 2006 Jul;105(1 Suppl):77.
- [11] Iacona A, Pini C, Vicari G. Enzyme-linked immunosorbent assay (ELISA) in the serodiagnosis of hydatid disease. *Am J Trop Med Hyg*. 1980; 29: 95-102.
- [12] McManus D. P, W. Zhang, J. Li, and P. B. Bartley. Echinococcosis. *The Lancet*. 2003, 362, 9392, 1295–1304.
- [13] Nur A, Murad B, Hakan H, Bülent E. Central nervous system hydatidosis in Turkey: a cooperative study and literature analysis of 458 cases. *J. Neurosurgery*. 2000, July, Vol.93: 1-8.
- [14] Onal C, Orhan B, Metis O et al. Three unusual cases of intracranial hydatid cysts in paediatric age group. *Pediatr Neurosurg*. 1997; 26 : 208-213.
- [15] Salaou O, Ibahioin Kh, Chellaoui A, Hilmani S, LAakhdar A, Ouboukhlik A, EL kamar A, EL Azhari. AIntracerebral hydatid cyst: 104 cases. *AJNS*. 2007 Vol. 26, No 1.
- [16] Shukla-Dave A, Gupta RK, Roy R, Husain N, Paul L, Venkatesh SK, Rashid MR, et al. Prospective evaluation of in vivo proton MR spectroscopy in differentiation of similar appearing intracranial cystic lesions. *Magn Reson Imaging*. 2001; 19:103–10.
- [17] Wenbao Zhang, Jun Li, and Donald P. McManus. Concepts in immunology and diagnosis of hydatid disease. *Clinical Microbiology Reviews*. Jan. 2003, 18–36.
- [18] Yas, A, Serdar K, Hasan N, Umit O, Adnan C, Masum S. Cerebral hydatid disease: CT and MR imaging findings. *Swiss Med Wkly*. 2004; 134: 459–467.

