

We are IntechOpen, the world's leading publisher of Open Access books Built by scientists, for scientists

4,800

Open access books available

122,000

International authors and editors

135M

Downloads

Our authors are among the

154

Countries delivered to

TOP 1%

most cited scientists

12.2%

Contributors from top 500 universities



WEB OF SCIENCE™

Selection of our books indexed in the Book Citation Index
in Web of Science™ Core Collection (BKCI)

Interested in publishing with us?
Contact book.department@intechopen.com

Numbers displayed above are based on latest data collected.

For more information visit www.intechopen.com



Recurrent Ovarian Cancer — Basic Knowledge, Current Management, and Future Directions

Bernardo L. Rapoport

Additional information is available at the end of the chapter

<http://dx.doi.org/10.5772/60609>

Abstract

Recurrent ovarian cancer is incurable. Chemotherapy is indicated to control disease-related symptoms. The benefit from chemotherapy in these patients depends on the platinum-free interval. Patients with platinum-resistant disease (a relapse of less than six months from the completion of platinum treatment) are managed with non-platinum agents. Patients with platinum semi-sensitive relapse (six to 12 months from the completion of treatment) have a response rate of 30% to second-line platinum treatment. In patients with platinum-sensitive relapse (more than 12 months from the completion of treatment), the response rate to platinum is 60–70%. Limited data is available regarding the benefits of secondary cytoreductive surgery. GOG 213 and the AGO Desktop III studies will define the role of this procedure in patients with recurrent disease. Two studies have shown benefit of bevacizumab in the treatment of patients with platinum-sensitive (Oceans) and refractory disease (Aurelia). Additional studies are needed to establish the optimal duration and timing of treatment. Cediranib has shown activity in patients with recurrent platinum-sensitive ovarian cancer (ICON 6 trial). Numerous novel biological agents are being investigated in relapsed ovarian cancer. This chapter focuses on current management and future directions in patients with relapsed ovarian cancer.

Keywords: Ovarian Cancer, relapsed, platinum sensitive, targeted therapy

1. Introduction

The vast majority of patients with advanced ovarian cancer will recur after first-line chemotherapy. [1] A common sign of relapse is a rise in the serum CA-125 level in the absence of symptoms (defined as marker-only relapse) or objective evidence of disease as assessed by physical or radiological examinations. Recurrent disease is not curable, and the majority of patients with recurrent disease will succumb to their disease irrespective of the second-line

treatment modality used. As there is no compelling evidence that early treatment with chemotherapy is beneficial in relapsed asymptomatic disease, patients with marker-only-relapse are often observed. The MRC OV05/EORTC 55955 did not show a survival benefit with early treatment of relapse on the basis of a raised CA125 concentration only. [2] Some patients with asymptomatic disease with tumour-marker elevation only may develop symptomatic disease within months, while others may take years. [2] Assessment of the rate of progression by CA 125 is essential and useful for most patients with advanced ovarian cancer in remission. CA 125 is elevated in most patients with documented progressive disease. Serial measurement is a useful marker to assess the response to chemotherapy according to GCIG criteria. [3] Clinicians should keep in mind that CA 125 is not specific for ovarian cancer. Raised CA 125 levels may also be found in non-gynaecological malignancies (breast cancer and lung cancer, as well as colon and pancreatic malignancies). An elevated CA 125 can be found in patients with benign conditions such as endometriosis, pelvic inflammatory disease, and ovarian cysts.

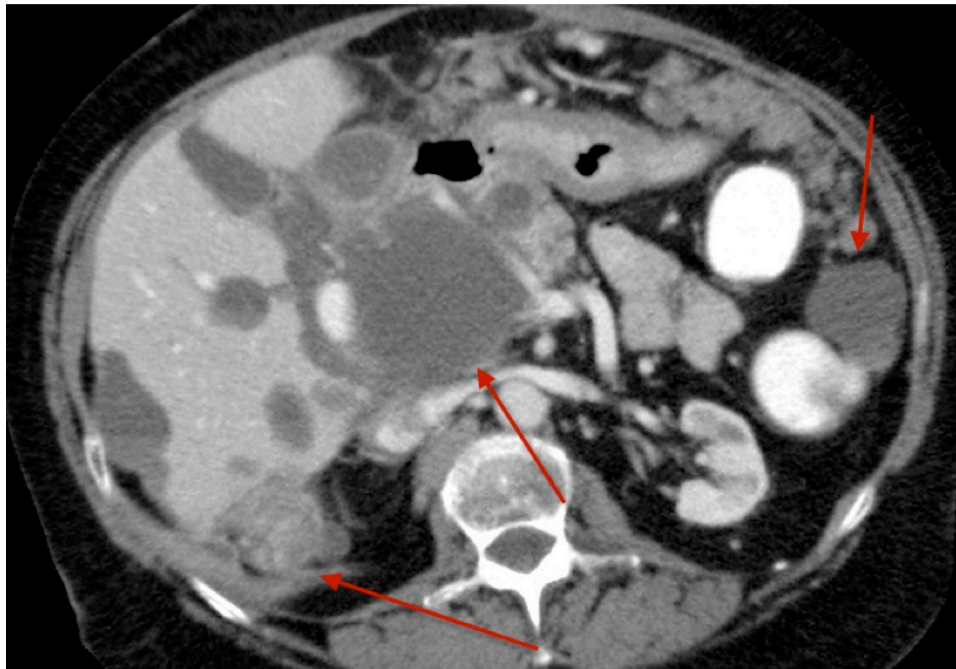


Figure 1. Progressive disease — shows multiple complex cystic/solid peritoneal deposits on the liver's surface (visceral peritoneum) and elsewhere in the peritoneal cavity.

2. Chemotherapy

The role of chemotherapy in the management of recurrent ovarian cancer is palliative and is usually indicated for ovarian cancer-related symptoms, or for patients with objective evidence of significant disease progression on physical or radiological examination.

The likelihood of benefit from chemotherapy treatment in patients with relapsed ovarian cancer depends on the platinum-free interval (PFI). PFI is defined as the interval between the

last dose of platinum and the time of relapse. Patients with platinum-resistant disease (PFI of less than six months) are unlikely to respond to second-line platinum agents and are often managed with an alternative agent (see Table 1). Patients with platinum semi-sensitive disease (PFI of between six and 12 months) have a response rate of approximately 30% to second-line platinum treatment. In patients with fully platinum-sensitive disease (PFI more than 12 months with a subset greater than 24 months), the response rate to second-line platinum may be as high as 60–70%. [4]

The role of combination chemotherapy has been assessed in randomized trials in the setting of platinum semi-sensitive and fully sensitive relapses. Patients with fully sensitive disease should be re-challenged with a platinum-based (cisplatin or carboplatin) chemotherapy regime. [5] Patients with platinum semi-sensitive disease should be treated with a platinum-based doublet combination. It has been demonstrated that retreatment results in valuable responses that translate into improvement in quality of life and survival. Patients with a PFI of greater than six months usually receive treatment with a platinum-based regimen either as a single-agent or in combination with agents like paclitaxel [6], gemcitabine [7], or pegylated liposomal doxorubicin (PLD) [8]

Agent (months)	Author (%)	ORR (months)	PFS (months)	OS
Liposomal Doxorubicin	Colombo [14]	15	3.9	13.2
Topotecan weekly	Sehouli [18]	19	3.7	9.6
Paclitaxel weekly	Markman [15]	20	5.6	13.5
Paclitaxel 3 weekly	Trimble [16]	22	4.5	8.8
Docetaxel	Francis [17]	40	5.0	8.0
Gemcytabine	Lund [19]	19	2.8	6.2
Pemetrexed	Miller [20]	21	2.9	11.4
Etoposide oral	Rose [22]	26	5.7	10.8
Ixabepilone	De Geest [21]	14	4.4	14.8

Table 1. Platinum refractory.

The International Collaborative Ovarian Neoplasm-4 (ICON-4) trial compared combination chemotherapy with paclitaxel and platinum to single-agent platinum in patients with platinum-sensitive disease. In this study, most patients had a PFI of 12 months or greater. ICON-4 showed a statistically significant improvement in overall survival (OS) in favour of combination chemotherapy for recurrent ovarian cancer, with a 7% absolute increase at two years ($P = 0.023$). Although the ICON-4 trial showed a positive outcome, the results remain controversial because of methodological limitations. Around, 40% of patients randomized to the platinum single-agent arm never received a taxane during the course of their disease, including first-line therapy and at disease progression, raising the possibility that the sequential use of platinum followed by paclitaxel at disease progression might have conferred the same survival advantage. [6]

Docetaxel has been investigated in the treatment of metastatic ovarian cancer, in both the front-line and relapsed setting. In the front-line setting, docetaxel was shown to be equivalent to paclitaxel. [9] Docetaxel may also be a useful choice for patients at risk of developing peripheral neuropathy. [9–11]

In a subsequent study, the AGO (Arbeitsgemeinschaft Gynaekologische Onkologie) from Germany conducted a randomized Phase III trial in patients with platinum-sensitive relapse to either gemcitabine and carboplatin, or carboplatin alone. [7] PFS was 8.6 months for the combination versus 5.8 months for single-agent carboplatin ($P = .0038$), with no improvement in OS. Quality of life was similar between the two arms, despite a higher incidence of thrombocytopenia, neutropenia, and anaemia with the combination.

Rapoport et al. investigated pegylated liposomal doxorubicin (PLD) in combination with carboplatin in a Phase II trial in patients with relapsed ovarian cancer with semi-sensitive and fully sensitive relapse. Results were encouraging, with a complete response rate of 35% and a partial response rate of 32.5% (overall response, 67.5%). Median time to progression was 11.9 months, and median survival was 30.0 months. Overall responses were higher in the platinum fully sensitive subgroup as opposed to the semi-sensitive group. [12] The GCIIG (Gynecologic Cancer Intergroup) conducted a Phase III study (CALYPSO trial) comparing paclitaxel and carboplatin with PLD and carboplatin in patients presenting with platinum-sensitive relapse. There was a significant improvement in median progression-free survival (PFS) (11.3 months vs. 9.4 months; $P = .005$), with a lower incidence of severe hypersensitivity reactions (5% vs. 18%), in favour of the PLD-containing arm. No difference in OS was noted. Toxicities were similar to the toxicities reported in the Phase II study by Rapoport et al. and included grade 2 or greater alopecia (83.6% vs. 7%) and sensory neuropathy (26.9% vs. 4.9%) in the paclitaxel-containing arm, and with more hand-foot syndrome (grades 2 to 3, 12.0% vs. 2.2%), nausea (35.2% vs. 24.2%), and mucositis (grades 2 to 3, 13.9% vs. 7%) in the PLD containing arm. [8]

As recurrent ovarian cancer is incurable, palliation and symptom control is the goal of second-line treatment. Choosing the most appropriate agent for use in the recurrent disease setting, therefore, involves balancing the need to attain a response to treatment against maintenance of reasonable quality of life. The decision to use platinum-based chemotherapy combinations or single-agent platinum in this setting should be based on a number of factors. These factors include patient age, disease burden, rate of relapse, and patient preference. For elderly patients who require chemotherapy for mild symptomatic and low tumour burden, platinum-sensitive relapse, the usage of single-agent carboplatin is a reasonable approach. PLD is a well-tolerated alternative in patients that develop an allergy to carboplatin during the course of treatment or if further use of carboplatin is contraindicated. Both agents are associated with a good quality of life as well as acceptable toxicity profiles in terms of alopecia or severe myelosuppression. A more aggressive approach is needed for younger patients with rapidly growing cancer and platinum-sensitive relapse. Combination chemotherapy with either paclitaxel and carboplatin, docetaxel and carboplatin [13], gemcitabine and carboplatin [7], or PLD and carboplatin are reasonable [8].

Patients with platinum/taxane-resistant disease (defined by a short PFI of less than six months, or progression during platinum-based chemotherapy) are best treated with agents who lack cross-resistance to platinum compounds or are not susceptible to the common resistance mechanisms.

Potentially non-cross-resistant drugs with activity in the platinum-resistant setting include PLD [14], paclitaxel [15–16], docetaxel [17], topotecan [18], gemcitabine [19], pemetrexed [20], ixabepilone [21], or oral etoposide [22] (Table 1). In the platinum-resistant setting, the overall response rate to any of these agents is approximately 20%. Responses are short, with a median PFS of four to six months. These responses are progressively shorter with each subsequent regimen.

In the setting of platinum-resistant relapse, PLD is well tolerated at doses of 40 mg/m² given every four weeks. Common toxicities include palmer-plantar erythrodysesthesia (hand-foot syndrome) and mucositis. Topotecan may cause significant myelosuppression and fatigue. A recently reported Phase II randomized multicenter study however showed that weekly topotecan has a favourable toxicity profile compared to the conventional 5-day schedule of topotecan with similar OS. [23]

The Cochrane Gynaecological Cancer Group conducted a meta-analysis of 14 randomized trials evaluating the usefulness of PLD in relapsed epithelial ovarian cancer. Results of this meta-analysis concluded that in patients with platinum-sensitive disease, PLD and carboplatin is more effective than paclitaxel and carboplatin, and is better tolerated. Therefore, PLD and carboplatin should be considered as the first option of treatment in women with platinum-sensitive relapse. PLD alone is also a useful agent for platinum-resistant disease. It remains unclear, however, how it compares with other single agents in this subgroup, and in which order these agents should be used. There is no data available to support the use of PLD in combination with other agents in patients with platinum-resistant relapse. [24]

As a general rule, combination chemotherapy regimens are not superior to single agents in the management of patients with platinum-resistant relapse. Combination regimens are also more toxic and should not be used in this palliative setting.

3. The role of surgery in the treatment of relapsed ovarian cancer

3.1. Secondary cytoreductive surgery

Surgery for the debulking of disease at the time of relapse, referred to as secondary cytoreductive surgery, is performed in selected patients prior to second-line chemotherapy. [25]

Due to a lack of large randomized trials, conclusive data are limited regarding the benefits of secondary cytoreductive surgery. The ability to complete a successful secondary cytoreduction may identify patients presenting with a biologically less aggressive disease or those patients who have a lower tumour burden at the time of relapse. A prospective randomized trial of secondary cytoreduction is required to determine whether this procedure improves survival in these patients. The value of secondary cytoreduction is currently being investigated in two prospective, randomized trials, GOG 213 and the AGO Desktop III study.

The Gynaecologic Oncology group (GOG) currently defines 'optimal' cytoreductive surgery as having residual tumours having a maximum diameter of 1 cm or less. Complete cytoreduction is the ideal surgical outcome in the form of microscopic disease. [26]

Secondary cytoreduction might be considered for the subgroup of patients with a progression-free interval of more than 12 to 18 months from the time of completion of adjuvant chemotherapy, localized recurrence amenable to complete cytoreduction, potentially chemosensitive disease, and good performance status. [27–31]

On the other hand, a patient with a rapid, multifocal recurrence is unlikely to obtain any clinical benefit from surgery. [26]

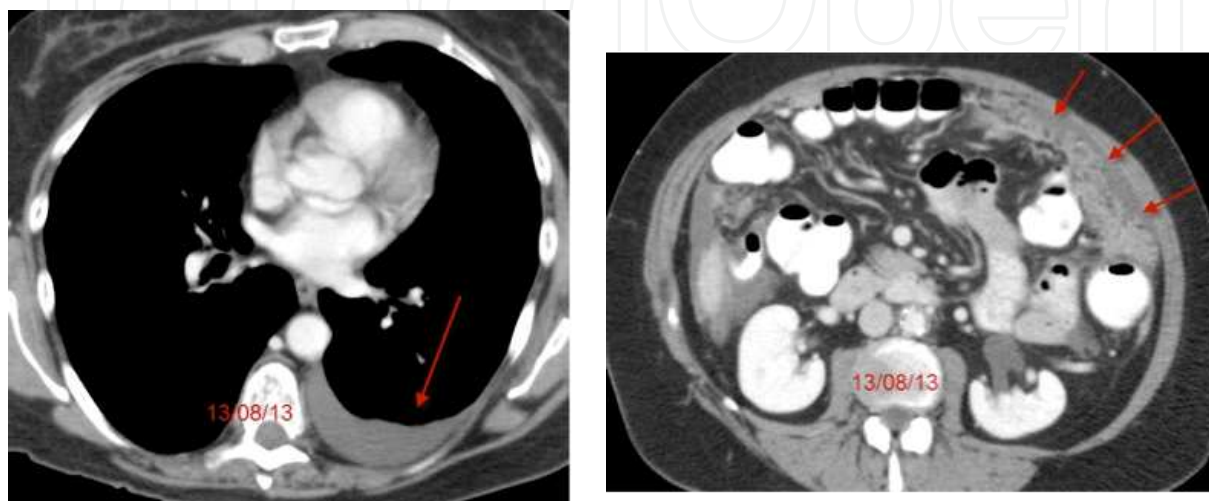


Figure 2. Pleural and peritoneal recurrence.

3.2. Palliative surgery

Palliative surgery may be indicated in patients with recurrent ovarian cancer. Standard operations performed in this setting include colostomy for relief of a large bowel obstruction, treatment of peritoneal adhesions, and management of small bowel obstruction. [32] Surgery to relieve small bowel obstruction should take into account the likelihood of continued responsiveness to chemotherapy postoperatively (platinum-sensitive as opposed to platinum-refractory disease). Women who develop a small bowel obstruction during first-line chemotherapy have aggressive and resistant ovarian cancer, and the procedure is not beneficial in this subset of patients. A palliative gastrostomy tube may be most appropriate in this situation. Best outcomes are seen in women who have had prolonged PFI, usually lasting more than one year.

Surgery is not indicated in the management of patients with a pseudo-obstruction due to an intra-abdominal carcinomatosis and infiltration of the myoenteric plexus of the small bowel. Pharmacological treatment with metoclopramide (an agent that improves motility of the upper gastrointestinal tract without stimulating gastric, biliary, or pancreatic secretions) may be helpful to treat this complication. A palliative colostomy may be indicated for patients developing a large bowel obstruction. This type of surgery can provide significant prolongation of survival and improved quality of life in selected patients.

3.3. Radiation therapy

Radiation therapy may be useful in the palliation of patients with recurrent ovarian cancer. Symptomatic pelvic masses may cause bleeding, pain, and rectal narrowing. Palliative pelvic radiotherapy can offer symptom relief. Cerebral or bone metastases are unusual complications of ovarian cancer and can be successfully palliated with radiotherapy.

4. Investigational Agents

Several investigational agents are being studied in the relapse setting.

4.1. Bevacizumab

4.1.1. *Bevacizumab single-agent activity*

Bevacizumab is a humanized antibody that recognizes and neutralizes vascular endothelial growth factor (VEGF). VEGF is a pro-angiogenic factor that is secreted by ovarian cancer cells. Randomized data in other metastatic malignant diseases have shown a survival advantage for the use of bevacizumab in combination with chemotherapy [33–35].

Single-agent bevacizumab has been shown by the GOG to induce a response rate of 18% in patients with relapsed ovarian cancer. In this GOG trial, there were two complete and 11 partial responses, with a median response duration of 10 months, and 25 patients (40%) survived progression-free for at least six months. Median PFS was 4.7 months and OS was 17 months. This study did not show a significant association with prior platinum sensitivity, age, number of prior chemotherapeutic regimens, or performance status. [36]

Cannistra et al. reported a risk of life-threatening bowel perforation in patients with ovarian cancer treated with bevacizumab. All patients in this trial were heavily pre-treated, with 50% having received three prior regimens. Partial responses were observed in seven patients (15.9%). Median PFS was 4.4 months (95% CI, 3.1 to 5.5 months), with a median survival duration of 10.7 months at study termination. Bevacizumab-associated grades 3 to 4 events included hypertension (9.1%), proteinuria (15.9%), bleeding (2.3%), and wound-healing complications (2.3%). The incidence of bowel perforation was 11.4%. This was higher than reported in bevacizumab trials of other tumour types. Risk factors for bevacizumab-induced bowel perforation included a higher number of prior chemotherapy regimens, radiographic presence of bowel wall involvement by tumour, or evidence of bowel obstruction. [37]

4.1.2. *Bevacizumab in combination with chemotherapy in newly diagnosed ovarian cancer patients*

Two randomized studies (GOG-0218 and ICON7) have shown improvement in the PFS in patients with advanced ovarian cancer treated with chemotherapy and bevacizumab. [38–39] In these trials, bevacizumab was evaluated in combination with standard paclitaxel plus carboplatin as part of initial treatment for women with ovarian cancer. Both these trials met their primary endpoints and demonstrated an improvement in PFS.

In the GOG-0218 trial, 1,873 women with newly diagnosed stage III (incompletely resectable) or stage IV epithelial ovarian cancer which had undergone debulking surgery were randomized to receive one of three treatments in a double-blind, placebo-controlled trial. Each of the three study regimens comprised 22 3-week cycles of intravenous infusions on day one, with the first six cycles consisting of standard chemotherapy with carboplatin and paclitaxel. [38]

Arm 1 – Control: chemotherapy with a placebo added in cycles 2 to 22.

Arm 2 – Chemotherapy with bevacizumab (15mg per kilogram of body weight) added in cycles 2 to 6, and a placebo from cycles 7 to 22.

Arm 3 – Chemotherapy with bevacizumab added in cycles 2 to 22.

At a median follow-up of 17.4 months, the median PFS was 10.3, 11.2, and 14.1 months in the control group, the bevacizumab-initiation group, and the bevacizumab-throughout group, respectively. No significant difference in OS was reported. The potential to detect a difference in survival is likely to be limited by lack of control for multiple subsequent regimens, including crossover to bevacizumab or other anti-VEGF agents. [38]

Although bevacizumab use resulted in additional toxicity, it was not associated with a decrease in quality of life. Grade 2 or greater hypertension was significantly more frequent with use of bevacizumab than a placebo. [38]

The second trial, ICON 7 was led by the U.K. Medical Research Council Clinical Trials Unit. This trial enrolled 1528 women with histologically confirmed, high-risk, early-stage disease (FIGO stage I or IIA and clear-cell or grade 3 tumours), or advanced (FIGO stage IIB to IV) epithelial ovarian cancer, primary peritoneal cancer, or fallopian-tube cancer. Patients were randomized to receive carboplatin and paclitaxel given every three weeks for six cycles, or to the same regimen plus bevacizumab (7.5mg per kilogram) given concurrently every three weeks for five or six cycles and continued for 12 additional cycles or until disease progression. Complete or partial response rates were reported in 67% of patients in the bevacizumab group and 48% in the control group ($p = 0.001$). With a median follow-up of 19.4 months, the data provide clear evidence of the biologic activity of bevacizumab with a median PFS of 19 months compared to 17.4 months in the standard therapy group (HR 0.81, CI, 0.70 to 0.94; $p = 0.004$). Final survival data are expected soon. Bevacizumab treatment did not affect the delivery of chemotherapy; it was, however, associated with a significant increase in side effects, including grade 2 or greater hypertension and bowel perforation. [39]

4.1.3. Bevacizumab in combination with chemotherapy in patients with recurrent platinum-sensitive disease

The OCEANS (Carboplatin and Gemcitabine plus Bevacizumab in Patients with Ovary, Peritoneal, or Fallopian Tube Carcinoma) study showed a benefit for the addition of bevacizumab to platinum-based chemotherapy in terms of PFS and a trend towards a benefit in OS.

Updated data by Aghajanian et al. indicate a median PFS advantage of four months (12.4 vs. 8.4 months) (hazard ratio 0.484) and overall response rate by RECIST of 21% (response rate 78.5% vs. 57.4%) were seen when bevacizumab was added to carboplatin and gemcitabine chemotherapy. Nevertheless, no benefit in OS was seen, but the data is still immature. [40]

Agent	Target	Phase	Clinical Setting
Cediranib	VEGFR1	Phase III	Concurrent carboplatin and paclitaxel for platinum sensitive relapse
	VEGFR2		
	VEGFR3		
	Lymphangogenesis C-Kit		
Aflibercept	VEGF Placental Growth Factor	Phase II	In combination with docetaxel
AMG 386 (Trebananib)	TIE-2 receptor	Phase III	TRINOVA-1 paclitaxel combination and maintenance in platinum sensitive and refractory relapse
	Angiopoietin-1	Phase III	TRINOVA-2 PLD combination and maintenance in platinum refractory relapse
	Angiopoietin-2	Phase III	TRINOVA-3 paclitaxel and carboplatin combination and maintenance in newly diagnosed metastatic disease
BIBF-1120	VEGFR	Phase II	Maintenance of relapsed ovarian cancer
	PDGFR		
	FGFR		
Pazopanib	VEGFR-1	Phase III	Maintenance of advanced ovarian cancer in the front-line setting
	VEGFR-2		
	VEGFR-3		
	PDGFR- α		
	PDGFR- β		
	FGFR-1		
	FGFR-3 C-Kit		
Olaparib	PARP	Phase III	Maintenance in inhibitor platinum-sensitive relapsed

VEGFR: Vascular endothelial growth factor receptor

PDGFR: platelet-derived growth factor receptor

FGFR: fibroblast growth factor receptor

PARP: poly-adenosine diphosphate [ADP]-ribose polymerase

TIE-2 receptor: receptor tyrosine kinase expressed predominantly on endothelial cells

c-Kit: trans-membrane receptor tyrosine kinase KIT, which is defined by the CD117 antigen

Table 2. Antiangiogenesis agents under investigation for the treatment of relapsed ovarian cancer.

4.1.4. Bevacizumab in combination with chemotherapy in patients with platinum-resistant disease

The AURELIA randomized Phase III study showed that addition of bevacizumab to standard chemotherapy with either PLD, topotecan, or weekly paclitaxel was associated with an improvement in PFS of 3.3 months and overall response rate by RECIST of 18%. OS and quality of life data from this study are still immature. [41]

Bevacizumab is an active agent in advanced and recurrent ovarian cancer. Large clinical trials are needed to improve the knowledge of the safety and effectiveness of bevacizumab, the duration and timing of treatment, and activity of this agent when given in combination with other chemotherapeutic agents. There is also an urgent need to identify biologic predictive factors of efficacy. When to start and end anti-angiogenesis therapy remain controversial questions, and further evaluation of personalized novel angiogenesis-based therapy is needed.

4.2. Cediranib

Cediranib (AZD2171) is a highly potent, small-molecule, oral tyrosine kinase inhibitor of VEGFR-1, -2, and -3, and c-Kit, which compete for the ATP-binding site within the receptor kinase domain. [42–43] It is postulated that cediranib is useful in the prevention of tumour progression, by inhibiting VEGFR-2 activity and angiogenesis, and also by concomitantly inhibiting VEGFR-3 activity and lymphangiogenesis.

Cediranib has been shown to be an active drug in recurrent ovarian cancer, fallopian tube, and peritoneal cancer with the predictable toxicities observed with other tyrosine kinase inhibitors. In a Phase II trial, partial responses were seen in eight of the 46 treated patients (17.4%). [44] The original dose was 45 mg/d, but the dose was lowered to 30 mg because of toxicity observed in the first 11 patients. Major grade 3 toxicities included hypertension (46%), fatigue (24%), and diarrhoea (13%). Grade 4 toxicities included central nervous system haemorrhage (n = 1), hypertriglyceridaemia/hypercholesterolaemia/elevated lipase (n = 1), and dehydration/elevated creatinine (n = 1). No GI perforations or fistulas occurred. [44]

Initial results of the international three-arm Phase III randomized trial (ICON 6) showed that the addition of cediranib to chemotherapy (carboplatin and paclitaxel) increased PFS by about three months in women with recurrent platinum-sensitive ovarian cancer. Additional benefit was obtained when cediranib was used as maintenance therapy, increasing overall PFS over chemotherapy alone. The time to disease progression increased from 9.4 to 12.6 months and OS was extended from 17.6 to 20.3 months over a follow-up period of two years. [45, 46]

5. Other investigational agents

Other anti-angiogenic agents have also been evaluated in recurrent ovarian cancer.

Aflibercept is a potent inhibitor of both VEGF and placental growth factor. Aflibercept has shown anti-tumour activity in combination with docetaxel and is useful as a single agent in the reduction of malignant ascites. The combination was tested in a Phase I/II study in patients

with measurable, recurrent, or persistent epithelial ovarian cancer. The confirmed objective response rate was 54% (25 of 46 patients responded to treatment, with 11 patients achieving a complete response and 14 a partial response). [47]

AMG 386 (trebananib) is a peptide-Fc fusion protein that inhibits angiogenesis by neutralizing the interaction between the Tie2 receptor and angiopoietin 1 and 2. Targeting of the angiopoietins/Tie2 pathway as a strategy to overcome bevacizumab resistance and toxicities has gained increasing interest in recent years. A randomized study of 161 patients with recurrent epithelial ovarian, fallopian tube, or primary peritoneal cancer evaluated weekly treatment with paclitaxel plus intravenous AMG 386 at a dose of 10mg/kg week (arm A), weekly paclitaxel plus AMG 386 at a dose of 10mg/kg week (arm B), or weekly paclitaxel plus placebo (arm C). Median PFS was 7.2 months in arm A, 5.7 months in arm B, and 4.6 months in arm C. The study has shown promising anti-cancer activity with a manageable safety profile when combined with weekly paclitaxel and a dose-response effect. [48] A recent publication of 919 enrolled patients, of whom 461 were randomly assigned to the trebananib group and 458 to the placebo group, was associated with a significantly longer median progression-free survival in favour of trebananib compared to placebo (72 months vs. 54 months; hazard ratio 0.66, $p < 0.0001$). There was no significant increase in the incidence of grade 3 or higher adverse events between treatment groups (244 [54%] of 452 patients) for the placebo group compared to 258 [56%] of 461 patients) in the trebananib group. In this Phase III study, inhibition of angiopoietins 1 and 2 with trebananib resulted in a significant prolongation in progression-free survival. The results of the ongoing TRINOVA-1, -2, and -3 trials will define the role of trebananib in the management of patients with advanced epithelial ovarian cancer. [49]

BIBF-1120 is a triple angiokinase inhibitor of VEGFR, PDGFR, and FGFR. This agent has shown promising activity in a randomized Phase II placebo-controlled trial in relapsed ovarian cancer in the maintenance setting. The study showed a 36 week PFS of 16.3% vs. 5.0% in favour of BIBF 1120 compared to the placebo group with a hazard ratio of 0.65 (95% CI, 0.42 to 1.02; $P = 0.06$). [50]

5.1. Pazopanib

Pazopanib inhibits this signalling pathway via ATP-competitive inhibition of VEGFR-1, VEGFR-2, and VEGFR-3; platelet-derived growth factor receptor (PDGFR)- α , PDGFR- β ; fibroblast growth factor receptor (FGFR)-1, FGFR-3, and c-Kit. [51] Friedlander et al. reported responses to pazopanib in 11 of 36 patients (31%) with advanced ovarian cancer. The median time to response was 29 days and median response duration 113 days. The overall response rate was 18% in patients with measurable disease at baseline. [52]

De Bois et al. reported results of the AGO OVAR16 trial investigating the role of pazopanib as maintenance treatment for patients with advanced ovarian cancer in the front-line setting following induction chemotherapy. A total of 940 patients with stage 3 or 4 disease were randomized. The median time from diagnosis to randomization was 7.1 months in the placebo arm and 7.0 months in the pazopanib arm. At a median follow-up of 24 months, patients in the pazopanib arm had a prolonged PFS compared to a placebo, 17.9 versus 12.3 months, respectively (HR = 0.766; 95% CI: 0.64-0.91; $p = 0.0021$). Sensitivity and subgroup analyses of

PFS, and analysis of PFS by GCIG criteria, were consistent with the primary analysis. The first interim analysis for OS (only 189 OS events = 20.1% of the population) showed no difference between the arms. Pazopanib treatment was associated with a higher incidence of adverse and serious adverse events (26% vs. 11%). The most common toxicities included hypertension, diarrhoea, nausea, headache, fatigue, and neutropenia. The AGO investigators concluded that pazopanib maintenance therapy provided a statistically significant and clinically meaningful PFS benefit in patients with advanced ovarian cancer. It is possible that pazopanib will be incorporated into the armamentarium of ovarian cancer drugs in routine practice in the near future. The OS data are not mature. [53–54]

5.2. PARP inhibitors

A new class of agents that inhibit poly-adenosine diphosphate [ADP]-ribose polymerase (PARP) demonstrated significant activity in patients with recurrent disease, especially those with a germline mutation in BRCA1 or BRCA2. Several recent ongoing studies are evaluating the activity of PARP inhibitors in epithelial ovarian cancer, primarily in BRCA-mutation carriers. A proof-of-concept Phase I study of olaparib was conducted in 50 BRCA-carrier patients with relapsed ovarian cancer. This study showed a 40% objective response rate judged by RECIST criteria and/or a CA125 response assessed by a greater than 50% decline in CA125. Patients that were platinum sensitive had a higher chance of achieving a response to olaparib. [55] In an international multicenter Phase II study, 57 BRCA-carriers patients with recurrent ovarian cancer were enrolled in two sequential cohorts of two doses of olaparib (400 mg and 100 mg orally twice daily). The overall response rate as per the RECIST criteria was 33% in the 400 mg and 13% in the 100 mg cohort. These results suggest a possible dose-response effect. [56] Finally, PARP inhibitors may also show activity in patients with sporadic disease without germline BRCA1 or BRCA2 mutations. Gelmon et al. had shown a 24% objective response rate in relapsed ovarian cancer in the absence of BRCA1 or BRCA2 mutations to PARP inhibitors. Olaparib was well tolerated with the most common adverse events being fatigue in 70% of patients, nausea in 66%, vomiting in 39%, and decreased appetite in 36%. [57]

Ledermann et al. studied the role of olaparib maintenance in the subset of patients with relapsed platinum-sensitive high-grade serous ovarian cancer. The study was a double-blind, placebo-controlled, Phase II study. Results showed a significantly higher PFS rate compared to a placebo (median, 8.4 months vs. 4.8 months, with a hazard ratio for progression of 0.35, $P < 0.001$). OS analysis is not yet mature. [58]

Olaparib was also investigated in combination with chemotherapy in patients with advanced ovarian cancer. In a randomized, open-label, Phase II study, adult patients with platinum-sensitive, recurrent, high-grade serous ovarian cancer who had received up to three previous courses of platinum-based chemotherapy and who were progression-free for at least six months before randomization received either olaparib (200 mg capsules twice daily, administered orally on days one to 10 of each 21-day cycle) plus paclitaxel (175 mg/m², administered intravenously on day one) and carboplatin (area under the curve [AUC] 4 mg/mL per min, according to the Calvert formula, administered intravenously on day one). Subsequently, patients received either olaparib monotherapy (400 mg capsules twice daily, given continu-

ously) until disease progression in the olaparib plus chemotherapy group, or paclitaxel (175 mg/m² on day one) and carboplatin (AUC 6 mg/mL per min on day one) then no further treatment in the chemotherapy alone group. The progression-free survival was significantly longer in the olaparib plus chemotherapy group (median 12.2 months [95% CI 9.7–15.0]) compared to chemotherapy alone group (median 9.6 months; 95% CI 9.1–9.7 and a HR 0.51; 95% CI 0.34–0.77; p=0.0012) — the difference was more pronounced in patients with BRCA mutations (HR 0.21 [0.08–0.55]; p=0.0015). [59]

Both the U.S. Food and Drug Administration and the EMA granted accelerated approval for olaparib (Lynparza) in the treatment of women with advanced ovarian cancer associated with defective BRCA genes, as detected by an FDA-approved test. [60]

6. Summary

Recurrent ovarian cancer is not curable. The goals of therapy should focus on palliation of cancer-related symptoms, extension of life, and maintenance of quality of life. The outlook has clearly improved over the last decade, due to an increase in options for the management of recurrent disease. Secondary cytoreduction has been advocated, but it remains controversial. For patients with platinum-sensitive disease retreatment with a platinum or a platinum-containing combination, such as carboplatin, should be considered. For patients with platinum-refractory or platinum-resistant disease, clinical trials should be considered. For patients who are not entering a trial, treatment with agents like PLD, paclitaxel, docetaxel, topotecan, gemcitabine, pemetrexed, ixabepilone, or oral etoposide can be considered. Despite the advances made in biological and targeted therapies like bevacizumab and pazopanib in extending disease-free survival in patients with recurrent advanced ovarian cancer, further research is needed to better understand the safety and effectiveness, the optimal duration and timing of treatment, and activity in association with other chemotherapeutic agents.

Author details

Bernardo L. Rapoport

Address all correspondence to: brapoort@rosebankoncology.co.za

The Medical Oncology Center of Rosebank, Saxonwold, Johannesburg, South Africa

References

- [1] S. A. Cannistra. Cancer of the ovary. *The New England Journal of Medicine*, vol. 351, no. 24, pp. 2519–2529, 2004.

- [2] G. J. Rustin, M. E. van der Burg, C. L. Griffin, et al.; MRC OV05; EORTC 55955 investigators. Early versus delayed treatment of relapsed ovarian cancer (MRC OV05/EORTC 55955): a randomised trial. *Lancet*, vol. 376, no. 9747, pp. 1155–63, 2010.
- [3] G. J. Rustin, I. Vergote, E. Eisenhauer, et al. Definitions for response and progression in ovarian cancer clinical trials incorporating RECIST 1.1 and CA 125 agreed by the Gynecological Cancer Intergroup (GCIG). *International Journal of Gynecological Cancer*, vol. 21, no. 2, pp. 419–423, 2011.
- [4] M. Markman, R. Rothman, T. Hakes, et al. Second-line platinum therapy in patients with ovarian cancer previously treated with cisplatin. *Journal of Clinical Oncology*, vol. 9, no. 3, pp. 389–93, 1991.
- [5] N. Colombo, J. L. Speyer, M. Green, et al. Phase II study of carboplatin in recurrent ovarian cancer: severe hematologic toxicity in previously treated patients. *Cancer Chemotherapy and Pharmacology*, vol. 23, no. 5, pp. 323–8, 1989.
- [6] M. K. Parmar, J. A. Ledermann, N. Colombo, et al.; ICON and AGO Collaborators. Paclitaxel plus platinum-based chemotherapy versus conventional platinum-based chemotherapy in women with relapsed ovarian cancer: the ICON4/AGO-OVAR-2.2 trial. *Lancet*, vol. 361, no. 9375, pp. 2099–106, 2003.
- [7] J. Pfisterer, M. Plante, I. Vergote, et al. Gemcitabine plus carboplatin compared with carboplatin in patients with platinum-sensitive recurrent ovarian cancer: an intergroup trial of the AGO-OVAR, the NCIC CTG, and the EORTC GCG. *Journal of Clinical Oncology*, vol. 24, no. 29, pp. 4699–707, 2006.
- [8] U. Wagner, C. Marth, R. Largillier, et al. Final overall survival results of phase III GCIG CALYPSO trial of pegylated liposomal doxorubicin and carboplatin vs paclitaxel and carboplatin in platinum-sensitive ovarian cancer patients. *British Journal of Cancer*, vol. 107, no. 4, pp. 588–91, 2012.
- [9] P. A. Vasey, G. C. Jayson, A. Gordon, et al. Scottish Gynaecological Cancer Trials Group. Phase III randomized trial of docetaxel-carboplatin versus paclitaxel-carboplatin as first-line chemotherapy for ovarian carcinoma. *Journal of the National Cancer Institute*, vol. 96, no. 22, pp. 1682–91, 2004.
- [10] D. A. Vorobiof, B. L. Rapoport, M. R. Chasen, et al. Phase II clinical trial of carboplatin and docetaxel in patients with metastatic ovarian cancer: active combination with low incidence of peripheral neuropathy. *International Journal of Gynecological Cancer*, vol. 13, no. 3, pp. 287–91, 2003.
- [11] D. Kudlowitz, F. Muggia. Defining risks of taxane neuropathy: insights from randomized clinical trials. *Clinical Cancer Research*, vol. 19, no. 17, pp. 4570–7, 2013.
- [12] B. L. Rapoport, D. A. Vorobiof, C. Slabber, et al. Phase II study of pegylated liposomal doxorubicin and carboplatin in patients with platinum-sensitive and partially

- platinum-sensitive metastatic ovarian cancer. *International Journal of Gynecological Cancer*, vol. 19, no. 6, pp. 1137–41, 2009.
- [13] A. Alvarez Secord, A. Berchuck, R. V. Higgins, et al. A multicenter, randomized, phase 2 clinical trial to evaluate the efficacy and safety of combination docetaxel and carboplatin and sequential therapy with docetaxel then carboplatin in patients with recurrent platinum-sensitive ovarian cancer. *Cancer*, vol. 118, no. 13, pp. 3283–93, 2012.
- [14] N. Colombo, E. Kutarska, M. Dimopoulos, et al. Randomized, open-label, phase III study comparing paclitaxel (EPO906) with pegylated liposomal doxorubicin in platinum-refractory or -resistant patients with recurrent epithelial ovarian, primary fallopian tube, or primary peritoneal cancer. *Journal of Clinical Oncology*, vol. 30, no. 31, pp. 3841–7, 2012.
- [15] M. Markman, J. Hall, D. Spitz, et al. Phase II trial of weekly single-agent paclitaxel in platinum/paclitaxel-refractory ovarian cancer. *Journal of Clinical Oncology*, vol. 20, no. 9, pp. 2365–9, 2002.
- [16] E. L. Trimble, J. D. Adams, D. Vena, et al. Paclitaxel for platinum-refractory ovarian cancer: results from the first 1,000 patients registered to National Cancer Institute Treatment Referral Center 9103. *Journal of Clinical Oncology*, vol. 12, pp. 2405–10, 1993.
- [17] P. Francis, J. Schneider, L. Hann, et al. Phase II trial of docetaxel in patients with platinum-refractory advanced ovarian cancer. *Journal of Clinical Oncology*, vol. 12, no. 11, pp. 2301–8, 1994.
- [18] J. Sehouli, D. Stengel, P. Harter, et al. Topotecan weekly versus conventional 5-day schedule in patients with platinum-resistant ovarian cancer: a randomized multicenter phase II trial of the North-Eastern German Society of Gynecological Oncology Ovarian Cancer Study Group. *Journal of Clinical Oncology* vol. 29, no. 2, pp. 242–8, 2011.
- [19] Lund B, Hansen OP, Theilade K, et al. Phase II study of gemcitabine (2',2'-difluorodeoxycytidine) in previously treated ovarian cancer patients. *Journal of the National Cancer Institute*, vol. 86, no. 20, pp. 1530–3, 1994.
- [20] D. S. Miller, J. A. Blessing, C. N. Krasner, et al. Phase II evaluation of pemetrexed in the treatment of recurrent or persistent platinum-resistant ovarian or primary peritoneal carcinoma: a study of the Gynecologic Oncology Group. *Journal of Clinical Oncology*, vol. 27, no. 16, pp. 2686–91, 2009.
- [21] K. De Geest, J. A. Blessing, R. T. Morris, et al. Phase II clinical trial of ixabepilone in patients with recurrent or persistent platinum- and taxane-resistant ovarian or primary peritoneal cancer: a gynecologic oncology group study. *Journal of Clinical Oncology*, vol. 28, no. 1, pp. 149–53, 2010.
- [22] P. G. Rose, J. A. Blessing, A. R. Mayer et al. Prolonged oral etoposide as second-line therapy for platinum-resistant and platinum-sensitive ovarian carcinoma: a Gynecologic

- logic Oncology Group study. *Journal of Clinical Oncology*, vol. 16, no. 2, pp. 405–410, 1998.
- [23] J. Sehouli, D. Stengel, P. Harter, et al. Topotecan weekly versus conventional 5-day schedule in patients with platinum-resistant ovarian cancer: a randomized multicenter phase II trial of the North-Eastern German Society of Gynecological Oncology Ovarian Cancer Study Group. *Journal of Clinical Oncology*, vol. 29, no. 2, pp. 242–8, 2011.
- [24] T. A. Lawrie, A. Bryant, A. Cameron, et al. Pegylated liposomal doxorubicin for relapsed epithelial ovarian cancer. *The Cochrane Library* (2013).
- [25] J. S. Berek, N. F. Hacker, L. D. Lagasse, et al. Survival of patients following secondary cytoreductive surgery in ovarian cancer. *Obstetrics and Gynecology*, vol. 61, no. 2, pp. 189–93, 1983.
- [26] . Sehouli, R. Richter, E. I. Braicu, et al. Role of secondary cytoreductive surgery in ovarian cancer relapse: who will benefit? A systematic analysis of 240 consecutive patients. *Journal of Surgical Oncology*, vol. 102 no. 6, pp. 656–62, 2010.
- [27] A. R. Munkarah, R. L. Coleman. Critical evaluation of secondary cytoreduction in recurrent ovarian cancer. *Gynecologic Oncology*, vol. 95, no. 2, pp. 273–280, 2004.
- [28] M. Güngör, F. Ortaç, M. Arvas et al. The role of secondary cytoreductive surgery for recurrent ovarian cancer. *Gynecologic Oncology*, vol. 97, no. 1, pp. 74–79, 2005.
- [29] T. Onda, H. Yoshikawa, T. Yasugi, et al. Secondary cytoreductive surgery for recurrent epithelial ovarian carcinoma: proposal for patients selection. *British Journal of Cancer*, vol. 92, no. 6, pp. 1026–1032, 2005.
- [30] R. Salani, A. Santillan, M. L. Zahurak, et al. Secondary cytoreductive surgery for localized, recurrent epithelial ovarian cancer: analysis of prognostic factors and survival outcome. *Cancer*. vol. 109, no. 4, pp. 685–691, 2007.
- [31] D. S. Chi, K. McCaughy, J. P. Diaz, et al. Guidelines and selection criteria for secondary cytoreductive surgery in patients with recurrent, platinum sensitive epithelial ovarian carcinoma. *Cancer*, vol. 106, no. 9, pp. 1933–1939, 2006.
- [32] D. F. Kolomainen, D. P. Barton. Surgical management of bowel obstruction in gynecological malignancies. *Current Opinion in Supportive and Palliative Care*, vol. 5, no. 1, pp. 55–9, 2011.
- [33] J. D. Patel, M. A. Socinski, E. B. Garon, et al. PointBreak: A randomized phase III study of pemetrexed plus carboplatin and bevacizumab followed by maintenance pemetrexed and bevacizumab versus paclitaxel plus carboplatin and bevacizumab followed by maintenance bevacizumab in patients with stage IIIb or IV nonsquamous non-small-cell lung cancer. *Journal of Clinical Oncology*, vol. 31, no. 34, pp. 4349–57, 2013.

- [34] D. Cunningham, I. Lang, E. Marcuello, et al. AVEX study investigators. Bevacizumab plus capecitabine versus capecitabine alone in elderly patients with previously untreated metastatic colorectal cancer (AVEX): an open-label, randomised phase 3 trial. *The Lancet Oncology*, vol. 14, no. 11, pp. 1077–85, 2013.
- [35] H. I. Hurwitz, N. C. Tebbutt, F. Kabbinavar, et al. Efficacy and safety of bevacizumab in metastatic colorectal cancer: pooled analysis from seven randomized controlled trials. *The Oncologist*, vol. 18, no. 9, pp. 1004–12, 2013.
- [36] R. A. Burger, M. W. Sill, B. J. Monk, et al. Phase II trial of bevacizumab in persistent or recurrent epithelial ovarian cancer or primary peritoneal cancer: a Gynecologic Oncology Group Study. *Journal of Clinical Oncology*, vol. 25, no. 33, pp. 5165, 2007.
- [37] S. A. Cannistra, U. A. Matulonis, R. T. Penson, et al. Phase II study of bevacizumab in patients with platinum-resistant ovarian cancer or peritoneal serous cancer. *Journal of Clinical Oncology*, vol. 25, no. 33, pp. 5180–6, 2007.
- [38] R. A. Burger, M. F. Brady, M. A. Bookman, et al. Gynecologic Oncology Group incorporation of bevacizumab in the primary treatment of ovarian cancer. *The New England Journal of Medicine*, vol. 365, no. 26, pp. 2473–2483, 2011.
- [39] T. J. Perren, A. M. Swart, J. Pfisterer, et al.; ICON7 Investigators. A phase 3 trial of bevacizumab in ovarian cancer. *The New England Journal of Medicine*, vol. 365, no. 26, pp. 2484–96, 2011.
- [40] C. Aghajanian, S. V. Blank, B. A. Goff, et al. OCEANS: a randomized, double-blind, placebo-controlled phase III trial of chemotherapy with or without bevacizumab in patients with platinum-sensitive recurrent epithelial ovarian, primary peritoneal, or fallopian tube cancer. *Journal of Clinical Oncology*, vol. 30, no. 17, pp. 2039–45, 2012.
- [41] E. Pujade-Lauraine, F. Hilpert, B. Weber, et al. Bevacizumab combined with chemotherapy for platinum-resistant recurrent ovarian cancer: the AURELIA open-label randomized phase III trial. *Journal of Clinical Oncology*, vol. 32, no. 13, pp. 1302–8, 2014.
- [42] C. A. Heckman, T. Holopainen, M. Wirzenius, et al. The tyrosine kinase inhibitor cediranib blocks ligand-induced vascular endothelial growth factor receptor-3 activity and lymphangiogenesis. *Cancer Research*, vol. 68, no. 12, pp. 4754–4762, 2008.
- [43] S. R. Wedge, J. Kendrew, L. F. Hennequin, et al. AZD2171: a highly potent, orally bioavailable, vascular endothelial growth factor receptor-2 tyrosine kinase inhibitor for the treatment of cancer. *Cancer Research*, vol. 65, no. 10, pp. 4389–4400, 2005.
- [44] U. A. Matulonis, S. Berlin, P. Ivy, et al. Cediranib, an oral inhibitor of vascular endothelial growth factor receptor kinases, is an active drug in recurrent epithelial ovarian, fallopian tube, and peritoneal cancer. *Journal of Clinical Oncology*, vol. 27, no. 33, pp. 5601–6, 2009.

- [45] F. A. Raja, C. L. Griffin, W. Qian, et al. Initial toxicity assessment of ICON6: a randomised trial of cediranib plus chemotherapy in platinum-sensitive relapsed ovarian cancer. *British Journal of Cancer*, vol. 105, no. 7, pp. 884–9, 2011.
- [46] J. A. Ledermann, T. J. Perren, F. A. Raja, et al. on behalf of the ICON6 Collaborators. Randomised double-blind phase III trial of cediranib (azd 2171) in relapsed platinum sensitive ovarian cancer: results of the icon6 trial. *International Journal of Gynecological Cancer*, vol. 23, no. 8, 2013.
- [47] R. L. Coleman, L. R. Duska, P. T. Ramirez, et al. Phase 1–2 study of docetaxel plus aflibercept in patients with recurrent ovarian, primary peritoneal, or fallopian tube cancer. *The Lancet Oncology*, vol. 12, no. 12, pp. 1109–17, 2011.
- [48] B. Y. Karlan, A. M. Oza, G. E. Richardson, et al. Randomized, double-blind, placebo-controlled phase II study of AMG 386 combined with weekly paclitaxel in patients with recurrent ovarian cancer. *Journal of Clinical Oncology*, vol. 30, no. 4, pp. 362–71, 2102.
- [49] J. Monk, A. Poveda, I. Vergote, et al. Anti-angiopoietin therapy with trebananib for recurrent ovarian cancer (TRINOVA-1): a randomised, multicentre, double-blind, placebo-controlled phase 3 trial. *The Lancet Oncology*, vol. 15, no. 8, pp. 799–808, 2014.
- [50] J. A. Ledermann, A. Hackshaw, S. Kaye, et al. Randomized phase II placebo-controlled trial of maintenance therapy using the oral triple angiokinase inhibitor BIBF 1120 after chemotherapy for relapsed ovarian cancer. *Journal of Clinical Oncology*, vol. 29, no. 28, pp. 3798–804, 2011.
- [51] G. Sonpavde, T. E. Hutson. Pazopanib: A novel multitargeted tyrosine kinase inhibitor. *Current Oncology Reports*, vol. 9, no 2, pp. 115–119, 2007.
- [52] M. Friedlander, K. C. Hancock, D. Rischin, et al. A phase II, open-label study evaluating pazopanib in patients with recurrent ovarian cancer. *Gynecologic Oncology*, vol. 119, no. 1, pp. 32–7, 2010.
- [53] A. Floquet, I. Vergote, N. Colombo, et al. Progression-free survival by local investigator versus independent central review: comparative analysis of the AGO-OVAR16 Trial. *Gynecologic Oncology*, vol. 136, no. 1, pp. 37–42, 2015.
- [54] A. du Bois, A. Floquet, J. W. Kim, et al. Incorporation of pazopanib in maintenance therapy of ovarian cancer. *Journal of Clinical Oncology*, vol. 32, no. 30, pp. 3374–82, 2014.
- [55] P. C. Fong, T. A. Yap, D. S. Boss, et al. Poly ADP-ribose polymerase inhibition: frequent durable responses in BRCA carrier ovarian cancer correlating with platinum-free interval. *Journal of Clinical Oncology*, vol. 28, no. 15, pp. 2512–9, 2010.
- [56] M. W. Audeh, J. Carmichael, R. T. Penson, et al. Oral poly ADP-ribose polymerase inhibitor olaparib in patients with BRCA1 or BRCA2 mutations and recurrent ovarian cancer: a proof-of-concept trial. *Lancet*, vol. 376, no. 9737, pp. 245–51, 2010.

- [57] K. A. Gelmon, M. Tischkowitz, H. Mackay, et al. Olaparib in patients with recurrent high-grade serous or poorly differentiated ovarian carcinoma or triple-negative breast cancer: a phase 2, multicentre, open-label, non-randomised study. *The Lancet Oncology*, vol. 12, no. 9, pp. 852–61, 2011.
- [58] J. Ledermann, P. Harter, C. Gourley, et al. Olaparib maintenance therapy in platinum-sensitive relapsed ovarian cancer. *The New England Journal of Medicine* vol. 366, no. 15, pp.1382–92, 2012.
- [59] A. M. Oza, D. Cibula, A. O. Benzaquen, et al. Olaparib combined with chemotherapy for recurrent platinum-sensitive ovarian cancer: a randomised phase 2 trial. *The Lancet Oncology*. vol. 16, no. 1, pp. 87–97, 2015.
- [60] E. D. Deeks. Olaparib: first global approval. *Drugs*. vol. 75, no. 2, pp. 231–40.

